

jcd

vol. 30 issue 3

Journal of Cosmetic Dentistry



How Pascal Magne Teaches Tooth Morphology

Xue Lily Du, BSc, MSc

7 Top Academic Programs in Esthetic Dentistry

AACD and the Next Generation

FALL 2014

AACD American Academy
of Cosmetic Dentistry®

INTRODUCING

Adhese® Universal

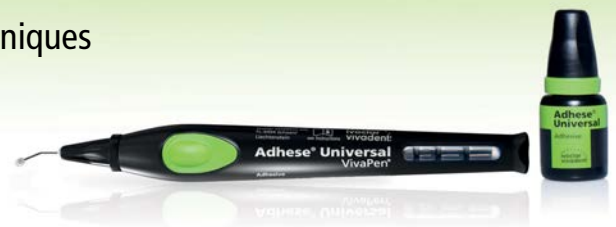Light-curing dental adhesive

All in one click...
Up to 190 applications.



The dental adhesive for all restorations and techniques

- Single adhesive for all materials and etching techniques
- High bond strength and virtually no post-operative sensitivity
- Available in the revolutionary VivaPen®



100% CUSTOMER SATISFACTION
GUARANTEED!



ivoclarvivadent.com

For more information, call us at 1-800-533-6825 in the U.S., 1-800-263-8182 in Canada.
© 2014 Ivoclar Vivadent, Inc. Ivoclar Vivadent, VivaPen and Adhese are registered trademarks of Ivoclar Vivadent, Inc.

ivoclar
vivadent®
passion vision innovation

EDITOR-IN-CHIEF Edward Lowe, DMD, AAACD
Vancouver, BC, Canada, edlowe@mac.com

EXECUTIVE DIRECTOR Barbara J. Kachelski, MBA, CAE, barbk@aacd.com

MANAGING EDITOR Tracy Skenandore, tracy@aacd.com

EDITORIAL ASSISTANT Denise Sheriff, denises@aacd.com

ART DIRECTOR Lynnette Rogers, lynnetter@aacd.com

GRAPHIC DESIGNER Sherry Misener, sherrym@aacd.com

EDITORIAL CONSULTANT Juliette Kurtz, publications@aacd.com

COMMUNICATIONS SPECIALIST Tiffany Stronghart, tiffanys@aacd.com

MANUSCRIPT DEVELOPMENT LIAISON Allison DiMatteo, MPS, allison@cremedellacreme.org

CHIEF MARKETING OFFICER Michael DiFrisco, michaeld@aacd.com

ADVERTISING AND SPONSORSHIP DIRECTOR OF STRATEGIC PARTNERSHIPS Jeff Roach, jeffr@aacd.com

CONTRIBUTING EDITORS Julie M. Gillis, DDS, AAACD, Grand Junction, CO
James H. Peyton, DDS, FAACD, Bakersfield, CA
Nelson A. Rego, CDT, AAACD, Santa Fe Springs, CA
Gregory B. Wright, DDS, FAACD, Southlake, TX

EDITORIAL MISSION

The mission of the *Journal of Cosmetic Dentistry* is to educate AACD members, as well as other professionals in the field, on the art and science of cosmetic dentistry. We will endeavor to do this by publishing well-researched, peer-reviewed articles accompanied by high-quality, comprehensive clinical imagery. The objective is to enhance readers' knowledge and skills while showcasing the latest cosmetic techniques and procedures. The *Journal of Cosmetic Dentistry* will strive to help readers become better clinicians, so they can offer their patients the best—and most responsible—treatment possible.

ADVERTISING POLICY

All advertising appearing in the *Journal of Cosmetic Dentistry (jcd)* is approved by the editorial team. Advertisements are not endorsed by the jcd or AACD.

AACD OFFICE

402 West Wilson Street, Madison, WI 53703
800.543.9220 • 608.222.8583
fax 608.222.9540 • info@aacd.com • www.aacd.com

Advertising: 800.543.9220 • 608.222.8583 or jeffr@aacd.com
Editorial: 800.543.9220 • 608.222.8583 or publications@aacd.com

EDITORIAL REVIEW BOARD

Pinhas Adar, MDT, CDT, Atlanta, GA
Irfan Ahmad, BDS, Middlesex, United Kingdom
Gary Alex, DMD, AAACD, Huntington, NY
Edward P. Allen, DDS, PhD, Dallas, TX
Chad J. Anderson, DMD, MS, Fresno, CA
Elizabeth M. Bakeman, DDS, FAACD, Grand Rapids, MI
Lee Ann Brady, DMD, Glendale, AZ
Ricardo M. Carvalho, DDS, PhD, Vancouver, BC, Canada
Christian Coachman, DDS, CDT, São Paulo, Brazil
John C. Cranham, DDS, Chesapeake, VA
Michael W. Davis, DDS, Santa Fe, NM
Gerald E. Denehy, DDS, Iowa City, IA
Newton Fahl Jr., DDS, MS, Curitiba-PR, Brazil
Jonathan L. Ferencz, DDS, FACP, New York, NY
Scott W. Finlay, DDS, FAACD, Arnold, MD
Hugh D. Flax, DDS, AAACD, Atlanta, GA
David A. Garber, DMD, Atlanta, GA
Ronald E. Goldstein, DDS, FACD, FICD, Atlanta, GA
Steve D. Hoofard, CDT, AAACD, Hermiston, OR
Kenneth Hovden, DDS, AAACD, Daly City, CA
Nelson Y. Howard, DDS, AAACD, San Marcos, CA
Ronald D. Jackson, DDS, FAACD, Middleburg, VA
Sang K. Jun, CDT, Monterey, CA
Michael J. Koczarski, DDS, AAACD Woodinville, WA
John C. Kois, DMD, MSD, Seattle, WA
Gerard Kugel, DMD, MS, PhD, Boston, MA
Cobi J. Landsberg, DMD, Tel Aviv, Israel
Ryan Langer, AAACD, Eagle, ID
David A. Little, DDS, San Antonio, TX
Robert A. Lowe, DDS, Charlotte, NC
Robert C. Margeas, DDS, Des Moines, IA
Frank J. Milnar, DDS, AAACD, St. Paul, MN
Ricardo Mitrani, DDS, MSD, Mexico City, Mexico
Carlos A. Munoz, DDS, MSD, Buffalo, NY
Thomas W. Nabors III, DDS, AAACD, Nashville, TN
W. Peter Nordland, DMD, MS, La Jolla, CA
Aikaterini G. Papathanasiou, DDS, Boston, MA
Gary M. Radz, DDS, Denver, CO
Christopher D. Ramsey, DMD, AAACD, Jupiter, FL
Nelson A. Rego, CDT, AAACD, Santa Fe Springs, CA
Dwight G. Rickert, CDT, AAACD, Indianapolis, IN
Robert G. Ritter, DMD, Jupiter, FL
Matthew R. Roberts, CDT, AAACD, Idaho Falls, ID
Henry Salama, DMD, Atlanta, GA
Maurice A. Salama, DMD, Atlanta, GA
Michael R. Sesemann, DDS, FAACD, Omaha, NE
Michael Sonick, DMD, Fairfield, CT
Rhys D. Spoor, DDS, AAACD, Seattle, WA
Thomas T. Teel, DDS, Fort Wayne, IN
Thomas F. Trinkner, DDS, AAACD, Columbia, SC
Eric Van Dooren, DDS, Antwerp, Belgium
Marcos A. Vargas, DDS, Iowa City, IA
Nondas Vlachopoulos, CDT, Athens, Greece
Dennis J. Wells, DDS, AAACD, Brentwood, TN
Barbara Warner Wojdan, CDT, AAACD, Oldsmar, FL

Reprints

High-quality reprints with possible customization are available for authors and advertisers. Please contact Hope.robinson@sheridan.com, Content Sales Specialist who will work with you to get the exact reprint you would like for your presentations, lectures, or patient literature.

Features

- 26** New Concept is Creating Positive Momentum ✦
Pascal Magne, DMD, PhD
- 28** Cover Visual "Essay" Unleashing My Creativity ✦
Xue Lily Du, BSc, MSc
- 36** Focusing on Expertise, Leadership Skills, and Passion ✦
Gerald E. Denehy, DDS, MS
Deborah S. Cobb, DDS, MS
- 38** Minimally Invasive Management of Missing Maxillary Lateral Incisors ✦
Rawa Alammari, DDS, MHI, MS
So Ran Kwon, DDS, MS, PhD
- 48** An Innovative Interdisciplinary Teaching Environment ✦
Barry D. Hammond, DMD
- 50** A Blended, Novel Team Approach in Academic Esthetic Dentistry ✦
Barry D. Hammond, DMD
Jae Seon Kim, DDS, MSD, FACP
Jimmy Londono, DDS
Marko Tadros, DMD
Aram Torosian, CDT, MDC, AS
- 62** Disciplined Training That is Both Traditional & Modern ✦
Gerard Kugel, DMD, MS, PhD
Aikaterini Papathanasiou, DDS, CAGS
- 64** Effect of Phosphoric Acid... ✦
Jonathan S. Bishop, BS
William W. Chao, BA
Melissa E. Ing, DMD
Steven E. Eisen, DMD
Aikaterini Papathanasiou, DDS, CAGS
Gerard Kugel, DMD, MS, PhD
- 70** A Systematic Approach: Performing What They Learn ✦
James F. Simon, DDS, MEd
Mojdeh Dehghan, DDS
Darnee Tantbirojn, DDS, MS, PhD
- 72** Investigative Prevention for Tooth Erosion ✦
Alex C. Fitzhugh, BS
Mojdeh Dehghan, DDS
Darane Tantbirojn, DDS, MS, PhD
James F. Simon, DDS, MEd
- 80** Extensive Training in the Realm of Esthetics ✦
Lee W. Boushell, DMD, MS
André V. Ritter, DDS, MS, MBA

82 Pragmatic Esthetics ✦
Vilhelm G. Olafsson, DDS
Lee W. Boushell, DMD, MS

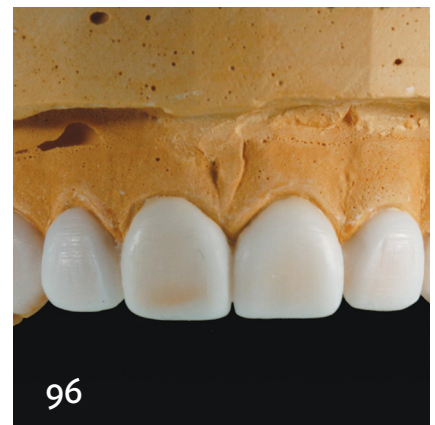
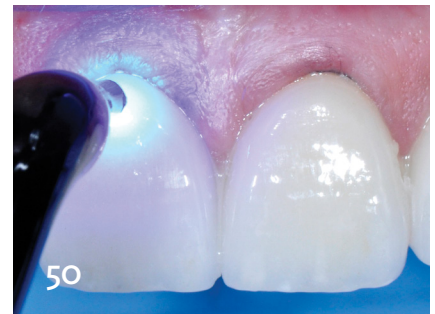
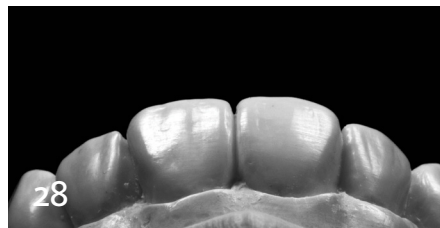
94 The "Crown Jewel" ✦
John R. Calamia, DMD

96 Esthetic Smile Design (CE article) ✦
Andi-Jean Miro, DDS
Jill Varriale, DMD
John R. Calamia, DMD



110 AACD Self-Instruction Continuing Education ✦

112 Book Review
Esthetic and Restorative Dentistry:
Material Selection and Technique
(2nd edition) ✦



Columns

8 Editor's Message
It's Academic...
Edward Lowe, DMD, AAACD

10 Up Front
Esthetic Dentistry in Dental School
Curricula: Challenging the Paradigm
Sillas Duarte, Jr., DDS, MS, PhD

2014 Statement of Ownership, Management and Circulation

Statement of Ownership, Management and Circulation, required by Title 39, United States Code 3685. Title of publication: *Journal of Cosmetic Dentistry*. Date of filing: September 29, 2014. Publication number: 1532-8910, USPS# 10452. Frequency of issue: quarterly. Annual subscription price: members, included in the membership dues; non-members/subscribers, \$200.00 (US and Canada), \$240.00 (all other countries) by the American Academy of Cosmetic Dentistry®, 402 West Wilson Street, Madison, WI, 53703. 800.543.9220 OR 608.222.8583. Periodicals postage paid in Madison, WI, and additional offices.

Mailing address of publisher: American Academy of Cosmetic Dentistry, 402 West Wilson Street, Madison, WI 53703. County: Dane. Name and address of the Editor: Edward Lowe, DMD, 402 West Wilson Street, Madison, WI 53703. Name and address of the Managing Editor: Tracy Skenandore, 402 West Wilson Street, Madison, WI 53703. Average number of copies each issue during preceding 12 months: Total number of copies (net press run): 6914; mailed outside-county paid subscriptions stated on PS Form 3541 5470: paid distribution by other classes of mail through the USPS: 1059; total paid distribution: 6529; free or nominal rate copies mailed at other classes through the USPS: 32; free or nominal rate distribution: 5; total free or nominal rate distribution: 37; total distribution: 6566; copies not distributed: 348; percent paid: 99. Number of copies of single issue published nearest to filing date: total number of copies (net press run): 6875; mailed outside-county paid subscriptions stated on PS Form 3541: 5476; paid distribution by other classes of mail through the USPS: 1066; total paid distribution: 6542. Free or nominal rate copies mailed at other classes through the USPS: 3; free or nominal rate distribution outside the mail: 0; total free or nominal rate distribution: 3; total distribution: 6545; copies not distributed: 330; percent paid: 99.9. I certify that all information furnished is correct and complete. Signed Tracy Skenandore, Managing Editor.

Think of us as the **tooth fairy**



(Without the sneaking into your house part)

**With Springstone's
affordable payment
solutions, it's
easier than ever
to find money**

Discover the Springstone Patient Financing advantage:

- Higher approval rates so more patients get the treatment they need¹
- Low fixed rates starting at 3.99% APR²
- Plans from 24 to 84 months for greater affordability

Plus save up to 20% a month in practice fees.³

Call 844-766-SAVE today



¹Based on findings from an independent research study of Springstone customers conducted by M. Lucier Consulting, July 2012.

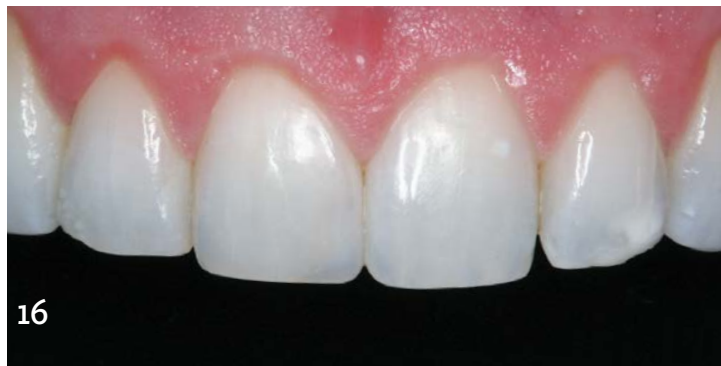
²The APR ranges from 3.99% to 17.99%. For example, a loan for \$10,000 with an 8.99% APR for 72 months will have a monthly payment of \$181. The APR will be determined based on the applicant's credit at time of application. All loans made by NBT Bank, N.A., Member FDIC, Equal Housing Lender.

³Publicly available data for other patient financing solutions as of July 2014.



Departments

- 12 Behind the Cover
Expressing the Finesse in
Tooth Morphology ♦
Xue Lily Du, BSc, MSc
- 14 Scientific Session
—San Francisco 2015
APEX Teaches Students What They
Don't Learn in Dental School ♦
Tiffany Stronghart, MA
- 16 Accreditation Essentials
Layering and Blending Composite ♦
Priya S. Tirumalasetty, DDS, FAGD
- 24 Examiners' Commentary
Envisioning the Final Outcome ♦
J.A. Reynolds, DDS, AAACD
- 92 Credentialing Announcement
Newly Accredited Fellows



HAVE YOU MOVED? ARE YOU PLANNING TO? LET US KNOW!

Do you have a new address? Please help us to deliver your *Journal of Cosmetic Dentistry (jCD)* in a timely fashion. If you have a new mailing address, contact: publications@aacd.com and let us know where we should deliver your copy of *jCD*. Thank you!



AACD MISSION STATEMENT

The American Academy of Cosmetic Dentistry is dedicated to advancing excellence in the art and science of cosmetic dentistry and encouraging the highest standards of ethical conduct and responsible patient care.



The *Journal of Cosmetic Dentistry* (ISSN 1532-8910), USPS (10452), published quarterly. \$200 per year (U.S. & Canada) or \$240 per year (All other countries), single issues available upon request, by the American Academy of Cosmetic Dentistry®, 402 West Wilson Street, Madison, WI 53703. 800.543.9220 OR 608.222.8583. Periodicals postage paid in Madison, WI, and additional offices.

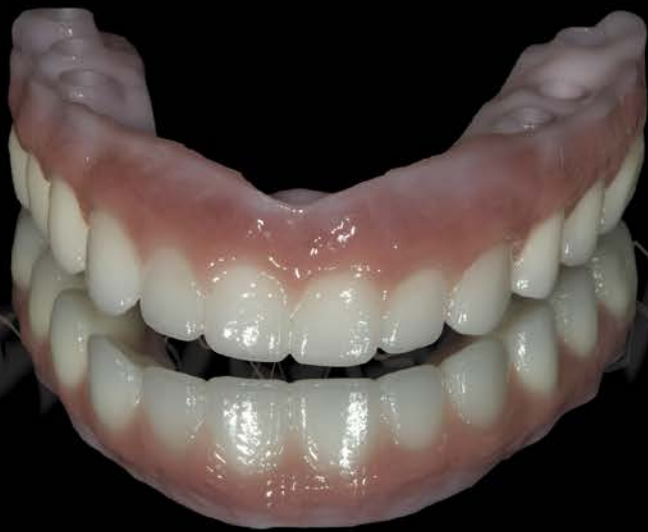POSTMASTER: send address changes to:
Journal of Cosmetic Dentistry
American Academy of Cosmetic Dentistry
402 West Wilson Street
Madison, WI 53703

Peer-reviewed articles are denoted with the following symbol: ♦

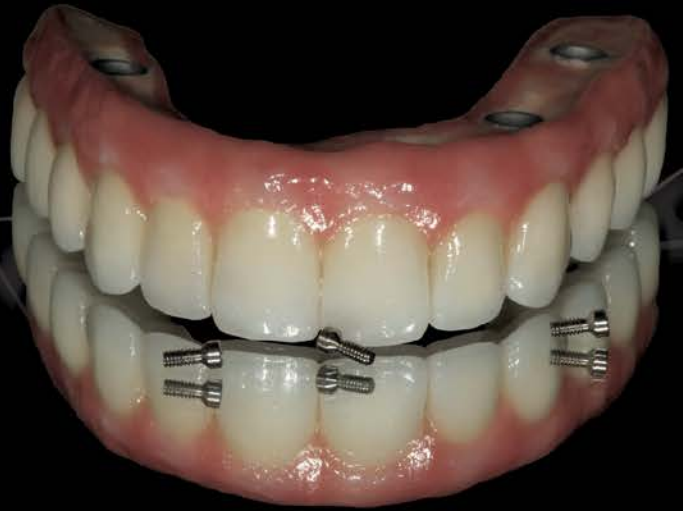Statements of fact and opinion are the responsibility of the authors alone and do not imply an opinion on the part of the officers of the AACD. Materials may not be reproduced without written permission. Contents© 2014 American Academy of Cosmetic Dentistry®

The *Journal of Cosmetic Dentistry* maintains signed patient release forms for all articles featuring clinical or other patient photography.

*Experienced, Knowledgeable,
Predictable, and Exquisite*



Screw-Retained CAD/CAM Milled
Layered Zirconium Art



Screw-Retained Layered Ceramic
Titanium Based Art

Our Philosophy at LSK121

Screw-Retained/Cement Porcelain Implant Bridge

- ◆ Skilled, expert, world-class Ceramists on-staff
- ◆ Highest technology currently available is in-house
- ◆ Life-like, hand-layered porcelain with easy cleaning and care
- ◆ Superb esthetics, strength, durability, stain-resistance and longevity
- ◆ Tissue colored porcelain utilized when required
- ◆ On-staff licensed Prosthodontist to offer case guidance
- ◆ Smooth and predictable turn-around times
- ◆ Complete lab assistance under one roof

LSK121
Oral Prosthetics

Find out more information about Porcelain Implant Bridge at LSK121.com

info@lsk121.com | 888.405.1238

One Lab, One Resource, Ultimate Solution

LSK121 Oral Prosthetics utilizes the
initial ceramic system

It's Academic...

“ I strongly believe that the way instructors treat students during this critical time has a direct effect on their future view of dentistry and opinion of their alma mater. ”

We were all dental students at one time. Then we graduated and were thrust into the formidable world of dental practice.

As students we constantly ask ourselves if we are prepared for the “real” world. I never felt smart enough or that I worked hard enough during dental school...and some of my clinical instructors and professors let me know that! If it were not for some individuals who took the time to mentor me and give me the courage to believe in myself, I might have graduated with a pessimistic outlook about this highly honorable profession.

Dental school can be daunting, between attending classes, meeting deadlines for projects, completing clinical requirements, studying the never-ending mass of new didactic material that does not seem to make any sense, and taking exams based on that material. I strongly believe that the way instructors treat students during this critical time has a direct effect on their future view of dentistry and opinion of their alma mater.

As an undergraduate, I never fully appreciated the time and effort some of the faculty took to give us a dental education. Like many a student who wanted to graduate and be let loose upon the unsuspecting public, I snickered at the full-time academics who seemed to never leave their university's ivory towers and grounds.

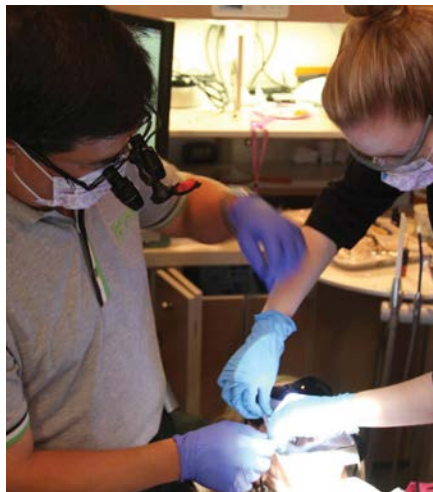After graduating from dental school, I went to work and did as much clinical dentistry as I could to fill in the voids that were missing from my undergraduate training. My principal mentors were the dentists at the two practices I associated at, and I learned quickly that dental practice was not the same as dental school.

Now, nearly 30 years later, I realize that many of the academics that do research and teach dentistry have truly dedicated their lives to the advancement of the field. They are the ones who bear the responsibility of ensuring that dental research continues to flourish and that graduating students are given the best chance to succeed.

It is both humbling and exhilarating how much more I believe I can still learn and grow. I may have been a slow starter, but I now deeply appreciate the many educators and coaches who have shaped and informed my professional career.

One of my greatest joys in dentistry is contributing and giving back to my profession by mentoring and sharing my experiences with others in order to make their passage through the challenges of dentistry a more enjoyable voyage.

This issue of the *jCD* showcases some of the top academic programs involved in esthetic dentistry today. Given the quality of the articles presented, you can rest assured that we are in good hands.



Edward Lowe

Edward Lowe, DMD, AAACD
Editor-in-Chief



WE'RE JUST SAYING.

REALLY? YES, REALLY.

You know what it's like to change a life with a smile makeover - you and your patients love it when the case is completed and everyone is happy. But let's get real. Most real dentistry lies in-between those big cases - a molar here, a posterior bridge there - small cases that over the course of time amount to a lifetime of really beautiful smiles, and more patient referrals. We get it, really we do. We can help you with all of your restorative needs; from the most esthetically challenging and complicated to the simple quadrant dentistry. Experience affordable, real dentistry every day with LK Dental Studio, your full service dental laboratory.

Call today and ask about about our LK Dental Studio Fall Special, just for our favorite AACD clients. Mention the code word "REALLY" and we'll take really good care of you, and your patients.

Laura Kelly

AACD 2007-2008 PRESIDENT
American Academy
of Cosmetic Dentistry
ACCREDITED MEMBER

DENTAL **LK** STUDIO
TOLL-FREE 866-550-3522 LKDENTALSTUDIO.COM

Esthetic Dentistry in Dental School Curricula: Challenging the Paradigm

Sillas Duarte, Jr., DDS, MS, PhD

Esthetics is a philosophical concept as to what is beautiful. Although this definition may sound broad and elusive, teaching esthetics is possible and concrete. Very often a course on esthetic dentistry is where students are taught anterior composite restorations and porcelain veneer preparations. Although a specific course on esthetics is an important introduction to restorative techniques, it is far from ideal in terms of providing a comprehensive approach to esthetic dentistry. Moreover, in some extreme cases, important esthetic concepts are broken down into several smaller and elective courses within the academic curriculum, thus diluting the teaching of important concepts that will guide dental students' professional lives.

Academic curricula should expose students as early as possible to those magnificent but complex esthetic concepts. These concepts should then be integrated into all other preclinical restorative courses and associated non-restorative courses alike. Once students reach the clinic, they should be familiar with the techniques and concepts discussed by faculty and other instructors in their preclinical life. When students are exposed to such a sequence and harmony among different courses, they become excited about and truly engaged in discovering and applying esthetic principles to fulfill their patients' needs.

It can be argued that students in the early stages of their dental education might not be prepared to receive and absorb this information; however, our experience at the Herman Ostrow School of Dentistry has been the complete opposite. We have seen students become much more engaged in learning and dedicating themselves to improving their knowledge of and skills in esthetic dentistry. But make no mistake—this is not an easy task to accomplish academically. We introduce esthetic concepts to our students at a very early stage—the first trimester of dental education—and we follow up on these concepts until graduation.

For this vision to become reality, all restorative preclinical and clinical courses, from dental morphology to implant dentistry, have

been completely redesigned. New topics such as indirect bonded and cemented restorations, including CAD/CAM technologies, ceramic-reinforced polymers, and all-ceramic restorations were added, as were competency exams. Different types of composite resins, with different optical properties such as translucency, opacity, opalescence, and fluorescence, became available to students, as did digital shade matching. Restorative criteria and novel grading schemes were developed for different procedures to ensure transparency of what is expected from dental students and to improve students' self-assessment skills. In

other words, all topics were subjected to numerous detailed revisions to update our teaching sequence, methods, and techniques to nurture the learning of esthetics and noninvasive concepts in dentistry. Today, esthetic dentistry is no longer a single isolated course, but rather a comprehensive and continuous learning opportunity across all trimesters at the Herman Ostrow School of Dentistry.

In addition, a significant investment in faculty development in terms of hiring, updating, teaching, coaching, and mentoring has been made.

The products of this enhanced curriculum—the students themselves—also play an important

role in keeping the faculty informed and updated about the newest technologies and trends.

All these factors have combined to form an essential cycle in which traditional teaching methods have been supplanted by a forward-thinking, innovative, cohesive philosophy that leads our students and faculty to excellence in restorative esthetic dentistry. At the end of the day, although *esthetics* is a philosophical concept, universities are realizing the need to find innovative ways to integrate esthetic dentistry into their curricula. As the old paradigm is challenged, it is important for us to remember that the valuable insight and guidance we give to each student will ultimately bring fulfillment and joy to everyone involved—including our patients.

Although a specific course on esthetics is an important introduction to restorative techniques, it is far from ideal in terms of providing a comprehensive approach to esthetic dentistry.

”



Dr. Duarte is associate professor and chair, Division of Restorative Sciences; and director of the Advanced Program in Operative Dentistry at the Herman Ostrow School of Dentistry of USC.

Beauty and Precision -For Every Indication!

Brilliant Artistry... World Class Technology... **Ultimate Performance**

For aesthetically sensitive cases, no materials perform like IPS e.max[®] and IPS e.max[®] CAD. No other laboratory can match Aurum Ceramic[®] in making the most of your Advanced Cosmetic restorations.

- > A perfect fit in your practice... for strength, precision and aesthetics throughout the mouth.
- > Beautiful, durable all-ceramic restorations - Crafted by the leader in Comprehensive Aesthetic and Implant Dentistry.
- > Unique optical techniques create the ultimate esthetic result.
- > Comprehensive Integrated Digital Workflow and Solutions that simplify the restorative process - from initial impression to final restoration.
- > Indicated for everything from single units to full mouth aesthetic cases. IPS e.max[®] is also a great choice for 3 unit anterior bridges (from 2nd bi-cuspid forward).


Visit our redesigned website at www.aurumgroup.com

Connect with us on  @aurumgroup



Call your closest Aurum Ceramic Laboratory TOLL FREE

Nevada, Utah, New Mexico And Arizona: 1-877-254-5334
Washington, Oregon, Montana And Idaho: 1-800-423-6509
Other North American Locations: 1-800-661-1169

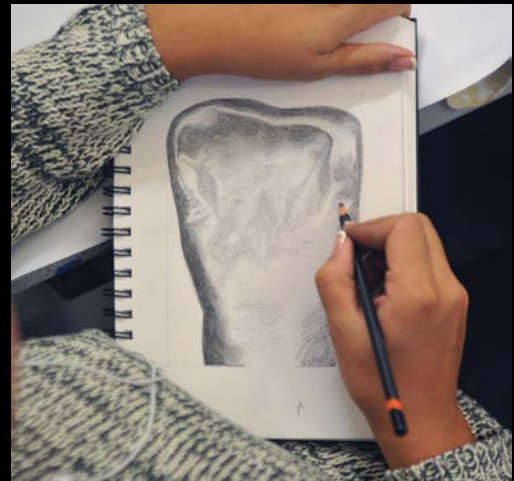*Designed and Manufactured in North America 



Expressing the **Finesse in Tooth Morphology**

By Xue Lily Du, BSc, MSc
Student, Herman Ostrow School of Dentistry of USC

“The concept seemed strange at first, but as I started to sketch the unfamiliar objects, the drawings “came alive” on the page.”



To some, dentistry is just a job. But to me, it means much more. I have always wanted to be a dentist and when I was accepted to the Herman Ostrow School of Dentistry of USC, everything seemed to fall into place.

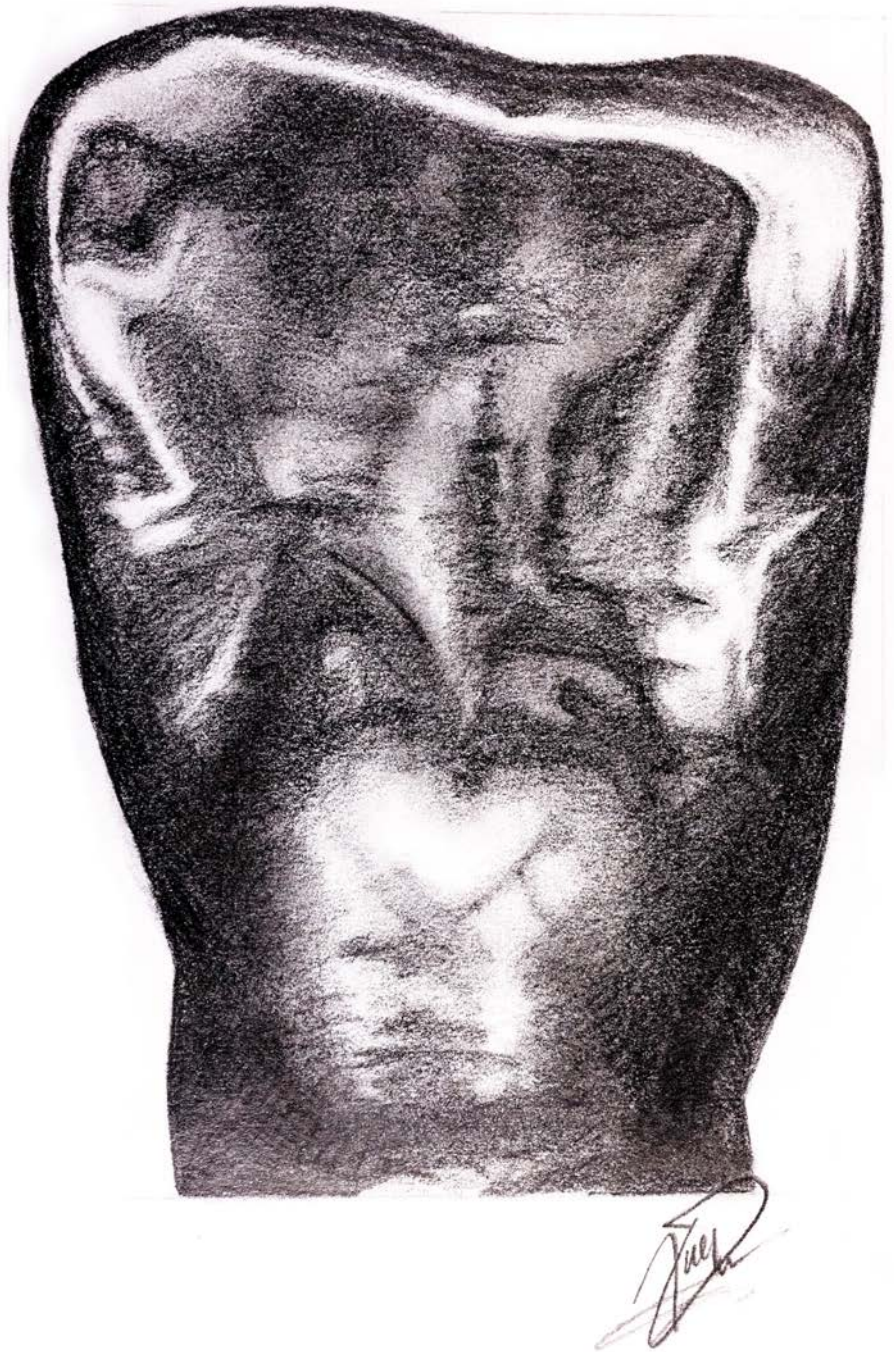The experience of learning from and working with Dr. Pascal Magne has exceeded my expectations. The DDS program was offering, for just the second time, the Dental Morphology, Function and Esthetics (DMFE) course; this uniquely structured module has allowed me and my colleagues to learn not only the “big picture,” but also the details and finesse that are the foundation of implant and esthetic dentistry.

The distinctive academic theory behind teaching tooth morphology in a “2D-3D-4D” approach was unlike anything I had ever experienced. Our first project was to create detailed 2D drawings of 3D teeth. The concept seemed strange at first, but as I started to sketch the unfamiliar objects, the drawings “came alive” on the page. In capturing the highlights that represent convex shapes and creating shadows to give the impression of concavities within a tooth structure, I was able to personally recognize and visualize the beauty behind dentistry.

As I progressed further into the DMFE module, I learned about crucial 3D and 4D concepts, priceless skills to have in the field of biomimetic and esthetic dentistry. I have always had a passion for the exquisiteness that underlies the profession of dentistry. The DMFE module has fostered in me an even stronger desire to learn, as well as be able to create beautiful smiles for patients that can emulate nature at its finest.

The cover art was drawn by Xue Lily Du (Los Angeles, CA), a student at the Herman Ostrow School of Dentistry of USC, Class of 2017. The cover photograph was taken by Pascal Magne, DMD, PhD, Don and Sybil Harrington Foundation Professor of Esthetic Dentistry at the Herman Ostrow School of Dentistry, with a Nikon D800E camera.

For more about Xue Lily Du's learning experience in USC's Dental Morphology, Function and Esthetics course, please turn to page 28.



APEX Teaches Students What They Don't Learn in Dental School

Scholarship Sends Select Students to the Renowned AACD Annual Scientific Session Every Year!

Tiffany Stronghart, MA

For the past four years, AACD has given dental students the chance to attend its annual scientific session at no charge through the APEX Award scholarship program. The award is valued at nearly \$1,700, but the experience students receive is priceless.

"How many dental students can say they've learned from specialists such as Dr. Newton Fahl, Jr., Dr. John Kois, and Dr. Frank Spear?" said Tara Ferris, a 2013 APEX recipient. Ferris, now a graduate of Marquette University School of Dentistry, noted that the "wealth of knowledge" she acquired was immeasurable.

In addition to tuition, students' airfare and hotel expenses are covered. They are also given a one-year membership in the AACD.

APEX was created to help attract dental students to the Academy, in the hope that they would retain their membership status as they progress in their careers and attend future meetings. When interviewed about APEX in 2013, Ferris said she planned to go to future AACD meetings (she did in fact attend AACD 2014 in Orlando).

APEX also seeks to cultivate students who have leadership potential, hoping they might strive to run for positions on AACD boards or committees. But more than anything, APEX helps get dental students excited about cosmetic dentistry education, which is rarely offered in the scope of a traditional dental school curriculum.

Walberto Cantu, a 2014 APEX winner and Marquette University School of Dentistry student, said his experience at AACD 2014 enabled him to learn things he would not have learned at school.

"As a dental student we are limited to the training and education that we get at school," Cantu said. "The courses that are offered at the AACD meeting are second to none. I took classes ranging from dental implants, to five-layer technique restoring a

“In addition to tuition, students' airfare and hotel expenses are covered. They are also given a one-year membership in the AACD.**”**

Class IV lesion, to how to increase the profit of your practice.”

Cantu said the highlight of his experience was learning from Dr. Newton Fahl, Jr. at one of his hands-on workshops.

APEX also helps students connect with other dental professionals who can mentor and inspire them.

Natalie Lesinski, a University of Colorado dental student and 2014 APEX winner, said her experience at AACD 2014 was one she will not forget.

“As a first-year dental student I wasn’t sure what to expect and my experience was greater than I could possibly have wished,” she said. “The community of dentists I had the opportunity to interact with was outstanding—top cosmetic dentists of the world. In fact, everyone I met was more than willing to help me grow as a current student and future dentist. World-renowned dentists including the immediate past president, Dr. Jack Ringer, along with other current and past representatives of AACD went out of their way to make me feel welcome.”

It helped solidify her career choice, too.

“Attending this meeting has assured me that I am going into the best profession,” she said. “Obtaining the AACD APEX scholarship has made me smile, knowing I will have the opportunity to forever give beautiful smiles to others.”

William Guthrie, another 2014 APEX winner, says he received sound guidance at the AACD’s Annual Scientific Session in Seattle in 2013.

“Many dentists stressed the importance of doing the best you can for every patient. They said that there will be failures, and new research will continue to change some of the things we do...but if you can say you did the best you could at that time for every patient, you will have a successful and rewarding career as a dentist. I thought that was great advice, especially for somebody just entering the profession.”

APEX’s popularity has grown significantly. When the program launched in 2011, two students were awarded. This year, 11 students were named APEX winners. With the number of APEX applicants rising each year, it is easy to see the value students are receiving from attending the meetings.

As AACD works to expand its influence across the globe, APEX has attracted many international students. While the first APEX winners were from the U.S., each year, students from countries such as Canada, Poland, Sweden, and France have received the award.

APEX is awarded annually. Criteria are based upon students’ academic achievement, and their understanding of and commitment to the future of cosmetic dentistry. Students are required to submit an essay about cosmetic dentistry, along with two letters of recommendation, to be considered for the award. The deadline for the 2015 APEX Award is January 30. Winners will attend AACD 2015 in San Francisco, May 6-9.

Support for the award is given by AACD members and corporate partners, with up to five scholarships matched by the Academy. AACD is always seeking new sponsors for the award, and encourages members to sponsor the award jointly if they cannot bear the full cost.

AACD is currently seeking applicants and sponsors for the 2015 APEX Award. For more information, or to apply, visit www.aacd.com/apex. **JCD**



AACD awarded the APEX Scholarship to 11 dental students in 2014. Students attended AACD 2014 in Orlando at no charge and received one-year memberships. Back row (from left): Charles W. Vittitow, University of Kentucky; Adam Hammerbeck, Marquette University; Vera Telyakova, University of Toronto; Natalie Lesinski, University of Colorado; Walberto Cantu, Marquette University. Front row (from left): Ida Zarrabi, University of California—San Francisco; Zuleidy Arencebia, University of Puerto Rico; Jessica Tucker, University of Tennessee; Andi-Jean Miro, New York University; Lea McQuigg, University of Colorado; Alexander Rubinov, Columbia University.



Ms. Stronghart earned a Master’s degree in journalism from the University of Wisconsin—Madison. She is the communication specialist for the American Academy of Cosmetic Dentistry.

Disclosure: The author did not report any disclosures.

Layering and Blending Composite

Conservative and Esthetic Restoration of a Class IV Fractured Central Incisor

Priya S. Tirumalasetty, DDS, FAGD

Key Words: conservative treatment, Class IV composite, layering, translucency, Accreditation Case Type IV

// As they age, anterior restorations begin to stain and fracture and the need for a highly esthetic replacement restoration becomes a priority. //



Figure 1: Preoperative full-face smile. The stained, old restoration is visible from a distance.

Introduction

Esthetic anterior restorations are necessary in today's appearance-conscious society. Many of the cosmetic challenges that dentists currently face relate to patients who present with a history of childhood trauma that resulted in the restoration of one or more anterior teeth. As they age, anterior restorations begin to stain and fracture and the need for a highly esthetic replacement restoration becomes a priority.

Patient History and Chief Complaint

The patient, a 27-year-old male, presented with a stained and fractured Class IV restoration on tooth #8. He wanted the restoration to be replaced with a more esthetic one. The tooth had been fractured during a fall when the patient was 11. The original restoration was placed soon after the trauma and had not been replaced.

The tooth was asymptomatic, and showed no signs of pulpitis or pulpal necrosis secondary to trauma and the subsequent restoration of the tooth. Clinical examination revealed good oral hygiene and healthy periodontium. Previous dental work included amalgam restorations in the posterior and the Class IV composite on #8. The patient, who was in excellent general health, had no temporomandibular joint symptoms and was asymptomatic upon load-testing the joints in centric relation; minor wear facets were noted in the anterior (Figs 1-3).

Diagnosis and Treatment Plan

The diagnosis was a defective and discolored composite restoration on the mesial incisal of tooth #8. The existing composite was stained and fractured. The maxillary midline was deviated to the left, causing the maxillary centrals to lack symmetry and dominance. The treatment plan consisted of take-home whitening with full-arch custom trays, and restorations of #8 and #9 with composite resin. Tooth #9 was included in the treatment plan to close the existing diastema and achieve symmetry of the maxillary central incisors. The patient requested conservative treatment options and refused periodontal surgery or orthodontics. One of the major goals of restorative treatment was to close the “black triangle” between #8 and #9. Care was taken to avoid blunting the papilla and to have the gingival levels be in harmony with the adjacent teeth. Composite was placed as close as possible to close the black triangle and the gingiva responded favorably.

Treatment

Preoperative

Photographs were taken to assess the existing restoration and formulate the sequence for treatment. Impressions were made to fabricate the take-home full-arch custom bleach trays and to create a diagnostic wax-up. The patient was given the trays, a two-syringe take-home bleaching kit (Zoom NiteWhite 16% calcium phosphate, Philips Oral Healthcare; Los Angeles, CA), fluoride gel (Relief Gel, Philips), and written and verbal directions for their use. He was instructed to wear the bleach trays overnight for six consecutive nights. The patient returned three weeks later for replacement of the composite restorations on #8 and #9.

Bonding, Layering, and Blending

The patient was anesthetized with 2% lidocaine with 1:100,000 epinephrine (Henry Schein; Melville, NY). The existing unesthetic restoration was removed. The tooth was prepared with a scalloped bevel extending into the middle third of the tooth to enhance the blending of the finish line.¹ There was no recurrent decay noted. A 40% phosphoric acid gel etch (Henry Schein) was used as directed. The bonding agent, Optibond FL (Kerr; Orange, CA), was then applied. The use of a fourth-generation bonding agent with the total-etch technique was preferred due to the high enamel content of the cavity preparation and resulting high bond strength.² Charisma composite resin (Heraeus Kulzer; South Bend, IN) and IPS Empress Direct (Ivoclar Vivadent; Amherst, NY) were placed

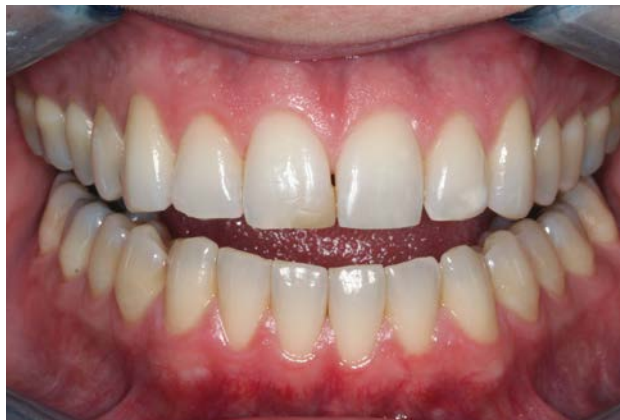

Figure 2: Preoperative retracted frontal image (1:2). The difference in axial inclination of the central incisors is apparent.

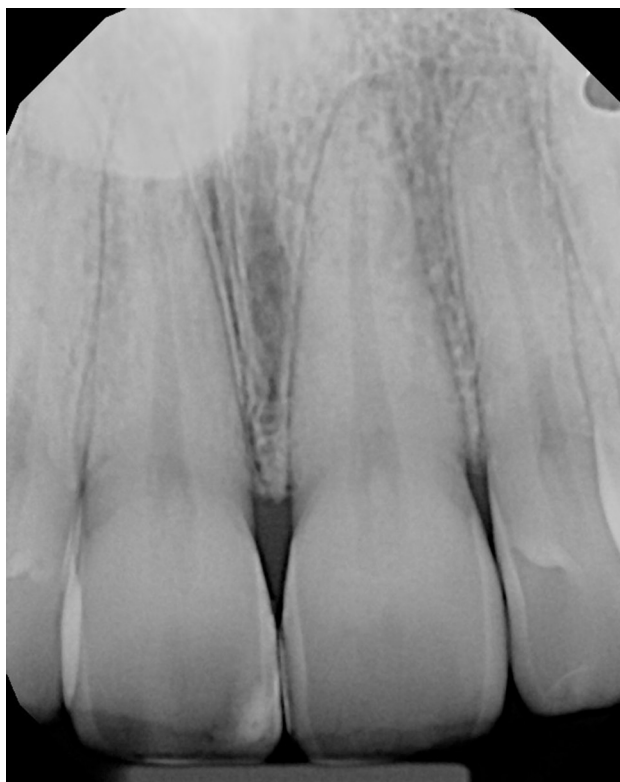

Figure 3: The x-ray shows the completed restorations on #8 and #9.

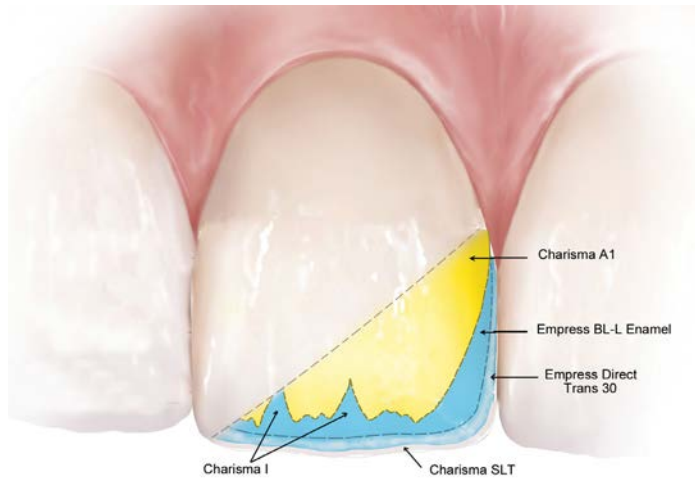


Figure 4: Color map of the various layers of composite from a frontal view. (Illustration by Zach Turner)

COLOR MAP - CLASS IV COMPOSITE

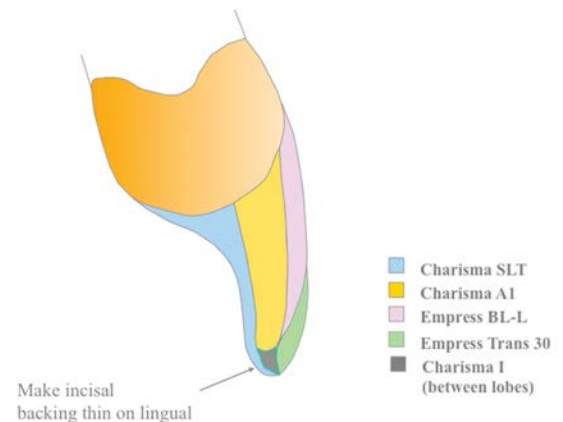


Figure 5: Color map of the various layers of composite from a side view. (Illustration by James H. Peyton, DDS, FAACD)

in incremental layers to simulate the various anatomic layers of the tooth. Thus, a dentin shade replaces the dentin layer, an enamel shade replaces the enamel layer, and a translucent or effect shade replaces the incisal area of the tooth. The incremental layering process results in a natural-looking, polychromatic restoration.^{3,4} All increments were cured with a BluePhase G2 LED curing light (Ivoclar Vivadent) (Figs 4 & 5).

Composite resin was placed slightly subgingivally to support the papilla at the top of the interproximal connector, along the mesiofacial of #8 and #9. Care was taken to prevent the formation of sharp “elbows” of composite that floss could snag on, which potentially could fracture the composite or inflame the gingival tissue. A clear matrix strip (Contour-Strip, Ivoclar Vivadent) was used to create a smooth contact between #8 and #9 (Fig 6). The strip was formed and “tacked” into place using a clear, unfilled resin (Heliobond, Ivoclar Vivadent) (Fig 7). The outside edge of the strip was shaped with the handle of a composite instrument to form a “beak” that could be tucked slightly subgingivally. Once the matrix was tucked in and formed an inverted U-shape, it was held in place by unfilled resin placed on the outside of the strip and cured. This method allows for the placement of composite subgingivally without sharp angles or corners, and allows the resin to transition smoothly from the cervical to the mesial interproximal interface.⁵

The initial layer of Charisma shade SLT (Heraeus Kulzer), a microhybrid composite, was placed to build the lingual shelf. The lingual shelf layer is a very thin layer of milky-white enamel that is semi-translucent. This layer replicates the lingual layer of enamel and serves as a foundation upon which subsequent layers will be formed. The lingual shelf also precisely replicates the incisal edge and lingual contours of the tooth.^{6,7} Charisma shade A1 was used to build mamelons and mimic the dentin layer. This dentin layer was placed up to the fracture line and

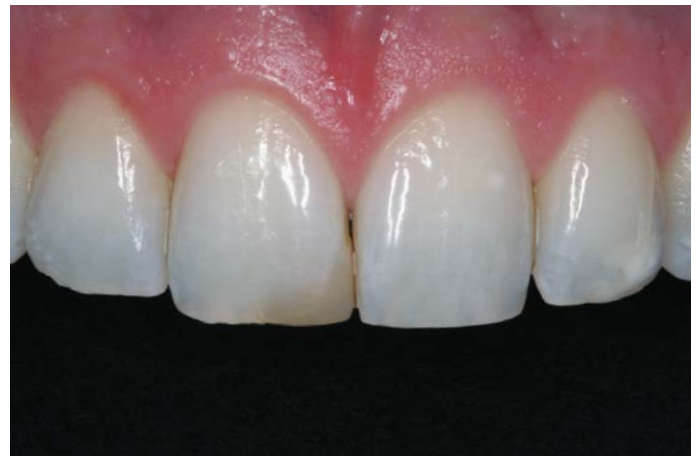

Figure 6: Preoperative retracted anterior image (1:1). The lack of symmetry in the width of the central incisors is evident.

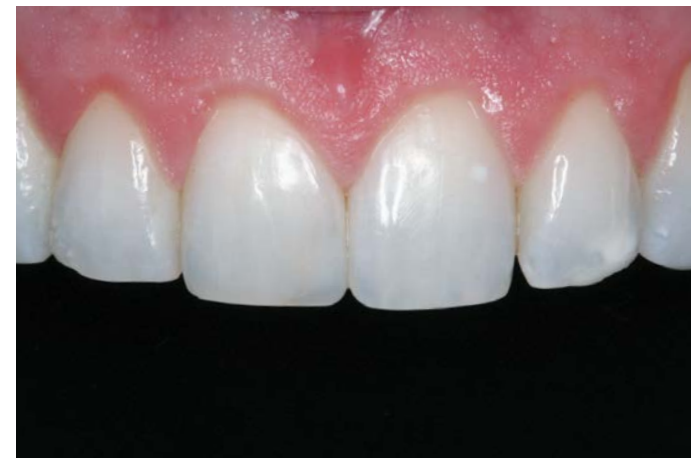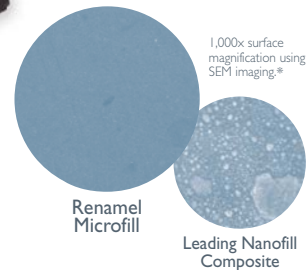

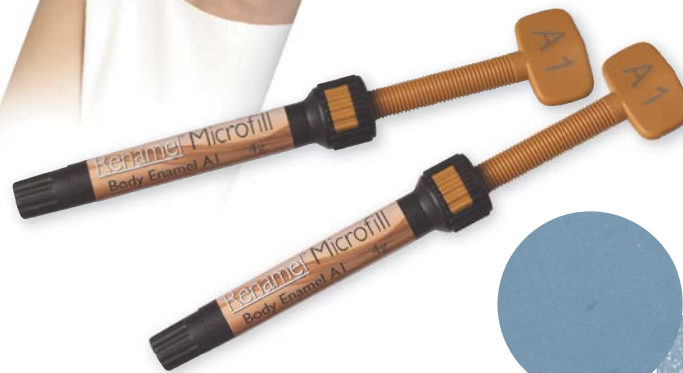
Figure 7: Postoperative retracted anterior image (1:1). The width of the central incisors appears symmetrical. Translucency has been incorporated into the layers of the new restorations.

Renamel® Microfill



When you think of enamel, think of Renamel Microfill. Just like natural enamel, Renamel Microfill combines beauty with long-lasting color stability and wear resistance. If you want beautiful, long-lasting restorations, Renamel Microfill is a must!



NOTHING
POLISHES LIKE
A MICROFILL

BETTER *for* DENTISTS

- Long term wear resistance
- Polishes like glass
- Color stable
- Incredible handling properties
- Easiest composite to marginate
- Extensive shade selection to match any tooth

BETTER *for* PATIENTS

- Beautiful esthetics and long-lasting polish
- Resists stain and plaque development
- Amazing durability
- Natural fluorescence
- Biologically, the tissue response is unsurpassed

Helping you succeed with quality products and dedicated support.

Call us at: 800 . 621 . 6729

www.cosmedent.com

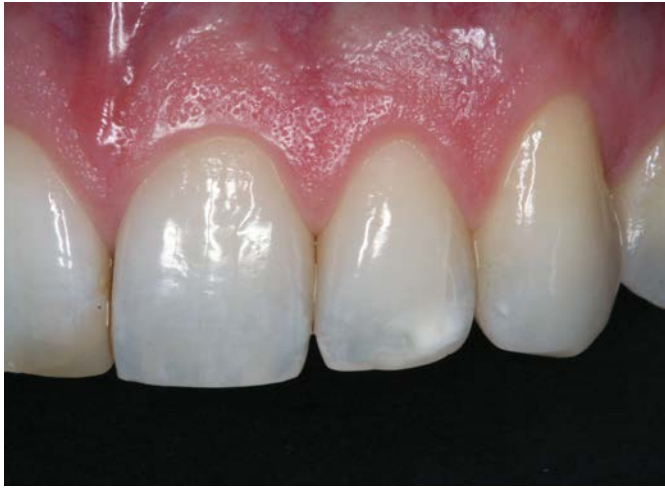

Figure 8: Preoperative retracted left lateral image (1:1).

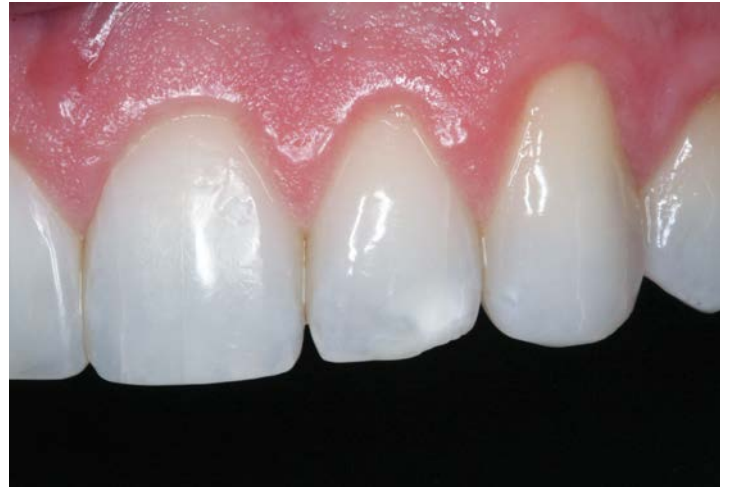

Figure 9: Postoperative retracted left lateral image (1:1).

slightly beyond to make the fracture line disappear and blend into the composite.³ A small amount of Charisma shade I (Incisal) was placed in between the lobes to create translucency and contrast. The last layers of IPS Empress Direct Enamel BL-L and Trans 30 were used to recreate the enamel layer and incisal edge of the restoration. A final layer of BL-L was used to recreate the enamel layer of the restoration; this composite was extended beyond the scalloped bevel to blend and transition the finish line into existing tooth structure. The Trans 30 was used to incorporate translucence to mimic the existing incisal translucency of #9. The procedure to restore #9 was similar, but only BL-L composite was used, given the minimal amount of space that was needed to close the diastema. A fine-grit flame diamond bur was used to create primary and secondary facial anatomy. A graphite pencil was used to mark the line angles of #8 and #9. The pencil was very useful in achieving symmetry and developing the mesiofacial line angles.⁸ Carbide burs #7406 and #7901 (Brasseler USA; Savannah, GA) were used with an electric handpiece to finish margins and adjust the occlusion. The occlusion was checked and adjusted to ensure that the patient had smooth, even anterior guidance on both #8 and #9 in protrusive and excursive movements, with posterior disclusion (Figs 8 & 9).⁹

Finishing and Polishing

EP finishing discs (Brasseler) were used to finish the restoration and establish primary anatomic form. The putty matrix was also helpful in visualizing the incisal edge position and incisal embrasures. Visualization of the restoration from the incisal view can detect irregularities in the facial contour and proximal line angles. From the postoperative occlusal view, one can see that the facial contours are correct.^{6,7} Polishing was accomplished with Dialite composite polishing points

(Brasseler), followed by application of Enamelize paste with a FlexiBuff wheel (Cosmedent; Chicago, IL). Teeth #8 and #9 had areas of pitted enamel that were smoothed and polished after the restorations were placed. Final polish was achieved with a plain cotton buff wheel (Brasseler), using a staccato motion with a slow-speed straight cone handpiece (Figs 10-13).¹⁰

// The use of a fourth-generation bonding agent with the total-etch technique was preferred due to the high enamel content of the cavity preparation and resulting high bond strength. //

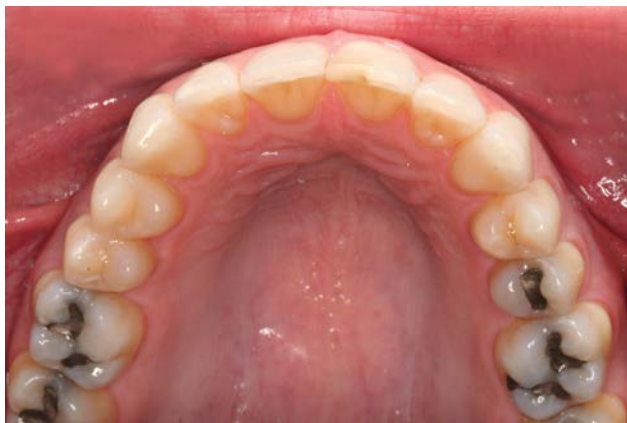

Figure 10: Preoperative retracted maxillary occlusal image (1:2). A midline cant is evident.

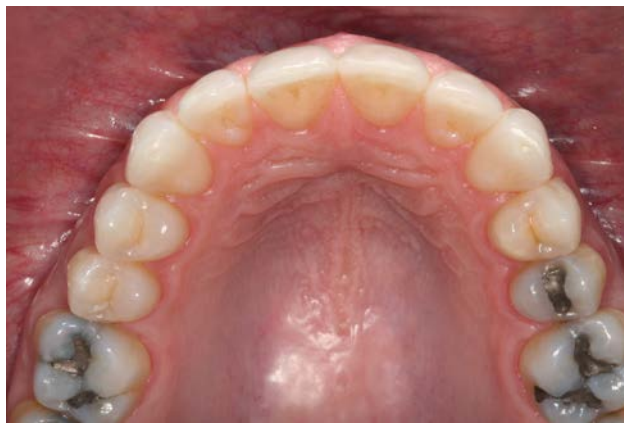

Figure 11: Postoperative retracted maxillary occlusal image (1:2). The midline cant and appearance of the papilla between the central incisors is improved.

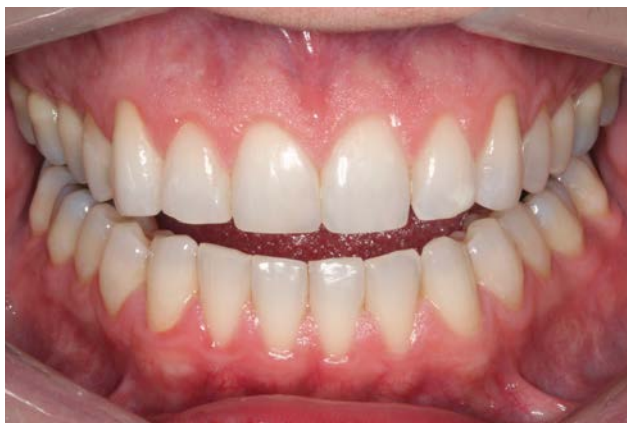

Figure 12: Postoperative retracted frontal image (1:2). The central incisors appear to have a symmetrical, harmonious slight mesial-axial inclination.



Figure 13: Postoperative full-face smile. The new restoration blends in well enough to “disappear” in this view.

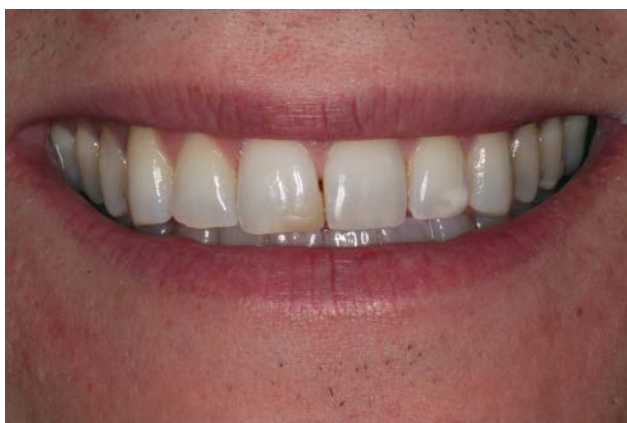

Figure 14: Preoperative frontal natural smile. A black triangle is noticeable.

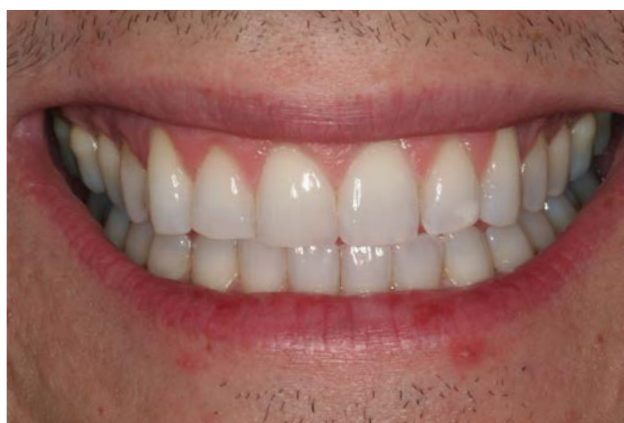

Figure 15: Postoperative frontal natural smile. The black triangle is no longer visible.

Postoperative

The patient was recalled several weeks after the initial placement of the restorations to examine the shape and health of the papilla. Oral hygiene instructions were reviewed, considering the contact between #8 and #9 was previously light. The patient was able to floss the new contact between #8 and #9 easily and did not shred or snag floss.

He was very happy with the esthetic outcome of the restorations, and had no postoperative sensitivity. At the six-month recall appointment, he demonstrated the ability to maintain the health of the papilla between #8 and #9, and the shape of the restorations without fracturing the newly restored incisal edges.

Summary

Composite resin was the material of choice for the restoration of #8 and #9 because of the conservative nature of the bonding process and minimal preparation required.^{11,12} There are many excellent composite systems on the market today. However, through repeated use, one or two particular shades of composites taken from a particular kit or manufacturer may become the “go-to” shade or shades. In this case, composites from two different manufacturers (Heraeus Kulzer and Ivoclar Vivadent) were used. The translucency achieved was due solely to the layering of shades of composite, without the use of tints (Figs 14 & 15).³

High bond strengths can be achieved using a fourth-generation bonding agent.² The midline cant was improved and central dominance was achieved with the use of direct resin. Challenges to achieving esthetic results included blending the finish line, restoring symmetric line angles, and obtaining the necessary surface luster to match the existing dentition. Also, consideration of the adjacent papilla heights played a role in determining the length of the contact point between #8 and #9. It was imperative to close the midline diastema conservatively without blunting the papilla. Several different lengths were attempted before achieving a balance between preservation of the papilla and closure of the existing triangle.

The pleasing esthetic results realized here demonstrate that direct composite resin should be considered as a definitive final material for replicating natural tooth structure and obtaining a lifelike, polychromatic restoration.

References

- Vargas M. Using a universal composite to create natural-looking anterior restoration. *Inside Dent*. 2009 Jan;5(1):84-7.
- Brucia J. Adhesive dentistry: materials and techniques simplified. Available from: <https://www.academyofoperativedentistry.com/2.pdf>.
- Finlay SW. Stratification: an essential principle in understanding Class IV composite restorations. *J Cosmetic Dent*. 2012 Spring;28(1):32-4.
- Fahl N Jr. A solution for everyday direct restorative challenges. Part 1. *J Cosmetic Dent*. 2010 Fall;26(3):56-68.
- Belvedere P, Lambert D. Advancing your direct composites through the use of a specialized matrix. *Oral Health*. 2002 Apr;92(4):75-83.
- Fahl N Jr. Step-by-step approaches for anterior direct restorative challenges. Part 2. *J Cosmetic Dent*. 2011 Winter;26(4):42-55.
- Peyton JH. Finishing and polishing techniques: direct composite resin restorations. *Pract Proced Aesthet Dent*. 2004 May;16(4):293-8.
- Peyton J, Arnold J. Six or more direct resin veneers case for Accreditation: hands-on typodont exercise. *J Cosmetic Dent*. 2008 Fall;24(3):38-48.
- Dawson PE. *Functional occlusion: from TMJ to smile design*. St. Louis: Mosby; 2007.
- Terry DA. Direct applications of a nanocomposite resin system: part 2—procedures for anterior restorations. *Pract Proced Aesthet Dent*. 2004 Oct;16(9):677-84.
- Terry DA, Leinfelder KE, Geller W. *Aesthetic and restorative dentistry: material selection and techniques*. 2nd ed. Hanover Park (IL): Quintessence Pub.; 2013.
- Baratieri LN, de Araujo EM Jr, Monteiro S Jr. *Composite restorations in anterior teeth: fundamentals and possibilities*. 1st ed. São Paulo: Brazil. Quintessence Pub.; 2005. **JCD**

Composite resin was the material of choice for the restoration of #8 and #9 because of the conservative nature of the bonding process and minimal preparation required.



Dr. Tirumalasetty maintains a private practice in Chicago, Illinois.

Disclosure: The author did not report any disclosures.

RESPONSIVE Website Design

Websites that display beautifully on every device, every size:
no pinching, zooming or squinting required.



A Multifaceted Approach to Healthcare Marketing

Top dentists demand top results, and at Rosemont Media we have every angle covered to get you there. We've hand-selected the industry's best in design, SEO, content creation, & social media marketing to ensure your practice is carving out a name for itself in your market. We provide the very best in web marketing & design for dentists worldwide.

1010 Turquoise Street, Suite 301, San Diego, CA 92109
www.rosemontmedia.com • info@rosemontmedia.com • www.facebook.com/rosemontmedia

Call Today
800.491.8623

AACD 2015 - Find us at booth 1808



Envisioning the Final Outcome

Success with Class IV Fractures

J.A. Reynolds, DDS, AAACD

// To achieve Accreditation, the candidate must have a good working knowledge of tooth anatomy from the inside out. //

Of the five clinical cases required for Accreditation, Case Type IV often is the first one assayed by members in the process. This case type, which occurs frequently in many dental practices, employs the use of anterior direct resin to restore a Class IV fracture or to close a diastema. The focus of this case type is to evaluate the clinician's ability to match the natural dentition in shape, size, and shade.¹ (For more in-depth information about all case types, please go to aacd.com.)

The color of a tooth depends upon the nuances of a more opaque dentin and the outer layer of translucent enamel. Due to their improved characteristics, composite resins have evolved over the years to become a long-term conservative solution to many anterior restorative situations. With different opacities of materials, the light-scattering properties of composite will vary. The combination of different opacities and thicknesses of composite are necessary to obtain an esthetic result.²

To achieve Accreditation, the candidate must have a good working knowledge of tooth anatomy from the inside out. As the restoration is built, the clinician must envision the exact position of the incisal edge to allow for appropriate thickness of each layer. Incisal indices made from a wax-up are extremely helpful. It all comes down to mimicking the light transmission and absorption effects of the restoring materials.³ Dr. Tirumalasetty did an excellent job of matching the surrounding tooth structures using specific layering of both dentin and enamel materials (Fig 1). The examiners passed this case with only minor faults, most noted as follows:

Criterion 44: *Does the surface exhibit the appropriate finish, polish, and luster?* Irregular polish and low luster are present.

Criterion 52: *Does the restoration have "show-through" of tooth structure or the fracture line under the material?* The fracture line is visible in some views.

Criterion 84: *Are the incisal embrasures proper? Is there a natural progressive increase in incisal embrasure size from the central to the cuspid?* The mid-line embrasure is nonsymmetric.

Understanding tooth morphology and composite resin properties is essential in providing a seamless anterior restoration. Dr. Tirumalasetty envisioned the natural anatomy as the restoration was built and, using familiar materials to layer dentin and enamel shades, she was successful in delivering an excellent service to her patient. **JCD**

COLOR MAP - CLASS IV COMPOSITE

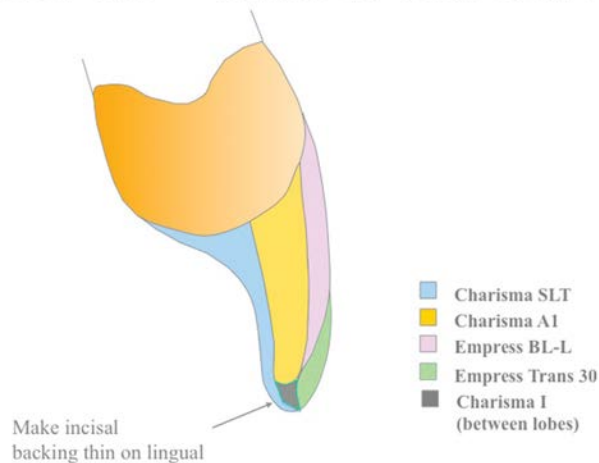


Figure 1: Color map of the various layers of composite from a side view. (Illustration by James H. Peyton, DDS, FAACD.)

References

1. American Academy of Cosmetic Dentistry (AACD). A guide to Accreditation criteria. Madison (WI): AACD; 2014. p. 36-7.
2. Vichi A, Fraioli A, Davidson CL, Ferrari M. Influence of thickness on color in multi-layering technique. *Dent Mater.* 2007 Dec;23(12):1584-9.
3. Roselino L, Garcia L, Sousa A, Pires-de-Sousa F. Influence of increment thickness on the similarity of composite shade: a pilot study. *Gen Dent.* 2012 Jan;60(1):27-30.




Dr. Reynolds is an AACD Accredited Member, has been an AACD Accreditation Examiner since 2003, and is the current Accreditation chair. He practices in Franklin, Tennessee.

Disclosure: The author did not report any disclosures.

New Concept is Creating Positive *Momentum*

Dental Morphology, Function, and Esthetics at the University of Southern California

Pascal Magne, DMD, PhD



The 145 freshman students at the Herman Ostrow School of Dentistry of the University of Southern California (USC) (Los Angeles, CA) have been exposed to a different kind of experience that started in summer 2012. The Dental Morphology and Occlusion module (now in its third cycle) was renamed Dental Morphology, Function and Esthetics (DMFE). I am the director of this module. The program extends over 30 weeks (two trimesters), during which resource sessions (90 minutes of classroom time per week) are offered, followed by extensive laboratory sessions and weekly assignments. Students undergo weekly evaluations in addition to midterms and final exams each trimester. Detailed step-by-step manuals and corresponding instructional movies are associated with each laboratory session and are accessible online at all times through the school's intranet.

One of the DMFE program's goals is to "unleash the artist within" each student while reflecting the most current trends in the dental profession: adhesive and implant dentistry. The module begins with numerous drawing exercises (Figs 1-3). Perceptual skills and artistic development ("right brain" activities) are fostered through visual art and the drawing of natural teeth (the two-dimensional [2D] phase of the module), simultaneously allowing students to learn morphology and nomenclature.¹

Another of the program's goals is to emphasize clinically relevant techniques for all laboratory exercises. The typodont model therefore is presented and considered as a new "patient." The production of diagnostic models (Fig 4) according to new standards provides better esthetic

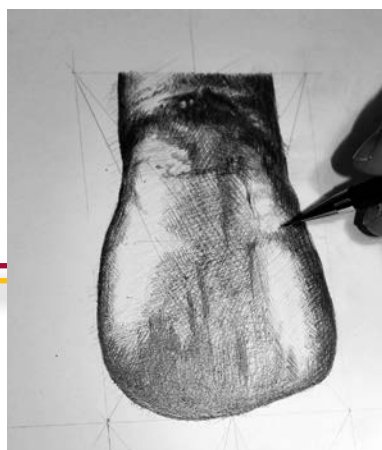


Figure 1: Drawing by student Minju Yi.



Figure 2: Drawing by student Alexander Lee.



Figure 3: Drawing by student Sue Chung.

guidance for progressive wax-up procedures (the three-dimensional [3D] phase of the module). Laboratory exercises in the anterior dentition start with basic wax additions and culminate with smile design techniques and a full “canine-to-canine” wax-up using prefabricated wax patterns. Throughout the process, the use of natural dentition casts and replicas is emphasized to “imprint” on students the fundamentals of tooth form and function.

The last phase of the module includes layering exercises using acrylic resins and mock-ups (Fig 5) and composite resins (Fig 6) (the four-dimensional [4D] phase). During this final step, all the knowledge acquired during the previous phases is brought to fruition.

The so-called “2D-3D-4D” approach is repeated twice, first for the anterior dentition (first trimester), then for posterior teeth (second trimester).²

Another unique feature of the module is the utilization of new high-quality materials for optimal visual perception and hands-on experience, including Type IV white stone, white opaque wax, electric waxers (“wax pencils”), casts of intact natural dentition, silicone molds for prefabricated wax patterns, as well as optimized acrylic and composite resins.

An unexpectedly large number of students from the previous class have been volunteering as teaching assistants to help their freshman classmates. Also, thanks to a significant number of volunteer faculty members (including dental technicians), the student-to-faculty ratio ranges between 5:1 to 8:1 (not counting the numerous teaching assistants). This demonstrates the positive momentum created by this new module.

In closing, I would like to introduce Xue Lily Du, who earned her Bachelor of Science and Master of Science in Physiology and Biochemistry at the University of Western Ontario in London, Ontario, Canada, and was then accepted at the Herman Ostrow School of Dentistry of USC. Lily is very excited to continue in this fulfilling artistic and creative career, where the interactions we have with patients help to improve their confidence and well-being. Her dedication to the profession is evident in her visual essay, which begins on page 28; as well as in her cover art for this issue, which exemplifies her experience in my Dental Morphology, Function and Esthetics course. I hope you enjoy her pictorial journey.

References

1. Magne P. The right start: DMFE class for freshman students at the Ostrow School of Dentistry of USC. In: Duarte S, editor. 2014 QDT. Hanover Park (IL): Quintessence Pub.; 2014. p. 7-12.
2. Magne P. Dental Morphology, Function and Esthetics module with the “2D-3D-4D” concept. Int J Esthet Dent. Forthcoming 2015.



Figure 4: Study models by student Alexandre Gaeta.

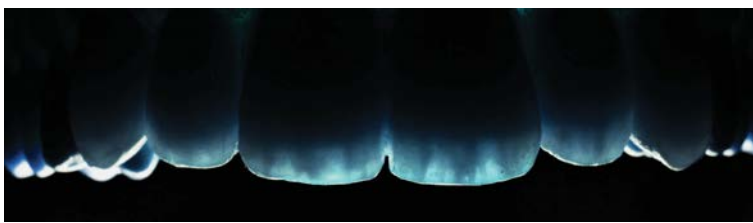


Figure 5: Wax-up/mock-up in transillumination by student Katie Schwarz.

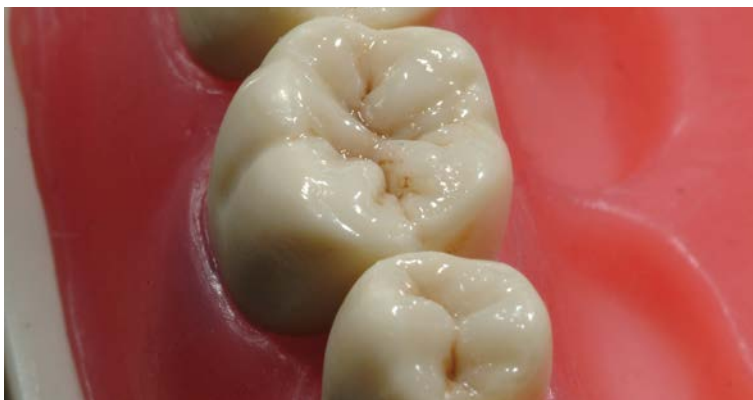

Figure 6: Composite resin restorations by student Jiwon Kim.

“One of the DFME program’s goals is to “unleash the artist within” each student while reflecting the most current trends in the dental profession: adhesive and implant dentistry.”

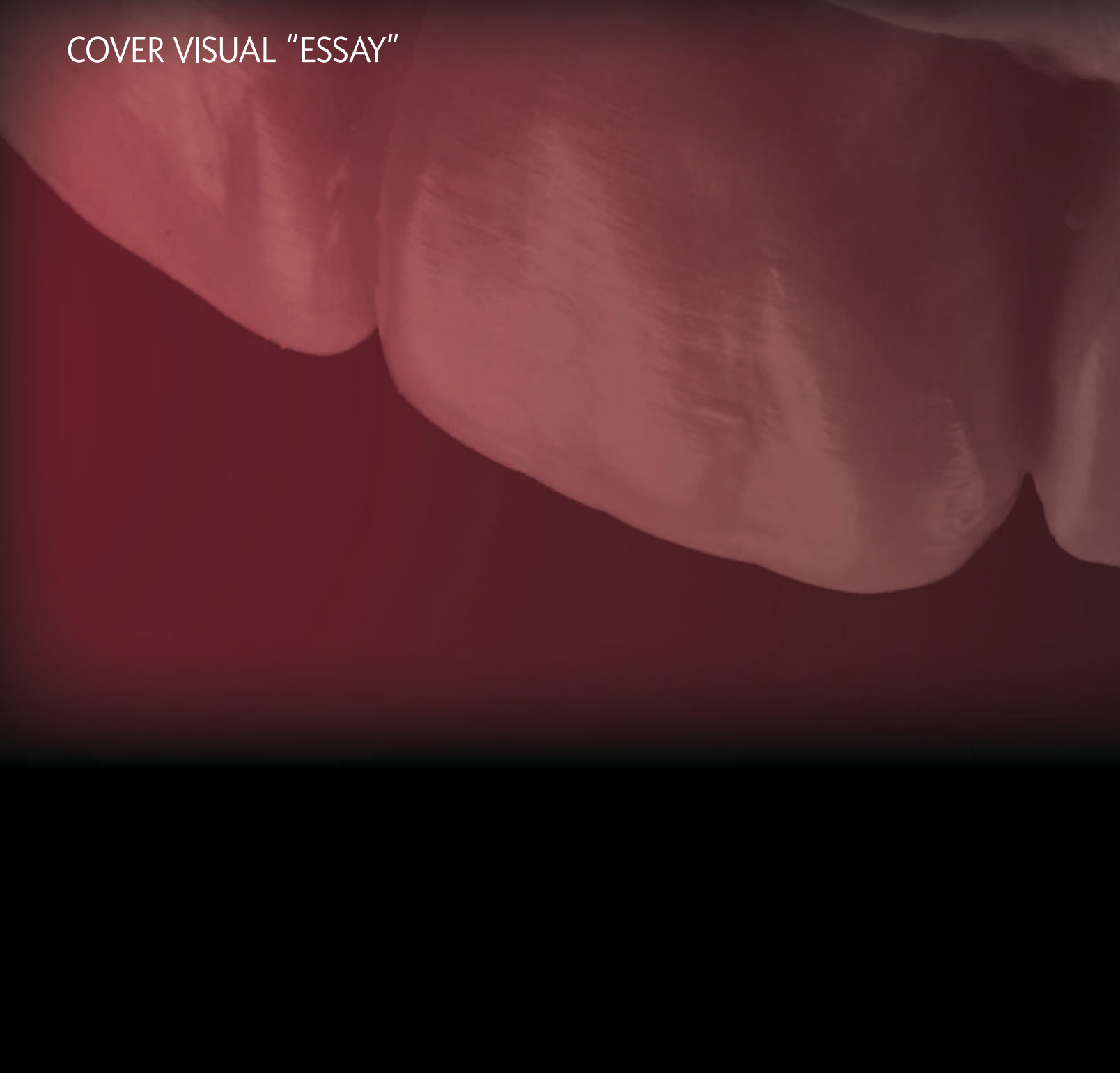


Dr. Magne is the Don and Sybil Harrington Foundation Professor of Esthetic Dentistry at the Herman Ostrow School of Dentistry of USC (Los Angeles, CA). He also is the director of the school’s Dental Morphology, Function and Esthetics module.

Disclosure: The author did not report any disclosures.

Photo credits: The jCD thanks the University of Southern California for the use of their photos in this editorial.

COVER VISUAL "ESSAY"



// ...from Day One, students are immersed in learning about the outline, grooves, transitional line angles, and oblique ridges that help to define and individualize a tooth. //

Unleashing My *Creativity*

Understanding the Complexities and Intricate
Details of Tooth Morphology

Xue Lily Du, BSc, MSc

The Dental Morphology, Function and Esthetics (DMFE) module taught by Dr. Pascal Magne at the Herman Ostrow School of Dentistry of USC is unique in that, from Day One, students are immersed in learning about the outline, grooves, transitional line angles, and oblique ridges that help to define and individualize a tooth. The module began with a focus on anterior tooth morphology; this not only increased our knowledge, but also enhanced our “eye for beauty.” Also integrated into the module were guest lectures that introduced us to principles of biomimetics, temporomandibular joints and diseases, laboratory techniques, dental materials, and societal versus individual perceptions of beauty. The second part of the course focused on posterior teeth, bringing everything together as a whole arch.

For both areas of concentration, the “2D-3D-4D” approach was used. First, we explored our artistic skills through sketching different views of singular teeth. Next, we worked with white wax to recreate the detailed morphology of the grooves, pits, and fissures within each tooth (**Fig 1**). Last, we experimented with different dental materials such as New Outline acrylic resin (Anaxdent; Ardmore, OK) to produce exquisite cutback mock-ups that can mimic

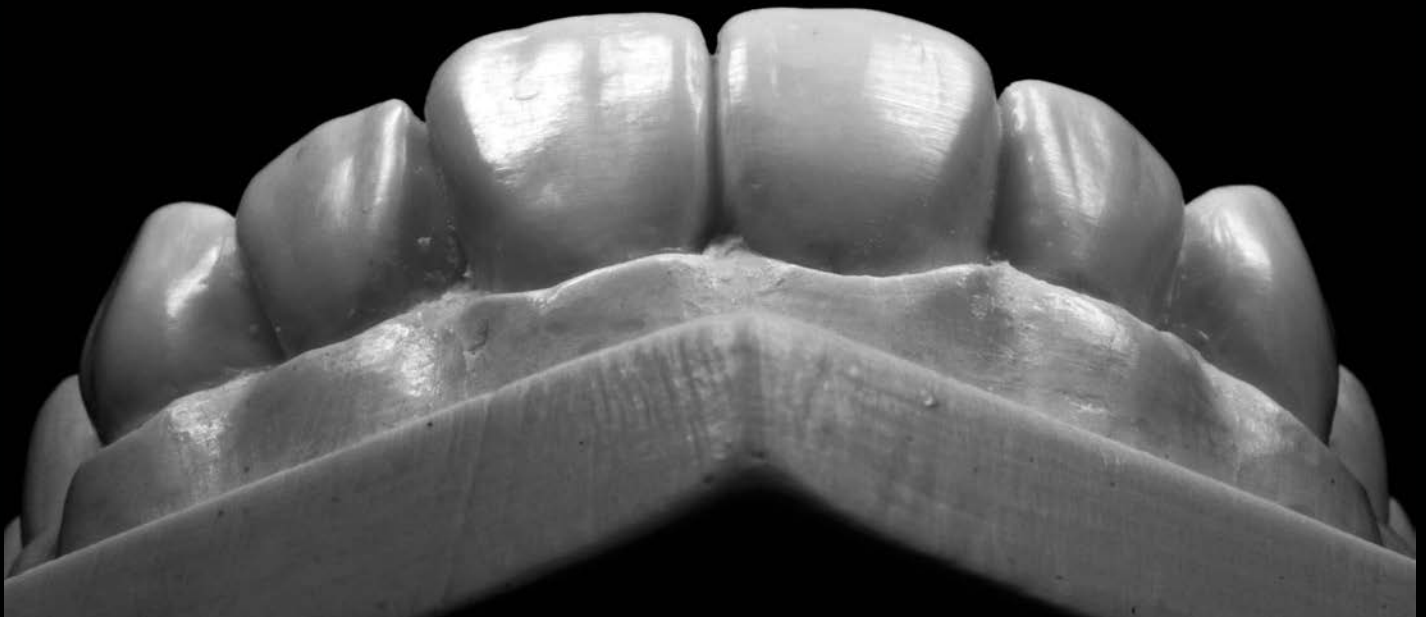


Figure 1: Labial view of canine-to-canine full wax-up on white stone cast.

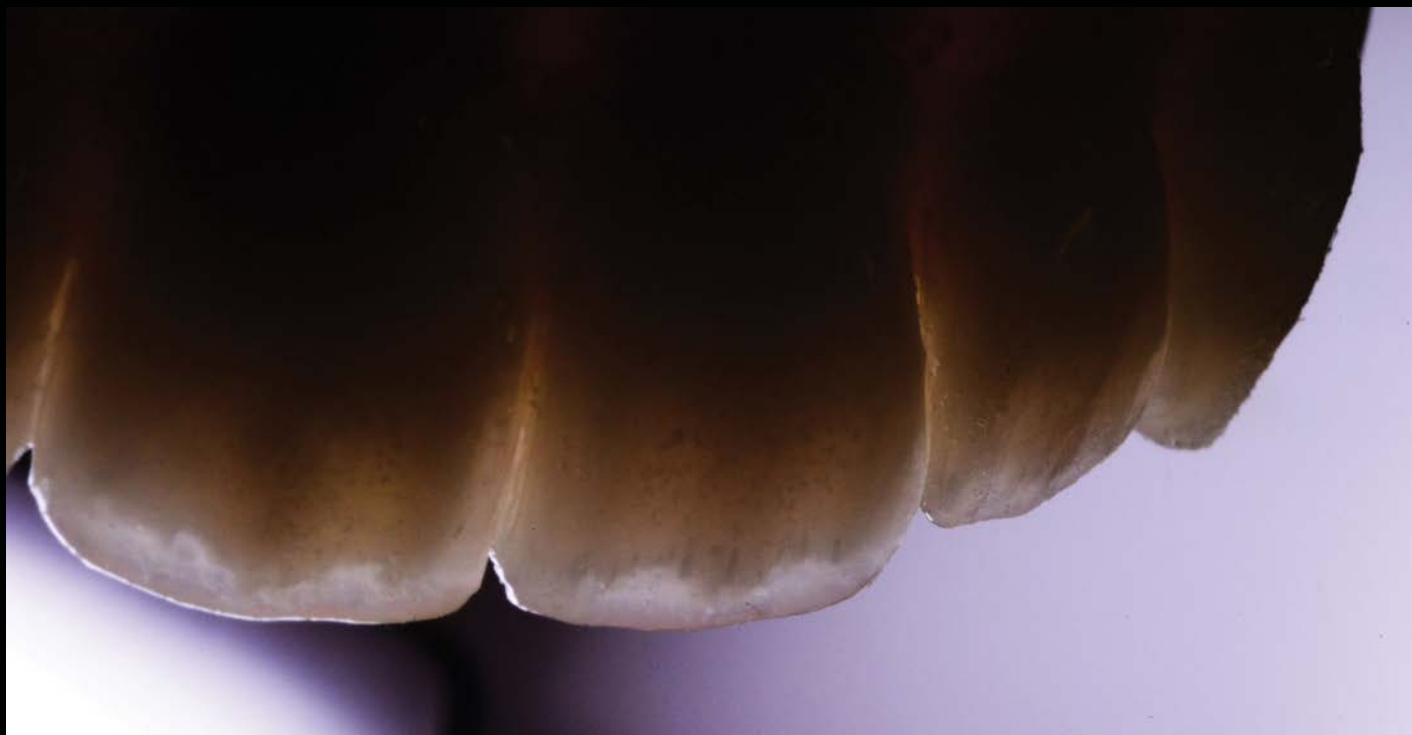

Figure 2: Transilluminated mock-up simulating the dentinoenamel interface.

the natural biological structure of the dentinoenamel interface (**Fig 2**). Throughout the entire course, faculty members and teaching assistants worked closely with us to show us all the different aspects of the profession. Their expertise dovetailed with the videos that Dr. Magne personally recorded for each step of every project. Being able to watch these videos as we completed our own wax-ups and cutback mock-ups allowed for a very detailed review and minimized the chance for errors. Step-by-step manuals provided in this course outlined the important concepts and provided examples to follow along with each new skill we were learning to develop. I think the DMFE module went above and beyond in the cohesive way it taught students who were completely unfamiliar with this territory.

I was fortunate to have a relatively solid background in the art of pencil sketching and clearly understood the concepts of light and dark used to represent a three-dimensional object, such as a tooth, in a two-dimensional drawing. This seemingly unrelated and basic exercise helped me to recognize the different cusps and grooves that exist in a tooth. Moving on to partial and full wax-ups on stone casts was the highlight of my experience in the DMFE module; I greatly enjoyed working with a malleable material that can be melted and shaped to simulate the delicate outlines of a tooth. I learned and loved how I could make a sharp mesial angle but also a smooth, soft distal transition with just a stroke of the heated metal instruments (**Fig 3**). I found my passion and was able to unleash my creativity while constructing my own tooth; it was a great exercise that definitely helped me to understand the outline and shape of each tooth (**Figs 4a & 4b**). Building upon these skills,

// I found my passion and was able to unleash my creativity while constructing my own tooth; it was a great exercise that definitely helped me to understand the outline and shape of each tooth. //

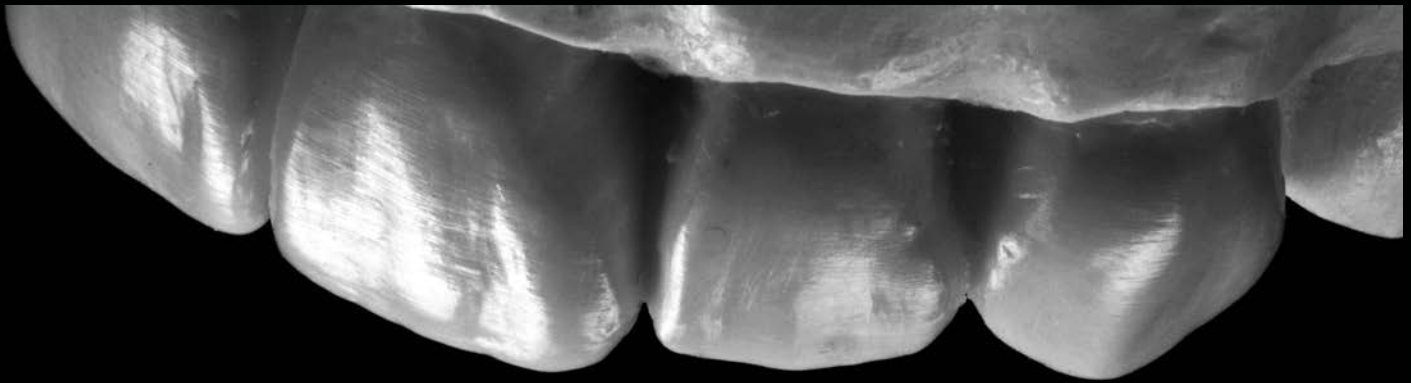
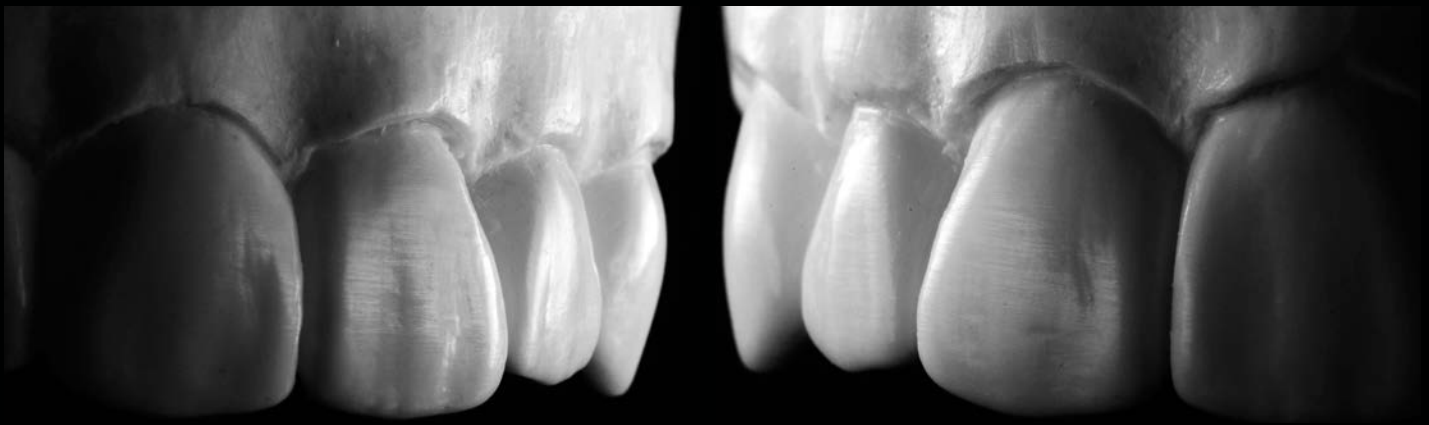

Figure 3: Angled view of wax-up emphasizing straight mesial lobes and round distal lobes on central and lateral incisors.



Figures 4a & 4b: Straight views of left and right anterior wax-up showing three lobes and horizontal texture.

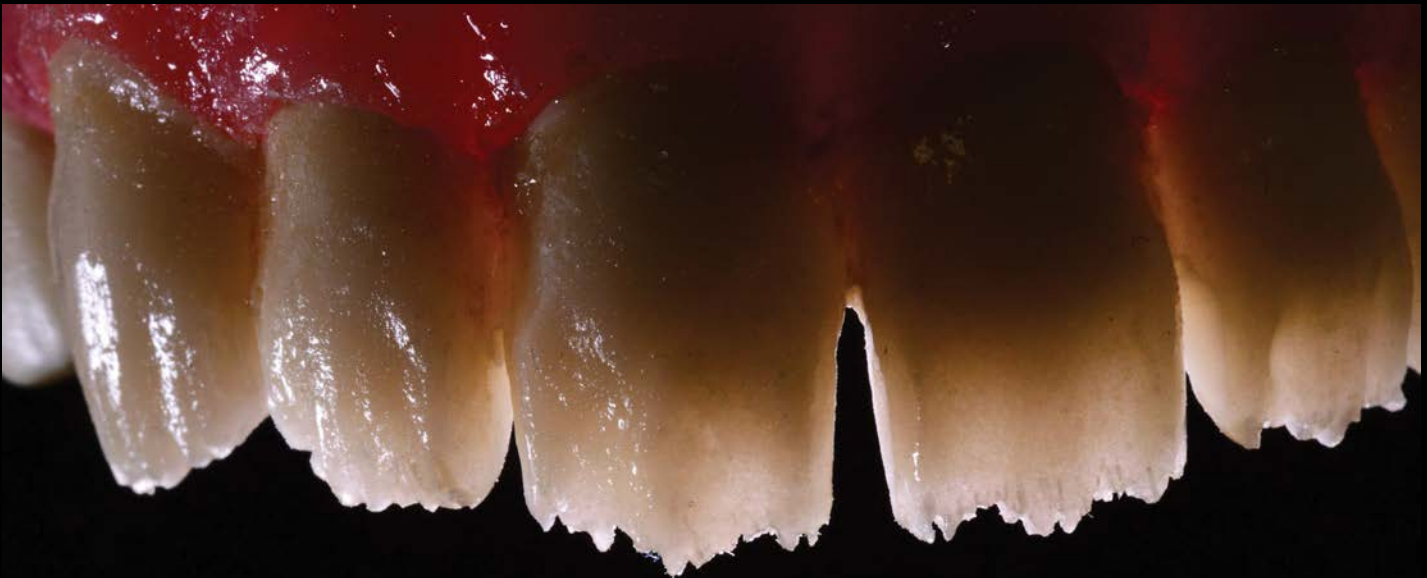


Figure 5: Cutback stage representing inner dentin layer with subtle color staining.

the last “canine-to-canine” cutback exercise topped it all off (**Fig 5**). As a result of learning how to fabricate four-dimensional mock-ups of a full set of anterior teeth, I feel confident in my ability to create restorations that can mimic the translucency of enamel and show through to the dense and strong dentin below (**Fig 6**). I was even able to create the illusion of mamelons through color staining and the dentin cutback layer, giving my mock-ups the look of natural dentition.

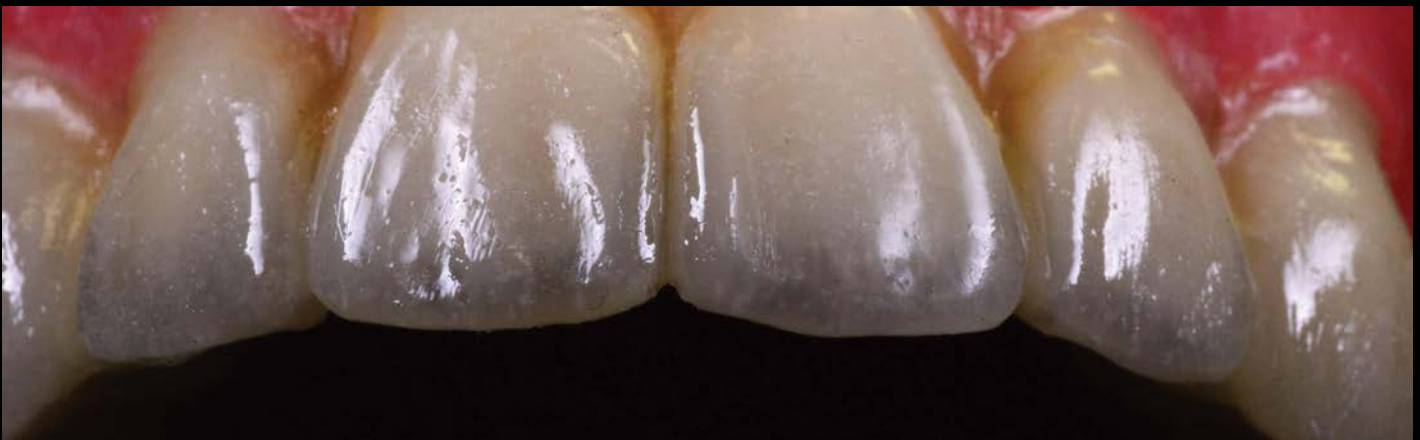

Figure 6: Labio-incisal view of final cutback mock-up.

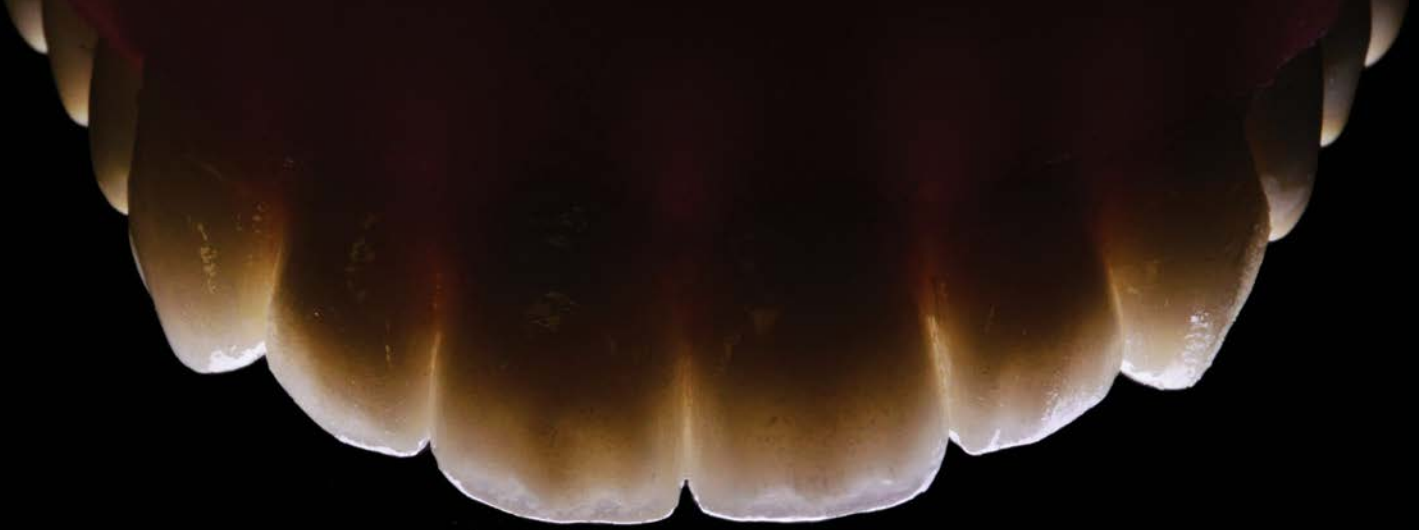

Figure 7: Transilluminated mock-up emphasizing translucent enamel and more dense dentin cutback showing through.

During my time in the DMFE course, I felt a strong connection to the principles of biomimetics. Although esthetic dentistry had always appealed to me and highlighted my artistic side, I never really knew all the complexities and intricate details that were concealed beneath that hard enamel surface (**Fig 7**). This module helped me to better understand what was underneath the surface, making me a better dental student with greater confidence and creativity when restoring teeth. The course not only taught the basics of tooth morphology, its function, and occlusal properties, but it also has enhanced my esthetic restorative ability through increased exposure to high-quality materials and advanced application techniques (**Figs 8 & 9**). Overall, I believe that the DMFE module was very beneficial to my dental education and gave me skills that will further my goals in esthetic dentistry. Last year, I was given the opportunity to serve as a teaching assistant to the first-year dental class of 2018; it was very satisfying to pass on what I had learned and, hopefully, help to instill in future dentists and colleagues the same passion and dedication that I feel. jcd

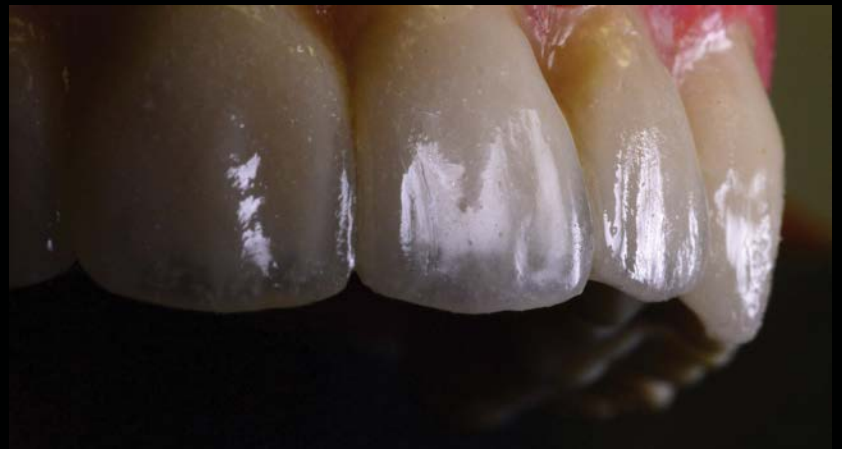

Figure 8: Straight view of anterior cutback mock-up.

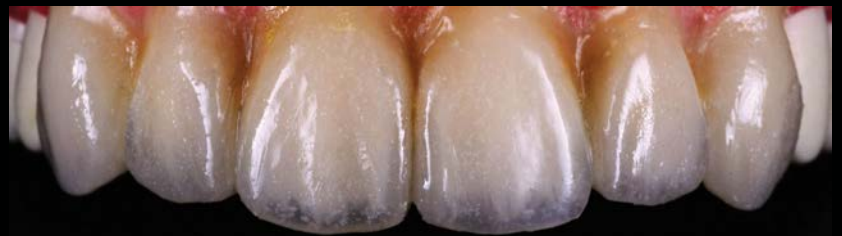

Figure 9: Frontal view of cutback mock-up with color staining to emulate the natural beauty of teeth and interpapillary gingiva.

“Overall, I believe that the DMFE module was very beneficial to my dental education and gave me skills that will further my goals in esthetic dentistry.”

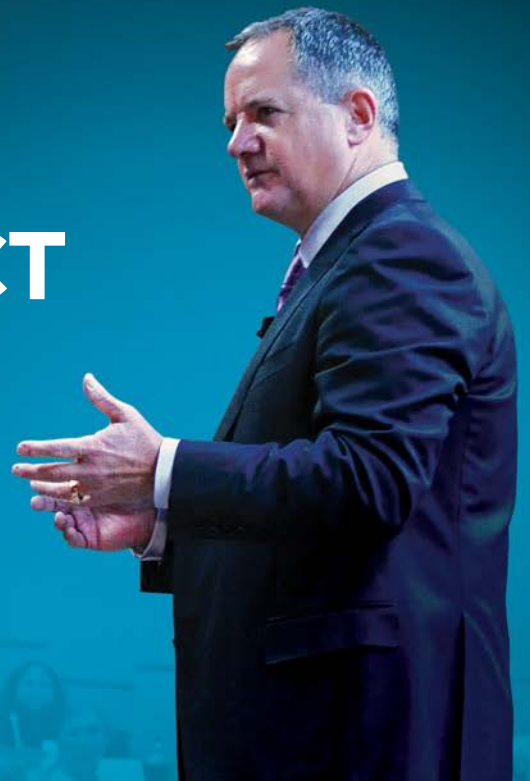

Ms. Du is a second-year student at the Herman Ostrow School of Dentistry of USC, in Los Angeles, California.

Disclosure: The author did not report any disclosures.

SIX WAYS TO POSITIVELY IMPACT YOUR PRACTICE

Make 2015 your year of transformation. Spear seminars lead you to a more productive practice with targeted learning you'll use right away.



2-DAY SEMINARS **15 CE CREDITS**
LOCATION: THE SPEAR CAMPUS, SCOTTSDALE, ARIZ.

1 The Periodontal-Restorative Interface

Feb. 14-15 2015

Explore the essentials of everyday interdisciplinary therapy from the perspective of the periodontist and a restorative dentist

2 Implants - The Surgical/Restorative Connection

April 24-25 2015

Learn treatment planning, placement and restoration of dental implants in both simple and complex implant reconstructions

3 The Art of Treatment Planning and Case Presentation

Aug. 20-21 2015

Understand treatment options for a number of common but complex dental problems

4 Creating Esthetic Excellence

March 26-27 2015

Gain confidence in diagnosing, treatment planning and presenting esthetic dentistry to your patients

5 Demystifying Occlusion

April 30 - May 1 2015

Eliminate the confusion and fear surrounding occlusion in your practice

6 Treating the Worn Dentition

April 9-10 2015 (Chicago) + May 28-29 2015

Acquire a solid foundation in what to look for, how to plan and predictably treat worn dentitions

Learn more at speareducation.com/seminars
or speak to an education advisor at 866.781.0072 or info@speareducation.com.

SPEAR

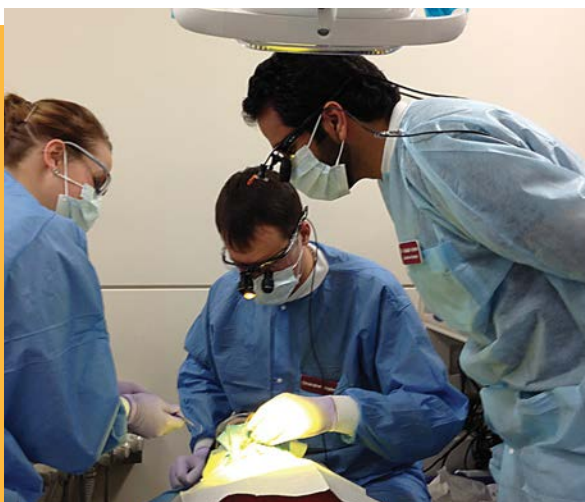

Focusing on Expertise, Leadership Skills, and Passion

The Graduate Program in Operative Dentistry at UIOWA

Gerald E. Denehy, DDS, MS
Deborah S. Cobb, DDS, MS

The program, which began more than 50 years ago, has approximately 120 graduates, more than 80% of whom are now in dental education in the U.S. and internationally.



The primary goal of the University of Iowa's Department of Operative Dentistry is to provide students with the knowledge, technical skills, critical thinking, and judgment to diagnose, prevent, and manage dental caries and non-carious dental defects using minimally invasive adhesive procedures of the highest esthetic quality. The department provides national leadership in dental academia, research, and advanced restorative technology through its continuous efforts in the Graduate Program in Operative Dentistry. We strongly believe that each field of dentistry is best taught by those who have advanced training in that particular domain. Our goal is to provide future educators in operative dentistry with the expertise, leadership skills, and passion to guide curricula and clinical instruction in operative dentistry at their future institutions.

The graduate program includes a three-year Master of Science degree in Oral Science from the University of Iowa and a Certificate in Operative Dentistry. The program, which began more than 50 years ago, has approximately 120 graduates, more than 80% of whom are now in dental education in the U.S. and internationally. The graduates include dental school

deans, graduate program directors, and department chairs. In addition, the program has produced renowned speakers and leaders in the area of esthetic dentistry, including Dr. Edward Swift, Dr. Newton Fahl, Jr., Dr. Marcos Vargas, and Dr. So Ran Kwon.

The graduate program provides a solid foundation in teaching, research, and clinical training in operative dentistry. It is the department's philosophy that a significant amount of learning comes through teaching others. Therefore, students are heavily involved in teaching during each semester of their program. Students directly teach in all levels of dental school courses, including dental anatomy, preclinical operative dentistry, two different levels of clinical operative dentistry, and the student simulation clinic of the direct resin-based composite esthetic course. They are often given the responsibility of preparing a lecture on a specific topic in operative dentistry and presenting it to predoctoral dental students.

The research component of the program gives students the opportunity to develop skills in the area of critical evaluation of dental literature as well as to test their own scientific hypotheses through a research project and a defended thesis. This helps them to gain an appreciation for incorporating evidence-based procedures and materials into their practice philosophy. It also is intended to result in presentation of their research at a major dental meeting and submission of a manuscript for publication in preparation for a career in academic dentistry.

The clinical training aims to develop and refine students' skills in advanced operative dentistry techniques involving caries and non-carious lesions and esthetic dentistry with an emphasis in the area of direct esthetic restorations. We believe that learning the important elements of direct esthetic restorations, including isolation, the bonding process, freehand anatomic resin placement, effective polymerization, and esthetic finishing is essential for all esthetic dental procedures, including indirect restorations. Direct resin-based composites fit nicely into the minimally invasive dentistry principles that guide the department. Graduate students also gain significant clinical experience in comprehensive restorative dentistry within the interdisciplinary environment of the College of Dentistry. Additionally, our graduate program provides the opportunity for clinical case development and preparation for students interested in board certification from the Academy of Operative Dentistry.

The program's ultimate goal is to produce graduates who have evidence-based knowledge and skills in operative dentistry, as well as educators who can impart this knowledge to others in the dental profession.

Dr. Rawa Alammari, co-author of the article, "Minimally Invasive Management of Missing Maxillary Lateral Incisors," which begins on page 38, completed the Graduate Program in Operative Dentistry at The University of Iowa in August 2014, receiving a Master of Science degree and Certificate in Operative Dentistry. She has been accepted into the Oral Science PhD program at The University of Iowa and will work under Dr. So Ran Kwon in the area of tooth whitening. Dr. Alammari excelled in the areas of teaching, research, and patient care throughout her graduate program and is highly motivated to pursue a career in academic dentistry.

During her time in the graduate program, Dr. Alammari gained considerable experience in the area of cosmetic and restorative dentistry. Emphasis is placed on caries risk assessment, preventive interventions, and minimally invasive dentistry. In addition to general restorative dentistry, Dr. Alammari's clinical training included esthetics with direct composite, indirect restorations, restoration of single tooth implants, and complex restorative cases.

Dr. Alammari's clinical expertise and artistry are impressive and we are very proud to have her represent The University of Iowa with her clinical case in this issue of *jCD*.

Acknowledgment

Dr. Cobb expresses her appreciation to Dr. Denehy for his significant contributions as a leading educator in operative dentistry.

It is the department's philosophy that a significant amount of learning comes through teaching others.



Dr. Denehy is the Dr. Bob H. and Jerilee H. Williams Professor in Restorative Dentistry and a professor in the Department of Operative Dentistry, The University of Iowa (UIOWA) College of Dentistry.



Dr. Cobb is an associate professor and graduate program director in the Department of Operative Dentistry, UIOWA College of Dentistry.

Disclosure: The authors did not report any disclosures.

Photo credits: The jCD thanks the University of Iowa for the use of their photos in this editorial.

minimally invasive management of **Missing Maxillary Lateral Incisors**

Canine Substitution with Direct Resin Composite Buildups

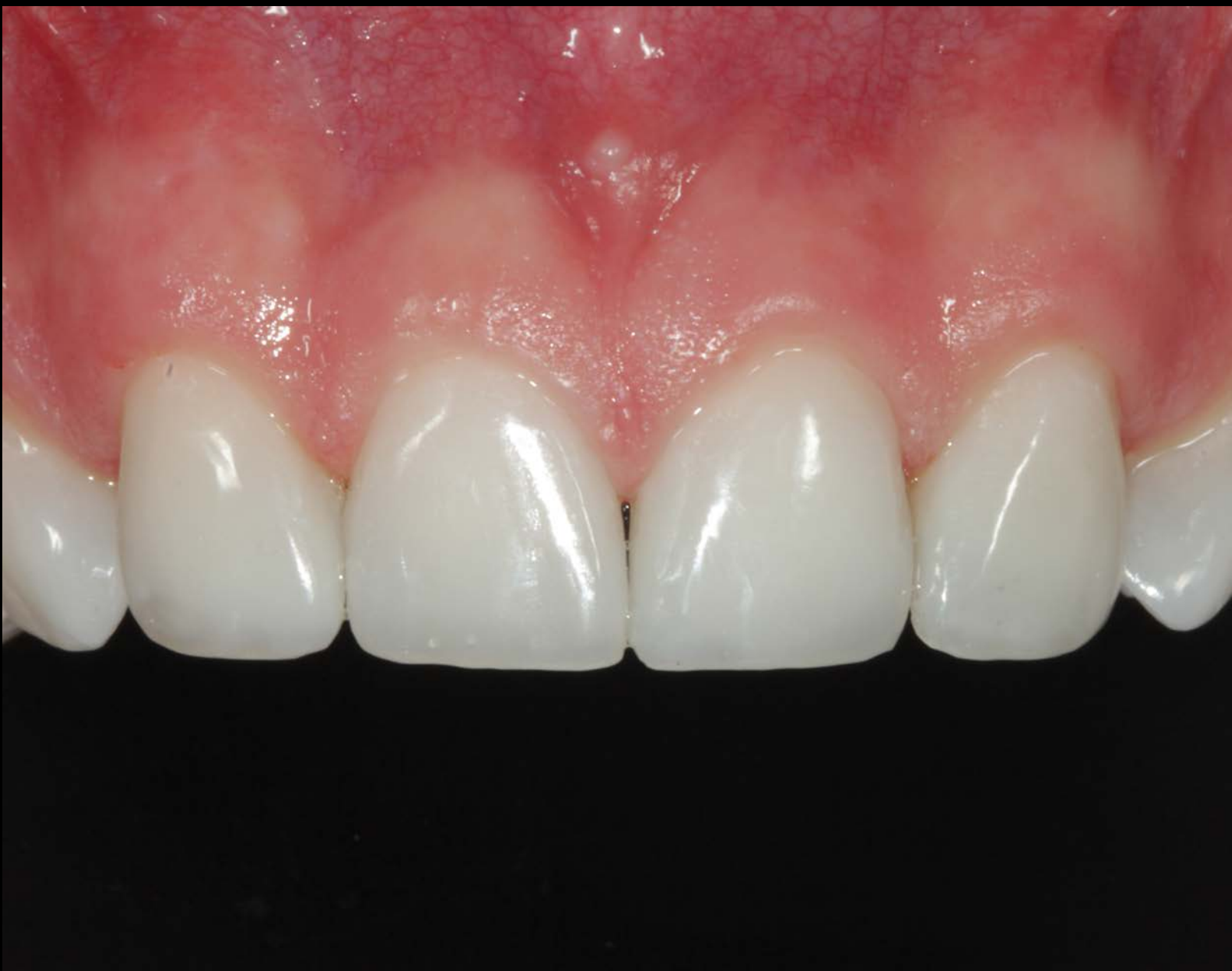There are two common treatment approaches for managing missing lateral incisors.

Rawa Alammari, DDS, MHI, MS
So Ran Kwon, DDS, MS, PhD

Abstract

This case report describes the treatment of a patient with bilateral congenitally missing maxillary lateral incisors managed with orthodontic treatment, followed by canine substitution with direct resin composite buildups. The esthetic concerns of the patient were managed by a careful smile analysis and diagnostic wax-up. Special emphasis was placed on contouring the shape of the canines to mimic and facilitate the buildups to lateral incisors. During the composite buildups, the occlusal scheme was altered to lateral excursive movements in an anterior group function.

Key Words: canine substitution, smile analysis, direct resin composite, lateral incisors



Introduction

Missing maxillary lateral incisors create an esthetic challenge that raises several important issues requiring an interdisciplinary approach.^{1,2} A major key to success in establishing a beautiful smile in patients with missing teeth in the esthetic zone is the clinician's ability to properly diagnose the patient's amount and distribution of spaces and type of malocclusion. Additionally, a clear understanding of the patient's chief complaint and expectations in seeking dental treatment to correct the esthetic concern is essential to be able to address them in a way that is least invasive and also satisfies the patient's esthetic and functional needs.

Two Common Treatment Approaches

There are two common treatment approaches for managing missing lateral incisors.³⁻⁹ The first approach is to create adequate space to replace the missing teeth with traditional fixed partial dentures, resin-bonded fixed partial dentures, removable partial dentures, or osseointegrated implants. This approach is indicated when enough space is available in the maxillary arch, or when maxillary central incisors need to be protruded labially to correct an existing anterior cross bite or to provide enhanced upper lip support.¹⁰ The amount of space needed for orthodontic space opening is dictated by the smile design to fulfill the patient's esthetic needs in the anterior region and functional considerations addressing adequate occlusion. The main advantage of space opening is achievement of an ideal buccal intercuspation with a normal canine relationship. A major drawback is the need for a permanent prosthesis in an area in which tooth color, gingival contour, and margins are critical and not always easy to manage.¹⁰

The second approach is to close the space and substitute the missing lateral incisors with canines. This is indicated in patients with a balanced profile and minimal space available in the maxillary arch. The major advantage of orthodontic space closure is the permanence of the finished result with minimal intervention. In cases where canines cannot be contoured to mimic a lateral incisor, composite buildups can be utilized to improve the esthetic outcome. Disadvantages include the inability to establish canine-protected occlu-

sion, necessitating that the final occlusal scheme be designed with lateral excursive movements in an anterior group function.¹¹ The orthodontist plays a key role in both approaches to achieve specific space requirements by aligning teeth to an ideal position.

Esthetics

Esthetics are subjective and therefore may be judged differently by the patient and the dentist. A study by Armbruster and colleagues attempted to determine how general dentists, orthodontists, combined dental specialists, and laypeople perceived the relative attractiveness of a series of photographs that showed the treatment outcomes in cases of missing maxillary lateral incisors.¹² The cases were treated with Maryland bridges, dental implants, and orthodontic space closure with canine substitution. The results revealed that the groups differed in their evaluations of the photographs, with laypeople ranking photographs of the canines substituted as lateral incisors to be the best of all options. Another study, by Brough and colleagues, compared orthodontists', general dentists', and laypeople's differing perceptions of the influence of canine morphology, size, and shade on smile attractiveness in cases of canine substitution for missing maxillary lateral incisors.¹³ All three groups agreed that the morphology and color of canines have a significant effect on perceived esthetics. Dentists preferred natural shades, whereas laypeople preferred bright shades. Regarding the width of canines, 1.5-mm reductions were scored highly by orthodontists and dentists, while 3.0-mm reductions were scored highly by laypeople, supporting the notion that esthetics is subjective and the criteria different for dental professionals and laypeople. Thus, it is critical to involve the patient in the decision-making process so as to achieve a mutually satisfying result.

The following case report describes the treatment of a patient with bilateral congenitally missing maxillary lateral incisors managed with orthodontic treatment, followed by canine substitution with direct resin composite buildups.

Patient History

A 16-year-old male presented with bilateral congenitally missing maxillary lateral incisors with multiple diastemas between his maxillary anterior teeth (Figs 1-4). He had completed orthodontic treatment to redistribute the space and facilitate canine substitution for the lateral incisors. The patient was on the school wrestling team and had experienced a traumatic injury that caused some chipping and infraction on his anterior teeth. He was unhappy with his smile and desired improved esthetics by addressing the multiple spaces and the shape and color of his maxillary canines. He was in good health with no remarkable issues in his medical history.

Diagnosis and Treatment Planning

A thorough clinical examination including radiographs was completed at the first visit (Figs 5 & 6). Baseline photographs and impressions were taken to plan for the final treatment. The examination revealed multiple diastemas between the maxillary anterior teeth, a horizontal craze line, and chipped enamel on the left maxillary central incisor. The patient presented a Class II molar and canine relationship with a 2-mm overjet and overbite. No temporomandibular joint abnormalities were noted. Treatment options included six upper porcelain laminate veneers, or space closure with direct resin composite buildups. Considering the patient's age and cost of the treatment, the patient and his parents decided upon the second treatment option.

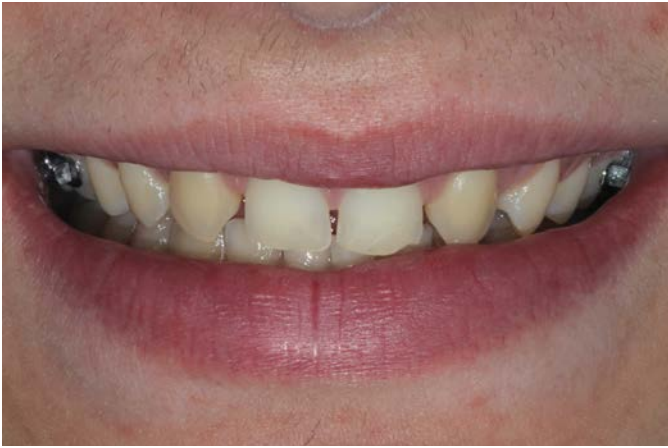

Figure 1: Preoperative image of patient's smile.

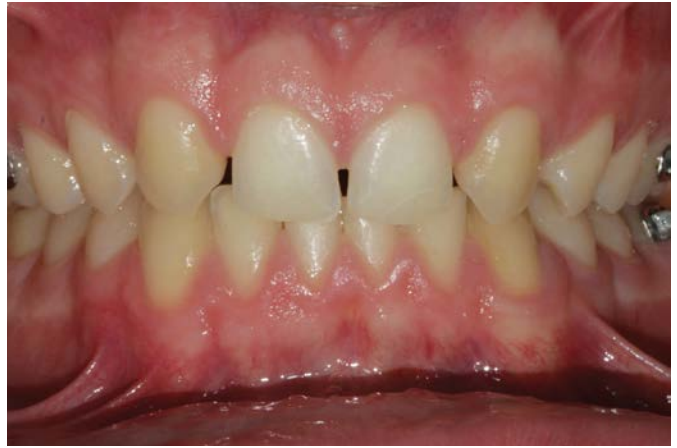

Figure 2: Preoperative intraoral frontal view.

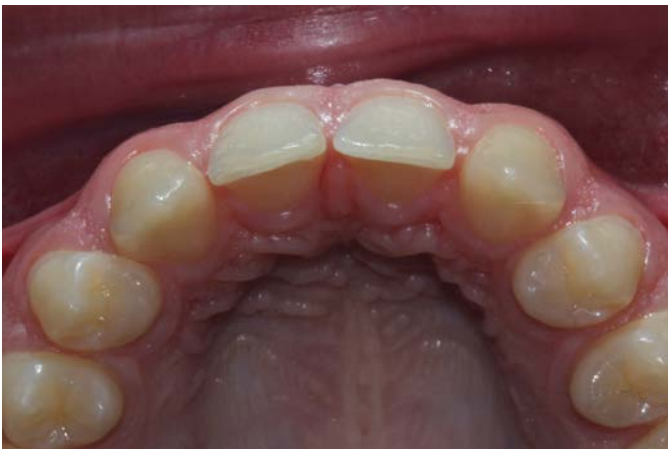

Figure 3: Preoperative intraoral incisal view.

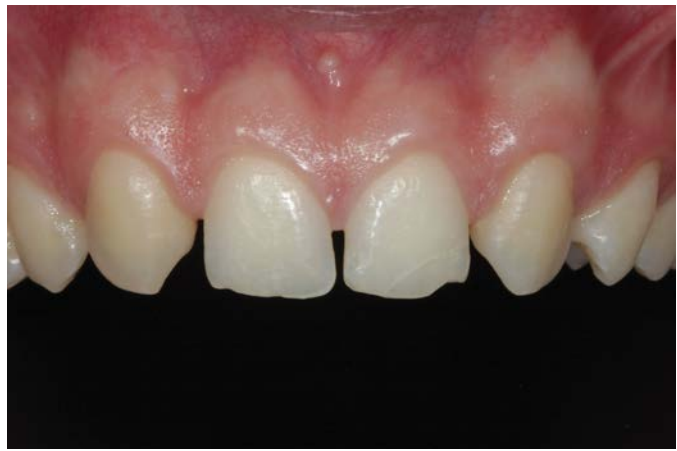

Figure 4: Preoperative intraoral frontal view of maxillary anterior teeth.

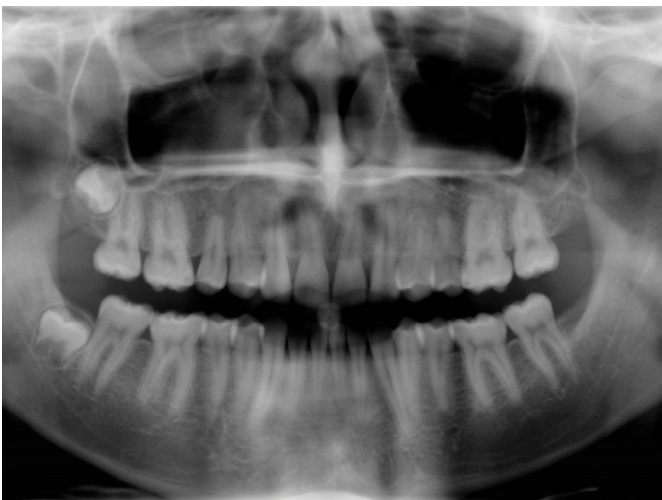

Figure 5: Pantomograph at initial visit.

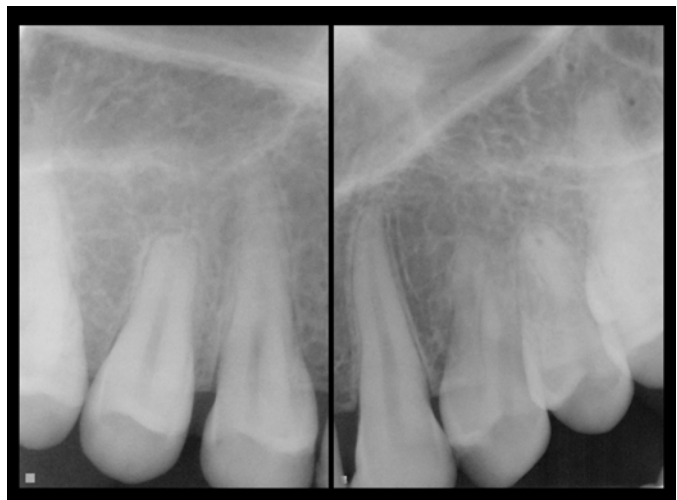

Figure 6: Periapical radiographs.

Biological Considerations

Clinical and radiographic examinations revealed healthy periodontal condition. This was a favorable factor for the long-term prognosis of the anterior direct resin composite buildups.

Esthetic Considerations

Contouring of the upper canines and whitening the tooth color to blend in with the adjacent teeth were key for success in this case. The gingival contour would not be altered due to the patient's moderately low lip line.

Functional Considerations

Adjustment of the occlusal scheme to lateral excursive movements in an anterior group function was essential in preventing any overload to the upper first premolars.

Treatment Plan Sequence

1. Tooth whitening to establish color balance of central incisors and canines.
2. Recontouring of maxillary canines to facilitate composite buildups.
3. Direct resin composite buildups of #5, #6, #8, #9, #11, and #12 to close spaces and establish proper anterior teeth proportions.
4. Fabrication of retainer and mouthguard to provide retention of existing occlusion and protect teeth when the patient wrestled.

Description of Treatment

Smile Analysis

The study casts (Fig 7) and preoperative photographs were analyzed following the basic smile checklist of The University of Iowa College of Dentistry's Department of Operative Dentistry (Table 1). The amount of contouring needed for the maxillary canines and the buildups on the planned six teeth was transferred to a three-dimensional diagnostic wax-up with a focus on developing features within the parameters provided, including the facial and dental mid-lines, incisal edge position relative to the lower lip line, tooth angulation, and proper occlusal scheme (Fig 8).¹⁴ This wax-up was also used to fabricate a lingual matrix using a silicone matrix material (Template, Clinician's Choice Dental Products; New Milford, CT).

The orthodontist plays a key role in both approaches to achieve specific space requirements by aligning teeth to an ideal position.

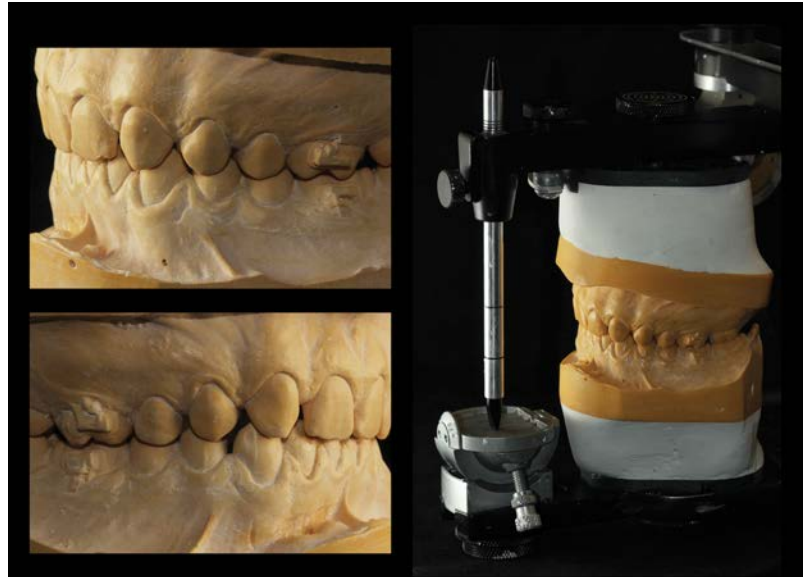


Figure 7: Mounted maxillary and mandibular casts.

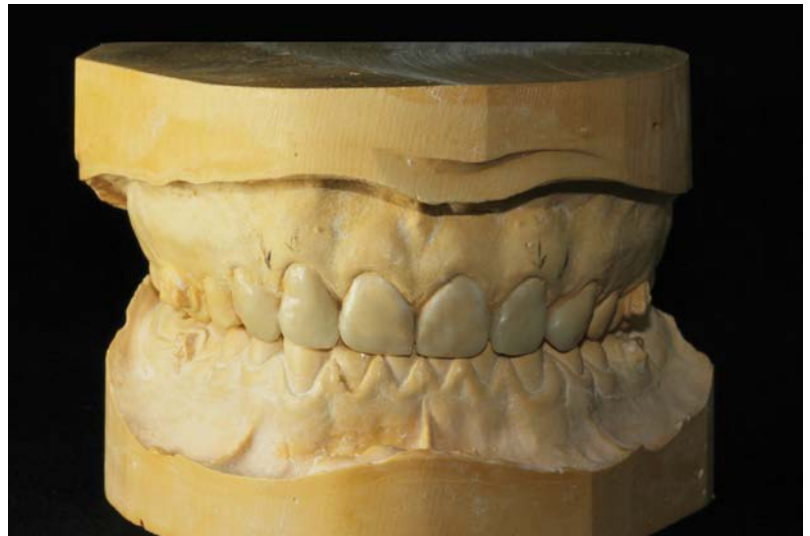

Figure 8: Diagnostic wax-up.



Smile height	Interlabial distance at rest	Exposure of upper central incisors at rest	Upper central incisors RATIO
<input type="checkbox"/> Low (< 1mm)	<input type="checkbox"/> Low (< 1mm)	<input type="checkbox"/> < 1mm	<input type="checkbox"/> < 75 %
<input type="checkbox"/> Medium (1-3mm)	<input type="checkbox"/> Medium (1-3mm)	<input type="checkbox"/> 1-5mm	<input type="checkbox"/> 75-80%
<input type="checkbox"/> High (> 3mm)	<input type="checkbox"/> High (> 3mm)	<input type="checkbox"/> > 5mm	<input type="checkbox"/> >80%

CENTRAL INCISORS ideal RATIO (WIDTH : LENGTH) \cong 75 - 80%
 The upper CENTRAL incisors are WIDER than upper LATERAL incisors \cong 2.0 - 3.0 mm
 The upper CENTRAL incisors are WIDER than upper CANINES \cong 1.0 - 1.5 mm
 The upper CANINES are WIDER than upper LATERAL incisors \cong 1.0 - 1.5 mm
 The upper CENTRAL incisors have \cong 1 1/2 the width of the lower CENTRAL incisors



Table 1. Smile Checklist.

Tooth Whitening

Baseline shade measurements were taken using the VITA Classic shade guide (VITA Zahnfabrik; Bad Säckingen, Germany). The upper canines were determined to be A2 and the adjacent teeth B1. A custom-fabricated tray was delivered with a 10% carbamide peroxide at-home whitening gel (Opalescence PF, Ultradent; South Jordan, UT). At the whitening check appointment, significant whitening of the upper arch compared to the non-whitened lower arch was noted (Fig 9). The upper canines remained more chromatic on the cervical areas but blended in with the adjacent teeth (Fig 10). The lower tray was delivered to continue whitening on the lower arch. The patient did not experience any sensitivity and was very satisfied with the whitening outcome. A two-week waiting period was planned prior to initiating restorative procedures to allow for optimal bond strength and color stabilization.

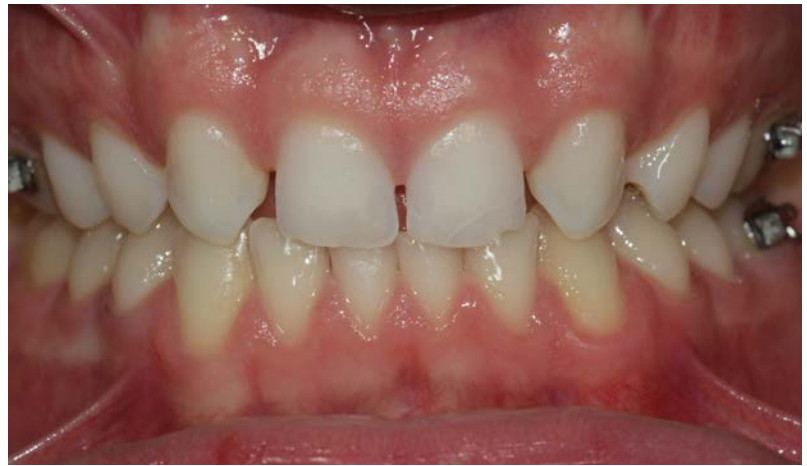

Figure 9: Post-whitening intraoral frontal view.

Three different shades... were selected for the enamel replacement, dentin replacement, and halo effects, respectively.

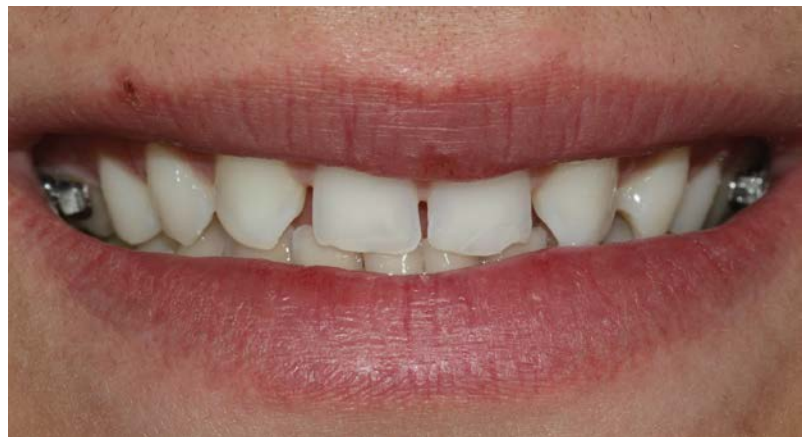

Figure 10: Post-whitening image of patient's smile.

Direct Resin Composite Buildup

The natural layering protocol was followed to optimize esthetic results with the use of Estelite Omega, a nanohybrid composite resin material (Tokuyama Dental; Tokyo, Japan).¹⁵ A custom-fabricated shade guide was used for proper shade selection (Fig 11). Three different shades—MW, BL2, and Trans—were selected for the enamel replacement, dentin replacement, and halo effects, respectively (Fig 12). The lingual silicone matrix was used to facilitate the build up of the lingual profile, width, and the positions of the incisal edge of the direct resin composite restoration. The first layer (MW) was placed directly onto the lingual matrix and transferred to the lingual surface of the anterior teeth and light-cured (Fig 13). A thin layer of Trans was placed just short of the incisal edges. BL2 was then used as a dentin replacement material, followed by a final enamel layer of MW. Tight and properly contoured contacts were achieved using the “pull-through” matrix technique, in which a strip is pulled from the facial toward the lingual to push the resin material through the proximal to form a smooth contour adapted properly to the adjacent tooth (Fig 14).^{16,17} Final polishing and occlusal adjustment of the buildups was performed and postoperative photographs taken (Figs 15 & 16). The patient was very happy with the final esthetic outcome (Figs 17 & 18).



Figure 11: Custom-fabricated Estelite Omega shade guide tabs.

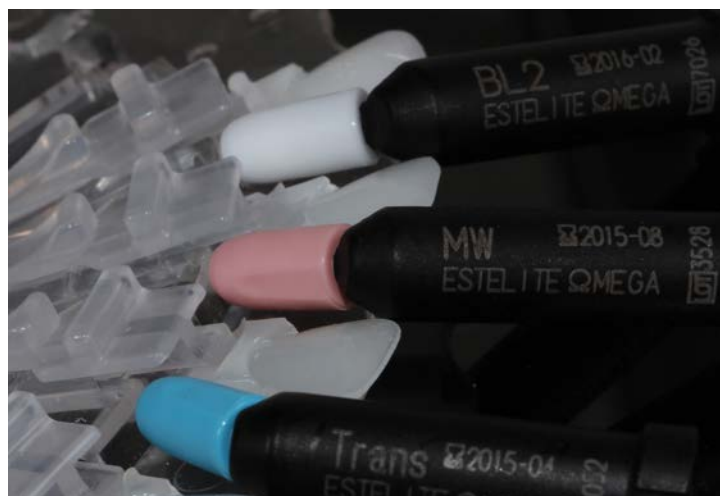

Figure 12: Selected shades for treatment (MW, Trans, BL2).



Figure 13: Silicone lingual matrix filled with resin shell of MW.

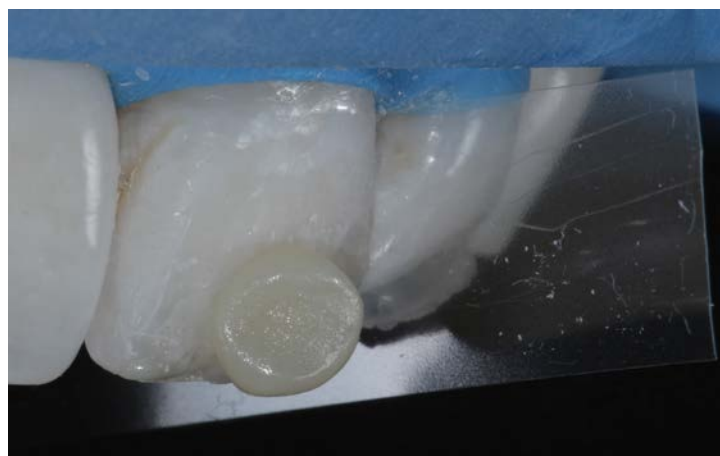

Figure 14: Pull-through technique using a clear celluloid strip.

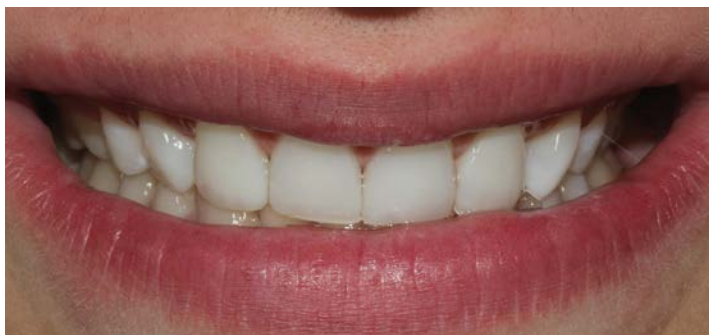

Figure 15: Postoperative image of patient's smile.

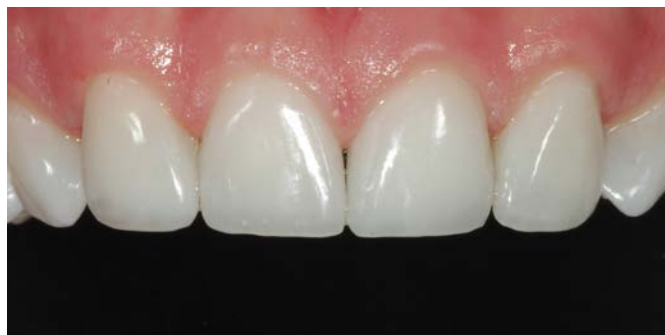

Figure 16: Postoperative intraoral frontal view of maxillary anterior teeth.

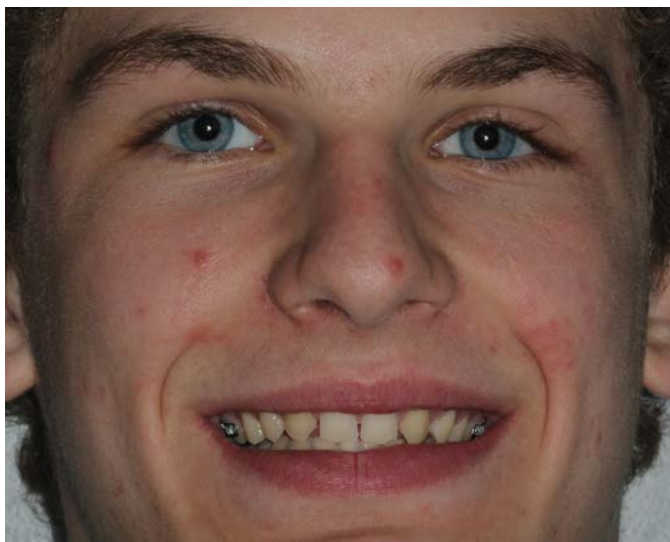

Figure 17: Preoperative image of patient's full smile.



Figure 18: Postoperative image of patient's full smile.

Summary

This case report described the treatment of a patient with bilateral congenitally missing maxillary lateral incisors managed with orthodontic treatment, followed by canine substitution with direct resin composite buildups (Figs 19a-19c). A major key to success in this case was the clinicians' ability to properly address the patient's esthetic concerns. Multiple spaces in the esthetic zone were managed by a careful smile analysis to meet all esthetic parameters. Special emphasis was placed upon contouring the shape of the canines to mimic and facilitate the buildups to lateral incisors. During the composite buildups, the occlusal scheme was altered to lateral excursive movements in an anterior group function. The authors expect that the minimally invasive management with canine substitution will serve the patient as a long-lasting esthetic and functional treatment.

Acknowledgments

The authors thank Drs. Gerald Denehy, Deborah Cobb, and Rodrigo Maia for their expertise and feedback, which helped lead to the success of this case. They also recognize the orthodontic treatment provided by Dr. John Sleichter.

References

1. Zilberman Y, Cohen B, Becker A. Familial trends in palatal canines, anomalous lateral incisors, and related phenomena. *Eur J Orthod.* 1990 May;12:135-9.
2. Kavadia S, Papadiochou S, Papadiochos I, Zafiriadis L. Agenesis of maxillary lateral incisors: a global overview of the clinical problem. *Orthodontics (Chic.).* 2011 Winter;12(4):296-317.
3. Millar BJ, Taylor NG. Lateral thinking: the management of missing upper lateral incisors. *Br Dent J.* 1995 Aug 5;179(3):99-106.
4. Araújo EA, Oliveira DD, Araújo MT. Diagnostic protocol on cases of congenitally missing maxillary lateral incisors. *World J Orthod.* 2006 Winter;7(4):376-88.
5. Argyropoulos E, Payne G. Techniques for improving orthodontic results in the treatment of missing maxillary lateral incisors. *Am J Orthod Dentofacial Orthop.* 1988 Aug;94(2):150-65.

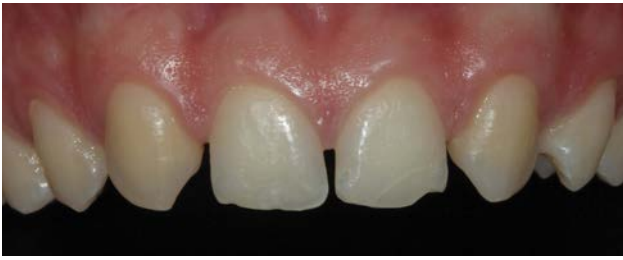

Figure 19a: Preoperative intraoral frontal view of maxillary anterior teeth.

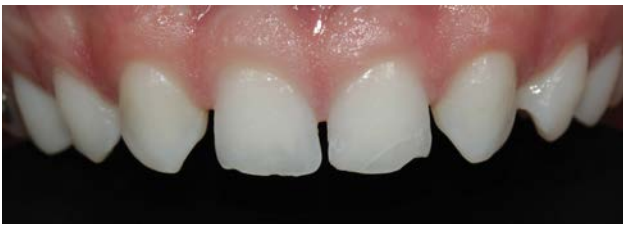

Figure 19b: Post-whitening intraoral frontal view of maxillary anterior teeth.

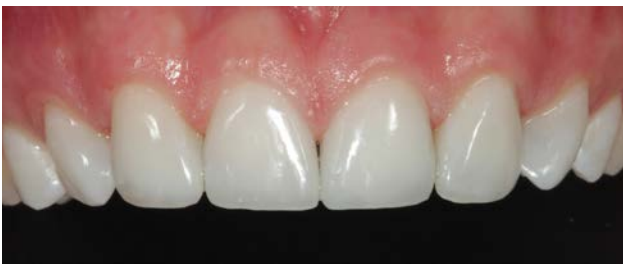

Figure 19c: Postoperative intraoral frontal view of maxillary anterior teeth.

Multiple spaces in the esthetic zone were managed by a careful smile analysis to meet all esthetic parameters.

6. Rosa M, Zachrisson BU. Integrating esthetic dentistry and space closure in patients with missing maxillary lateral incisors. *J Clin Orthod*. 2001 Apr;35(4):221-34.
7. Kinzer GA, Kokich VO Jr. Managing congenitally missing lateral incisors. Part II: tooth-supported restorations. *J Esthet Restor Dent*. 2005;17(2):76-84.
8. Kinzer GA, Kokich VO Jr. Managing congenitally missing lateral incisors. Part III: single-tooth implants. *J Esthet Restor Dent*. 2005;17(4):202-10.
9. Krassnig M, Fickl S. Congenitally missing lateral incisors—a comparison between restorative, implant, and orthodontic approaches. *Dent Clin N Am*. 2011 Apr;55(2):283-99.
10. Sabri R. Management of missing maxillary lateral incisors. *J Am Dent Assoc*. 1999 Jan;130(1):80-4.
11. Kokich VO Jr, Kinzer GA. Managing congenitally missing lateral incisors. Part I: canine substitution. *J Esthet Restor Dent*. 2005;17(1):5-10.
12. Armbruster PC, Gardiner DM, Whitley JB Jr, Flerra J. The congenitally missing maxillary lateral incisor. Part 1: esthetic judgment of treatment options. *World J Orthod*. 2005;6(4):369-75.
13. Brough E, Donaldson AN, Naini FB. Canine substitution for missing maxillary lateral incisors: the influence of canine morphology, size, and shade on perceptions of smile attractiveness. *Am J Orthod Dentofacial Orthop*. 2010 Dec;138(6):705.e1-9.
14. Paolucci B, Calamita M, Coachman C, Gürel G, Shaydar A, Hallawell P. Visagism: the art of dental composition. In: Duarte S, editor. *QDT 2012*. Hanover Park (IL): Quintessence Pub.; 2014. p. 1-14.
15. Dietschi D, Ardu S, Krejci I. A new shading concept based on natural tooth color applied to direct composite restorations. *Quintessence Int*. 2006 Feb;37(2):91-102.
16. Kwon SR, Denehy GE. Predictable diastema closure using an innovative, indirect mock-up technique. *Cosmetic Dent*. 2011;5(3):12-5.
17. Denehy GE. A direct approach to restore anterior teeth. *Am J Dent*. 2000 Nov;13(Spec No):55D-59D. **jCD**



Dr. Alammari completed The University of Iowa Graduate Program in Operative Dentistry in 2014, receiving a Master of Science degree and Certificate in Operative Dentistry. She has been accepted into the Oral Science PhD Program at The University of Iowa and will work under Dr. So Ran Kwon in the area of tooth whitening.



Dr. So Ran Kwon is an associate professor in the Department of Operative Dentistry at The University of Iowa College of Dentistry.

Disclosure: The authors did not report any disclosures.

Comfort Patients Remember.

Revolutionary Crescent Bodyrest System

- Calms and reduces fear and anxiety in the dental chair
- Stabilizes and aligns patient
- Relieves lower back and hip pain from sitting for extended periods of time
- Cushions and supports entire body for maximum comfort
- Gently supports and tilts patient's head back to naturally turn jaw up and open
- Removes voids between patient and dental chair

**Transform the patient experience in your dental chair.
Choose the Crescent Bodyrest System.**



800.989.8085 • www.CrescentProducts.com

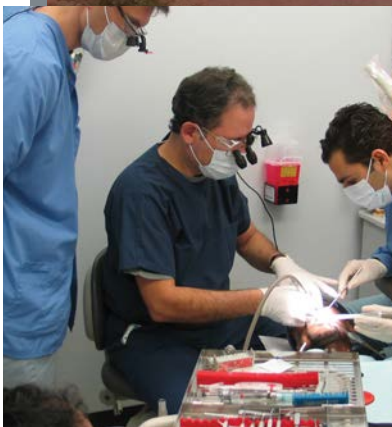An Innovative Interdisciplinary Teaching Environment

The Ronald Goldstein Center for Esthetic and Implant Dentistry at GRU

Barry D. Hammond, DMD

Esthetics in the dental school curriculum is typically taught one of three ways: through a course dedicated to dental esthetics, by means of esthetics topics intermingled with other preclinical courses, or a combination of both. The undergraduate program at Georgia Regents University (GRU) College of Dental Medicine offers topics on esthetics techniques and materials via several courses in the preclinical curriculum as well as in a dedicated esthetics course given in the third year.

As the knowledge base regarding esthetics techniques and materials continues to expand, it is increasingly evident that it is difficult, at best, to schedule larger or more complex cases in the conventional academic clinical setting. Providing a high level of esthetic care requires students and faculty members alike to pay particular attention to details. Just as students have had minimal experience with advanced esthetics techniques (such as porcelain laminate veneers), not all faculty are equally trained or comfortable supervising such procedures. To enable students to provide these types of services under the skillful supervision of highly trained and calibrated faculty, a new and innovative teaching environment was implemented that pairs an undergraduate senior dental student with a postgraduate prosthodontic resident.



...it is increasingly evident that it is difficult, at best, to schedule larger or more complex cases in the conventional academic clinical setting.

Due to time and space restrictions as well as ceramist support, the program allows for a limited number of participants each year. Students are selected for participation based upon academic standing and proficiency in other clinical requirements, and must be willing to meet the additional demands required of them. These include time, laboratory work, research of techniques and materials, and a commitment to excellence. Also, the patient's needs must meet selected criteria for acceptance into GRU's Goldstein Center for Esthetic and Implant Dentistry as a student/resident case. Advantages of this teaching approach include allowing the student to work with an interdisciplinary team and resident in planning more complex cases; performing diagnostic and preparatory procedures (including comprehensive wax-ups, surgical guides, and esthetic mock-ups); and providing the opportunity to participate in additional learning opportunities afforded by this type of dedicated educational/clinical environment. Additionally, there is improved continuity of care that is beneficial not only to the patient but also to the student, as they do not have numerous faculty members working with them throughout the treatment process, which at times can be confusing and counterproductive. Through the Center, students are immersed in all aspects of esthetic care, including occlusion, dental materials, laboratory procedures, and digital photography. The result has been a significant increase in their confidence in performing esthetic dental procedures. An added benefit is the mentor/teacher experience gained by the graduate prosthodontic resident. Both students and patients attest to the unique experience. The following testimonial captures its essence from the perspective of a student who went on to complete her prosthodontic residency training and served as a graduate mentor as well:

"As a student, I was introduced to a level of dentistry that raised the bar for my clinical performance and created a standard for evaluating ceramic restorations. As a resident, it has been my pleasure to help students find ways to connect with their patients and increase their knowledge in delivering esthetic treatment." (Amy Camba, Medical College of Georgia Class of 2010).

The vision of GRU's interdisciplinary esthetics team is to create an environment that is innovative and exciting, one that fosters students' desire to expand their knowledge of comprehensive treatment that is esthetically focused and evidenced-based. This educational opportunity provided through the Center for Esthetic and Implant Dentistry is now in its sixth year and has seen an increase in the number of students interested in participating as well as in the number of procedures and indirect units fabricated each year. Even though the selection process and demands on the students are very rigorous, those that have elected to take advantage of this opportunity have come away with the knowledge, experience, skills, and a level of confidence that will help them to succeed in their future graduate programs or practices.

Dr. Marko Tadros, now a first-year prosthodontic resident at GRU, was a third-year student at GRU College of Dental Medicine when he started working on the case featured in this issue of *jCD*. He decided to work under the mentorship of Dr. Gerard Chiche to achieve the patient's chief request of an esthetically pleasing smile. Through interdisciplinary treatment planning and including the patient in potential outcomes, the final restorations exceeded the patient's expectations and earned Dr. Tadros first place at DSD (Digital Smile Design) Super Week USA - Miami in 2014. To read the article co-authored by Dr. Tadros, please turn to page 50.

Students...must be willing to meet the additional demands required of them. These include time, laboratory work, research of techniques and materials, and a commitment to excellence.



Dr. Hammond is an associate professor and director of Dental Continuing Education, Department of General Dentistry, Georgia Regents University College of Dental Medicine in Augusta, Georgia.

Disclosure: The author did not report any disclosures.

Photo credits: The *jCD* thanks Georgia Regents University for the use of their photos in this editorial.

A Blended, Novel Team Approach in Academic Esthetic Dentistry

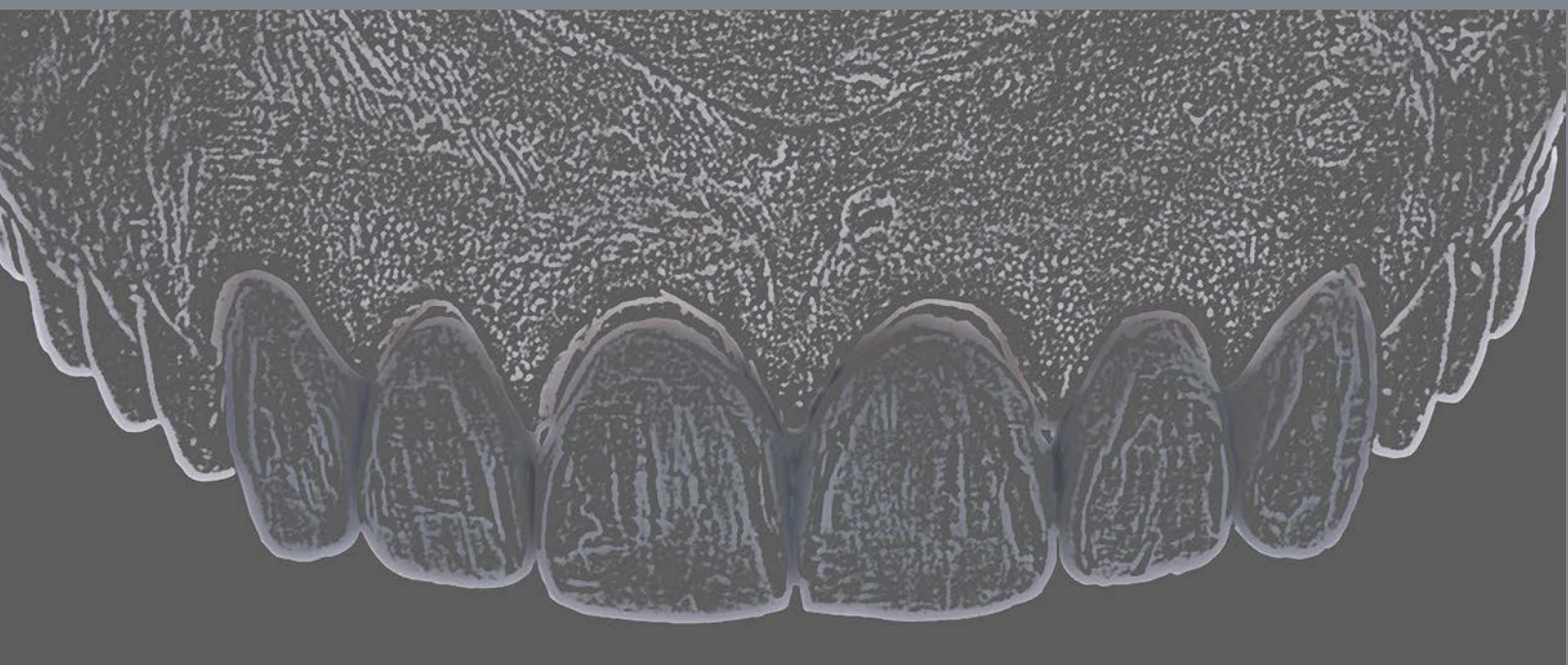
Correcting Esthetic and Functional Issues at GRU Using Conservative Veneers and Periodontal Surgery

Barry D. Hammond, DMD
Jae Seon Kim, DDS, MSD, FACP
Jimmy Londono, DDS
Marko Tadros, DMD
Aram Torosian, CDT, MDC, AS

Abstract

Patients are seeking esthetic dental care in ever-increasing numbers. Dentists learn to perform the required procedures in dental school, residency training, practice experience, or at postgraduate education centers. Utilizing a team approach (dental student paired with a postdoctoral dental resident) under the supervision of a highly qualified, interdisciplinary team of faculty has led to a new and effective approach to implement clinical esthetic training into the predoctoral education curriculum. The following case demonstrates the exceptional results that can be obtained in such a highly controlled environment while providing the undergraduate student with a valuable and exciting learning experience.

Key Words: porcelain veneers, esthetic crown lengthening, minimally invasive dentistry, interdisciplinary dentistry, digital smile design



Introduction

Patients seek elective esthetic dentistry for a variety of reasons, including improving self-esteem, enhancing attractiveness, and increasing chances for career success.¹ In fact, the same source reveals that virtually all Americans (99.7%) believe that an attractive smile is an important social asset. Regardless of the motivational factors, patients' demand for treatment to improve the esthetics of their anterior teeth is steadily growing.² It is, however, incumbent upon all dentists to practice ethical dentistry and provide the least invasive treatment that will meet the esthetic objectives of the patient and the treatment goals (esthetic and functional) of the practitioner.

There are numerous benefits to conservative care, including tooth conservation,^{3,4} longevity,^{4,7} maintenance of periodontal health by virtue of the ability (in many instances) to keep cervical margins supragingival or equigingival,⁸ and reduced chance for endodontic consequences.^{3,9} Additionally, porcelain is considered the most esthetic and biocompatible material in dentistry,² having the capacity to replicate the esthetically pleasing characteristics and vitality of natural teeth.¹⁰ Ultimate restorative success must always begin with an appropriate diagnosis and well-thought-out treatment plan, which often mandates an interdisciplinary approach. In cases of significant wear and parafunctional activity, particular attention must be given to the pathways of occlusion in order to restore the dentition to the best functional scheme possible. However, even with advances in ceramic materials and adhesive techniques,¹¹ esthetic rehabilitations likely will not withstand the ravages of occlusal and functional disharmony, as reported by Christensen and Walls, who showed higher incidences of veneer fractures in patients with a history of bruxism.^{12,13}

Although there generally are several treatment options that can be considered and should be discussed with the patient, the preferred option may require additional time and cost to achieve the optimal result while preserving tooth structure for bonding and structural integrity. Any patient constraints (e.g., time, finances, fear) must be dealt with on an individual basis and the benefits to following the proposed course of treatment explained.

“It is...incumbent upon all dentists to practice ethical dentistry and provide the least invasive treatment that will meet the esthetic objectives of the patient and the treatment goals (esthetic and functional) of the practitioner.”

Too often, shortcuts taken for the sake of expedience may ultimately affect the long-term success of the care provided.

Setting the frame for the ideal tooth proportions for optimal esthetics may involve esthetic periodontal crown lengthening or orthodontic tooth movements, which secondarily may allow for more conservative preparations. It has been shown that conservatively prepared veneers can recover strength that is lost as an inherent part of tooth preparation for restorative procedures,¹⁴ restoring the fracture strength of teeth to values of intact teeth.¹⁵⁻¹⁷ Because of the esthetic nature of these restorations as well as their durability and biocompatibility, porcelain veneers are considered in most cases to be the standard of care for the treatment of anterior teeth.⁶ Teeth often can be prepared conservatively (especially in cases where the goal is to augment volume), thereby keeping the majority of the preparation in enamel, which has been shown to improve long-term success.¹⁸ Friedman observed that the best long-term retention for porcelain veneer restorations is achieved when at least 50% of the supporting substrate is enamel and all finish lines end within enamel.¹⁸ Further, Rinke and colleagues showed a 10-fold higher risk for technical complications for veneers where greater than 50% of the preparation was in dentin.¹¹ When parafunctional habits are controlled and there is suitable substrate in which to bond porcelain laminate veneers, the survival rate has been shown to be highly successful (the longest follow-up, involving 3,500 porcelain veneers, had a 93% success rate over 15 years⁵ and a 2005 study showed a success rate of 94.4% at 12 years⁶). Results from Edelhoff and Sorensen suggest that minimally invasive veneer preparations offer significant advantages over conventional crown preparations, in that less than half the amount of tooth structure was removed compared to the most conservative complete crown preparation.⁹ Porcelain laminate veneers offer a predictable and successful treatment option that preserves a maximum amount of sound tooth structure,⁴ and over time have proven to be one of the most successful treatment modalities that modern dentistry has to offer.¹⁹

The following interdisciplinary case (restorative treatment provided by a senior undergraduate dental student and a second-year graduate prosthodontic resident) demonstrates the use of conservatively prepared bonded porcelain laminate veneers, in conjunction with periodontal surgery, to correct a variety of esthetic and functional issues.

Case Report

Chief Complaint and Medical History

The patient, a 27-year-old Caucasian male, presented to the College of Dental Medicine at Georgia Regents University (GRU) in Augusta, Georgia, with a chief complaint of, "I want to close those spaces" (Figs 1 & 2). His medical history was noncontributory and was classified as ASA I.

Dental, and Head and Neck Examination

The patient visited his dentist twice a year for regular cleanings and check-ups, brushed his teeth twice a day, and flossed occasionally. He also reported drinking one or two carbonated drinks a day at mealtimes. He had minimal dental restorations and was classified as a low caries-risk patient with visible diastemata mainly in the maxillary anterior region (Fig 3). He had attrition localized to the anterior region resulting in excursive group function bilaterally. Radiographic examination revealed no apical pathology and the head and neck exam was within normal limits with no signs or symptoms of temporomandibular disease.

Examination, Findings, and Treatment Plan

The following seven categories as described by Dr. Gerard Chiche²⁰ were carefully evaluated during the esthetic analysis portion of the comprehensive examination: smile line, incisal profile, incisal length, central incisor proportions, tooth-to-tooth proportion, gingival outline, and desired fullness.

The result of the esthetic evaluation revealed the following:

- lack of tooth display at rest
- undersized anterior dentition
- diastemata
- disproportionate width-to-length ratio of maxillary central incisors
- localized attrition
- bilateral group function
- uneven gingival outline in the maxillary anterior region
- low labial frenal attachment.

After completion of the examination and evaluation of articulated study casts, the proposed treatment plan was presented to the patient: orthodontic intrusion of the maxillary anterior dentition to idealize the gingival outline, followed by preparation of teeth ##6-11 for porcelain veneers to address the esthetic and functional issues. The patient declined orthodontic treatment due to time and inconvenience, but ultimately accepted surgical crown lengthening to correct the gingival levels and porcelain laminate veneers as his definitive treatment choice.



Figure 1: Facial analysis.

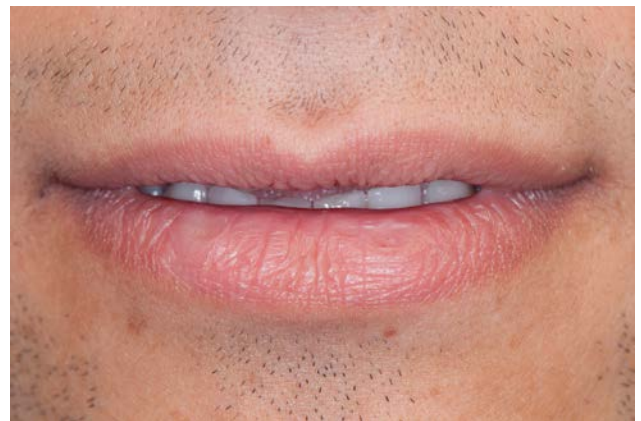

Figure 2: Repose (rest position).

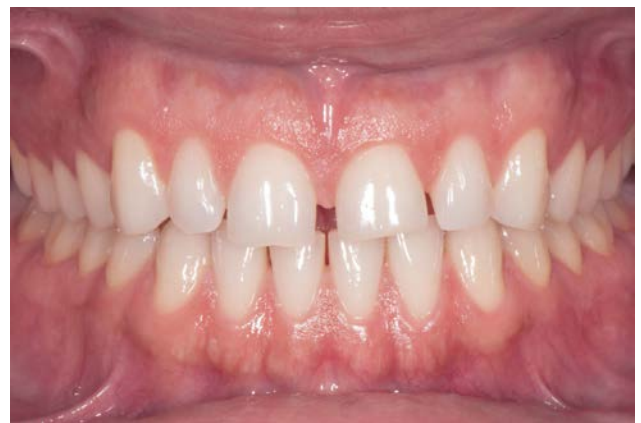

Figure 3: Maximum intercuspation.

A diagnostic wax-up was completed with the aid of Digital Smile Design²¹ (Figs 4 & 5) to address the esthetic problems previously described. Canine guidance was reestablished with the addition of wax to the lingual slopes and cusp tips of the canines.

A bis-acryl (Integrity, Dentsply; York, PA) esthetic mock-up (Figs 6-8) based upon the diagnostic wax-up was performed to assess the shape, incisal display, and gingival outline, and to give the patient an esthetic preview of the proposed treatment. Following patient approval, a surgical guide (.020" Clear Temporary Splint/Surgical Tray Material, Buffalo Dental; Syosset, NY) was fabricated for use during the crown-lengthening phase of treatment.

Periodontal Esthetic Crown Lengthening

Following periodontal probing and bone-sounding, the patient's biologic width (epithelial and connective tissue attachment)^{22,23} was determined to be 2 mm; therefore, the definitive osseous correction was planned to position the facial bone 3 mm apical to the idealized gingival levels.²⁴ The surgical guide was placed and a scalloped gingivectomy was performed (based on having an adequate zone of keratinized tissue) at the level of the desired free gingival margin.²⁵ A full-thickness mucoperiosteal flap was reflected subsequently (Fig 9) and bone was removed to establish the patient's unique biologic width (Fig 10). The interproximal bone was left intact despite the fact that the existing papilla length was more than 50% of the clinical crown length. The rationale for preserving the interproximal bone was based upon the mock-up, in which the proposed increase in incisal length would make the papilla-to-crown ratio more ideal.²⁶ The existence of pretreatment diastemata provided additional rationale for preserving interproximal bone, as their presence coupled with the addition of bone removal could result in unwanted cervical black triangles. Secondly but just as importantly, apical repositioning of the free gingival margin at the cemento enamel junction ensures that the cervical extent of the preparation will remain in enamel; this is important for the long-term success of bonded porcelain restorations.¹⁸

After completion of the surgical phase of care, the patient was allowed to heal for three months, at which time a probable sulcus had been reestablished. Currently, there is a lack of consistency regarding the recommended healing time before prosthodontic procedures can be initiated or continued following crown-lengthening surgery. Some clinicians advocate waiting until a probable sulcus is present, which indicates adequate redevelopment of the dentogingival complex.²⁷ This approach was taken in this case to

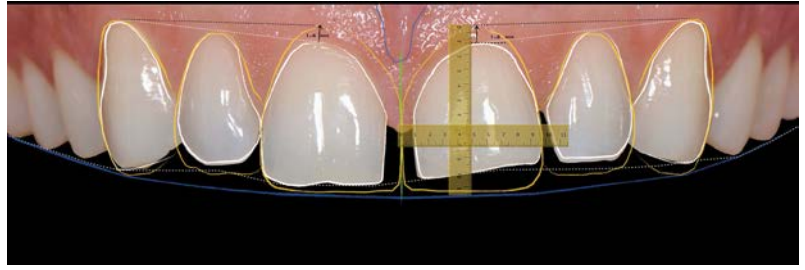


Figure 4: Digital esthetic mounting and smile design.

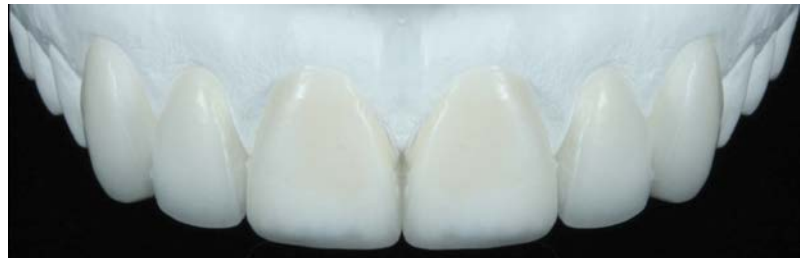

Figure 5: Diagnostic wax-up.

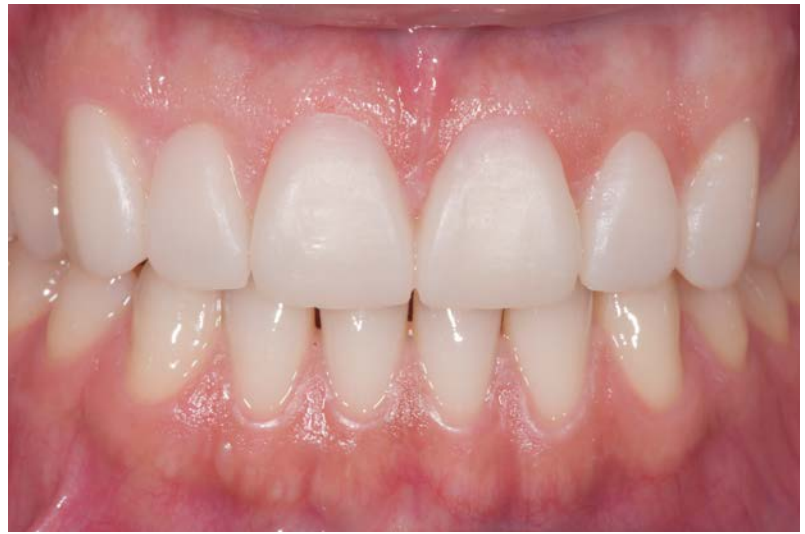

Figure 6: Initial intraoral mock-up.

“ Too often, shortcuts taken for the sake of expedience may ultimately affect the long-term success of the care provided. ”

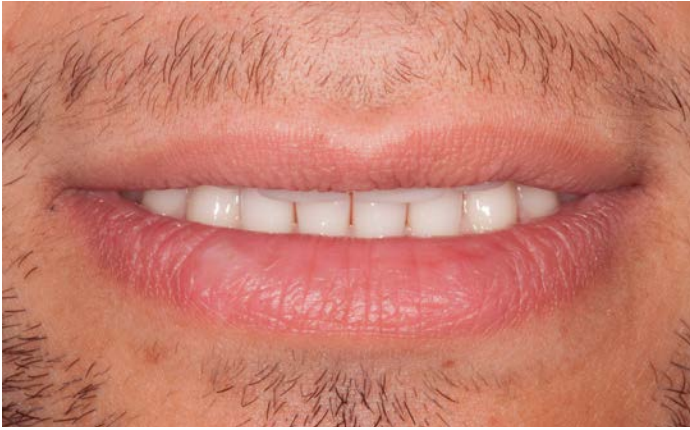

Figure 7: Patient in repose with bis-acryl mock-up.

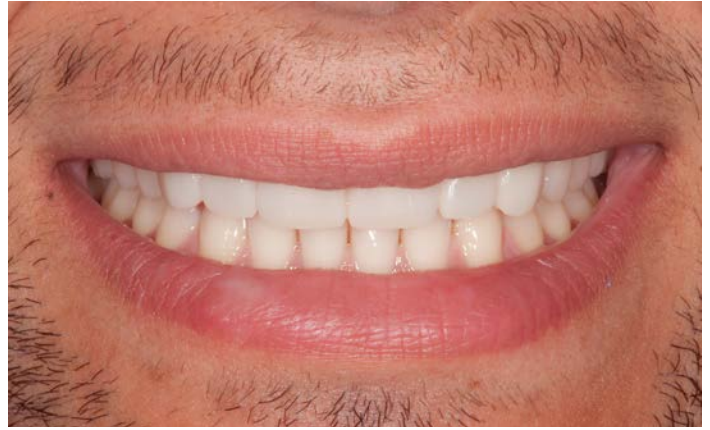

Figure 8: Patient smiling with bis-acryl mock-up.

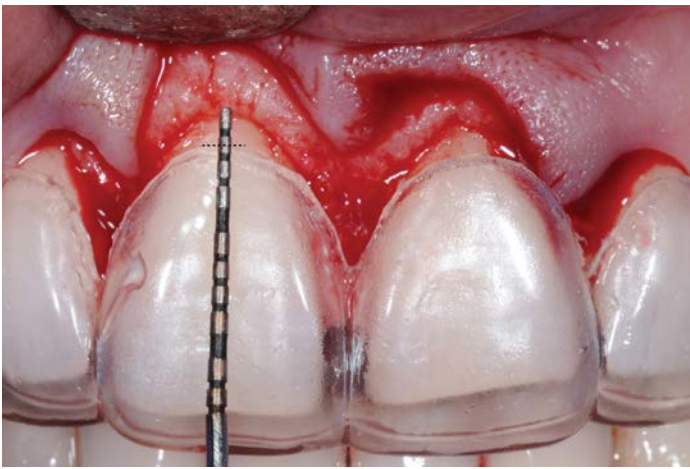


Figure 9: Flap elevation prior to bone reduction, showing need for labial osseous reduction.

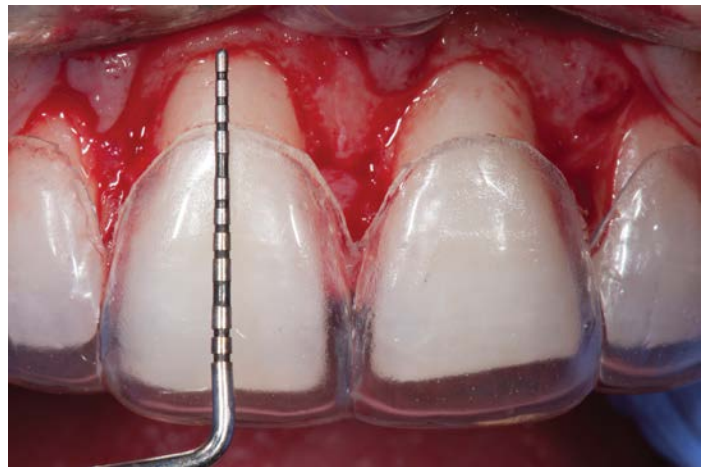


Figure 10: Osseous crest placed 3 mm from the apical margin of the proposed porcelain veneer margin.

minimize any risk of the preparation margin impinging on the newly established biologic width. **Figure 11** shows the repositioned free gingival margins, which will allow for better gingival symmetry and tooth proportions.

Tooth Preparation

A second bis-acryl mock-up was used as a guide for the minimal preparation technique as described by Gürel,²⁸ and Magne and Belser (**Fig 12**).¹⁷ Preparation of the mock-up and tooth structure was initiated using high-speed round donut-shaped diamond-coated burs (828-026, Brasseler USA; Savannah, GA) to create 0.5-mm horizontal depth cuts. The incisal edges were reduced by 1.0 mm using the same bur (**Fig 13**). Contact points were prepared using a tapered bur (699L-009, Brasseler) to create a new proximal emergence profile in order to prevent black triangles. The depth cuts were connected using a flat-end tapered coarse bur (LV53-6844-016, Brasseler) (**Fig 14**), followed by an ultra-fine grit diamond (LV54-014, Brasseler) to blend and smooth the preparations. A mosquito diamond (8392-016, Brasse-

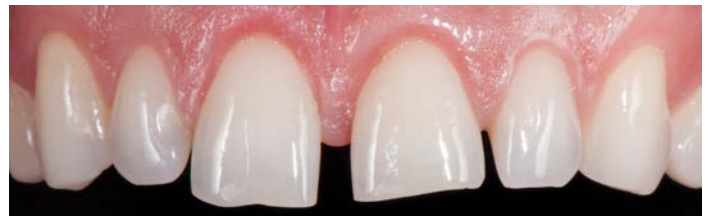

Figure 11: Three months post esthetic crown-lengthening surgery.

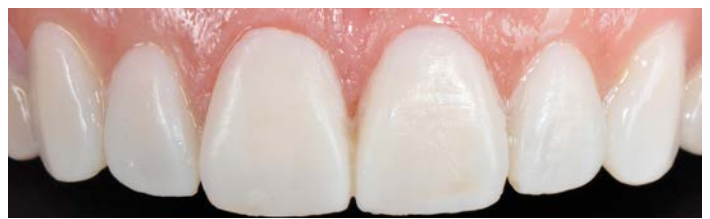

Figure 12: Second diagnostic mock-up.

ler) was used to round off sharp corners and line angles (Fig 15). Two plain knitted retraction cords, 000 and 00 (Ultrapak; Ultradent, South Jordan, UT) were placed using the double cord technique, and a definitive impression was made using heavy- and light-body vinyl polysiloxane impression material (Extrude, Kerr; Orange, CA).

Wax Design and Processing of Pressed Ceramics

A full-contour wax-up for the definitive veneers was performed on the master cast (Fig 16). The maxillary anterior veneers were then pressed with the Value 3 lithium disilicate glass ceramic ingot (IPS e.max Press, Ivoclar Vivadent; Amherst, NY). After adapting the margins and adjusting the fit of the restorations, the veneers were seated on the master solid cast. Using a silicone matrix (Matrix Form 70 A+ B, Anaxdent; Ardmore, OK) fabricated from the definitive wax-up shown in Figure 16, a cutback was performed to control thickness of the veneering ceramic (Fig 17). The e.max veneers were air-particle abraded with 100- μ glass beads (Rolloblast, Renfert USA; Chicago, IL) to improve the bond between the core and veneering ceramic. Multiple fluorapatite ceramic powders (e.max Ceram; Ivoclar Vivadent) were used to create a natural appearance. At this stage, tooth morphology was outlined in the facial, cervical, and interproximal areas to provide an overall preview of the final proportions and forms of the teeth. Using the marked outlines as a guide, final contour adjustments were made (Fig 18). To achieve lifelike characteristics of the ceramic, subtle external stains were applied to the surface prior to glazing. A fixation firing was subsequently carried out to freeze the stains in place, followed by glaze paste application (e.max Ceram) and hand polishing with silicone wheels (diamond-impregnated rubber wheel, Edenta; Hauptstrasse, Switzerland) and #3 fine pumice (Kerr) (Fig 19).

Bonding

Prior to bonding the veneers, the provisional restorations were removed, and the teeth were air-particle abraded using 50- μ aluminum oxide (50 micron White, Danville; San Ramon, CA) to remove residual temporary cement and increase micromechanical retention. The finished veneers were adjusted for ideal fit of proximal contacts and repolished. Try-in pastes (Da Vinci Formula 1 Try-in Gel, Bright, Cosmedent; Chicago, IL) were used to simulate the post-cementation result, and the patient was allowed to visualize and approve the esthetics prior to bonding. The veneers were rinsed to remove the try-in paste and steam-cleaned, followed by application of 5% hydrofluoric acid etch (IPS Etching Gel; Ivoclar Vivadent) for 20 seconds and rinsed. In addition, the veneers were placed in an ultrasonic bath with distilled water for five minutes to remove any residual porcelain precipitates as a result of etching.

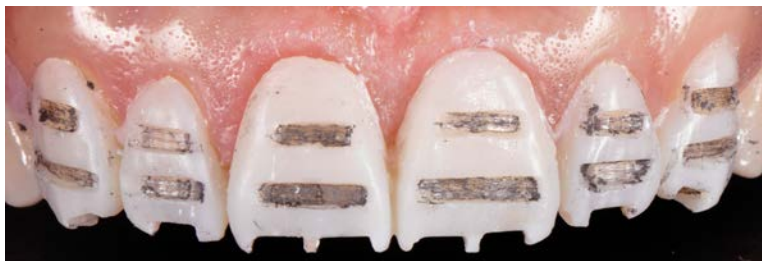

Figure 13: Depth guide cuts made through the mock-up.

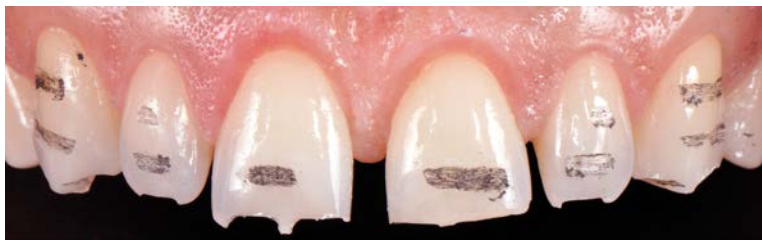

Figure 14: Pencil markings indicating the minimal amount of preparation needed.

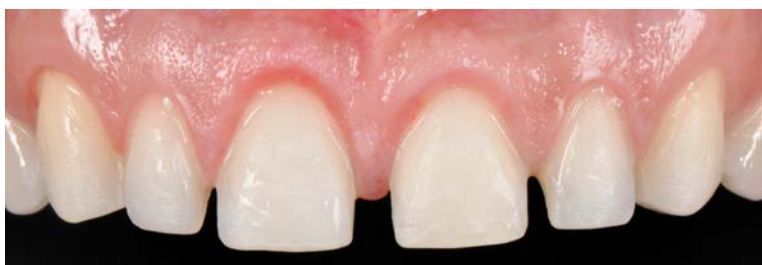

Figure 15: Final conservative preparations.

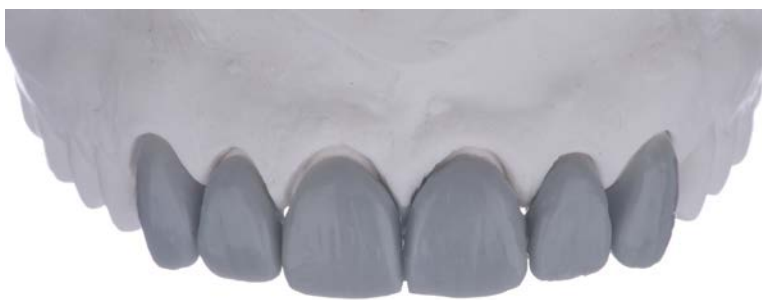

Figure 16: Definitive wax design of the final restorations on the master solid cast.

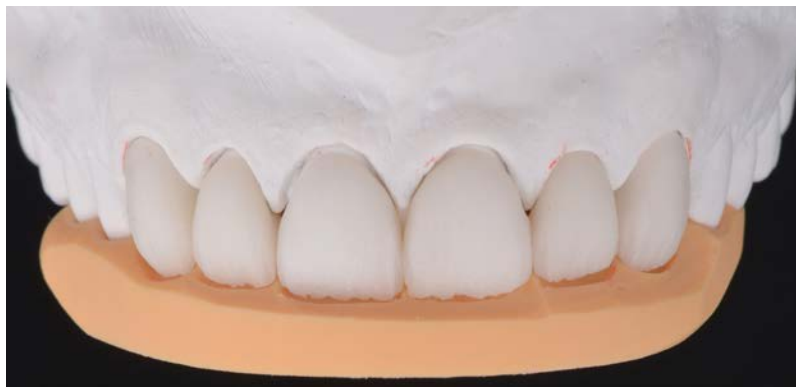

Figure 17: Labial cutback using silicone matrix as a guide.

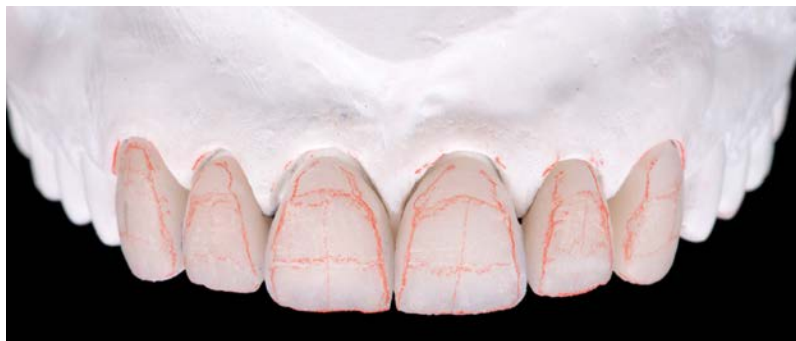

Figure 18: Morphological contouring.

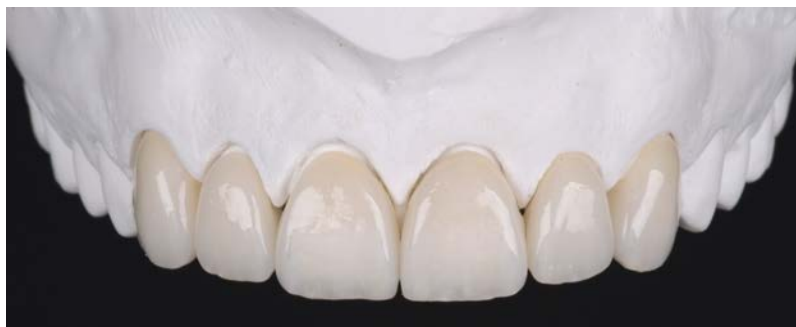

Figure 19: Final anterior restorations on solid cast.

“The rationale for preserving the interproximal bone was based upon the mock-up, in which the proposed increase in incisal length would make the papilla-to-crown ratio more ideal.”

Ceramic primer (Monobond Plus; Ivoclar Vivadent) was then applied for 60 seconds, thoroughly air-dried, and treated with heat, as it has been shown that application of heat to the silane-treated porcelain surface has the potential to significantly improve bond strength to composite.^{29,30} A non-latex rubber dam (Paro, Clinician's Choice; New Milford, CT) was placed using the slit technique (Fig 20) and 000 cords (Ultrapak) were placed around each preparation to control sulcular fluids and facilitate cement removal.

The teeth were etched using 32% phosphoric acid (Uni-Etch, Bisco; Schaumburg, IL) for 15 seconds and rinsed, followed by adhesive application (Single Bond, 3M ESPE; St. Paul, MN) (Fig 21). The adhesive was air-thinned and photopolymerized using an LED curing light (Valo, Ultradent) for 15 seconds. The adhesive was also applied to the intaglio surfaces of the veneers (and air-thinned to remove residual solvent) but not cured, followed by placement of the light-cure resin cement (Da Vinci Formula 1, Bright).³¹

The veneers were gently placed on the teeth and excess cement carefully removed, then spot-photopolymerized using a 2-mm small light guide (Demi Plus, Kerr) for five seconds on the cervical of the veneers to tack the veneers in place (Fig 22). Final removal of any residual cement was performed, followed by application of glycerin gel (Oxygone, Cosmedent) at the margins to prevent formation of an oxygen-inhibited layer (Fig 23).³²

Definitive photopolymerization was performed for 40 seconds facially and palatally (Fig 24), followed by removal of the retraction cords and careful removal of any remaining resin cement with a #12B disposable scalpel (Henry Schein; Melville, NY). Occlusal adjustment was performed in centric relation in the supine position and refined in the upright position to ensure passive anterior contacts and allow for postural freedom. Lateral guidance was verified to confirm canine protection of the posterior teeth in excursive movements and maxillary incisal edges in crossover.

An occlusal guard was fabricated and delivered to the patient at a subsequent appointment to provide nighttime protection for the new restorations. Figures 25 and 26 show the final result two months post-delivery, which met the esthetic and functional results desired.

Summary

Multiple measures were taken to improve the odds for long-term success of this esthetic rehabilitation: minimally invasive preparations for enamel conservation, selection of high-strength ceramic (lithium disilicate) to provide better fracture resistance, reestablishment of canine guidance and smooth crossover to protect the veneers, and fabrication/delivery of an occlusal guard to minimize the risk of restoration fracture at night due to likelihood of ongoing parafunctional activity. The results of this case illustrate the quality of esthetic care provided by the undergraduate senior dental student and graduate prosthodontic resident under the guidance of an interdisciplinary esthetic faculty team. The final outcome was a result of careful diagnosis, treatment planning, and delivery of care in a dedicated environment, and is representative of the level of care that students and residents working together are able to provide through the Goldstein Center for Esthetic and Implant Dentistry at GRU.

Acknowledgment

This work was supported by the Nobel Biocare/GRU Center of Excellence.

References

1. Beall AE. Can a new smile make you look more intelligent and successful? *Dent Clin North Am.* 2007 Apr;51(2):289-97, vii.
2. Peumans M, Van Meerbeek B, Lambrechts P, Vanherle G. Porcelain veneers: a review of the literature. *J Dent.* 2000 Mar;28(3):163-77.
3. Fradeani M. Six-year follow-up with Empress veneers. *Int J Periodontics Restorative Dent.* 1998 Jun;18(3):216-25.
4. Dumfahrt H, Schäffer H. Porcelain laminate veneers. A retrospective evaluation after 1 to 10 years of service: part II—clinical results. *Int J Prosthodont.* 2000 Jan-Feb;13(1):9-18.
5. Friedman MJ. A 15-year review of porcelain veneer failure—a clinician's observations. *Compend Contin Educ Dent.* 1998 Jun;19(6):625-8, 30, 32 passim; quiz 38.
6. Fradeani M, Redemagni M, Corrado M. Porcelain laminate veneers: 6- to 12-year clinical evaluation—a retrospective study. *Int J Periodontics Restorative Dent.* 2005 Feb;25(1):9-17.
7. Smales RJ, Etemadi S. Long-term survival of porcelain laminate veneers using two preparation designs: a retrospective study. *Int J Prosthodont.* 2004 May-Jun;17(3):323-6.

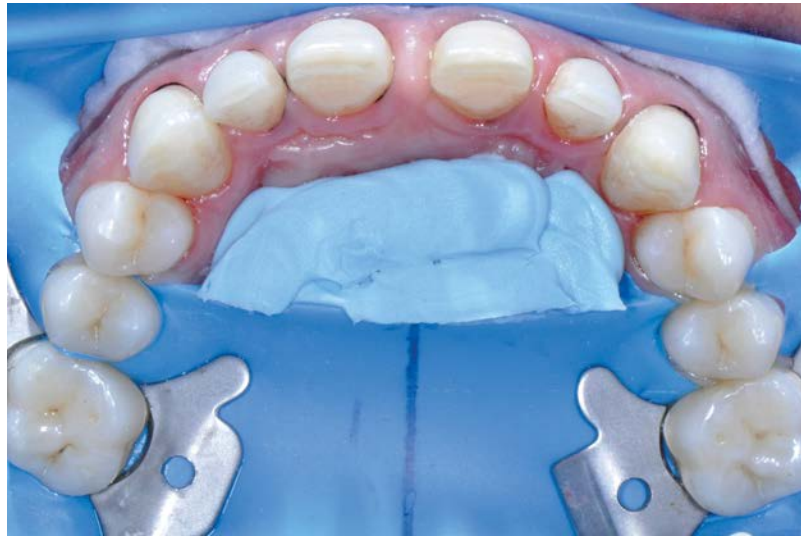


Figure 20: Rubber dam in place using slit technique.

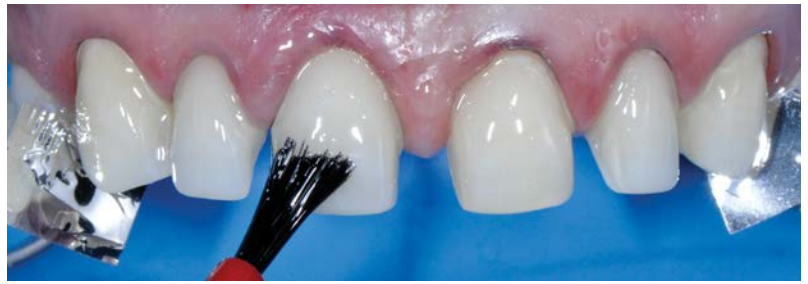

Figure 21: Adhesive application.

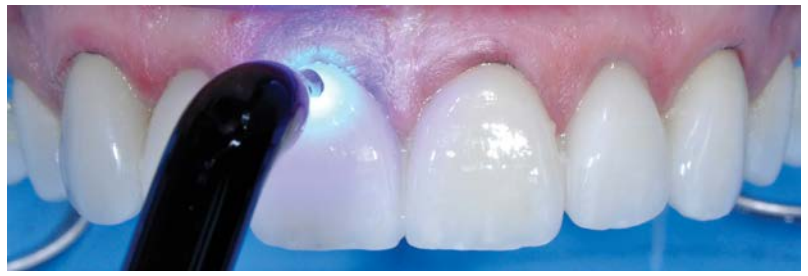

Figure 22: Tack photopolymerization of the veneers.

“Multiple measures were taken to improve the odds for long-term success of this esthetic rehabilitation.”

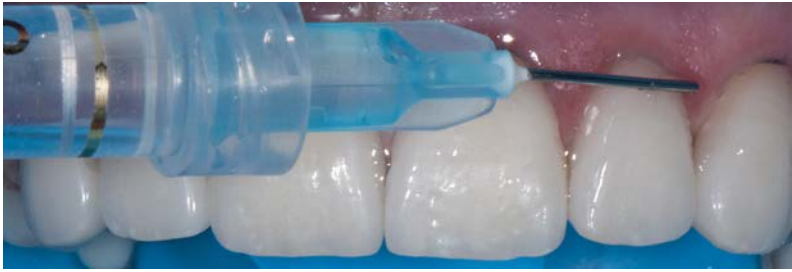

Figure 23: Application of glycerin gel.

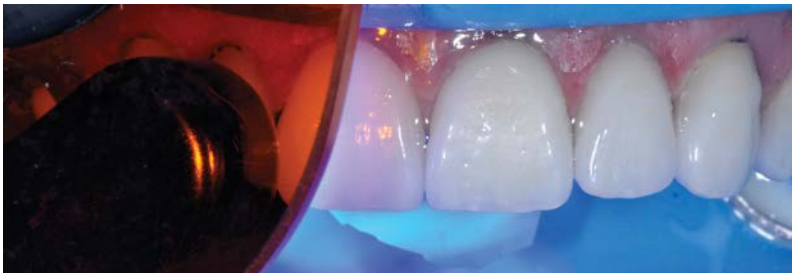


Figure 24: Definitive photopolymerization of the resin cement.

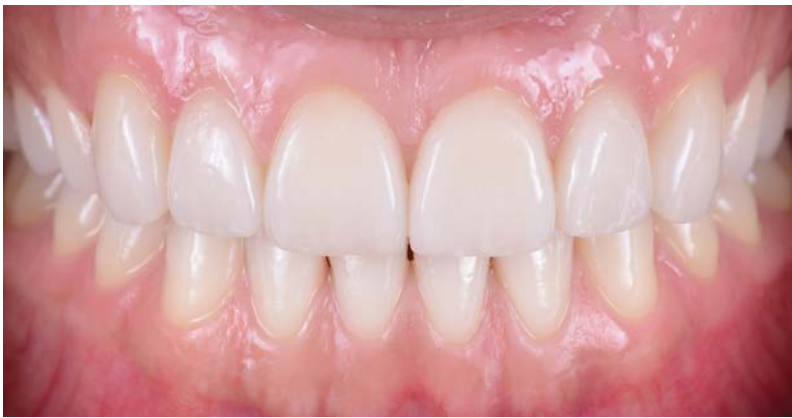

Figure 25: Final restorations, two months postoperative.

8. Spear F. Using margin placement to achieve the best anterior restorative esthetics. *J Am Dent Assoc.* 2009 Jul;140(7):920-6.
9. Edelhoff D, Sorensen JA. Tooth structure removal associated with various preparation designs for anterior teeth. *J Prosthet Dent.* 2002 May;87(5):503-9.
10. Webber B, McDonald A, Knowles J. An in vitro study of the compressive load at fracture of Procera AllCeram crowns with varying thickness of veneer porcelain. *J Prosthet Dent.* 2003 Feb;89(2):154-60.
11. Rinke S, Lange K, Ziebolz D. Retrospective study of extensive heat-pressed ceramic veneers after 36 months. *J Esthet Restor Dent.* 2013 Feb;25(1):42-52.
12. Christensen GJ, Christensen RP. Clinical observations of porcelain veneers: a three-year report. *J Esthet Dent.* 1991 Sep-Oct;3(5):174-9.
13. Walls AW. The use of adhesively retained all-porcelain veneers during the management of fractured and worn anterior teeth: part 2. Clinical results after 5 years of follow-up. *Br Dent J.* 1995 May;178(9):337-40.
14. Magne P, Douglas WH. Cumulative effects of successive restorative procedures on anterior crown flexure: intact versus veneered incisors. *Quintessence Int.* 2000 Jan;31(1):5-18.
15. Magne P, Douglas WH. Design optimization and evolution of bonded ceramics for the anterior dentition: a finite-element analysis. *Quintessence Int.* 1999 Oct;30(10):661-72.
16. Stappert CF, Ozden U, Gerds T, Strub JR. Longevity and failure load of ceramic veneers with different preparation designs after exposure to masticatory simulation. *J Prosthet Dent.* 2005 Aug;94(2):132-9.
17. Magne P, Belser U. Bonded porcelain restorations in the anterior dentition: a biomimetic approach. Hanover Park (IL): Quintessence Pub.; 2002.
18. Friedman MJ. Porcelain veneer restorations: a clinician's opinion about a disturbing trend. *J Esthet Restor Dent.* 2001;13(5):318-27.
19. Calamia JR, Calamia CS. Porcelain laminate veneers: reasons for 25 years of success. *Dent Clin North Am.* 2007 Apr;51(2):399-417, ix.
20. Chiche GJ. Proportion, display, and length for successful esthetic planning. In: Cohen M, editor. *Interdisciplinary treatment planning principles, design, implementation.* Hanover Park (IL): Quintessence Pub.; 2008. p. 1-47.


21. Coachman C, Calamita M. Digital Smile Design: a tool for teaching treatment planning and communication in esthetic dentistry. QDT 2012. Hanover Park (IL): Quintessence Pub.; 2012.
22. Gargiulo AW, Wentz F, Orban B. Dimensions and relations of the dentogingival junction in humans. J Periodontol. 1961 Jul;32(3):261-7.
23. Vacek JS, Gher ME, Assad DA, Richardson AC, Giambarresi LI. The dimensions of the human dentogingival junction. Int J Periodontics Restorative Dent. 1994 Apr;14(2):154-65.
24. Kois JC. The restorative-periodontal interface: biological parameters. Periodontol 2000. 1996 Jun;11:29-38.
25. Schluger S, Yuodelis R, Page RC, Johnson RH. Periodontal disease: basic phenomena, clinical management, and occlusal and restorative interrelationships. 2nd ed. Philadelphia: Lea & Febiger; 1990. p. 612-41.
26. Tarnow DP, Magner AW, Fletcher P. The effect of the distance from the contact point to the crest of bone on the presence or absence of the interproximal dental papilla. J Periodontol. 1992 Dec;63(12):995-6.
27. Schluger S, Yuodelis R, Page RC, Johnson RH. Periodontal disease: basic phenomena, clinical management, and occlusal and restorative interrelationships. 2nd ed. Philadelphia: Lea & Febiger; 1990. p. 666-706.
28. Gürel G. Porcelain laminate veneers: minimal tooth preparation by design. Dent Clin North Am. 2007 Apr;51(2):419-31, ix.
29. Shen C, Oh WS, Williams JR. Effect of post-silanization drying on the bond strength of composite to ceramic. J Prosthet Dent. 2004 May;91(5):453-8.
30. Papacchini F, Monticelli F, Hasa I, Radovic I, Fabianelli A, Polimeni A, Ferrari M. Effect of air-drying temperature on the effectiveness of silane primers and coupling blends in the repair of a microhybrid resin composite. J Adhes Dent. 2007 Aug;9(4):391-7.
31. Stamatacos C, Simon JF. Cementation of indirect restorations: an overview of resin cements. Compend Contin Educ Dent. 2013 Jan;34(1):42-4, 46.
32. Bergmann P, Noack MJ, Roulet JF. Marginal adaptation with glass-ceramic inlays adhesively luted with glycerine gel. Quintessence Int. 1991 Sep;22(9):739-44. **jcd**



Figure 26: Final full smile.



Dr. Hammond is an associate professor and director of Dental Continuing Education, Department of General Dentistry, Georgia Regents University (GRU) College of Dental Medicine in Augusta, Georgia.



Dr. Kim is a diplomate, American Board of Prosthodontics; and an assistant professor, Department of Oral Rehabilitation, GRU College of Dental Medicine.



Dr. Londono is an assistant professor, Department of Oral Rehabilitation, GRU College of Dental Medicine.



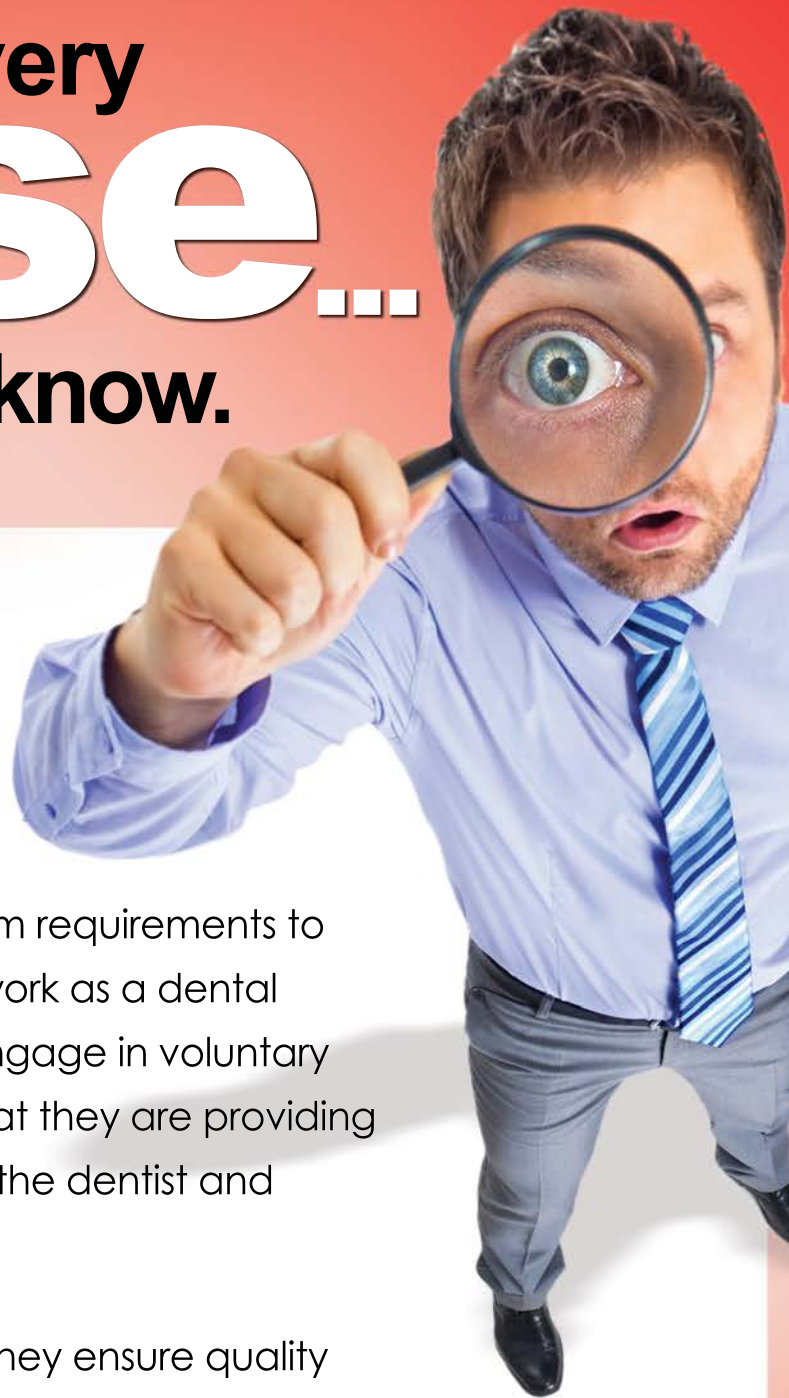Dr. Tadros is a first-year graduate prosthodontic resident, GRU College of Dental Medicine.



Mr. Torosian is a master dental ceramist at the Goldstein Center for Esthetic and Implant Dentistry, GRU College of Dental Medicine.

Disclosure: The authors did not report any disclosures.

Look very Close... Shocking? We know.



The simple truth...

**Your liability stays
with you indefinitely.**

3 out of 4 states have no minimum requirements to operate a dental laboratory or work as a dental technician. Some laboratories engage in voluntary standards programs to ensure that they are providing the highest quality restoration to the dentist and ultimately to the patient.

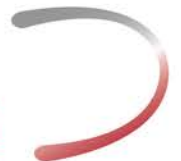Ask your dental laboratory how they ensure quality standards for your restorations and if they employ Certified Dental Technicians (CDTs). Visit www.whatsinyourmouth.us



**CERTIFIED
DENTAL
LABORATORY**



NADL
National Association of
Dental Laboratories



Visit us at www.whatsinyourmouth.us

Disciplined Training That is Both **Traditional & Modern**

Esthetic Dentistry at Tufts University

Gerard Kugel DMD, MS, PhD
Aikaterini Papathanasiou, DDS, CAGS



I (GK) gave my first esthetic dentistry lecture at Tufts University School of Dental Medicine (TUSDM) in 1988. It was met with resistance from many of the faculty, who felt it was not “necessary” dentistry. It was at the same time that we started our postgraduate esthetic dentistry program. We were the second dental school in the country (after UCLA) to have such a program. We are proud of our esthetic dentistry program graduates, many of whom have become leaders in the field. They include Dr. Joel Gale in Miami; Dr. Armida Dano in Boston; and Drs. Shradha Sharma, Ayman Aboushalla, and Susanna Ferreira, in Massachusetts.

TUSDM offers a two-year Advanced Education in Esthetic and Operative Dentistry (AEEOD) Certificate program. In the AEEOD clinical curriculum, students are trained to provide comprehensive dental care, utilizing the most appropriate technologies available to dental professionals. Students’ achievements include simple to more extensive smile treatments such as teeth whitening, direct composite restorations, porcelain laminate veneers, all-ceramic and porcelain-fused-to-metal crowns, CAD/CAM restorations, and implant-supported crowns. The program exposes students to all specialty phases of dentistry and medicine as they apply to esthetics.

During their didactic curriculum, students attend prosthodontics-oriented classes such as “Prosthodontics Treatment Planning Seminar,” “Comprehensive Evidence-Based Prosthodontics Literature Review,” “Biomaterials I and II,” “Temporomandibular Joint Disorders,” and “Occlusion.” Students also attend esthetics and multidisciplinary lectures such as “Comprehensive Evidence-Based Esthetic Literature Review” and “Science and Art of Esthetic Dentistry.”

Predoctoral students are taught the fundamentals of esthetic dentistry in operative dentistry, prosthodontics, and implant dentistry courses. They receive extensive training in modern adhesive dentistry, as well as in composite placement, anterior composite layering techniques, posterior composites, all-ceramic restorations, and implant esthetics. Since 1988, we also have been teaching porcelain laminate veneers and, more recently, all-ceramic crowns, including CAD/CAM restorations.

All preclinical students are given the opportunity to design a CAD/CAM crown restoration and many of them continue and do a CAD/CAM crown restoration in our undergraduate dental clinic.

Faculty members work closely with students in mastering diastema closures, composite veneers, posterior composites, and even more challenging prosthodontics esthetic cases.

Anyone who has attended an IADR or an AADR meeting will know how much research our students do in the field of cosmetic dentistry—from testing new composites, to bioactive filling materials, to all-ceramic options and tooth whitening.

In addition to its other endeavors, TUSDM recently established an Esthetic Dentistry Club for both students and faculty.

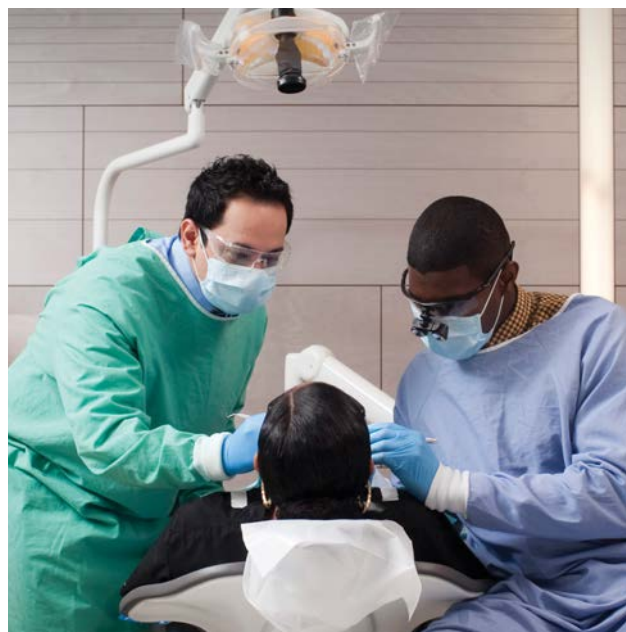
As the demand for esthetic restorative procedures has increased dramatically, TUSDM plans to dedicate additional hours to esthetic dentistry in its predoctoral curriculum to better prepare graduates for the ever-increasing demands of private practice.

During the past two years, Jonathan Bishop, currently a third-year student at TUSDM, has displayed immense interest in dental research. His research presentations gained him entrance to the 2014 AADR and Greater New York Dental Conferences. He won a Predoctoral Table Clinic award at the 2014 Tufts Bates-Andrews Research Day due to the study's clinical relevance to esthetic restorative techniques and is now treasurer of the Tuft's Bates Student Research Group. The article he co-authored, "Effect of Phosphoric Acid on Vitrebond Plus Resin-Modified Glass Ionomer," begins on page 64.

Acknowledgments

Dr. Papathanasiou extends her appreciation to Dr. Kugel, who was her mentor both in research and in research writing. His expertise in clinical research and esthetic dentistry, including more than 120 articles and 200 abstracts, has added immeasurable knowledge to the field.

Dr. Kugel recognizes Dr. Papathanasiou, a graduate of the TUSDM Advanced Education in Esthetic Dentistry program, for her outstanding service to the cosmetic dentistry community, including her roles in leading cosmetic dentistry programs both in the U.S. and in Greece.



“In the AEEOD clinical curriculum, students are trained to provide comprehensive dental care, utilizing the most appropriate technologies available to dental professionals.”



Dr. Kugel is an associate dean, dental research; and professor, Department of Prosthodontics and Operative Dentistry, Tufts University School of Dental Medicine (TUSDM).



Dr. Papathanasiou is an assistant professor, Department of Prosthodontics and Operative Dentistry, TUSDM; and a visiting lecturer for the Linhart Continuing Dental Education Program at New York University College of Dentistry.

Disclosure: The authors did not report any disclosures.

Photo credits: The jCD thanks Tufts University for the use of their photos in this editorial.

Modern restorative dentistry and its effectiveness are largely attributed to the success of current bonding techniques.

Effect of Phosphoric Acid...

on Vitrebond Plus Resin-Modified Glass Ionomer

Jonathan S. Bishop, BS
William W. Chao, BA
Melissa E. Ing, DMD
Steven E. Eisen, DMD,
Aikaterini Papathanasiou, DDS, CAGS
Gerard Kugel, DMD, MS, PhD

Abstract

Objective: This study sought to determine whether phosphoric acid etching of Vitrebond Plus RMGI liner/base material (3M ESPE; St. Paul, MN) affects the shear bond strength between itself and Filtek Supreme Ultra nanocomposite (3M ESPE). **Methods:** 3 mm x 6 mm cylindrical molds were filled with Vitrebond Plus RMGI liner and light-cured for 20 seconds. Samples were then either treated with 35% phosphoric acid (Group 1; N = 27); or not treated with phosphoric acid (Group 2; N = 26). All samples were then treated with Excite F total-etch bonding agent (Ivoclar Vivadent; Amherst, NY) and light-cured for 10 seconds. Once the bonding agent was cured, Filtek Supreme Ultra nanocomposite was placed over the Vitrebond Plus RMGI liner using 8 mm x 3 mm cylindrical molds and light-cured for 40 seconds using a light-emitting diode curing light (DEMI Plus, Kerr; Orange, CA). All samples were treated in accordance to manufacturers' instructions. After sitting at room temperature for 24 hours the shear bond strength of each sample was determined using a universal testing machine at a crosshead speed of 1.0 mm/min. **Results:** No statistically significant difference was observed between the acid-etched and non-etched groups ($p = 0.918$). **Significance:** Findings suggest that clinicians who currently implement selective-etching may no longer need to use this technique when using Vitrebond Plus RMGI liner and Filtek Supreme Ultra together because there is no detriment as a result of etching Vitrebond Plus RMGI liner. Clinically, this may decrease both application time and indicates that phosphoric acid neither positively nor negatively alters bond strength between the two materials.

Key Words: dental materials, bonding, composite, RMGI, phosphoric acid

Introduction

Modern restorative dentistry and its effectiveness are largely attributed to the success of current bonding techniques. Proper understanding of these techniques improves practitioners' ability to increase the success and longevity of their restorations. In the case of deep restorations, the use of a liner/base is often recommended with composite resin layered over the glass ionomer or resin-modified glass ionomer (RMGI) liner or base.^{1,2} Placement of the RMGI material offers a number of benefits to the patient. Fluoride release will help remineralize tooth structure, addition of RMGI material over dentin tubules helps to reduce postoperative sensitivity, micro-leakage of the overall restoration is decreased, and bonding itself does not require the use of a bonding agent.³⁻⁵ Because RMGI has a resin component, the air-inhibited layer allows us to chemically bond composite to the resin-based material via a chemical chelation interaction; hence, a bonding agent is not required.³ Following the placement of this liner or base, the practitioner can either implement a self-etch system, a total-etch (one or two bottle) etch-and-bond system (applying phosphoric acid to all internal walls of the preparation), or a selective-etch system (applying phosphoric acid only on enamel surface). While self-etch systems are becoming increasingly popular, many practitioners still implement total-etch and selective-etch systems for various reasons, including the increase in long-term bond strength.⁶

When using a total-etch composite resin system after the placement of certain liners or bases, the application of phosphoric acid to the liner/base can have varying effects on the strength of the bonded restoration, depending upon the

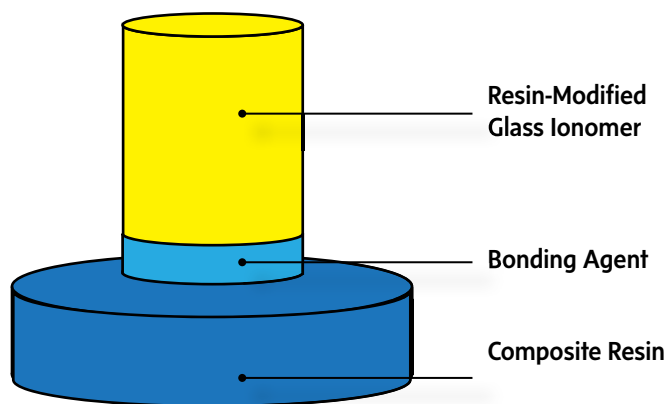


Figure 1: Button made by bonding RMGI and composite resin.

liner material (e.g., conventional glass ionomer versus resin-modified glass ionomer).⁷⁻⁹ When viewing the bond strength between an RMGI and composite resin, previous studies have shown varying results in bond strength after applying phosphoric acid to a number of popular RMGI bases. Some studies have shown a decrease in bond strength while others have shown an increase in strength between the two materials.^{7,10,11} Due to the belief that phosphoric acid may decrease bond strength between an RMGI and composite resin, many practitioners selectively etch the enamel to limit the effects of phosphoric acid on the RMGI.

This study sought to determine the effects of phosphoric acid on the shear bond strength between Vitrebond Plus RMGI liner and Filtek Supreme Ultra nanocomposite (both 3M ESPE; St. Paul, MN).

Materials and Methods

Cylindrical molds (3 mm x 6 mm) were filled with Vitrebond Plus RMGI. Samples were then treated in one of two ways:

- RMGI surfaces were treated with 35% phosphoric acid (Group 1; N = 27)
- RMGI surfaces were not treated with phosphoric acid (Group 2; N = 26).

Within each category, all samples were treated with Excite F total-etch bonding agent (Ivoclar Vivadent; Amherst, NY) and light-cured for 10 seconds. Separate cylindrical molds (8 mm x 3 mm) were then placed over the RMGI samples and 3 mm of A2 shade Filtek Supreme Ultra was added to each sample in 1.5-mm increments, each layer being light-cured for 40 seconds.

In order to test the samples, the composite resin was carefully embedded in an acrylic mold necessary for use with a test base clamp (Ultradent; South Jordan, UT). It should be noted that the dimensions of Vitrebond Plus and Filtek Supreme Ultra used in the button were dictated by the actual testing process. Filtek Supreme Ultra samples needed to be large enough that they would remain embedded in acrylic during shear bond strength tests (Fig 1).

Placement of the RMGI material offers a number of benefits to the patient.

Once completed, molds were kept at room temperature for 24 hours before the shear bond strength was tested. All experimental samples were created following manufacturers' instructions. The shear bond strength of each button was determined using a 5566A universal testing machine (Instron; Norwood, MA) at a crosshead speed of 1.0 mm/min (Fig 2).

During testing, the Instron testing machine's shear bond strength testing attachment was placed as close to the interface between the Vitrebond Plus and Filtek Supreme Ultra as possible. Proper placement limits any lever effect that might be added by incorrect placement of the testing attachment during bond strength testing.




Figure 2: Button placed in acrylic being tested for bond strength.

Results

Results are shown in **Table 1** and **Figure 3**. No statistically significant difference was observed between the acid-etched and non-etched groups ($p = 0.918$).

Due to the differences in products tested and technique used in this study compared to previously published studies, we conducted a brief six-sample pilot study (three samples per subgroup) to assist in calculating a sample size.^{10,11} It was determined that a sample size of 54 (27 in each group) will have 80% power to detect a difference in means of 0.390 (the difference between a Group 1 mean [m1] of 3.040 and a Group 2 mean [m2] of 2.650), assuming that the common standard deviation is 0.497 using a two-group t-test with a 0.050 two-sided significance level. During preparation in the full study, one sample's results might have been augmented by excessive acrylic near the junction of the Vitrebond Plus and Filtek Supreme Ultra. This outlier was withheld from statistical analysis, though the statistical outcome remained

Table 1. Group Statistics.

Group	N	Mean (MPa)	SD (MPa)
Etched	27	3.17	1.97
Non-etched	26	3.22	1.84

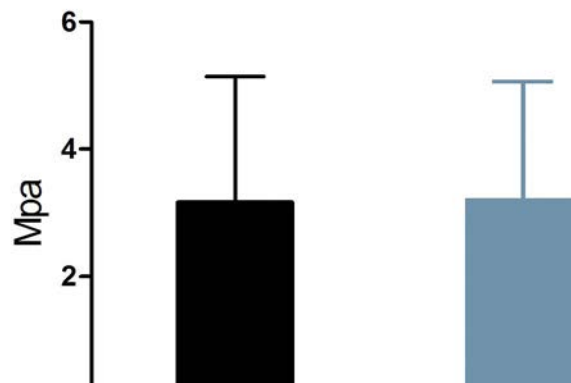


Figure 3: Phosphoric acid effect on etched versus non-etched samples. It should be noted that all samples separated along the interface between Vitrebond™ Plus and Filtek™ Supreme Ultra.

the same with or without this sample added to the analysis.

Data were analyzed via the independent-samples t-test. A p-value < 0.05 was considered statistically significant.

Discussion

During the process of selectively applying phosphoric acid to the enamel external walls of a preparation, it often is inevitable to have some of the acid come in contact with the edges of the internal walls of the preparation, where a base has been placed. While many universities and practitioners have varying recommendations for either selectively etching enamel or total-etching enamel when applying a composite resin over an RMGI liner, there seems to be a lack of evidence to support either recommendation over the other. Review of literature reveals minimal research showing the effects of phosphoric acid on the bonding of Vitrebond Plus RMGI liner to Filtek Supreme Ultra nanocomposite, two of the most popular materials on the market.

While some clinicians selectively etch RMGI, there is no statistically significant increase or decrease in bond strength between Vitrebond Plus and Filtek Supreme Ultra nanocomposite. Therefore, there is no need to etch the RMGI with 35% phosphoric acid. Due to this finding, a selective-etch system may not yield better results in terms of shear bond strength than a total etch system even though 3M states their products may be used with either technique in a clinical setting.¹² In practice, the use of a total-etch over a selective-etch technique would decrease the time and precision with which the clinician needs to properly apply phosphoric acid to the walls of a preparation while avoiding any contact between an RMGI base

and phosphoric acid. Concurrently, clinicians should not expect any improvements or detriments to bond strength after the use of phosphoric acid on the RMGI surface. We can now state that the application of 35% phosphoric acid for 30 seconds to Vitrebond Plus neither positively nor negatively affects the bond strength between Vitrebond Plus and Filtek Supreme Ultra.

Although the effects of phosphoric acid on bond strength between Vitrebond Plus and Filtek Supreme Ultra were not significant, this study did not involve bonding to tooth structure. Therefore, these results may or may not be clinically significant. It should also be mentioned that while some studies have shown that the use of phosphoric acid may alter microleakage between tooth structure and RMGI material, it is shown that the use of an RMGI base or liner limits microleakage due to its chemical bonding properties.¹³⁻¹⁵ Further research should be conducted to investigate these concerns.

Conclusion

While selective etching remains a viable option prior to placement of Filtek Supreme Ultra nanocomposite over Vitrebond Plus RMGI, this technique may be an excessive precaution that demands increased precision and time from the practitioner. Therefore, implementing a self-etch or total-etch process is simpler in practice. Nonetheless, all three etch-and-bond systems may be used when combining Vitrebond Plus and Filtek Supreme Ultra in a closed sandwich restoration.

References


1. Lee JJ, Lee YK, Choi BJ, Lee JH, Choi HJ, Son HK, Hwang JW, Kim SO. Physical properties of resin-modified glass ionomer cement modified with micro and nano-hydroxyapatite. *J Nanosci Nanotechnol*. 2010 Aug;10(8):5270-6.
2. Kasraei S, Azarsina M, Majidi S. In vitro comparison of microleakage of posterior resin composites with and without liner using two-step etch-and-rinse and self-etch dentin adhesive systems. *Operative Dent*. 2011 Mar-Apr;36(2):213-21.
3. Sidhu SK, Watson TF. Resin-modified glass ionomer materials. A status report for the American Journal of Dentistry. *Am J Dent*. 1995 Feb;8(1):59-67.
4. ADA Council on Scientific Affairs. Core materials: laboratory testing methods. *ADA Professional Product Rev*. 2008 Fall;3(4). Available from: http://www.ada.org/~media/ADA/Publications/PPR/0810_ppr.ashx.
5. Loguercio AD, Alessandra R, Mazzocco KC, Dias AL, Busato AL, Singer Jda M, Rosa P. Microleakage in class II composite resin restorations: total bonding and open sandwich technique. *J Adhes Dent*. 2002 Summer;4(2):137-44.
6. Miyazaki M, Sato M, Onose H. Durability of enamel bond strength of simplified bonding systems. *Oper Dent*. 2000 Mar-Apr;25(2):75-80.
7. Rao KS, Reddy TP, Yugandhar G, Kumar BS, Reddy SC, Babu DA. Comparison of shear bond strength of resin reinforced chemical cure glass ionomer, conventional chemical cure glass ionomer and chemical cure composite resin in direct bonding systems: an in vitro study. *J Contemp Dent Pract*. 2013 Jan 1;14(1):21-5.

8. Nujella BP, Choudary MT, Reddy SP, Kumar MK, Gopal T. Comparison of shear bond strength of aesthetic restorative materials. *Contemp Clin Dent*. 2012 Jan-Mar;3(1):22-6.
9. Almuammar ME, Schulman A, Salama FS. Shear bond strength of six restorative materials. *J Clin Pediatr Dent*. 2001 Spring;25(3):221-5.
10. Pamir T, Sen BH, Evcin O. Effects of etching and adhesive applications on the bond strength between composite resin and glass-ionomer cements. *J Appl Oral Sci*. 2012 Nov-Dec;20(6):636-42.
11. Otsuka E, Tsujimoto A, Takamizawa T, Furuchi T, Yokokawa M, Tsubota K, Miyazaki M. Influence of surface treatment of glass-ionomers on surface free energy and bond strength of resin composite. *Dent Mater J*. 2013;32(5):702-8.
12. Filtek Supreme Ultra Universal Restorative System technical product profile. St. Paul (MN): 3M ESPE; 2010.
13. Bona AD, Pinzetta C, Rosa V. Effect of acid etching of glass ionomer cement surface on the microleakage of sandwich restorations. *J Appl Oral Sci*. 2007 Jun;15(3):230-4.
14. Kasraei S, Azarsia M, Majidi S. In vitro comparison of microleakage of posterior resin composites with and without liner using two-step etch-and-rinse and self-etch dentin adhesive systems. *Oper Dent*. 2011 Mar-Apr;36(2):213-21.
15. Simi B, Suprabha B. Evaluation of microleakage in posterior nanocomposite restorations with adhesive liners. *J Conserv Dent*. 2001 Apr-Jun;14(2):178-81. **JCD**

While self-etch systems are becoming increasingly popular, many practitioners still implement total-etch and selective-etch systems for various reasons, including the increase in long-term bond strength.



Mr. Bishop is a 2009 graduate of Emory University in Atlanta, Georgia, with a dual degree in Neuroscience and Education. He then worked as a clinical research coordinator at the Joslin Diabetes Center in Boston, Massachusetts. He began his studies at the Tufts University School of Dental Medicine (TUSDM) in Boston in 2012 and received a Tufts University Bates Research award in 2014.



Mr. Chao is a third-year student at TUSDM. While completing his preclinical coursework, he discovered an interest in dental materials and their applications in clinical settings. He is a member of the International and American Associations for Dental Research and the Robert R. Andrews Research Honor Society.



Dr. Ing is an associate professor, Department of Prosthodontics and Operative Dentistry, TUSDM.



Dr. Eisen is an associate professor, Department of Prosthodontics and Operative Dentistry, TUSDM.



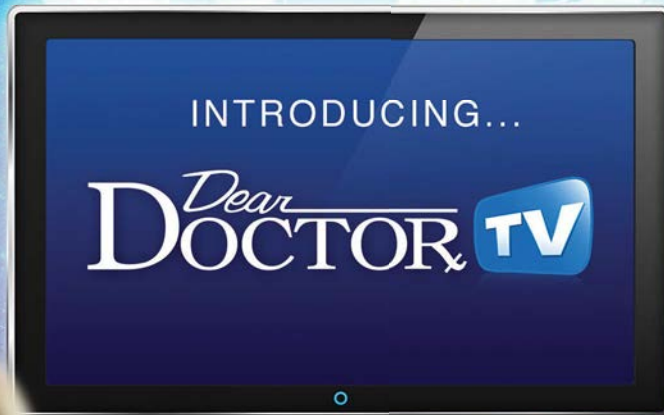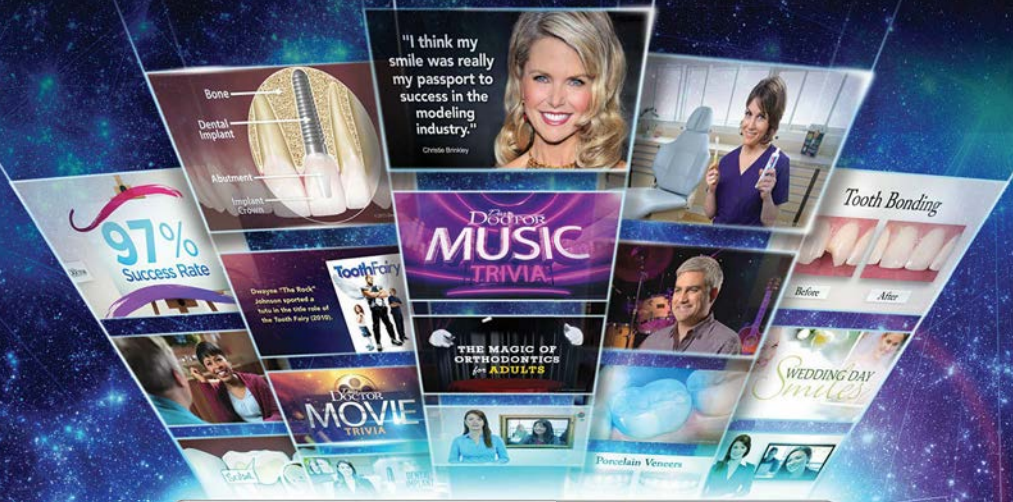Dr. Papatnasiou is an assistant professor, Department of Prosthodontics and Operative Dentistry, TUSDM.



Dr. Kugel is an associate dean, dental research; and professor, Department of Prosthodontics and Operative Dentistry, TUSDM.

Disclosure: The authors did not report any disclosures.

TRANSFORM YOUR RECEPTION AREA!



Learn more at www.DearDoctor.tv or call 866-799-5014

A Systematic Approach: Performing What They Learn

The Esthetic Dentistry Curriculum at UTHSC



James F. Simon, DDS, MEd
Mojdeh Dehghan, DDS
Daranee Tantbirojin, DDS, MS, PhD

Patients' increased awareness of esthetic outcomes and their desire to look better and to feel better about themselves have led to enormous demands on dentists to perform esthetic procedures. Dentists' ability to fulfill patients' expectations is directly related to their knowledge and clinical skills in this specialty.¹

Many practitioners claim to be "esthetic dentists," but are they really capable of delivering the type of dentistry that justifies that designation? There are organizations such as the AACD that can offer these dentists an opportunity to improve their esthetic/cosmetic skills; however, this education should start in their dental school curriculum. The teaching of esthetic dentistry in North American dental schools is highly variable and is often shared among different disciplines.¹

The University of Tennessee Health Science Center (UTHSC) College of Dentistry addressed this issue by establishing an esthetic dentistry curriculum in 2001 as part of the Department of Restorative Dentistry. Students are introduced to handling composite materials in the third month of their first year in the operative dentistry course. In the Fall semester of their second year, students are introduced to small composite preparations and restoration.

In the Spring semester of their second year the students have two courses. The first course has them performing more complex restorations, while the second course is devoted entirely to esthetic procedures. This esthetic dentistry course consists of 14 one-hour lectures and 14 three-hour preclinical laboratory sessions. The course covers a variety of subjects with the idea of better preparing the students to eventually treat patients in the clinic. The topics covered are direct and indirect posterior esthetic restorations, shade selection, diagnostic wax-ups, all-ceramic crowns (both anterior and posterior), direct and indirect veneers, diastema closure, vital tooth bleaching, bonding of indirect restorations, introduction to lasers, and nightguard construction. The students hear a lecture on each of these topics and then go to the laboratory and perform the procedure.

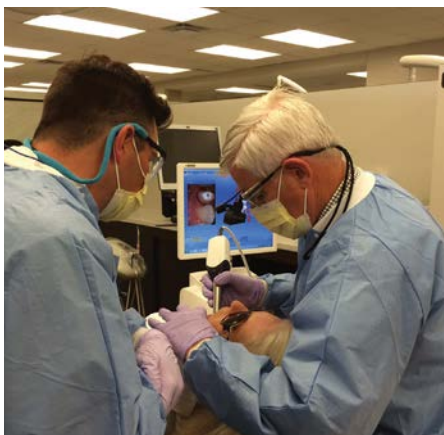

Figure 1: Esthetics division faculty member helping a fourth-year student to image a restoration with CEREC Omnicam.

In 2001 the dental school also committed to CAD/CAM dentistry, with the CEREC system (Sirona Dental Systems; Long Island City, NY) as part of its curriculum both in the clinic and in the preclinic.^{2,3} The students prepare, design, and then mill two posterior crowns and one onlay as part of the fixed prosthodontics course and the esthetic course. They stain and glaze one of these crowns and then bond them onto the typodont teeth.

During the students' third and fourth years, they can sign up to treat their patients in the esthetic dentistry clinic, which is open three half-days a week. Here, they are able to complete their veneer, anterior crown, and CEREC cases under close supervision (Fig 1). During the 2012-2013 school year, students fabricated 172 CEREC units from porcelain, lithium disilicate, composite, and zirconia materials.

In 2013, to provide students with feedback on the optimal delivery of energy to a composite restoration using a curing light, the school purchased a MARC patient simulator (BlueLight Analytics; Halifax, NS, Canada) (Fig 2).⁴ This technology has allowed second-year students to see the effectiveness of their light-curing skills before they work on patients in the clinic.

The school has had a student AACD study club since 2008. With the help of local AACD members, speakers are brought in to talk with students and a photography workshop is held. This has been a great help in reinforcing what students are taught in the school curriculum, and is an example of a successful collaboration between members of the Tennessee chapter of AACD and university faculty in the esthetics division at UTHSC College of Dentistry.

The College awards a Student Summer Research Fellowship to approximately 20 dental students each year; they receive a stipend funded by the University of Tennessee College of Dentistry Alumni Association and the Tennessee Dental Association. This is a great opportunity for first-, second-, and third-year students to become involved in dental research and benefit from mentoring by their faculty members.

Alex Fitzhugh, now a fourth-year student, carried out his summer research projects in 2012 and 2013, and was awarded the Student Summer Research Fellowship in 2013. Alex also received the Student Clinician Award when he was a third-year dental student and represented UTHSC at the 2014 ADA/DENTSPLY Student Clinician Research Program at the ADA Annual Meeting in San Antonio. He will be starting his endodontic residency program at Rutgers School of Dental Medicine in 2015. The article "Investigative Prevention for Tooth Erosion," which Alex co-authored with the authors of this article, begins on page 72.

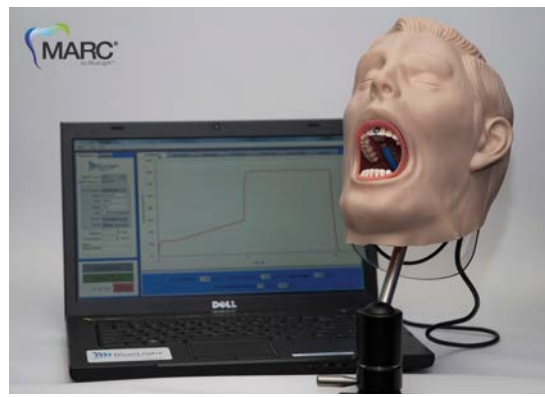

Figure 2: MARC simulator.

References

1. Gordan VV, Abu-Hanna A, Mjör IA. Esthetic dentistry in North American dental schools. *J Canadian Dent Assoc.* 2004;70(4):230-230d.
2. Simon JF, Dehghan M. Technology in a dental school curriculum. *Inside Dent.* 2012;8(3):116-8.
3. Dehghan M, Simon JF, Harrison J. Integrating the CEREC technology at UT College of Dentistry. *J Tennessee Dent Assoc.* 2012;92(1):19-21.
4. Price RB, Strassler HE, Price HL, Sachin S, Lee CJ. The effectiveness of using a patient simulator to teach light-curing skills. *J Am Dent Assoc.* 2014;145(1):32-43. **jCD**

// The school has had a student AACD study club since 2008. //



Dr. Simon is a professor and director of the Division of Esthetic Dentistry, Department of Restorative Dentistry, University of Tennessee Health Science Center (UTHSC) in Memphis, Tennessee.



Dr. Dehghan is an assistant professor in the Department of Restorative Dentistry, UTHSC.



Dr. Tantbirojn is an associate professor in the Department of Restorative Dentistry, UTHSC.

Disclosure: The authors did not report any disclosures.

Photo credits: The jCD thanks the University of Tennessee for the use of their photos in this editorial.

Investigative Prevention for Tooth Erosion

Effectiveness of a Neutralizing Mouthwash in Rehardening Softened Enamel

Alex C. Fitzhugh, BS
Mojdeh Dehghan, DDS
Daranee Tantbirojn DDS, MS, PhD
James F. Simon, DDS, MEd

Abstract

Erosion of dental enamel can result from consumption of a highly acidic diet, low salivary flow, and systemic conditions such as bulimia and gastroesophageal reflux disease. The purpose of this in vitro study was to investigate the effectiveness of a proprietary neutralizing mouthwash in rehardening enamel softened by hydrochloric acid (HCl) in saliva or a saliva-like solution. Extracted human molars were embedded and polished, and Vickers hardness was measured at baseline, softened by HCl and after remineralization. Results showed the use of this neutralizing mouthwash was an effective treatment for enamel hardness recovery.

Key Words: dental erosion, bulimia, GERD, saliva, remineralization, neutralizing mouthwash



Introduction

Dental erosion is the loss of tooth structure due to exposure to an acidic medium.¹ Damage to enamel occurs when the pH of the oral cavity drops below 5.5.² Enamel loss leads to the exposure of dentin that wears at an even faster rate than enamel, causing increased sensitivity and/or pain. Erosive tooth wear can result in major tooth damage that may require extensive dental treatment (Figs 1 & 2).

Erosive tooth wear has become more prevalent in recent years.³ Some of the primary causes for the decrease of pH in the oral cavity are consumption of acidic beverages like fruit juices, sport drinks, and carbonated soft drinks, as well as systemic conditions such as bulimia and gastroesophageal reflux disease (GERD), medications that cause dry mouth, and consumption of illegal drugs. Preventive treatment modalities are needed to arrest this irreversible loss of enamel. Different preventive regimens and products (e.g., fluoride-containing mouthrinses, remineralizing gels, and toothpastes) are available to patients suffering from acidic challenges. Our study attempted to test a new preventive regimen utilizing a mouthwash to neutralize acid prior to remineralizing the damaged tooth structures.

“Damage to enamel occurs when the pH of the oral cavity drops below 5.5.”

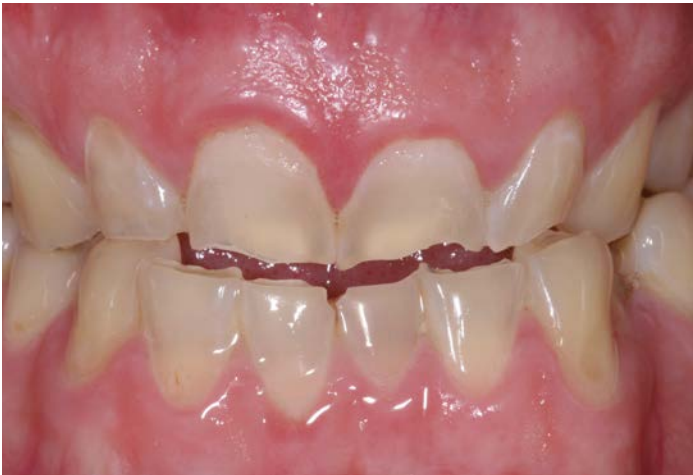

Figure 1: Extensive tooth erosion in a patient with GERD reveals thinning of facial enamel, chipped incisal edges, incisal grooves (#25 and #26), and erosion-abrasion lesions in the cervical areas.

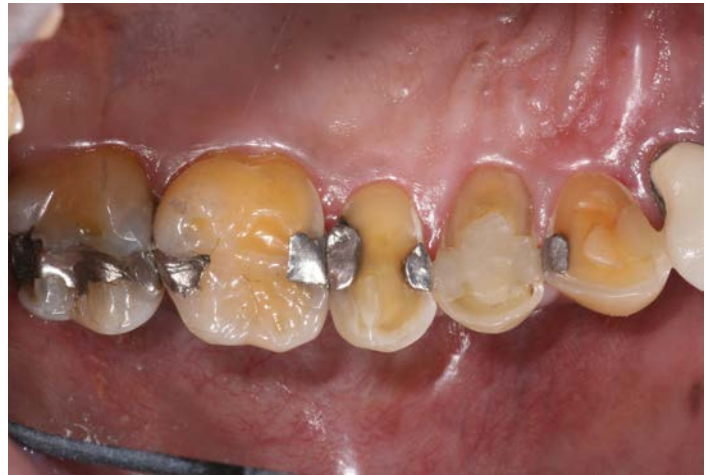

Figure 2: Another instance of tooth erosion from prolonged stomach acid regurgitation. Posterior teeth with worn lingual cusps and dentin exposure are shown. Amalgam restorations protude due to loss of surrounding tooth structures.

Objective

The objective of this study was to determine the effectiveness of a neutralizing rinse, the first step of a proprietary two-step mouthwash, to increase the rehardening of tooth enamel softened by hydrochloric acid (HCl).


A proprietary two-step mouthwash (inventors: Mojdeh Dehghan, DDS, and Daranee Versluis-Tantbirojn, DDS, MS, PhD; title: "Methods and compositions for preventing and treating tooth erosion"; PCT/US2014/019447, February 28, 2014) was developed for the prevention and control of dental erosion by neutralizing acid prior to remineralization of the affected tooth structure. The proprietary mouthwash contains calcium, phosphate, fluoride salts, and other natural ingredients. The first step of the mouthwash aims to neutralize the acid present in the mouth, and the second-step rinse is designed to help remineralize the enamel.

Methods and Materials

This study was approved by the University of Tennessee Health Science Center (UTHSC) Institutional Review Board (IRB) and given approval #10-01122-XM. Thirty non-carious extracted human molars were cut into buccal and lingual halves, and then embedded in acrylic resin. Each half was polished to create a smooth, flat surface using 240-, 400-, and 600-grit silicone carbide paper and then polished with alumina suspension (0.5 and 1.0 μm). Baseline Vickers surface hardness (VH) was measured.

After inducing acid erosion, followed by the rinsing treatment, the rehardening or remineralization procedure was carried out in saliva or a saliva-like solution. To determine the effectiveness of each treatment, enamel hardness was measured at each stage of the experiment to represent the progress or regress of the erosion process.

The hardness was measured on four sites on the polished enamel surface and averaged to a single value to represent each specimen, 10 specimens per group. The hardness was carried out using a Vickers Indenter with 200-g load and 10 seconds' dwell time (Micromet 2103, Buehler; Lake Bluff, IL) as shown in **Figure 3a**. The specimens were then immersed in 25 ml of 10 mM hydrochloric acid solution pH 2.5 (**Fig 3b**) for 10 minutes to mimic regurgitated stomach acid, followed by rinsing with 5 ml deionized water, 5 ml neutralizing rinse, or both (5 ml deionized water followed by 5 ml neutralizing rinse) as shown in **Figure 3c**. VH softening was measured. The specimens were then immersed in 5 mL pooled human saliva or a saliva-like solution (**Fig 3d**) and stored for one hour



Figures 3a-3d: Experimental steps (a) microhardness tester; (b) immersing specimen in hydrochloric acid solution; (c) rinsing; (d) remineralizing in pooled human saliva or a saliva-like solution.

Table 1. Hardness Results.

	VH baseline	VH softening	VH hardening
A-saliva	385 ± 13 a	329 ± 9 c	361 ± 12 b
B-saliva	380 ± 17 a	335 ± 20 b	377 ± 13 a
C-saliva	374 ± 16 a	327 ± 22 b	358 ± 14 a
A-saliva-like solution	381 ± 19 a	322 ± 18 c	363 ± 18 b
B-saliva-like solution	382 ± 17 a	338 ± 19 b	363 ± 17 a
C-saliva-like solution	377 ± 13 a	330 ± 15 c	360 ± 22 b

Mean ± SD of enamel specimens at baseline, after softening and rinsing with water (A), neutralizing solution (B), or both (C), and after remineralizing ('hardening') in saliva or saliva-like solution. Lowercase letters indicate statistically significant differences among the experimental stages within the same treatment group (ANOVA followed by Student-Newman-Keuls post-hoc test, $P < .05$).

at 37°C to resemble the oral cavity, rinsed, and then VH hardening was measured. The saliva used during the study was collected from four participants (UTHSC IRB #10-01122-XM) on the five mornings of the experiment and pooled together. The individuals who participated in this study and provided saliva samples were advised to refrain from brushing each morning to avoid variability in the collected saliva due to toothpaste. The saliva-like solution was prepared from 1.5 mM CaCl₂, 0.9 mM KH₂PO₄, 20 mM HEPES, 130 mM KCl, adjusted pH to 7.0 with 1 M KOH.⁴ Sample size was 10 for each group. The results were statistically analyzed with ANOVA followed by Student-Newman-Keuls post-hoc test (significance level 0.05).

Results

Vickers hardness values (VH; Mean ± SD) and statistical results are shown in **Table 1**. The bar graphs shown in **Figures 4 and 5** separately reported the VH results when the remineralization process was carried out in saliva or a saliva-like solution, respectively. Same lowercase letters denote hardness values that were not significantly different among experimental stages within the same group. VH significantly decreased after the acid challenge in all groups. After rinsing and remineralization, VH increased significantly in all groups. VH recovered to the baseline values in Group B (neutralizing rinse) remineralized either in saliva or a saliva-like solution, and in Group C (water + neutralizing rinse) remineralized in saliva (**Table 1**, **Figs 4 & 5**).

“The neutralizing rinse improved the hardness recovery of enamel softened by HCl when remineralized in saliva or a saliva-like solution.”

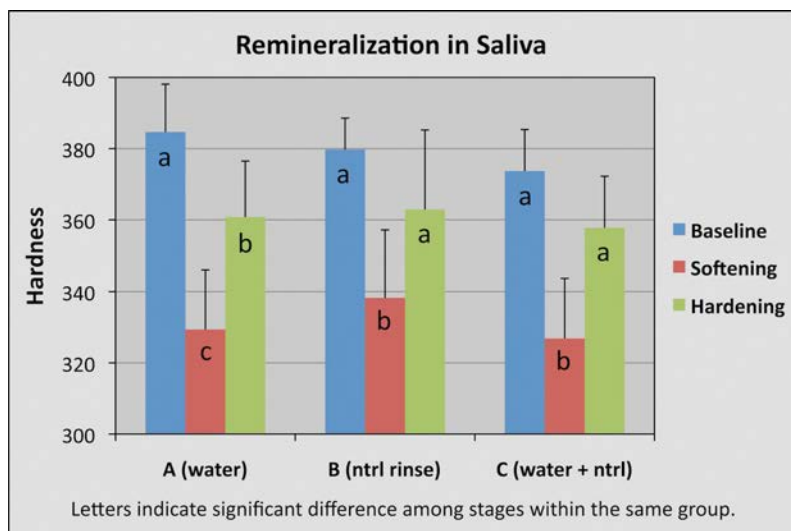


Figure 4: Hardness values (means and standard deviation) of the enamel specimens at baseline, softening, and hardening stages when remineralization was carried out in saliva. The bars are grouped according to the treatment (A = water, B = neutralizing rinse, C = water + neutralizing rinse). Letters (a, b, c) represent statistical results. Different letters indicate significant differences among the experimental stages within the same treatment group.

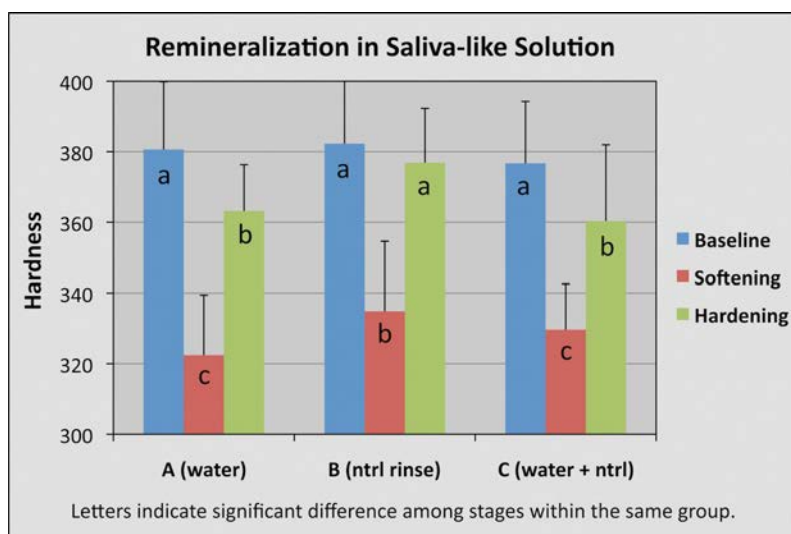


Figure 5: Similar to Figure 4, except the remineralization was carried out in a saliva-like solution rather than in saliva.

The neutralizing rinse improved the hardness recovery of enamel softened by HCl when remineralized in saliva or a saliva-like solution.

Discussion

Hardness reduction is the initial stage of erosion before surface loss occurs and therefore is an indicator of enamel erosion. There is no cure for tooth erosion; as dentists it is our responsibility to recognize the early signs and formulate a treatment plan to minimize the irreversible process.³ Prevention of tooth erosion that results from acid regurgitation in patients with bulimia or acid reflux is one of the priorities of most dental professionals. However, brushing teeth after an acidic challenge even with fluoride-containing toothpastes can cause further tooth erosion.⁵ One common mistake most patients make after an acidic exposure is their brushing habits, which can accelerate the erosion. Patients need to be informed that brushing can abrade away the tooth structures softened by acid. Preventive treatment modalities such as using fluoride rinses and avoiding immediate brushing can reduce tooth damage caused by acidic exposure. The authors of a recent article concluded that saliva alone was not sufficient to significantly increase recovery of enamel; however, saliva in conjunction with fluoride and CPP-ACP had the highest recovery.⁶ Further clinical studies are needed to determine if a two-step mouthwash similar to the neutralizing mouthwash discussed here can be more effective in the remineralization process of enamel than saliva alone.

This in vitro study attempted to replicate a clinical situation wherein tooth enamel is exposed to stomach acid from a regurgitation or purging episode. Hydrochloric acid pH 2.5 was used to represent stomach acid, the 10-minute exposure of which caused softening of surface enamel as shown in the results. Enamel softening is the initial stage before surface loss occurs and thus is indicative of tooth erosion. Patients suffering from stomach acid regurgitation usually rinse their mouth after an episode. The rinsing was simulated in this study by using water, a neutralizing solution, or

“Patients need to be informed that brushing can abrade away the tooth structures softened by acid. Preventive treatment modalities such as using fluoride rinses and avoiding immediate brushing can reduce tooth damage caused by acidic exposure.”

both. After rinsing, the softened tooth enamel was subjected to a remineralization process by immersing in pooled human saliva or a saliva-like solution for one hour. Human saliva would better represent clinical conditions but collecting human saliva in sufficient quantity for an in vitro study is a challenge. In addition, saliva composition is different between individuals. The saliva used in this study was collected each morning from four participants and pooled together to reduce individual variation that could affect the results. The saliva-like solution used in this study had calcium and phosphate content similar to normal saliva but did not have any protein or mucopolysaccharide components.⁴ The results showed similar remineralization of softened enamel between pooled human saliva and saliva-like solution for Groups A (water rinse) and B (neutralizing rinse), but the pooled human saliva showed better remineralization in Group C (water + neutralizing rinse). In other words, the differences between the saliva-like solution and pooled human saliva may not be clinically significant. This suggests that the saliva-like solution may be used as a replacement for human saliva in future in vitro studies.

This in vitro study showed that the neutralizing mouthwash improved the rehardening of enamel softened by HCl; however, further clinical studies are necessary to determine the effectiveness of the mouthwash in the oral cavity. A sequel to this investigation was presented at the ADA Annual Meeting in San Antonio in October 2014 as part of the 2014 ADA/DENTSPLY Student Clinician Research Program.

Acknowledgments

The authors thank Dr. A. Versluis and Dr. F. Garcia-Godoy for their help. This study was supported by a research grant from the University of Tennessee College of Dentistry Alumni Endowment Fund and the Tennessee Dental Association.

References

1. Zero DT, Lussi A. Erosion—chemical and biological factors of importance to the dental practitioner. *Int Dent J.* 2005;55(4 Suppl 1):285-90.
2. Lussi A, Schlueter N, Rakhmatullina E, Ganss C. Dental erosion—an overview with emphasis on chemical and histopathological aspects. *Caries Res.* 2011;45(Suppl 1):2-12.

3. Jaeggi T, Lussi A. Prevalence, incidence and distribution of erosion. *Monogr Oral Sci.* 2006;20:44-65.
4. Mukai Y, Lagerweij MD, ten Cate JM. Effect of a solution with high fluoride concentration on remineralization of shallow and deep root surface caries in vitro. *Caries Res.* 2001 Sep-Oct;35(5):317-24.
5. Lussi AJ, Carvalho TS, Cvikl B. Toothbrushing after an erosive attack: will waiting avoid tooth wear? *Eur J Oral Sci.* 2014;122(5):353-9.
6. Dehghan M, Stanley PJ, Tantbirojn D, Versluis A. Investigation of treatment options to minimize the effects of acid erosion on enamel. *Gen Dent.* 2014 Jul-Aug;62(4):e30-3. **JCD**

“Human saliva would better represent clinical conditions but collecting human saliva in sufficient quantity for an in vitro study is a challenge. In addition, saliva composition is different between individuals.”



Mr. Fitzhugh is a fourth-year dental student at the University of Tennessee Health Science Center (UTHSC) College of Dentistry in Memphis, Tennessee.



Dr. Dehghan is an assistant professor, Department of Restorative Dentistry, UTHSC.



Dr. Tantbirojn is an associate professor, Department of Restorative Dentistry, UTHSC.



Dr. Simon is a professor and director of the Division of Esthetic Dentistry, Department of Restorative Dentistry, UTHSC.

Disclosure: The authors did not report any disclosures.

FINANCIAL INTELLIGENCE FOR THE CLINICAL MIND

2015 SEATTLE STUDY CLUB SYMPOSIUM

Dentist as CEO—The Science Behind Financial Success

January 21 – 24, 2015

The Ritz-Carlton, Amelia Island, Florida

REGISTER: seattlestudyclub.com/symposium

CALL: 425.576.8000

FOR THE FIRST TIME IN OUR 23-YEAR HISTORY, WE'RE OPENING OUR SYMPOSIUM TO DENTISTS OUTSIDE THE SEATTLE STUDY CLUB® NETWORK. WE INVITE YOU TO JOIN US. Hosted by the Seattle Study Club team and emceed by Andy Boynton, the Dean of Boston College's Carroll School of Management, this Symposium will immerse you in the fundamentals of running your practice like a highly efficient business. At this intensive four-day event, you'll learn from experts in leadership, management, and marketing. You'll discover insights from top business thinkers, and examine case studies from dentists and business owners who have taken charge of their financial futures. This is a unique opportunity to ensure your financial security. Earn up to 27.5 CE credits while educating yourself on best practices and proven methods for managing people, profits, and the product called dentistry. Space is extremely limited for this exceptional learning opportunity, so we encourage you to register today.

VISIT SEATTLESTUDYCLUB.COM/SYMPOSIUM OR CALL 425.576.8000.



Academy of General Dentistry
Approved PACE Program Provider
Provider ID 300136
FAGD/MAGD Credit Approval does not
imply acceptance by a state or provincial
board of dentistry or AGD endorsement. Term
approval: 10/1/2011 to 9/30/2015

ADA C-E-R-P® | Continuing Education
Recognition Program

*"Enhance your clinical education with
financial know-how and prepare to take
your practice to the next level."*

Michael Cohen, DDS, MSD, FACD
Founder, Seattle Study Club



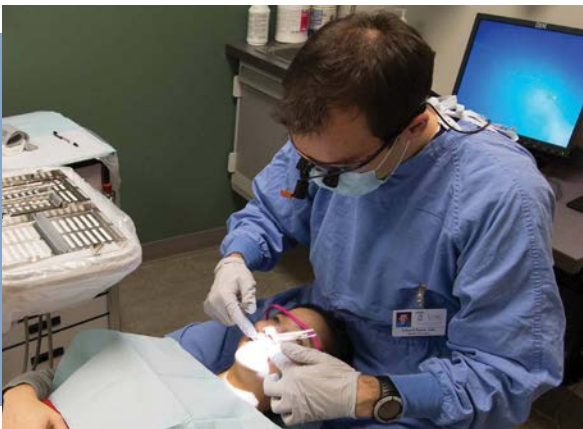
SEATTLE STUDY CLUB®
Cultivating Excellence in Comprehensive Dentistry



Extensive Training in the Realm of Esthetics

The Graduate Program in Operative Dentistry at UNC

Lee W. Boushell, DMD, MS
André V. Ritter, DDS, MS, MBA




The increased complexity of restorative options, materials, techniques, adhesive dentistry strategies, and esthetic dentistry possibilities have resulted in a need for advanced training in operative dentistry.

The Department of Operative Dentistry at the University of North Carolina (UNC) at Chapel Hill offers a three-year comprehensive graduate program leading to a Master of Science degree and a Certificate in Operative Dentistry. The program's primary objective is to provide advanced operative dentistry training that will prepare graduates for careers in dental education and research; this includes extensive training in the realm of esthetics. Graduates also have the potential for other careers such as clinical or technical research directors; and consultants to dental corporations, insurance providers, public health policy organizations, professional dental societies, and philanthropic dental research or education funding agencies.

Curriculum

The Operative Dentistry Graduate Program curriculum begins by providing foundational education in core courses that support the profession of dentistry. Advancement in the program then affords operative dentistry discipline-specific courses. These include intensive literature reviews in the area of restorative and esthetic dentistry and small group seminars to study the subtleties of patient care with identification and planning for optimal esthetic treatment outcomes. Graduate students also participate in interdisciplinary care conferences that highlight esthetic options and regularly teach in preclinical/clinical settings where principles of restorative and esthetic dentistry must be applied. Each resident has the opportunity to design and carry out research on materials and methods that support and advance esthetic dentistry. In addition, students can enroll in a wide range of elective courses based upon their research and career interests, including courses in public health, epidemiology, clinical research methods, material sciences, oral biology, biostatistics, and education.



Patient Care

All operative dentistry graduate students provide patient care during weekly clinic sessions. Patient care is centered primarily on (1) caries risk assessment and management; and (2) conservative, esthetic, adhesive operative dentistry procedures, such as anterior and posterior composite resin restorations, esthetic composite additions following orthodontics, diastema closure, porcelain veneers, esthetic crowns, ceramic inlays/onlays, and restoration of fractured anterior teeth. Residents also receive didactic and clinical training in a variety of implant-supported restoration techniques. Students receive training to develop the skill set necessary to document cases with digital photography and records, and are required to present them throughout the program in both discipline-specific and interdisciplinary seminars.

Teaching

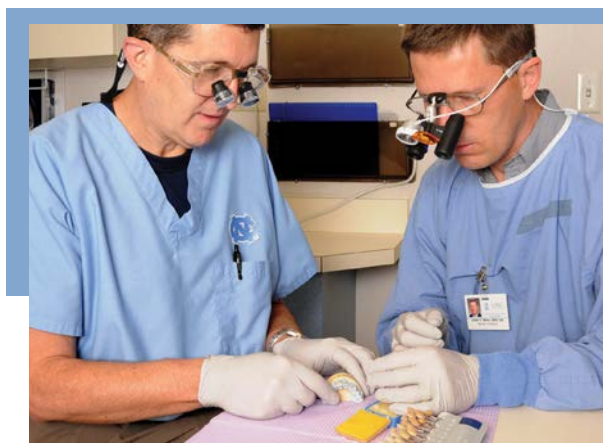
Since the primary objective of the program is to provide advanced operative dentistry training that will prepare graduates for careers in dental education, teaching also is a key component of our program. As noted in the curriculum section described previously, operative dentistry graduate students have the opportunity to engage in a variety of teaching internships, including preclinical laboratory, clinical, and didactic courses offered by the department. These opportunities require mastery of principles and techniques utilized in esthetic dentistry.

Research

One vital component of our program is the development and successful completion of a thesis research project. Core courses in research design and protocol development assist students in this task. Specific research themes include basic (biomedical) research, which includes materials and methods that support esthetic dentistry; behavioral and social sciences research; and translational research. Operative dentistry graduate students are encouraged to identify a research topic and select a mentor early in the program, and to work with their mentor and committee toward the successful completion of the thesis project. Students typically defend their thesis in the spring of their third year in the program. The Department of Operative Dentistry is involved in a wide array of research projects spanning many interests, including in vitro biomaterials research, operative dentistry clinical research, and health services research. The primary focus of the majority of these efforts is to improve the treatment outcomes of patients who receive esthetic dentistry procedures. The department also works collaboratively with other units and schools, extending the range of opportunities for graduate thesis research.

Dr. Vilhelm Olafsson is a third-year resident in the Operative Dentistry Master's Program, UNC School of Dentistry. He is co-author of the article, "Pragmatic Esthetics," which begins on page 82.

Dr. Olafsson received his doctoral training in dentistry from the University of Iceland Faculty of Odontology in 2007. He served as an adjunct faculty member in preclinical and clinical operative dentistry from 2010 to 2012 and also practiced general dentistry in Iceland until 2012, when he began his Master of Science and Certificate in Operative Dentistry curriculum at the UNC School of Dentistry. Dr. Olafsson has a keen interest in the combination of the conservative foundations of dentistry with the advantages afforded through the disciplines of esthetic dentistry. His goal is to pursue a career in academic dentistry, mentoring dental students in restorative dentistry, with a special emphasis on esthetic dentistry.



“The program’s primary objective is to provide advanced operative dentistry training that will prepare graduates for careers in dental education and research...”



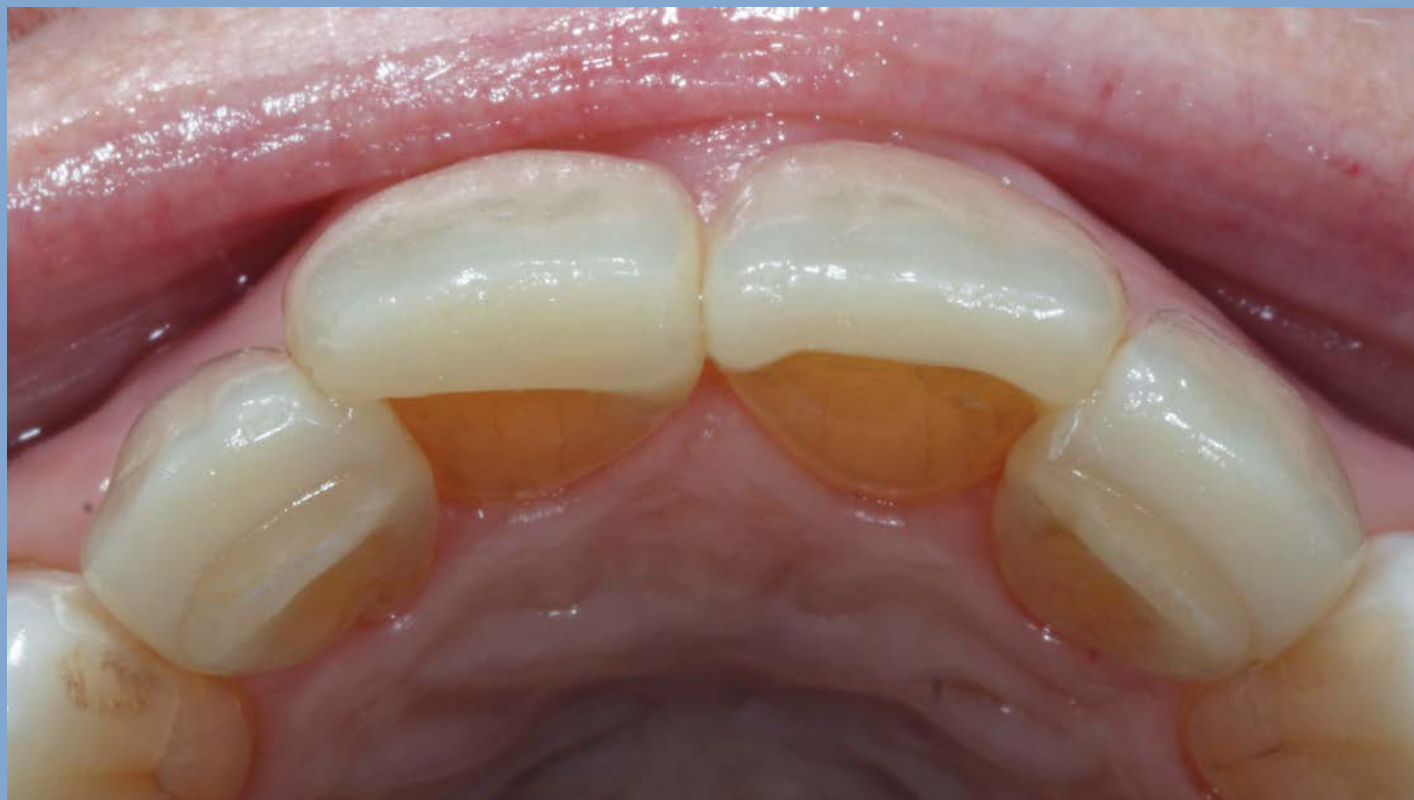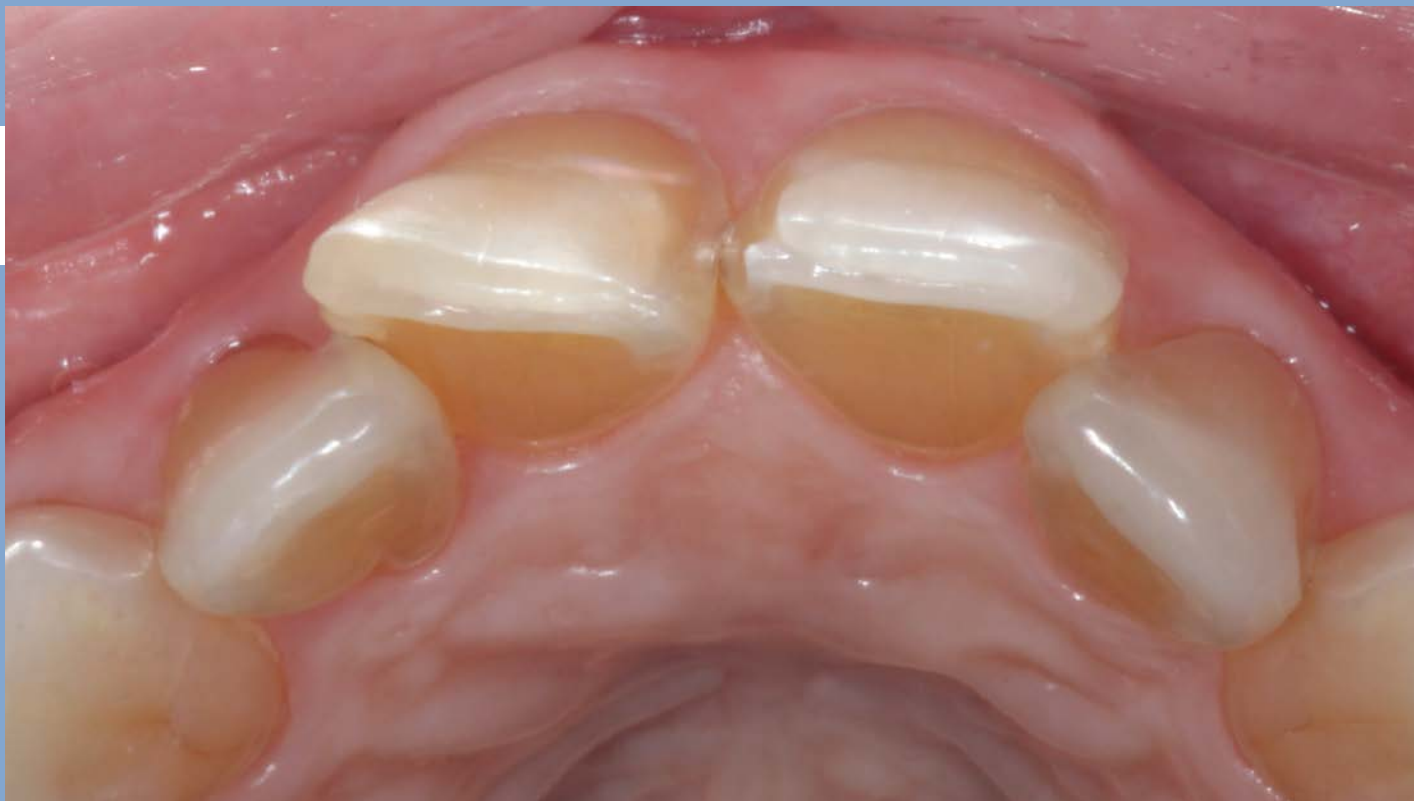Dr. Boushell is the graduate program director and an associate professor, Department of Operative Dentistry, School of Dentistry, University of North Carolina (UNC) at Chapel Hill.



Dr. Ritter is professor and chair, Department of Operative Dentistry, School of Dentistry, UNC at Chapel Hill.

Disclosure: The authors did not report any disclosures.

Photo credits: The jCD thanks the University of North Carolina at Chapel Hill for the use of their photos in this editorial.



Pragmatic Esthetics

Severe Labial Erosion Corrected with Direct Composite Resin Veneers

Vilhelm G. Olafsson, DDS
Lee W. Boushell, DMD, MS

Abstract

Erosive tooth wear (ETW) is a complex, multifactorial condition that may lead to extensive loss of tooth structure if left undiagnosed and untreated. Early detection and prevention is critical to avoid the necessity for complex rehabilitations. In early stages of ETW, additive treatment with composite resins is able to simultaneously prevent sensitivity, protect the remaining tooth structure from further ETW, and improve esthetics. This article illustrates a situation where localized severe labial erosion had compromised the integrity of the maxillary anterior dentition. Diet counseling and treatment with direct composite resin veneers were selected as the means of preserving and protecting tooth structure while simultaneously resolving esthetic concerns.

Key Words: erosive tooth wear, intrinsic erosion, extrinsic erosion, pragmatic esthetics, direct composite resin veneers

There are two types of erosion: intrinsic and extrinsic.

Introduction

Dental erosion is defined as the irreversible loss of tooth structure by a chemical process that does not involve bacteria.^{1,2} There are two types of erosion: intrinsic and extrinsic. The former results from gastric acids entering the oral cavity, most often due to gastroesophageal reflux disease (GERD) or vomiting. The latter is due to the ingestion of acidic foods and beverages. In both instances, acidic content with a pH below the critical pH of enamel (5.2 - 5.5 for hydroxyapatite, 4.5 for fluorapatite)³⁻⁵ and dentin (6.7)⁶ dissolves and weakens the hard tissues of the tooth. Careful clinical observation of the distinct erosion pattern is useful in identifying the etiology of the dental condition. Intrinsic erosion is generally seen on the palatal surfaces of the maxillary teeth and the occlusal surfaces of the mandibular molars. Extrinsic erosion is generally seen on the labial surfaces of the anterior teeth, the buccal surfaces of the posterior teeth, and on the occlusal surfaces of the mandibular molars.⁷

Acid erosion may be further exacerbated by abrasion, attrition, and perimolysis, which accelerate the loss of acid-softened enamel and dentin.⁸⁻¹⁰ Because chemical erosion is rarely the sole cause of tooth structure loss, erosive tooth wear (ETW) is a more appropriate term to describe the process of tooth wear. Since multiple factors may be involved, the patient's dietary and oral hygiene habits must be investigated in addition to looking for signs of parafunctional habits. Work and recreational activities may also need to be investigated, as some industrial workers and athletes can be at an elevated risk for ETW.⁷ If the source of acid is believed to be intrinsic then appropriate referrals need to be accomplished in order to investigate and treat GERD or eating disorders. A diet analysis, as described by Kidd,¹¹ can be useful in investigating the amount and frequency of extrinsic erosive attacks. Patients often are not aware of the erosive nature of their diet, as common erosion-causing fruits and beverages are generally believed to be very healthful. When administering a diet analysis, it is important to make sure that the patient reports dietary intake on a weekend as well as weekdays, so as to account for associated changes. Corrective steps should first and foremost focus on preventing further damage by identifying and limiting/eliminating the source(s) of acids. This is followed by protecting the remaining tooth structure from further ETW. Alleviation of sensitivity, the preservation of function, and the improvement of esthetics may be accomplished simultaneously.^{7,12} Conservative methods of accomplishing this include fluoride application to enamel and sealing of exposed dentin with composite resins.

Historical Treatment

Historical treatment of severe ETW was often by means of crowning affected teeth or even through full-mouth rehabilitation with the goal of achieving ideal occlusal relationships and esthetics. Such treatment methods, however, actually effected a more massive destruction of the affected teeth than the causative factors themselves had produced. This was elegantly stated as "a strange way to treat teeth which were already compromised by wear."¹³ The authors introduced the concept of pragmatic esthetics, with special reference to the treatment of tooth wear. They proposed bonding composite resins to worn teeth to simultaneously protect them from further wear and improve patient-perceived esthetics. It was suggested that, even though pragmatic esthetics might not conform to the highest principles of dental esthetics, the philosophy of treatment was a practical way to improve patient-perceived esthetics while preserving tooth structure. The following case report is an example of how the concept of pragmatic esthetics may be applied in the treatment of severe labial erosion resulting from ETW.

Case Report

Subjective Findings

A 69-year-old female sought treatment at the Operative Dentistry Graduate Clinic at the University of North Carolina (UNC) School of Dentistry. Her chief concern was that she had lost enamel on her front teeth, and that some of her front teeth had started chipping and breaking (**Fig 1**). Review of her medical history revealed a diagnosis of hypertension in 2002, which was being treated with aspirin, lisinopril, and bisoprolol; and GERD in 2008, which was being treated with ranitidine. Other aspects of her medical history were non-contributory. She reported that the medications gave her dry mouth, especially at night. The patient had a history of yearly dental checkups.

A four-day diet analysis was performed, including two weekdays and a weekend. In addition, a custom questionnaire was used to analyze her past and present oral hygiene techniques, as well as any habits, such as placement of food/drink under her lips or lemon sucking. The diet analysis and questionnaire revealed that she ate apples four or five times a week as well as grapes and pears frequently. She drank lemon-flavored ice tea daily—throughout the day—to relieve dry mouth symptoms. She stated that she had reduced juice, citrus fruit, and tea consumption since her GERD diagnosis. With relation to oral hygiene techniques, she admitted that in the past she had brushed her front teeth very aggressively with "whitening" toothpaste because she was unhappy with the shade of her teeth. She now brushes less aggressively due to concerns about enamel loss but still uses the same toothpaste, and the shade of her teeth is no longer a concern. The patient reported using Biotène Oral Balance (GlaxoSmithKline; Research Triangle Park, NC) at bedtime to prevent her upper lip from sticking to her teeth in the morning, an unpleasant side effect of dry mouth.

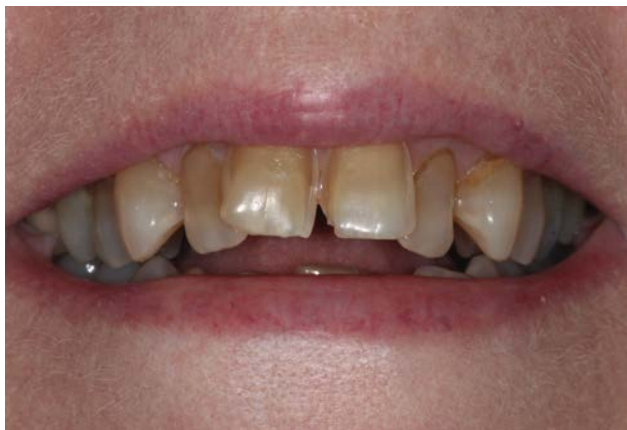

Figure 1: Preoperative smile. Note the loss of labial enamel, a Class IV fracture on #9, anterior crowding, and reverse smile line.

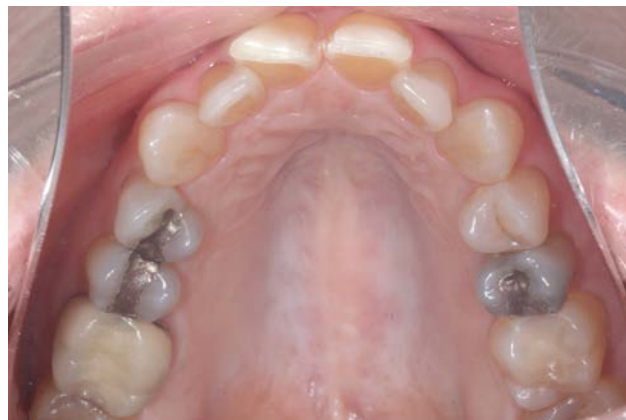

Figure 2: Maxillary occlusal view. Severe erosion can be seen on the labial surfaces but signs of erosion are less evident on occlusal or palatal surfaces.

Objective Findings

Clinical examination revealed that the patient had good overall oral hygiene. Restorations included a porcelain-fused-to-metal crown at #3 and multiple posterior teeth with Class I or II amalgam or resin-composite restorations that were serving the patient well. None of the anterior teeth had ever been restored (Figs 2 & 3). An anterior open bite and reverse smile line was noted, along with severe crowding in the anterior maxillary sextant (Figs 1, 4, & 5). Most of the cervical and middle third labial enamel was missing on ##7-9. The remaining labial enamel of #10 was minimal. A mesial Class IV fracture was detected on #9. A thin, although interrupted, rim of enamel was still present along the gingiva in ##7-9. Less severe loss of facial enamel was present in the cervical areas of the maxillary canines and premolars. The incisal/occlusal surfaces had not suffered as much loss of tooth structure (Figs 6 & 7) and the lingual surfaces seemed to be unaffected (Figs 2 & 3).

Assessment

It was concluded that the patient had chronic moderate to severe xerostomia, an anterior open bite with maxillary anterior crowding, and was experiencing severe ETW associated with her maxillary anterior labial surfaces. The location of the patient's erosion was consistent with common findings in patients with ETW.⁹ All the lingual and occlusal surfaces seemed to be unaffected (Figs 2 & 3); this supported an extrinsic etiology, despite the patient's GERD diagnosis a few years earlier. The diet analysis/questionnaire revealed factors, in addition to dry mouth, that have been associated with a higher incidence of dental erosion.¹⁴ Apples, citrus fruits, and certain tea drinks have been reported to have great erosive potential.^{15,16} The ETW was likely exacerbated by aggressive tooth brushing with an abrasive toothpaste. Biotène Oral Balance has

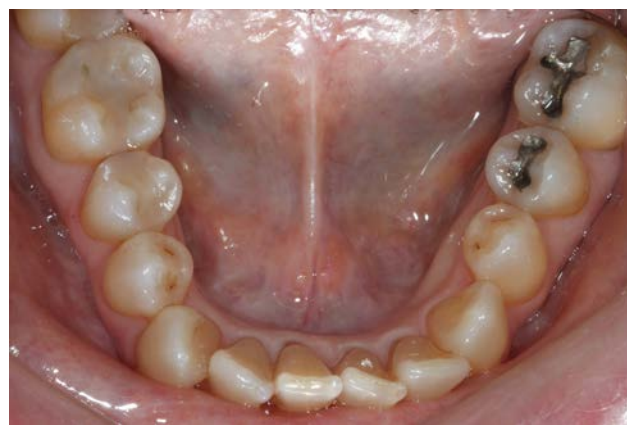

Figure 3: Mandibular occlusal view.

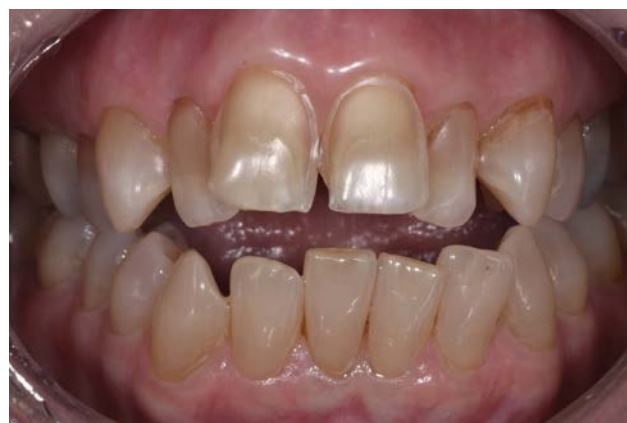

Figure 4: Frontal view. Labial/buccal enamel loss can be clearly seen, along with a Class IV fracture on #9. An open bite with anterior crowding is evident.

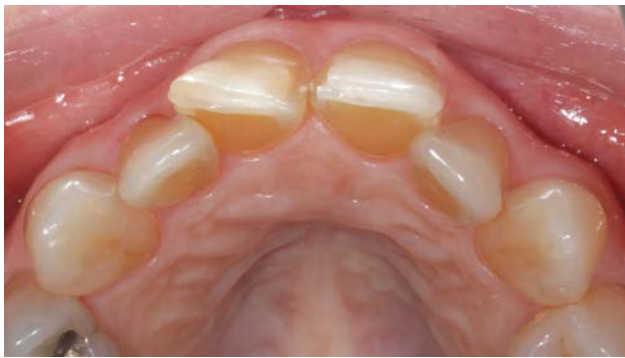

Figure 5: Anterior maxillary sextant. Crowding and labial enamel loss are evident.

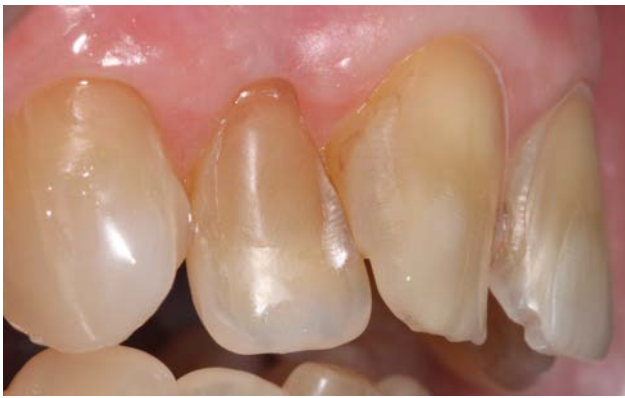

Figure 6: Pattern of erosive tooth wear on ##6-8.

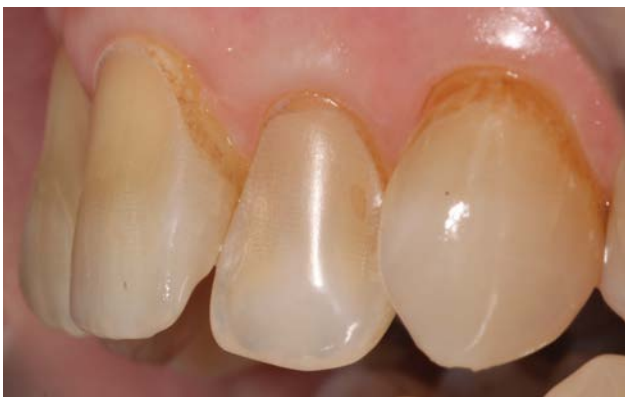

Figure 7: Pattern of erosive wear on ##9-11.

Careful clinical observation of the distinct erosion pattern is useful in identifying the etiology of the dental condition.

been found to have an average pH of 6.6, is not erosive to enamel, and thus was not be considered to be part of the primary etiology.

An orthodontic consultation from the UNC Department of Orthodontics was obtained and the patient was presented with different treatment options to correct the open bite and crowding. The patient declined all orthodontic treatment.

Treatment Plan

The patient was counseled with regard to ETW and encouraged to modify her dietary habits toward a less erosive pattern, especially in between meals. She was also encouraged to use xylitol-containing chewing gum on a daily basis to stimulate her natural salivary flow and to use a less abrasive toothpaste.

A conservative treatment plan for direct composite resin veneers on ##7-10 was developed and presented to the patient. The proposal included addition of composite resin to the facial surfaces of #7 and #10 to bring them into the same facial plane as #8 and #9, as well as increasing overall incisal length to correct the reverse smile line. A diagnostic wax-up of the anticipated outcome was presented to the patient, who approved the approach and consented to the treatment. A polyvinyl siloxane lingual matrix was generated from the wax-up for use as a guide for incisal edge position during the restorative phase (Figs 8-10).

Treatment

Composite resin shade was determined by first finding an approximate shade match using the Vita Classical Lumin guide (Vita Zahnfabrik; Bad Säckingen, Germany), and then making a direct mock-up using the corresponding shades on the affected teeth. A nanohybrid composite, shade D3, was used for dentin replacement due to its desirable opacity and strength (Venus Pearl, Heraeus Kulzer GmbH; Hanau, Germany). For enamel replacement, a microfilled composite, shade D3, was chosen for its excellent polishability, polish retention, and appropriate translucency for enamel replacement (Durafil VS, Heraeus Kulzer).

A non-latex flexible retraction ring (OptraGate, Ivoclar Vivadent AG; Shaan, Liechtenstein) was used during the restorative procedures. Associated gingiva was retracted using an unmedicated #00 retraction cord to facilitate composite resin application, finishing, and polishing (Ultrapak, Ultradent; South Jordan, UT). Prior to etching, the teeth were cleaned with pumice and water, rinsed, and dried. The enamel was then lightly roughened with a fine diamond to remove the fluoride-rich outer layer and increase surface area available for

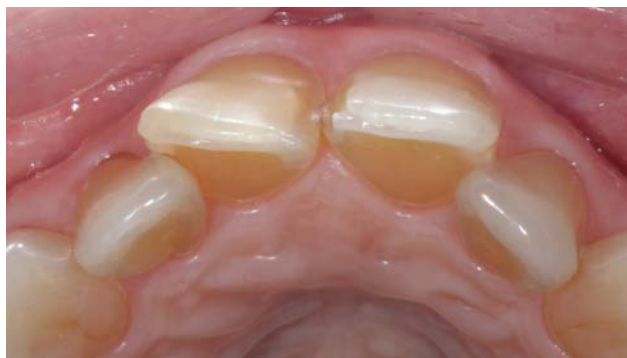

Figure 8: Facial planes of ##7-10 prior to restorative treatment.

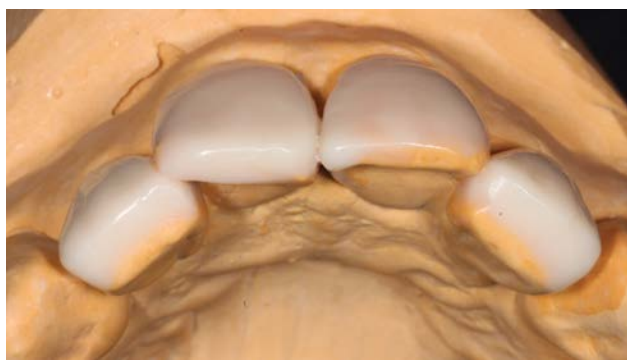

Figure 9: Wax-up of proposed restorative treatment, bringing the facial surfaces of ##7-10 into a more natural arch form.

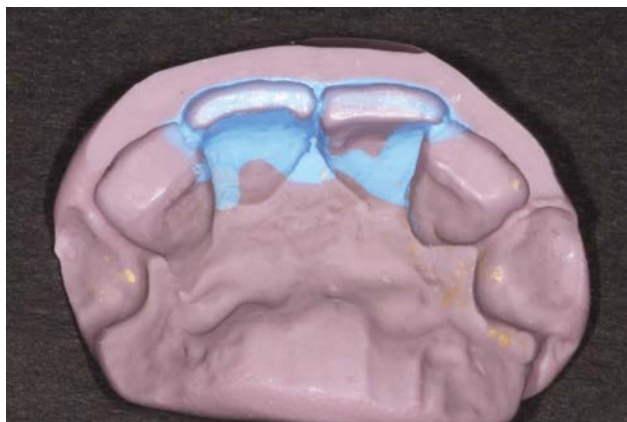


Figure 10: A silicone matrix was developed to serve as a guide for incisal edge alignment.

bonding. The teeth were etched with 35% phosphoric acid (Ultra-Etch, Ultradent) prior to treating them with two coats of a primer/desensitizer (Gluma Desensitizer, Heraeus Kulzer) to prevent post-operative sensitivity and retard breakdown of the hybrid layer.^{17,18} After lightly drying the desensitizer, two coats of a two-step etch-and-rinse adhesive (Adper Single Bond Plus, 3M ESPE; St. Paul, MN) were applied and air-thinned to remove excess solvent and minimize thickness of the adhesive layer. The adhesive was light-cured for 20 seconds with a high-output LED curing light (Demetron A.2, Kerr; Orange, CA). The dentin increments were applied to the lateral incisors using the matrix as a visual aid, to build them further out toward the labial, leaving an appropriate space for the enamel increments. Only a thin layer of dentin replacement composite was placed on the cervical areas of #8 and #9. The enamel increments were placed using the lingual matrix for incisal edge position and thickness. The labial increments were then applied, using conventional instruments and sable brushes. All increments were light-cured for 20 seconds. A pencil was used to highlight line angles and draw anatomical features to be replicated during finishing, which was performed using fine-grit flame-shaped diamonds (Brasseler USA; Savannah, GA) and flexible pop-on discs (Sof-Lex, 3M ESPE) (Fig 11). The incisal edges of #7 and #10 were reduced toward the lingual to hide their apparent thickness (Figs 8, 9, & 12). Final polish was obtained using a fine-grit aluminum-oxide polishing paste (Prisma Gloss Fine, Dentsply Caulk; Milford, DE) in a buff disk (Super-Snap, Shofu Dental; San Marcos, CA) (Fig 13). The patient tolerated the procedures well and was very pleased with the esthetic result.

The patient returned for postoperative assessment after one week (Figs 14 & 15); at eight months, at which time a minor repair was necessary (Figs 16 & 17); and at 20 months (Figs 18-20). At eight months and 20 months the restorations were repolished. No color change was noted at any interval and polish retention was deemed clinically acceptable, although the clinician (VGO) decided to polish the restorations at follow-up appointments to minimize plaque adhesion and maximize esthetic longevity. No marginal discoloration was noted, although a repair was necessary at the eight-month interval (a lamination defect had occurred at the mesial line-angle of #8). Successful repair was performed and the defect was not evident at the 20-month recall (Fig 20). Patient satisfaction remained very high from the initiation to the completion of treatment.

When administering a diet analysis, it is important to make sure that the patient reports dietary intake on a weekend as well as weekdays, so as to account for associated changes.

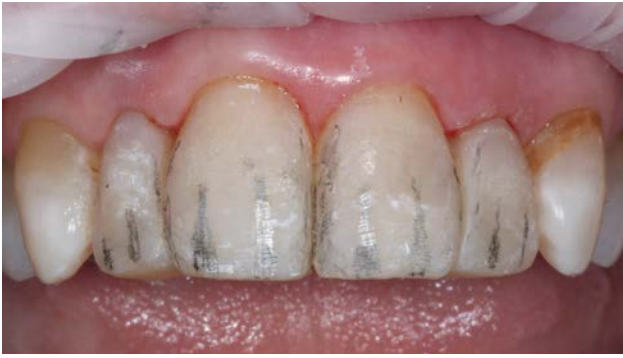

Figure 11: Pencil marks were used as a visual aid during finishing. Line angles and anatomical features to be replicated were identified.

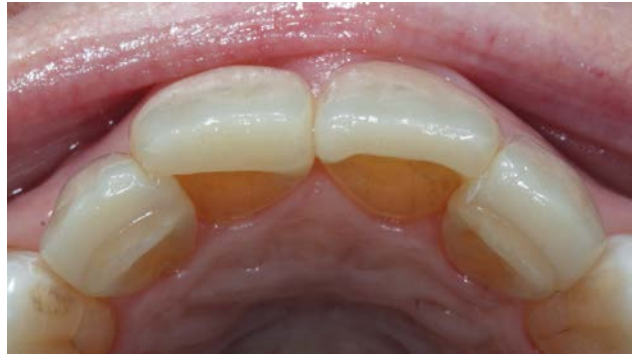

Figure 12: Facial planes of ##7-10 after restorative treatment.

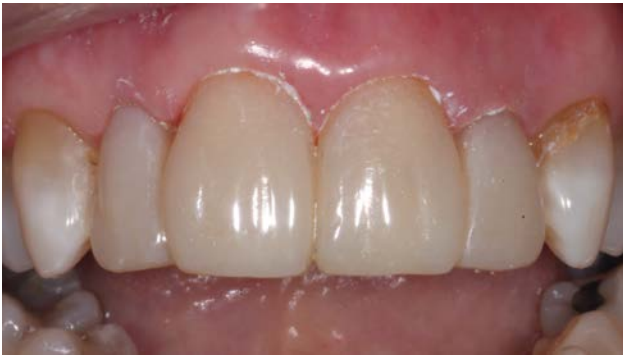

Figure 13: Polishing paste was applied using felt disks to achieve a final luster while preserving facial anatomy and texture.

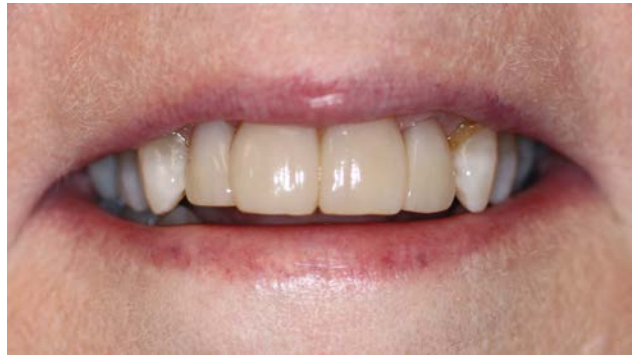

Figure 14: Smile, one week postoperative. Note improved relationship of incisal edges with lower lip.

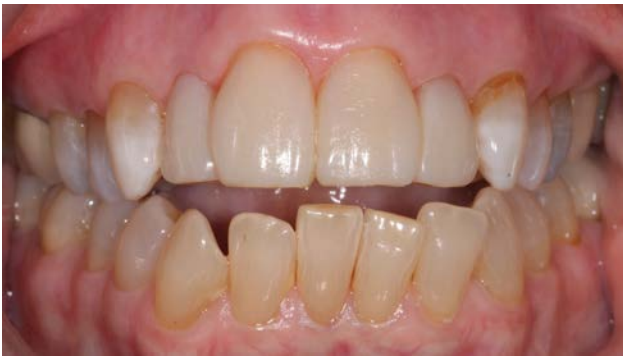

Figure 15: One-week postoperative frontal view.

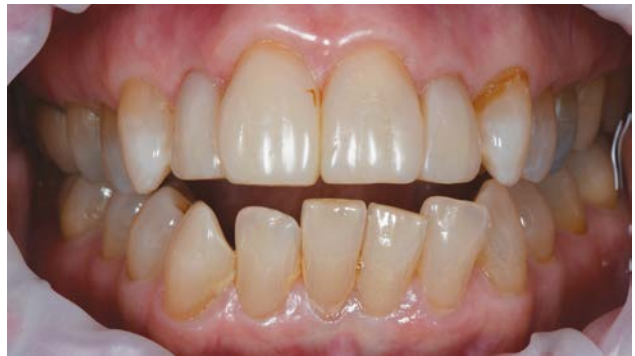

Figure 16: Follow-up after eight months. A repair was necessary at the mesial line angle of #8, where a lamination defect had accumulated stain.

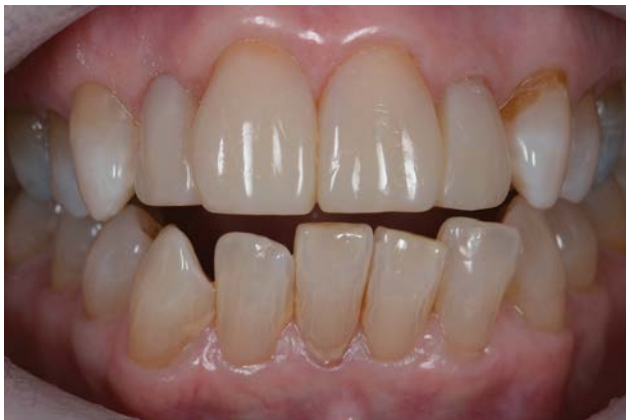

Figure 17: Follow-up after eight months, after correction of the lamination defect as well as repolishing of the direct composite resin veneers.

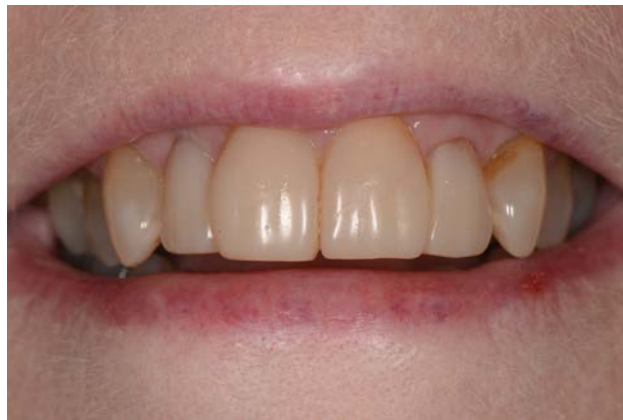

Figure 18: Smile at the 20-month follow-up.

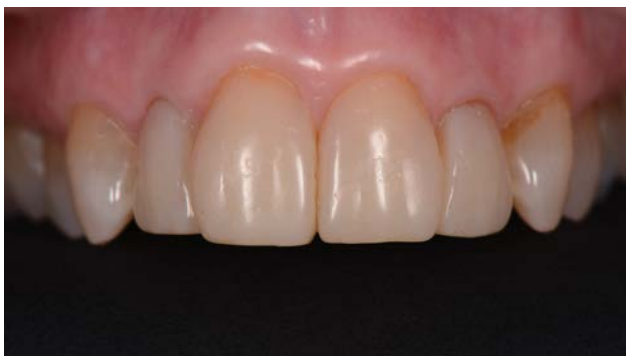

Figure 19: Retracted maxillary view at the 20-month follow-up. Very slight marginal staining can be seen at the mesial margin on #8, other margins are stain-free, and polish retention remains clinically acceptable. Evidence of layering technique is visible.

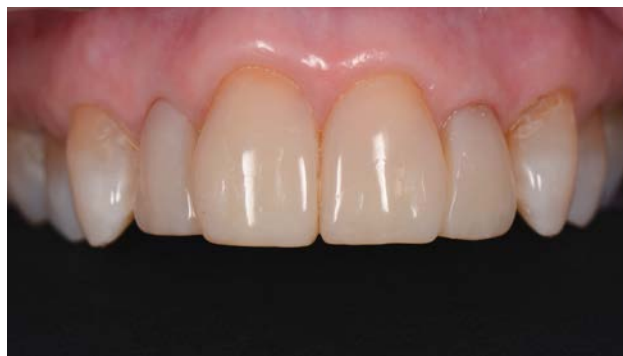

Figure 20: Retracted maxillary view at the 20-month follow-up, after repolishing of the direct composite resin veneers.

Direct composite resin application presents a very conservative, cost-effective method for treatment of the patient with moderate to severe ETW.

Conclusions

Direct composite resin application presents a very conservative, cost-effective method for treatment of the patient with moderate to severe ETW. This procedure is able to simultaneously protect the remaining tooth structure, limit sensitivity, improve esthetics, and enhance function. While application of these restorations is technique-sensitive, maintenance is readily accomplished and can increase longevity. Advantages of the reversible nature of the procedure include preservation of tooth structure and the option of different treatments in the future.

The direct composite resin additions presented here may not conform to the highest principles of dental esthetics with regard to tooth proportion, alignment, and smile design. However, the concept of pragmatic esthetics was adhered to, as evidenced by improved patient-perceived esthetics without the use of more aggressive treatment modalities. "Our objective should be the perpetual preservation of what remains rather than the meticulous restoration of what is missing."¹⁹

References

1. Pindborg J. Pathology of dental hard tissues. Copenhagen: Munksgaard; 1970.
2. Eccles JD, Jenkins WG. Dental erosion and diet. *J Dent*. 1974 Jul;2(4):153-9.
3. Anderson P, Hector MP, Rampersad MA. Critical pH in resting and stimulated whole saliva in groups of children and adults. *Int J Paediatr Dent*. 2001 Jul;11(4):266-73.
4. McIntyre JM. Erosion. *Aust Prosthodont J*. 1992;6:17-25.
5. Larsen MJ. Dissolution of enamel. *Scand J Dent Res*. 1973;81(7):518-22.
6. Surmount P, Martens, LC. Root surface caries: an update. *Clin Prev Dent*. 1989 May-Jun(11):14-20.
7. Gandara BK, Truelove EL. Diagnosis and management of dental erosion. *J Contemp Dent Pract*. 1999 Nov;1(1):16-23.
8. Bartlett D, Phillips K, Smith B. A difference in perspective—the North American and European interpretations of tooth wear. *Int J Prosthodont*. 1999 Sep-Oct;12(5):401-8.
9. Lussi A, Hellwig E, Zero D, Jaeggi T. Erosive tooth wear: diagnosis, risk factors and prevention. *Am J Dent*. 2006 Dec;19(6):319-25.
10. Amaechi BT, Higham SM, Edgar WM. Influence of abrasion in clinical manifestation of human dental erosion. *J Oral Rehabil*. 2003 Apr;30(4):407-13.
11. Kidd EA. The use of diet analysis and advice in the management of dental caries in adult patients. *Oper Dent*. 1995 May-Jun;20(3):86-93.
12. Donovan T. Dental erosion. *J Esthet Restor Dent*. 2009;21(6):359-64.
13. Burke FJ, Kelleher MG, Wilson N, Bishop K. Introducing the concept of pragmatic esthetics, with special reference to the treatment of tooth wear. *J Esthet Restor Dent*. 2011 Oct;23(5):277-93.
14. Jarvinen VK, Rytomaa, II, Heinonen OP. Risk factors in dental erosion. *J Dent Res*. 1991 Jun;70(6):942-7.
15. Clark DC, Woo G, Silver JG, Sweet D, Grisdale JC. The influence of frequent ingestion of acids in the diet on treatment for dentin sensitivity. *J Can Dent Assoc*. 1990 Dec;56(12):1101-3.
16. Phelan J, Rees J. The erosive potential of some herbal teas. *J Dent*. 2003 May;31(4):241-6.
17. Tjaderhane L, Nascimento FD, Breschi L, Mazzoni A, Tersariol IL, Geraldeli S, Tezvergil-Mutluay A, Carrilho M, Carvalho RM, Tay FR, Pashley DH. Strategies to prevent hydrolytic degradation of the hybrid laye—a review. *Dent Mater*. 2013 Oct;29(10):999-1011.
18. Bedran-Russo AK, Pashley DH, Agee K, Drummond JL, Miescke KJ. Changes in stiffness of demineralized dentin following application of collagen crosslinkers. *J Biomed Mater Res B Appl Biomater*. 2008 Aug;86(2):330-4.
19. Devan MM. The nature of the partial denture foundation: suggestions for its preservation. *J Prosthet Dent*. 1952 Mar;2(2):210-18. **JCD**



Dr. Olafsson is a resident in the Operative Dentistry Master's Program, School of Dentistry, University of North Carolina (UNC) at Chapel Hill.



Dr. Boushell is the graduate program director and an associate professor, Department of Operative Dentistry, School of Dentistry, University of North Carolina (UNC) at Chapel Hill.

Disclosures: The authors did not report any disclosures.

The Learning Never Stops: AACD Builds Relationships with Dental Faculty and Students Through Outreach Initiatives

Understanding the importance of collaborating with other educators, the AACD continues to strengthen its relationships with university faculty members and dental students in two different ways: the University Outreach Program and the University Educators Forum (UEF).

University Outreach Program

The University Outreach Program connects dental students with AACD Accredited Members. During each University Outreach event, the Accredited Members discuss clinical cases, smile design principles, and responsible esthetics with students. The Accredited Members also tell students how AACD can benefit their careers and help them advance their education beyond dental school through the AACD Accreditation Program.

The events include a lunch or dinner, and attendees are given *"Photographic Documentation and Evaluation in Cosmetic Dentistry: Guide to Accreditation Photography."* Sample copies of the *"Guide to Accreditation Criteria: Contemporary Concepts in Smile Design"* are also available for preview before purchase.

For more information about these events, contact Tori Pixler, AACD Credentialing Coordinator, at torip@aacd.com.

University Educators Forum

The UEF is open to dental faculty members who are also AACD Members, with the intent of passing on clinical excellence to others who wish to explore the desire to learn more about comprehensive cosmetic dentistry. UEF participants receive webinar information, recommended courses, *Journal of Cosmetic Dentistry* articles, white papers, and the satisfaction of supporting UEF through their dental schools.

Last year, more than 30 faculty members worldwide met at AACD 2014 in Orlando. AACD hopes to welcome an even larger crowd at AACD 2015 in San Francisco, May 6-9.

For more information about UEF, or to join, contact Amy Ballard, AACD Staff Liaison, at amyb@aacd.com.

Congratulations!

The AACD is proud to announce its Newly Accredited Fellows!

Since its inception in 1992, the AACD Fellowship program has provided an exceptional opportunity for dentists and laboratory technicians to greatly enhance their professional skills and knowledge in the areas of cosmetic and restorative dentistry. The program is unique in that it requires a dentist or laboratory technician to implement and demonstrate what they have learned at a level of proficiency. AACD credentialing processes are accessible regardless of location, educational background, or years of clinical experience. Candidates must have the resolve to meet challenges head-on, aspire to continually seek growth, and work persistently toward a worthy goal.

Fellowship is the highest level of achievement available to members of the American Academy of Cosmetic Dentistry, in accordance with the AACD's mission of education and excellence. The AACD is pleased to announce the latest members to have attained Accredited Fellow status: Dr. Nicholas Davis, Dr. Laura Justice, and Dr. Marc Montgomery.

The new Accredited Fellows will be recognized for their achievement at AACD 2015 in San Francisco.

Nicholas C. Davis, DDS
Newport Beach, California
Member since 1990



Laura L. Justice, DMD
Lexington, Kentucky
Member since 1999



Marc L. Montgomery, DDS
Woodbury, Minnesota
Member since 1998



Join us at Sawgrass for dynamic seminars and workshops!

Ponte Vedra Beach, FL / February 12-14, 2015 / The TPC Sawgrass Clubhouse

Selection: The Most Crucial Steps

Three renowned course speakers will review the most crucial aspects of material selection, restoration design, effective communication, and treatment planning to final cementation.

Material Selection Dr. Raigrodski

Shade Selection Yoshida, RDT

Cementation Selection Dr. Blatz

Optional hands-on workshop:

Capture Shade Taking Methods by Digital Photography

Yoshida, RDT



Markus B. Blatz
DMD, PhD



Ariel J. Raigrodski
DMD, MS, FACP



Aki Yoshida, RDT

Visit www.academyofdes.org for program details and accommodations.

ADES

Academy of Dental Esthetics and Sciences



Reserve NOW for Dr. Gerard Chiche's Seminar
November 6-7, 2015 / Ponte Vedra Beach, FL
The Esthetic Zone Inside and Out



ADES, The Educational Division of Cusp Dental

Sponsors: **kuraray** *Noritake*

HENRY SCHEIN

Nobel Biocare

QUINTESSENCE PUBLISHING



AACD LOVES Dental Students

Educational Opportunities for Universities, Dental Students, Dental School Faculty, and Young Professionals



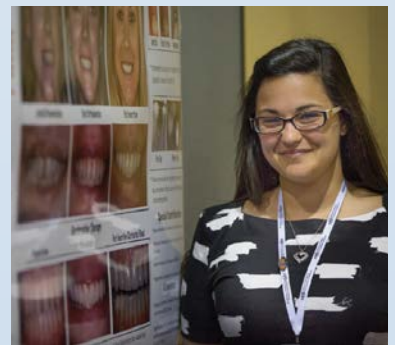AACD APEX
Student Scholarships to AACD's Annual Scientific Session. Valued at more than \$1,600!

AACD University Outreach

Successful cosmetic dentists visit select campuses to speak on responsible esthetics, the importance of continuing education, career options beyond graduation, and the value of AACD Accreditation.

Student Poster Sessions

Held in conjunction with the Annual AACD Scientific Session, the Academy recognizes deserving students and postgrads who demonstrate their unique perspective in cosmetic dentistry. Cash prizes awarded each year.



Special, Discounted Membership Rate

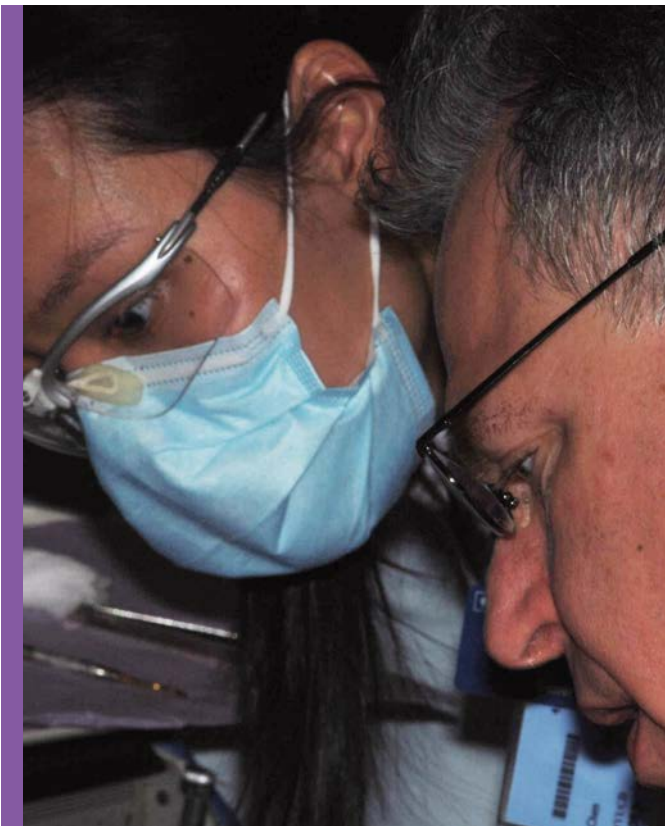
Dental students: \$60/year
Full-time dental faculty: \$135/year

Visit www.aacd.com/students to learn more about starting your dental career on the right foot.

The "Crown Jewel"

The Undergraduate Honors in Aesthetic Dentistry Program at NYU's College of Dentistry

John R. Calamia, DMD



I believe that the "crown jewel" of the New York University College of Dentistry (NYUCD) undergraduate esthetic dental curriculum is the Honors in Aesthetic Dentistry program, currently available to only 20 (of 370) fourth-year students. It is essentially a clinical concentration course in esthetic dentistry.

The students in this program devote one full day per week to multi-unit treatment. Not only do they address patients' functional and physiologic needs, but they also include in their initial treatment planning an esthetic component that is commonly considered in current practice as the key aspect in excellence in dental care. Thanks to a well-trained and dedicated cadre of faculty (and a faculty-to-student ratio that is often 1:3 or better), these students have proved to be very capable of producing work of consistently high quality.

As director of esthetic dentistry in the Department of Cariology and Comprehensive Care, I, as well as the rest of the esthetics-conscious faculty, am involved in numerous aspects of the NYU undergraduate curriculum. These include lecturing first-year students about dental anatomy (taught with white wax instead of blue to allow students to begin to understand diagnostic esthetic wax-ups) and about dental caries and its effect on esthetics; and providing second-year students with preclinical training in smile evaluation, diagnostic wax-ups, design and preparation of anterior porcelain veneers and posterior ceramics, and CAD/CAM design in fabrication of inlays, onlays, and crowns. In addition to instruction, students also receive a certificate related to their training in Invisalign in their second year.

Our advanced restorative lecture series for third-year students includes such topics as treatment plan options and case presentations involving other disciplines, esthetics implications in implants, periodontal conditions, endodontic implications, and the needs of geriatric patients.

In addition, third- and fourth-year students are asked (using the medical model) to present their patients' initial workups and lists of problems to their fellow students and faculty in group practice seminars. Everyone works together to diagnose patients' problems and develop a treatment plan and sequence of treatment. Therefore, students and faculty alike all learn from each case.

Thanks to NYUCD's administrators allowing our undergraduate curriculum to impart the critical value of esthetics in all disciplines of clinical dentistry, we have prepared our graduates with a jumping-off point in their pursuit of further knowledge in esthetic dentistry. We have whet their appetite for clinical excellence so that they seek further training in university-based continuing education, specialty training, and other postgraduate training provided by private learning institutions and educational organizations such as the AACD.

It is no accident that recent dental undergraduates and graduates flocked to the AACD Annual Scientific Session in Orlando in 2014 and that AACD's membership is gradually getting younger.

More and more universities are realizing that the AACD is steadfast in its commitment to responsible esthetic dentistry and that the AACD has assumed the obligation to continue the education of our newest generation of dentists. At the annual AACD University Forum, universities worldwide find a helping hand. Educators from schools further along in their esthetic curriculum speak and answer questions from educators from schools that still need to progress. There is no room for a "We are better than you are attitude"; rather, a spirit of "What can we do to help each other get better?" permeates these discussions.

I invite you to read NYU's student feature article beginning on page 96. The primary author, Dr. Andi-Jean Miro, is an excellent representative of undergraduate dental

education at NYU. Dr. Miro knew, from her second year, that she wanted to learn more about esthetic dentistry. In her third year, she served as a dental assistant for fourth-year students in NYU's Undergraduate Honors in Aesthetic Dentistry program. In her fourth year she began her own Honors term. This exceptional then-student (a 2014 graduate of NYUCD) was an officer in the NYU Aesthetic Club, in addition to many other accomplishments, including the following:

- Recipient of a 2014 AACD APEX award, presented to students who describe (in essay format) why esthetic dentistry is an important component of their dental education.
- Winner of the 2014 AACD Clinical Award for the best clinical case (in poster format) submitted by a senior dental student.
- First Place in the AACD International Poster Competition at AACD Orlando 2014 in the category, "Undergraduate Clinical Case."

Dr. Miro also delivered a PowerPoint presentation of her winning poster to her undergraduate and graduate dental student colleagues during AACD Orlando 2014.

Finally, I would like to thank *jCD* Editor-in-Chief Dr. Edward Lowe for inviting NYUCD's participation in this special Academic Issue of the *jCD*.



...we have prepared our graduates with a jumping-off point in their pursuit of further knowledge in esthetic dentistry.



Dr. Calamia is professor and director of Aesthetic Dentistry, Department of Cariology and Comprehensive Care, New York University College of Dentistry. He also is a university representative on the AACD Board of Directors and chairman of the AACD University Relations Committee.

Disclosure: The author did not report any disclosures.

Photo credits: The jCD thanks New York University for the use of their photos in this editorial.

Esthetic Smile Design

A Multidisciplinary Approach to Diastema Closures

Andi-Jean Miro, DDS
Jill Varriale, DMD
John R. Calamia, DMD

Abstract

Dental students and practitioners alike should develop treatment strategies focused on providing patients with functional, physiologic, and esthetic restorations. Although this is the foundation for proper treatment, the aspect of esthetics is frequently not considered a high priority. As dental standards rise, greater emphasis is being placed upon esthetics along with functionality. Esthetics can be considered the difference between good dental care and dental excellence. The modern dentist must navigate between various types of restorative options, smile guidelines, and patient preferences to meet patient expectations and achieve exceptional esthetic results.

Key Words: multidisciplinary, treatment planning, ceramics, esthetics



After reading this article, the participant should be able to:

1. Understand the advantages of multidisciplinary treatment planning.
2. Appreciate the benefits of utilizing a smile evaluation form.
3. Follow a structured systematic approach to esthetic treatment beginning with the desired endpoint in mind.

To achieve the desired esthetic results, a combination of dental modalities was deemed necessary and included orthodontics, implant therapy, and restorative treatment. ”



Introduction

In the following case, a comprehensive treatment plan was created to address the chief concerns of the patient, who was a first-year dental student. The initial treatment plan was completed with the use of a smile evaluation form (Figs 1 & 2).^{1,2} To achieve the desired esthetic results, a combination of dental modalities was deemed necessary and included orthodontics, implant therapy, and restorative treatment. After the orthodontic treatment was accomplished a new smile evaluation form was completed to help determine the appropriate final treatment plan. Lastly, the final restorations were placed. By using multiple benchmarks—such as the smile evaluation forms and revisions of provisionals—to gauge patient preferences, the clinicians were ultimately able to achieve an esthetic result that exceeded the patient's expectations.

Chief Complaint

The patient was first seen for a restorative consultation in her first year of dental school. The consult was provided by the Undergraduate Honors in Aesthetic Dentistry Program at the NYU College of Dentistry (NYUCD). The smile evaluation form was used as an adjunct to radiographs, photographs, and study casts to determine possible treatment plans to address the patient's chief complaint. She had already been through much of the first-year dental curriculum and realized that she wanted to "close all the spaces on both the upper and lower arches and make them whiter" (Figs 3-6). The patient had heard about porcelain veneers and thought she could address all of her esthetic concerns with these "simple restorations." As a future dentist she wanted to exemplify to her patients the importance of having a beautiful smile.

In the Honors Aesthetic Clinic, all treatment begins with carefully listening to and understanding the patient's esthetic goals, followed by detailed records to visualize the path to the end result. According to Spear and Kokich, "If the treatment planning sequence proceeds from biology to structure to function and finally to esthetics, the eventual esthetic outcome may be compromised."^{3,4} This philosophy has been embraced by the Undergraduate Honors in Aesthetic Dentistry Program, such that each case begins with esthetics

NYU College of Dentistry Smile Evaluation Form

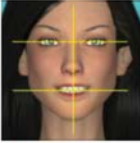
Patient Name: _____ Chart #: _____ Date: _____ Faculty Start Sig: _____ #: _____

Are you happy with the way your teeth appear when you smile? **YES** **NO** (circle one)
If NO, what is it about your smile you would like to change? _____

Patients requests and expectations: _____

Preferences: White Aligned Teeth Natural Teeth with Slight Irregularities

Facial Analysis




Lips
 Thick
 Medium
 Thin

Inter-Pupillary line
 Normal Slanted down RT LT

Commissural line
 Normal Slanted down RT LT

Facial midline
 Normal Off to Patients RT LT

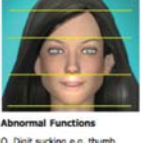


E-plane
Max ____ mm
Min ____ mm

Nasal-Labial
 > 90 degrees
 < 90 degrees
 = 90 degrees

Skeletal Pattern Profile
 Skeletal Class I Normal
 Skeletal Class II Convex
 Skeletal Class III Concave

Occlusion/Orthodontic Evaluation



UFH/LFH
Lower Facial Height [Sn-Me]
 WNL
 Excess
 Deficient

Abnormal Functions
 Digit sucking e.g. thumb
 Object biting/sucking
 Tongue Thrust Swallow
 Grinding / Bruxism
 Lip sucking/biting
 Mouth breathing
 Clenching
 Other _____

Midline
 Upper and lower midlines coincide with the facial midline
 Upper dental midline is deviated to the R L (circle)
 Lower dental midline is deviated to the R L (circle)

Overbite
 WNL (0-10%) Moderate (11-69%) Severe (70-100%)
 Anterior Crossbite Dental Skeletal


Overjet
 WNL (1-2 mm) Moderate (3-5mm) Severe (more than 5mm)


Maxillary
 Crowding Spacing
 Anterior Crossbite Dental Skeletal


Mandibular
 Crowding Spacing
 Skeletal Functional shift


Classification of Occlusion/ Malocclusion
 Normal Occlusion C I Malocclusion
 C II Div 1 C II Div 2 C I

Phonetic Analysis

M  **"M" Sound**
Space between lips visible
Max ____ mm
Mand ____ mm

E  **"E" Sound**
Interlabial space occupied by maxillary teeth
 < 80%
 > 80%

S  **"S" Sound**
 Normal
 Lip
 S - Sound Deficiency

FV  **"F" & "V" Sounds**
Max. Incisor in relation to lower lip
Edge ____ mm to lip


Swallowing 
 Normal
 Abnormal

Figure 1: Smile evaluation form, page 1.

in mind, followed by the function, structure, and physiology that would be required to achieve the best possible esthetic result. After filling in this patient's smile evaluation form it became apparent that, to produce an excellent esthetic result, orthodontic and implant components had to be considered, contrary to the patient's assumption that her case would be just a "simple restorative process."

Facial Analysis

The facial analysis utilized the smile evaluation form (Fig 7). The patient presented with a normal horizontal interpupillary line and commissural line. From the profile, her face was slightly convex. When analyzing from the profile in relation to Dr. Robert Ricketts' esthetic plane (an imaginary line drawn from the tip of the nose to the tip of the chin),⁵ her maxillary lip appeared 5 mm from the plane and her mandibular lip appeared to be 3 mm from the plane. Her nasiolabial angle appeared greater than 90 degrees.

Occlusal Analysis

The occlusal analysis (Fig 8) also utilized the smile evaluation form. The patient's facial midline was normal and was coincidental with her mandibular dental midline; her maxillary dental midline was 1 mm to the right of the facial midline. Her lower-third facial height was slightly larger than the other thirds of her face. The patient denied any parafunctional or dysfunctional habits. She had an end-on overbite and overjet, with several teeth in cross bite. Her maxillary arch was U-shaped and symmetric, with 8 mm of spacing. Her mandibular arch was also U-shaped but asymmetric, with 13 mm of spacing including a missing mandibular right first molar, which had been extracted when she was a child. Following this analysis the patient was referred to the NYUCD Orthodontic Department for a consultation and comprehensive orthodontic workup.

Anterior Dental Analysis		Dental-facial Analysis	
Mark any irregularities on the diagram for maxillary dentition		Mark any irregularities on the diagram for mandibular dentition	
		Horizontal and Vertical Components	
		Tooth lower lip position	<input type="radio"/> Touching <input type="radio"/> Not touching <input type="radio"/> Slightly covered
		Lip line	<input type="radio"/> Normal <input type="radio"/> LOW <input type="radio"/> <2-3mm ging. seen <input type="radio"/> HIGH
		Midline - Relationship of central incisors to philtrum	<input type="radio"/> Centered <input type="radio"/> Off to pts. right <input type="radio"/> Off to pts. left
		Midline - Canting to right or left	<input type="radio"/> Normal <input type="radio"/> To pts. right <input type="radio"/> To pts. left
		Teeth exposure during physiologic rest position	<input type="radio"/> Average <input type="radio"/> Full <input type="radio"/> Little or no exposure
		Smile line (maxillary incisal edge relation to superior border of lower lip)	<input type="radio"/> Convex <input type="radio"/> Straight <input type="radio"/> Reverse
		Number of teeth exposed in a full smile	<input type="radio"/> 6 <input type="radio"/> 8 <input type="radio"/> 10 <input type="radio"/> 12
		Buccal corridor (bilateral negative space)	<input type="radio"/> Normal <input type="radio"/> Deficient <input type="radio"/> Full
MAXILLARY TEETH	MANDIBULAR TEETH	MAXILLARY TEETH	MANDIBULAR TEETH
Axial Inclination	Axial Inclination	Axial Inclination	Axial Inclination
<input type="radio"/> Normal <input type="radio"/> Abnormal	<input type="radio"/> Normal <input type="radio"/> Abnormal	<input type="radio"/> Normal <input type="radio"/> Abnormal	<input type="radio"/> Normal <input type="radio"/> Abnormal
Drawing Checklist:	Drawing Checklist:	Drawing Checklist:	Drawing Checklist:
Facial Contour	Facial Contour	Facial Contour	Facial Contour
<input type="radio"/> Normal <input type="radio"/> Abnormal	<input type="radio"/> Normal <input type="radio"/> Abnormal	<input type="radio"/> Normal <input type="radio"/> Abnormal	<input type="radio"/> Normal <input type="radio"/> Abnormal
Golden Proportion	Golden Proportion	Golden Proportion	Golden Proportion
<input type="radio"/> Normal <input type="radio"/> Abnormal	<input type="radio"/> Normal <input type="radio"/> Abnormal	<input type="radio"/> Normal <input type="radio"/> Abnormal	<input type="radio"/> Normal <input type="radio"/> Abnormal
Incisal Embrasures	Incisal Embrasures	Incisal Embrasures	Incisal Embrasures
<input type="radio"/> Normal <input type="radio"/> Blurred <input type="radio"/> Abnormal	<input type="radio"/> Normal <input type="radio"/> Blurred <input type="radio"/> Abnormal	<input type="radio"/> Normal <input type="radio"/> Blurred <input type="radio"/> Abnormal	<input type="radio"/> Normal <input type="radio"/> Blurred <input type="radio"/> Abnormal
Tooth Spacing	Tooth Spacing	Tooth Spacing	Tooth Spacing
<input type="radio"/> WNL <input type="radio"/> Crowded <input type="radio"/> Diastemata	<input type="radio"/> WNL <input type="radio"/> Crowded <input type="radio"/> Diastemata	<input type="radio"/> WNL <input type="radio"/> Crowded <input type="radio"/> Diastemata	<input type="radio"/> WNL <input type="radio"/> Crowded <input type="radio"/> Diastemata
Gingival Zenith	Gingival Zenith	Gingival Zenith	Gingival Zenith
<input type="radio"/> Normal <input type="radio"/> Irregular	<input type="radio"/> Normal <input type="radio"/> Irregular	<input type="radio"/> Normal <input type="radio"/> Irregular	<input type="radio"/> Normal <input type="radio"/> Irregular
Gingival Papilla	Gingival Papilla	Gingival Papilla	Gingival Papilla
<input type="radio"/> Normal <input type="radio"/> Blurred	<input type="radio"/> Normal <input type="radio"/> Blurred	<input type="radio"/> Normal <input type="radio"/> Blurred	<input type="radio"/> Normal <input type="radio"/> Blurred
Gingival Biotype	Gingival Biotype	Gingival Biotype	Gingival Biotype
<input type="radio"/> Thick <input type="radio"/> Thin	<input type="radio"/> Thick <input type="radio"/> Thin	<input type="radio"/> Thick <input type="radio"/> Thin	<input type="radio"/> Thick <input type="radio"/> Thin

The smile evaluation form was used as an adjunct to radiographs, photographs, and study casts to determine possible treatment plans to address the patient's chief complaint. ”

Figure 2: Smile evaluation form, page 2.



Figure 3: Initial full-face image.

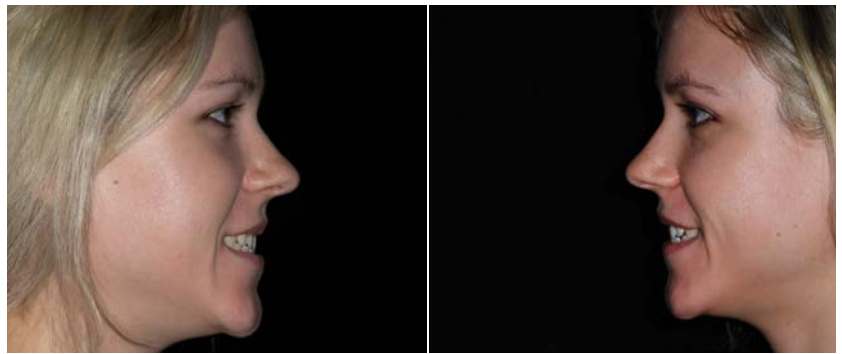


Figure 4: Initial profile (right and left).

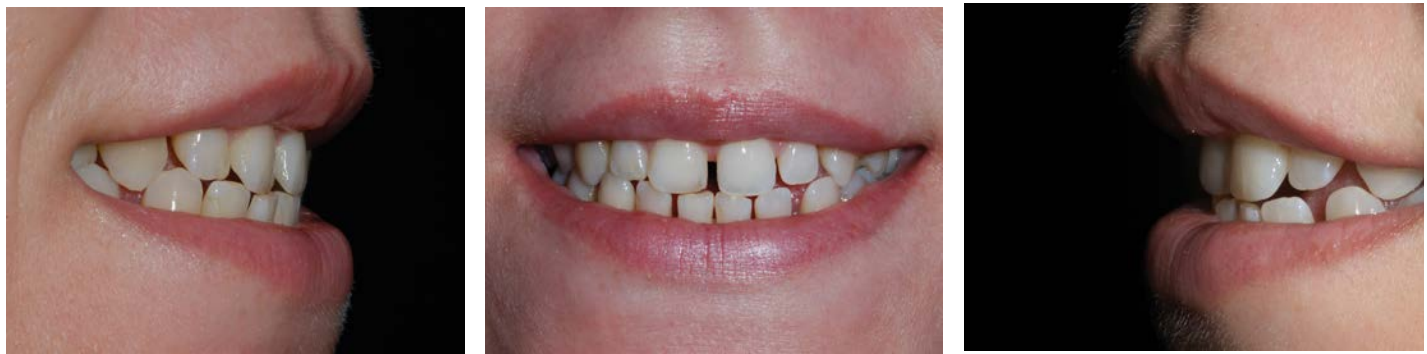

Figure 5: Initial smile, non-retracted.

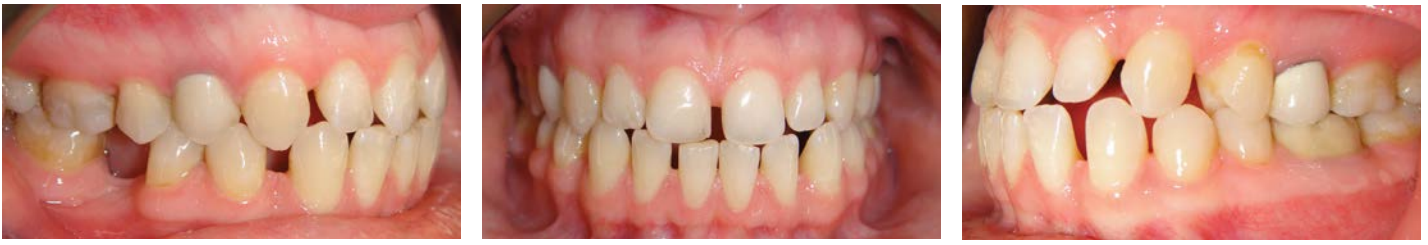

Figure 6: Initial retracted image.

NYU College of Dentistry Smile Evaluation Form

Patient Name: _____ Chart #: _____ Date: _____ Faculty Start Sig: _____ #: _____

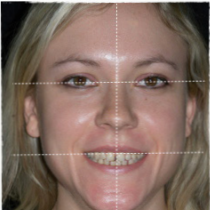
Are you happy with the way your teeth appear when you smile? YES **NO** (circle one)

If NO, what is it about your smile you would like to change? *"I would like to close the spaces and fix my smile"*

Patients requests and expectations: *"I want pretty, natural looking teeth"*

Preferences: White Aligned Teeth Natural Teeth with Slight Irregularities

Facial Analysis

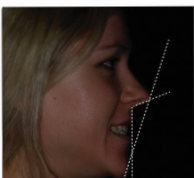


Lips
 Thick
 Medium
 Thin

Inter-Pupillary line
 Normal Slanted down RT LT

Commissural line
 Normal Slanted down RT LT

Facial midline
 Normal Off to Patients RT LT




E-plane
 Max 5 mm
 Man 3 mm

Nasal-Labial
 > 90 degrees
 < 90 degrees
 = 90 degrees

Skeletal Pattern
 Skeletal Class I
 Skeletal Class II
 Skeletal Class III

Profile
 Normal
 Convex
 Concave

Occlusion/Orthodontic Evaluation



UFH/LFH
 Lower Facial Height [Sn-Me]
 WNL
 Excess
 Deficient

Abnormal Functions
 Digit sucking e.g. thumb
 Object biting/sucking
 Tongue Thrust Swallow
 Grinding / Bruxism
 Lip sucking/biting
 Mouth breathing
 Clenching
 Other _____

Midline
 Upper and lower midlines coincide with the facial midline
 Upper dental midline is deviated to the **(R)** L (circle)
 Lower dental midline is deviated to the R **(L)** (circle)

Overbite
 WNL [0-30%] Moderate [31-69%] Severe [70-100%]
 Anterior Open Bite _____ mm Dental Skeletal


Overjet
 WNL [1-2 mm] Moderate [3-5mm] Severe [more than 5mm]


Maxillary
 Crowding Spacing
 Anterior Crossbite Dental
 Posterior Crossbite R or L Dental Skeletal


Mandibular
 Crowding Spacing
 Skeletal Functional shift
 Skeletal Functional shift


Classification of Occlusion/ Malocclusion
 Normal Occlusion CI I malocclusion
 CI II Div 1 CI II Div 2 CI

Phonetic Analysis

M  **"M" Sound**
 Space between lips visible
 Max 3 mm
 Mand 2 mm

E  **"E" Sound**
 Interlabial space occupied by maxillary teeth
 ≤80%
 >80%

S  **"S" Sound**
 Normal
 Lisp
 S - Sound Deficiency

FV  **"F" & "V" Sounds**
 Max. Incisor in relation to lower lip
 Edge 2 mm to lip


Swallowing
 Normal
 Abnormal 

Figure 7: Patient's initial smile evaluation form.

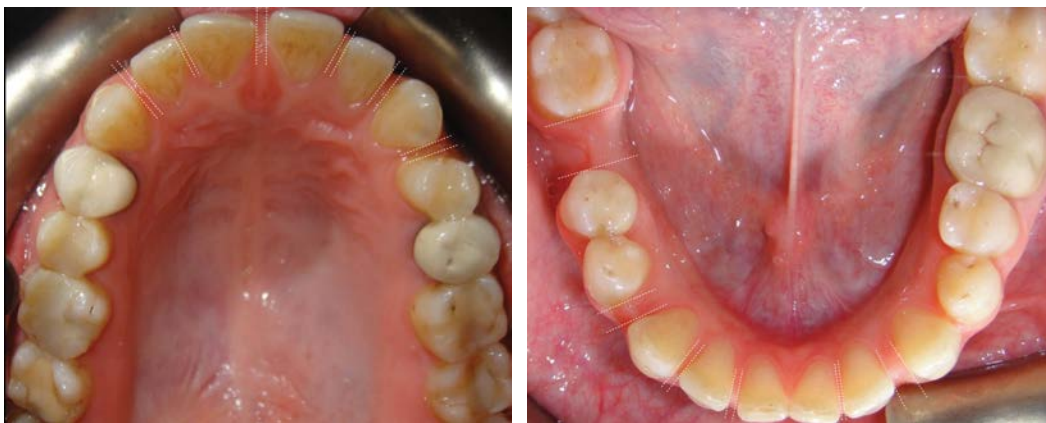


Figure 8: Occlusal analysis.

Orthodontic Analysis and Treatment

The patient presented to the orthodontic clinic and was evaluated using orthodontic parameters including diagnostic photographs, models, lateral cephalometrics, and panoramic imaging (Fig 9). The patient had a symmetric face, competent lips, and an orthognathic straight profile. Her molar angle classification was Class III on the left side and was unclassified on the right side due to the missing mandibular right first molar. Her right canine was Class I and left canine was super Class I. She had generalized spacing with 8 mm in the maxillary and 13 mm in the mandibular. Her overbite was end-on with 0 mm of overjet.

Cephalometric analysis revealed a Class I skeletal pattern with a normodivergent profile, and proclined maxillary incisors and mandibular incisors that were within normal limits. Primary considerations for this orthodontic treatment were the shallow overjet and overbite.

The patient had a tooth size discrepancy; her maxillary incisors were small and closing them would not yield a desired esthetic result. Alternatively, closing the spaces on the maxillary and mandibular arches would yield a Class III malocclusion with an anterior crossbite. Lastly, retroclining the dentition would have yielded a concave facial profile, which would exacerbate with age.

Orthodontics

The objectives and goals of the orthodontic phase were to level and align both arches, achieve Class I canine relationships, maintain molar relationships, close the spaces on the mandibular arch using an elastic chain and sliding mechanics, open space for an implant using an open NiTi coil spring (Dentsply; York, PA), distribute the spaces evenly on the maxillary arch while coinciding the midlines, and develop an overjet and overbite in an ideal position for the veneer preparations. First, the mandibular arch was bonded with brackets and arch wire. This was completed in order to retract the lower incisors, and straighten and retrocline the anterior segment (Fig 10). Once this was accomplished the maxillary arch was bonded with brackets and treatment continued (Fig 11).

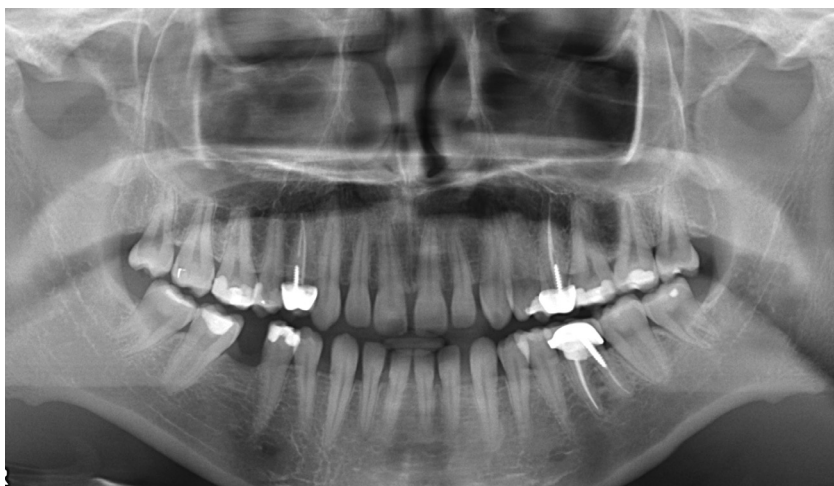
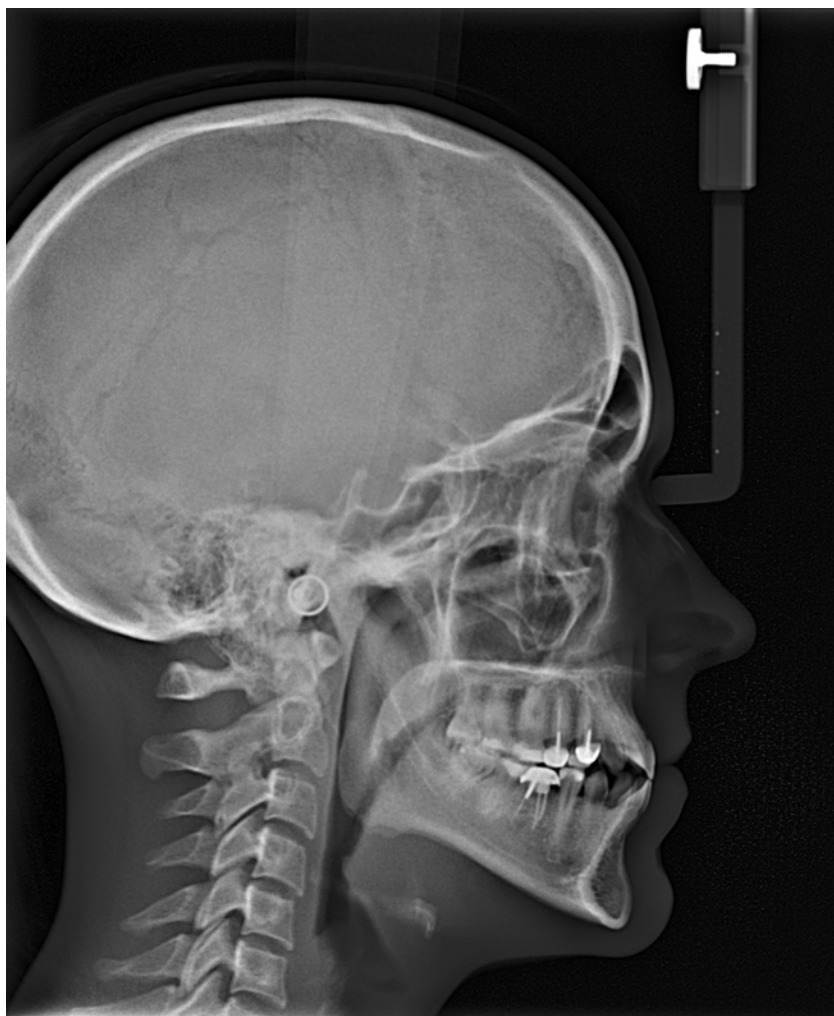

Figure 9: Lateral cephalometric and panoramic imaging, pre-orthodontics.

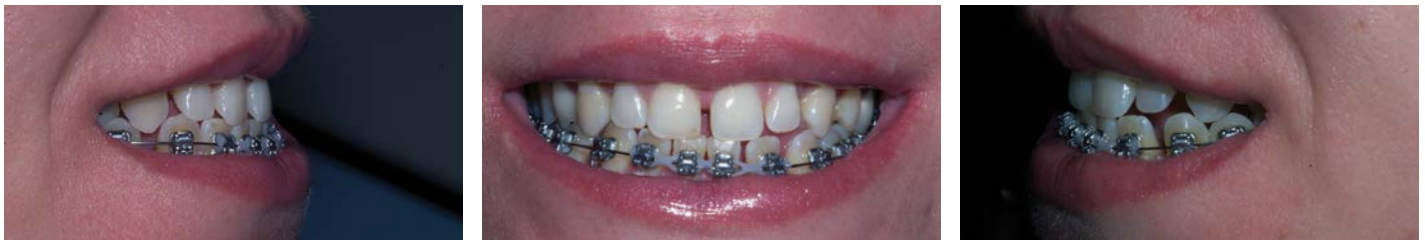

Figure 10: Phase One of orthodontics.

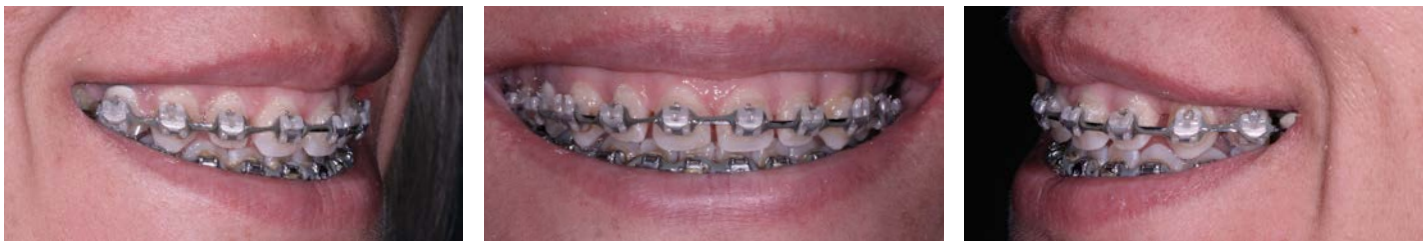

Figure 11: Phase Two of orthodontics.

This case emphasizes the importance of communication and collaboration between the orthodontist and restorative dentist. Orthodontics alone may focus on a final outcome that has all spaces eliminated, while a different set of diagnostic parameters utilized by the restorative dentist may require a specified amount of balanced spacing to allow adequate space for restorations. The orthodontist and Honors in Aesthetic Dentistry team periodically consulted each other to make sure the orthodontic treatment would end at an adequate position for the restorative treatment to begin.

Reevaluation Post-Orthodontics

After 20 months of orthodontic treatment it was determined that the maxillary spacing was adequate and the brackets and arch wire were ready for removal (Figs 12-14). Upon completion of orthodontic treatment, the patient was given a maxillary Essix retainer (Dentsply) to wear full time until the restorative aspect of treatment began. A fixed lingual arch wire retainer bonded with composite was placed from canine to canine on the mandibular arch. In the posterior region, in the area of the missing lower right first molar, brackets were kept on #29 and #31 along with a fixed space maintainer with a closed coil. This space was to be maintained for future implant placement as well as during the four months of integration following the placement of the implant, to eliminate relapse or loss of space (Fig 15).



Figure 12: Post-orthodontics, full face.

This case emphasizes the importance of communication and collaboration between the orthodontist and restorative dentist. ”

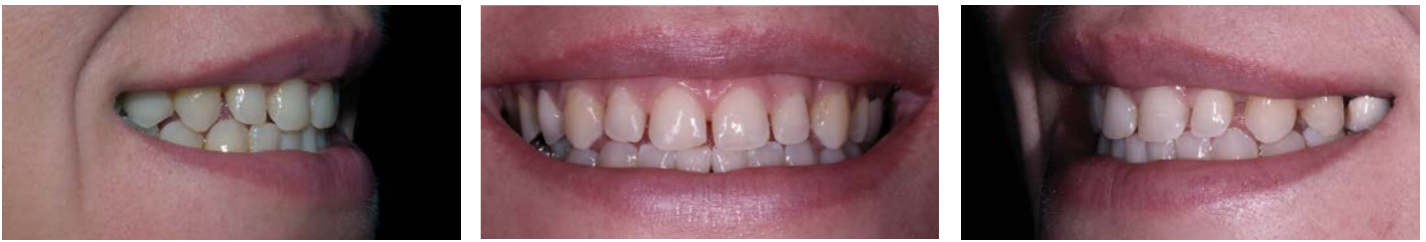

Figure 13: Post-orthodontics smile, non-retracted.

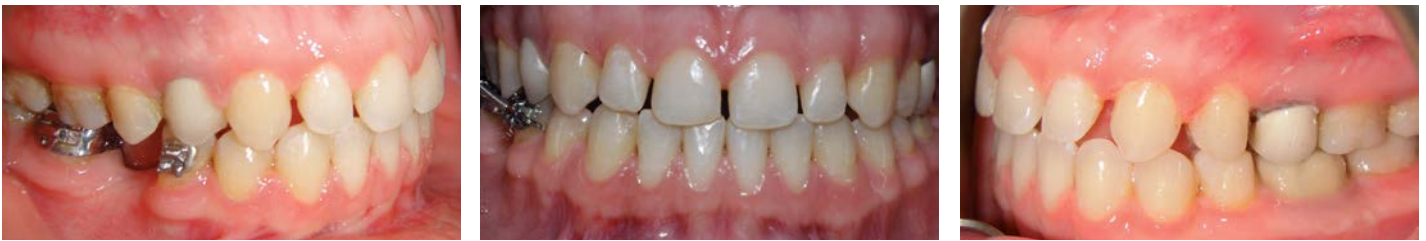

Figure 14: Post-orthodontics, retracted.

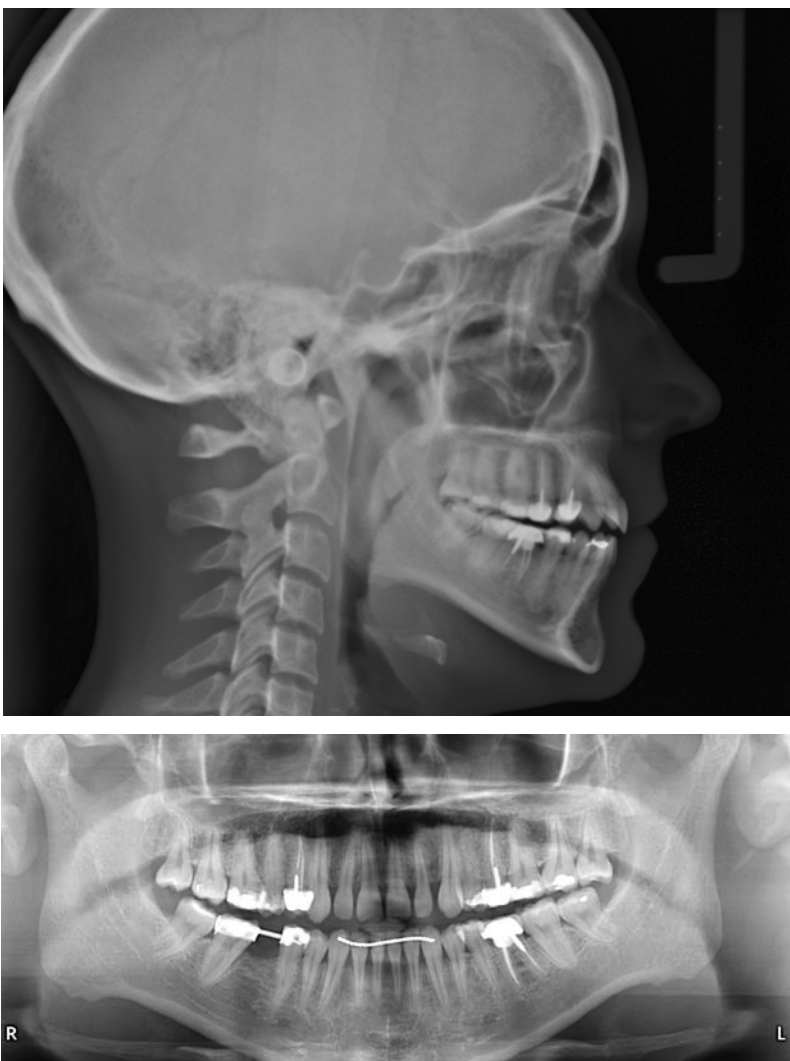


Figure 15: Lateral cephalometric and panoramic imaging, post-orthodontics.

On the mandibular arch, all of the spaces were closed while maintaining the midline. The maxillary midline was approximately 0.5 mm off the facial midline. It was determined that it could easily be corrected to coincide the facial midline with the final restorations and did not warrant additional orthodontic treatment. Adequate overbite and overjet were created. The axial inclinations were satisfactory but not ideal. Teeth #7, #9, and #10 were slightly distally inclined but did not require a continuation of orthodontic treatment as they would be corrected when the final restorations were placed.

Finalized Treatment Plan

Once the braces were removed a new smile evaluation form was completed (Fig 16), new diagnostic models were created, and a diagnostic pre-therapeutic wax-up was fabricated (Fig 17). This wax-up would serve multiple purposes. First it would act as a blueprint for treatment. From a duplicate model, a buccal reduction guide, incisal reduction guide, and a temporary matrix (Fig 18) were fabricated from vinyl polysiloxane (VPS) impression material (Reprosil, Dentsply) to be used during preparation. The patient had a full buccal corridor and wanted to achieve a full and uniform maxillary shade change utilizing the final restorations. It was determined that, to reach the

NYU College of Dentistry Smile Evaluation Form

Patient Name: _____ Chart #: _____ Date: _____ Faculty Start Sig: _____ #: _____

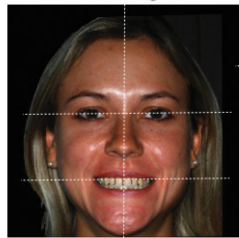
Are you happy with the way your teeth appear when you smile? **YES** **NO** (circle one)

If NO, what is it about your smile you would like to change? *"I would like to close the spaces and fix my smile"*

Patients requests and expectations: *"I want pretty, natural looking teeth"*

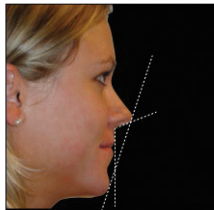
Preferences: White Aligned Teeth Natural Teeth with Slight Irregularities

Facial Analysis



- Lips**
- Thick
 - Medium
 - Thin

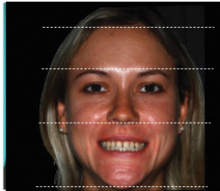- Inter-Pupillary line**
 Normal Slanted down RT LT
- Commissural line**
 Normal Slanted down RT LT
- Facial midline**
 Normal Off to Patients RT LT



- E- plane**
- Max 5 mm
 - Man 3 mm
- Nasal-Labial**
- > 90 degrees
 - < 90 degrees
 - = 90 degrees

- Skeletal Pattern**
- Skeletal Class I
 - Skeletal Class II
 - Skeletal Class III
- Profile**
- Normal
 - Convex
 - Concave

Occlusion/Orthodontic Evaluation



- UFH/LFH**
 Lower Facial Height [Sn-Me]
- WNL
 - Excess
 - Deficient

- Abnormal Functions**
- Digit sucking e.g. thumb
 - Object biting/sucking
 - Tongue Thrust Swallow
 - Grinding / Bruxism
 - Lip sucking/biting
 - Mouth breathing
 - Clenching
 - Other _____

- Midline**
- Upper and lower midlines coincide with the facial midline
 - Upper dental midline is deviated to the **(R)** L (circle)
 - Lower dental midline is deviated to the R **L** (circle)

- Overbite**
- WNL [0-30%]
 - Moderate [31-69%]
 - Severe [70-100%]
- Anterior Open Bite _____ mm Dental Skeletal

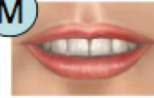- Overjet**
- WNL [1-2 mm]
 - Moderate [3-5mm]
 - Severe [more than 5mm]

- | | | | |
|--|--|--------------------------------|--|
| Maxillary | <input checked="" type="radio"/> Spacing | Mandibular | <input type="radio"/> Spacing |
| <input type="radio"/> Crowding | <input type="radio"/> Dental | <input type="radio"/> Crowding | <input type="radio"/> Skeletal |
| <input type="radio"/> Anterior Crossbite | <input type="radio"/> Dental | <input type="radio"/> Skeletal | <input type="radio"/> Functional shift |
| <input type="radio"/> Posterior Crossbite R or L | <input type="radio"/> Dental | <input type="radio"/> Skeletal | <input type="radio"/> Functional shift |

- Classification of Occlusion/ Malocclusion**
- Normal Occlusion
 - CI I malocclusion
 - CI II Div 1
 - CI II Div 2
 - CI

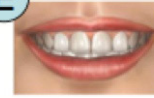Phonetic Analysis

(M)



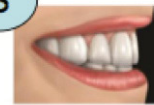- "M" Sound**
- Space between lips visible
- Max 3 mm
- Mand 2 mm

(E)



- "E" Sound**
- Interlabial space occupied by maxillary teeth
- < 80%
 - > 80%

(S)



- "S" Sound**
- Normal
 - Lisp
 - S - Sound Deficiency

(FV)



- "F" & "V" Sounds**
- Max. Incisor in relation to lower lip
- Edge 2 mm to lip

Swallowing

- Normal
- Abnormal

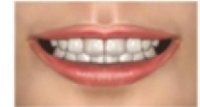

Figure 16: New smile evaluation form.

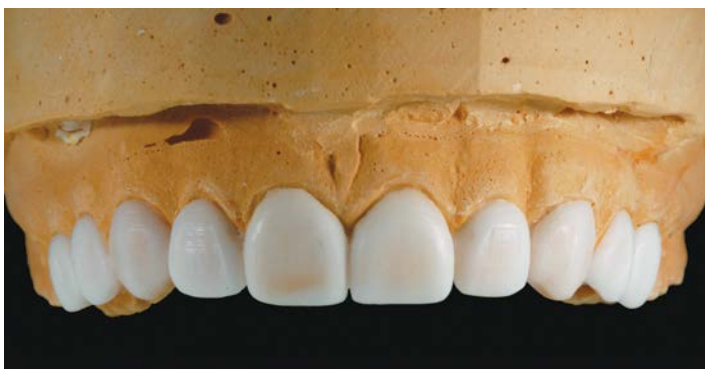

Figure 17: Diagnostic wax-up.



Figure 18: Matrixes.

It was paramount to the patient that the preparations be as minimally invasive as possible.”

patient's ideal esthetic goals, ##4-13 had to be treated. Teeth #5 and #13 had previously been treated using porcelain-fused-to-metal crowns. The final planned restorations would consist of eight feldspathic porcelain veneers and two lithium disilicate crowns. Two weeks prior to preparation of the maxillary arch, the mandibular arch was bleached in office (Zoom Whitening, Philips Oral Healthcare; Stamford, CT) to better match the future maxillary restorations. After insertion of all restorations, retention was achieved using a clear Essix retainer.

Implant

Post-orthodontics and prior to the restorative aspect of the case a cone beam computed tomography (CBCT) was studied. Based upon the CBCT it was determined that the patient had a knife-edge ridge and that there would be sufficient space to augment the ridge and place an implant. A tapered 4.3 x 10-mm implant was placed (Nobel Biocare; Kloten, Switzerland) with healing cap; this was in place for five months along with the brackets and closed coil to maintain the space until the implant was to be restored (Fig 19).

Preparation and Provisionalization

It was paramount to the patient that the preparations be as minimally invasive as possible. This was considered in the beginning of the treatment plan, which was why the patient opted for orthodontic therapy. Conservative enamel-sparing preparation design yields restorations with a maximum longevity.⁶ Bond strengths of resin cements to enamel are higher than to dentin, which contributes to the increased longevity and higher predictability in conservative preparations.^{3,4}

Teeth ##4-13 were prepared on the facial with a 0.5-mm depth-cutting bur (Rosenthal Apa Bur Block 5007901U0, Brasseler USA; Savannah, GA). Since we wanted to achieve a longer appearance, we were able to have a very minimal incisal preparation. Preparation finish lines were refined with chamfer on the facial at the level of the free gingival margin (Two Striper Diamond #799, Primer Dental; Plymouth Meeting, PA). It is important to note that interproximally the teeth were not finished with a chamfer but rather prepared straight through, removing any undercut and without a definitive finish line (Fig 20). The preparations were impressed with medium- and light-body VPS impression material (Aquasil Ultra, Dentsply). Provisional restorations were fabricated utilizing the putty matrix (Dentsply) from the diagnostic wax-up and using Luxatemp and Luxaflow shade B1 (DMG America; Englewood, NJ). The provisional restorations were considered a "test drive" for the patient. Adjustments were made 24 hours after initial insertion; photographs were taken and models made when the patient was satisfied (Fig 21). Photographs and diagnostic impressions of the provisional restorations were taken and analyzed, and desired changes were communicated to the dental laboratory.

Laboratory Fabrication

Feldspathic porcelain veneers were selected as the restorative material because it is the most esthetic restorative material and also requires the least amount of tooth reduction.⁷ Lithium disilicate was selected as the crown material because of its strength and esthetic qualities. Photographs of the maxillary preparation shade and final shade after bleaching of the mandibular arch were taken into consideration when selecting the final shade of the maxillary restorations.

The eight feldspathic veneers were fabricated on dies that were first overlaid with platinum foil. Using enamel ceramics (Softspar Creation, Pentron; Orange, CA) of different translucencies, a final product was created. The cores for the two lithium disilicate crowns were milled using CAD/CAM milling technology. Feldspathic porcelain was added to the core of the crowns when the veneers were fabricated. The veneers were created using different dentin and enamel shades to achieve optimal esthetics and match the shade of the mandibular teeth. The veneers and crowns were glazed, the platinum foil was removed from the veneers, and then the restorations were etched with hydrofluoric acid (Tri-Dynamics Gel for Ceramics, Patterson Dental; St. Paul, MN) prior to being delivered for insertion.

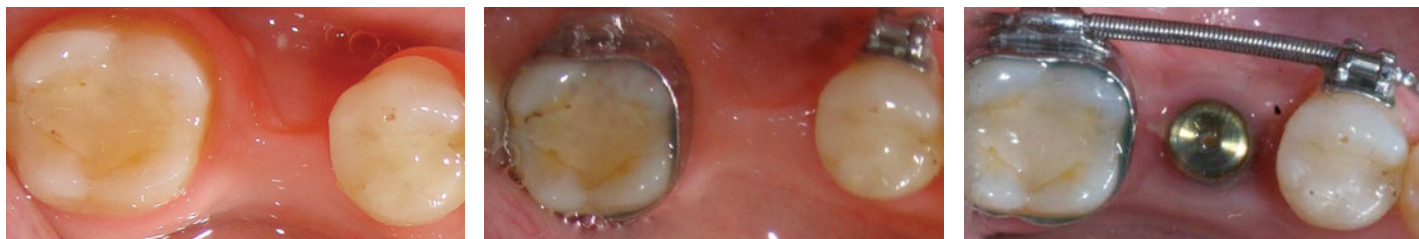


Figure 19: Pre-orthodontic space, post-orthodontic space, post-implant placement.

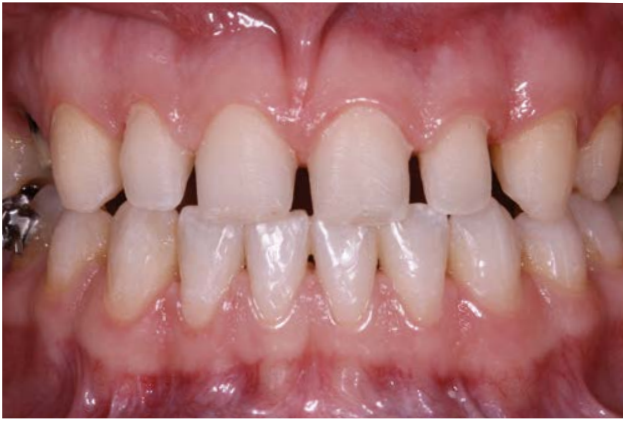

Figure 20: Preparations.

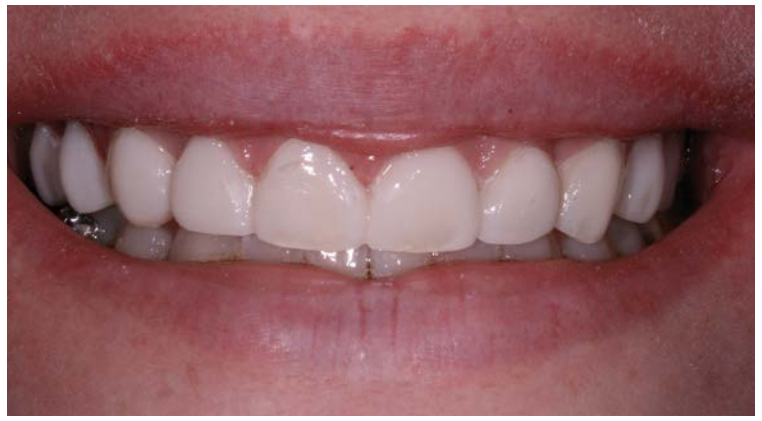

Figure 21: Provisionals.

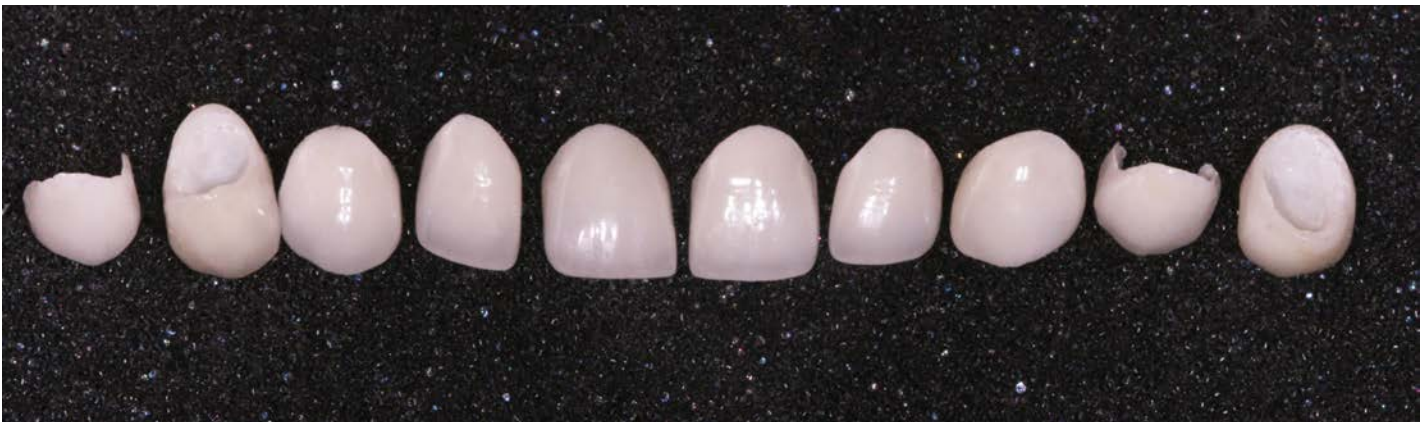

Figure 22: Restorations prior to insertion.

While every practitioner may plan a case in a different way, it is important to keep the esthetic outcome at the forefront of the treatment plan. ”

Insertion

Upon delivery from the laboratory (DSG Americus Dental Laboratory; Queens, NY), the restorations were examined on the master cast for fit, integrity, accuracy, and consistency of shade (Fig 22). The patient was scheduled to return and the provisionals were removed, preparations were cleaned, rinsed and dried, and the restorations were tried in. An Optragate (Ivoclar Vivadent; Amherst, NY) was placed to retract the lips and keep a controlled, moisture-free, uncontaminated field. The restorations were tried in with water placed on the internal aspect of the veneers. This allowed us to visualize the margin integrity, fit, contour, length, and shade of all restorations prior to inserting them permanently. The parameters were evaluated and it was determined that the shade did not require any alteration for insertion, so a translucent shade of luting resin (Choice 2, Bisco; Schaumburg, IL) was used to place the restorations.




Figure 23: Postoperative full-face image.

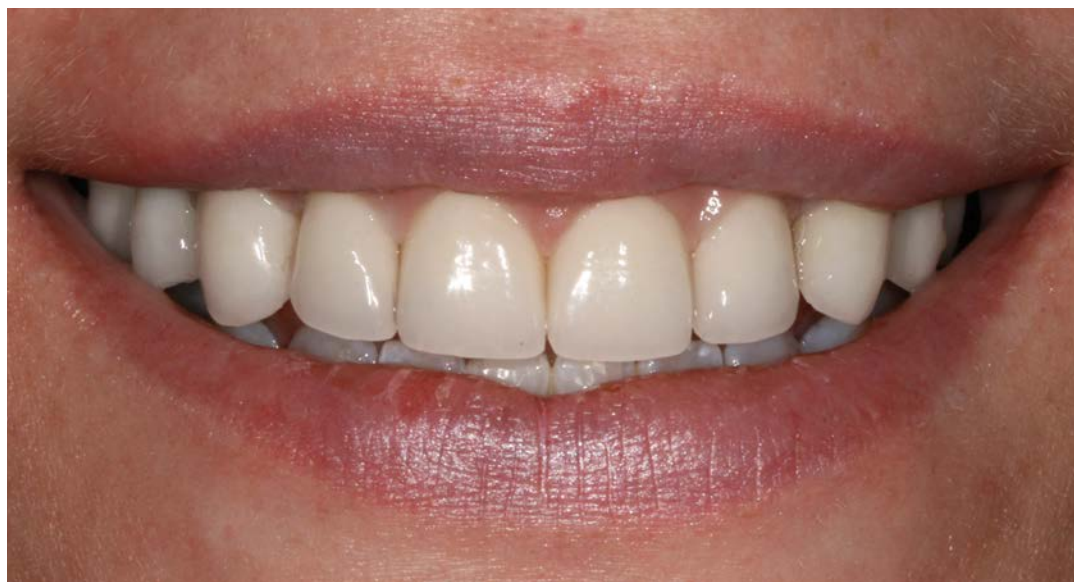

Figure 24: Postoperative smile, portrait image.

The restorations were cleaned with phosphoric acid 35% (Ultradent; South Jordan, UT) for 20 seconds. Each restoration had previously been etched with hydrofluoric acid by the laboratory; however, phosphoric acid was used to remove any debris on the restorations that might have occurred during try in. Additional hydrofluoric acid was not used so as to avoid creating porcelain salts, which can weaken strengths between the intaglio surface of the veneer and the tooth.⁸ The restorations were then silanated (Bis-Silane Parts 1 and 2, Choice 2, Bisco) and a thin bond coat (Porcelain Bonding Resin, Choice 2) was placed on the intaglio surfaces of the veneers and covered while the teeth were prepared for the bonding process. The teeth were etched with 35% phosphoric acid (Ultradent) for 20 seconds. All-Bond Parts 1 and 2 (Choice 2) were combined, applied to the teeth, and air-thinned. Translucent luting resin (Choice 2) was applied to the restorations and the restorations were placed on the teeth. The excess was cleaned with bristle brushes and the restorations were light-tacked at the gingival margins (Valo Curing Light, Ultradent). The excess was flossed away and the restorations were light-cured for 45 seconds. The occlusion was adjusted accordingly. The restorations were polished and the incisal edges were recontoured slightly. The patient returned 48 hours later for further adjustments and for photographs to be taken (Figs 23 & 24).



Figure 25: Postoperative portrait.

Maintenance

It is important for the restorative dentist to think about post-orthodontic retention. It was decided that the best form of retention would be an Essix retainer, fabricated after the completion of the restorative treatment. On the mandibular arch, a lingual arch wire was placed from canine to canine, and a bracket and spring was placed in the area of the missing right first molar to maintain the space during integration and until the implant is ready for the restorative therapy.

Discussion

In his book *The 7 Habits of Highly Effective People*, Stephen Covey writes that we must “begin with the end in mind.”⁹ This idea can be applied to dentistry in a multitude of ways. Prior to picking up a handpiece, the practitioner must visualize the desired esthetic outcome of a case. Utilizing different diagnostic modalities and different specialties will help envision the future restorations prior to the start of treatment. Planning and diagnostics are in a sense more important than the actual preparation. While every practitioner may plan a case in a different way, it is important to keep the esthetic outcome at the forefront of the treatment plan.

Summary

Postoperatively, the maxillary and mandibular dental midlines now coincide with each other as well as with the facial midline. The axial inclinations of the teeth treated are close to ideal. The patient has a full buccal corridor. All spaces have been closed. The patient has a Class I canine relationship on both the right and left side. With the final placement of the implant crown the molar relationships will be improved. Adequate overbite and overjet have been achieved. The overall facial esthetic has been improved with the restorations, which are both functional and esthetic. The patient and the dentists agreed that their wishes for an optimal clinical and esthetic result had been realized¹⁰ (Fig 25).

Acknowledgments

The authors thank Oleg Gorlenko (DSG Americus Dental Laboratory; Queens, NY), who served as liaison between NYUCD’s Undergraduate Honors in Aesthetic Dentistry Program and the laboratory. Dr. Miro took the portrait photography in this article; Dr. Calamia and Dr. Miro took the case photography.

The occlusion was adjusted accordingly. The restorations were polished and the incisal edges were recontoured slightly. ”

References

1. Calamia JR, Levine JB, Lipp M, Cisneros G, Wolff MS. Smile design and treatment planning with the help of a comprehensive esthetic evaluation form. *Dent Clin North Am.* 2011 Apr;55(2):187-209.
2. Calamia JR, Levine JB, Lipp M, Cisneros G, Wolff MS. Smile design and treatment planning with the help of a comprehensive esthetic evaluation form. In: Calamia JR, Trushkowsky RD, Wolff MS, editors. *Esthetic and cosmetic dentistry for modern dental practice: update 2011.* St. Louis: Mosby; 2011. p. 187-209.
3. Spear FM, Kokich VG. A multidisciplinary approach to esthetic dentistry. *Dent Clin North Am.* 2007 Apr;51(2):487-505.
4. Spear FM, Kokich VG. A multidisciplinary approach to esthetic dentistry. In: Calamia JR, Wolff MS, Simonsen RJ, editors. *Successful esthetic and cosmetic dentistry for the modern dental practice.* St. Louis: Mosby; 2007. p. 487-505.
5. Spear F. Evaluating facial esthetics: the esthetic plane. *Daily Digest.* Available from: <http://www.speareducation.com>.
6. Calamia JR, Calamia CS. Porcelain laminate veneers: reasons for 25 years of success. *Dent Clin North Am.* 2007 Apr;51(2):399-417.
7. Gürel G. Porcelain laminate veneers: minimal tooth preparation by design. *Dent Clin North Am.* 2007 Apr;51(2):419-31.
8. Alex G. Preparing porcelain surfaces for optimal bonding. *Compend Contin Educ Dent.* 2008 Jul-Aug;29(6):324-35.
9. Covey SR, Covey SM. *The 7 habits of highly effective people.* New York: St. Martin's Griffin; 1998.
10. Kokich VO Jr, Kiyak HA, Shapiro PA. Comparing the perception of dentists and lay people to altered dental esthetics. *J Esthet Dent.* 1999;11(6):311-24. **JCD**

The patient and the dentists agreed that their wishes for an optimal clinical and esthetic result had been realized. ”



Dr. Andi-Jean Miro was in the Undergraduate Honors in Aesthetic Dentistry Program, New York University College of Dentistry (NYUCD). She is an instructor in NYUCD's Department of Cariology and Comprehensive Care, and a postgraduate general practice resident at Lutheran Medical Center, Brooklyn, New York. She can be contacted at andijejanmiro@gmail.com.



Dr. Varriale is an orthodontist in Astoria, Queens, New York.



Dr. Calamia is a professor in NYUCD's Department of Cariology and Comprehensive Care. He maintains a private practice in New York City.

Disclosure: The authors did not report any disclosures.

AACD Self-Instruction Continuing Education Information



General Information

This continuing education (CE) self-instruction program has been developed by the American Academy of Cosmetic Dentistry (AACD) and an advisory committee of the *Journal of Cosmetic Dentistry*.

Eligibility and Cost

The exam is free of charge and is intended for and available to AACD members only. It is the responsibility of each participant to contact his or her state board for its requirements regarding acceptance of CE credits. The AACD designates this activity for 3 continuing education credits.

Testing and CE

The self-instruction exam comprises 10 multiple-choice questions. To receive course credit, AACD members must complete and submit the exam and answer at least 70% of the questions correctly. Participants will receive test results immediately after taking the examination online and can only take each exam once. The exam is scored automatically by the AACD's online testing component. The deadline for completed exams is one calendar year from the publication date of the issue in which the exam appeared. The exam is available online at www.aacd.com. A current web browser is necessary to complete the exam; no special software is needed.

Note: Although the AACD grants these CE credits, it is up to the receiving governing body to determine the amount of CE credits they will accept and grant to participants.

Verification of Participation (VOP)

VOP will be sent to AACD members via their MyAACD account upon pass completion. Log into www.aacd.com to sign into your MyAACD account.

For members of the Academy of General Dentistry (AGD): The AACD will send the AGD proof of your credits earned on a monthly basis. To do this, AACD must have your AGD member number on file. Be sure to update your AGD member number in your AACD member profile on MyAACD.com.

All participants are responsible for sending proof of earned CE credits to their state dental board or agency for licensure purposes.

Disclaimer

AACD's self-instruction exams may not provide enough comprehensive information for participants to implement into practice. It is recommended that participants seek additional information as required. The AACD Self-Instruction Program adheres to the guidelines set forth by the American Dental Association Continuing Education Recognition Program (CERP), and the AGD Program Approval for Continuing Education (PACE). Exams will be available for a maximum of 3 years from publication date.

Questions and Feedback

For questions regarding a specific course, information regarding your CE credits, or to give feedback on a CE self-instruction exam, please contact the AACD Executive Office by e-mailing info@aacd.com or by calling 800.543.9220 or 608.222.8583.



ADA CERP is a service of the American Dental Association to assist dental professionals in identifying quality providers of continuing dental education. ADA CERP does not approve or endorse individual courses or instructors, nor does it imply acceptance of credit hours by boards of dentistry. AACD designates this activity for 3 continuing education credits. Concerns or complaints about a CE provider may be directed to the provider or to ADA CERP at www.ada.org/goto/cerp.

The 10 multiple-choice questions for this Continuing Education (CE) self-instruction exam are based on the article, "Esthetic Smile Design: A Multidisciplinary Approach to Diastema Closures," by Andi-Jean Miro, DDS; Jill Varriale, DMD; and John R. Calamia, DMD. This article appears on pages 96-109.

The examination is free of charge and available to AACD members only. AACD members must log onto www.aacd.com to take the exam. **Note that only Questions 1 through 5 appear in the printed and digital versions of the jCD; they are for readers' information only.** The complete, official self-instruction exam is available online only—completed exams submitted any other way will not be accepted or processed. A current web browser is necessary to complete the exam; no special software is needed. The AACD is a recognized credit provider for the Academy of General Dentistry, American Dental Association, and National Association of Dental Laboratories. For any questions regarding this self-instruction exam, call the AACD at 800.543.9220 or 608.222.8583.

1. The dental modalities necessary to achieve the desired esthetic results in this case were
 - a. orthodontics and restorative treatment only.
 - b. smile evaluation and restorative treatment only.
 - c. orthodontics, periodontics, and restorative treatment.
 - d. orthodontics, implant therapy, and restorative treatment.
2. In NYU's Undergraduate Honors in Aesthetic Dentistry Program, the smile evaluation form
 - a. completes the required esthetic evaluation.
 - b. is only used in the initial treatment-planning phase.
 - c. is used as an adjunct along with other information to determine treatment.
 - d. carries more weight than the verbalization of the expected goals of the patient.
3. Each case in the program begins
 - a. with biological structure and function as the highest priority.
 - b. by selecting the appropriate ceramic required to restore the case.
 - c. by utilizing a universal preparation and reduction protocol.
 - d. with the eventual esthetic goal in mind.
4. What would be the likely outcome of treating the case presented with only orthodontics?
 - a. Closing the spaces with orthodontics would have been an acceptable esthetic option.
 - b. The patient's tooth size discrepancy would not be an esthetic problem.
 - c. Closing the spaces on both sides would yield a Class III occlusion with crossbite.
 - d. The patient's facial profile is not a consideration when orthodontics is used as the sole treatment modality.
5. The case presented emphasizes what important concept?
 - a. That it is the orthodontist's decision to decide how to manage special relationships in restorative cases.
 - b. That excess spaces should be set up for esthetics with occlusion being a secondary consideration.
 - c. The importance of collaborative communication between the orthodontist and the restorative dentist prior to and during treatment.
 - d. That it is necessary for the dentist to evaluate spacing only once orthodontic treatment is complete.

To see and take the complete exam, log onto www.aacd.com/jcdce. Click "Dental Professionals", "Journal of Cosmetic Dentistry", "jCD CE", and log in.

jCD Book Review


“***Esthetic and Restorative Dentistry* is an invaluable resource for clinicians and technicians alike.**”

The *Journal of Cosmetic Dentistry's* Book Review is an opinion piece by jCD reviewers. It highlights works that are currently available from publishers in the dental industry.

Title: *Esthetic and Restorative Dentistry: Material Selection and Technique (2nd edition)*

Authors: Douglas A. Terry, DDS, and Willi Geller, MDT

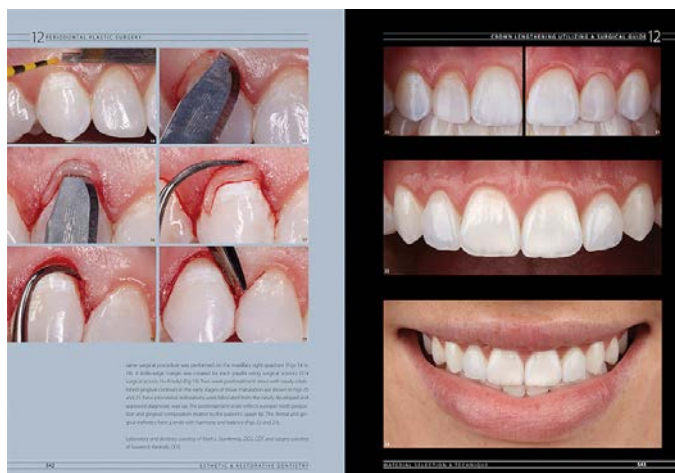Publisher: Quintessence Publishing



Esthetic and Restorative Dentistry: Material Selection and Technique is a timely and very thorough overview of modern concepts in esthetic and restorative dentistry. It is impressive to see a work this complete, considering the rapid pace of technological change in dental methods and materials. High-quality photographs and illustrations capture not only direct and indirect restorative dentistry and surgery, but also the artistry of dental technicians in a way that cannot always be adequately conveyed by the written word alone.

This 700+-page work imparts to readers what is clinically possible within their own practice of dentistry, offering step-by-step solutions to many restorative and esthetic challenges. A team approach and the critical importance of communication are highlighted throughout. Technical matters such as mechanical properties of dental materials, C-factor, adequate crown ferrule, peri-implant tissue health, importance of biologic width, etc. are addressed. The authors are well-grounded in dental science and dental health, and at the same time, create superlative dental art. Each chapter in and of itself could have been expanded into a book.

Esthetic and Restorative Dentistry is an invaluable resource for clinicians and technicians alike. It is, frankly, a modern classic.

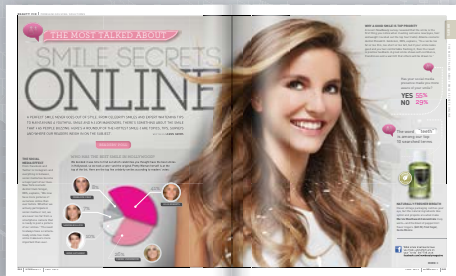

A Special Gift for jCD Readers:

Take advantage of a special offer from Quintessence Publishing! As an AACD member, you can receive a preview download of *Esthetic and Restorative Dentistry* and 25% off the regular price. Simply enter promo code JCD2014 at checkout. To take advantage of this discount, visit: <http://www.quintpub.com/jcd/>

HAVE YOUR PRACTICE FEATURED IN **NEWBEAUTY MAGAZINE** WHERE **EDUCATED CONSUMERS** TURN FOR EXPERT ADVICE

GUM LIFT | IN-OFFICE WHITENING | BRACES | INVISALIGN | BONDING | VENEERS
DENTAL IMPLANTS | CROWNS | GUM RECONTOURING | TOOTH CONTOURING

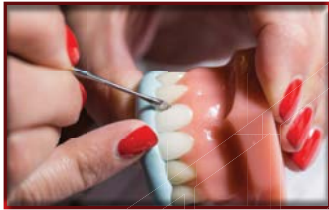


THE ONLY NATIONAL BEAUTY MAGAZINE WITH
COSMETIC DENTISTRY EDITORIAL IN EVERY ISSUE!

NEWBEAUTY & AACD | A BEAUTIFUL PARTNERSHIP

To have your practice featured, call 866-NEWBEAUTY or visit newbeauty.com





THE BEST IN Comprehensive Cosmetic Dentistry

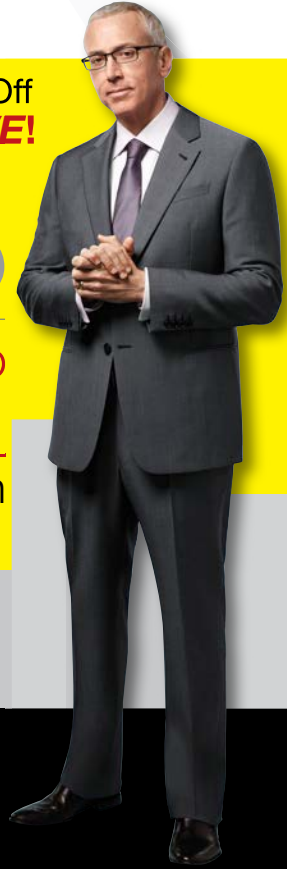Conference Kick-Off
with Dr. Drew **LIVE!**

AACD 2015

San Francisco

May 6 - 9

31st Annual AACD Scientific Session



educate | inspire | connect

AACD 2015 Educator Headliners



Dr. Christian
Coachman



Dr. Eric
Van Dooren



Dr. Didier
Dietschi



Dr. Galip
Gürel



Dr. Dwayne
Karateew



Dr. Dennis
Tarnow


Lab Program Headliners



Mr. Peter
Pizzi



Mr. Nondas
Vlachopoulos



Mr. Michel
Magne

Cosmetic Dentistry Educators from Around the Globe

Topics include smile design, digital dentistry, implants, restorative dentistry, ortho and much more.

All-Inclusive Conference Experience: An Incredible Value!

Tuition includes ALL workshops and courses, breakfasts and lunches, Exhibit Hall access, and much more.

Social Receptions/Networking Opportunities

Share cocktails and discuss dentistry with the world's most progressive and innovative dental professionals.

Register at

www.AACDconference.com

IPS Empress® Direct

Direct Esthetic Composite System

The most complete
esthetic composite system!



IPS Empress® Direct

The direct composite system formulated to offer the esthetics of Empress with the convenience of a composite. With IPS Empress Direct, Flow, Color and Opaque you now have the esthetic options necessary to mimic the natural beauty of teeth.

100% CUSTOMER SATISFACTION
GUARANTEED!



ivoclarvivadent.com

For more information, call us at 1-800-533-6825 in the U.S., 1-800-263-8182 in Canada.
© 2014 Ivoclar Vivadent, Inc. Ivoclar Vivadent and IPS Empress are registered trademarks of Ivoclar Vivadent, Inc.


passion vision innovation

A close-up portrait of a woman with blonde hair and blue eyes, smiling warmly. She is wearing a dark blue top. The background is a solid dark blue.

Mary DeRose

DENTISTRY BY
Dr. Ann Malotky, Redding, CA
AACD MEMBER

MACSTUDIO BY MICRODENTAL LABORATORIES

Developed 15 years ago by dentists and MicroDental, Macstudio restorations are the leading choice for dentists who are committed to life-changing dentistry.

Dr. Malotky's treatment plan began with an observation of uneven and misshapen front teeth, along with fractured incisal edges and staining. Mary commented that she too noticed these details and wished to get her beautiful smile back. The Macstudio team carefully crafted a wax-up and temporaries based on Dr. Malotky's preferences and prescription. Mary's natural looking new smile is the result of 8 e.max porcelain veneers, and she looks for opportunities to flash her elegant smile each day now.

From full-mouth rejuvenations to single tooth restorations; MACVENEERS™ to crowns, bridges, implants and removables; Macstudio restorations can create A SMILE FOR EVERY STORY™.

MACSTUDIO
BY MICRODENTAL LABORATORIES

AACD American Academy
of Cosmetic Dentistry
CORPORATE GOLD MEMBER



SMILES MATTER™
MicroDental.com/macstudio
800.229.0936

MICRODENTAL
LABORATORIES