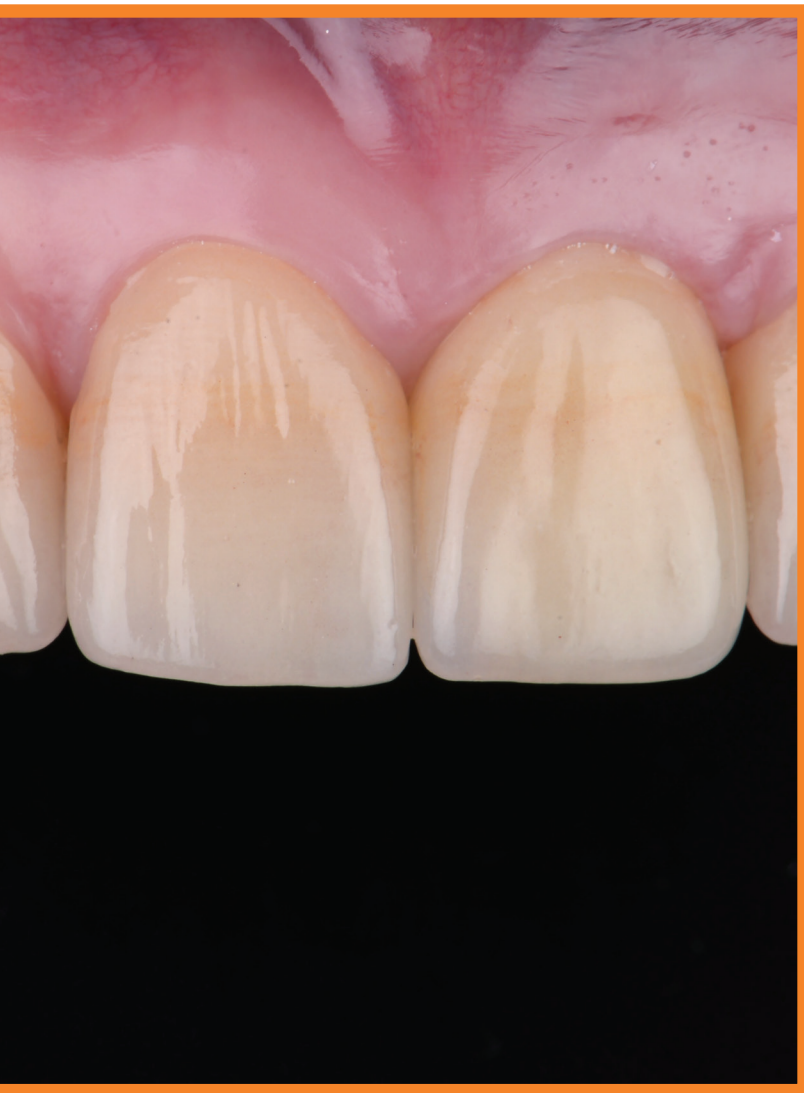

# Integrating Natural Hard and Soft Tissue

## An Implant-Supported Restoration in the Esthetic Zone

Somkiat Aimplee, DDS, MSc



**// The successful replacement of anterior teeth with implants requires an interdisciplinary approach. //**

### Abstract

The integration of a restoration with the natural hard and soft tissue is a key factor for an excellent esthetic outcome. A comprehensive treatment plan along with a smile design concept, appropriate material selection, and good communication between the surgeon, restorative dentist, and laboratory technician are also crucial in creating a suitable foundation for implant restoration. This article discusses concepts and procedures for implant treatment in the esthetic zone using a diagnostic wax-up and an implant-supported provisional as a blueprint for successful definitive restoration.

**Key Words:** delayed implant placement, implant-supported provisional restoration, custom impression coping, veneer restorations, diagnostic wax-up, Case Type III

### Introduction

Achieving excellent esthetics with an implant restoration in the anterior zone continues to be a challenge in dentistry. The successful replacement of anterior teeth with implants requires an interdisciplinary approach. Accurate diagnosis and treatment planning; meticulous implant site development; and close communication between the restorative dentist, surgeon, and laboratory technician are all critical to success.

## Patient History

The patient was a 40-year-old female with no medical problems. She presented with an edentulous area (the maxillary central incisor, #9) and an existing removable partial denture. We performed a thorough clinical, periodontal, and occlusal examination, including radiographs and photographs (Figs 1-5). Implant treatment was planned based on the data gathered.

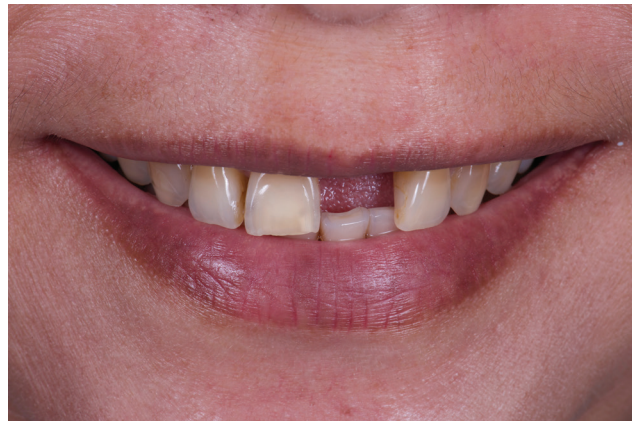## Clinical Examination and Findings

The surgeon and the restorative dentist subsequently examined the patient together. A panoramic radiograph, a periapical radiograph, cone-beam computed tomography of the #9 site, and preoperative photographs were taken. The patient's oral hygiene was fair and there was very slight tissue inflammation. Medium bone loss was observed on the radiographs (AAP Type II). Teeth #7, #8, and #10 exhibited worn incisal edges with discolored composite restorations.

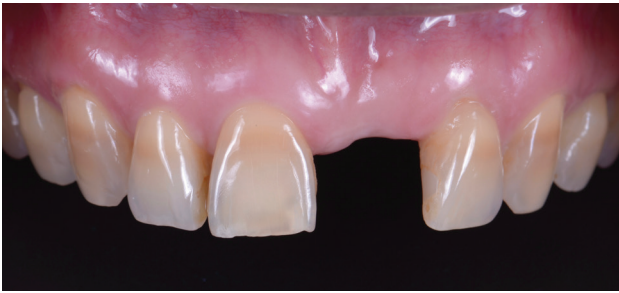There were no signs or symptoms of functional problems. A thorough examination of muscles and occlusion revealed no abnormal findings. Temporomandibular joint sounds and range of motion were normal, and joint load and immobilization tests were negative. As the patient was determined to have proper function, no occlusal treatment was deemed necessary. A dentofacial examination found medium lip dynamics and a normal-to-flat gingival scallop around the anterior teeth. The patient wanted the restorations to match her existing dentition.



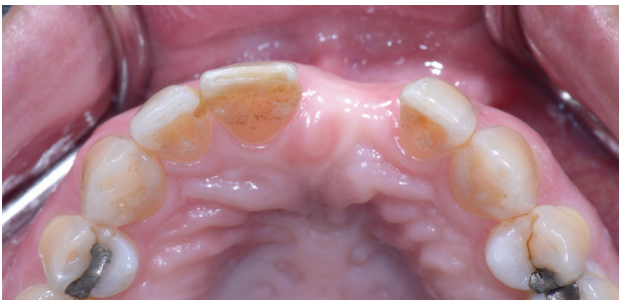**Figure 1:** Preoperative; the patient's unhappy, unconfident smile.



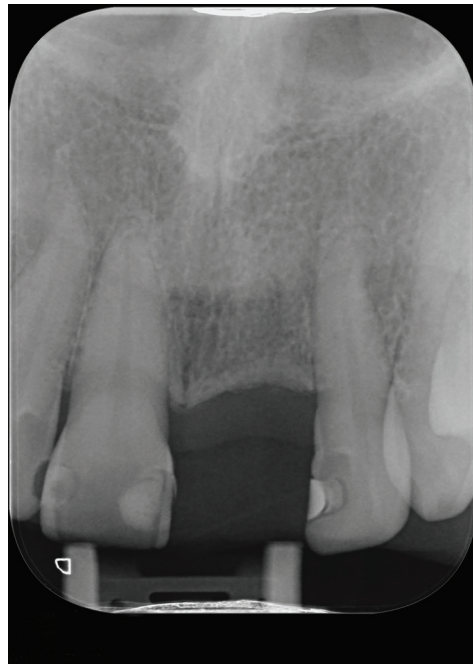**Figure 2:** Preoperative close-up view; medium smile line.



**Figure 3:** Preoperative intraoral frontal view; worn dentition and missing soft tissue.



**Figure 4:** Preoperative occlusal view; medium bone resorption at edentulous area.



**Figure 5:** Preoperative periapical radiograph; medium bone resorption at edentulous area and faulty restorations.

## Treatment Plan

We began with periodontal therapy consisting of scaling and polishing, with an emphasis on improved home care and six-month recall visits.

Direct composite restorations were planned to replace all the questionable restorations and eliminate decay. Ceramic veneer restorations for #7, #8, and #10 were planned to restore tooth shape and harmonize tooth color. Implant placement was planned for the missing #9. Utilizing a fixed dental prosthesis could decrease the long-term treatment success due to the increased biomechanical risk to the abutment teeth.

To accurately predict peri-implant esthetics, the restorative dentist and the surgeon jointly assessed relative tooth shape and position, form and biotype of the periodontium, and position of the osseous crest. The gingival margin level, the normal-to-thick biotype, and the triangular tooth shape were all taken into consideration.

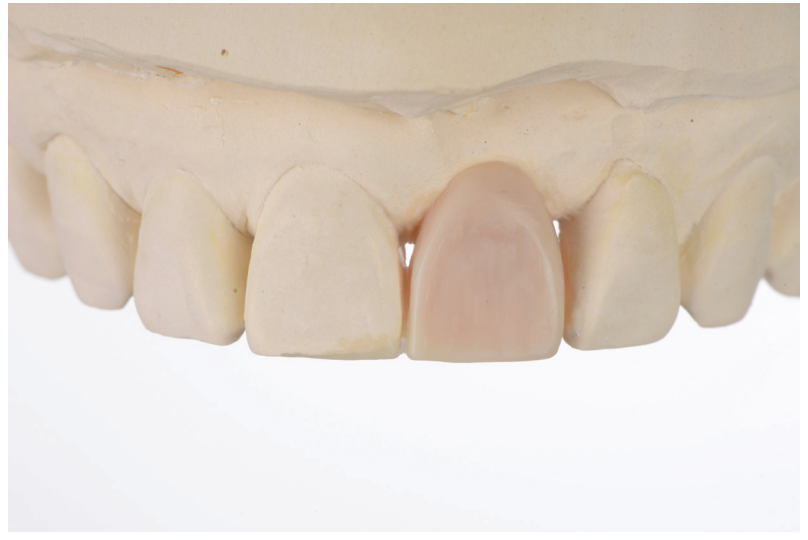A diagnostic wax-up was fabricated as a blueprint of the definitive restoration according to the smile design plan. It served as a very effective communication tool between the members of the interdisciplinary team and with the patient (Fig 6).

## Treatment

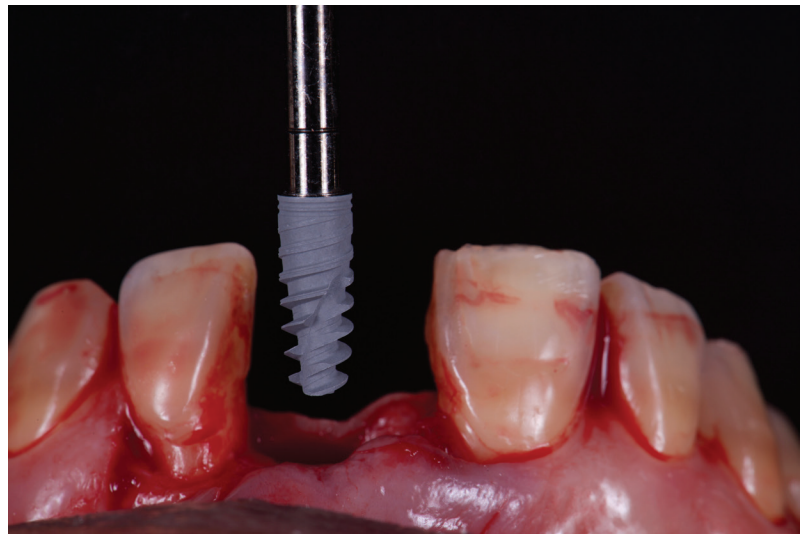
### Surgery

The surgical procedures were performed under local anesthesia. The soft tissue in the edentulous area was cut using a fine 15C surgical blade (Henry Schein; Melville, NY) to separate the periodontium. The goal was to preserve as much of the gingival architecture as possible and not damage the surrounding bone.<sup>1</sup>

A narrow platform implant (3.5 mm x 11 mm NobelActive, Nobel Biocare; Yorba Linda, CA) was placed 4 mm below the predetermined gingival margin to facilitate adequate postoperative prosthetic emergence. It was placed to engage the cortical bone with the position angled toward the incisal edge and torqued to 50 Ncm (Fig 7). A small cover screw was then placed. The labial bone around the dental implant was augmented with an allograft filler particle (BioOss, Zimmer Dental; Carlsbad, CA) mixed with the patient's blood. A deepithelialized connective tissue graft harvested from the maxillary palate was added to cover the filler particles and increase tissue availability. The surgical site was closed with 4-0 and 5-0 Vicryl sutures (Ethicon; Blue Ash, OH).<sup>2,3</sup> The patient was fitted with a temporary partial denture, which was adjusted so that no pressure would be exerted on the implant site.



**Figure 6:** Diagnostic wax-up; this was a blueprint of the definitive restoration and also a good communication tool between team members and the patient.



**Figure 7:** Delayed implant placement surgery. A narrow platform implant was selected to allow space for optimal hard and soft tissue, creating a natural-looking contour.

**// A diagnostic wax-up...served as a very effective communication tool between the members of the interdisciplinary team and with the patient. //**

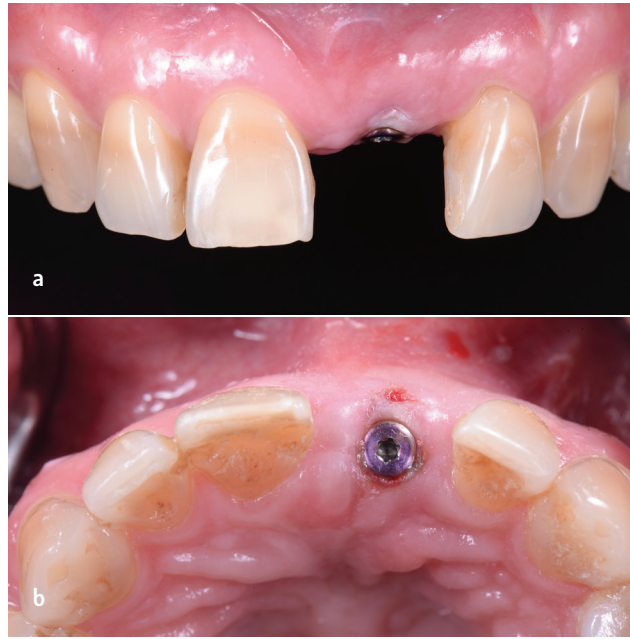

### Healing Period

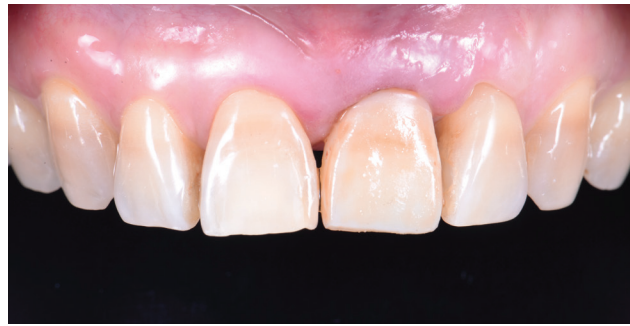Both the restorative dentist and the surgeon evaluated the patient regularly during a six-month healing period. An intrasulcular partial-thickness incision was made at the second-stage surgery on #9 and the implant was connected to a suitable healing abutment (Figs 8a & 8b), which was replaced by a customized temporary abutment one week later. A putty index (Sil-Tech, Ivoclar Vivadent; Amherst, NY) made from the diagnostic wax-up was loaded with a Bis-GMA temporary material (Protemp4, 3M ESPE; St. Paul, MN) and placed in the patient's mouth until it was fully set and firmly connected to the temporary abutment. The assembly was unscrewed and the subgingival emergence profile was modified by carefully adding composite resin (Filtek Z350, 3M ESPE) so as not to overcontour the subgingival area, which can cause recession of the soft tissues.<sup>4,5</sup> The patient had several more appointments to groom the tissues into the desired shape by modifying the subgingival emergence profile and changing contours and contact points of the provisional crown (Figs 9 & 10).

### Final Restorations

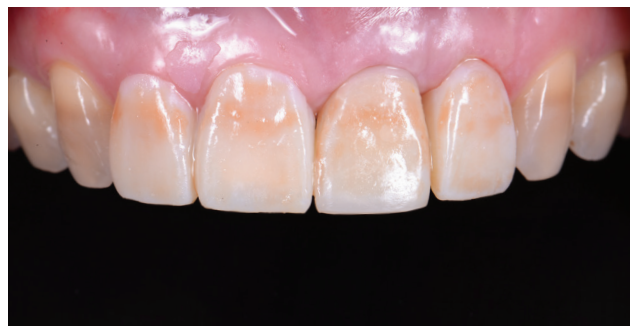After the ideal tissue contours had been developed and matured by modifying the provisional (Figs 11a & 11b) and #7, #8, and #10 were prepared for veneer restorations, a final impression was taken. A fixture level impression with a custom impression coping was made using a polyvinyl siloxane impression material (Extrude, Kerr; Orange, CA).<sup>6</sup> To create the custom implant coping, the provisional crown was removed and then connected to a fixture replica and impressed into a plastic cylinder filled with putty. The provisional crown was then unscrewed, an impression coping was connected to the replica, and the space was filled with acrylic (Pattern Resin, GC America; Alsip, IL (Fig 12)). The obtained custom coping was marked on the labial surface to aid orientation and unscrewed from the putty cylinder. It was then connected to the implant fixture and used in an open-tray technique for the final impression.<sup>7</sup> This method replicates the accurate soft tissue contour onto the working cast and provides the laboratory technician with detailed information to duplicate the established emergence profile.<sup>8,9</sup> Multiple shade photographs were taken to communicate with the technician. A custom zirconia abutment (NobelProcera, Nobel Biocare) was fabricated and torqued to 35 Ncm (Figs 13a-14). The ceramics were e.max Press (Ivoclar Vivadent) with a cut-back and layering technique; the ingot was LT A2 layered with A2, E14, T11, and T Neutral (Ivoclar Vivadent).



**Figures 8a & 8b:** Osseointegrated implant with soft tissue healing.



**Figure 9:** Implant-supported provisional crown for soft tissue development.



**Figure 10:** Provisional restorations #7-10.

## Seating

At the seating appointment, the lithium disilicate crown and veneers were tried-in and photographed for analysis.<sup>10</sup> After a retraction cord was placed around the implant abutment, the crown was bonded using a paired adhesive/resin cement system (ScotchBond Universal and RelyX Ultimate, 3M ESPE). The veneer restorations were bonded using an adhesive (Single Bond, 3M ESPE) and a light-cured resin cement (RelyX veneer cement). Static and dynamic occlusion was verified and all necessary adjustments were carried out.

An occlusal guard was fabricated and delivered at a subsequent appointment to provide overnight protection for the new restorations.

The patient returned one week later, at which time a periapical radiograph and final photographs were taken (Figs 15-18).

## Summary

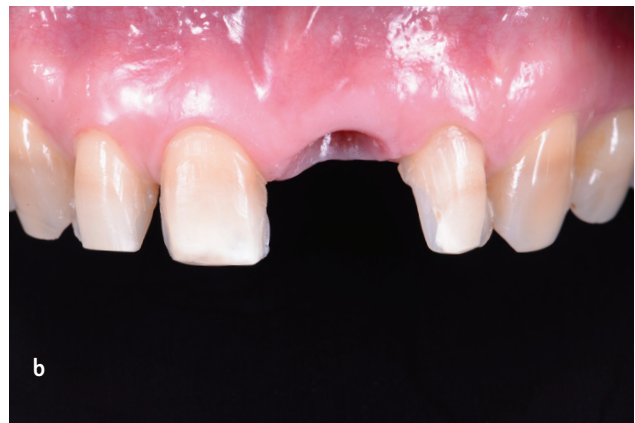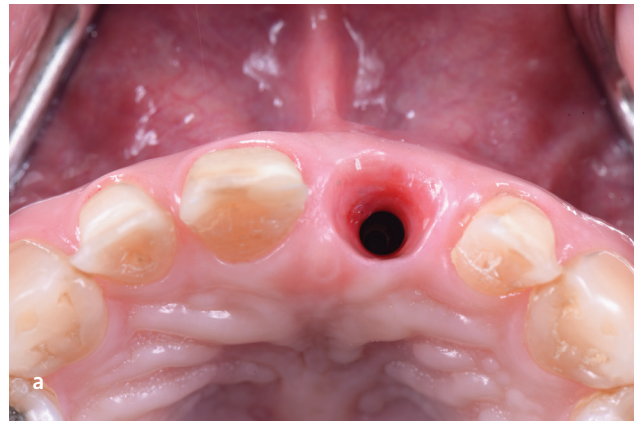
This case demonstrates that implant treatment necessitates meticulous treatment planning along with optimized implant positioning, detailed step-by-step prosthetic procedures and, most importantly, good communication and teamwork between the surgeon, the dentist, and the laboratory technician. The patient was extremely pleased with the outcome and overall positive experience.

## Acknowledgment

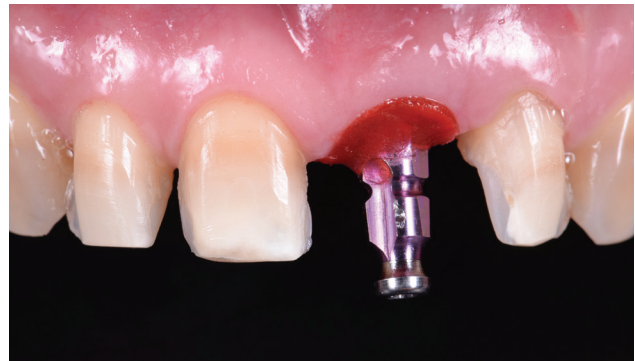*The author thanks Dr. Gerard Chiche, director of the Ronald Goldstein Center for Esthetics and Implants at Augusta University College of Dental Medicine (Augusta, GA) for his guidance.*

## References

1. Phillips KM, Kois JC. Aesthetic peri-implant site development. The restorative connection. *Den Clin North Am.* 1998 Jan;42(1):57-70.
2. Kan JY, Rungcharassaeng K, Umeza K, Kois JC. Dimensions of peri-implant mucosa: an evaluation of maxillary anterior single implants in humans. *J Periodontol.* 2003 Apr;74(4):557-62.
3. Babbush CA, editor. *Dental implants: the art and science.* 2nd ed. Philadelphia: W.B. Saunders; 2001.
4. Saadoun AP, Le Gall MG. Periodontal implications in implant treatment planning for aesthetic results. *Pract Perio Aesthet Dent.* 1998 Jun-Jul;10(5):655-64.

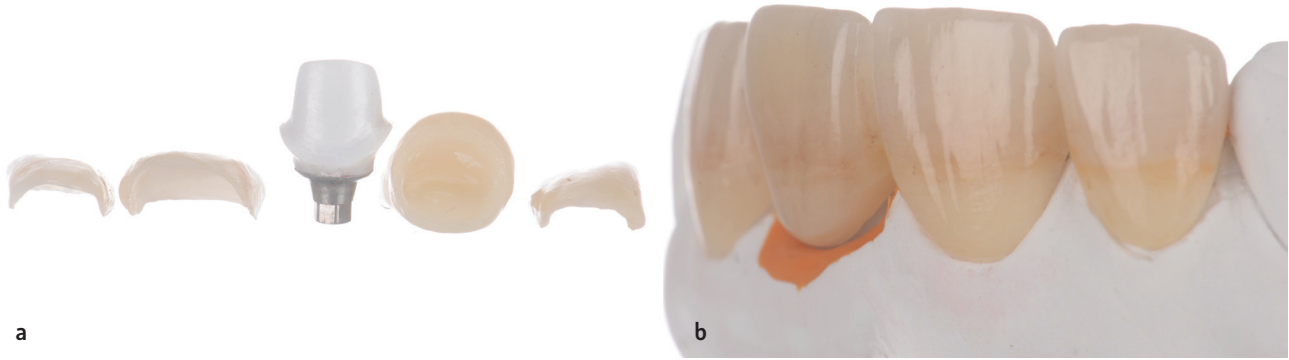


**Figures 11a & 11b:** Tissue was developed from the provisional restoration.

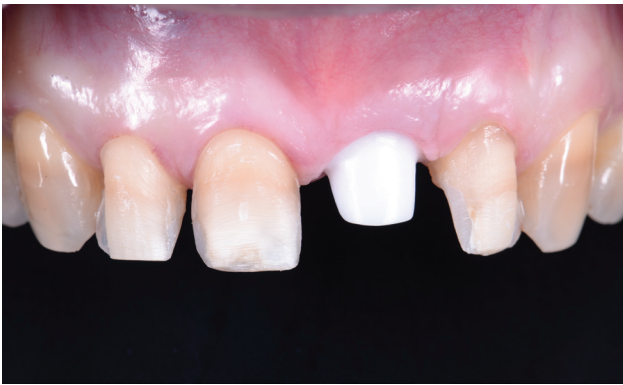

**Figure 12:** A customized impression coping was duplicated from the provisional restoration.

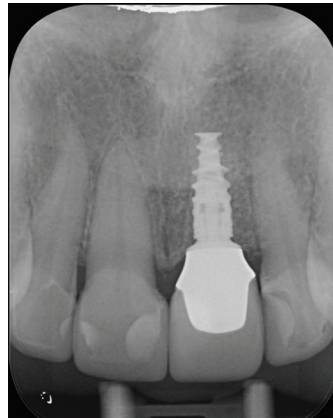
**// Both the restorative dentist and the surgeon evaluated the patient regularly during a six-month healing period. //**



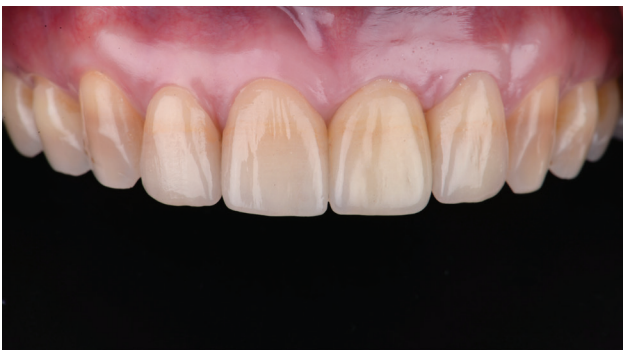**Figures 13a & 13b:** Definitive restoration. The lithium disilicate ceramic veneers and crown were fabricated with a pressed and layered technique to create natural translucence.



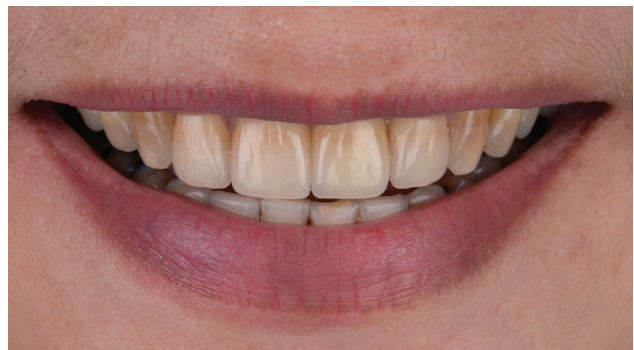**Figure 14:** Preparations #7, #8, and #10, and CAD/CAM zirconia abutment hybrid with titanium base.



**Figure 15:** Postoperative periapical radiograph; crestal bone stability around the implant and complete integration of restorations and abutments.



**Figure 16:** Postoperative frontal intraoral view; harmony of restorations and natural teeth was achieved by following the smile design blueprint.



**Figure 17:** A natural, harmonious smile that follows the patient's upper and lower lips.



5. Tarnow DP, Magne AW, Fletcher P. The effect of the distance from the contact point to the crest of the bone on the presence or absence of the interproximal dental papilla. *J Periodontol.* 1992 Dec;63(12):995-6.
6. Grunder U. Stability of the mucosal topography around single-tooth implants and adjacent teeth: 1-year results. *Int J Periodontics Restorative Dent.* 2000 Feb;20(1):11-7.
7. Polack MA. Simple method of fabricating an impression coping to reproduce peri-implant gingiva on the master cast. *J Prosthet Dent.* 2002 Aug;88(2):221-3.
8. Sclar A. Soft tissue and esthetics considerations in implant therapy. Hanover Park (IL): Quintessence Pub.; 2003. p. 243-61.
9. Kois JC. Predictable single-tooth peri-implant esthetics: five diagnostic keys. *Compend Contin Educ Dent.* 2004 Nov;25(11):895-6, 898.
10. Chiche GJ, Pinault A. Esthetics of anterior fixed prosthodontics. Hanover Park (IL): Quintessence Pub.; 1996. **jCD**



**Figure 18:** Postoperative full-face smile view. The patient's smile looks very natural and in harmony with her face.

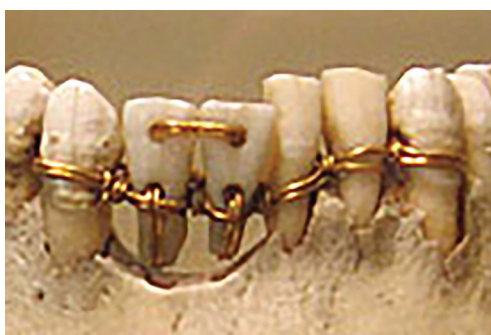

Dr. Aimplee is an assistant adjunct professor, Oral Rehabilitation Department, Augusta University College of Dental Medicine, Augusta, Georgia. He is in private practice limited to prosthodontics and esthetic dentistry in Bangkok, Thailand.

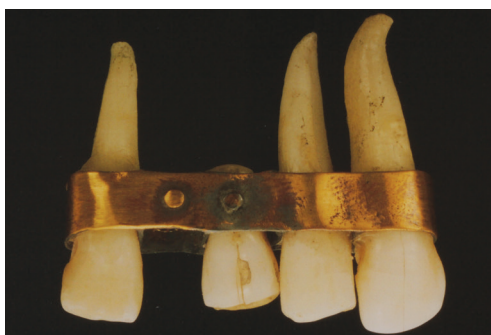Disclosures: The author did not report any disclosures.

## Attention to Detail in Case Type III

J.A. Reynolds, DDS, AAACD



**Figure 1:** Gold wire bridge, 500 BC.



**Figure 2:** Tooth riveted with gold strap.



**Figure 3:** First dental implants.

The esthetic replacement of missing teeth has historically been a challenge in dentistry. Fortunately, advances in technology and science have birthed techniques that enable today's clinicians to provide patients with natural-looking tooth replacement options, whether using a bridge or an implant.

The first dental bridges—simple gold wires used to hold teeth in place—were placed around 500 BC by the Etruscans. Later, gold bands, which became increasingly elaborate and indicated the wearer's status (Figs 1 & 2), were utilized. To show off their affluence, wealthy women were even known to have their natural teeth removed and replaced with gold.<sup>1</sup>

Of course, the dental bridge has advanced significantly both clinically and esthetically and is still used today. Interestingly, dental implants share a similar evolution. Evidence shows that, around AD 600, the Mayans implanted nonorganic material in living people using tooth-shaped shell fragments placed in empty tooth sockets (Fig 3). Radiographic evidence shows compact bone formation around the pieces similar to that of a blade implant<sup>2</sup> (undoubtedly this would have been a difficult case selection for Accreditation, but it was a great service to the patient).

In his Case Type III, Dr. Somkiat Aimplee provides a good example of how a dental implant can be a valuable tool in modern dentistry. Knowledge of technique—with both hard and soft tissue—is paramount in achieving a high level of success. In the maxillary anterior, proper implant placement slightly palatally and at least 3 mm apical to the final facial contour allows sufficient room to shape final tissue contours.<sup>3</sup> It is vital to test the emergence profile with the provisionals in situ, allowing time for tissue maturation.<sup>4</sup>

This case is what Accreditation is all about: paying close attention to detail, using proven clinical techniques, listening to and learning from a mentor, and recording the process with quality photography. Congratulations to Dr. Aimplee on a job well done. We certainly have come a long way from gold wire and shell implants!



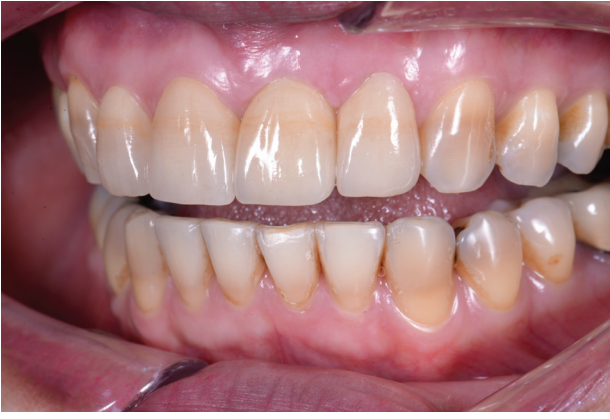

Figure 4: Slightly long contacts due to papilla height.

The examiners passed this case unanimously, with only minor deductions noted as follows:

- **Criterion #64:** *Is the interproximal contact or connector proper in length and position? Long contact areas are evident, especially distal #9 (Fig 4).*
- **Criterion #87:** *Are contralateral teeth in harmony in terms of size, shape, or position? Tooth #8 appears wider than #9 and the lateral incisors are asymmetrical (Fig 5).*

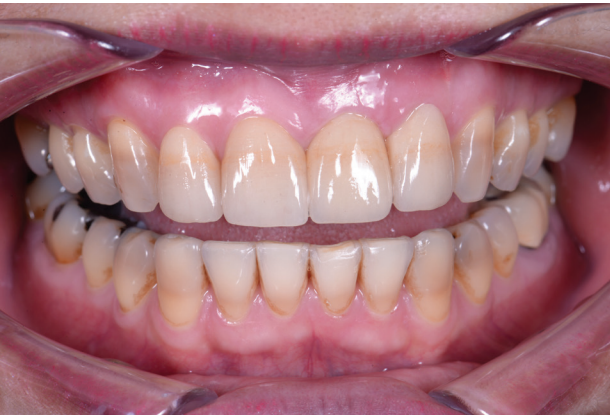

Figure 5: Note contralateral tooth size.

References

1. Ring ME. Dentistry: an illustrated history. New York: Harry N. Abrams; 1985. p. 43
2. Ibid., p. 17
3. Butler B, Kinzer GA. Managing esthetic implant complications. *Compend Contin Educ Dent.* 2012 Jul-Aug;33(7):514-8, 520-2.
4. Schoenbaum TR. Abutment emergence profile and its effect on peri-implant tissues. *Compend Contin Educ Dent.* 2015 Jul-Aug;36(7):474-9. **JCD**

**// It is vital to test the emergence profile with the provisionals in situ, allowing time for tissue maturation. //**



Dr. Reynolds is an AACD Accredited Member and has been an AACD Accreditation Examiner since 2003. He practices in Franklin, Tennessee.

Disclosure: The author did not report any disclosures.