

jcd

vol. 27 issue 2

Journal of Cosmetic Dentistry

Myths vs. Realities: Prepped and Prep-Less Veneers

Drs. Brian LeSage and Dennis Wells

Multi-faceted Ceramic Solutions—Earn Free CE!

Matthew Roberts, CDT, and Drs. Franklin Shull, James Fondriest, and Thomas Trinkner

Solving a Patient's Precise Request with Veneers

Dr. W. Johnston Rowe, Jr. and Wayne Payne

SUMMER 2011

AAFD American Academy
of Cosmetic Dentistry®

Immediate high strength bonds you can rely on.

Multilink® Automix

Easy Clean-Up Formula!



Developed to maximize the performance of indirect restorations, Multilink® Automix creates a strong immediate bond between dentin & enamel, and all types of restorative materials providing security you and your patients can rely on.

- High-immediate bond strengths to all types of restorative materials
- Fast, easy clean-up
- Self-etching primer for reduced sensitivity

Recommended for
IPS e.max®

**Multilink®
Automix**
UNIVERSAL ADHESIVE CEMENT

100% CUSTOMER SATISFACTION
GUARANTEED!

ivoclarvivadent.com/multilink

Call us toll free at 1-800-533-6825 in the U.S., 1-800-263-8182 in Canada.
©2011 Ivoclar Vivadent, Inc. Multilink is a registered trademark of Ivoclar Vivadent, Inc.

**ivoclar
vivadent®**
passion vision innovation

The only Direct Composite that can be called Empress®

Confidence

The esthetics of ceramic with the convenience of composite.

Reliability

- Exceptional Handling
- Simplified Application
- True-To-Nature™ Shades
- Superior Polish

Esthetics



IPS Empress® Direct

Direct Esthetic Composite



Introducing the New
IPS Empress® Direct Flow

100% CUSTOMER SATISFACTION
GUARANTEED!

ivoclarvivadent.com

Call us toll free at 1-800-533-6825 in the U.S., 1-800-263-8182 in Canada.
© 2011 Ivoclar Vivadent, Inc. IPS Empress is a registered trademark of Ivoclar Vivadent, Inc..

ivoclar
vivadent®
passion vision innovation

YONES & TONYA
DENTISTRY BY DR. ALEX NAINA
& DR. JOSEPH BARTON

MACSTUDIO. A SMILE FOR EVERY STORY™

MACVENEERS by MACSTUDIO are highly aesthetic and functional restorations that create lasting impressions for your patients and unique success stories for your practice.

By combining master level artistic and technical skills with a truly collaborative approach to every smile design, MACVENEERS by MACSTUDIO are crafted with the ultimate attention to detail and expertise in all occlusal philosophies—whether single units or the most complex aesthetic rehabilitations.

To offer your patients the life-changing and AACD GALLERY AWARD-WINNING dentistry that MACVENEERS can provide, contact MACSTUDIO today and experience complete service beyond ordinary expectations.

© 2011 DTI

MACSTUDIO
BY MICRODENTAL LABORATORIES

DUBLIN, CALIFORNIA 800.229.0936
LAS VEGAS, NEVADA 800.933.6838
VANCOUVER, BC 800.561.0926

www.macveneers.com

jcd

vol. 27 Issue 2
Journal of Cosmetic Dentistry

EDITOR-IN-CHIEF

Edward Lowe, DMD, AAACD
Vancouver, BC, Canada, edlowe@mac.com

MANAGING EDITOR

Tracy Skenandore, tracys@aacd.com

PUBLICATIONS ASSISTANT

Denise Sheriff, denises@aacd.com

ART DIRECTOR

Lynnette Rogers, lynnetter@aacd.com

GRAPHIC DESIGNER

Elizabeth Kiracofe, elizabethk@aacd.com

EDITORIAL CONSULTANT

Juliette Kurtz, publications@aacd.com

MANUSCRIPT

DEVELOPMENT LIAISON

Allison DiMatteo, MPS, adimatteo720@centrainy.twcbc.com

MEMBERSHIP

AND MARKETING DIRECTOR

Michael DiFrisco, michaeld@aacd.com

ADVERTISING AND SPONSORSHIP

DIRECTOR OF STRATEGIC PARTNERSHIPS

Jeff Roach, jeffr@aacd.com

CONTRIBUTING EDITORS

Scott W. Finlay, DDS, FAGD, FAACD, Arnold, MD
Julie M. Gillis, DDS, AAACD, Grand Junction, CO
James H. Hastings, DDS, AAACD, Placerville, CA
James H. Peyton, DDS, FAACD, Bakersfield, CA
Nelson A. Rego, CDT, AAACD, Santa Fe Springs, CA
Gregory B. Wright, DDS, FAACD, Southlake, TX

EDITORIAL MISSION

The mission of the *Journal of Cosmetic Dentistry* is to educate AACD members, as well as other professionals in the field, on the art and science of cosmetic dentistry. We will endeavor to do this by publishing well-researched, peer-reviewed articles accompanied by high-quality, comprehensive clinical imagery. The objective is to enhance readers' knowledge and skills while showcasing the latest cosmetic techniques and procedures. The *Journal of Cosmetic Dentistry* will strive to help readers become better clinicians, so they can offer their patients the best—and most responsible—treatment possible.

AACD OFFICE

CHIEF EXECUTIVE OFFICER

Ed Simeone

402 West Wilson Street, Madison, WI 53703

800.543.9220 • 608.222.8583

fax 608.222.9540 • info@aacd.com • www.aacd.com

Advertising: 800.543.9220 • 608.222.8583 or jeffr@aacd.com
Editorial: 800.543.9220 • 608.222.8583 or publications@aacd.com

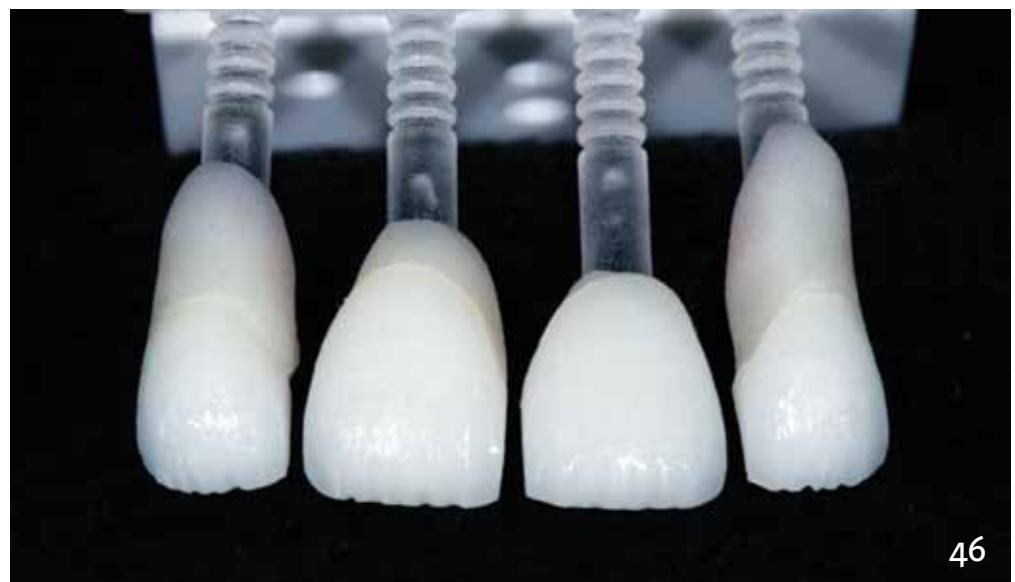
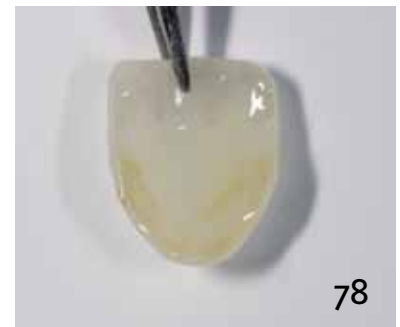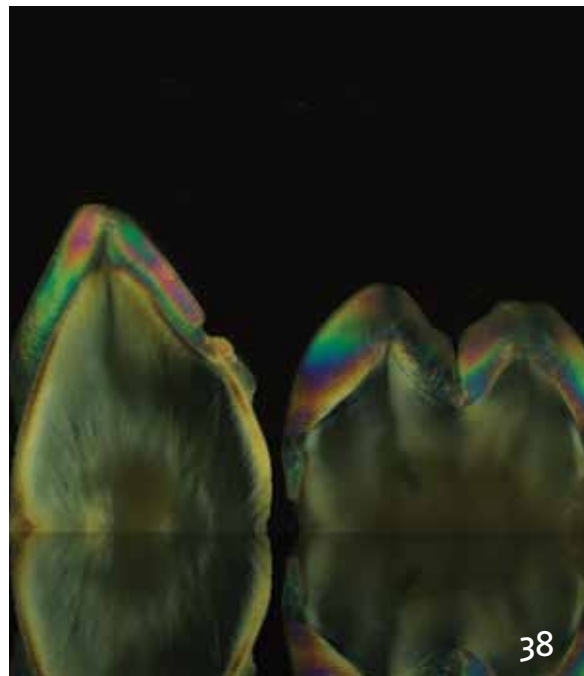
A PUBLICATION OF THE
AMERICAN ACADEMY OF COSMETIC DENTISTRY

EDITORIAL REVIEW BOARD

Pinhas Adar, MDT, CDT, Marietta, GA
Naoki Aiba, CDT, Monterey, CA
Gary Alex, DMD, AAACD, Huntington, NY
Edward Pat Allen, DDS, PhD, Dallas, TX
Elizabeth M. Bakeman, DDS, FAACD, Grand Rapids, MI
Oliver Brix, MDT, Kelkheim, Germany
Christian Coachman, DDS, CDT, São Paulo, Brazil
Michael W. Davis, DDS, Santa Fe, NM
Gerald E. Denehy, DDS, Iowa City, IA
Newton Fahl Jr., DDS, MS, Curitiba-PR, Brazil
Hugh D. Flax, DDS, AAACD, Atlanta, GA
David A. Garber, DMD, Atlanta, GA
Ronald E. Goldstein, DDS, FACD, FICD, Atlanta, GA
Dan Holtzclaw, DDS, MS, Austin, TX
Steve D. Hoofard, CDT, AAACD, Hermiston, OR
Nelson Y. Howard, DDS, AAACD, San Marcos, CA
Ronald D. Jackson, DDS, FAACD, Middleburg, VA
Michael J. Koczarski, DDS, AAACD, Woodinville, WA
John C. Kois, DMD, MSD, Seattle, WA
Gerard Kugel, DMD, MS, PhD, Boston, MA
Trevor R. Laingchild, RDT, AAACD, Burlington, ON, Canada
Ernesto Lee, DMD, Bryn Mawr, PA
David A. Little, DDS, San Antonio, TX
Robert A. Lowe, DDS, Charlotte, NC
Frank J. Milnar, DDS, AAACD, St. Paul, MN
Ricardo Mitrani, DDS, MSD, Mexico D.F., Mexico
Michael T. Morris, CDT, FAACD, Lexington, KY
Carlos A. Munoz, DDS, MSD, Buffalo, NY
Thomas W. Nabors III, DDS, AAACD, Nashville, TN
W. Peter Nordland, DMD, MS, La Jolla, CA
Paul S. Petrunaro, DDS, North Oaks, MN
Gary M. Radz, DDS, Denver, CO
Christopher D. Ramsey, DMD, AAACD, Jupiter, FL
Nelson A. Rego, CDT, AAACD, Santa Fe Springs, CA
Dwight G. Rickert, CDT, AAACD, Indianapolis, IN
Robert G. Ritter, DMD, Jupiter, FL
Matthew R. Roberts, CDT, AAACD, Idaho Falls, ID
Jean-François Roulet, DDS, PhD, Schann, Liechtenstein
Henry Salama, DMD, Atlanta, GA
Maurice A. Salama, DMD, Atlanta, GA
Michael R. Sesemann, DDS, FAACD, Omaha, NE
Michael Sonick, DMD, Fairfield, CT
Rhys D. Spoor, DDS, AAACD, Seattle, WA
Thomas T. Teel, DDS, Fort Wayne, IN
Thomas F. Trinkner, DDS, AAACD, Columbia, SC
Eric Van Dooren, DDS, Antwerp, Belgium
Marcos A. Vargas, DDS, Iowa City, IA
Dennis J. Wells, DDS, AAACD, Brentwood, TN

Features

- 38 Visually Speaking
The Art and Application of
Studying Nature ♦
Joshua Polansky, MDC
- 46 Clinical Cover Story
Enhancing Nature to Achieve
Patients' Desires ♦
W. Johnston Rowe, Jr., DDS, AAACD
Wayne B. Payne, AAACD
- 66 Myths vs. Realities
Prepped and "Prep-less" Veneers ♦
Brian P. LeSage, DDS, FAACD
Dennis J. Wells, DDS, AAACD
- 78 20 Tips on Resin Veneer Cements ♦
Carlos A. Munoz-Viveros, DDS, MSD
- 86 Visualizing Treatment Outcomes ♦
Bradley L. Jones, FAACD
Tim J. Huff, DDS
- 98 Lifelike Characteristics
Demonstrating Predictable
Durability ♦
George Priest, DMD
- 110 Colors, Shapes, and
Arrangements for Comprehensive
Results (CE article) ♦
Matthew R. Roberts, CDT, AAACD
Franklin Shull, DMD
James F. Fondriest, DDS
Thomas F. Trinkner, DDS, AAACD
- 128 AACD Self-Instruction
Continuing Education ♦
- 130 Advertising Index



Columns

- 8 Guest Editorial
Veneers and
Responsible Esthetics
John R. Calamia, DMD
- 10 Up Front
Digital Smile Design—The
Smart Tool for Engaging
Savvy Patients ♦
Edward A. McLaren, DDS
- 12 President's Message
Is AACD an "Apple"? ♦
John K. Sullivan, DDS, AAACD

Why use Patient News to advertise your practice?



ON TIME.



ON BUDGET.



ON TARGET.

- We're the marketing company many of your AACD colleagues trust for superior acquisition and retention campaigns, great customer service support, and higher-quality patients.
- Our clients often experience double-digit new-patient growth within 12 months of implementing the acquisition program.
- 99% of all newsletter, postcard, and email campaigns have been sent out on time in the past 5 years.
- 100% of all marketing campaigns are pre-determined and pre-approved and stay on budget.

Actual Independent Client Results:

- 137 unique patient calls within 30 days
- \$223,284 increase in annual revenue
- #1 referral source
- 10:1 return on investment
- \$10,000 increase in monthly revenue
- 129 new patients in the first year
- \$140,000 increase in annual revenue

Call for a quick 10-minute demonstration today!

877.779.2767

Departments

14 Behind the Smile
A Defined Smile ♦
W. Johnston Rowe, Jr., DDS, AAACD

16 Speaker Spotlight–Boston
**Interview with
 Dr. Gordon Christensen** ♦
David Eshom, DDS, AAACD
George Tysowsky, DDS, AAACD

20 Give Back a Smile™
Together Strong ♦
Thomas W. Monahan, III, DMD

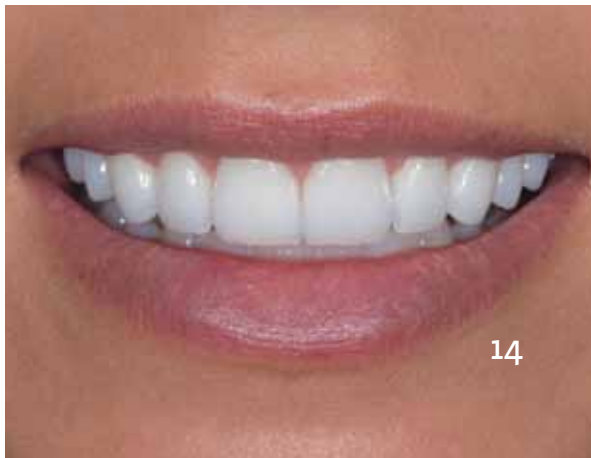26 Accreditation Essentials -
 Clinical Case Type I
**Changing Appearance to
 Improve Function** ♦
Naoki Ned Shimizu, DDS, AAACD

34 Examiners' Observations
**Combining Accreditation with
 Treatment Protocols** ♦
Scott W. Finlay, DDS, FAGD, FAACD

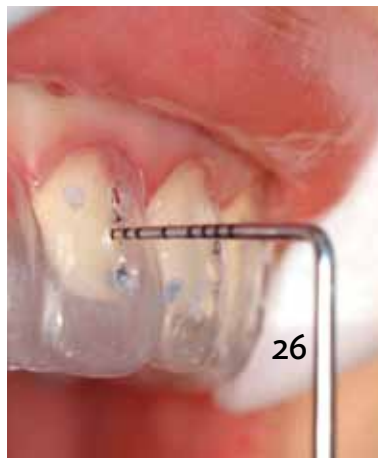36 Accreditation Tips
**The Importance of Using Your
 Resources** ♦
James H. Peyton, DDS, FAACD



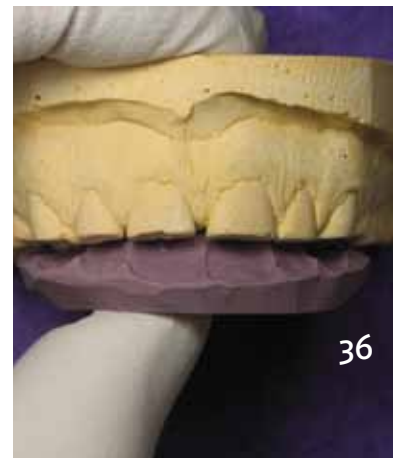
20



14



26



36



AACD MISSION STATEMENT

The American Academy of Cosmetic Dentistry is dedicated to advancing excellence in the art and science of cosmetic dentistry and encouraging the highest standards of ethical conduct and responsible patient care.



The *Journal of Cosmetic Dentistry*, ISSN # 1532-8910, USPS# 10452, published four times a year, January, April, July, and October. \$35 per copy / \$135 per year (U.S. & Canada) or \$42 per copy / \$160 per year (All other countries), by the American Academy of Cosmetic Dentistry®, 402 West Wilson Street, Madison, WI 53703. 800.543.9220 OR 608.222.8583. Periodicals postage paid in Madison, WI, and additional offices.

POSTMASTER: send address changes to:

Journal of Cosmetic Dentistry
 American Academy of Cosmetic Dentistry
 402 West Wilson Street
 Madison, WI 53703

Peer-reviewed articles are denoted with the following symbol ♦

Statements of fact and opinion are the responsibility of the authors alone and do not imply an opinion on the part of the officers of the AACD. Materials may not be reproduced without written permission. Contents® 2011 American Academy of Cosmetic Dentistry®

The *Journal of Cosmetic Dentistry* maintains signed patient release forms for all articles featuring clinical or other patient photography.

Heraeus

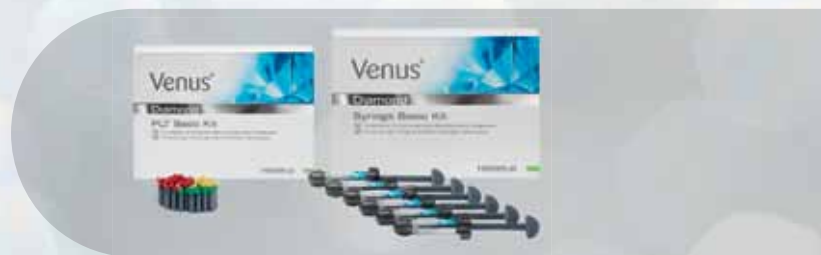
Venus Diamond® & Venus Diamond® Flow

- An unprecedented system of composites that offers a combination of low shrinkage stress, high durability, and excellent handling
- Together with the ability to use a single shade that can produce a restoration that appears layered and polychromatic, Venus Diamond and Venus Diamond Flow are the ideal choice for all your direct restorations

"Using a single shade of Venus Diamond can produce a restoration that appears layered and polychromatic."

Unpaid endorsement

Corky Willhite, DDS – AACD Accredited Fellow



AACD Charitable Foundation, Inc. Give Back a Smile

Purchase a **Venus Diamond Basic Kit** and **Heraeus** will make a **generous donation** to the **AACD Give Back a Smile** program!
Visit www.givebackasmile.com/venusbyheraeus to learn more!

Venus®
The New Esthetics

Veneers and Responsible Esthetics



John R. Calamia, DMD
AACD Board of Directors
Professor, Director of Esthetics
Department of Cariology and
Comprehensive Care, New York
University College of Dentistry

Veneers have revolutionized the art and science of cosmetic dentistry. This issue of *JCD* offers a variety of articles and photography that discuss and display how veneers are utilized today. In accordance with this, Editor-in-Chief Dr. Edward Lowe is honored to present this Guest Editorial by Dr. John Calamia.

It has been nearly 30 years since Dr. Richard Simonsen and I developed a technique to improve upon the color-unstable composite resin veneers that were the state of the art in 1982 with a treatment that was conservative, as far as tooth reduction, yet had the promise of being as esthetically pleasing and long lasting as “Hollywood caps” or full crowns.

Our research showed that if one were to etch porcelain and bond it to the surface of a tooth, sufficient bond strengths could be achieved that were expected to retain these restorations for many years.

It is up to us to seek the knowledge and skills to either provide the least invasive procedures required by a thorough examination of our patients’ needs, be they reconstructive or elective, or to refer them to colleagues who have mastered this knowledge.

Our continued studies indicated that a mild preparation of approximately .5 mm, for the most part keeping our margins within enamel, allowed for the thickness of the actual veneer to be placed. This restored the original emergence profile of the tooth yet provided enough room in the ceramic to create improved, natural-looking esthetics.

Although the bond strengths to enamel were more than sufficient for retention, the feldspathic porcelains sometimes exhibited fracture within the “substrate porcelain” itself. Practitioners started moving toward deeper preparations, thinking that the resultant increased thickness of the porcelain would cause fewer fractures. Unfortunately, the opposite was true as preparation into more motile dentin proved to be less supportive than enamel.

The development of pressed ceramics proved to be a great help in the use of etched porcelain posteriorly, but their use anteriorly, due to the initial need for a minimum of .7 mm to 1.0 mm of space to get the best esthetic result, led to over-preparation in this most visible area. Modern pressed ceramics and lithium disilicate, which can be made as thin as .3 mm, have led to our returning to more conservative tooth preparation. These technologies, plus the development of zirconium substructures for all-ceramic crowns and bridges, allow for the restoration of whole dentitions that are metal-free.

It is up to us to seek the knowledge and skills to either provide the least invasive procedures required by a thorough examination of our patients’ needs, be they reconstructive or elective, or to refer them to colleagues who have mastered this knowledge. We need fewer courses on how to sell cases and more courses on the techniques of diagnosis, familiarity with the materials that will best serve our patients, and attention to the ethics we are sworn to employ in patient treatment. I am proud of the commitment the AACD has made to Responsible Esthetics.



EXPERIENCE

WE MAKE IT
PERSONAL



DENTAL LK STUDIO

LKDENTALSTUDIO.COM

A FULL SERVICE DENTAL LABORATORY

866-550-3522 TOLLFREE

Laura Kelly **AND** 2007-2008 PRESIDENT
American Academy
of Cosmetic Dentistry
MEMBER SINCE 2007

Digital Smile Design—The Smart Tool to Engage Savvy Patients



Edward A. McLaren, DDS

UP FRONT provides a guest editorial forum for influential leaders to share their opinions. In this issue, we welcome Dr. Edward A. McLaren. Dr. McLaren is the director of the UCLA Center for Esthetic Dentistry.

Disclosure: The author did not report any disclosures.

Today's dental patients are savvy consumers. Before they step foot into the practice, many educate themselves about the dentist, the procedure(s) they may undergo, and the eventual cost. Therefore, today's dentists need to be just as savvy. Digital smile design can be the dentist's most powerful tool and give them the edge they need to show patients they have "something better" to offer.

Digital smile simulations are straightforward, clear ways to demonstrate treatment possibilities and projected outcomes to patients seeking dental treatment. They clarify procedural steps, confirm patient expectations, and increase treatment acceptance. Cost-effective, user-friendly, two-dimensional digital editing software such as Photoshop (Adobe Systems Inc.; San Jose, CA) can be used in combination with digital photography.

With Photoshop, demonstrating treatment plans is easier than just presenting "before and after" images. Each restorative step can be demonstrated and its necessity explained. Editing tools such as Clone, Liquefy, Dodge, Custom Brushes, and Grids enable the operator to move and graft sections of tooth structure, close spaces, adjust the smile line, and bleach the teeth within the image.

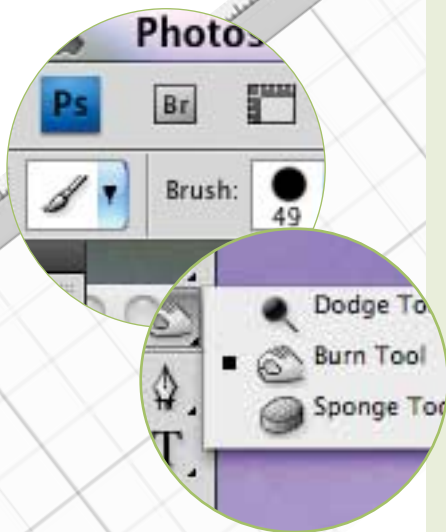
Digital smile simulations are straightforward, clear ways to demonstrate treatment possibilities and project outcomes to patients seeking dental treatment.

It is one thing to explain tooth proportion and color, because patients can easily see and understand those concepts. Digital smile design tools are most valuable for addressing the more complex, "behind-the-smile" issues they could not visualize before. And dentistry is a visual profession, one in which patient expectations, treatment acceptance, and payment are based on the final visual outcome. When patients can visualize their personal results firsthand before agreeing to the

procedure, they are more confident and certain about accepting the treatment plan.

Having digital images on file also creates the opportunity to compare a patient's existing condition to previous similarly treated cases, demonstrating the improvements achieved, and emphasizing that their results will be equally impressive. And, although patients should certainly be made aware that their altered smile design images do not guarantee identical results but do provide a preview of how treatment outcomes are expected to appear, their preview and detailed understanding of the procedure is likely to result in increased case acceptance.

When the dentist "down the street" can only show patients a "before and after" image, you must do something better, and that involves demonstrating what you propose to do, how, and why in order to get them to the "after." When you can show them the intervening steps and say, for example, "This is why I want to move the gingiva up on this tooth," and "This is why I want to bring the edge of this tooth down here," while showing real-time snapshots using two-dimensional editing software, you demonstrate that your expertise and skill are superior to those of other clinicians. Today's savvy dental patient will recognize the difference.



Our Average Approval
is over \$12,000!

Let's talk. :-)



Visit springstoneplan.com

Call 800-630-1663



Is AACD an "Apple"?



John K. Sullivan, DDS, AACD
AACD President

What do you think when you hear the word, *apple*? Years ago, it was a matter of Golden Delicious versus Granny Smith. Now it's iPods, iPhones, and iPads. These products are considered innovative, exciting, and cutting edge. Items that we take for granted today, such as "smart" phones and MP3 players, have become mainstream, largely due to the influence of Apple Corp.

Can the AACD have this same level of influence and innovation when it comes to cosmetic dentistry?

Apple Corp. emphasizes the importance of design and understanding the crucial role esthetics play in public appeal. Steve Jobs' vision of wanting to change the world was a driving force in the development of both functional and elegant products that earned Apple a devoted following.

It wasn't always this way, however. There was a time when Apple strayed from its core ideology of being innovative and on the leading edge; this, when combined with economic events, caused its loyal following to also stray. Once Apple returned to its original ideology, the company's influence on society increased to an even higher level.

Is AACD an "Apple"? We have a following of devoted, dedicated members and

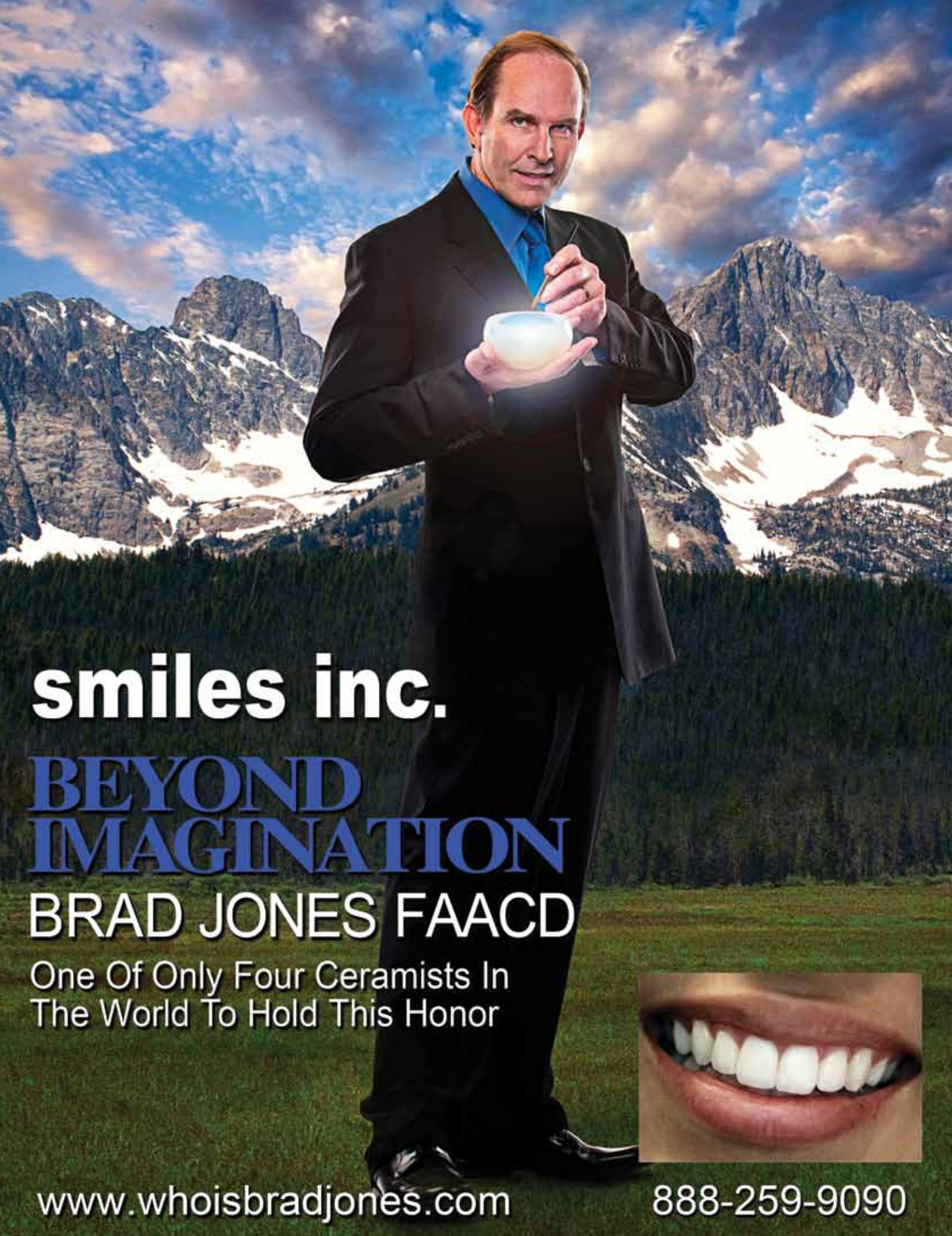We are poised for greatness, as our core ideology positions us to influence society to the pinnacle of the next bell curve.

volunteers; we have shown rapid growth; and we are on the cutting edge of worldwide dental education and philanthropy. Like many organizations, we have, due to economic conditions, experienced a downturn over the past few years, but have emerged stronger than ever, with a stable membership and with our assets protected.

Like other organizations, our growth and success follows the track of the bell-shaped curve. Following the path of that curve, once at the peak, there is only one direction in which to go, and that is down. However, as Seth Godin describes in his book *The Dip*, once the descent begins, changes can occur in an organization that will cause the bell curve to begin an upward rise again.

The AACD is currently at that point. Like Apple in the 1990s, we can continue as we have and likely follow that bell curve downward. Or, we can do as Apple has done more recently with its innovative products, marketing, and vision, and take our influence to a new high.

AACD is a leading organization with its own brand of education, its own philosophy of "responsible esthetics," and a true belief in inclusion. The word *cosmetic* is not just part of our name—it is part of our belief system, and we are changing the world, one patient at a time. We emphasize and enhance nature to help our patients find health and the confidence they desire. We are poised for greatness, as our core ideology positions us to influence society to the pinnacle of the next bell curve.

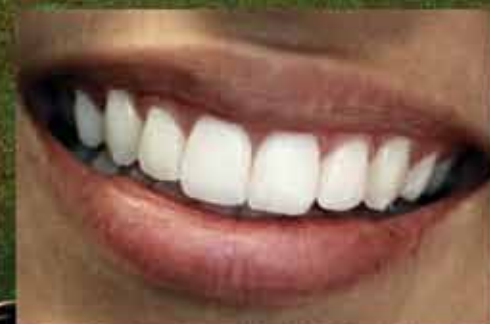

smiles inc.

**BEYOND
IMAGINATION**

BRAD JONES FAACD

One Of Only Four Ceramists In
The World To Hold This Honor



www.whoisbradjones.com

888-259-9090



// Now...I never worry when I smile or even laugh. In fact, I get compliments on my smile all the time and I couldn't be happier! //

A DEFINED SMILE

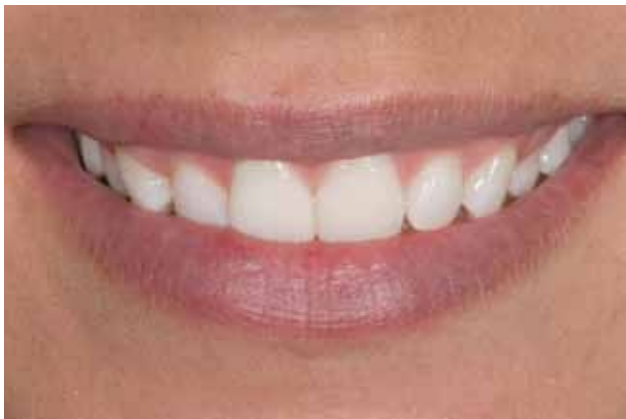It is not uncommon to have patients present for a cosmetic consultation with some very precise requests for their envisioned smile makeover. Jessie was one of these patients. She knew how she wanted her smile to look, and had researched her options extensively. One of the keys to success was to interpret her requests and incorporate them into a beautiful, functional smile design.

Although we discussed different treatment options, including orthodontics and cosmetic bonding, Jessie already knew she wanted porcelain veneers. Her history as an extremely successful pageant contestant and model had made her conscious of the power of a beautiful smile. She had always wanted a prettier smile, and I was happy to help her accomplish this dream. When we first met she was a pharmaceutical sales representative (she now works in medical sales), was self-conscious about her smile, and felt it was time for a change, as her success was largely dependent on her confidence. We discussed her desires, looked at photographs of my completed cases, and talked about her proposed treatment. I then communicated the details of the case to my master ceramist. The benefits of our collective planning were realized the day I delivered Jessie's veneers, and she hasn't stopped smiling since!

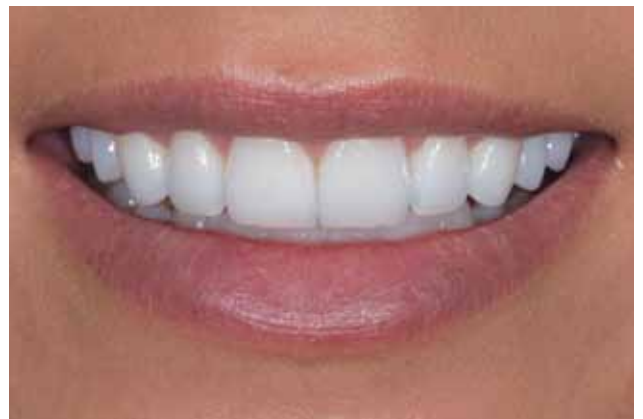The AACD provides many educational opportunities focusing on smile design, patient communication, and collaboration between dentists and laboratory technicians. Taking advantage of these opportunities provided me with a foundation of learned skills essential for completing Jessie's case successfully and, most importantly, to her satisfaction.

For information on the clinical aspects of this case, please turn to page 47.

Restorative dentistry and clinical images by W. Johnston Rowe, Jr., DDS, AAACD (Jonesboro, AR). Porcelain work by Wayne B. Payne, AAACD (San Clemente, CA). Cover photography by Michael L. Baxley (Little Rock, AR). Cover photograph shot with a Canon EOS 5D Mark II.



Preoperative



Postoperative

Thoughts on the Future of Esthetic Dentistry

An Interview with Dr. Gordon Christensen

David Eshom, DDS, AAACD

George Tysowsky, DDS, AAACD

Gordon J. Christensen, DDS, MSD, PhD, a world-renowned clinician and educator, is the cofounder of and senior consultant for Clinician's Report (CR), which offers unbiased research on thousands of dental products. He also is the director of Practical Clinical Courses (PCC), an international continuing education organization that provides courses and videos for dental professionals. In this interview, Dr. Christensen answers questions from David Eshom, DDS, AAACD, and George Tysowsky, DDS, AAACD.

Dr. Christensen will be speaking at the 28th AACD Annual Scientific Session in Washington, D.C., on May 12, 2012. Registration opens August 15, 2011.

Q: Dr. Christensen, you have been a mentor, teacher, and objective source for choosing dental materials for decades. What dental products and procedures have most impressed you over the last 20 years?

A: There have been many excellent products introduced over the years. In *Clinicians Report (CR)*, previously named *CRA*, we evaluate approximately 700 new products per year. About one out of five or six new introductions is considered to be faster, easier, better, or less expensive than those previously on the market. After observing and evaluating so many products, I have developed a type of "sixth sense" about whether a product will make it on the market.

An example from several decades ago was the air rotor



handpiece. Within a year of its introduction, nearly every dentist had abandoned belt-driven handpieces and purchased an air rotor. Some products have immediate and nearly unanimous acceptance. Other examples include resin-based composites in the early 1960s, which replaced silicate cement; and changes from zinc-phosphate cement to polycarboxylate, then to glass ionomer, then to resin-modified glass ionomer, and now on to various resin cements. In fixed prosthodontics, the porcelain-fused-to-metal (PFM) restoration was a welcome esthetic replacement for cast gold restorations. Now, all-ceramic crowns, comprising more than 50% of total crowns, are replacing PFM. Other examples over the years include light-cured resins, computer-aided design/computer-assisted manufacturing (CAD/CAM), brackets instead of bands in orthodontics, rotary and reciprocal endodontics, bone grafting, root form implants, digi-

tal radiography, and many more. Of course, there also have been many hundreds of products/techniques that have come and gone during my career.

Additionally, there are now many apparently valuable concepts that are struggling to become mainstream, including laser, in-office milling of restorations, electronic shade selection, tooth remineralization, and unconventional orthodontic procedures. When something does not gain universal acceptance rapidly, it is likely because it is perceived as not meeting the four criteria I mentioned earlier (faster, easier, better, or less expensive).

Q: You have always provided dentists with objective and unbiased information. How and why did you develop CR research?

A: In the mid-1970s, after many years of practice, teaching, and research, I concluded that dentists had very little help in determining whether new products were good, unless they bought and tried the products themselves. The formal organizational evaluating committees were slow and often did not provide conclusive information. Products had usually been on the market for several years before any evaluating groups made suggestions or commitments about them.

Additionally, scientific papers and lectures were not useful, because the "ethical" way to report scientific information at that time was to label products without the brand names (they were referred to as brand "A," "B," etc.). This information was not useful for clinicians. I was one of the first educators to break this useless protocol

by actually naming the products being tested. Some criticized this, but the profession responded very positively, and the rest is history.

About one out of five or six new introductions is considered to be faster, easier, better, or less expensive than those previously on the market.

My wife, Dr. Rella Christensen, and I started Clinical Research Associates (CRA) in 1976. She was its director for 27 years, and she is now conducting long-term research projects in the newly named Technologies, Restoratives and Caries (TRAC) portion of CR. Dr. Paul Child is the CEO of CR, and I remain highly involved as a senior consultant. The organization's publication, *Clinician's Report*, is now in about 100,000 offices monthly in nine languages and in nearly 90 countries.

Many groups have tried to emulate CRA. However, we remain as the only non-profit, non-manufacturer-supported group that evaluates products and techniques.

Q: In the current economic climate our members are looking to diversify their practices. What products and procedures do you see dentists using to keep their practices busy and profitable?

A: Dentists have moved toward much more conservative procedures and less expensive materials. Fewer crowns are being done in the U.S. Resin-based composite now constitutes about two-thirds of the posterior tooth direct restorations in the U.S., while amalgam comprises the other

one-third. Crown and ceramic veneer placement during the recession dropped significantly. Fewer full-mouth restorations are being done. There is a tendency to provide more "fixes" and fewer extensive treatment plans (personal communication with Mr. Jim Shuck, VP Sales & Marketing, Glidewell Laboratories; Newport Beach, CA; and Bennett Napier, Executive Director of the National Association of Dental Laboratories; Tallahassee, FL).

These changes can be interpreted as good or bad. In my opinion, some of it is good, since we are seeing far fewer overt over-treatment plans.

Q: Even though you serve dentists directly, you have always thought about what is best for patients. What have you seen dentistry do best for patients during the last 20 years?

A: The orientation of many schools toward more conservative therapies is laudable. Some examples are smaller tooth preparations and the instruments to make them, small-diameter implants, remineralization concepts, conservative periodontal therapy not involving surgery, endodontic treatment instead of tooth extraction, instruments to remove teeth without removing significant bone, providing "informed consent" information for patients instead of just doing whatever extensive treatment appears to be logical, emphasis on more onlays rather than crowns, and aggressive caries and periodontal disease prevention programs.

Q: What do you think dentists will be providing for patients in the next 10 years?

A: Conservative cutting of tooth structure is being promoted by schools and continuing education instructors. The more conservative trends in esthetic/cosmetic dentistry are a welcome change. There was gross over-treatment a few years ago in many areas of dentistry; this has decreased due to optimum use of tooth whitening, resin-based composite, conservative orthodontics, tooth recontouring, occlusal equilibration, and other modalities.

Some dentists believe that only extensive procedures are revenue producing for practices. In my opinion, they are wrong. Expanded use of staff for many procedures can increase revenue and free dentists for the procedures only they can do. Revenue production can be very adequate with what is termed "minimally invasive dentistry."

Q: Cosmetic dentists have done a great job of providing patients with the smiles they desire. How have these materials and procedures improved over the years and what is coming in the future?

A: Resin-based composites have improved significantly over the 50+ years they have been in use. They now simulate tooth structure well. They wear almost like tooth structure, and they have adequate strength. It is our research-supported conclusion that the major need in cosmetic/esthetic dentistry and in some other areas of dentistry is not the materials. The challenge is having dentists develop enough speed and clinical expertise to use the materials to an optimum level.

There is too much to teach and to learn in dental school. Continuing education, study clubs, experienced mentors, self-learning, and whatever mode of education is most attractive and useful for specific dentists are needed to overcome the challenge to develop clinical excellence.

The ongoing development of new technologies will continue to assist in creating high-quality dental treatment. Better use of implants will continue to satisfy

The challenge is having dentists develop enough speed and clinical expertise to use the materials to an optimum level.

clinical challenges not treatable in the past.

Q: What can cosmetic dentists do to improve service to patients?

A: The significant areas that need improvement in cosmetic/esthetic dentistry are clear to me:

- Full information about proposed treatment plans should be provided to each patient so that they can give informed consent. Almost every treatment plan has several levels of aggressiveness. Patients need to be able to select the level they desire.
- The AACD has done an admirable job in educating dentists about cosmetic procedures and providing ways to enhance their qualifications. This should be continued and increased.



Attendees at the 27th Annual AACD Scientific Session in Boston, May 2011.

- Flagrant over-advertising should be discouraged. It is disheartening to see the self-aggrandizement that is present in many ads. Quality treatment, complete patient education, and excellent patient public relations—not self-promotion, build practices.

Although new concepts are coming, current materials, devices, and techniques are excellent. I would like to see an emphasis on proper, excellent use of the ever-evolving concepts in cosmetic dentistry.

Q: What new products are on the brink of changing the way we practice dentistry?

A: The change from PFM to all-ceramic restorations, and especially the increasing use of zirconia and lithium disilicate for crowns and fixed prostheses, will change much of restorative dentistry in the immediate future. Although refinements are necessary, I see the replacement of the “metal” age in dentistry coming soon.

The orientation of many schools toward more conservative therapies is laudable.

In-office CAD/CAM and in-lab dentistry are taking over. The lost-wax restoration concept is dying. Restorative dentistry in the future will have a major technological orientation.

In summary, people will not cease eating foods and drinking beverages that promote caries. They continue to NOT clean their teeth. It is well known that periodontal disease at a moderate to severe level is present in about 35% of the adult population. It has yet to have a cure. Bruxism and clenching are present in about one-third of the population, without a cure. In other words, dentistry is not going away. It is older than Biblical writings (gnashing of teeth) and needs for oral treatment will probably extend into another millennia. **jCD**



Dr. Christensen is an adjunct professor at Brigham Young University and the University of Utah. A Diplomate of the American Board of Prosthodontics, he has a private prosthodontics practice in Provo, Utah.

Disclosure: Dr. Christensen is cofounder and senior consultant for the CR Foundation, which publishes *Clinician's Report*.



Dr. Eshom is an Accredited Member of the AACD, and co-chair of the AACD Professional Education Committee. He has a private practice in San Diego, California.



Dr. Tysowsky is clinical assistant professor at the State University of New York at Buffalo, School of Dental Medicine. He is an Accredited Member of the AACD, and co-chair of the AACD Professional Education Committee.

Together Strong

Giving Back with CAD/CAM Dentistry

Thomas W. Monahan, III, DMD

The AACD Charitable Foundation's Give Back a Smile™ (GBAS) program restores the smiles of domestic violence survivors at no cost. In response to crucial volunteer feedback, the GBAS guidelines have been updated to move away from full-mouth reconstruction cases and focus on injuries incurred to the smile zone. This section shares the triumphs of the GBAS program. Please visit www.givebackasmile.com for more information on how you can help restore a smile.

Case Presentation

Patient History

The AACD's Give Back a Smile (GBAS) program contacted my office about a survivor of domestic violence. The information described a 10-year abusive relationship resulting in, among other problems, several broken and missing teeth and facial scarring (Fig 1). The woman had been drug-free and away from her abuser for five years. Additional information indicated a potential problem with transportation; it was a four-and-a-half hour round trip to my office in Albany, Georgia, from her home in the Florida Panhandle.

Findings

"Katie" came to our office in August 2009 for an initial examination. She was introverted, nervous, and depressed but seemed desperate for someone to help her (Fig 1). She stated that she felt hopeless—her teeth were ugly, she had trouble chewing food, her front teeth kept breaking, and she wanted to be able to smile again. During her examination, records, diagnostic models, radiographs and photographs were taken. Severe wear and separation were present on ##7-10, with failing restorations on #3 and #11. There were only three posterior teeth remaining in the maxillary arch. No posterior teeth occluded with any mandibular teeth. Incisal wear was present on the mandibular anteriors, there was a loss of cuspids, and most of the posterior teeth presented problems (Figs 2 & 3).

The separation between ##7-10 could potentially cause problems with smile restoration from a tissue management perspective. In terms of occlusion, ##8-10 were striking ##23-26. This had caused wear and chipping fractures on the maxillary and mandibular anterior teeth. She had only six mandibular teeth and was missing her mandibular cuspids. Tooth #23 was the most posterior tooth on the mandibular left side. She had a totally collapsed occlusion, super-erupted teeth, wear and separation of the anterior teeth. Overall, the general tissue health seemed good on the remaining teeth (Figs 4 & 5). The case was mounted. The more I studied her models, the more I wanted to do this full-mouth case with computer-aided design/computer-assisted manufacturing (CAD/CAM) technology.



Treatment Plan

For this complicated case, the most critical element would be the amount of increased vertical dimension of occlusion (VDO) that could be achieved (Figs 4-6). If a solid centric occlusion could be established, things should be fine.¹ Even though there was a wax-up, designing this milling case would prove challenging as there were no occlusal references and no teeth distal to #6 and #11. Provisionals would be placed for ##6-11 and ##23-26 and then a temporary mandibular acrylic partial would be placed. This would open the VDO while protecting the anterior provisionals and allow for the designing of #29 and #31. The patient's lower lip determined the anterior length of ##6-11. Due to the size of ##23-26, it was decided it would be best to press and layer these porcelain crowns using e.max (Ivoclar Vivadent; Amherst, NY). Except for ##23-26, all other porcelain would be designed using a Cerec Acquisition Unit (Sirona; Charlotte, NC). A maxillary acrylic retained partial would replace #4, #5, and #12. An implant-retained mandibular cast partial would replace ##18-22, #27, #28, and #30. Two implants would need to be placed on the left side for #19 and #22. Teeth #29 and #31 would be used if it were possible to get the necessary reduction on these teeth for clasp assemblies. Lingual rest was also planned for ##23-26, resting on the patient's natural teeth and not on the planned porcelain. Treatment for this full-mouth rehabilitation would require a team effort and would take place over an extended period of time.

Concerns

The main concern was patient compliance. This would be an extensive restorative case needing multiple dental visits. The patient's round-trip travel time of more than four hours could present a problem in her commitment to complete the case. The treatment plan was explained to the patient and she gave assurances that she would attend every appointment.

The second concern was obtaining the assistance required to complete this case: finding a periodontist to place the implants, and two laboratories—one for the porcelain phase and one for the partial phase. Fortunately, there was no problem getting the necessary help once those approached were made aware of the GBAS program and visited the AACD Web site. The team to give Katie back her smile comprised periodontist Dr. Holland Wright (Albany; GA), Strom Dental Lab (Albany, GA; porcelain phase), and Albany Dental Lab (Albany, GA; partial phase). They volunteered and donated all their materials and services for this collaborative case. Porcelain e-max blocks (shade BL 3) were donated by Patterson Dental (Marietta, GA).

Treatment

Provisionals and Laboratory Phase

In November 2009, Dr. Wright placed two Straumann RN SL implants (Andover, MA) at #19 and #22. He required a waiting period of at least two months for healing. Then the temporary mandibular acrylic partial would be placed in order to open the VDO.

During the healing period, the porcelain phase was initiated. The tissue in the maxillary anterior region was not level, so tissue on ##6-11 was contoured with an Odyssey 2.4 G diode laser (Ivoclar

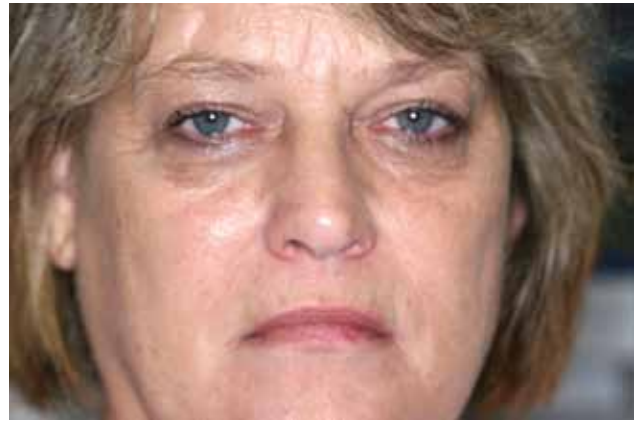

Figure 1: Initial visit.

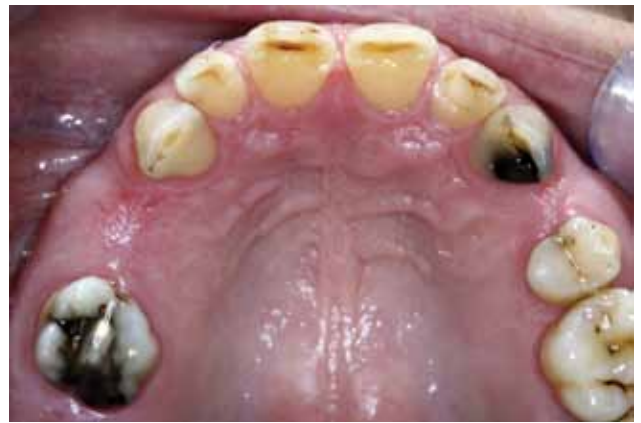

Figure 2: Occlusal view of maxillary arch.

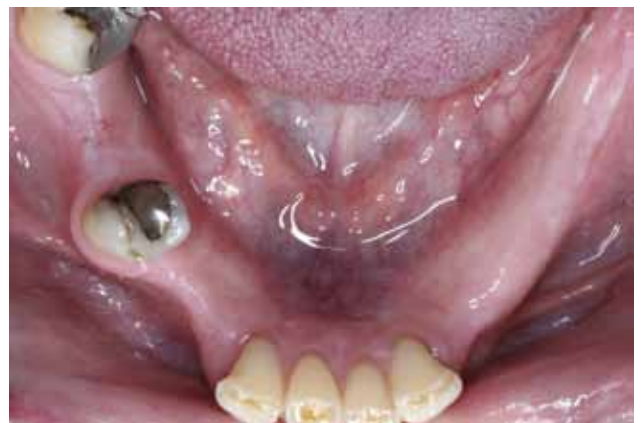

Figure 3: Occlusal view of mandibular arch.

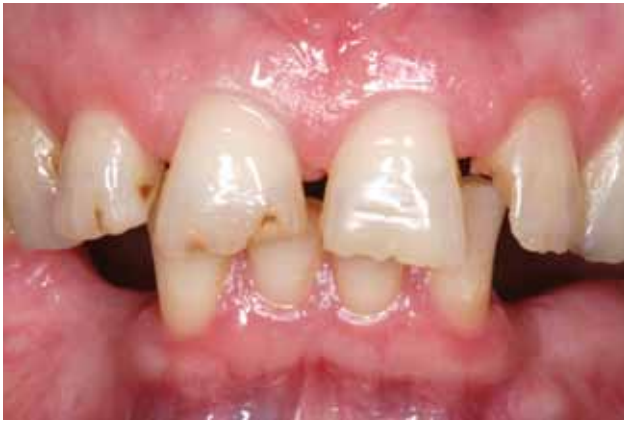

Figure 4: Centric occlusion before treatment.

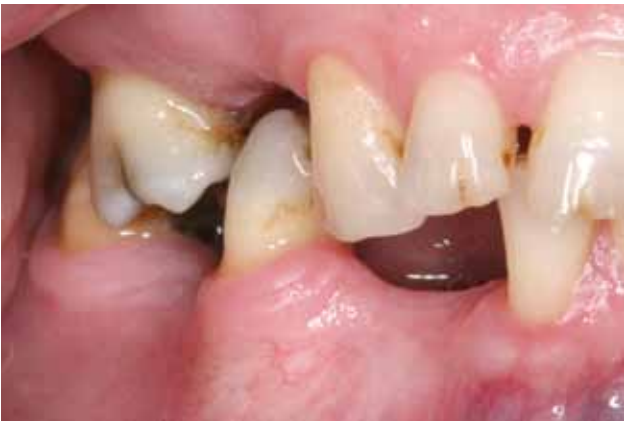

Figure 5: Teeth #3, #29, and #31 were super-erupted.

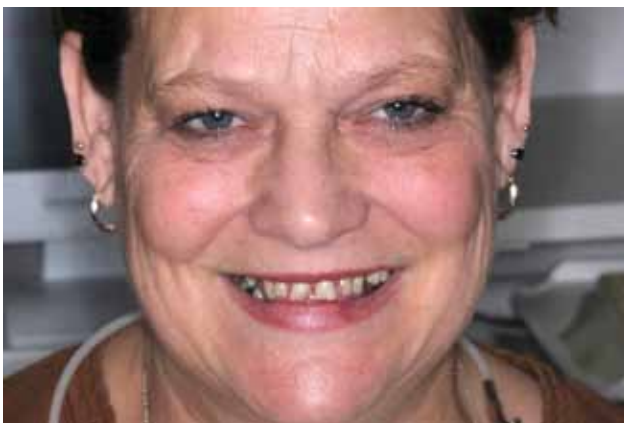

Figure 6: Pre-treatment smile.

She stated that she felt hopeless—her teeth were ugly, she had trouble chewing food, her front teeth kept breaking, and she wanted to be able to smile again.

Vivadent); teeth were prepared and provisionals placed on ##23-26 without preparation using Luxatemp Fluorescence (DMG America; Englewood, NJ). Strom Dental Lab received the temporary mandibular acrylic partial, which was used to open the vertical and protect the anterior provisionals. The patient was instructed that she must wear this partial at all times and that she would have to wear the final partials at all times after her case was completed. She was overjoyed with her provisionals, exclaiming, "I have teeth!"

Katie returned in February 2010, to prepare and impress #3, ##6-11 and #13. Provisionals for ##6-11 were remade, provisionals for #3 and #13 were constructed, and all were temporarily cemented. One week later, the Luxatemp on ##23-26 was removed; then ##23-26, #29 and #31 were prepared and impressed for porcelain restorations. The provisionals were placed with temporary cement.

The porcelain phase of treatment consisted of 14 units of e.max porcelain. Ten units were planned for Cerec CAD/CAM.^{2,3} Due to the complexity of this case and my experience mostly with bicuspid and molar areas, I decided to design all the porcelain on models. The only exception was the preparations on ##23-26. Due to their size it was decided to have these porcelains pressed and layered. To create the porcelain on ##6-11, the esthetic wax-up was used as a guide, making the teeth 1 mm longer than the wax-up to give room to shape the teeth to the desired length in the mouth.⁴ The designs of the porcelains on a Cerec AC Unit were downloaded and delivered to Strom Dental Lab via flash drive. All the porcelain except ##23-26 was returned after milling in the blue stage (pre-crystallized state) for try in (Fig 7).

After the try-in appointment, the e.max crowns were returned to the laboratory to be crystallized, stained, and, in the case of ##6-11, layered.

Seating

At the patient's next appointment, in April 2010, all porcelain restorations were seated. For the anterior teeth, Optibond FL (Kerr; Orange, CA) and Variolink veneer cement (Ivoclar Vivadent) were used and for the posterior teeth Multilink (Ivoclar Vivadent) was used. The abutments were torqued in at #19 and #22. The patient was instructed to continue wearing the provisional mandibular acrylic partial to protect the porcelain and to open the VDO (Figs 8 & 9). Impressions were taken to fabricate a maxillary acrylic-retained partial for #4, #5 and #12; and an implant-retained mandibular cast partial for ##18-22, #27, #28, and #30. The impressions were sent to Albany Dental Lab.

Three weeks later Katie returned to my office and both the maxillary and mandibular partials were seated with minor adjustments. Locators were placed for abutments on sites #19 and #21, and clasp assemblies on #29 and #31 (Figs 10-13).

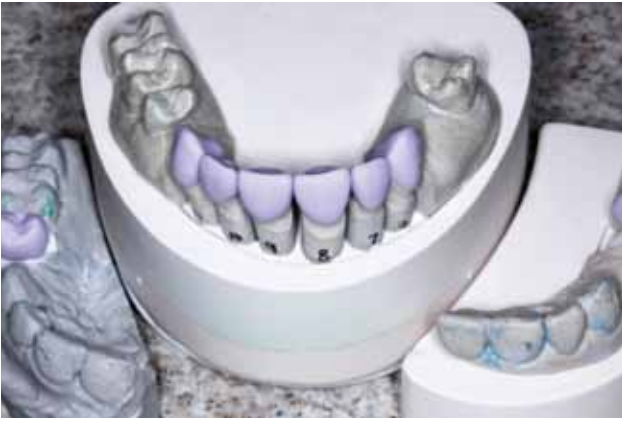

Figure 7: After milling in the blue stage (pre-crystallized state).

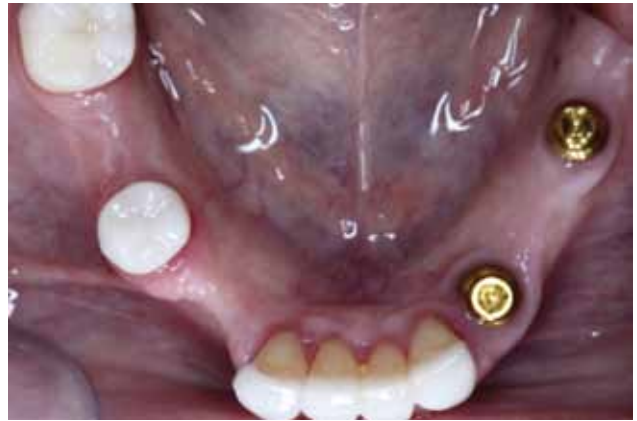

Figure 8: Porcelain seated on the mandibular teeth and abutments torqued in on #19 and #22.

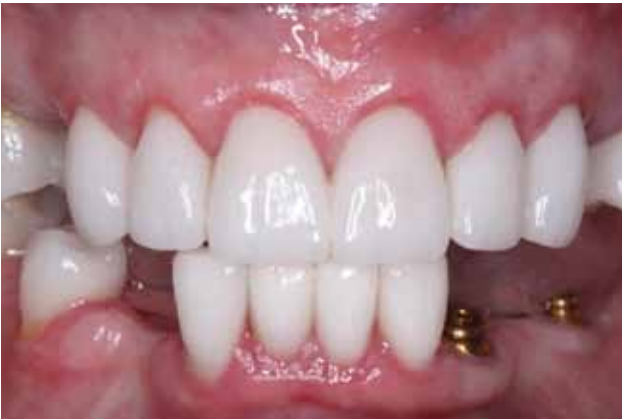

Figure 9: All porcelain seated on the same visit.

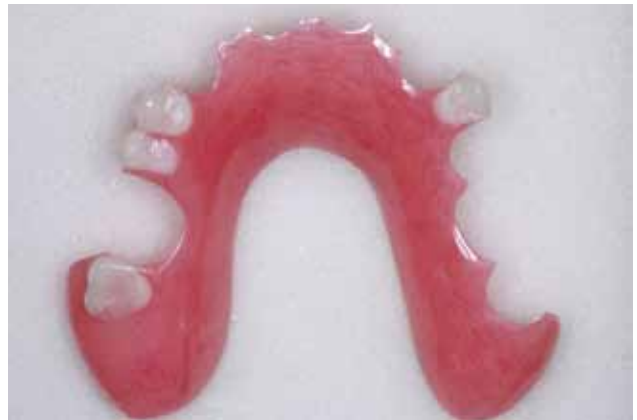

Figure 10: Maxillary acrylic partial.

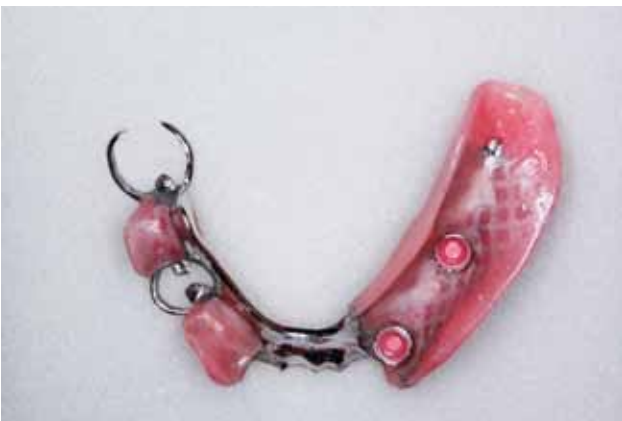

Figure 11: Implant-retained mandibular cast partial.

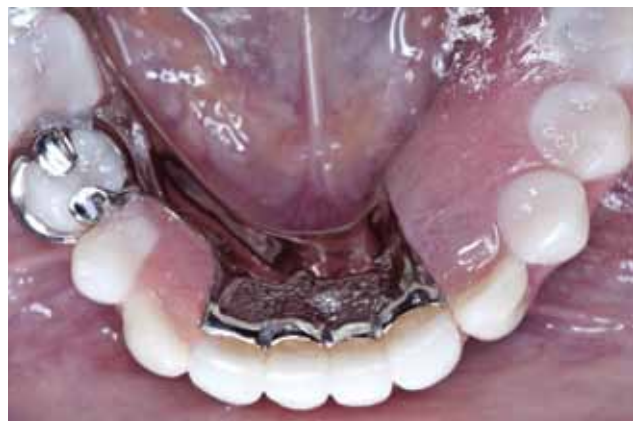

Figure 12: Seated implant-retained mandibular cast partial with clasp assemblies.

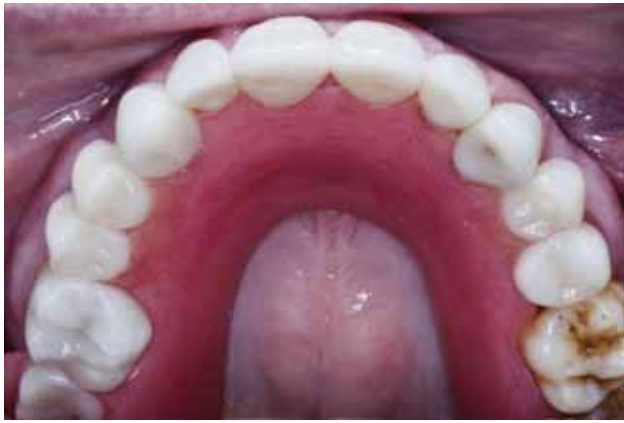

Figure 13: Seated maxillary acrylic partial.

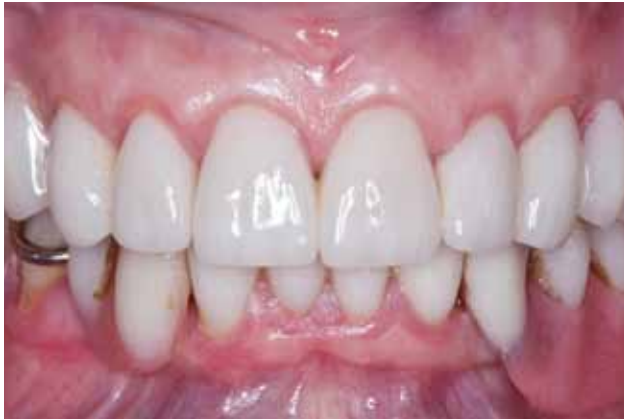

Figure 14: Two weeks postoperative.



Figures 15: The happy patient with her new smile.

Postoperative

At the postoperative check appointment, further instruction was needed on the maintenance of her partials for adequate cleaning (**Fig 14**). At this time, other photographs were taken. Katie looked like a different person and was extremely happy (**Fig 15**).

She came in for a six-month follow-up appointment and to take final photographs in January 2011. Tissue response was very good. Minor adjustments were made to her partials and her bite.

Rewards

What a personality change in this patient! Would I do another case milling the entire mouth? Probably not, but it was fun doing this case, while giving back to GBAS.

This was a great team effort and all involved have been very pleased with the final result, especially the patient. She has taken good care of her new smile; it is obvious she truly values it. Very often, the dentistry that can really make a difference in a person's life is needed by the people who can least afford it. This is a case I will never forget.

References

1. Kois JC, Phillips KM. Occlusal vertical dimension: alteration concerns. *Compend Contin Educ Dent*. 1997 Dec;18(12):1169-74, 1176-7; quiz 1180.
2. Klim J. Chairside CAD/CAM aesthetic restorations. *Australasian Dent Pract*. 2009 Nov/Dec;146-56.
3. Touchstone A, Nieting T, Ulmer N. Digital transition: the collaboration between dentists and laboratory technicians on CAD/CAM restorations. *J Am Dent Assoc*. 2010 Jun;141 Suppl 2:15S-9S.
4. Magne P, Belser U. Bonded porcelain restorations in the anterior dentition: a biomimetic approach. Hanover Park (IL): Quintessence Pub.; 2002. **jCD**

Very often, the dentistry that can really make a difference in a person's life is needed by the people who can least afford it.



Dr. Monahan graduated from the Medical College of Georgia, School of Dentistry in 1973. He has a comprehensive and cosmetic practice in Albany, Georgia.

Disclosure: The author did not report any disclosures.

Experience the Beauty and Precision!

Three World-Class Leaders in Dental Technology combine to give your patients the aesthetic and high strength all-ceramic restorative solutions they demand.

Aurum Ceramic® Dental Laboratories

The leader in digital technologies for Comprehensive Aesthetic and Implant Dentistry. Offering unique optical techniques that create the ultimate IPS e.max® CAD result. Partnering with Core 3d™ Centres to provide unsurpassed accuracy, beauty and communication.

Core 3d™ Centres

The global leader in digitally advanced, five-axis milling technology for premium restorations. Officially validated with Ivoclar Vivadent Inc.

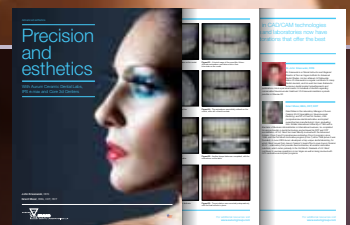
IPS e.max® CAD

Beautiful, durable all-ceramic monolithic restorations. Perfect for everything from single units to full mouth aesthetic cases.

See the difference for yourself!

Download our reprint of a Case Study (including laboratory/clinical protocols and pictorial review) to see the beauty and precision that can be achieved with IPS e.max® CAD milled by Core 3d™!

Visit www.emaxfromcore3d.com/article



NEVADA, UTAH, COLORADO AND ARIZONA: 1-877-254-5334
WASHINGTON, OREGON, MONTANA AND IDAHO: 1-800-423-6509
OTHER NORTH AMERICAN LOCATIONS: 1-800-661-1169
www.aurumgroup.com

Changing Appearance to Improve Function

Accreditation Clinical Case Report, Case Type I: Six or More Indirect Restorations

Naoki Ned Shimizu, DDS, AAACD

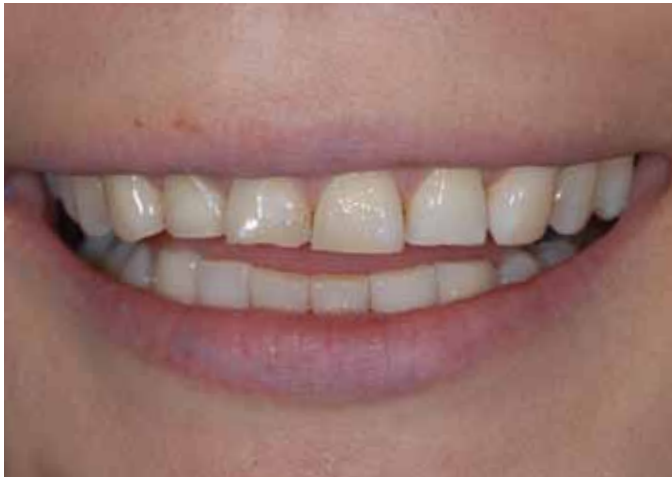

Figure 1: Preoperative smile.

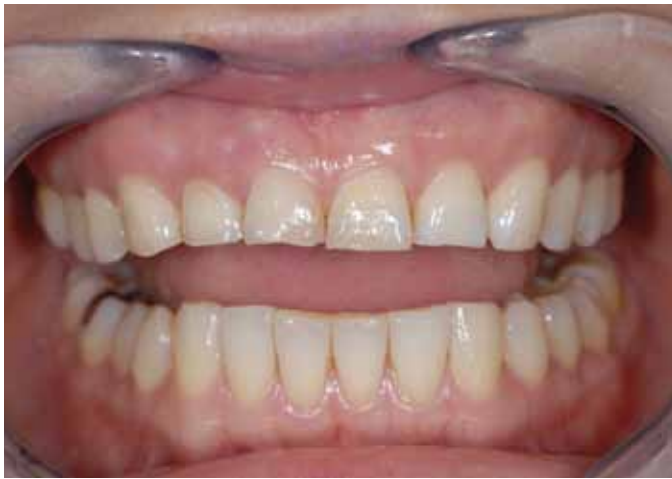

Figure 2: Preoperative retracted frontal view.

Introduction

Due to advances in dental technology, materials, and techniques, dentists can now help people to change their appearance and improve their function. Another benefit to such dental treatment is that patients' self-esteem or even their lives can be affected in a most positive way.

Patient History

The patient, a 35-year-old female, had a great deal of wear on her upper front teeth and she wanted a perfect smile. She was in excellent health. There was incisal and lingual wear on ##6-11, as well as occlusal wear on #5 and #12. Teeth ##7-9 had had root canal treatments and post buildups. Gingival heights were uneven and #10 appeared too wide compared to #7. The patient wanted longer teeth that would function well, and an attractive smile (Figs 1-4).

The oral hygiene and soft and hard tissue health were in good condition. All pocket depths were 2.5 to 3.0 mm. Radiographic and oral cancer examinations were within normal limits. Teeth ##7-9 had been endodontically treated, but there were no symptoms or apical lesions. There was no temporomandibular joint pain, clicking, or popping. She had never had extensive restorative dental treatment. The chief concerns were the occlusion and the etiology of the wear. There was no history of bulimia or perimolysis.

The primary issues that required attention prior to definitive restoration were tooth wear, gingival heights, and the width of #10.

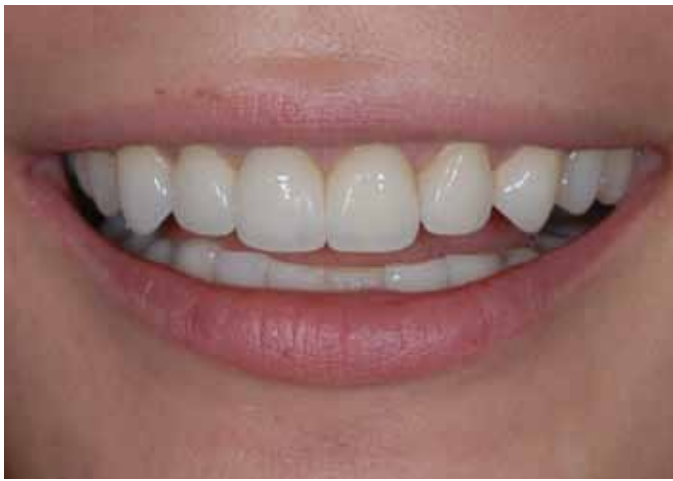

Figure 3: Postoperative smile.

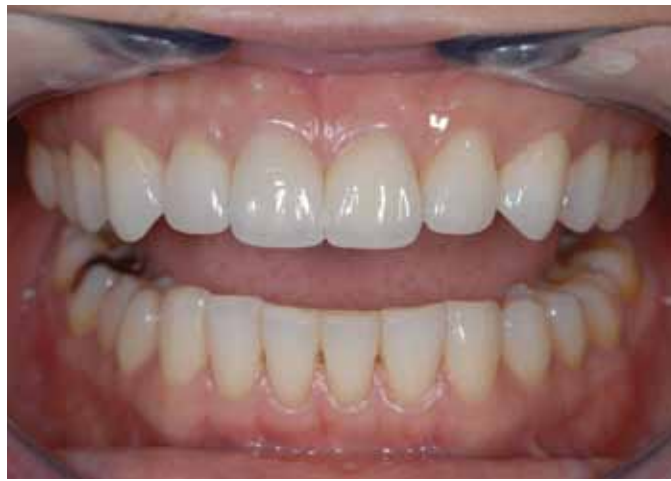

Figure 4: Postoperative retracted frontal view.

Diagnosis and Treatment Plan

The patient was in good dental health except for the anterior tooth wear. Full diagnostic data, including x-rays, study models, earless facebow transfer (Panadent; Colton, CA), centric relation (CR) records using NTI (NTI-TSS, Inc.; Mishawaka, IN), digital photographs using a Nikon D200 camera with 60-mm macro (Nikon; Tokyo, Japan) and periodontal probing chart were taken. The models were mounted on a Stratos 300 articulator (Ivoclar Vivadent; Amherst, NY) and checked for occlusal discrepancy. Premature contacts were noted on the first and second molars on both sides (Figs 5 & 6).

To achieve the best combination of strength and esthetics, it was decided to place e.max crowns (Ivoclar Vivadent) on ##5-12. A diagnostic wax-up was necessary to evaluate the teeth size and shape and evaluate the gingival levels.^{1,2} Prior to restorative treatment, the following procedures were performed: gingivectomy on ##6-9, and occlusal adjustments. In order to make #10 narrower, directional preparations were performed. The distal of #8 and the mesial of #9 were prepared more aggressively than the contralateral side so that the final restorations could be shifted to the left to make #10 narrower (Fig 7).³

Treatment

The primary issues that required attention prior to definitive restoration were tooth wear, gingival heights, and the width of #10. To properly analyze these problems, a CR bite was taken with the help of an NTI appliance. The patient wore the NTI the night before in order to deprogram her habitual occlusion, and a CR bite was taken. The case was mounted on the articulator using an earless facebow. The premature contacts were noted at the molar areas. At the next appointment, all premature contacts were removed and a gingivectomy was performed on ##6-9. A

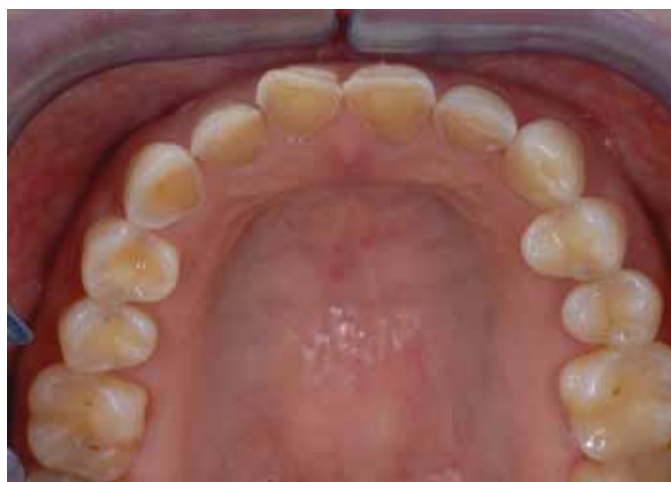

Figure 5: Preoperative occlusal view.

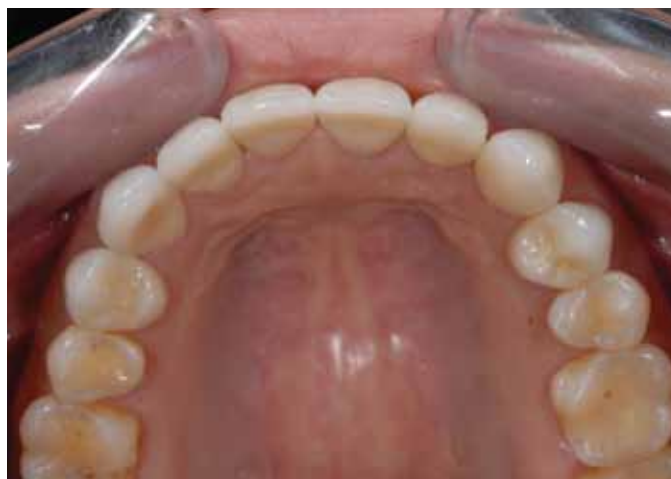

Figure 6: Postoperative occlusal view.

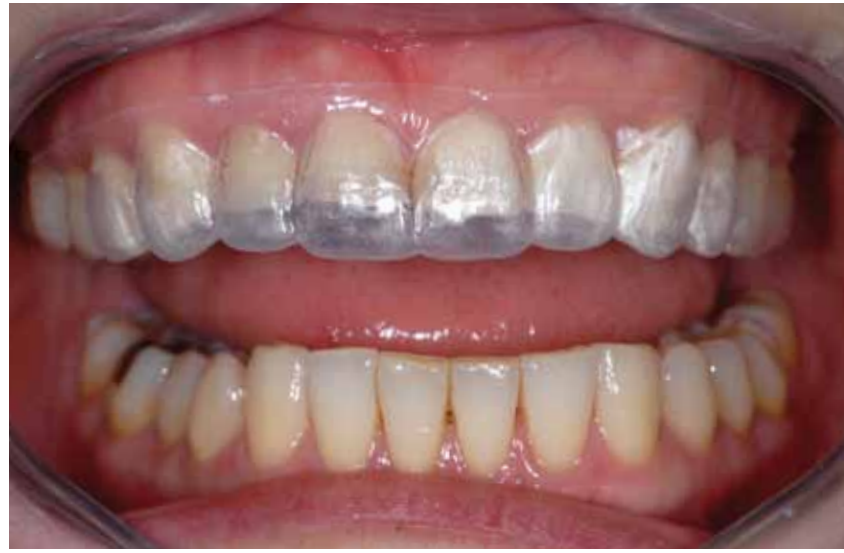

Figure 7: Clear matrix from the diagnostic wax-up placed **prior** to preparation.

mock-up was done with Luxatemp (DMG; Englewood, NJ) in the patient's mouth using the clear matrix from the diagnostic wax-up.^{4,5} The patient needed some time to get used to the changes resulting from the occlusal adjustments and the gingivectomy. Four days later, the occlusion was checked for proper anterior protrusive guidance and canine guidance. The occlusion was ideal and the patient was very comfortable. The final preparation appointment was scheduled for two weeks later.

Preparation Appointment

At the preparation appointment, the mock-up was evaluated for function and esthetics. The patient was satisfied with the mock-up, and the gingival architecture and health were significantly improved. The shade selection was performed at the beginning of the appointment. The patient wanted teeth that were natural looking and not too white. Shade 01/110-1A/120 was chosen for ##7-10, #5, and #12; and 1A/120 was selected for #6 and #11 using the Chromascop shade guide (Ivoclar Vivadent). Shade photographs were taken before dehydration of the teeth from different angles with and without the shade tabs.^{6,7} After the area was anesthetized using 2% lidocaine with 1:100,000 epinephrine, the teeth were prepared using the mock-up as a guide to create 0.8 to 1.0-mm reduction at the facial and 0.5 mm at the gingival area. Occlusal clearance was 0.8 to 1.0 mm. The clear matrix was used to check for sufficient clearance (Fig 8).^{8,9}

After the final preparations were completed, all the teeth were polished with fine polishing burs (Brasseler USA; Savannah, GA). Several #8 Pascord (Pascal; Bellevue, WA) cords with Hemodent (Premier Dental; Plymouth Meeting, PA) were placed and the impression was taken with Impregum (3M ESPE; St. Paul, MN). A stick bite was taken to verify that the incisal

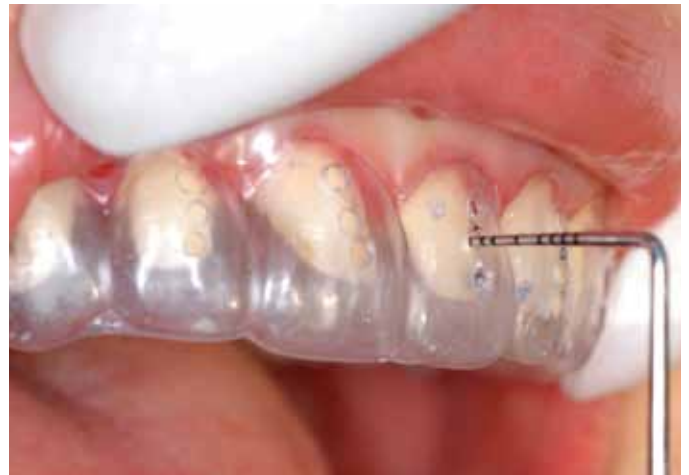

Figure 8: Verifying that reduction was adequate using the clear matrix and perio probe.

The patient was satisfied with the mock-up, and the gingival architecture and health were significantly improved.

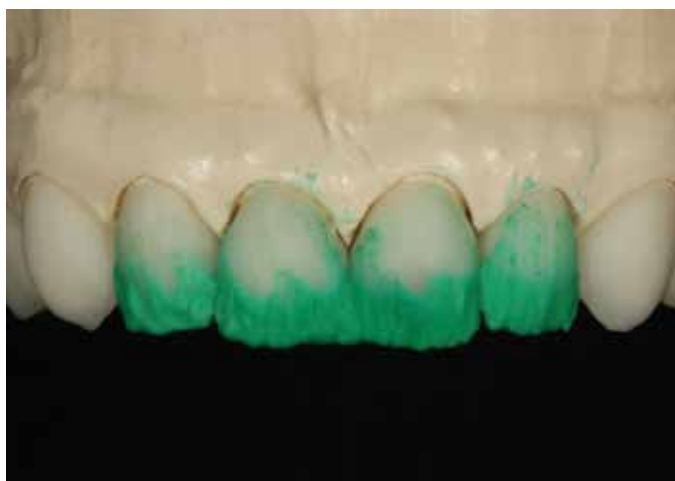

Figure 9: Incisal bake.

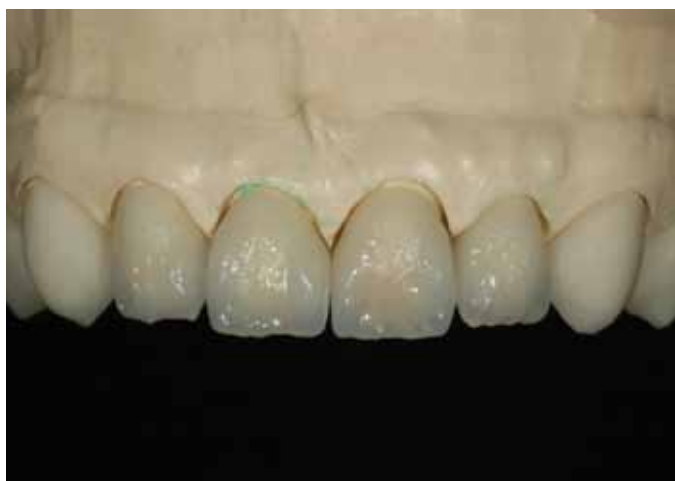

Figure 10: First firing.

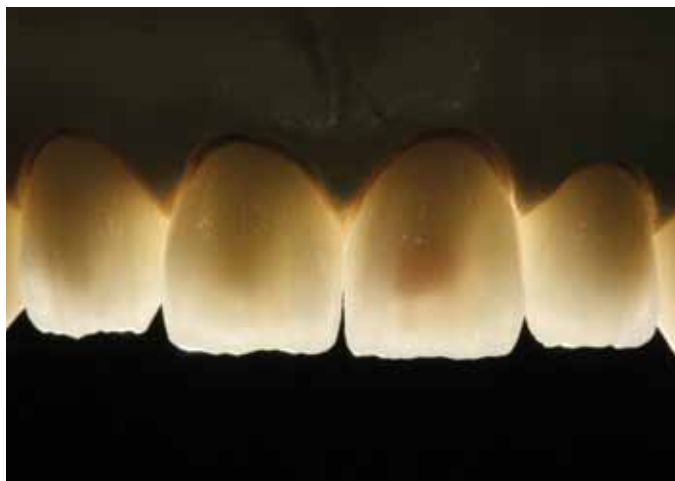

Figure 11: Illuminated translucence.

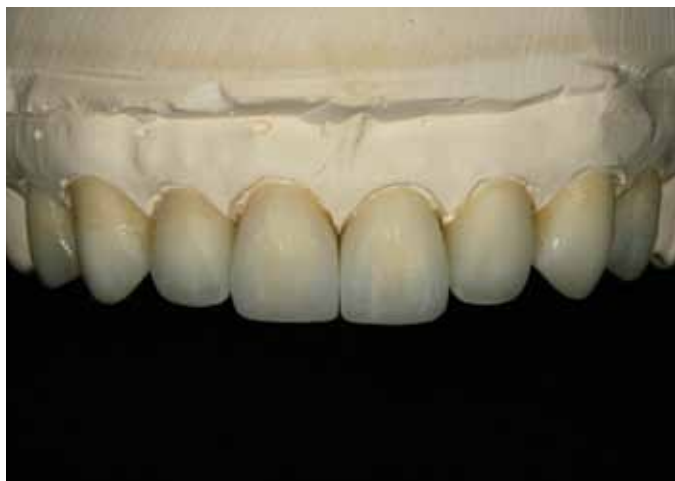

Figure 12: Bisque evaluation.

edges would be parallel with the horizon. The ST9 stump shade was selected for #5 and #7-12, and shade ST1 was chosen for #6 with a stump material shade guide (Ivoclar Vivadent). Photographs of the stick bite and the stump shade were taken. The centric occlusion (CO) bite was taken using Virtual Bite Registration (Ivoclar Vivadent). Provisionals were made with Luxatemp using the clear matrix from the wax-up and cemented with TempBond Clear (Kerr; Orange, CA).⁴ The bite was checked

with articulating paper and adjusted. The earless facebow record was taken with the provisionals, and photographs of the facebow in place were taken. Upper and lower impressions were made with Virtual Monophase Fast-set (Ivoclar Vivadent). CO bite registration with the provisionals was taken with Virtual Bite Registration. Oral hygiene instructions were given to the patient. The patient was asked to use superfloss and hydrogen peroxide irrigation in addition to regular brushing.

The following day, the patient came back for the bite and esthetic check. She was satisfied with the result and several photographs were taken of the provisionals because she was not numb anymore and we could see her natural smile line.

Laboratory Instructions

The patient, doctor, and staff all determined that shade 01/110-1A/120 would be used in fabricating the new restorations.

A complete laboratory prescription with the following items was sent to the laboratory:

- earless facebow
- two sets of master impressions (upper)
- opposing impressions
- stick bite with preparations
- impression of provisionals
- color map drawing
- length of the teeth.

All photographs, including the following, were mailed to the laboratory:

- preoperative smile, full-face, and profile
- desired shade with Chromascope shade guide being held near various teeth (01/110 and 1A/120)
- prepared teeth with stump shade guide being held near various teeth (St1 and St9)
- stick bite
- facebow
- smile with provisional crowns
- bite registration.

Cementation

During the three weeks that the case was fabricated in the laboratory, there was significant communication with the ceramist via telephone and e-mail. This allowed for a better understanding of the case. It was especially helpful to have the laboratory technician check the bisque bake stage of the restorations (Figs 9-12).⁹

When the case was returned from the laboratory, prior to scheduling the patient, all the restorations were checked for fracture, length, shade, and shape to prevent any possible problem that might arise. The case was sent back before the patient's appointment to have minor changes made.

On the day of cementation, the patient was anesthetized. Provisionals were removed with a small spoon excavator. The provisionals popped off easily. The prepared teeth were cleaned with chlorhexidine and hydrogen peroxide and lightly pumiced. The restorations' fit was checked one at a time, two by two, and then all together to verify fit of proximal contacts. After this, only canines were placed to check the occlusal contacts. Adjustments were done with fine burs (Brasseler USA) and polished with a silicone wheel (Shofu; San Marcos, CA). After the first try in, the resulting gum level around #9 was found not to be ideal. Bone sounding was performed. A limited site crown lengthening procedure was completed to balance the periodontal architecture with respect to the biological width. Tooth #9 was prepared again and an impression was taken. Restorations for #8 and #9 were re-made (Figs 13-15).

When all the adjustments were finished, translucent try-in paste was used to verify the shade and the patient's esthetic approval was obtained. Crowns were cleaned and acidified with 37% phosphoric acid, silanated for 60 seconds, and air-dried. Crowns were coated with Excite (Ivoclar Vivadent) and air-

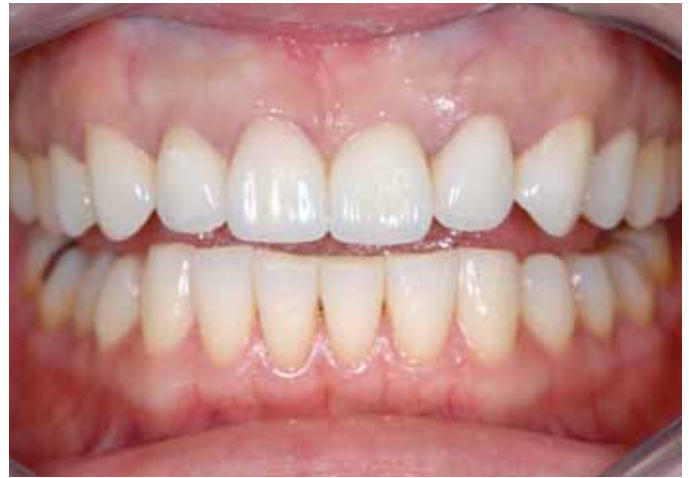

Figure 13: At the first try in, note the gingival height discrepancies and asymmetries on #8, #9, and #10.

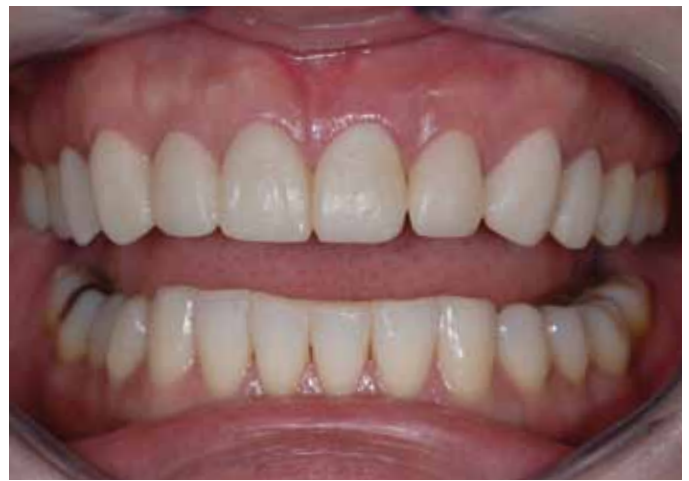

Figure 14: Provisional restorations after flapless crown lengthening.

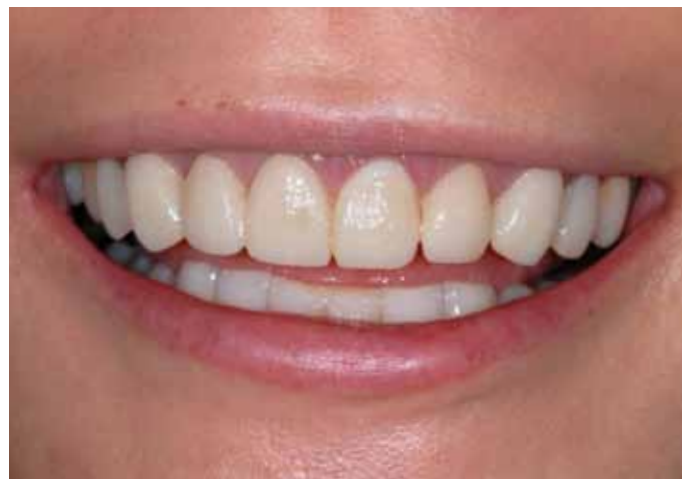

Figure 15: Frontal smile, 1:2 view, with second set of provisional restorations.



Figure 16: Preoperative portrait.

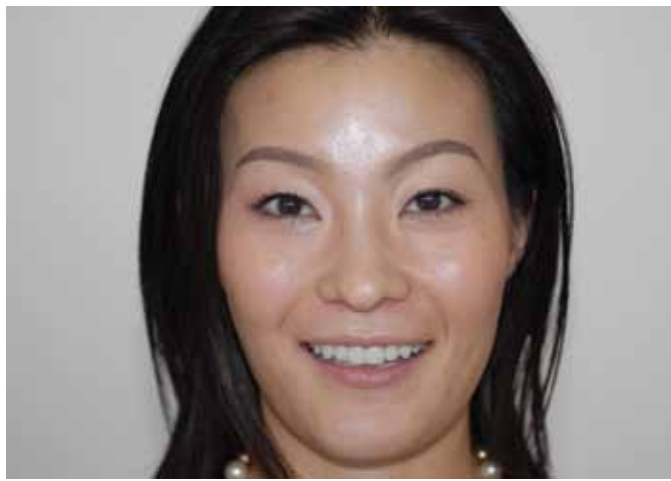


Figure 17: Postoperative portrait.

dried, then Variolink Veneer (Ivoclar Vivadent) translucent shade was placed in the crowns. The crowns were placed in a light-secure box (Vivapad, Ivoclar Vivadent). A rubber dam was placed before seating. Then all teeth were etched (three at a time to avoid over-etching), Systemp. desensitizer (Ivoclar Vivadent) was applied and blot-dried, then two coats of Excite were applied. All the prepared teeth were air-dried with an ADEC air dryer, and light-cured for 20 seconds per tooth. All crowns were seated starting with centrals, then laterals, cuspids, and bicuspids.

The tack and wave technique³ was used to light-cure the bonding cement and then excess cement was removed before completely cured. Contacts were opened by dental floss and the margins were coated by Oxyguard (Kuraray; Tokyo, Japan) All crowns were light-cured by bluephase 16i (Ivoclar Vivadent) from the lingual and facial aspects for 40 seconds each. The Oxyguard was removed and contacts were cleaned with the dental floss and Epitex finishing strips (GC America; Alsip, IL). Where needed, #12 surgical blades (Patterson Dental; St. Paul, MN) were used to clean the excess. The rubber dam was removed and the occlusion was adjusted with occlusal paper and fine diamonds and then the restorations were polished. Postoperative instructions were given to the patient.

Three days later, the patient was seen for a postoperative check. She was extremely happy with the comfortable bite and the esthetic result.

SUMMARY

All-ceramic restorations are the most natural and lifelike advanced restorative materials. By using these materials and techniques, dentists can offer more choices in restoring a smile esthetically with function. The positive impact that den-

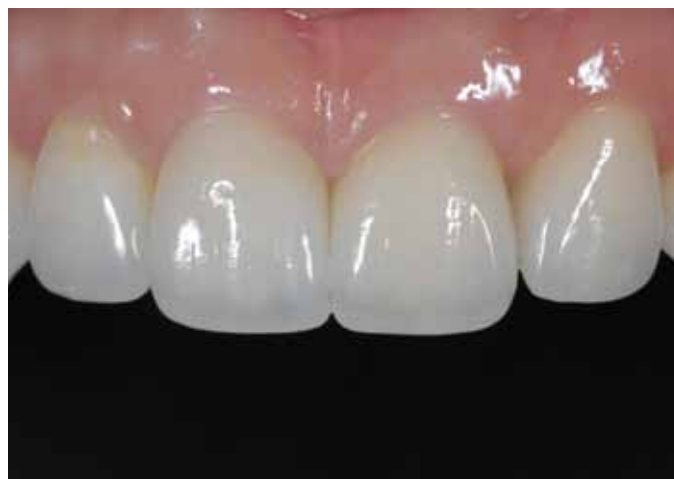

Figure 18: Postoperative 1:1 frontal view.

The positive impact that dentists can have on patients' lives is enormous.

tists can have on patients' lives is enormous (Figs 16-18).

The patient was extremely happy with her new uniform white smile and natural appearance; the result was beyond her expectations. Her three-year-old twin daughters were very excited to see their mother's new smile and said, "Wow! What happened? Who did it?" Maybe in the future, one of them will become a cosmetic dentist!

Acknowledgment

The author thanks ceramist Erik R. Haupt, AAACD (Haupt Dental Lab; Brea, CA), for his expertise in fabricating beautiful restorations.

References

1. Chiche GJ, Pinault A. Esthetics of anterior fixed prosthodontics. Hanover Park (IL): Quintessence; 1995. p. 13-73.
2. Cohen M, Chiche GJ. Interdisciplinary treatment planning. Hanover Park (IL): Quintessence; 2008. p. 2-31.
3. Kois J. Functional occlusion: science-driven management. J Cosmetic Dent. 2007;23(3):54-7.
4. Hollar S. The "trial smile" experience. J Cosmetic Dent. 2008;24(3):106-10.
5. Peyton JH, Arnold JF. Six or more direct resin veneers case for Accreditation: hands-on typodont exercise. J Cosmetic Dent. 2008;24(3):38-48.
6. Fahl N Jr. Mastering composite artistry to create anterior masterpieces, part 1. J Cosmetic Dent. 2010;26(3):56-68.
7. Fahl N Jr. Mastering composite artistry to create anterior masterpieces, part 2. J Cosmetic Dent. 2010;26(4):42-55.
8. Magne P, Belser U. Bonded porcelain restorations in the anterior dentition. Hanover Park (IL): Quintessence; 2002. p. 240-64.
9. Phelan S. Conservative porcelain veneer techniques guided by three different preparation stents. J Cosmetic Dent. 2008;24(3):181-8.

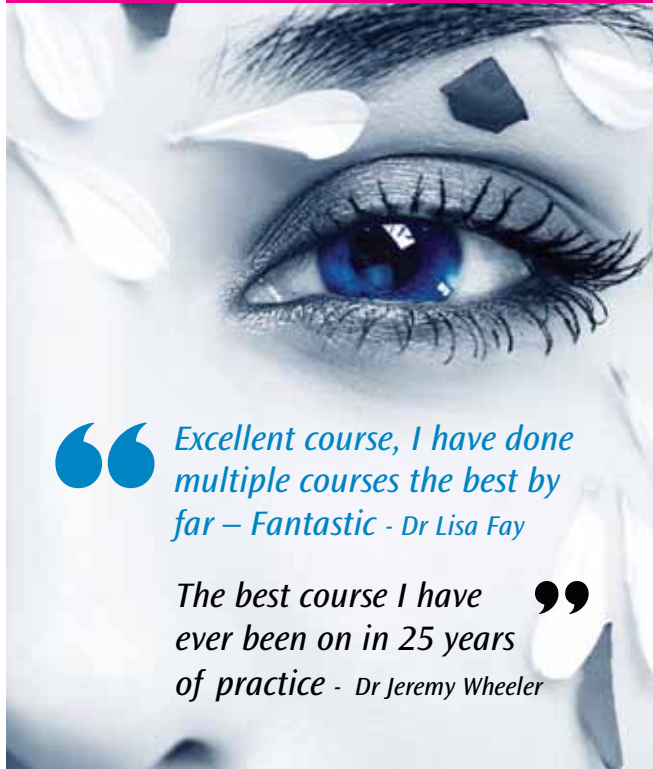jCD



Dr. Shimizu graduated from Loma Linda University in 1997 after seven years of practice in Japan. He owns a practice in Houston, Texas.

Disclosure: The author did not report any disclosures.

THE UK'S No.1 FACIAL AESTHETIC COURSES



“Excellent course, I have done multiple courses the best by far – Fantastic - Dr Lisa Fay

The best course I have ever been on in 25 years of practice - Dr Jeremy Wheeler”

The ORIGINAL
PIONEERING
HANDS ON COURSES
IN BOTULINUM TOXIN
& DERMAL FILLERS

By Dr Bob Khanna



Dr. Bob Khanna, BDS FIADFE (NY)
(President of the International Academy of
Advanced Facial Aesthetics - IAFA)

COURSE ENQUIRES

Call Sonia Pal 07956 378526
email: sonia@drbobkhanna.com
www.drbobkhanna.com



10% DISCOUNT*

Voucher towards your malpractice insurance
*Redeemable with Hamilton Fraser Insurance



Comprehensive Aesthetics Center
Uncompromised Excellence

Commitment, focus
& passion mean
everything...

Especially when
everything counts.

To learn how we can help you
reach the ultimate Accreditation,

contact us on **Facebook**

or via the Web at:

knightdentalgroup.com

or call us at:

800-359-2043

Cosmetic Solutions



Barbara Honner Widen, CDT, AAACD

AAACD American Academy
of Cosmetic Dentistry®
ACCREDITED MEMBER



An exclusive Division of Knight Dental Group, CDL, DAMAS | (800) 359-2043 | www.knightdentalgroup.com

Examiners' Observations

Combining Accreditation with Treatment Protocols

Scott Finlay, DDS, FAGD, FAACD

Illustration by Dave Mazierski

Accreditation Case Type I presents the clinician with the broadest canvas to showcase his or her skills. This case type involves six or more indirect restorations within the maxillary arch, treating at least the incisors and canines. The key to delivering an optimal result lies in the clinician's ability to create a successful rapport with the laboratory technician. Smile design elements weigh heavily with this case type. While the restorations can be crowns, veneers, or a combination, it is critical that the practitioner demonstrate his or her ability to carefully address the patient's condition, esthetics, and overall health. The comprehensive understanding of materials, preparation designs, and adhesive techniques should facilitate conservation of tooth structure while still meeting the parameters of function and health.

The examiners evaluate cases based on a point system that identifies minor, major, and catastrophic faults. A passing score is -7 or better. The examiners are also given the latitude to reward the candidate with a +1 point, in situations where the result deserves additional merit. Dr. Shimizu's case passed unanimously with scores that ranged from -5 to -7. Almost all of the criteria faults were identified as minor and two examiners rewarded Dr. Shimizu with a +1. No case is perfect; the goals of Accreditation are to create a vision and demonstration of excellence, not perfection.

The comprehensive understanding of materials, preparation designs, and adhesive techniques should facilitate conservation of tooth structure while still meeting the parameters of function and health.

Dr. Shimizu achieved a wonderful result for his patient. The preoperative indications for treatment supported the final treatment plan. Dr. Shimizu extended treatment to include eight teeth because of the clinical indications. The indications for treatment are driven by the functional and health needs of the patient. Dr. Shimizu followed an established treatment protocol that helped to ensure a predictable result.

The examiners identified several common deficiencies in this case; often, these criteria are inter-related:

- One of the initial observations was the excessive length of connectors and the effect this had on the periodontal health and architectural harmony (*Criteria #64, #71, and #72*). An accepted guideline that is observed in nature relates to the proportion and size of the apparent contact zone or connectors between adjacent teeth. Typically, the ideal connector zone between the central incisors is 50% of the length of the centrals.¹ The size of these connectors decreases in a symmetrical fashion as you move posterior (**Fig 1**). The effect of excessive connector length in this case appears to contribute to the impingement upon the cervical embrasures and the blunting of the papilla. The

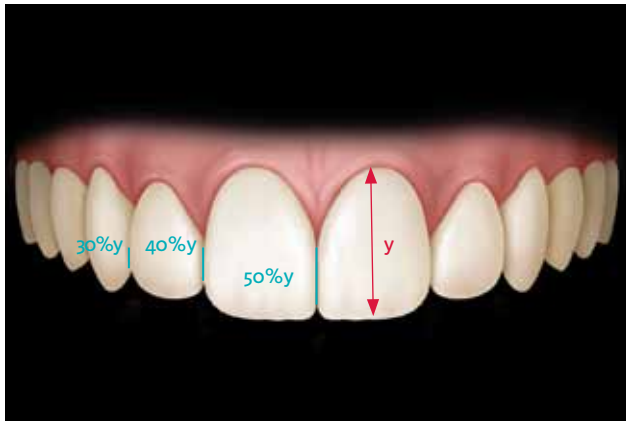


Figure 1: The apparent contact zone between the centrals is ideally 50% of the visual length of the centrals. Connectors between the centrals and laterals are 40% of this length, and the connectors between the laterals and cuspids are 30% of this length (50/40/30 rule).

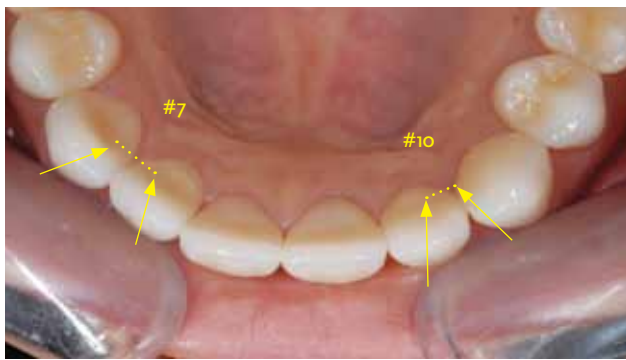


Figure 2: The management of the facial line angles can have a significant impact on the visual reveal of the tooth.

examiners noted the asymmetry of gingival zeniths, papilla heights, and inflammation of the tissue.

- *Criteria #87* focuses on the visual harmony of contralateral teeth. The examiners identified a lack of symmetry of the visual width of the lateral incisors. This requires the careful management of the facial line angles and can be readily identified from the occlusal view (**Fig 2**).² Although the occlusal view is not how teeth are typically viewed in a social setting, it is a valuable perspective in helping to appreciate the impact that these line angles have on the reflective surfaces of the teeth. In this case, the occlusal view is helpful in visualizing why the facial plane of #10 appears narrower compared to #7. The cuspids also lack similar balance in contour and shape.
- *Criteria #56* identifies the effectiveness in utilizing translucency to mimic nature and to harmonize with the balance of the smile.³ Several of the examiners found the intensity, volume, and pattern of the translucency to be slightly excessive and not reflective of what would otherwise be observed in nature.

Accreditation presents a consistent measurement of excellence in providing esthetic functional restorations of our patients' smiles. Dr. Shimizu has demonstrated his ability to meet this standard. He should be very proud of the result he achieved for his patient.

References

1. Morley J. A multidisciplinary approach to complex aesthetics restoration with diagnostic planning. *Pract Perio Aesth Dent.* 2000;12:575-7.
2. Snow SR. Esthetic smile analysis of maxillary anterior tooth width: the golden percentage. *J Esthet Dent.* 1999;11(4):177-84.
3. Villarroel M, Fahl N Jr., De Sousa AM, De Oliveira OB. Direct esthetic restorations based on translucency and opacity of composite resins. *J Esthet Restor Dent.* 2011 Apr;23(2):73-87. **jCD**



Dr. Finlay is an AACD Accredited Fellow and has been an AACD Accreditation Examiner since 2008. A 1986 graduate of the University of Maryland, Baltimore College of Dental Surgery, Dr. Finlay practices in Arnold, Maryland.

Disclosure: The author did not report any disclosures.

The Importance of Using Your Resources

Useful Tips for Accreditation Case Type I

James H. Peyton, DDS, FAACD
 Illustration by Zach Turner

// Mentors can be a valuable resource and help you to be more efficient in achieving your goals. //

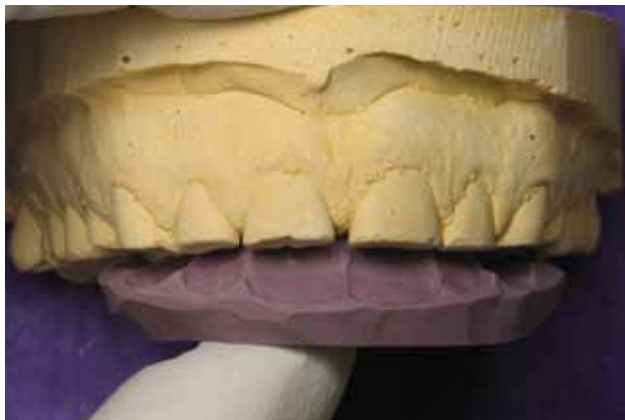

Figure 1: Model showing severely worn teeth.

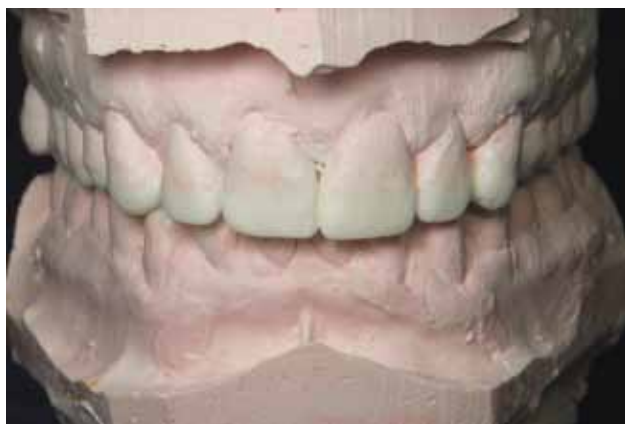

Figure 2: Diagnostic wax-up on articulated models.

THE FIRST STEP in creating restorative excellence is to partner with a laboratory technician who shares your vision and criteria when designing a case. Although there are many talented laboratory technicians, candidates might wish to work with a technician who has already achieved Accreditation or is in the process. A list of laboratory technicians who are participating in the Accreditation program can be found in the Accreditation resources area on www.aacd.com, under "Case Participation Program."

MENTORS CAN BE a valuable resource and help you to be more efficient in achieving your goals. Mentors are examiners that have been calibrated and have a keen understanding of the criteria to be evaluated in each case. By previewing potential cases prior to initiating treatment, you can avoid the frustrations of wasted time or compromised results.

Great Read!

FOLLOW THE AACD *Guide to Accreditation Criteria*. This guide is full of extremely useful information to help you through the Accreditation process.¹

READ RECENT ARTICLES on Case Type I, especially those in the Accreditation Essentials section of the *jCD*. Understanding the "Examiners' Observations" (formerly called "Examiners' Perspective") will help you refine your own vision of excellence. Many previous issues are available for free on the AACD Web site.²⁻⁴

BE SURE THE gingival tissue is healthy prior to starting your Accreditation case. Evaluate the need for gingival contouring or crown lengthening.

PREDICTABILITY IN TREATMENT can come only with proper planning. Mounted diagnostic study models are key to understanding and designing a functionally esthetic result. This will help to visualize the anticipated contours of

the restorations. Matrices can then be fabricated to use chairside to aid in preparation design; this will help to conserve maximal tooth structure and to create provisional restorations. These prototypes can then be tested and refined for esthetics and function directly in the patient's mouth. A copy of these approved provisional restorations can serve as a guide for the laboratory technician in creating the best possible result (Figs 1 & 2).

SCHEDULE FOR SUCCESS. Allow plenty of clinical time to complete the procedure. It would be best to do on a day when other patients are not scheduled.

MAKE A LIST of what you want to accomplish during the clinical appointment and check off each item as you proceed. Checklists are the guardian of quality control and give you the best opportunity to succeed.

PATIENT SELECTION IS important. An apprehensive, demanding, hurried patient may affect your ability to achieve an excellent result. The patient should be completely "on board" with your pursuit of Accreditation, allowing you to do whatever is necessary and grant you as much time as needed.

OUTSTANDING COMMUNICATION IS essential to enable your technician to have a "virtual seat" chairside. Excellent photography and meticulous detail in illustration of color mapping to include your vision of shades, textures, translucencies, and contours will improve your chances in receiving restorations that meet the standards to which you aspire (Fig 3).^{3,4}

CONSIDER A "TRY-IN APPOINTMENT." There is no rule that the restorations have to be seated the first time they are received from the laboratory. Try in the restorations with the appropriate cement simulator and re-photograph the case with the same views that will later be used to critique the case and decide whether the case would benefit from additional "detailing" by the laboratory technician. If the answer is "yes," simply replace or refabricate the provisionals and return the complete case with the try-in images to the laboratory with a specific detailing list. Repeat the process at subsequent visits until your standards are met.

Basic Shade Vita 3-D Master OM-3
(OM-3 is too translucent - make more "dense")

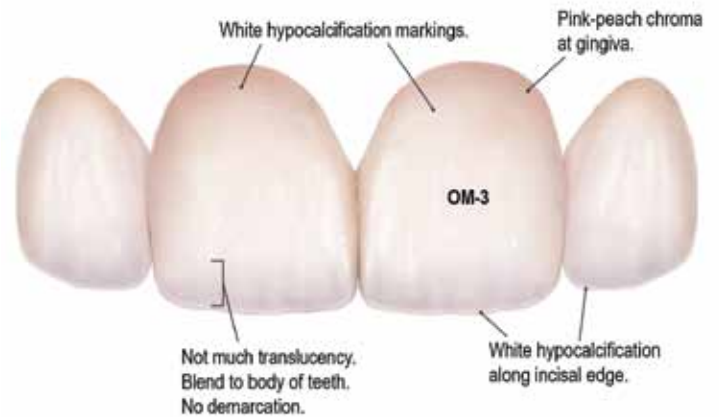


Figure 3: Color map showing desired shades and characterizations.

References

1. American Academy of Cosmetic Dentistry. Diagnosis and treatment evaluation in cosmetic dentistry: a guide to Accreditation criteria. Madison (WI): The Academy; 2001.
2. Peyton J. Practical tips for case type V. J Cosmetic Dent. 2010;26(3):38.
3. Cook S. Accreditation clinical case report, case type II: one or two indirect restorations. J Cosmetic Dent. 2010;26(2):34-43.
4. Peyton J, Arnold F. Six or more direct resin veneers case for Accreditation: hands-on tyodont exercise. J Cosmetic Dent. 2008;24(3):38-48.



Dr. Peyton is an AACD Accredited Fellow and has been an AACD Accreditation Examiner for six years. A part-time instructor at the UCLA School of Dentistry, he practices in Bakersfield, California. Disclosure: The author did not report any disclosures.

THE *Art* AND APPLICATION

A Visual Journey into the Study and Reproduction of Natural Dentition

Joshua Polansky, MDC

"I'm not trying to copy Nature. I'm trying to find the principles she is using."

~Buckminster Fuller

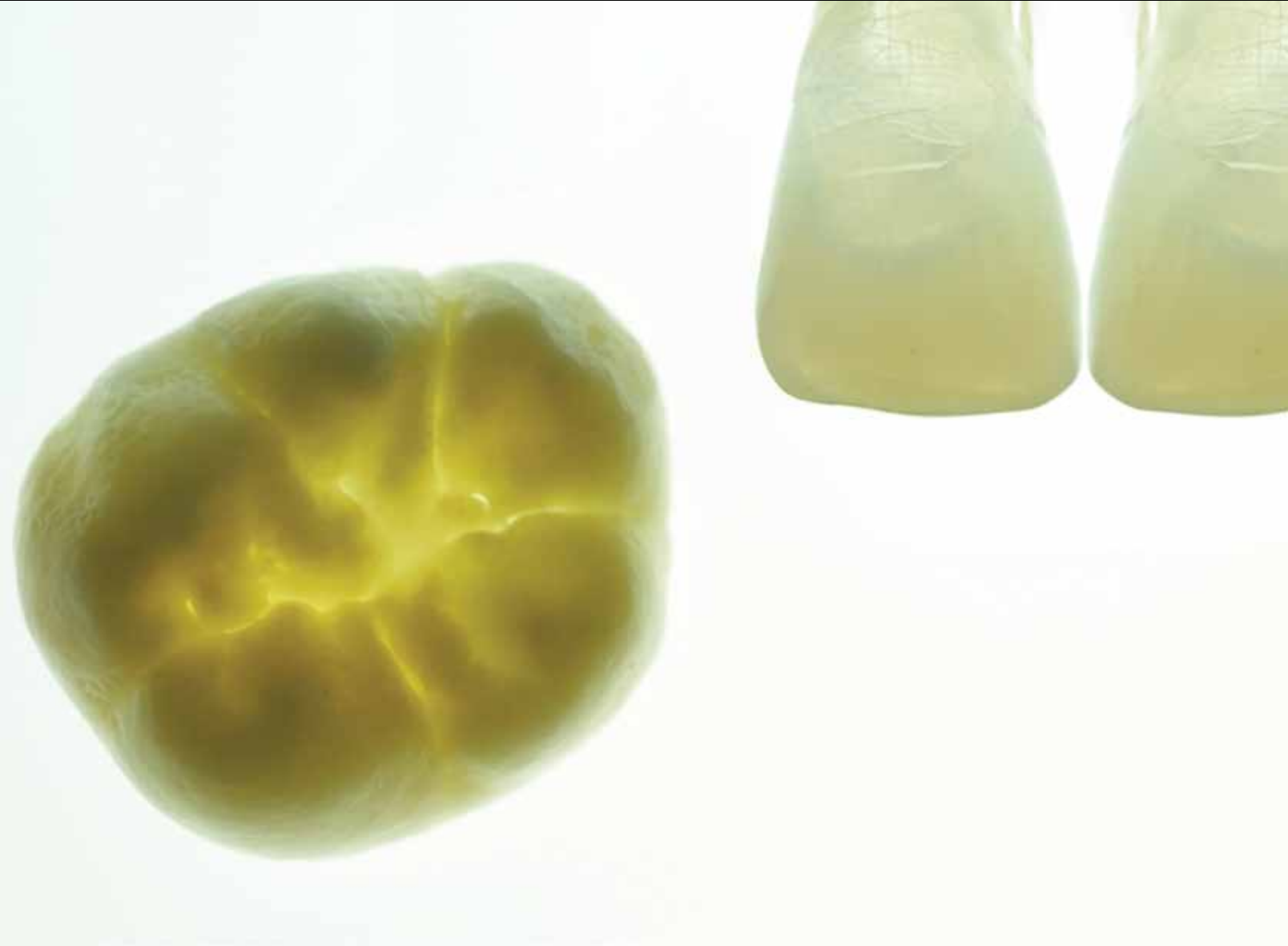
Introduction

Teeth are far more than objects of beauty. Their purpose is to sustain human life through proper function; and nature, very efficiently, makes them beautiful as well. To study esthetics is to study the science of beauty and nature. It is our task to protect nature and provide patients with the most efficient and functional restorations possible.

Architect, designer, and philosopher Buckminster Fuller said it best in his quote above. His geodesic dome is an example of perfect design. From studying nature, he developed his philosophy of sustainability. He believed that by exploring nature's principles we can find design solutions. These are not new ideas: da Vinci and Michelangelo studied human anatomy and produced art that has endured for centuries.

Above all, our work must fulfill certain criteria: beauty, function, predictability, and sustainability. The exploration of nature is where our work begins.

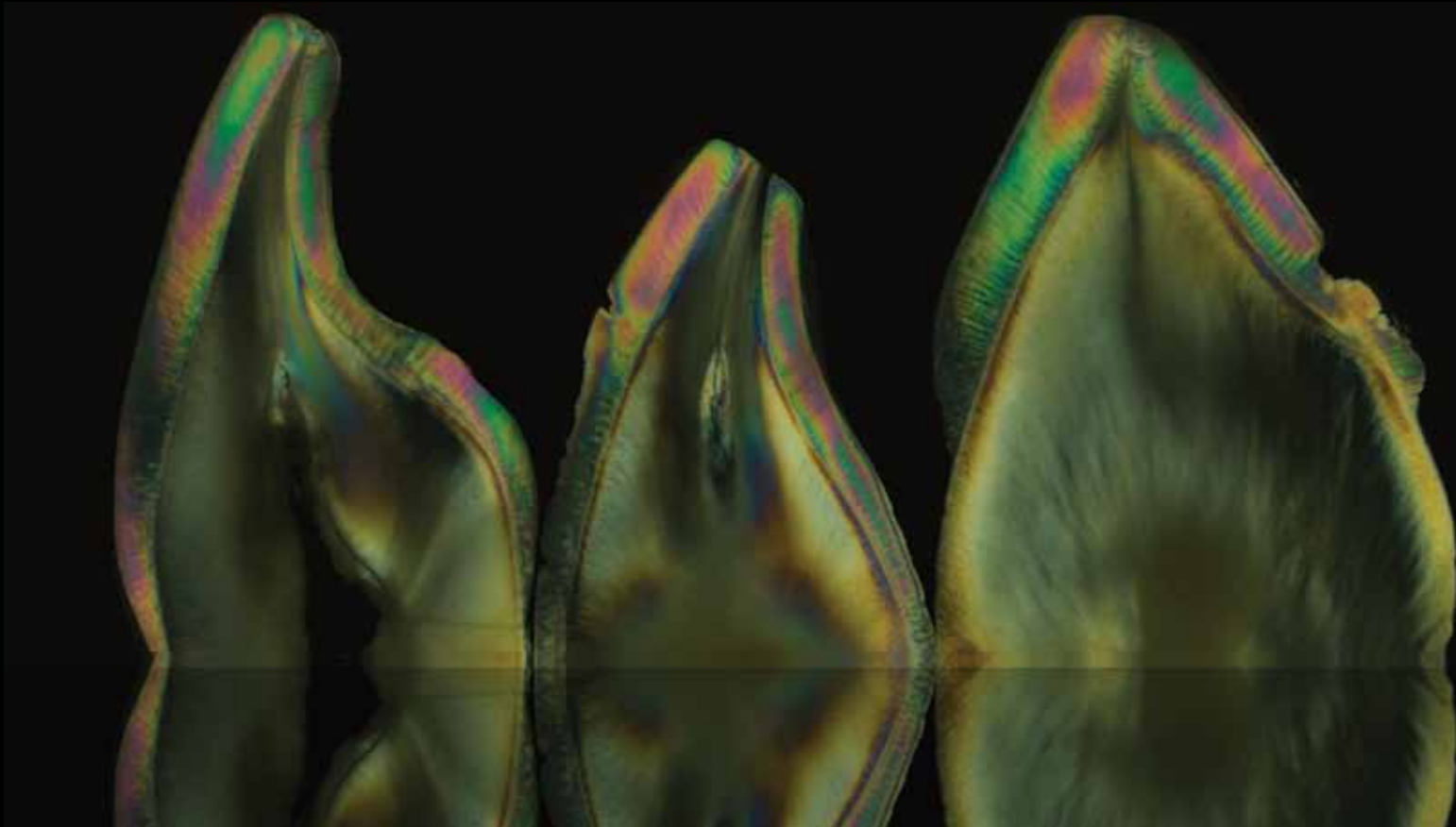
OF STUDYING NATURE



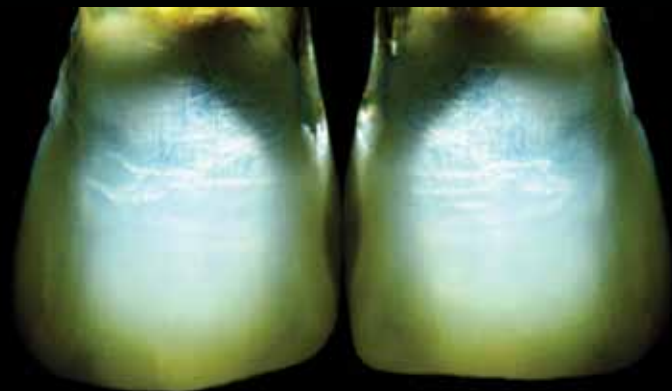Everything one needs to know lies within nature. Careful observation of natural dentition is necessary for growth in the area of restorative dentistry.



Items should be studied not only from a macro view; they also should be studied three-dimensionally, including the insides. Going deeper into nature will uncover invaluable information.

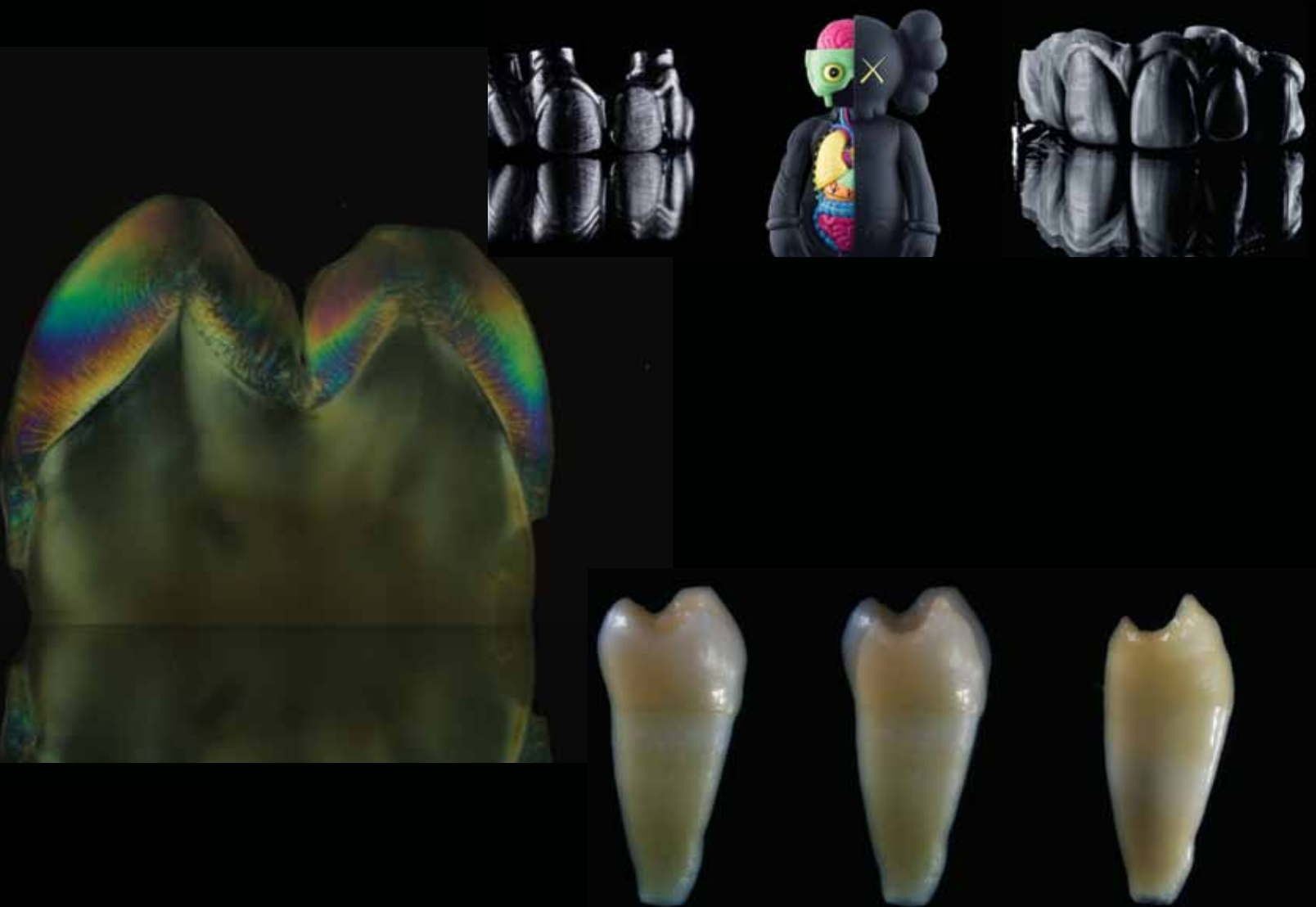


Once inside natural dentition it is possible to observe the light refractive index of nature and see how light interacts with natural dentin, enamel, and pulp. This proves just how complex nature truly is and the challenges we face in our restorations.

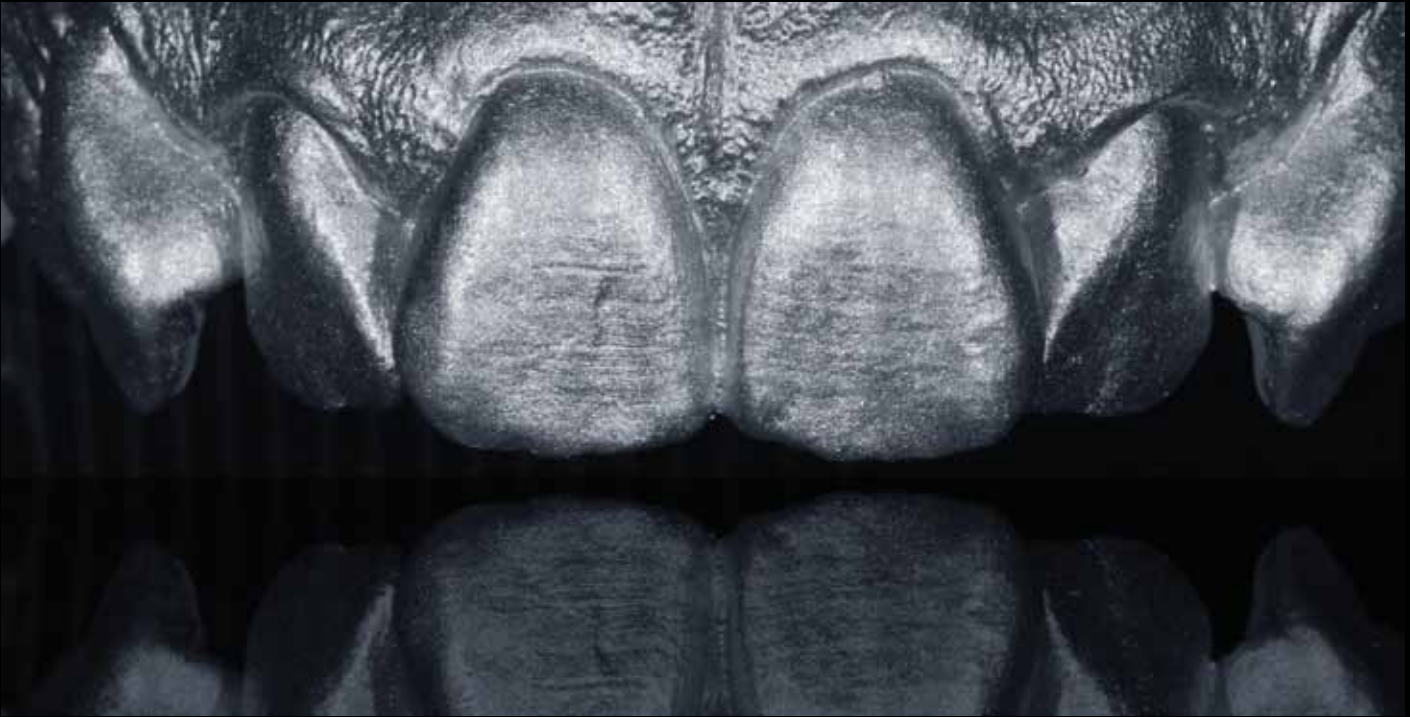



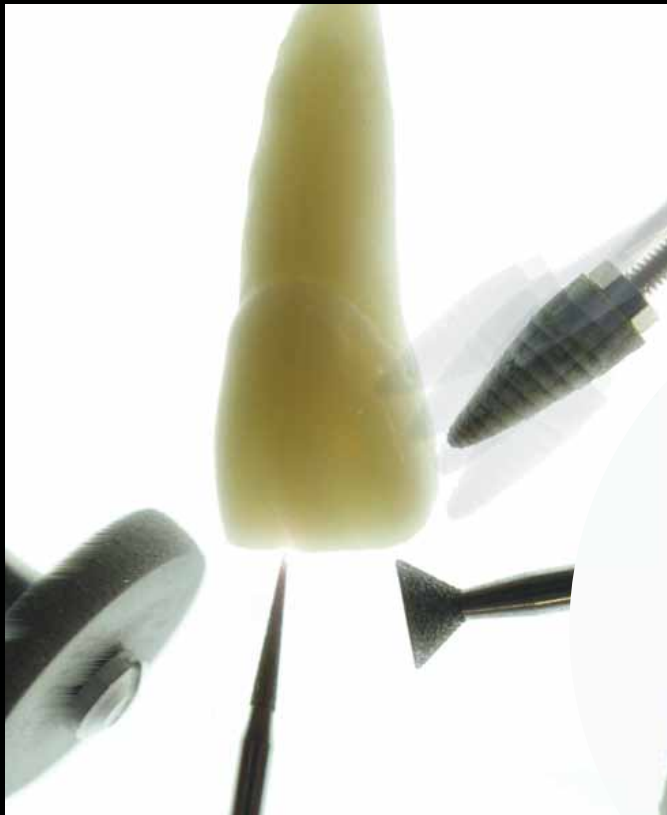
The concept of studying nature from the "inside out" can be traced back to the forefathers of modern art, including da Vinci and Michelangelo. They understood the value of observing the object as a whole, recognizing that in order to have what lies on the outside we must also have what lies within. This concept is easily applied to any creative field. It will allow for proper frame support when fabricating the design of the framework with a definitive vision of the final restorations achieved first.




Natural teeth can also be "reverse-engineered" by de-enamelizing with hydrochloric acid. With a 10-30% hydrochloric acid bath in an ultrasonic unit (Renfert USA; St. Charles, IL) for 20 minutes, enamel is stripped from the natural tooth, leaving only dentin exposed. This gives a clear view of where dentin truly lies in nature and how it should be mimicked when layering ceramic.

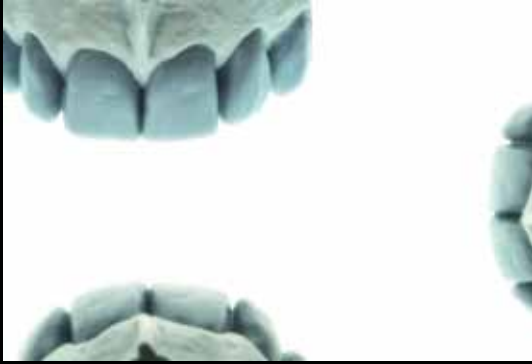

Once the interior is observed one can clearly see how the interior relates to the exterior. Dentition can now be seen in a whole new light. Details such as surface texture become clearer with this complex understanding of the composition.

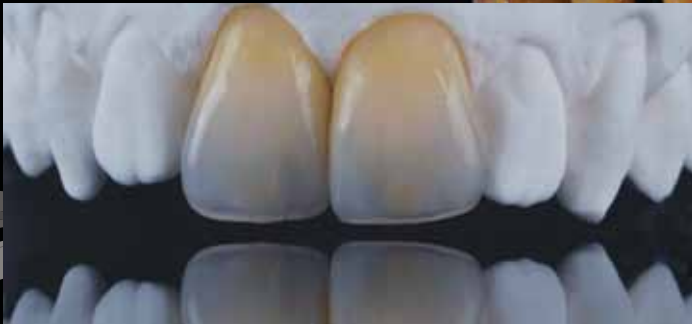
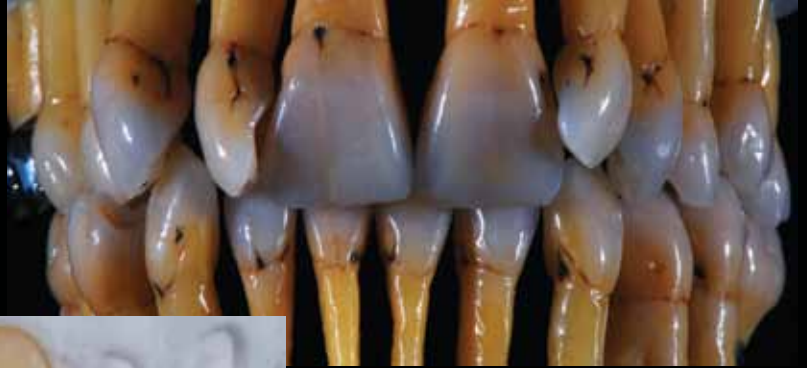
Concepts in studying nature can be directly applied to ceramic layering and detail work such as form and surface texture when creating restorations.



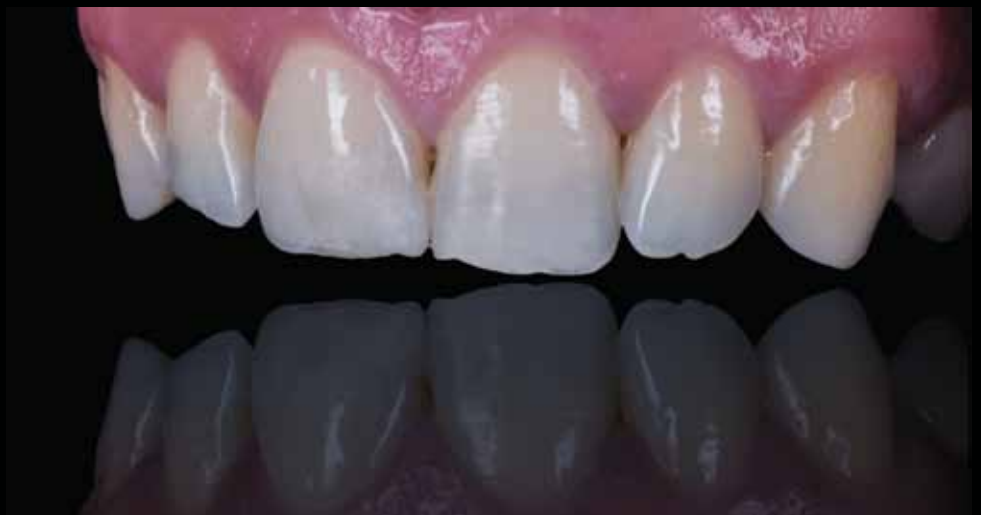

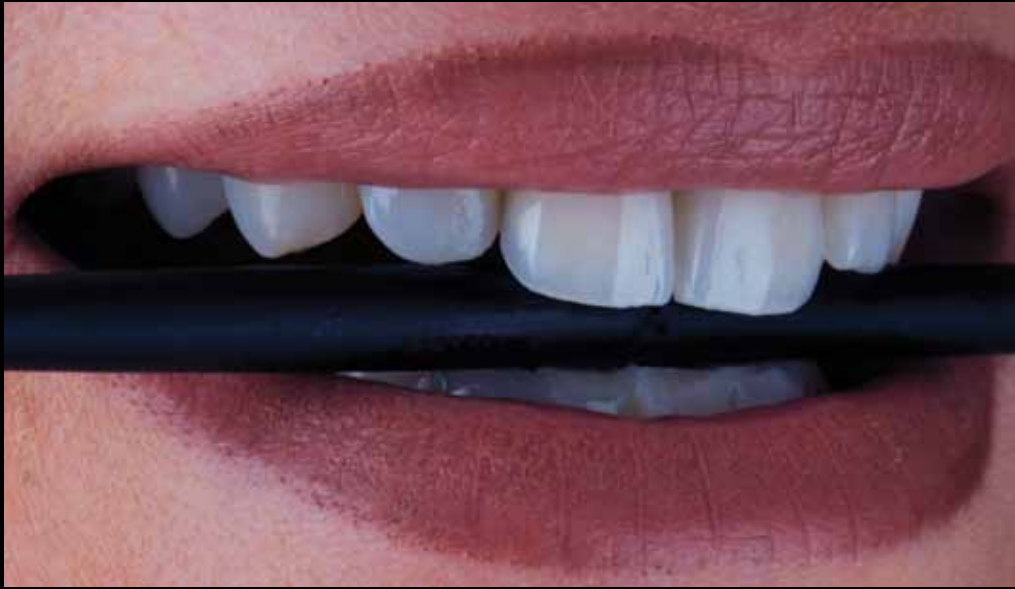Nature will always guide the medium, whether one is working with wax, ceramic, or acrylic.



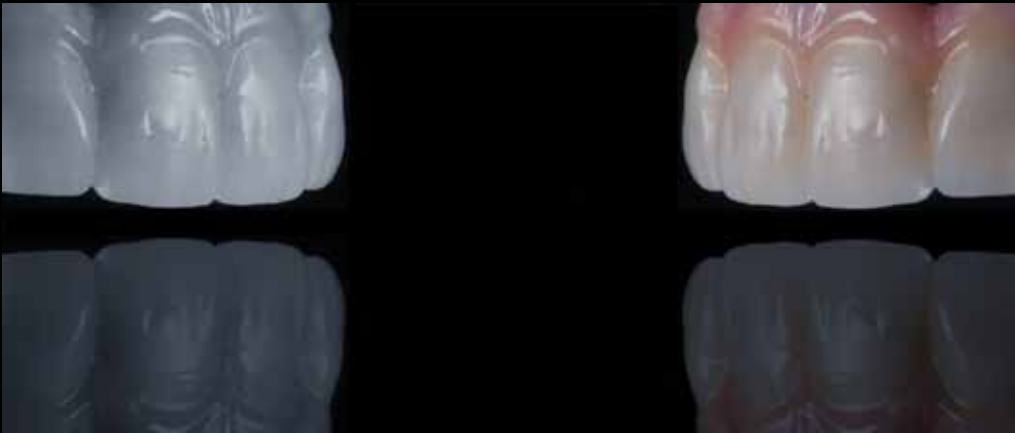With the studies laid out, the skills must be translated to the mouth. The mouth poses new variables that must always be considered, such as lips, lip line, tissue, etc.

Mastering natural dentition and color will prove worthwhile when one is faced with the task of layering and fabricating a single central incisor (#8 veneered utilizing GC Initial's Mc ceramic system [GC America; Alsip, IL]). Dentistry by Dr. Barry Polansky (Cherry Hill, NJ).

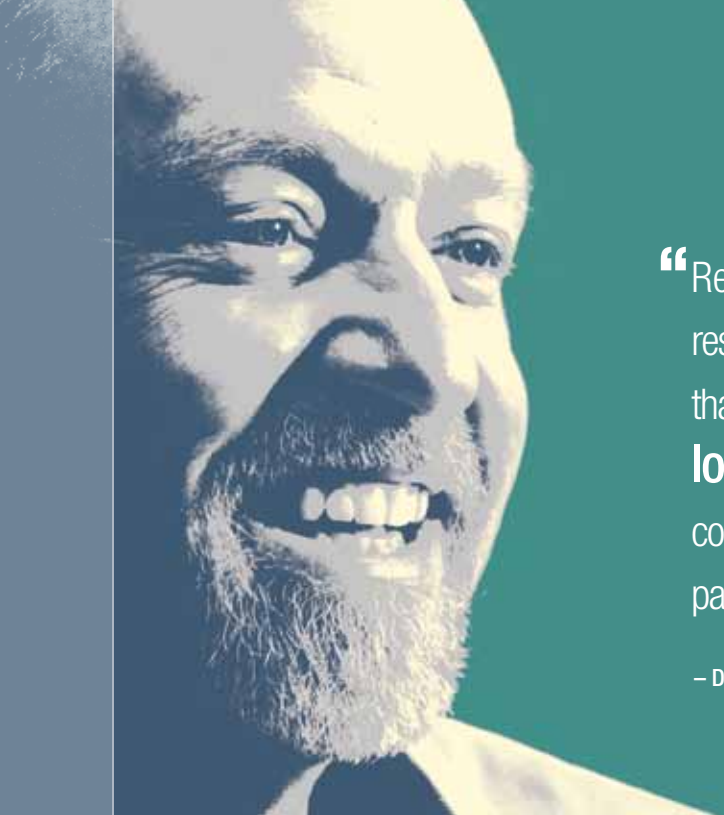




The ability to translate knowledge from brain to brush to mouth is becoming a lost art with the advances in CAD/CAM technology. Being able to recreate nature is not only limited to dentition; the study of tissue and tissue color is imperative to creating natural restorations as well. (Top: #8 and #9 restored, #8 zirconia custom abutment with zirconia layered crowns over #8 and #9 using GC Initial zirconia ceramic system. Dentistry by Dr. Barry Polansky. Bottom: Metal ceramic pink-and-white bridge over four custom-milled abutments using GC Initial Metal ceramic system and GC Initial gums shade ceramics. Dentistry by Dr. Jamie Laviola [Atlantis, FL].)



Mr. Polansky owns and operates Niche Dental Studio in Cherry Hill, New Jersey.
Disclosure: The author did not report any disclosures.



“Results are all that matter. I’ve been prescribing Lava restorations for about six years. I know from experience that when I send the case to my lab, it’s going to **look and fit perfectly—and last.** I’ve had consistent success, even on six-unit bridges. Our patients love it so much, they actually tell their friends.”

– Dr. Kyle Edlund

Why? How about 10 years,
100 studies and
millions of cases.¹

Staggering statistics aside, there are endless reasons to prescribe Lava™ Zirconia. Start with patient demand for a crown or bridge with no metal in it. Or the look of genuine satisfaction when a patient sees beautiful Lava zirconia where a large amalgam once was. Lava zirconia takes cosmetics to a whole new level. Isn't that where you want to take your practice? Start now.

Prescribe authentic Lava zirconia.



**Lava™
Zirconia**

▶ Learn how you can offer Lava Zirconia.
Call 800-634-2249 or visit www.3MESPE.com/Lava

3M ESPE

Enhancing Nature to Achieve Patients' Desires

A Smile Makeover Utilizing Porcelain Veneers

W. Johnston Rowe, Jr., DDS, AAACD
Wayne B. Payne, AAACD

Introduction

Today's esthetically driven dental consumers can be very exacting with regard to the results they expect from their cosmetic dentist. Advances in cosmetic dentistry techniques and materials have provided clinicians with the armamentarium to meet virtually any reasonable request with incredible accuracy. Excellent communication between patient, dentist, and laboratory technician, coupled with meticulous planning and precise execution of the plan by all parties, yields excellent results. Porcelain veneers are often the most beautiful and most durable esthetic enhancement a dentist can offer a patient. When executed properly, porcelain veneers can often be mistaken for "perfect" natural teeth.

CLINICAL COVER STORY



Figure 1a

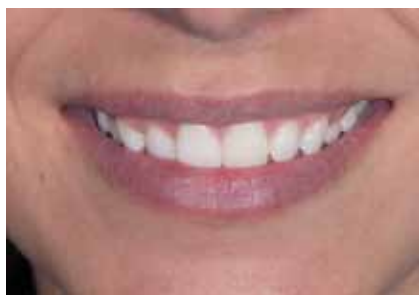

Figure 1b

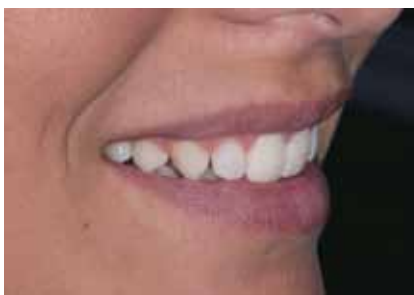

Figure 1c

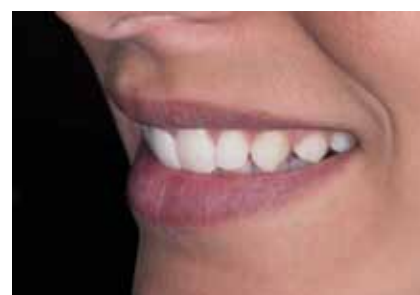
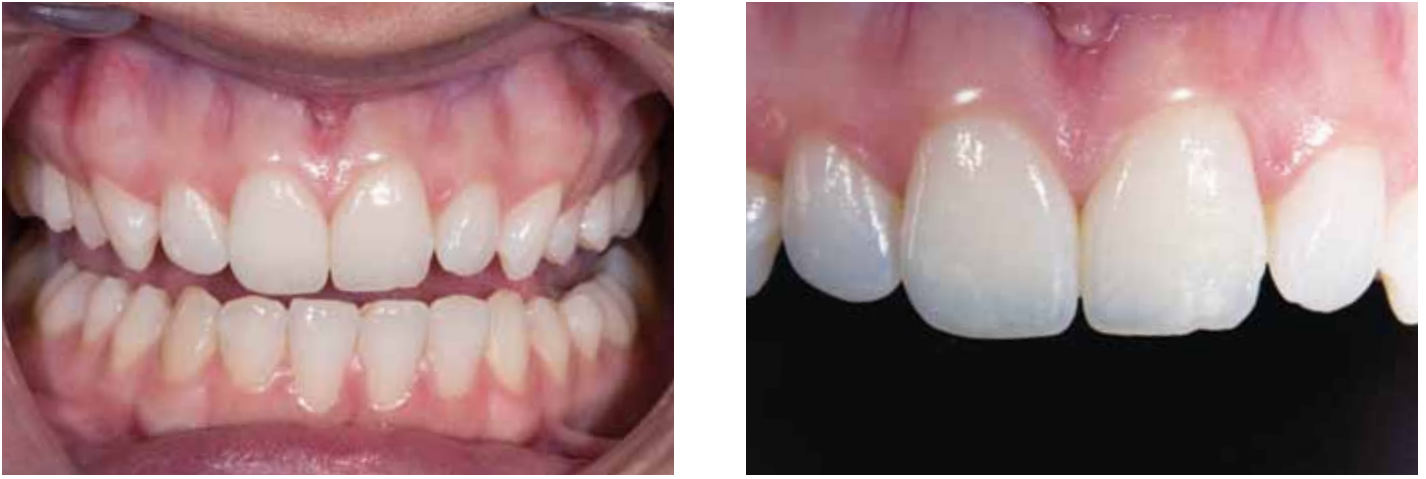
Figure 1d

Figures 1a-1d: Pre-restorative full-face images demonstrate the patient's concerns with the general shape and shade of her teeth. Note the irregular gingival heights and deficient buccal corridors.

When executed properly, porcelain veneers can often be mistaken for "perfect" natural teeth.



Figures 2a & 2b: Pre-restorative retracted 1:1 and 1:2 views show the developmental malformation of the distal-incisal edge of #9 and the poor positioning and shape of the canines and laterals, resulting in improper incisal embrasure form.

Case Presentation

Chief Complaint and History

The patient was a 29-year-old female in excellent health. She stated she had annual dental cleanings, had whitened her teeth in the past, and had no other particular dental concerns other than the esthetic appearance of her smile. The patient was a successful pageant contestant and was very specific regarding her complaints about her smile. She was particularly unhappy with the general shape and shade of her teeth (Figs 1a-1d), did not like the shape or positioning of her canines, and was concerned about the developmental malformation of the distal incisal angle of #9 (Figs 2a & 2b). She noted her deficient buccal corridors were an issue by explaining that her smile did not “fill her mouth.”¹

She further stated she did not want an “artificial”-looking smile and that achieving a beautiful, natural result was paramount; she had no desire to pursue orthodontic options.

A full-mouth series of periapical radiographs was made of the patient's teeth and no pathology was noted. Occlusion was also evaluated to rule out any possible traumatic interferences

that would affect the longevity of new restorations.² Canine guidance was observed without noting any posterior excursive interferences. A small chip was noted on the mesial incisal edge of #24 and, after questioning, was determined to be the result of biting down on a sewing needle several years in the past.

The clinical examination revealed a Class II molar and canine relationship with no significant occlusal interferences (Figs 3a & 3b). Evidence of mild wear was found on the patient's anterior and molar teeth (Figs 4a & 4b) and, after evaluation of occlusion, it was determined that this process of pathologic wear appeared to be controlled by the nightly wearing of a hard, flat plane, acrylic occlusal guard. The patient exhibited no symptoms of any temporomandibular joint (TMJ) disorder and appeared asymptomatic during a TMJ evaluation.²

Diagnosis and Treatment Plan

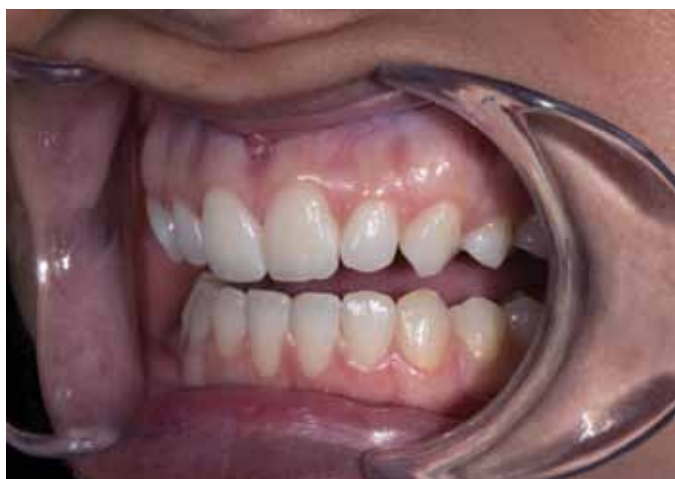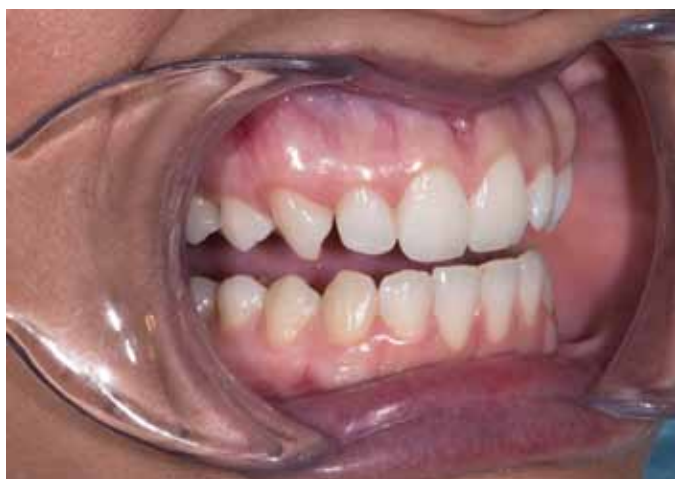The patient's dentition exhibited mild wear, unesthetic tooth shape, and poor tooth size proportions.¹ Some crowding was also present, with a slightly constricted arch form in the premolar areas of the maxilla.¹ Several areas of gingival asymmetry were noted. The patient had

a Class II occlusion with a history of mild pathologic wear; any parafunction was controlled by nightly wear of an occlusal guard.

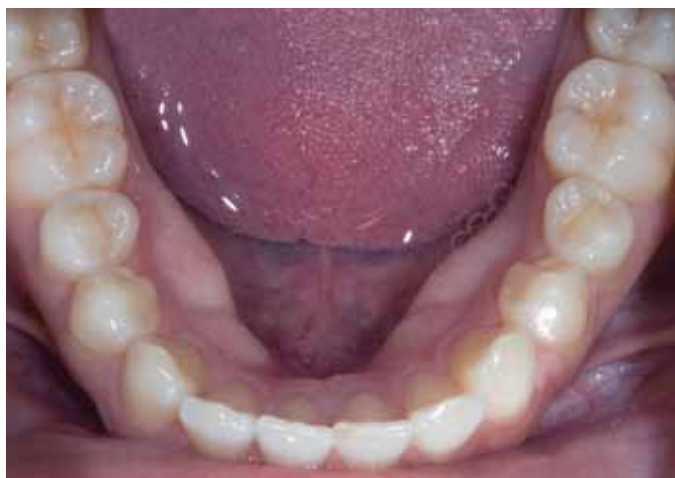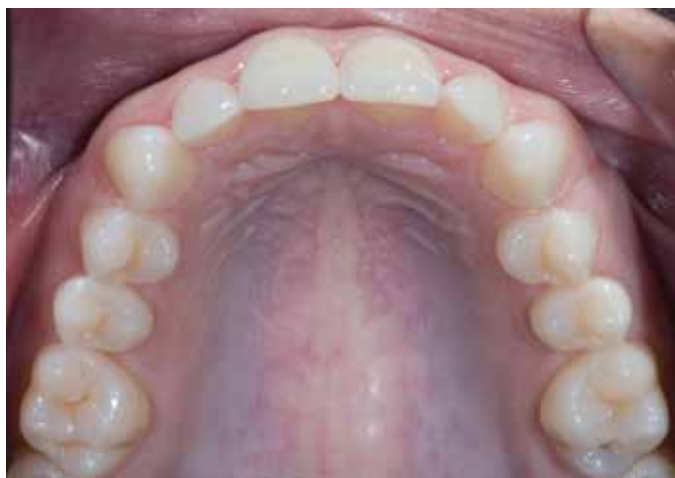Following discussion of esthetic restorative options for her smile, the patient elected to pursue a treatment plan that included tray bleaching of her maxillary and mandibular teeth, followed by treatment of #4-13 with minimal preparation porcelain veneers. She was excited by the idea of having her teeth restored in a conservative manner, without having to pursue prolonged orthodontic treatment.

In addition to being unhappy with the size, shape, and color of her front teeth, she did not like the transition in her smile from the canines to the premolars and wanted to treat the premolars to blend appropriately with her anterior teeth (Figs 2a, 3a & 3b, 5a & 5b). A natural, beautiful result was the patient's primary goal. She chose not to address the chipped incisal edge of #24 (restoration with composite filling material was recommended). Proper care for the future porcelain restorations was discussed, including the nightly wearing of a maxillary full arch, hard protective occlusal guard; and the importance of optimal maintenance,

CLINICAL COVER STORY



Figures 3a & 3b: Pre-restorative right and left lateral retracted 1:2 views show improper progression of incisal embrasures, Class II canine relationship, and poor transition from anterior to posterior teeth.



Figures 4a & 4b: Maxillary and mandibular pre-restorative occlusal views demonstrate mild wear on the anterior and molar teeth.

including regular cleanings and examinations was stressed.³

A comprehensive set of records was made of the patient's preoperative condition to allow for proper communication between the dentist and the ceramist. A laboratory prescription was prepared, including the patient's complaints and proposed smile changes. In addition to the information provided to the ceramist, the operator called the ceramist to discuss the fine points of the case (clarification of the specific patient desires and discussion of the restorative material and technique

planned for the case). Due to the lingual inclination of the patient's maxillary teeth inherent with her Class II occlusal setup, minimal preparation veneers were indicated. Alginate impressions of both the maxillary and mandibular arches were made and study models were fabricated in die stone.³⁻⁶ Polyvinyl siloxane (PVS) impressions were made of both arches and a Megabite PVS bite registration (Discus Dental; Culver City, CA) was made, along with numerous digital photographs, meticulously documenting the preoperative shade, texture, and shape of surrounding

teeth.^{3,4,6,7} A facebow transfer was done, as well. All records were sent to the laboratory, where the study models were mounted on a semi-adjustable articulator, and teeth ##4-13 were waxed to full contour by the ceramist. A putty PVS stent was then formed to fabricate an incisal reduction matrix. Custom whitening trays were also fabricated from the study models and were delivered, at the initial records appointment, with 10% Opalescence PF whitening gel (Ultradent; South Jordan, UT) and instructions for use.

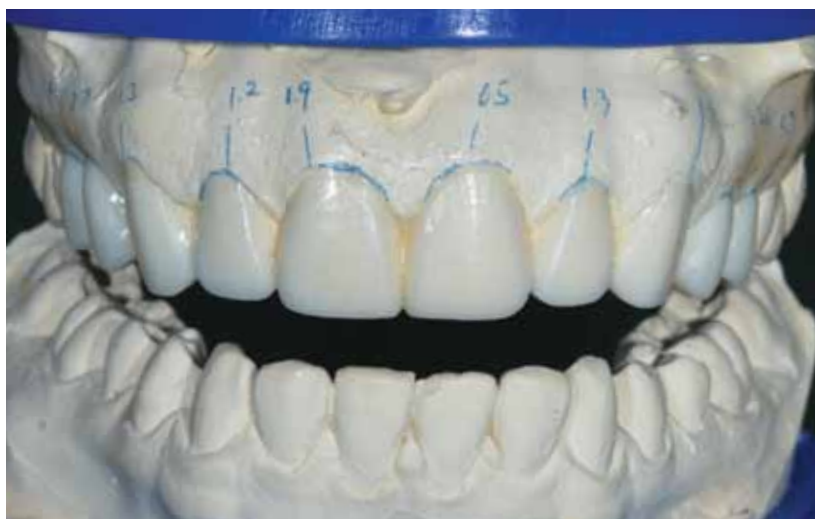

Figure 6: Waxed-up study casts demonstrate a blueprint for restorative success.

Treatment

The patient reviewed the diagnostic wax-up of her smile on the day of her preparation appointment. She was able to view and approve the waxed teeth presented on mounted study models prior to any preparation of her teeth^{3,4} (Figs 6, 7a & 7b, 8a & 8b, & 9). Following approval of the wax models, shade selection was performed immediately to ensure proper match of hue, chroma, and value, prior to any dehydration of the teeth that would occur during the treatment process.^{3,4} Under color-corrected lighting, digital photographs were made from multiple angles, with at least two shade tabs per photograph, to assist in shade matching and color mapping.⁴ The dentist also provided a shade map for the ceramist, to be used as a complementary guide with the photographs.

Profound anesthesia was obtained through the use of a topical anesthetic followed by injection of articaine with 1:100,000 epinephrine in the areas of ##4-13. Tissue sculpting was performed with a Waterlase ErCr: YSGG laser (Bio-lase; Irvine, CA) to even gingival levels on ##5-8 and #12 (Figs 6, 8a & 8b). Careful attention was paid in measuring tissue to be removed, coupled with preoperative bone sounding to avoid

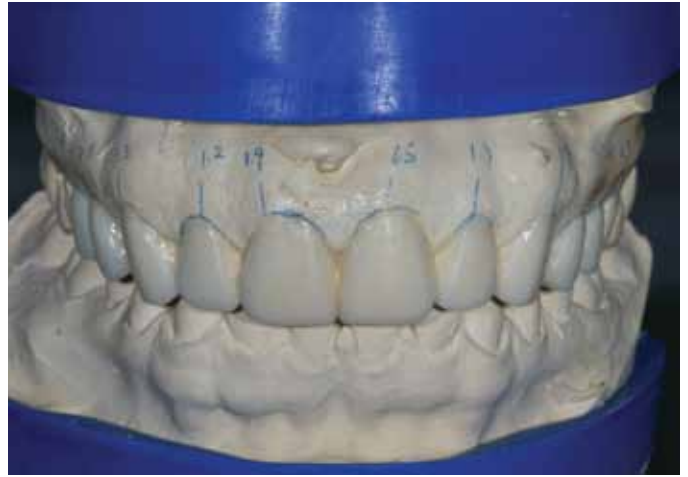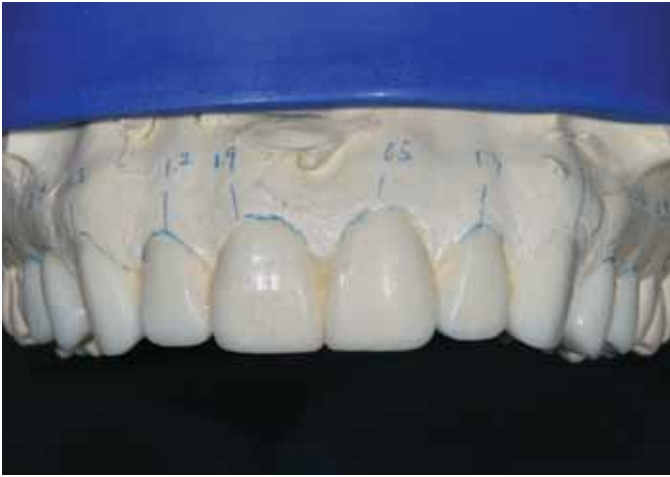invasion of biologic width.^{3-6,8} A clear plastic surgical guide was used to gauge the tissue reduction as marked on the diagnostic wax-up.

Initial tooth preparation was completed with a 2000.10 Two Stripper super-coarse grit diamond bur (Premier Dental; Plymouth Meeting, PA) in a high-speed handpiece under copious water spray. Due to the size and positioning of the patient's teeth, minimal tooth reduction of the enamel was required. Adequate incisal (1.5 mm) and facial (.75 mm) porcelain thickness was needed to provide room for layering, slight color change, and addition of incisal effects in the porcelain.^{3,4} A well-defined cervical margin was established with a 703.8F diamond bur (Premier Dental) to provide for a positive veneer stop and a precise porcelain to tooth interface that would be smooth and easily cleanable.^{3,4} Careful attention was paid to prepare the margin deep enough to allow for appropriate thickness of porcelain for strength, without compromising proper emergence profile. Abrasive discs (Cosmedent; Chicago, IL) in a slow-speed handpiece were used to smooth the preparations and eliminate any sharp angles that could cause internal stress points in the porcelain restorations.^{3,4} Appropriate incisal reduction

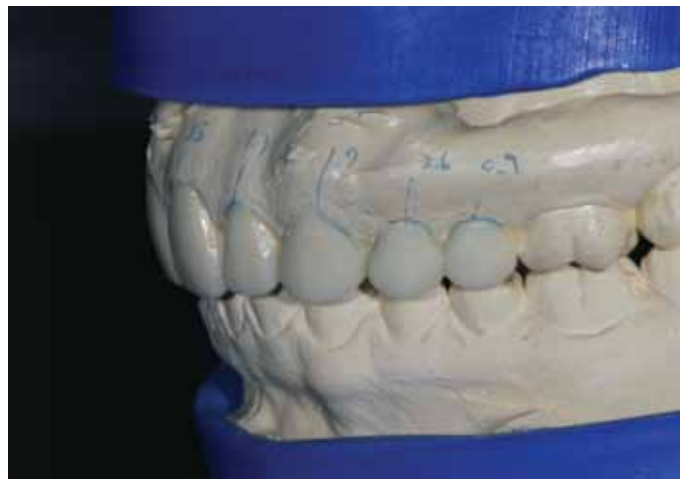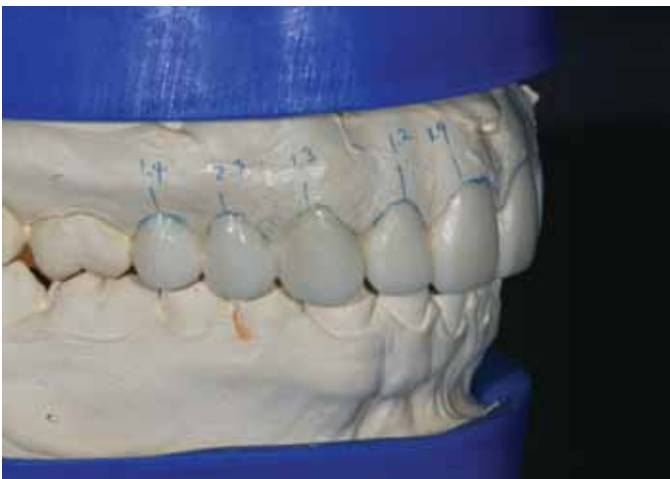was confirmed with the lingual and incisal PVS stent. Photographs of the preparations were made and a preparation shade of st9 (Ivoclar Vivadent; Amherst, NY) was observed and recorded to be communicated to the ceramist. Expa-syl gingival retraction paste (Kerr; Orange, CA) was expressed around all gingival margins to provide hemostasis and adequate tissue reflection for the master impression. After three minutes, the paste was rinsed away with a copious, forceful water spray. The preparations were dried and a master polyvinyl impression was made with Honigum Light and Heavy impression material (DMG America; Englewood, NJ). A Megabite stick bite of the prepared teeth in centric occlusion (CO) was made and photographed. All impressions were disinfected and sent to the laboratory with the photographic records and instructions for the ceramist.

The patient's teeth were then lubricated with a thin layer of glycerin gel to minimize any chance of adhesion during provisional fabrication. The PVS stent made from the diagnostic wax-up was filled with BL Luxatemp (DMG America), placed over the prepared teeth and allowed to cure. After approximately one minute, the stent was gently

CLINICAL COVER STORY



Figures 7a & 7b: Measurements for tissue recontouring were marked on the study models and transferred to the mouth for precise tissue sculpting.



Figures 8a & 8b: Right and left lateral views of wax-up demonstrate corrected progression of embrasures and gingival contours.

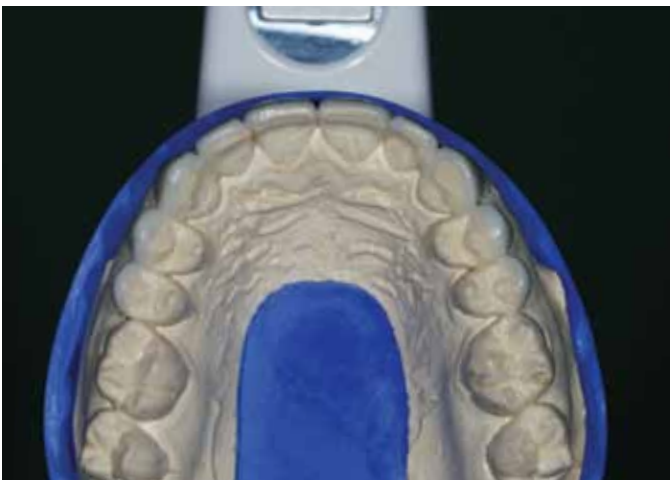

Figure 9: Occlusal view of maxillary wax-up demonstrates corrected arch form and proper facial embrasures.

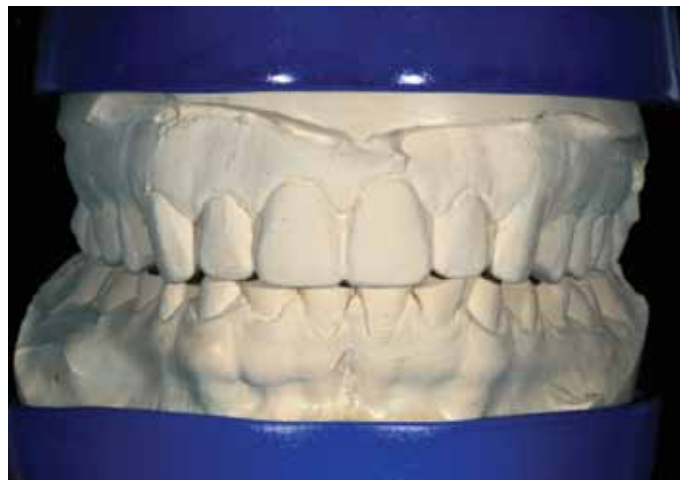
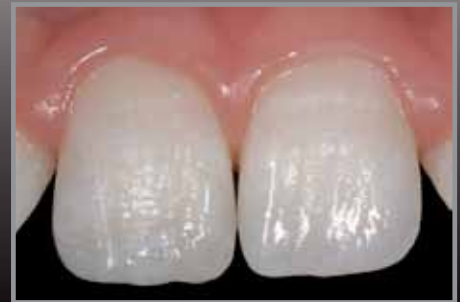
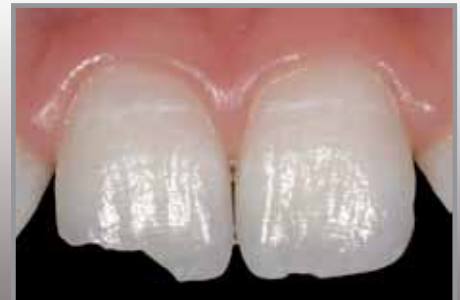Figure 10: Temporary model articulated.

ENA HRi
HIGH TECHNOLOGY
PASSION FOR ESTHETICS



Ena HRi is the first and only composite material to possess the same refractive index as natural enamel



RESTORATION MADE BY DR. LORENZO VANINI



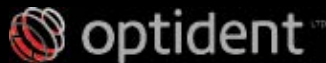
only \$249.00

Ref. EHR6

TRIAL KIT ENA HRi 6x2,5g including 6 syringes 2,5 g with holder
 4 dentin: UD1 (A1), UD2 (A2), UD3 (A3), UD4 (A4)
 2 universal enamel: UE2, UE3



Micerium S.p.A.
 Via G. Marconi, 83
 I 6036 Avegno (Ge) Italy
 Tel. +39 0185 7887870
 hfo@micerium.it



To order contact our dealer today:
 Optident USA
 Tel. 855 549 4511 • hri@optident.com

To order contact our dealer today: Optident USA • Tel. 855 549 4511 • Fax 855 549 4512 • hri@optident.com
 Special offer form: Trial Kit ENA HRi • Ref. EHR6 \$249.00
 Dr.
 Phone
 Address
 City State
 Date and Signature Zip

CLINICAL COVER STORY

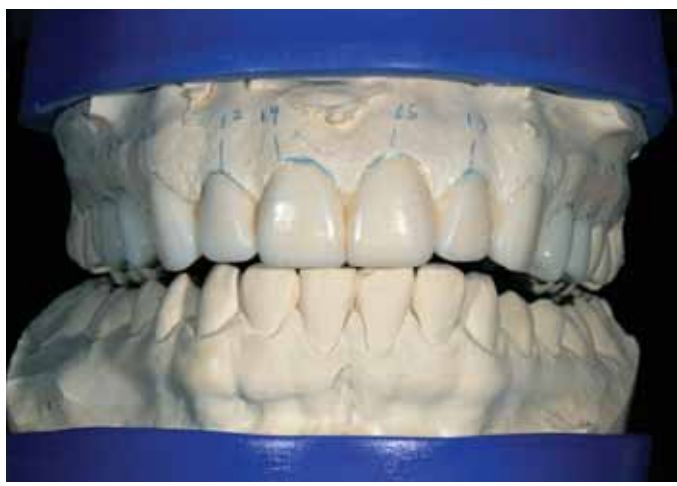

Figure 11: Wax-up articulated.

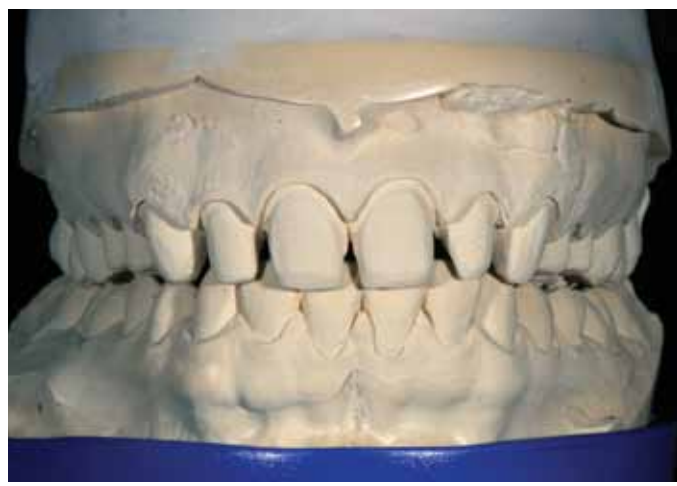

Figure 12: Solid model articulated.

removed, with the veneer provisionals remaining inside. Excess material was scaled away from the teeth and the teeth were cleaned with pumice and Consepis chlorhexadine (Ultradent). The provisionals were removed from the stent and trimmed. The provisional restorations were then seated with Optibond FL resin (Kerr) and cured for five seconds on each tooth with a Fusion LED curing light (DentLight; Richardson TX). Excess material was removed with a scaler and a #12 scalpel blade, and the provisionals were smoothed and finished with abrasive discs (Cosmedent) and a rubber cup polisher (Cosmedent). Occlusion was verified and checked and the patient was scheduled for a postoperative check 24 hours later.

The 24-hour postoperative check was particularly important because it was the patient's first opportunity to evaluate the proposed shapes and contours of her new teeth without being anesthetized. The check began with an esthetic and phonetic evaluation by the patient and the doctor. The patient reviewed and approved the shape of her provisional restorations and the shade tabs selected at the prior appointment. Proper occlusion and anterior guidance were confirmed. Photographs were taken of the approved provisional restorations and shade tabs were made. Other

provisional records were made, including a stick bite in CO and a polyvinyl impression of the approved provisionals. All records were disinfected and sent to the ceramist, accompanied by a complete laboratory prescription and all photographs taken to that point. The ceramist was instructed to use the impression of the approved provisionals as a guide for the final shape, size, and contour of the porcelain restorations.

Laboratory Phase

During the three-week provisional phase following the master impression appointment, the patient was able to further reevaluate the provisional restorations. If she had requested any changes, they would have been communicated to the ceramist during this period. No changes were requested during this time.

The patient's approved basic shade choice of BL2 (Ivoclar Vivadent) with a slight fade to BL3 at the gingival (more on #7 and #10 than on the centrals), and a cervical BL4 on the canine teeth was communicated to the ceramist on the laboratory prescription. A moderate incisal translucency pattern was requested with natural gingival staining and a polished gloss lightly textured finish. Additional information sent to the laboratory included the following:

- shade map (proposed)

- digital photographs: preoperative, prepared, and provisionalized
- digital photographs of teeth with shade guides: preoperative, prepared, and provisionalized
- stick bite registrations with photographs: preoperative, prepared, and provisionalized
- master PVS impression of prepared teeth (two sets)
- opposing PVS impression of mandibular teeth
- PVS impression of maxillary provisional restorations
- specific written details of case goals with special emphasis on shade.

At this time, a prescription for 10 Authentic porcelain veneers (Jensen Industries; North Haven, CT) was written. On receipt of the case, the records were reviewed by the ceramist and the material choice on the prescription was confirmed during a telephone conversation. Shape, shade, and characterization were discussed again and finalized in the planning stage.

The laboratory received PVS impressions of the preparations, opposing arch, and approved provisional restorations, as well as a stick bite, bite records, and detailed prescription of the patient's desired restorative results. The dentist and ceramist discussed and agreed to use a pressed ceramic material (Authentic) for the restorations.

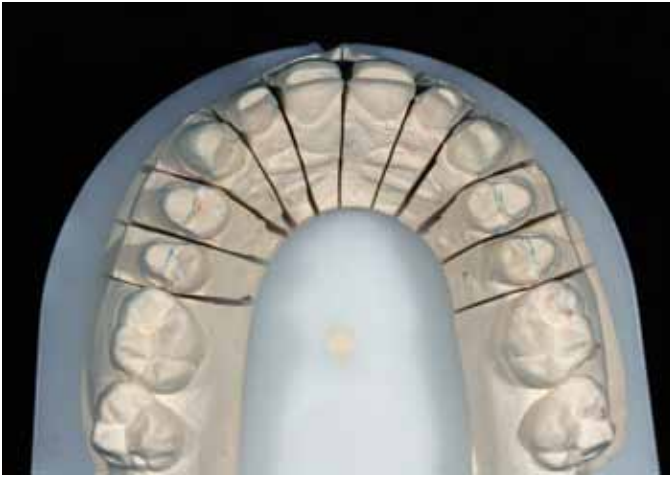

Figure 13: Die model cut.

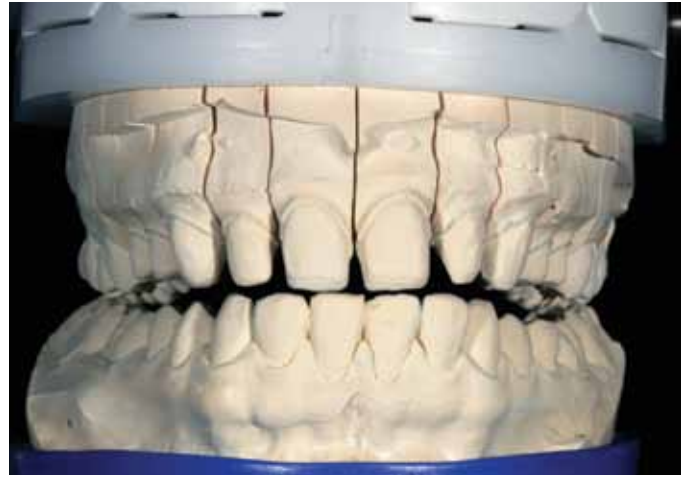


Figure 14: Die model articulated.

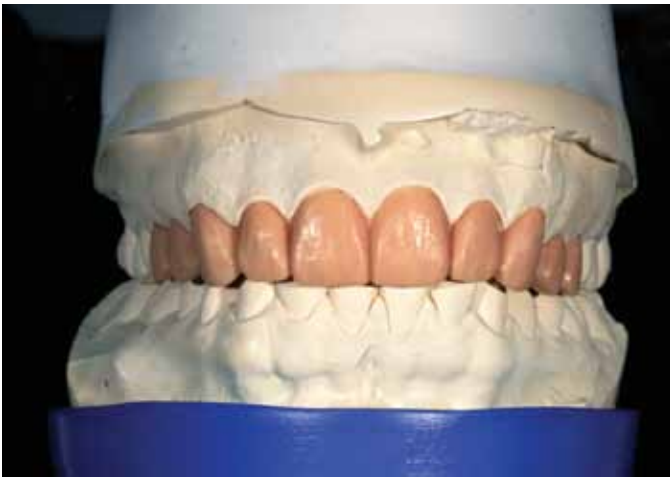


Figure 15: Wax injection on solid model articulated.

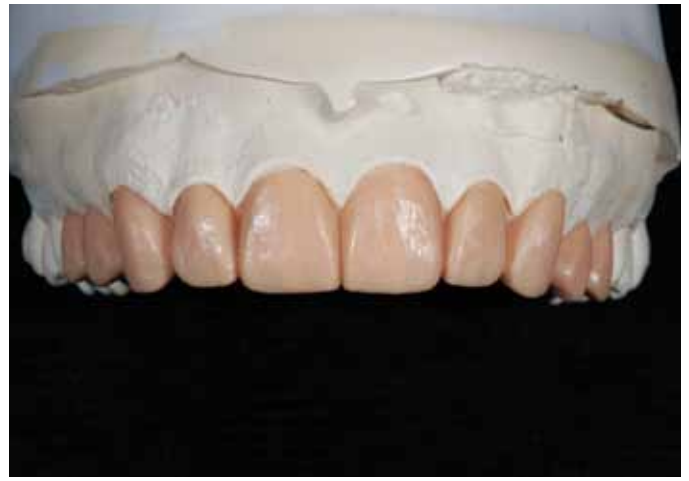

Figure 16: Wax injection on solid model.

Models were poured in ivory diamond die stone (Hi-Tec Dental; Greenback, TN), and the master impression was pinned (Giroform system, Amann Girrbach America; Spring Hill, FL). A solid model was created for tissue form.

The case was articulated using bite records on a Stratos 200 (Ivoclar Vivadent). The die, solid, and provisional models were all mounted and cross-mounted to check for accuracy (Figs 10-12).

A silicone matrix was made (Sil-Tech, Ivoclar Vivadent) from the patient's approved temporary model. This tooth

form was transferred to the solid die model using a wax injector (Pro-Craft, Grobet USA; Carlstadt, NJ) with beige Thowax (Yeti Dental; Engen, Germany). The wax was checked for length, width, function, and deflective and reflective line angles, as well as gingival emergence (Figs 13-16).

The case was sliced into single units and the margins sealed, after which it was sprued and invested (Microstar HS Investment, Jensen Industries). It was set for 17 minutes before being placed in an 855° C burnout furnace and burned out for one hour. The case was

pressed using a W+ ingot in a pressing furnace (EP 600, Ivoclar Vivadent) to 925° C. Once cooled, it was devested using 50- μ glass beads.

Units were cut off the sprues using a #911.104.220 diamond disc (Komet USA; Rock Hill, SC). Marginal integrity and contacts were established using a #850.HP.016 tapered bur (Komet) and checked with Accufilm 2 (Parkell; Edgewood, NY). Occlusion was also checked for accuracy using Accufilm and burs (Fig 17).

At this point, photographs of the patient and the model were scrutinized

CLINICAL COVER STORY

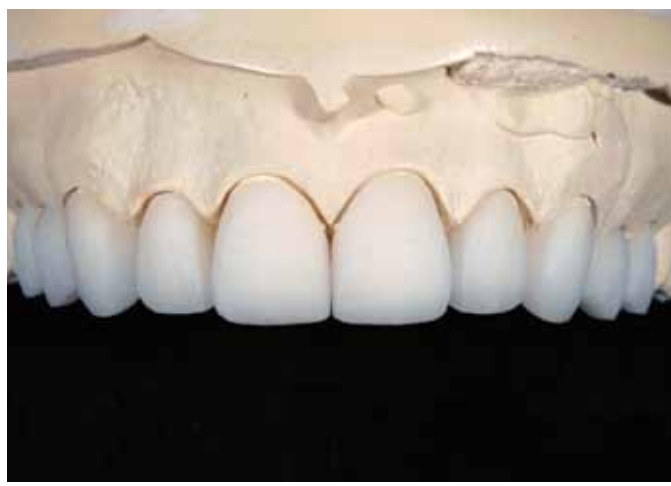

Figure 17: After pressing, seated on solid model.

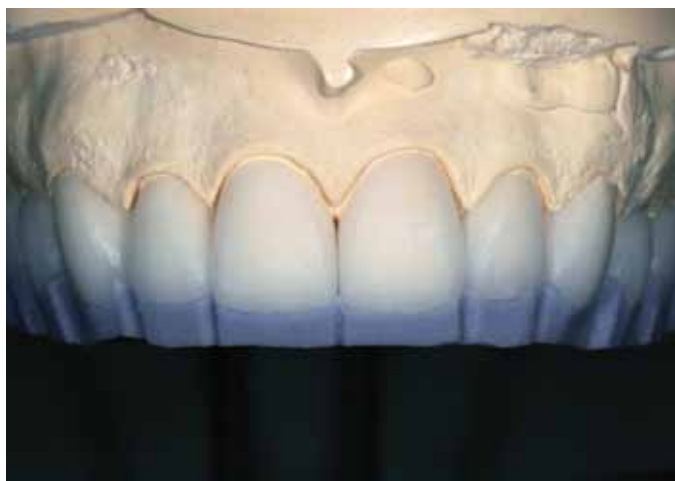


Figure 18: Veneers contoured with lingual matrix.

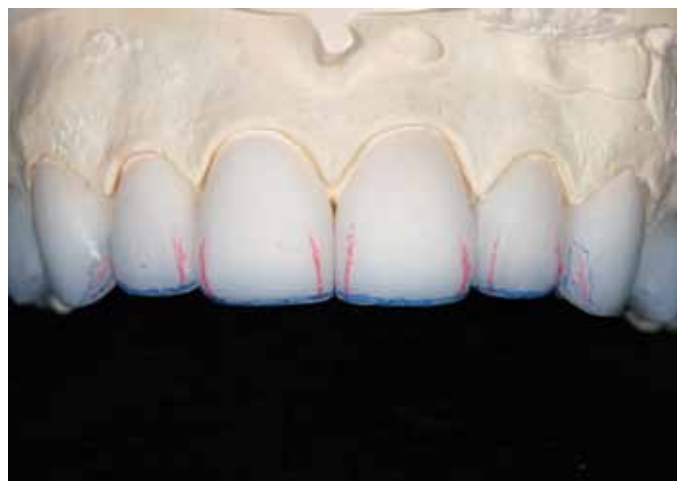

Figure 19: Cutback map defined.

to ensure that the shape and labial contours of the final restorations would match the patient's desired results. A lingual matrix was made of the patient's approved temporary model (Sil-Tech), and the lingual surface of the matrix was sprayed with pink fit checker (Quick-check Red, Vacalon; Pickerington, OH). The restorations were adjusted to fit the matrix, after which they were cleaned and a new matrix of the restorations was made on the solid model (Fig 18).

It is important to note that working from the patient's approved temporary model is significant to achieving successful outcomes because this model

represents what the patient expects and has verbalized as acceptable in terms of esthetics, fit, function, color, shape, etc. In esthetic dentistry, the ball can be dropped when a patient-approved temporary is not followed.

Therefore, tracing the approved temporary utilizing the lingual/incisal matrix allows for an exact duplication of the lingual side and incisal edge of the patient's approved provisional, which are key to the bite, function, and phonetics experienced in the final restorations. Building a case using the incisal/lingual matrix as a guide ensures that the final restorations will mimic what

the patient has been experiencing during the temporary period and helps to ensure predictability and success.

The restorations were then cut back for porcelain layering using a diamond-impregnated rubber wheel (Meister Point SD-61, Noritake Dental; Aichi, Japan). The incisal edge was dropped in .5 mm on ##7-10 and indicated with blue pencil. The mesial line angles of #6 and #11 were beveled and marked in blue and red. The mesial and distal grooves also were created for ##7-10, and areas to receive incisal effects were marked in red (Fig 19).

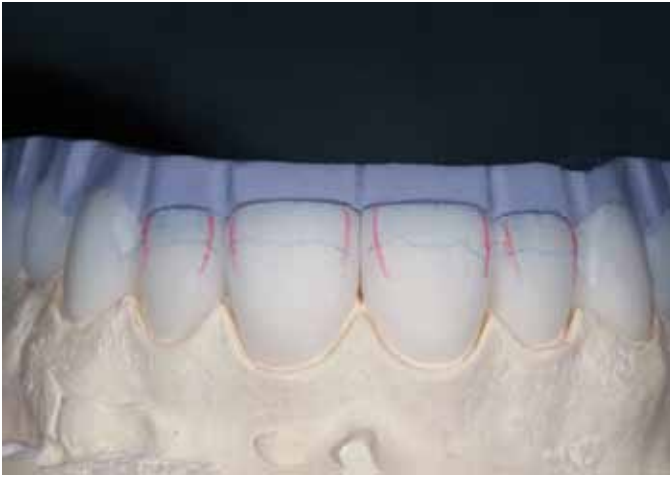

Figure 20: Cutback started, incisal reduced.

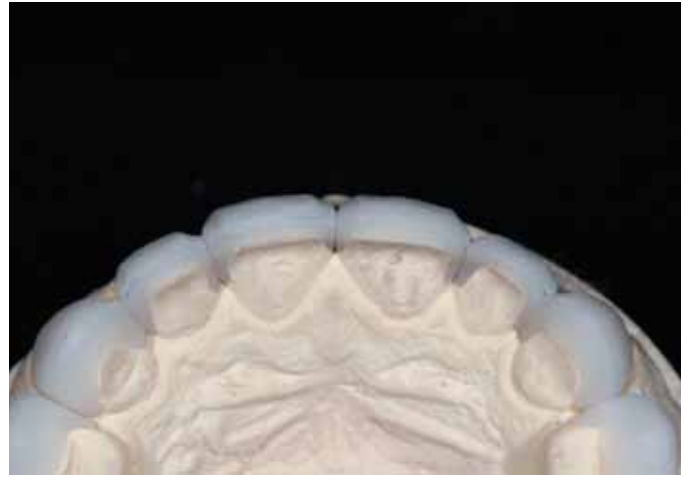

Figure 21: Incisal view showing mesial and distal grooves; incisal bevel from lingual of incisal edge to facial.

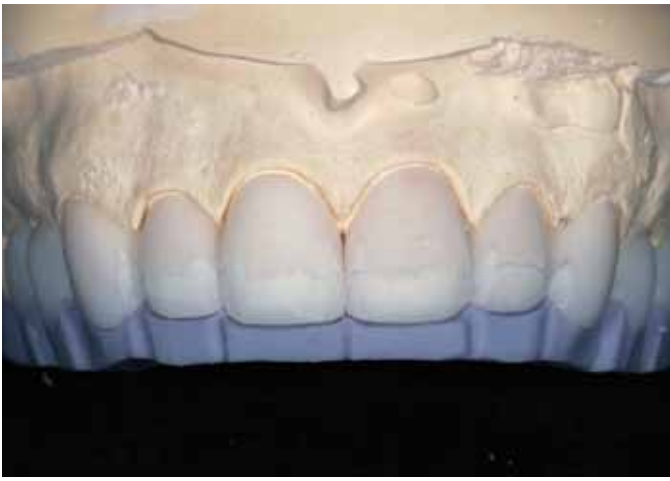

Figure 22: Labial view showing length of incisal blend.

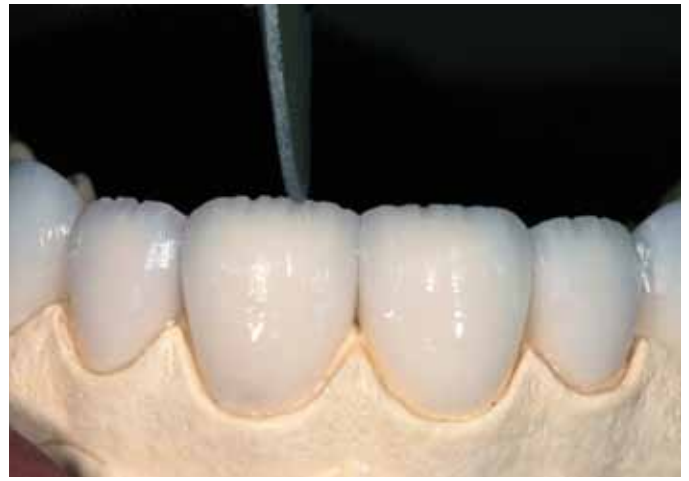

Figure 23: View of mamelon cutback; porcelain wetted to show depth of cutback.

The blue line on the incisal edge and the desired length of the incisal blend were then beveled at a 45-degree angle and checked into the matrix for appropriate depth (Figs 20 & 21). The key to establishing lifelike, subtle effects is to always refer to the matrix and ensure that all cutbacks are identical in each tooth (Fig 22).

To create the mamelon effect, each tooth was divided into three sections, divided into smaller sections, and then checked with the matrix for uniform thickness. The outside labial surface was decreased by .3 mm to .5 mm,

feathering out to the margins to enable porcelain layering over the entire length of the restorations (Fig 23). The units were then sandblasted at 20 psi to clean the surface.

Very highly fluoresced stains (Authentic) were applied internally using an S1 stain brush (Shofu Dental; San Marcos, CA) to mimic nature (Fig 24). Shade A and white stains were mixed 50/50, with the resulting color used for the mamelons. Shade B stain was lightly used in the gingival one-fourth and interproximal areas. Fluorescent Blue stain was used in the mesial and distal

grooves and very lightly across the incisal edge of the mamelon cutback.

After application, the stained restorations were fired in an oven (P500, Ivoclar Vivadent) to 735° C, holding for one minute in air and no vacuum. The stains were checked to ensure symmetry (Fig 25), and adjustments were made, if necessary.

A P7 brush (Shofu) was used to start the buildup. Using the incisal/lingual matrix lubricated with ceramic separating liquid (Ivoclar), the porcelain buildup was initiated with a 50/50 mix of Opal 1 and Opal 2, Opal 2 alone,

CLINICAL COVER STORY

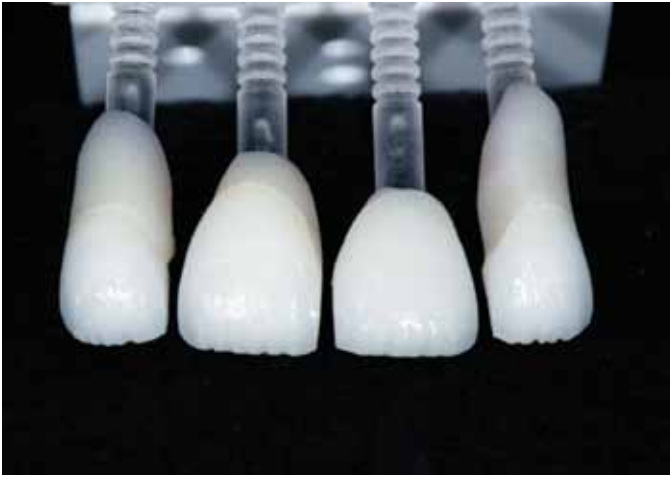


Figure 24: Stain applied.

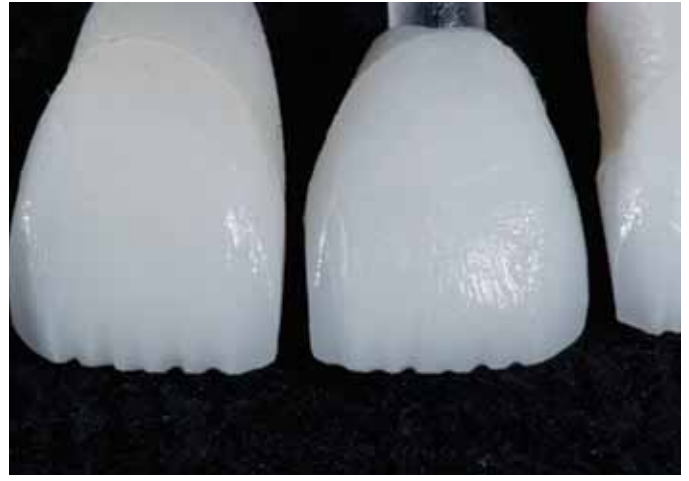

Figure 25: Close-up image of stain application.

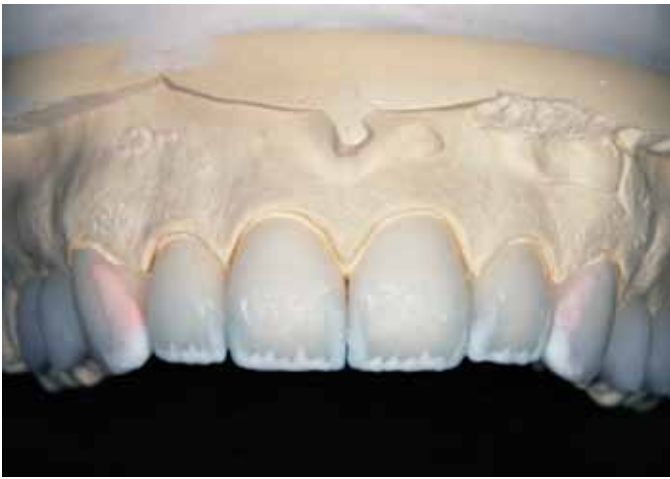

Figure 26: First layer of porcelain started. Pink = 50% Opal 1 and 50% Opal 2; blue = Transparent Blue Fluorescent; white = Opal 2.

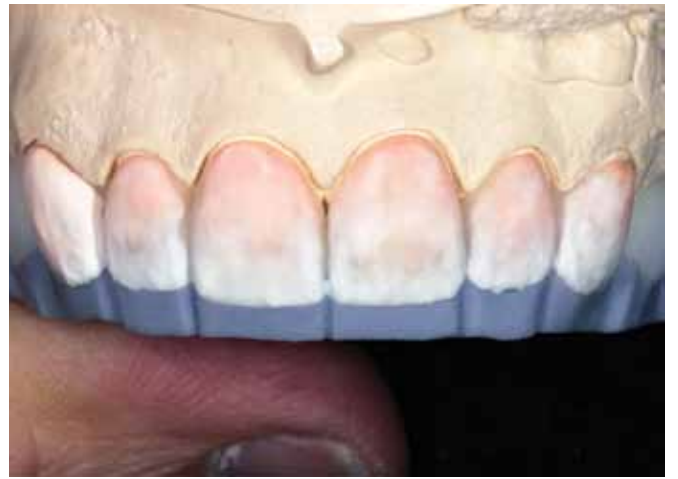

Figure 27: First layer finished with complete overlay of porcelain.

Transparent Blue Fluorescent by itself, and Opal 4, which is a Transparent Amber powder (Fig 26). Transparent Blue was used in the mesial and distal grooves of ##7-10, and the mesial line angles of #6 and #11. Opal 2 was used to fill #6 and #11 to contour, and to fill the incisal length of #7 and #10.

The lubricated matrix was placed over the wet porcelain, which was carefully blended toward the gingival with Opal 2 at about 3 mm to 4 mm from the incisal edge. At this point, micro-layering with a mix of Opal 1 and Opal 2 was used to complete all the restora-

tions to full contour (Fig 27). The interproximals were sliced, and contacts were not added.

The restorations were fired at 785° C under vacuum and held in air for one minute. The units were placed back on the model (Fig 28) and the matrix re-lubricated.

The 50/50 mix was added to the mesial and distal, .5 mm taller than the restorations. Then, Opal 4 was used to mimic the amber incisal edge, going from mesial to distal (Fig 29). The matrix was seated, after which that blend was completed using Opal 2. The 50/50

mix was applied to create the final contour and line angles of the teeth and, once sliced, .5 mm of the 50/50 mix was added to the mesial and distal corners of ##7-10.

The restorations were fired at 780° C under vacuum with a one-minute hold under air (Fig 30). The contacts were fit, and the buildup matrix was sprayed (Quickcheck Red) and fit back onto the solid model; then the temporary matrix was sprayed and fit to verify the accuracy of the length compared to the approved temporaries.

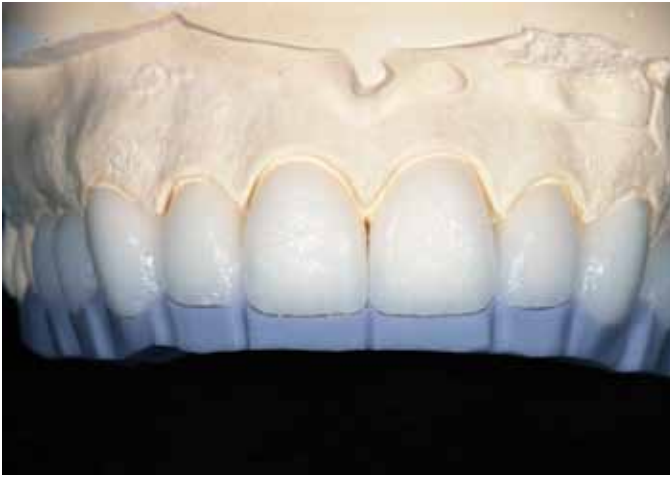

Figure 28: First layer of porcelain fired.

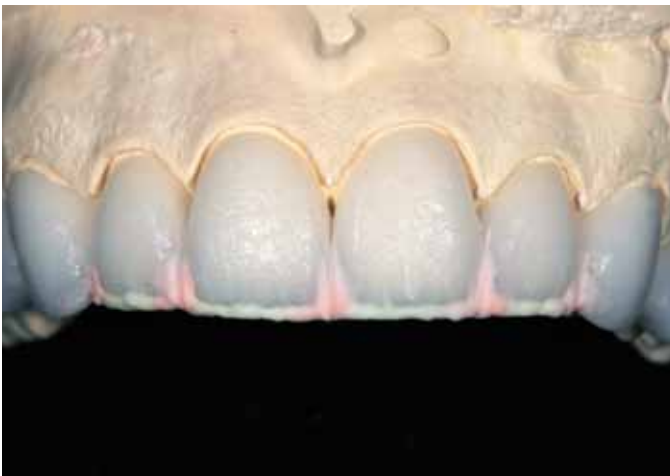


Figure 29: Second layer started; pink = 50% Opal 1 + 50% Opal 2; yellow = Opal 4 (amber).

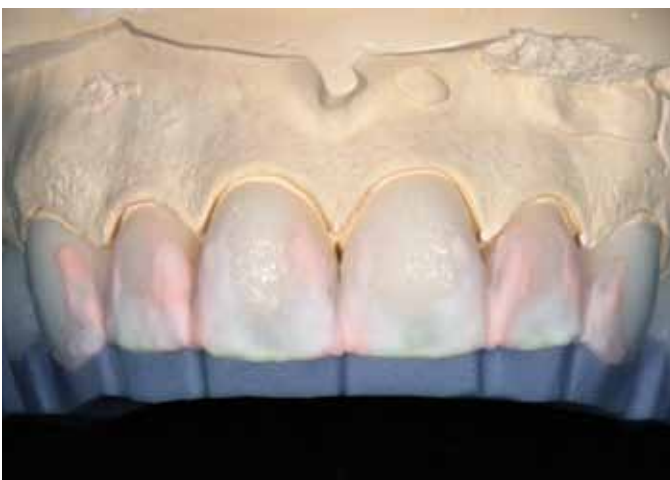

Figure 30: Second layer complete.

Burs (863.HP.012, 850.HP.016, Komet) were used to create tooth morphology, anatomy, and surface texture, after which a low-fusing glaze (Authentic) was applied and the units fired at 710° C in air. The contacts and occlusion were checked with Accufilm, and all units were polished with a #12 Buffalo bristle brush (Abbot-Robinson, Pearson Dental; Sylmar, CA) with Diashine fine-grit polisher (VH Technologies; Lynnwood, WA) (Fig 31). The units were etched and returned to the dentist for delivery to the patient.

Cementation

Upon return from the ceramist, the porcelain restorations were inspected on the dies for marginal fit and on solid models for proper interproximal contacts. They were also inspected under magnification for any possible packing and shipping damage. Profound anesthesia was obtained through the use of a topical anesthetic, followed by infiltration injections at #4 and #13 and bilateral anterior middle superior alveolar injections of articaine with 1:100,000 epinephrine to allow the patient more control of her lip during and after the seating appointment. The provisional veneers were removed with a scaler and hemostats. The preparations were pumiced to clean off any residual resin, temporary material, or debris. The veneers were then tried into the patient's mouth and evaluated for fit and esthetics (first individually, then collectively with a glycerin-based try-in gel). The patient then viewed her smile in a hand mirror. No adjustments were needed and the patient approved the esthetic appearance.

The veneers were removed from the patient's mouth and carefully cleaned and re-etched to remove any possible contamination. The veneers were then placed in an ultrasonic cleaner under distilled water for three minutes.

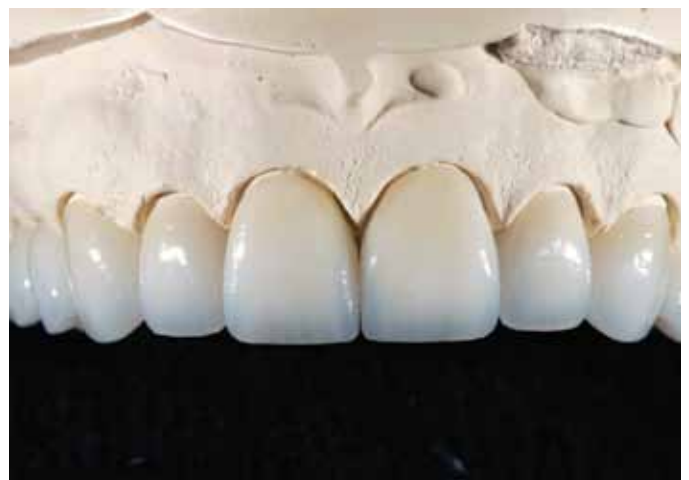

Figure 31: Completed stained and glazed restorations on solid model.

CLINICAL COVER STORY



Figure 32: The patient's restored smile.

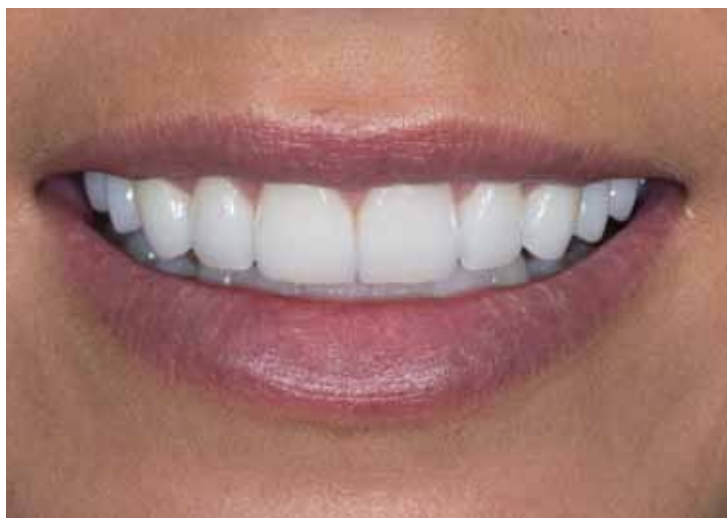

Figure 33: The restored full smile demonstrates proper progression of incisal embrasures and treatment of buccal corridors.

She was excited by the idea of having her teeth restored in a conservative manner, without having to pursue prolonged orthodontic treatment.

Upon removal from the water, they were dried with oil-free compressed air, and silane coupling agent (Ultradent) was applied to the intaglio of the veneers.⁹ After one minute they were dried again and a thin coating of Excite bonding agent (Ivoclar Vivadent) was applied to the inside of the veneers and air-thinned. RelyX Translucent Veneer Cement (3M ESPE; St Paul, MN) was applied to the veneers and they were immediately placed into a ResinKeeper light-safe box (Cosmedent) to prevent polymerization of the resin.^{3,4}

A split rubber dam was applied to isolate the prepared teeth from the oral environment. The preparations were then acid-etched for 15 seconds and the 35% Ultra-Etch phosphoric acid gel etchant (Ultradent) was removed with a copious air and water spray.^{3,4} All preparations were lightly dried, but not desiccated, with oil-free compressed air.^{3,4} The preparations were left moist and bonding agent was applied to each preparation and agitated for 20 seconds prior to air-thinning to evaporate solvents. The bonding agent was then cured for 20 seconds with a Fusion LED curing light. The veneers were removed from the light-safe box and seated on their respective preparations. Excess cement was removed with a Regular Microbrush (Grafton, WI) and they were tacked into place for five seconds each with the LED curing light.¹⁰ Additional excess was gently removed with a scaler, floss was passed through the contacts in the apical direction only, and the veneers were cured fully for an additional 30 seconds each.¹⁰ The margins were inspected and any excess cured cement was removed with a #12 scalpel blade.¹⁰ Interproximal areas were cleaned with Eptax finishing strips (GC America; Alsip, IL). DeOx oxygen-inhibiting gel (Ultradent) was placed around all margins and the restorations were cured an additional 10 seconds to finalize polymerization.^{3,4,9} Rubber dam isolation was removed and occlusal marking paper was used to evaluate the occlusion in CO and in excursive movements. The lingual aspect was then polished with diamond paste and Flexi-Buff polishers (Cosmedent) in a slow-speed handpiece.

The patient's teeth were inspected again for any excess restorative material. The occlusion was checked again and smooth, proper contacts were verified with unwaxed floss.

The patient returned the following day and her functional occlusion was evaluated and her teeth were inspected for any residual cement. Also at this 24-hour postoperative check appointment, maxillary and mandibular alginate impressions were made along with a PVS bite registration to be used for fabrication of a maxillary full-arch bite guard for nighttime wear.³

• COMPLETELY INTEGRATED • COLOR-CODED • WEAR RESISTANT • TOP RATED



Top Finishers™

Every
Patient.
Any
Restoration.



- **FlexiDiscs® (regular and mini)** are Better, Easier and Cheaper! Thin, highly flexible and resilient discs recommended as top choice for over 20 years. "Rates even with leading disc but half the price."
- **FlexiStrips™** contour and polish all interproximal surfaces exceptionally. "Ultrathin modification makes these strips easy-to-use."
- **FlexiCups™ and FlexiPoints™** are very wear resistant. These rubber cups and points polish gingival margins and hard to reach areas and impart labial characterization. "#1 rated rubber polishing instruments."
- **Enamelize™ and FlexiBuff™** The Final Polish! Doctors are amazed at the highly polished surface after using Enamelize, FlexiBuff and Felt FlexiPoint. "Great choice and a terrific value."
- **And More Top Finishers:** FlexiDiamond Strips; NANO/Microhybrid Diamond Polishing Kit; Porcelain Diamond Polishing Kit; Porcelize™ Diamond Polishing Paste, and mandrels.

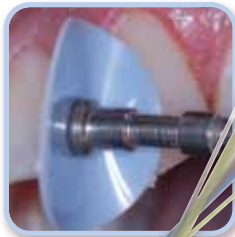

FlexiDiscs



FlexiPoints

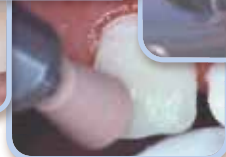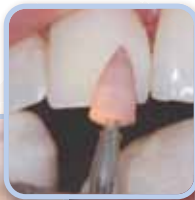Enamelize and FlexiBuff



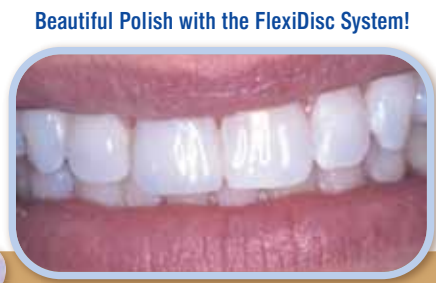
Look at the FLEX!



FlexiStrips



FlexiCups



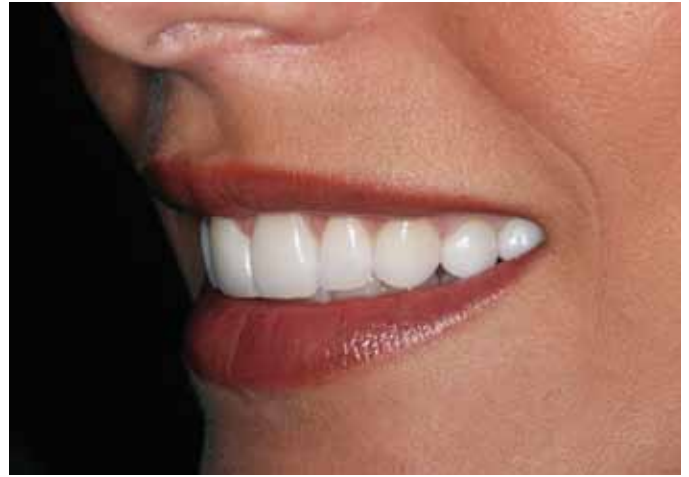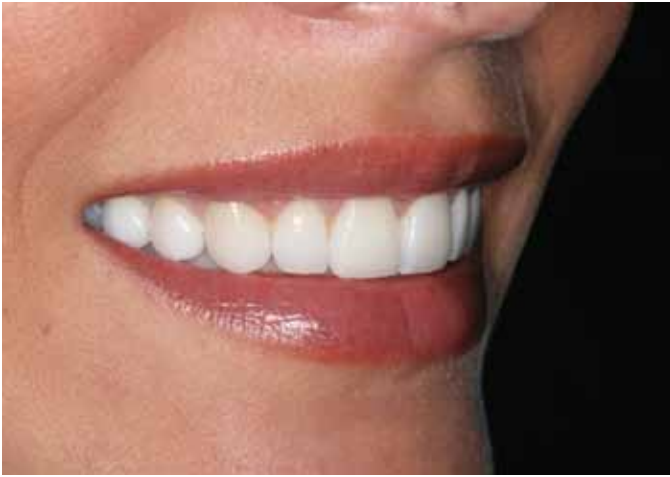Beautiful Polish with the FlexiDisc System!

TRY OUR 30 DAY
RISK-FREE GUARANTEE.

COSMEDENT®
Spreading Smiles™

to order Top Finishers
800-621-6729
WWW.COSMEDENT.COM

CLINICAL COVER STORY



Figures 34a & 34b: Restored right and left lateral full-smile images demonstrate proper progression of incisal embrasures.

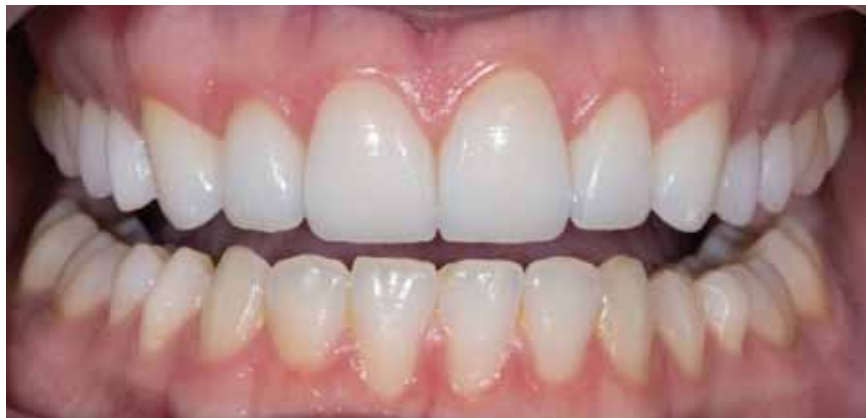
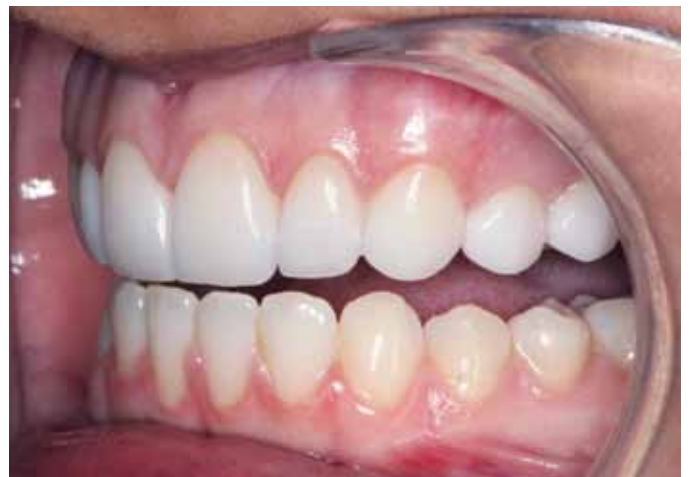
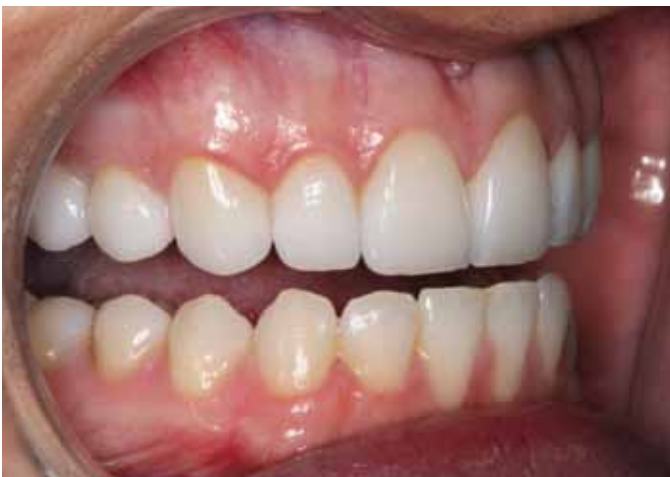Figure 35: Restored retracted 1:2 view demonstrates proper shape and proportions, resulting in a more harmonious smile.



Figures 36a & 36b: Restored right and left lateral retracted 1:2 views exhibit a more harmonious progression of incisal embrasures and transition from the anterior to the posterior.

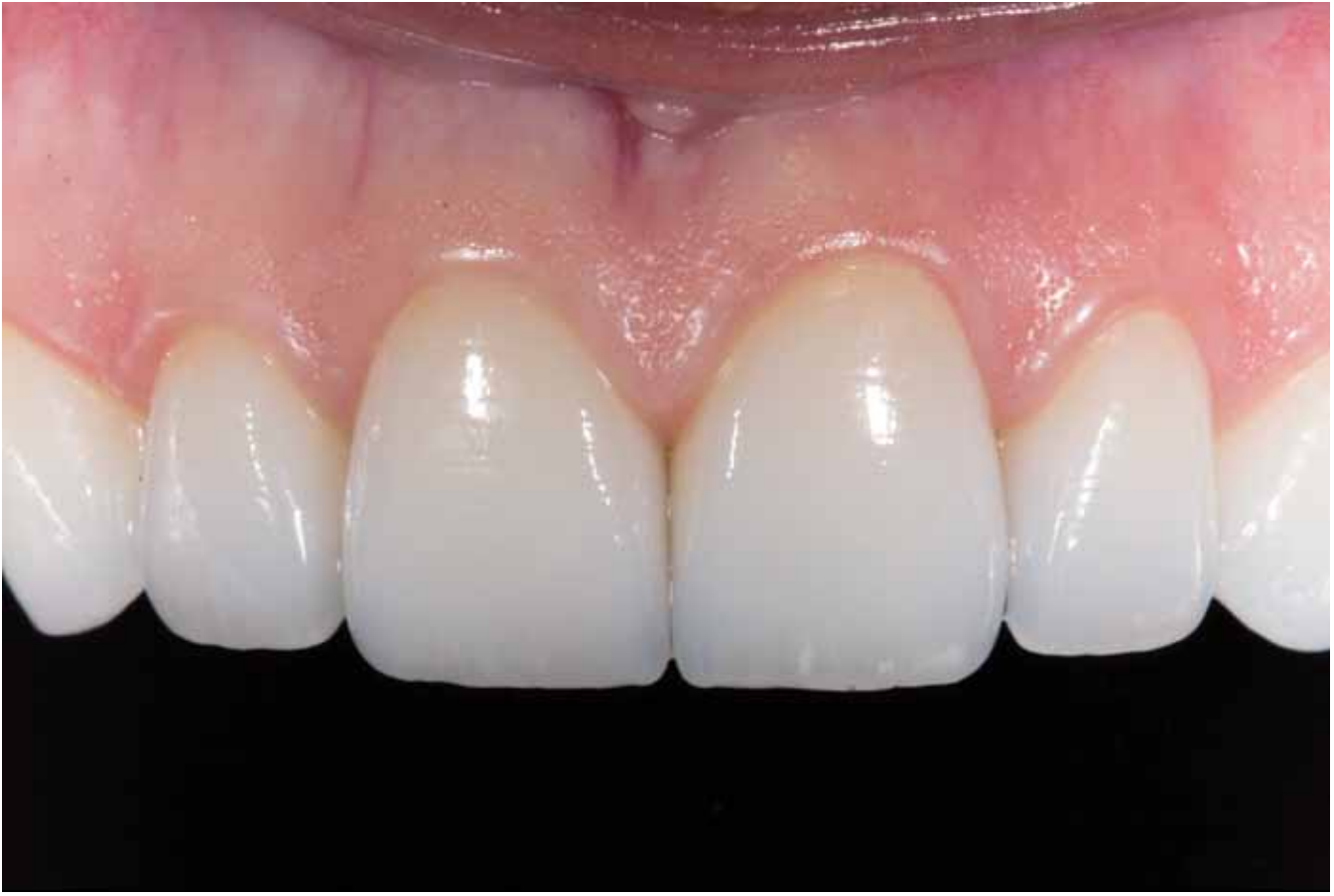
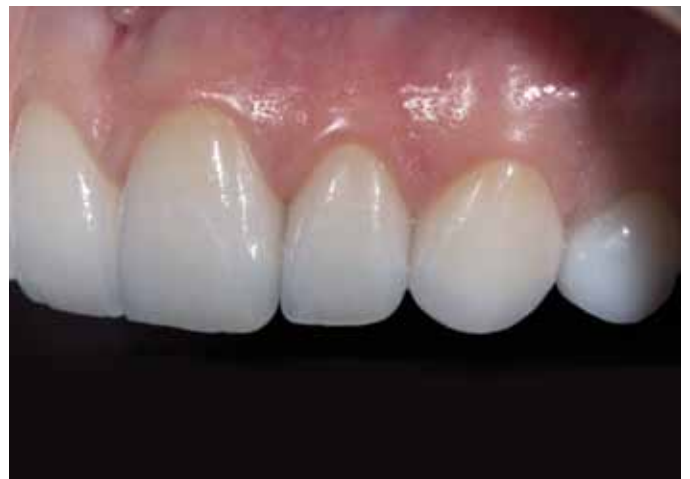
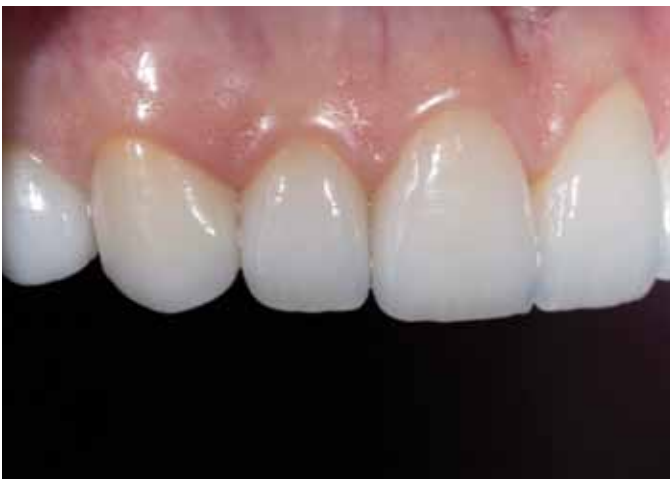Figure 37: Restored retracted 1:1 view demonstrates proper shape and proportion, resulting in a more harmonious smile. The distal incisal developmental defect on #9 has been corrected to mirror the appearance of #8.



Figures 38a & 38b: Restored retracted right and left lateral 1:1 views demonstrate proper shape and proportion, resulting in a more harmonious smile. The distal incisal developmental defect on #9 has been corrected to mirror the appearance of #8.

CLINICAL COVER STORY

Postoperative home care instructions were given and the patient was scheduled for a follow-up appointment for radiographic and photographic documentation, a final check for function and esthetic evaluation, and delivery of the maxillary protective bite guard³ (Figs 32-40).

Conclusion

Porcelain veneers can be employed to provide beautiful, natural, long-lasting functional cosmetic results. This patient presented with some very precise requests. Careful planning, great communication, and meticulous use of contemporary dental materials yielded an excellent result that surpassed the patient's expectations.

References

1. American Academy of Cosmetic Dentistry. Diagnosis and treatment evaluation in cosmetic dentistry: a guide to Accreditation criteria. Madison (WI): The Academy; 2001.
2. Dawson PE. Evaluation, diagnosis, and treatment of occlusal problems. St. Louis (MO): Mosby; 1989.
3. Magne P, Belser U. Bonded porcelain restorations in the anterior dentition: a biomimetic approach. Hanover Park (IL): Quintessence Pub.; 2002.
4. Gurel G. The science and art of porcelain laminate veneers. Hanover Park (IL): Quintessence Pub.; 2003.
5. Rufenacht CR. Fundamentals of esthetics. Hanover Park (IL): Quintessence Pub.; 1992.
6. Fradeani M. Esthetic analysis: a systematic approach to prosthetic treatment. volume 1. Hanover Park (IL): Quintessence Pub.; 2004.
7. Goldstein RE. Esthetics in dentistry. Hamilton (ONT, CA): B.C. Decker; 1998.
8. Flax H. Smile enhancement with laser technology—predictable and esthetic: a case report. *J Cosmetic Dent.* 2007;23(1):92-8.
9. Touati B, Quintas AF. Aesthetic and adhesive cementation for contemporary porcelain crowns. *Pract Proced Aesthet Dent.* 2001;13(8):611-20.
10. Miller MB. Reality: the techniques: volume I. Houston (TX): Reality Publishing; 2003. **JCD**

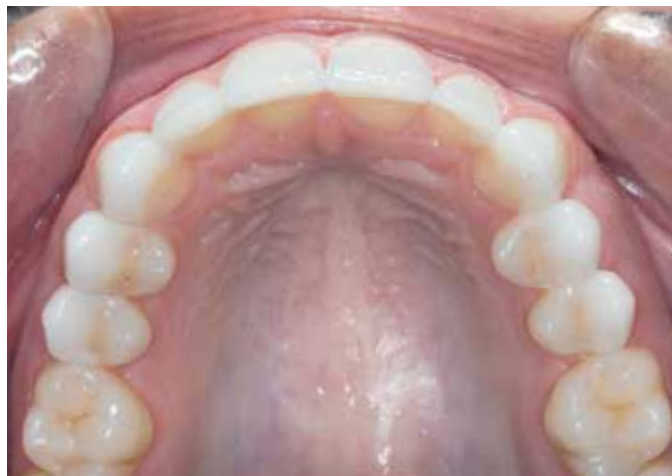

Figure 39: Maxillary postoperative occlusal view demonstrates corrected arch form and proper facial embrasures.

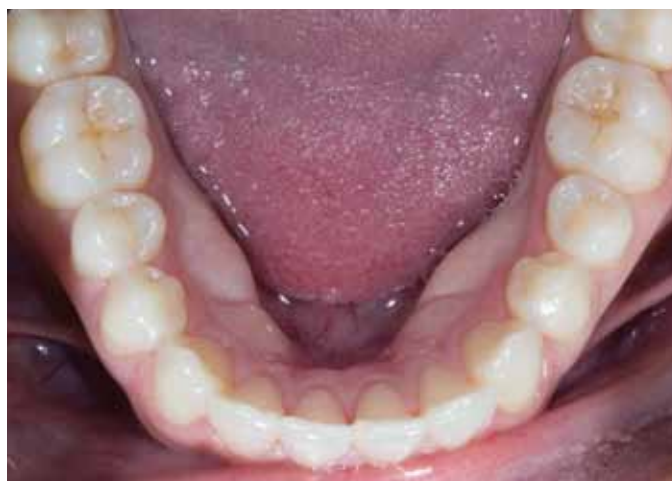

Figure 40: Postoperative mandibular occlusal view demonstrates no changes.




Dr. Rowe is an AACD Accredited Member, an AACD Accreditation Examiner, and a member of the American Board of Cosmetic Dentistry. He graduated from the University of Tennessee College of Dentistry in 2000 and owns a practice with his wife, Dr. Kristy Rowe, in Jonesboro, Arkansas.

Mr. Payne owns a dental laboratory in San Clemente, California, and is an Accredited Member of the AACD.

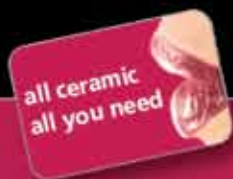Disclosures: Dr. Rowe serves as a clinical evaluator for DMG America. Mr. Payne did not report any disclosures.

The Authority on Aesthetics



WESTLUND DENTAL STUDIO

www.westlunddental.com | 800.728.9641



Westlund Dental Studio recommends the Strength, Durability and Esthetics of
IPS e.max[®] lithium disilicate

IPS e.max is a registered trademark of Ivoclar Vivadent.

**ivoclar
vivadent:**
passion vision innovation

▶ Myths vs.

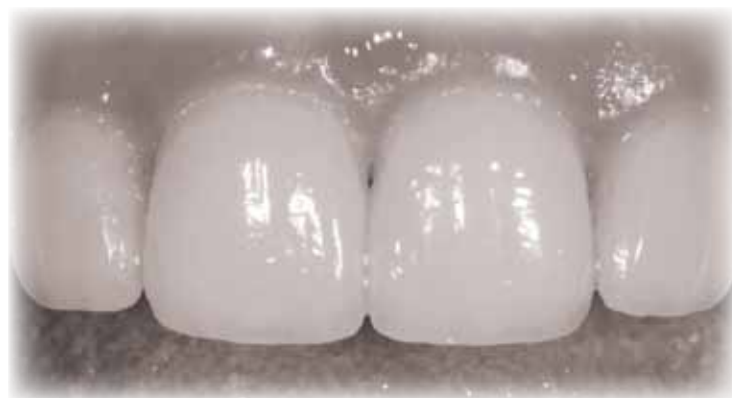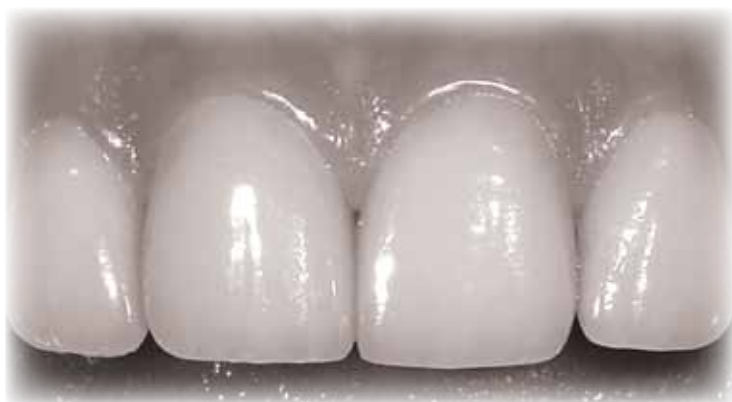Two Viewpoints on Prepared

jCD is pleased to offer readers a discussion on the issue of prepared and “prep-less” veneers. Here, Drs. Brian LeSage and Dennis Wells address some “myths vs. realities” regarding these two treatment modalities.

Realities

Veneers and Prep-Less Veneers

Brian LeSage, DDS, FAACD
Dennis Wells, DDS, AAACD



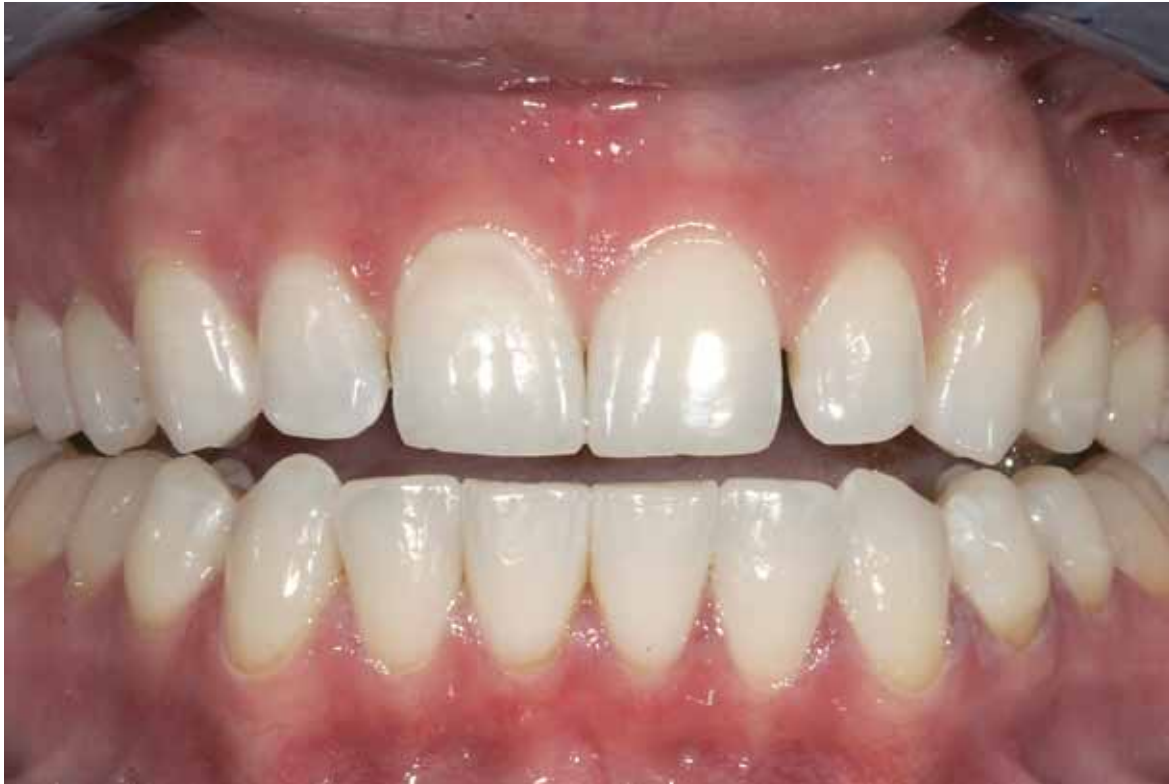

Figure 1: Preoperative retracted view showing diastemas, slight rotations, and asymmetries. Orthodontic treatment was declined even after an Invisalign work-up and ClinCheck.

Introduction

Lack of clear-cut guidelines for veneer preparations has led to myths and misunderstandings. Veneers originally were introduced as conservative, additive restorative methods for which little to no preparation was required.^{1,2} Feldspathic veneers were layered very thinly and could be placed conservatively, directly on enamel, and without significant removal of tooth structure.³

The veneer technique evolved to emphasize not maintaining tooth structure, but accommodating material requirements to satisfy esthetic and strength demands, and maintaining the convenience of the laboratory model. As new materials compensated for shortcomings in the strength of feldspathic veneers,³ laboratories embraced familiar waxing techniques, despite the more aggressive tooth reduction necessary (i.e., .75 mm or more) to ensure natural emergence profiles and esthetic nuances.⁴⁻⁶

Myth vs. Reality

The myth that prepared veneers need to be .75 to 1 mm in depth, which leads to exposed dentin, has contributed to over-preparation in many cases. Yet it has been customarily accepted as convention, even though today's pressed veneer options now can be made very thin.

The reality is that individual cases and their respective clinical criteria dictate material selection and preparation requirements, with different indications requiring different veneers, materials, and preparation designs. There is no one universal standard.

Proposed Classification System

Currently under peer review is an article detailing a new veneer classification system introduced by this author to clarify the gray zone between conventional veneer preparation and no or minimal-preparation veneers. This system is briefly addressed here. The four-class metric (CL-I through CL-IV) helps quantify tooth structure removal on a case-by-case basis. Although minimal to no preparation is the goal, it is not always ideal or possible.

For example, even with "prep-less" veneers, many ceramists prefer a loupes-detectable finish line to clarify porcelain margins and facilitate seating of the veneers. Such a nearly imperceptible preparation (CL-I) is easily accomplished using a bis-acrylic preparation guide made from a putty or silicone matrix of the diagnostic wax-up that is then placed on the teeth^{7,8} (Figs 1 & 2). Depth cuts of .5 mm are placed into the incisal and facial aspects of this guide (Fig 3), resulting in the depth-cutting bur often not even touching or barely touching enamel (Figs 4-6). This leads to a preparation that only removes aprismatic enamel, minimizing potential for over-preparation, and creating a nearly undetectable finish line (Figs 7 & 8).

This preparation design—as opposed to the more aggressive .75 mm to 1 mm, is possible and ideal when patients present with no exposed dentin, 95 to 100% enamel remaining, and/or peg-laterals, genetic anomalies that lead to smaller teeth, short and worn teeth, or orthodontics that lead to narrow arches, or larger lips. Such minimal preparation may not be ideal if significant shade alternations, correction of axial inclination, or gingival symmetry and proportion irregularities exist.^{9,10} Additionally, veneers placed with no preparation have been shown to contribute to periodontal problems as a result of over-contoured teeth that change the emergence profile (Fig 9).^{11,12}

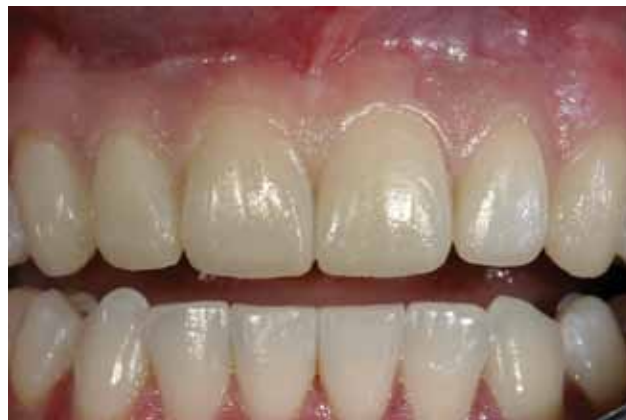

Figure 2: Bis-acrylic placed on unprepared teeth using a putty matrix made from the diagnostic wax-up as a preparatory guide. Demonstrates full and final contour of definitive minimally invasive porcelain restorations.

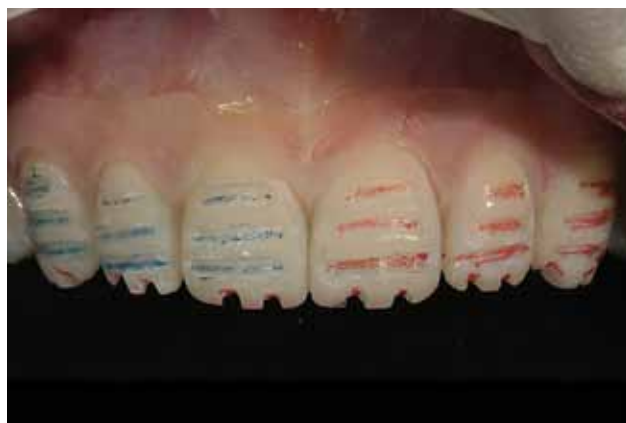

Figure 3: Depth-cutting grooves using a .5-mm depth-cutting bur directly into the bis-acrylic. Red and blue pencil lines are placed in grooves for ease of visibility.

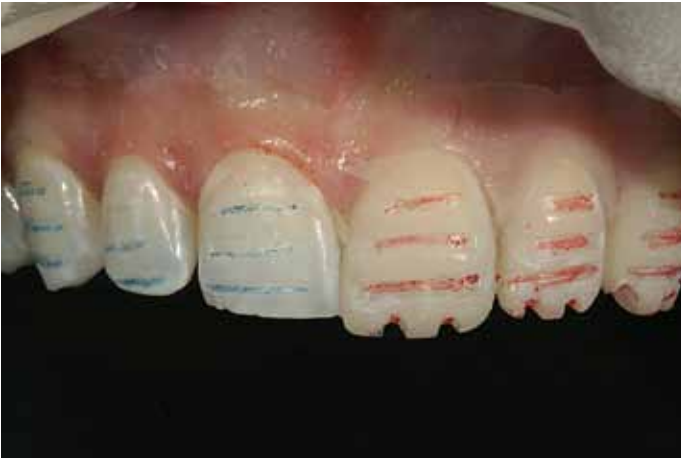

Figure 4: Bis-acrylic preparatory guide removed from ##6-8, showing minimal reduction to enamel to achieve diagnostic work-up result.

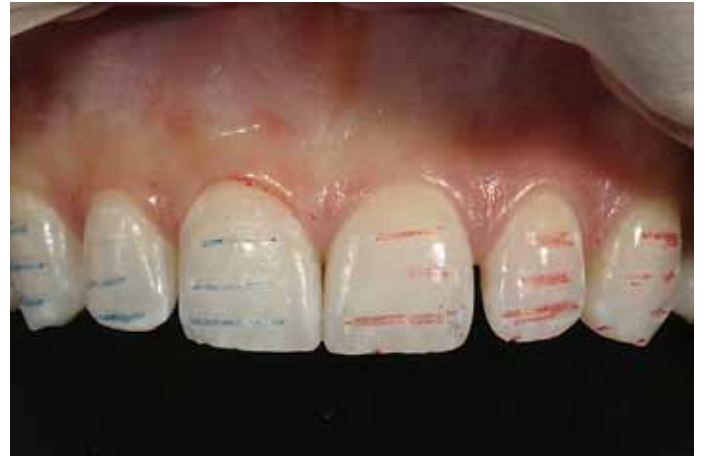

Figure 5: Bis-acrylic removed from ##6-11. Note some areas have not even been touched; no preparation was needed in those zones except to be contiguous with the remaining preparation.

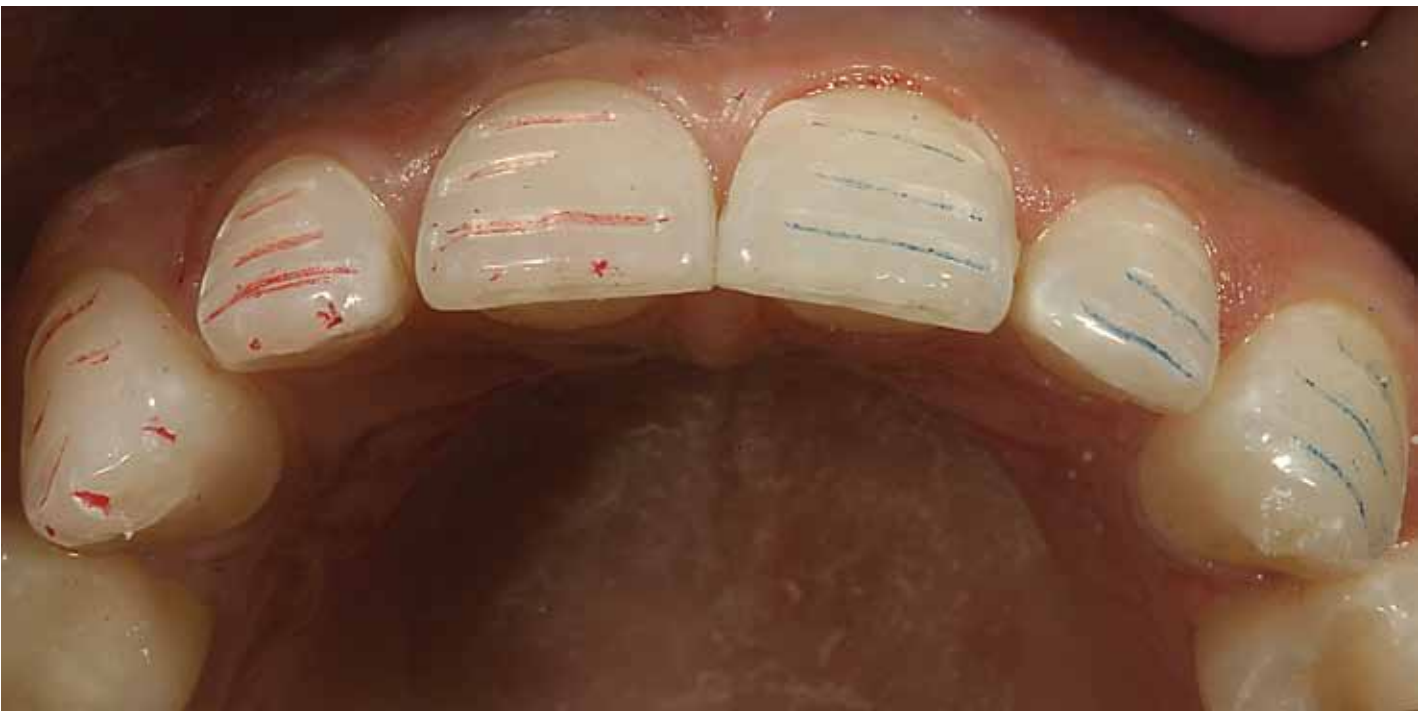

Figure 6: Occlusal view showing depth-cutting grooves. No area has even .5 mm of prepared enamel.

The myth that prepared veneers need to be .75 to 1 mm in depth, which leads to exposed dentin, has contributed to over-preparation in many cases.

A minimally invasive or “modified prep-less” veneer design (CL-II) may be appropriate when 80 to 95% enamel remains, with only 10 to 20% exposed dentin. Depth cuts are still limited to .5 mm, although the gingival margin may consist of slightly more dentin to establish a clear margin.¹³

Both preparation classes enable dentists to achieve optimal bonding, which occurs when the substrate is enamel as opposed to dentin. Long-term enamel bonding success makes no-preparation and minimal preparation veneers the preferred treatment.^{1,9,14,15}

To successfully bond veneers, 50% or more enamel must remain, 50% of the bonded substrate must be enamel, and 70% or more of the peripheral margin must be in enamel.⁴ The cingulum and lingual marginal ridges should be preserved, since these provide more than 80% of the tooth’s strength.^{4,16}

Conservative veneer preparations still can be realized when 60 to 80% enamel volume remains and 20 to 40% dentin is exposed. Tooth reduction may range from .5 mm to 1 mm and, although the gingival margin will typically involve more dentin because there is more room for restorative material,¹³ more than 70 to 80% of the finish line must still be in the enamel (CL-III).

The universally accepted full-veneer preparation design (CL-IV) consists of approximately 50% enamel volume remaining, more than 40% exposed den-

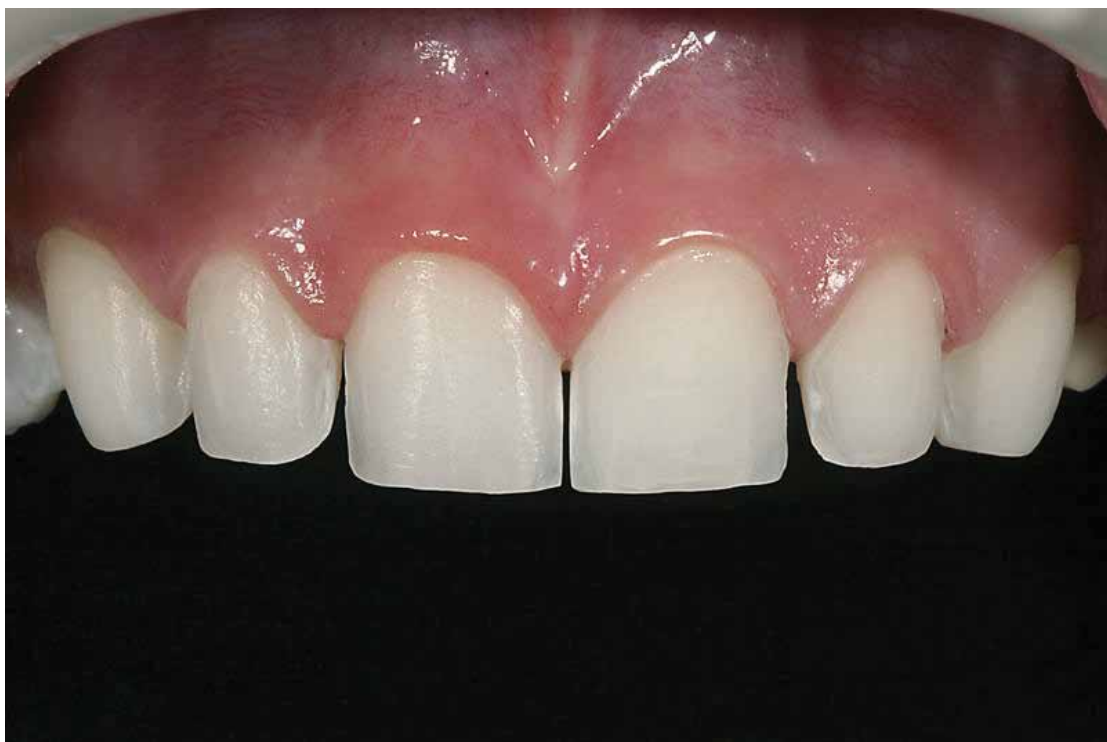

Figure 7: Final preparation to allow for diastema closures and rotations. There is no dentin exposure with the aid of preplanning and a bis-acrylic preparatory guide.

tin, and 1 mm or more of reduction. The peripheral margin may consist of only 50 to 70% enamel. Functional and esthetic limitations of this veneer preparation design include lower fracture loads and decreased marginal accuracy that contribute to restorative failure.^{17,18} Preparation design and fatigue influence the marginal accuracy of veneers, with significantly higher marginal gap formations developing in complete veneer preparations.^{18,19}

Summary

Veneers and their preparation designs are predicated on space requirements, working thickness, or material room; volume of enamel remaining; enamel periphery; and percentage of dentin exposed.^{3,4,7,8,15,16} These parameters dictate material selection and, therefore, preparation requirements, based on tooth col-

or, position, function (centric-relation mounted models, vertical dimension of occlusion, envelope of function), stress analysis; and patient expectations. Such case-by-case variations in preparation requirements debunk the myth that veneer preparations must be .75 mm to 1 mm in depth.

References

1. DiMatteo AM. Prep vs no-prep: the evolution of veneers. *Inside Dent*. 2009;5(6):72-9.
2. Calamia JR. Etched porcelain facial veneers: a new treatment modality based on scientific and clinical evidence. *NY J Dent*. 1983;53(6):255-9.
3. Giordano RA. A comparison of all-ceramic restorative systems. *J Mass Dent Soc*. 2002;50(4):16-20.

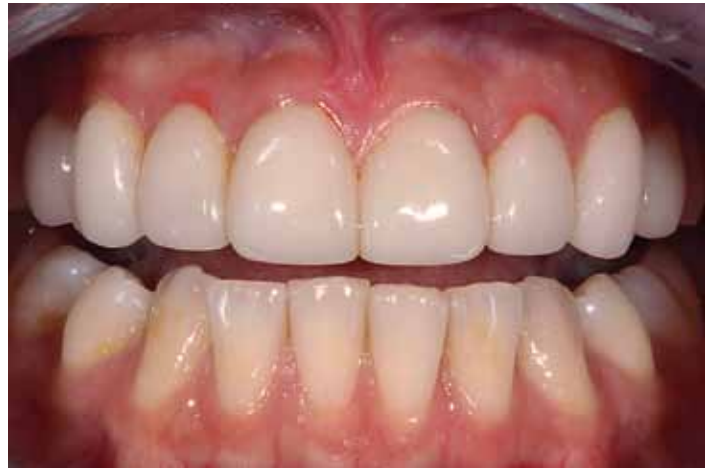
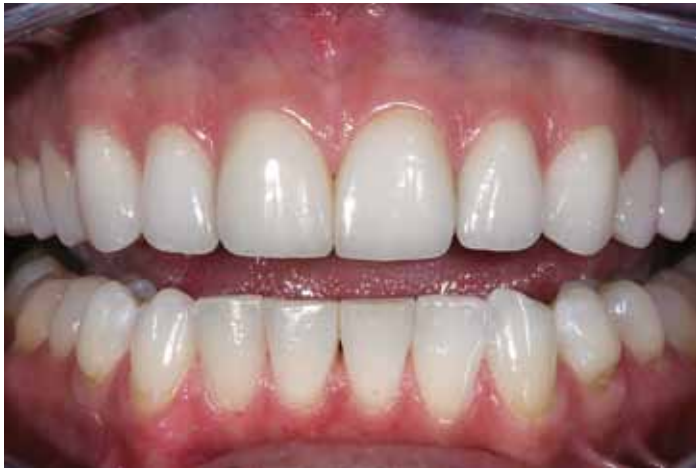
Figure 8: All-porcelain restorations on ##6-11 showing desired esthetic outcome. This outcome is expected when bonding exclusively to enamel and with minimal preparation with gingival health in mind.

Figure 9: Retracted image demonstrating esthetic and gingival health issues that can arise with improper diagnostic and esthetic planning with prep-less veneers.

4. McLaren EA, Cao PT. Ceramics in dentistry—part 1: classes of materials. *Inside Dent.* 2009;5(9):94-103.
5. Roulet JF, Degrange M. Adhesion: the silent revolution in dentistry. Hanover Park (IL): Quintessence Pub.; 2000.
6. Friedman MJ. A 15-year review of porcelain veneer failure—a clinician's observations. *Compend Contin Educ Dent.* 1998;19(6):625-30.
7. Gurel G. Porcelain laminate veneers: minimal tooth preparation by design. *Dent Clin North Am.* 2007;51(2):419-31, ix.
8. Gurel G. Predictable, precise, and repeatable tooth preparation for porcelain laminate veneers. *Pract Proced Aesthet Dent.* 2003;15(1):17-24; quiz 26.
9. LeSage BP. Revisiting the design of minimal and no-preparation veneers: a step-by-step technique. *J Calif Dent Assoc.* 2010 Aug;38(8):561-9.
10. Javaheri D. Considerations for planning esthetic treatment with veneers involving no or minimal preparation. *J Am Dent Assoc.* 2007;138(3):331-7.
11. Calamia JR. The current status of etched porcelain veneer restorations. *J Philipp Dent Assoc.* 1996;47(4):35-41.
12. Calamia JR, Calamia CS. Porcelain laminate veneers: reasons for 25 years of success. *Dent Clin N Am.* 2007;51:399-417.
13. Brunton PA, Wilson NH. Preparations for porcelain laminate veneers in general dental practice. *Br Dent J.* 1998;184(11):553-6.
14. LeSage BP. Minimally invasive dentistry: paradigm shifts in preparation design. *Pract Proced Aesthet Dent.* 2009;21(2):97-101.
15. Magne P, Douglas WH. Porcelain veneers: dentin bonding optimization and biomimetic recovery of the crown. *Int J Prosthodont.* 1999;12(2):111-21.
16. Magne P, Belser U. Bonded porcelain restorations in the anterior region: A biomimetic approach. Hanover Park (IL): Quintessence Pub.; 2002.
17. Rouse JS. Full veneer versus traditional veneer preparation: a discussion of interproximal extension. *J Prosthet Dent.* 1997;78(6):545-9.
18. Chun YH, Raffelt C, Pfeiffer H, Bizhang M, Saul G, Blunck U, Roulet JF. Restoring strength of incisors with veneers and full ceramic crowns. *J Adhes Dent.* 2010;12(1):45-54.
19. Stappert CF, Ozden U, Att W, Gerds T, Strub JR. Marginal accuracy of press-ceramic veneers influenced by preparation design and fatigue. *Am J Dent.* 2007;20(6):380-4. **JCD**



Figure 1: Prep-less (DURATHIN; Brentwood, TN) veneers, ##5-12.

Introduction

One of this author's first articles on no-prep veneers was called "Prepless Veneers—Ridiculous or Reality?"¹ The title is still relevant today, as opinion leaders continue to state their views in lectures and journals with a broad range of conflicting beliefs—most with a great degree of skepticism. It is the author's position that refined techniques, new and improved materials, and better training in emulating nature have enabled "prep-less" veneers to rival (or in some cases, even exceed) traditionally prepared veneers in overall beauty and natural appearance.

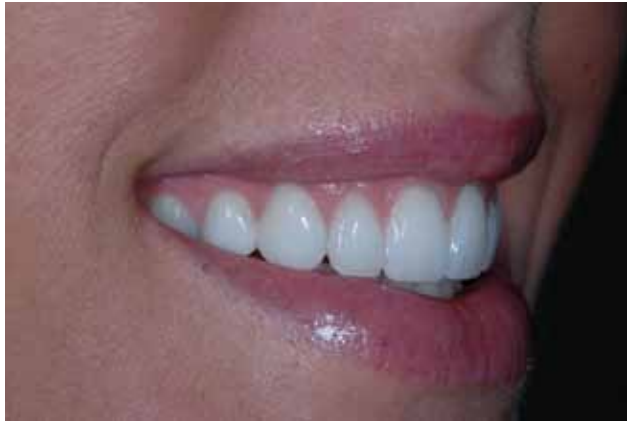

Figure 2: Prep-less veneers, ##5-12. Note the pleasing emergence profile and excellent tissue health.

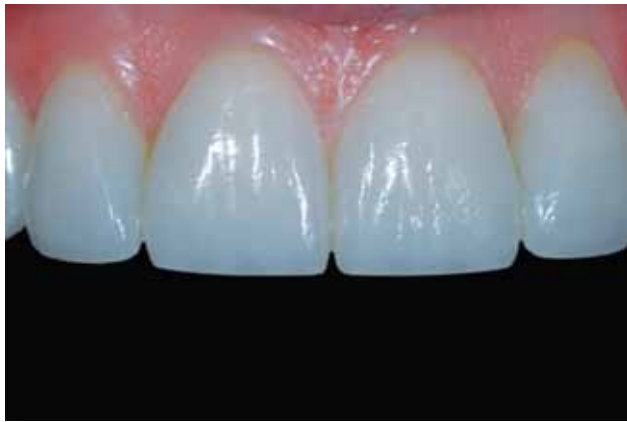

Figure 3: Feathered "infinity" margins at 1:1. Note undetectable margins and excellent tissue health.

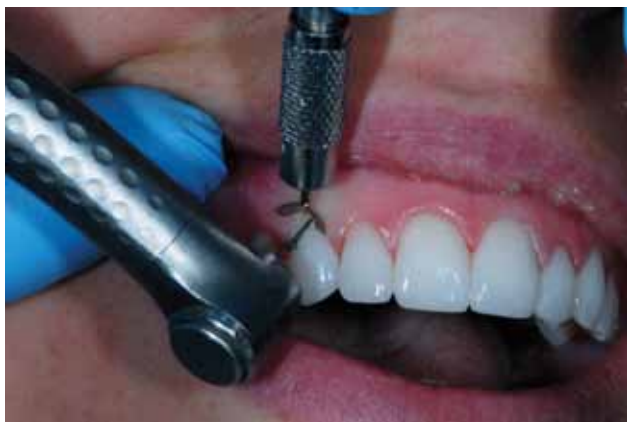

Figure 4: Zekrya retraction instrument (DMG America; Englewood, NJ) used to protect tissue while finishing.

Myths vs. Realities

Myth

Without preparation of the teeth, the porcelain margins will be inappropriate, causing unhealthy tissue, poor emergence profile, and detectable margins.

Reality

Prep-less veneers, when managed properly, can have biologically sound and optically beautiful margins and emergence profiles (Figs 1 & 2).²

In fact, of all the potential issues with prep-less veneers, the marginal area and emergence profile have become the least of this author's concerns. This is because with proper fabrication and post-cementation finishing, one can create an "infinity margin." Not only is this margin biologically sound, but it also is difficult to visibly detect as the ceramic feathers to the tooth surface (Fig 3). To achieve an outstanding result, dentists must be comfortable finishing porcelain in the mouth; this causes concern for many. However, materials and techniques have evolved to an extent that this can be readily accomplished. The fact that most ceramists currently hand finish the restorations with rubber wheels and brushes as opposed to oven glazing affords dentists the opportunity to accomplish similar results in the mouth provided certain precautions are taken. For example, careful attention must be paid to keep constant air on the teeth to avoid overheating, while liquid dam and special retraction instruments are utilized to prevent trauma to the tissue (Figs 4 & 5).

The ability to recontour and refinish porcelain after cementation opens up a whole new range of possibilities, as the minimum fabrication thickness of .3 mm can now be reduced even more—perhaps to as thin as .2 or even .1 mm. At this thickness, it is difficult to visually detect the increase in volume and the interproximal contours can be reduced to a pleasing level. Some would argue that just to minimally reduce the enamel makes much more sense and makes the outcome easier and more predictable, and in select cases this author would agree. However, there are some potential factors that may need to be addressed:

- The patient may refuse any drilling of their teeth.
- The average thickness of enamel at the cervical area of anterior teeth is .3 mm, and thus any enamel removal can significantly darken the tooth by removing the enamel "filter."³

It is very difficult for thin porcelain to adequately mask the influence of the darker dentin once some of the enamel filter has been removed; on the other hand, it is shocking how much a .1 to .2 mm of "extra" filter (porcelain) can brighten a tooth when no preparation is done. Minimal preparation will generally ease the burden of establishing ideal contours, but it can significantly increase the shine-through issues and make the margins more detectable.

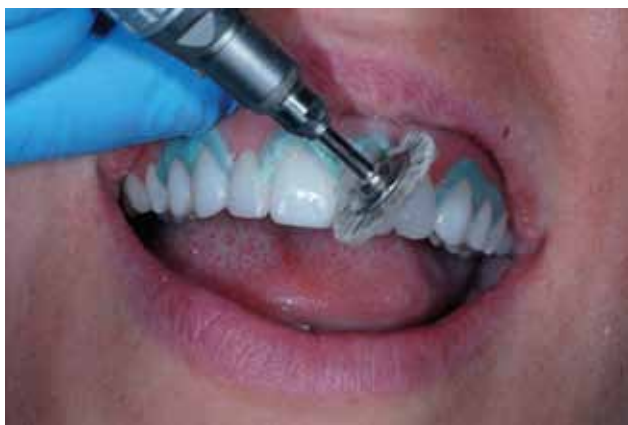

Figure 5: Liquid dam used to protect tissue during final polishing.

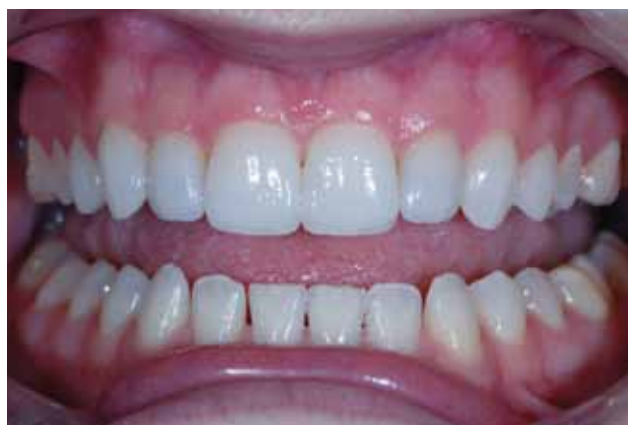

Figure 6: Five-year recall of prep-less veneers, ##5-12, demonstrating excellent durability and stability.

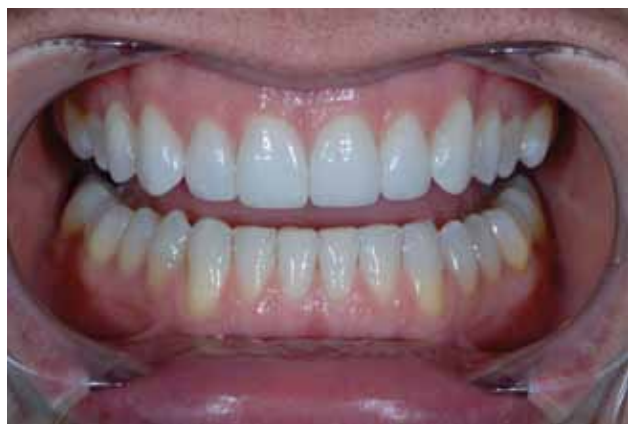

Figure 7: Prep-less (DURAthin) veneers, ##5-12. Note inherent warmth of color in the gingival one-third.

Myth

Thin, prep-less veneers break easily and are not as durable as prepared veneers.

Reality

Thin, prep-less porcelain veneers are very strong and durable once bonded to 100% enamel; they have as good as or better long-term results than prepared veneers.

Porcelain bonded to 100% enamel produces a strong, durable interface that has been well documented for more than 25 years.⁴ Although porcelain does tend to be stronger as it increases in thickness, overwhelming success has been achieved with .3-mm (or less) thick ceramic veneers. Prior to bonding to enamel, thin veneers are indeed more vulnerable to fracture and thus extra precautions should be taken, but once bonded in place with current total-etch techniques the strength is profound (Fig 6).

Another distinct advantage of the prep-less approach in regard to durability and wear is that the "additive only" veneer is outside the existing envelope of function.⁵ This fact generally minimizes the stresses placed on the veneer and improves the success rate of the porcelain. The 100% enamel bond, coupled with absolutely no encroachment of the envelope of function, provides the basis for prep-less veneers to be very stable and long term even when they are very thin.

Myth

Prep-less veneers lack color and translucency.

Reality

Prep-less veneers can offer beautiful, lifelike color and translucency, simply by serving as an extension of the enamel filter.

Utilizing feldspathic powders, an unlimited amount of opacity and translucency can be introduced into each restoration based upon the desired outcome.⁶ It is an entirely different strategy to build a thin "enamel extension" as opposed to recreating a "missing" part of the tooth that has been over-prepared. With prep-less veneers, the warmth of the gingival one-third will automatically be created as the veneer thins and becomes highly translucent. In most cases it is not necessary to add darker color in this zone as is often done with prepared veneers (Fig 7).

The mid-body area of the veneer at .3 mm of thickness or more can dramatically shift the color of the tooth, provided none of the original enamel has been removed. Contrary to popular belief, the opacity can be increased a significant amount without making the tooth look "dead," provided the veneer is relatively thin, and the end result can be a major color shift with very thin porcelain coverage. The key to a great color result is no preparation of the enamel, as even a slight reduction can create darkness that is difficult to overcome without excessive opacity or thickness of the porcelain.

The incisal edge can be managed in a variety of ways to create natural optics. If the teeth are lengthened (as is usually the

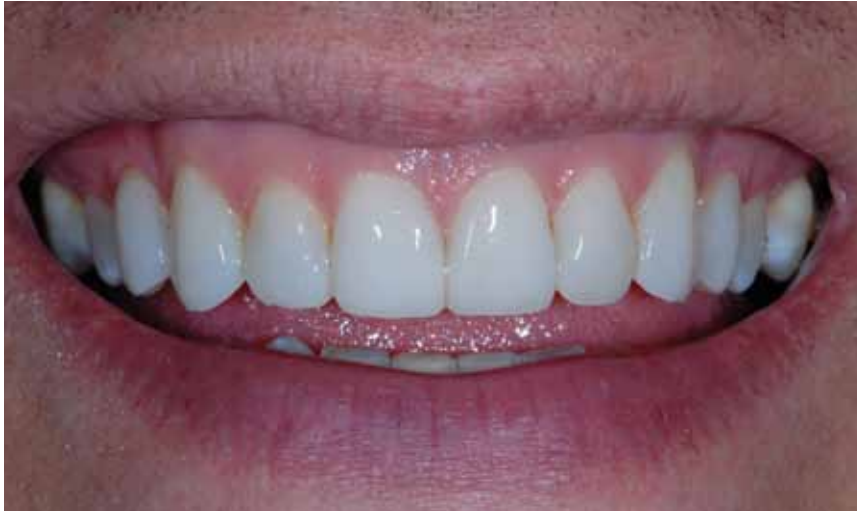

Figure 8: Composite prototypes, ##5-12.

case with prep-less veneers), then the porcelain extension will often have more light transmission and thus create a subtle incisal translucency with no additional effort. On the other hand, effects can be layered in using incisal powders as with traditional prepared veneers, with similar results. If the teeth are not lengthened, it is often possible to either decrease the thickness or decrease the opacity in the incisal zone and allow the tooth's natural incisal effects to shine through. It may be counter-intuitive, but it is definitely possible to achieve beautiful, polychromatic color with thin, prep-less veneers.

Myth

Prep-less veneers are easier and faster than conventional veneers; therefore, the fees should be lower.

Reality

High-quality prep-less veneers are often more difficult to achieve than conventional veneers—it is not an easier, less expensive procedure when done well.

Emulating nature and creating Accreditation-worthy cases are not easy tasks with any approach, but they can be especially difficult to accomplish with prep-less veneers. Additive-only restorations require an in-depth understanding of facial contours by both the dentist and the ceramist so that the in-

tentional increase in tooth volume does not appear bulky and inappropriate. To this end we create custom composite prototypes for each case that are hand-sculpted and spot-etched. These prototypes allow both the patient and the dentist to visualize the end results while at the same time confirming the feasibility of an additive-only approach (Fig 8). This is not an easy technique and it does take a considerable amount of time. More time is also required when compared to prepared veneers in seating the case due to the inherent need to finish the margins and refine contours.

No-prep dentistry is not an easier, quicker, or cheaper service, but rather a minimally invasive approach to smile design that has a premium value to many patients.⁷

Conclusion

By definition, prep-less veneers are an additive-only procedure and thus the final outcome will reflect a net gain in volume and size of the teeth. This is not necessarily a negative, as in fact some teeth need an increase in volume and size. Examples of this include:

- microdontia
- loss of enamel due to wear, abrasion, and erosion
- an excessively large frame (lips) that creates an imbalance between the frame and the teeth.

When an increase in volume is desired or can be tolerated, prep-less veneers are an incredible service to offer to patients, with multiple benefits and minimal risks. Much like medicine, dentistry is steadily moving toward less invasive procedures and this trend is not likely to change.

References

1. Wells D. Prepless veneers: ridiculous or reality? a clinical case review. *J Excellence*. 2009;1(3):29-37.
2. Radz GM. Enhancing the esthetics through addition: no-prep porcelain veneers. *Oral Health*. 2009 Apr;99(4):23-30.
3. Crispin, BJ. Esthetic moieties: enamel thickness. *J Esthet Dent*. 1993;5:37.
4. Calamia JR, Calamia CS. Porcelain laminate veneers: reasons for 25 years of success. *Dent Clin N Am* 2007 Apr;51(2):399-417.
5. Kois, JC. Functional occlusion I: science driven management [course]. Seattle (WA): Kois Center; 2008.
6. McLaren EA, LeSage B. Feldspathic veneers: what are their indications? *Compend Contin Educ Dent*. 2011 Apr;32(3):44-9.
7. Wells DJ. Don't we all do cosmetic dentistry? *Dent Econ*. 2007 Apr;97(4):106-9. **JCD**



Dr. Lesage, a Fellow of the AACD, is the course director at UCLA Aesthetic Continuum and the owner of Beverly Hills Institute of Dental Esthetics in Beverly Hills, California.

Disclosure: The author did not report any disclosures.

Dr. Wells is an Accredited Member of the AACD. He practices in Brentwood, Tennessee.

Disclosure: Dr. Wells is the co-developer of DURAthIn Veneers.



I'm sensitive
...I can't chew on one side.

We can fix that.

Adper™ Easy Bond Self-Etch Adhesive applies easily and virtually eliminates post-operative sensitivity† – guaranteed*. Formulated to create strong, lasting bonds between enamel and dentin, it's backed by over 100 years of adhesive science.

See for yourself!

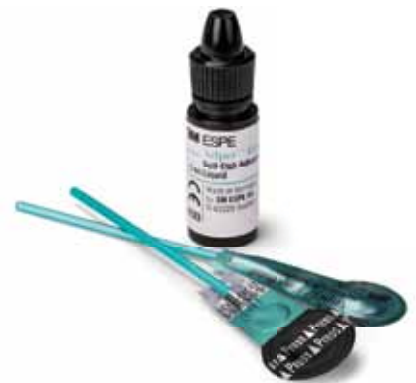Go to www.3MESPE.com/Adper or call 1-800-634-2249.

* Visit www.3MESPE.com/Adper for details about our Guarantee.



Scan this tag with your mobile phone
For details on our guarantee and special offers.

Get the free tag-scanner app at: <http://gettag.mobi>



Adper™
Easy Bond
Self-Etch Adhesive

3M ESPE

20 TIPS for Resin



HOW

Veneer Cements

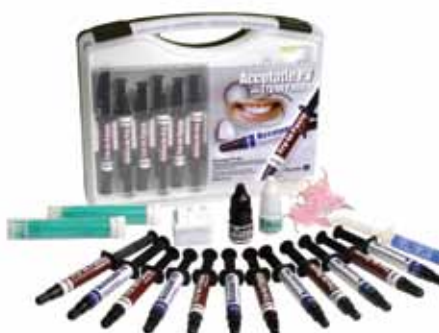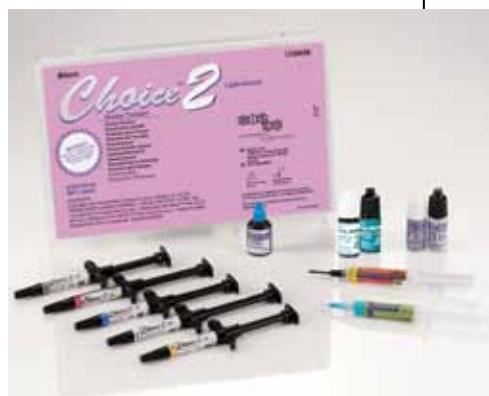How to Choose a Cement for Porcelain Laminate Veneers

Carlos A. Munoz-Viveros, DDS, MSD

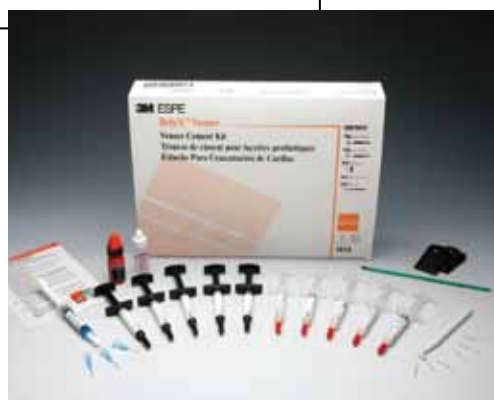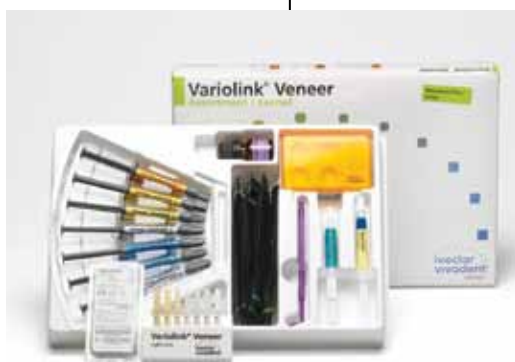INTRODUCTION

The advent of etching enamel has given rise to the use of porcelain veneers as a relatively conservative means of improving the appearance of teeth. Since its introduction in the early 1980s, a number of techniques and product advances have been developed to assist clinicians in the restoration of the anterior dentition. Because most of these restorations not only lack the necessary retention or resistance of conventional restorations but they also typically are very thin (.3 to .7 mm), the selection of the cement is critical to success.

The higher the translucency of the resin cement, the more natural the appearance.



1-5



CEMENT SELECTION >>1-5

1

It is preferable to use only light-activated resin cements. Light-only polymerized cements allow for longer working time, do not need to be mixed, have shorter finishing time, increased color stability, and longer shelf life.

2

Dual-cured resin cements contain amine co-initiators, whose byproducts in the catalyst may, over time, cause a "yellowing effect" to the veneer.

3

The higher the translucency of the resin cement, the more natural the appearance, whereas opaque cement will mask the tooth and make it more monochromatic. Opaque cements are more commonly used to block the darkness of severely discolored teeth.^{1,2}

4

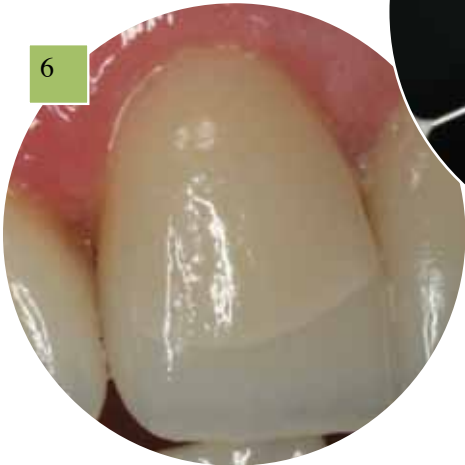
It is not recommended to refrigerate resin veneer cements; however, if they have been refrigerated, make sure that the cement is at room temperature or warmer, as cold temperatures might affect its pseudoplastic behavior, especially the opaque shades.³

5

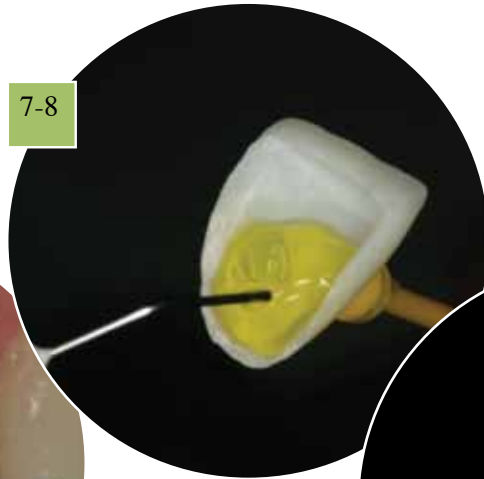
Light-only polymerized resin cements can be used with virtually any etch-and-rinse adhesive, provided that the manufacturer's directions for both the cement and the adhesive are followed.

VENEER PREPARATION >>6-12

6	7	8	9	10	11	12
<p>The greater the amount of cement spacer (greater than 100 micrometers), the greater the increase in internal stresses and the probability of veneer fracture.^{4,5}</p>	<p>Acid-etching with hydrofluoric acid is possible only with silica-based ceramics. Alumina and zirconia do not fall within this classification.</p>	<p>Make sure that the porcelain veneer is etched with hydrofluoric acid for the manufacturer's recommended etching time. Do not over-etch the veneer as this may cause any preexisting micro-cracks to increase, decreasing the flexural strength of the veneer.⁶</p>	<p>The bond between the resin cement and the etched enamel is mechanical in nature. The bond between the etched ceramic veneer and the resin cement is mechanical/chemical in nature and requires special preparation.</p>	<p>The placement of a silane coupling agent is key to provide a strong chemical bond between the cement and the veneer. Care should be taken to follow the manufacturer's recommended application time.⁶</p>	<p>The less water present in the laminate veneer, the better the silane coupling agent will work. If possible, immerse the veneers in acetone for five minutes prior to placing the ceramic primer. Also make sure the silane is fresh as the shelf life is usually short.</p>	<p>If a veneer debonds, it is important to evaluate the interface of the veneer. If the resin composite remains on the veneer, there is most likely a problem with the placement technique or the bonding substrate.</p>



6



7-8



10



12

TOOTH PREPARATION >>13-15

13

Clean the tooth with an oil-free, fluoride-free pumice paste. This will ensure removal of the pellicle and any other contaminants.

14

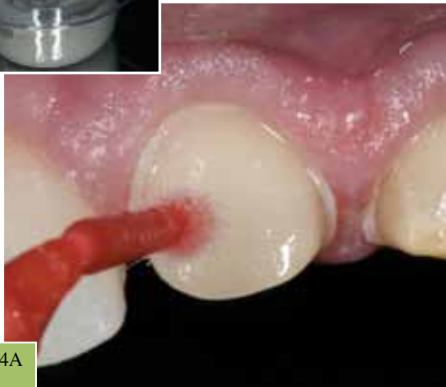Veneers bonded to a higher amount of dentin substrate (A) have a significantly higher likelihood of debonding than veneers bonded to enamel (B). Try to keep as much enamel present as possible.

15

It is preferable to mask the discolored tooth with a layer of dentin modifier than to mask the color with an opaque cement. Conversely, the chroma of the preparation can be modified by adding small amounts of stains to the veneer.



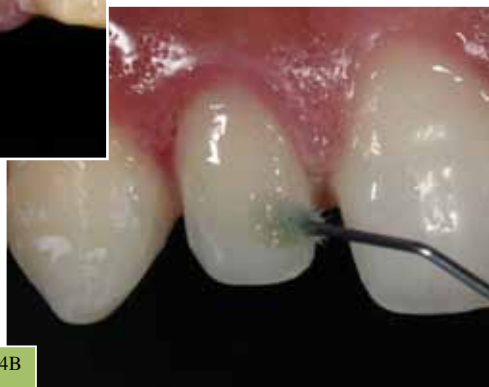13



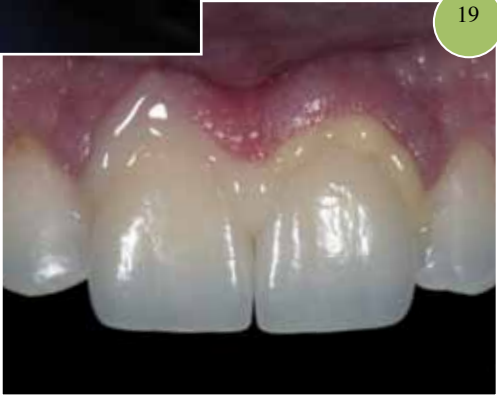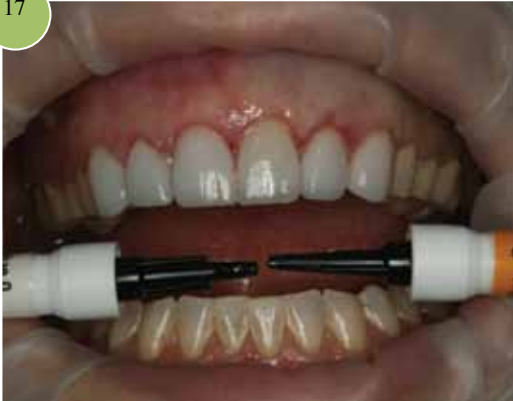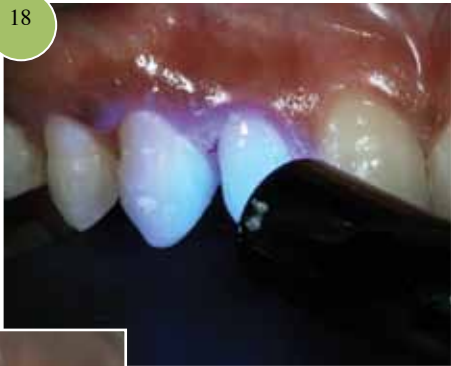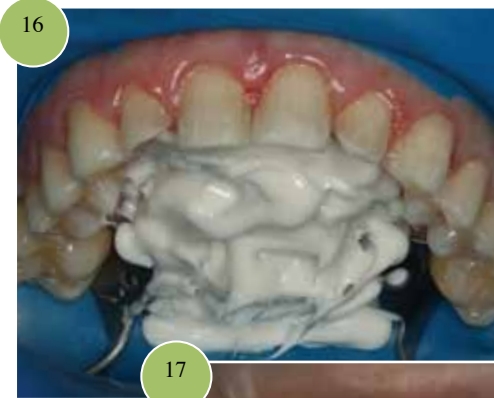14A



15



14B



PLACEMENT TECHNIQUE >>16-20

16	17	18	19	20
<p>Complete isolation is recommended to avoid contamination of the cement and adhesive with saliva or blood during bonding.</p>	<p>When using try-in pastes, be aware that differences have been found between try-in pastes and the cured resin of the same shade. Make sure that the try-in paste is completely water-soluble and not an actual resin cement with no initiators, as the cleanup of the preparation might be difficult.^{7,8}</p>	<p>If the laminate veneer is thicker than .8 mm, it is recommended that the polymerization time be doubled, as a thicker veneer might not allow the cement to reach its maximum hardness.⁹</p>	<p>Some clinicians prefer to use a highly filled flowable resin or a conventional resin composite to cement the veneer. However, proper steps must be taken to prevent veneer fracture, such as warming the composite in hot water or some type of electric warmer to improve the flow characteristics of the resin. This method allows for a much more controlled seating and cleanup is simplified.³</p>	<p>By following the preceding tips, clinicians can provide patients with one of the best-fitting, longest-lasting, esthetic ceramic restorations available.</p>

Acknowledgment

The author thanks Dr. Edward Lowe for providing most of the images in this article.

References

1. Ghavam M, Amani-Tehran M, Saffarpour M. Effect of accelerated aging on the color and opacity of resin cements. *Oper Dent*. 2010 Nov-Dec;35(6):605-9.
2. Omar H, Atta O, El-Mowafy O, Khan SA. Effect of CAD-CAM porcelain veneers thickness on their cemented color. *J Dent*. 2010;38 Suppl 2:e95-9.
3. Chadwick RG, McCabe JE, Carrick TE. Rheological properties of veneer trial pastes relevant to clinical success. *Br Dent J*. 2008 Mar 22;204(6):E11.
4. Cho SH, Chang WG, Lim BS, Lee YK. Effect of die spacer thickness on shear bond strength of porcelain laminate veneers. *J Prosthet Dent*. 2006 Mar;95(3):201-8.
5. Magne P, Douglas WH. Design optimization in evolution of bonded ceramics for the anterior dentition: a finite element analysis. *Quintessence Int*. 1999;30:661-72.
6. Alex G. Preparing porcelain surfaces for optimal bonding. *Compend Contin Educ Dent*. 2008 Jul-Aug;29(6):324-35.
7. ALGhazali N, Laukner J, Burnside G, Jarad FD, Smith PW, Preston AJ. An investigation into the effect of try-in pastes, uncured and cured resin cements on the overall color of ceramic veneer restorations: an in vitro study. *J Dent*. 2010;38 Suppl 2:e78-86.
8. Ulrich W. Cementing porcelain laminate veneers. *Dent Econ*. 2005 Mar;95(3):72-8.
9. Usumez A, Ozturk AN, Usumez S, Ozturk B. The efficiency of different light sources to polymerize resin cement beneath porcelain laminate veneers. *J Oral Rehabil*. 2004 Feb;31(2):160-5. **jCD**

Editor's Note: Any product images shown in this article do not imply endorsement by jCD or the AACD.

Suggested Reading

Hamlett K. The art of veneer cementation. *Alpha Omegan*. 2009 Dec;102(4):128-32.



Dr. Munoz-Viveros is a professor in the Department of Restorative Dentistry at the State University of New York at Buffalo.

Disclosure: The author receives a grant from Ivoclar Vivadent unrelated to the content of this article.

tough. thin. beautiful.

who says you can't have it all?

DURATHIN[®]
VENEERS



Tandi Schaeffer
Undeclared Professional MMA Fighter
Durathin Veneers Patient



experience dental studio

www.experiencedentalstudio.com

801.796.3878



Visualizing

The background of the page is a collage of images in a light blue and white color palette. The most prominent feature is a nautilus shell in the lower right quadrant, showing its characteristic logarithmic spiral. Above it, there's a close-up of a microscope lens or a similar optical component. To the right, a portion of a microscope slide with a grid pattern is visible. The overall composition is abstract and scientific, suggesting themes of visualization, biology, and technology.

Treatment Outcomes

Producing Optimal Esthetics through Proper Case Selection and Predictable Techniques

Bradley L. Jones, FAACD
Tim J. Huff, DDS

Introduction

In the field of conservative cosmetic dentistry, working backward is often the best way to achieve the most predictable results.¹ Many practitioners and laboratory technicians have found that by first visualizing the definitive result before initiating clinical and laboratory procedures, optimal esthetics and functional outcomes can be consistently produced.¹

Two major components of the restorative process require consideration when visualizing (or otherwise predicting) treatment outcomes.^{2,3} The first, case selection, involves recognizing which cases will embrace or facilitate specific treatment criteria.^{2,3} The other component incorporates application of techniques that will produce the most beautiful and predictable esthetics in support of the selected treatment plan.^{2,3}

According to Merriam-Webster, "To predict is to declare or indicate in advance on the basis of observation, experience, or scientific reason."⁴ Due to many uncontrollable variables, predictability in dentistry often is very difficult to achieve.¹ These variables include—but are not limited to—the patient's ability to maintain an open mouth or remain motionless, and the amount of limiting anatomical structures.² Dentists would love nothing more than to have guaranteed predictable results every time they pick up the handpiece, but this simply is not possible. However, by using observation, experience, and scientific reason, conservative and esthetic restorations can still be fabricated more predictably.^{1,3}

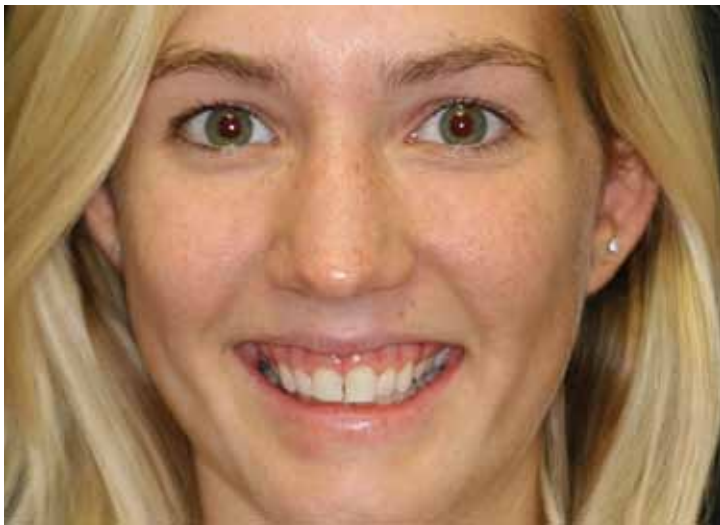

Figure 1: Preoperative portrait.

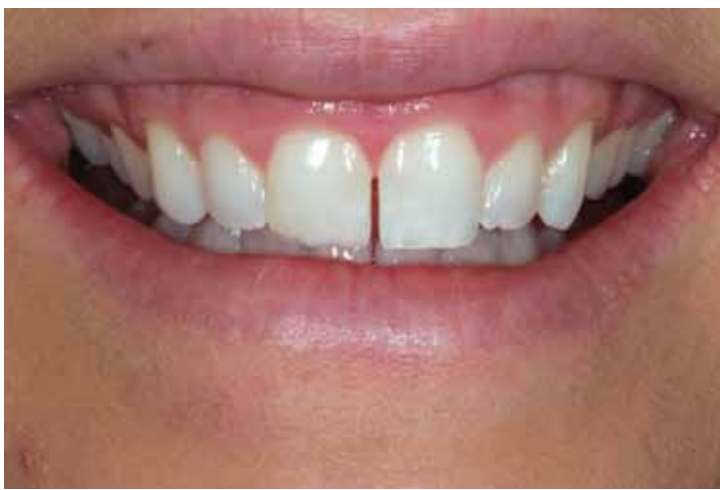

Figure 2: Preoperative smile.

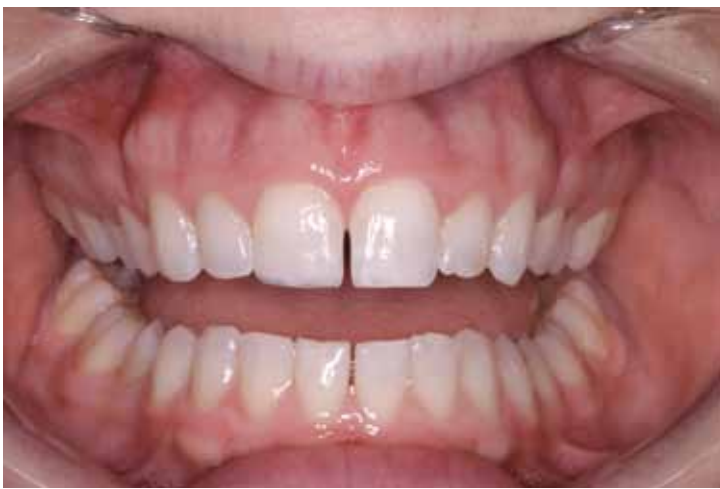

Figure 3: Preoperative retracted view of the dentition.

Observation

The first factor involved in prediction, observation, should involve the dentist, laboratory technician, and foremost, the patient.^{1,5} The most important observations are those of the patient, particularly in terms of the perceived problem areas,⁶ as well as their expectations and desired outcomes. The dentist and laboratory technician must then observe and communicate to each other how best to deliver the patient's anticipated results.⁶ Such observations should include pre-preparation aspects of the dentition to provide ideal esthetics,² the number of teeth to be involved in the process, what type of preparation design is needed, functional considerations, and what type of materials will be required.²

Experience

Another factor influencing predictability is the experience level of the dentist and laboratory technician.⁵ However, patients also must be educated so that they understand the techniques and skill levels required to deliver predictable results.⁵ Experience can only be gained with time, so it may be advisable for a less experienced dentist to find an experienced technician to assist with case selection to maximize the predictability of the restorative outcomes.⁵

Scientific Reason

Available scientific literature suggests that several parameters affect the outcomes of esthetic dentistry.⁵ Therefore, the scientific method can be applied to material selection, preparation design, and known biological limitations.⁷

There are many materials available for use in fabricating veneers, including porcelains and resins, all of which can produce excellent esthetics.⁷ There also are many types of materials and equipment used during the veneer treatment process, including temporary materials, burs, and bonding agents.⁷ Although only a few such specific materials are discussed in this article, others can be used to produce equivalent results.⁷

All materials have limitations that make them suitable for some indications and not for others. For example, IPS e.max porcelain (Ivoclar Vivadent; Amherst, NY) can be used in thin veneer cases based on its inherent strength.

Once a suitable material for the veneer case has been selected, scientific reasoning will then determine the material's influence on preparation design.⁷ Some materials require more aggressive preparation to satisfy both esthetic demands and physical strength

By carefully selecting the case and employing the technique described, the authors were able to achieve predictable esthetics and function without preparing much tooth structure.

requirements.⁷ Some materials can even be made so thin that no preparation is needed.⁷

Subsequently, biological limitations can be considered, such as the fact that the bond strength of materials to enamel is exponentially stronger than it is to dentin.⁸ Additionally, a patient is less likely to experience sensitivity if tooth structure can be conserved due to the fact that enamel is not directly linked to pulpal tissue.⁸

This article discusses the clinical and laboratory tools involved with observation during the treatment-planning process to ensure predictability when delivering conservative and esthetic restorative treatments. The specific case and material selection parameters that lead to success are also outlined, as are step-by-step protocols for both dentist and laboratory technician. The importance of communication between patient, dentist, and technician, as well as the use of shade-matching guides, diagnostic wax-ups, and photographs of the patient's problem areas and facial structure to ultimately develop predictable and exceptional esthetic restorations,⁹⁻¹¹ are emphasized in the following case example.

Case Presentation

Findings

A 23-year-old female presented one year ago with a fracture to the incisal of #8 that was a result of a traumatic incident. At that time, she expressed a desire for a more esthetically pleasing smile. Treatment options were discussed; these included veneers, orthodontics, and a simple resin restoration for #8. She decided at that time to undergo only an incisal composite filling on #8, even though she was advised that it would be very difficult to maintain the longevity of that restoration. Following

two restoration failures, the patient was determined to do whatever was necessary to achieve her desired esthetic goal.

Preoperative photographs revealed a collapsed buccal corridor, generalized spacing, and more specifically a diastema between #8 and #9 (Figs 1-3). Also noted was a moderate-size discrepancy between the central and lateral incisors, with dental decay in the posterior region. Although consideration was given to the patient's excessive gingival display, she was not concerned about it.

The patient wanted her dental treatment to achieve a bigger, whiter smile without gaps. Based on an understanding of predictability and technique, this case was ideal for multiple reasons for inclusion of 10 teeth in the makeover to provide the patient with the best esthetic outcome. Spatial issues were already present, there was a lack of buccal prominence, and the size of the central incisors was inadequate. Therefore, conservative additive esthetic dentistry could be employed. Although the case could have been accomplished using a no-preparation technique, some esthetic limitations would have resulted, as well as an inability to address the decay in the premolar region.

Thoughtful case selection is required when considering the use of no-preparation restorations. It is the authors' belief that no-preparation techniques are well-suited for cases involving generalized spacing, teeth that are too small for the patient's face, and lingually inclined incisors, where their use will not result in esthetic limitations. In this particular case, a minimal tooth preparation technique would be used, with all teeth prepared to some degree. However, most anterior tooth preparations involved

only enamel. By carefully selecting the case and employing the technique described, the authors were able to achieve predictable esthetics and function without preparing much tooth structure.

Laboratory Communication

Because the authors are in the same city, they were able to discuss all case details in the clinic, which facilitated direct involvement of the patient. The communication process began as early as the wax-up phase. During the esthetic consultation, the patient and dentist discussed what she liked and did not like about her existing teeth and overall smile. She was fairly happy with the size and shape of her teeth, with the exception of her central incisors, and she was not concerned about the amount of gingival display when smiling. She was very opposed to having periodontal surgery to correct the amount of gingival exposure upon smiling.

Preliminary alginate impressions and photographs were taken. This information was forwarded to the laboratory for use in creating a diagnostic additive-only wax-up, along with detailed instructions about the patient's desires. The laboratory technician delivered the diagnostic wax-up, and a preliminary appointment was scheduled to place provisional restorations directly over the patient's teeth so she could observe the new size and shape and evaluate color. This aspect of case selection and technique contributed to restorative predictability, as the patient basically underwent a "trial run" of her new smile before any irreversible procedures were initiated.

A bleach shade guide was used to determine the patient's existing shade and during discussions with her to determine her desired color. The

provisional material shade, BL2, was selected based on her input.

The patient was very happy with her provisional restorations and reported keeping them on for two days to show her friends and family and ask for feedback. Several minor adjustments were made to satisfy her requests, including shortening #8 and #9, after which treatment proceeded to the preparation appointment.

Clinical Preparation

The teeth were prepared using a reduction guide created with provisional material (PERFECTemp, Discus Dental; Culver City, CA) placed into a matrix and subsequently bonded using a single-component adhesive (Optibond Solo, Kerr; Orange, CA). The matrix was fabricated from an additive-only wax-up and placed intraorally (Fig 4). To facilitate retention while preparing the teeth, it was necessary to bond the provisional material prior to preparation. In some instances, spot-etching may be incorporated, but in this particular case it was not needed. Once the matrix was removed, the temporary reduction guide was light-cured.

Depth-cutting burs (Brasseler USA; Savannah, GA) were used to make 0.7-mm depth cuts to the middle and incisal two-thirds, and 0.5-mm depth cuts on the apical, or gingival, one-third (Fig 5). The provisional material remained in place and intact during preparation as a result of proper curing. Had the temporary material failed, a new diamond bur would have been used to ensure that it was cutting, not scratching.

Once the preparations were completed and the temporary material removed, it was easy to visualize complete enamel preparations (Fig 6). To deliver optimal results, it was necessary to conserve as much of this enamel as possible. Very minimal dentin was observed in the premolar area due to previous restorations and caries.

A preoperative shade comparison of the patient's natural teeth was taken using the 030 Chromoscop bleach shade tab (Ivoclar Vivadent) (Fig 7). A final impression was made using a light-body polyether impression material (Impregum Penta Soft Quick Step, 3M ESPE; St. Paul, MN), followed by heavy body (Fig 8). Once impressions were taken, provisional restorations were created in shade BL2 (PERFECTemp) and luted into place using a dual-curing provisional luting composite (Systemp.link, Ivoclar Vivadent).

Slight asymmetrical gingival heights presented on #8 and #9, which were still present at the one-week follow-up appointment. The reason for this was a slight overhanging of provisional material on #9, which made the gingival height of the contour too apical. However, the patient was very happy with the provisional restorations.

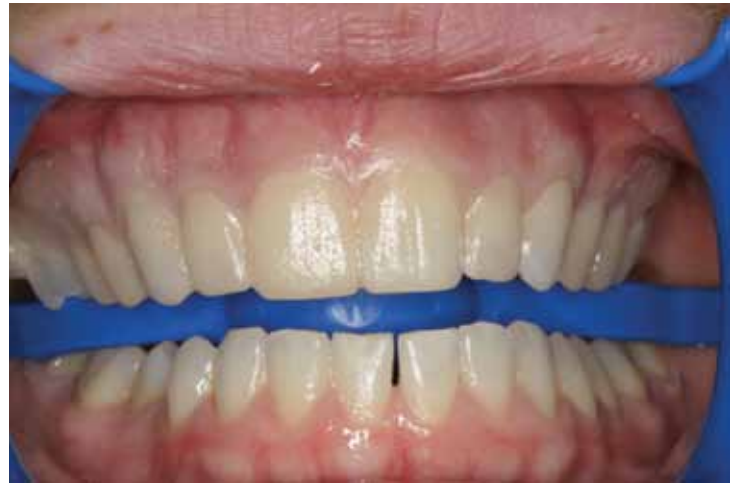

Figure 4: A matrix was created from the additive wax-up and used to form the intraoral mock-up.

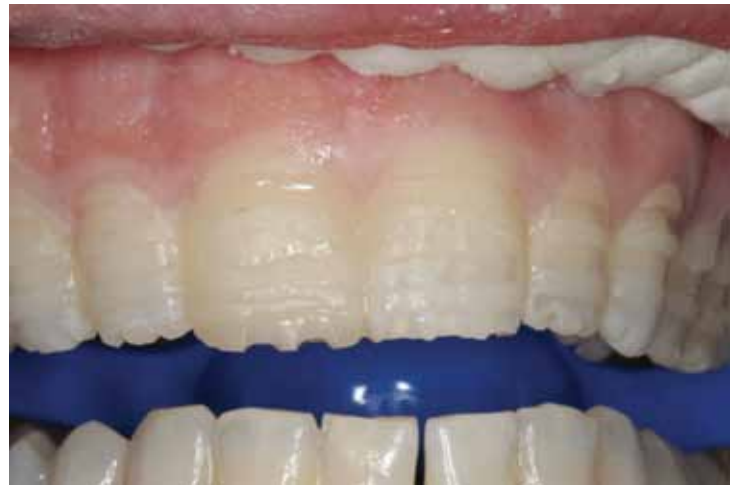

Figure 5: Using a .7-mm depth-cutting bur, the clinician prepared into the mock-up, being sure to preserve as much tooth structure as possible.

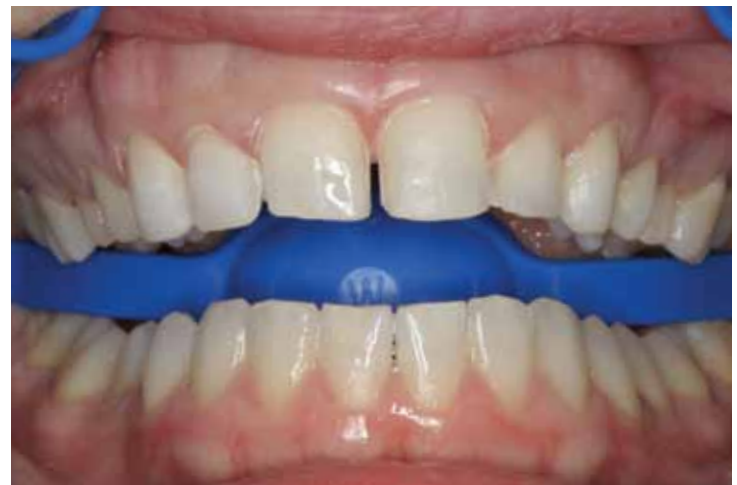

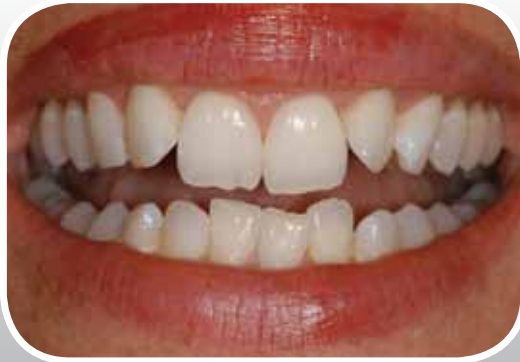Figure 6: View of the minimal and systematic preparations.

*There is a direct correlation between
cosmetic imaging and case acceptance...*

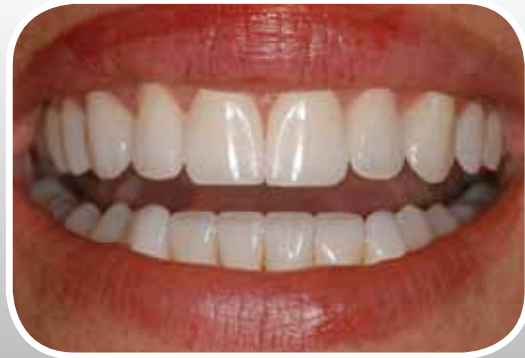

Imaging Service Now Available!

visit www.envisionasmile.com for details!



pre-op



imaging with
Envision a Smile



American Academy
of Cosmetic Dentistry[®]
CORPORATE GOLD MEMBER

Increase Case Acceptance
by purchasing the software OR using our service.

For a free on-line demonstration from your own photograph, visit us at

www.EnvisionASmile.com

or call 877-841-1122

Laboratory Fabrication

After receiving all relevant case information and photographs from the treating dentist, the laboratory technician was ready to fabricate the final restorations. Wax was injected through a matrix made from the provisionals and onto the master dies (Fig 9). The fitted restorations, composed of a lithium disilicate restorative material (IPS e.max Press) in ingot HTBL2, were then pressed at 913 °C (Fig 10). The HTBL2 ingot was used to achieve a Chromascop bleach shade of 030. The patient's preparation shades also were 030.

The restorations were pressed to full contour, after which the facial incisal edge was marked with a red pencil, followed by marking with a 0.3-mm lead pencil (Fig 11). The pencil marks were utilized to accurately indicate a line 0.5 mm lingually for facial reduction. A .5-mm facial reduction was accomplished using a K6974 220 centered diamond disc (Komet USA; Rock Hill, SC) (Fig 12), beveling down approximately one-half of the restoration. A red pencil was used once again to mark the incisal interproximal area to be troughed out with the centered diamond disc (Fig 13). The trough was created to carry the gray-blue stain in order to impart an incisal effect similar to that of the patient's natural dentition.

Universal stains (Ivoclar Vivadent) were applied to emulate the high- and low-value details found in the internal structures of the patient's natural teeth (Fig 14). After building the center lobe with light and salmon mamelon powders (Ivoclar Vivadent), OE4 white dentin powder (Ivoclar Vivadent) was applied to create the mesial and distal internal lobes (Fig 15). The IPS e.max powders were fired under full vacuum to 7500 C at a rate of climb of 60 degrees per minute, with a one-minute high temperature hold.

To finalize the internal effects, light mamelon material was placed on the incisal edge utilizing a fanned build-up brush to create a natural "halo" effect (Fig 16). Once this process was complete, the internal effects were fired (Fig 17).

OE1 (opal clear) and TI1 (high-value enamel) powders (Ivoclar Vivadent) were then carefully segmented to maintain OE1 on the outermost incisal, mesial, and distal edges (Fig 18). The contoured enamels that were carefully placed on the restorations were then fired (Fig 19).

After firing, the shape and contour of the restorations followed the patient's preoperative dentition in order to mimic her unique characteristics. A red pencil was used to copy this information to the surface of the restorations. The facial lobes and surface texture were created using an 842R diamond bur (Komet USA) (Fig 20).

A non-fluorescent glaze paste (IPS e.max) was applied to the finalized surface of the restorations, which

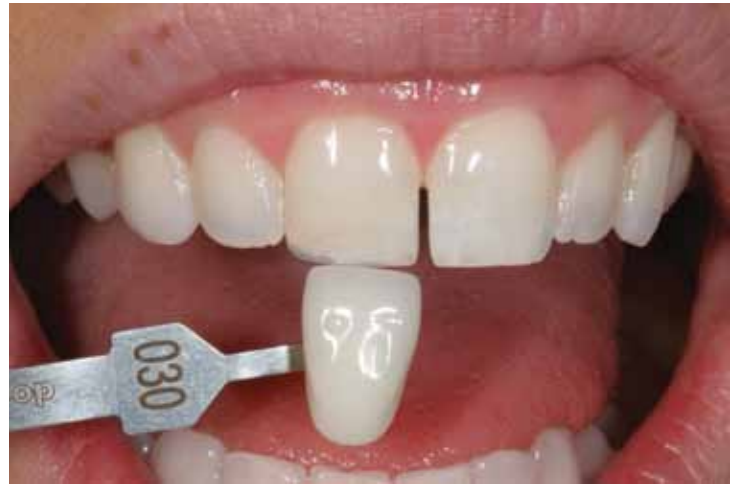

Figure 7: Using the Chromascop bleach 030 shade tab, the practitioner was able to choose and communicate to the laboratory the correct color for the final restorations.

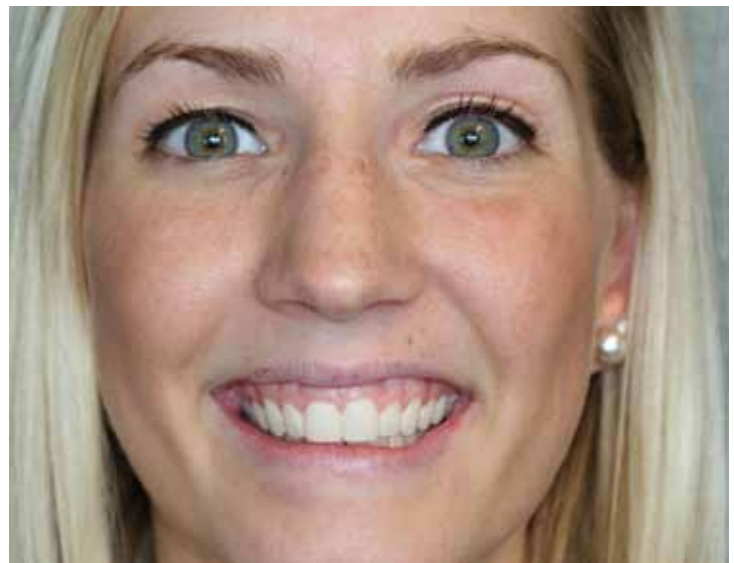

Figure 8: Eyebrow-to-chin image with the provisional restorations in place.

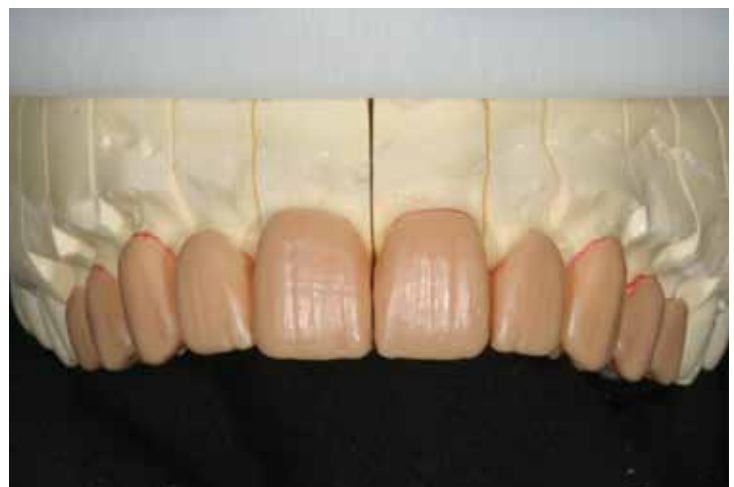

Figure 9: Wax was injected through a matrix made from the approved provisionals and placed onto the master dies.

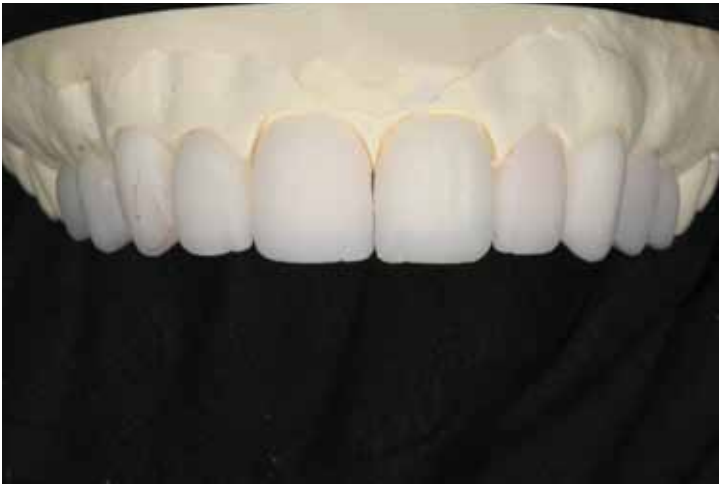

Figure 10: The fitted restorations, which were created using ingot HTBL2.

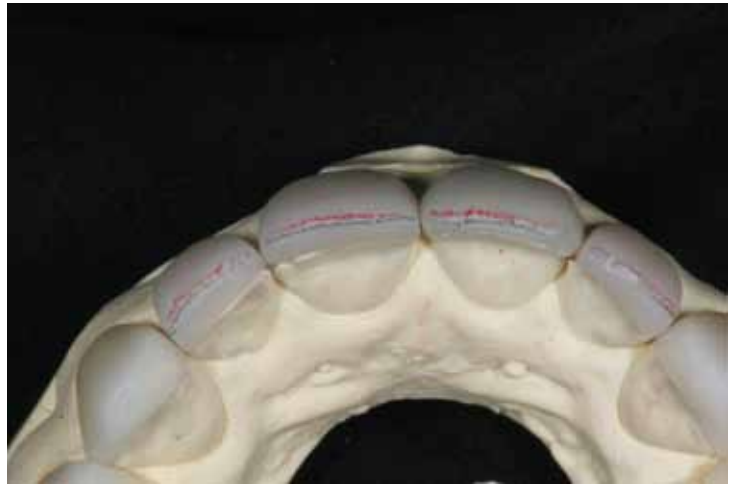

Figure 11: After marking the facial incisal edge with a red pencil, a .3-mm lead pencil accurately indicated a line .5 mm lingually for facial reduction.

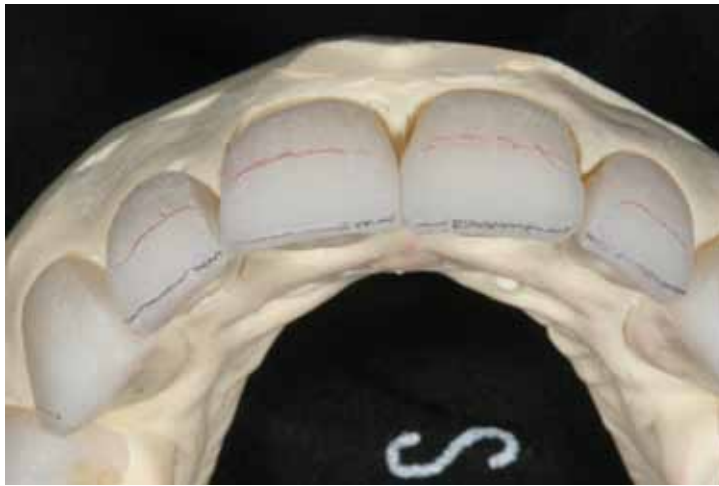


Figure 12: A .5-mm facial reduction was accomplished using a centered diamond disc to bevel down approximately one-half of the restoration.

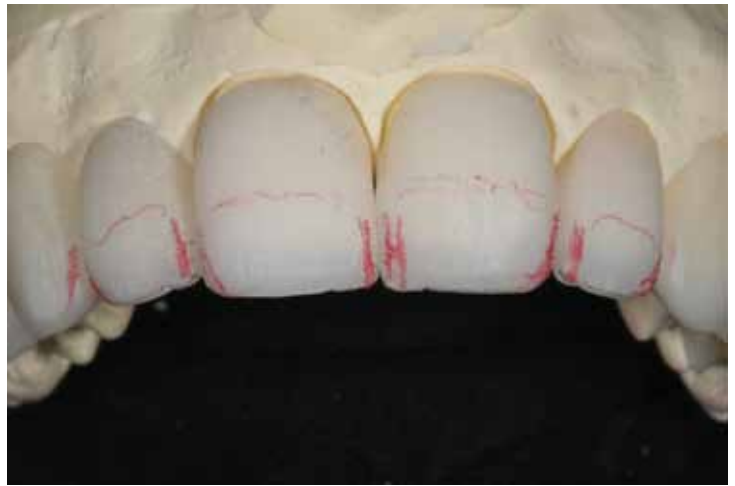

Figure 13: A red pencil was used to mark the incisal interproximal area to be troughed out using the centered diamond disc.

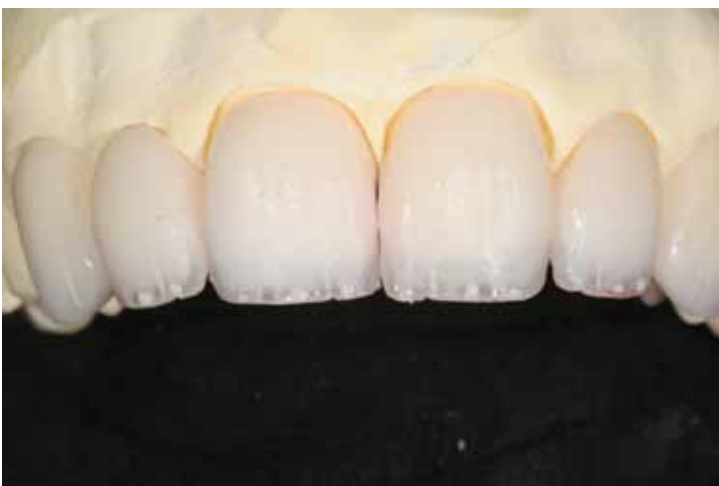

Figure 14: The technician emulated both high- and low-value details that are typically found internally in a natural tooth.

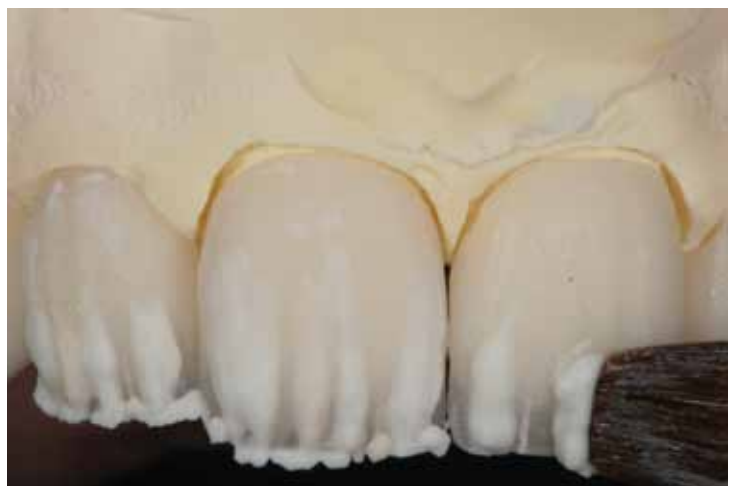

Figure 15: OE4 (white dentin) powder was used to make the mesial and distal internal lobes after the center lobe was built in using light and salmon mamelon powders.

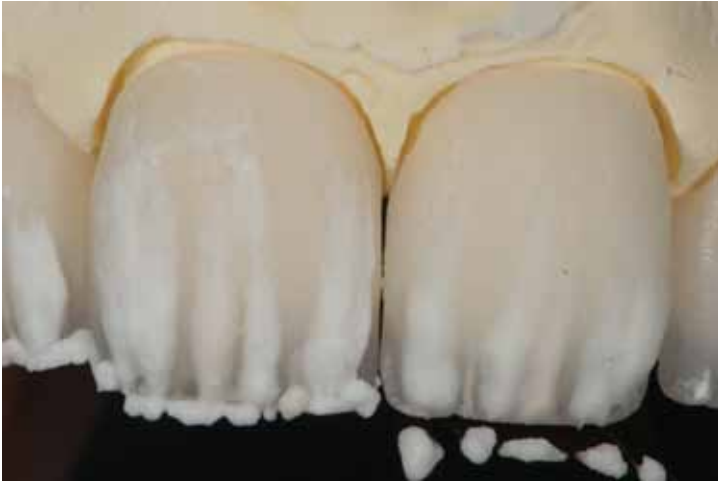

Figure 16: To finalize the internal powder effects, light mamelon material was placed on the incisal edge with a fanned build-up brush, creating a natural "halo" effect.

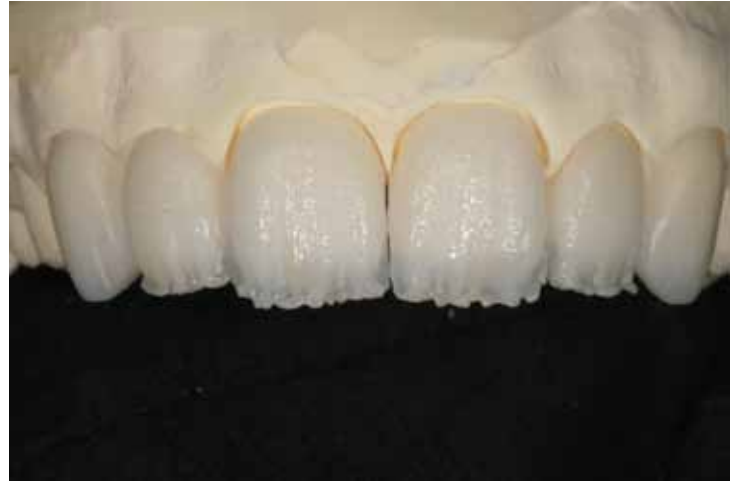

Figure 17: The internal effects after firing.

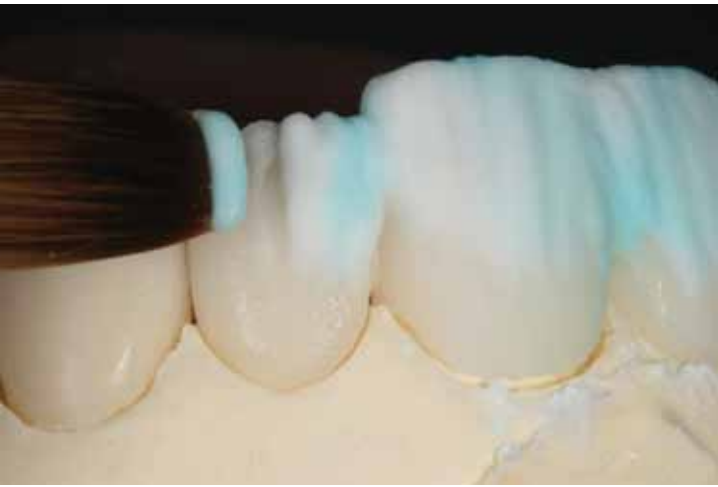


Figure 18: OE1 (opal clear) and T1 (high-value enamel) powders were segmented.

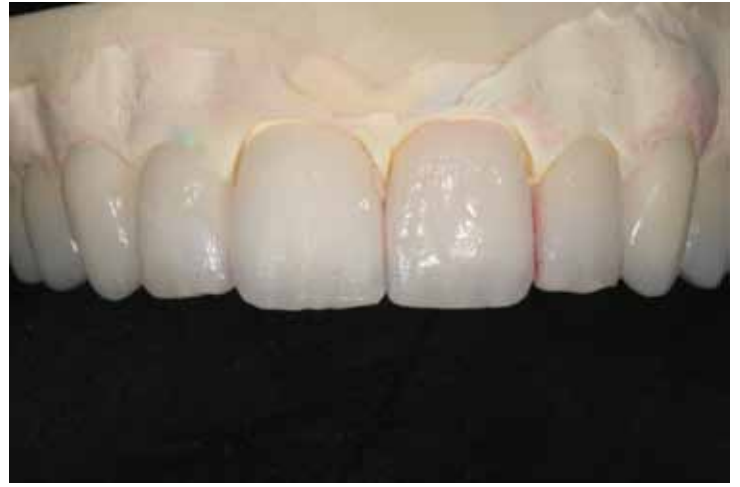

Figure 19: The contoured effects of the enamel after firing.

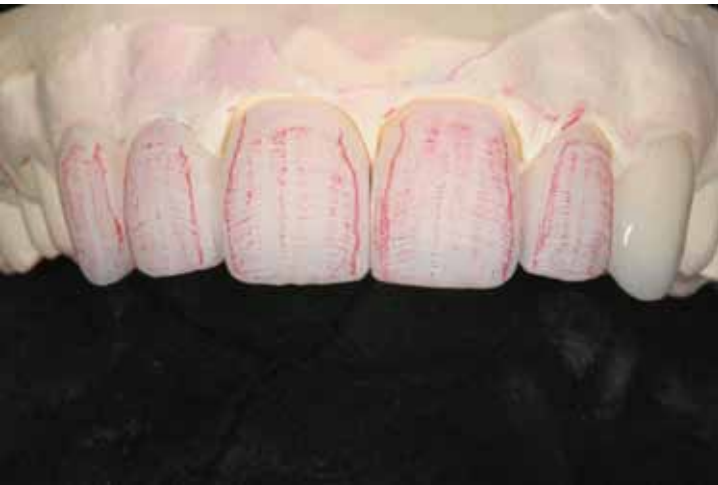

Figure 20: After the enamel was fired, the facial lobes and surface textures were placed on the restorations using a diamond bur.

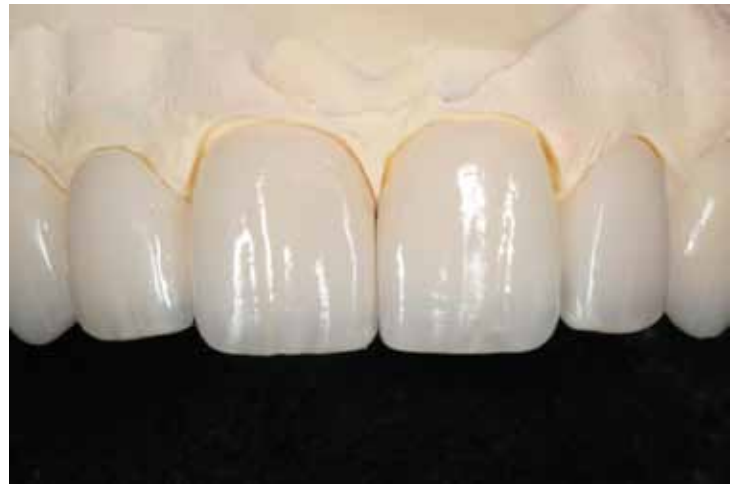

Figure 21: The final glazed and polished surfaces.

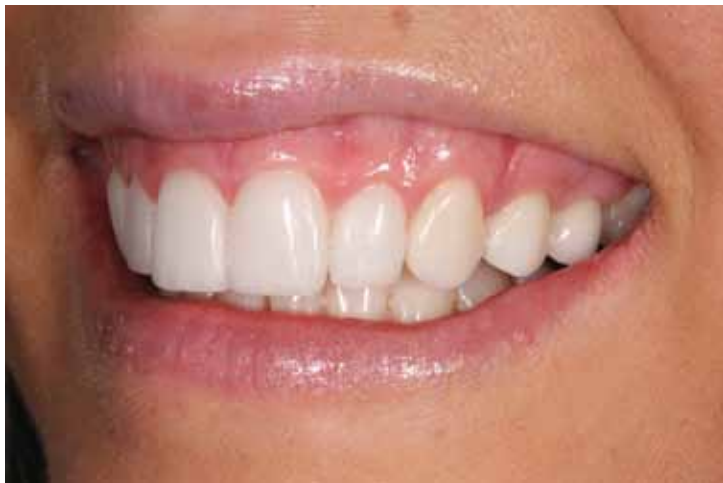

Figure 22: Postoperative; left lateral smile.

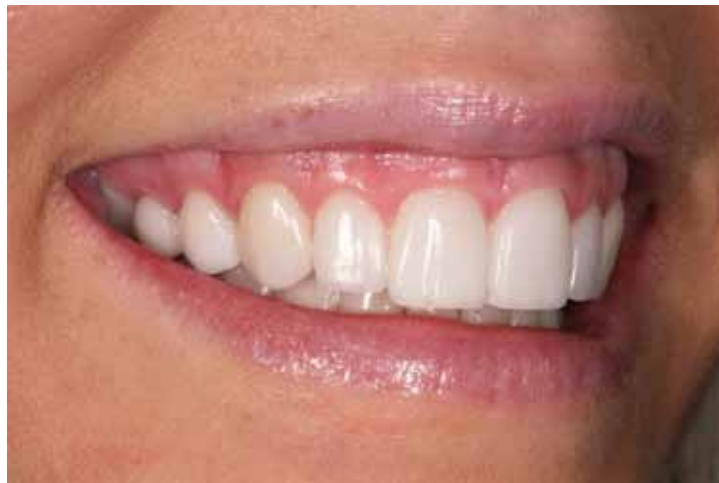

Figure 23: Postoperative; right lateral smile.

then were fired under full vacuum to 7400 C at a rate of climb of 70 degrees per minute, with a one-minute high temperature hold. To lessen the brassy appearance from the artificial glaze, a knife-edge carborandom-filled white rubber wheel was used (Komet 9537M). A diamond polishing knife-edge polisher (Komet 94003F) then was used to produce the final natural glazed appearance, after which the restorations were ready for delivery (Fig 21).

Final Cementation

Once the provisionals were removed and the teeth prepared for cementation, the patient was administered 15 mg of propantheline bromide 30 minutes prior to treatment. Propantheline was used because it stops most salivary flow for several hours, making isolation and cementation easier to achieve. Patients who wear contact lenses should remove them prior to taking the medication, as it will cause excessive drying of the eyes.

The patient was first fitted with a lip and cheek retractor (Opragate, Ivoclar Vivadent). The teeth were etched with a 37% phosphoric acid system (Total Etch, Ivoclar Vivadent) for 10 to 20 seconds. To prevent postoperative sensitivity, a dentin surface conditioner (Systemp. desensitizer) was placed and air-dried. A single-component bonding agent (Optibond Solo Plus) was placed in the veneers, which had been prepared

using a standard etching technique consisting of 5% hydrofluoric acid and a silane agent. The bonding agent was then applied to the preparations, air-dried, and light-cured.

A resin cement (Calibra, Dentsply International; York, PA) in a translucent base shade was used to ensure proper midline symmetry of the restorations for the central incisors, which were seated and bonded. These were tacked with a two-second cure directly on the facial using a 4-mm turbo tip. The restorations for the lateral incisors were then seated, followed by the canines, etc., each with a two-second turbo tack cure. Because all 10 restorations were seated in two minutes, some efficiency and speed was required. After seating, an 11-mm curved curing tip was used for approximately 10 seconds total to wave the buccal and lingual aspects of all restorations.

Excess cement was removed with a sickle scaler and floss. Glycerin gel was placed on all margins and a final cure was completed with an 11-mm tip for 20 seconds on both the buccal and lingual aspects. It was ideal to use two curing lights at the same time, one on the lingual of the tooth and one on the buccal, to ensure even curing and to prevent any shrinking of the cement toward or away from the light. Upon completion of the procedure, a beautiful esthetic outcome was achieved through the use

of predictable methods and materials (Figs 22-25).

Conclusion

When undertaking cosmetic restorative treatments, it is important to consider treatment modality options and available materials. It is also important to maintain proper communication between the dentist and technician, as well as with the patient, to achieve optimal results.

These exceptional outcomes are achieved not only from experience, but also from the ability of the dentist and technician to closely predict the results of each and every case. By considering case selection, method of treatment, and material factors, and by visualizing the anticipated restorations, dentists and laboratory technicians can be very successful in terms of delivering optimal esthetics and fulfilling patients' desires.

References

1. Powell T. Excellence and predictability: not an accident. *Dent Today*. 2009;28(9):122-4.
2. Ohyama H, Nagai S, Tokutomi H, Ferguson M. Recreating an esthetic smile: a multidisciplinary approach. *Int J Periodont Restor Dent*. 2007;27(1):61-9.

3. Koczarski M. Smile makeover utilizing direct composite resin veneers. *Dent Today*. 2008;27(12):76, 78-9.
4. Merriam-Webster English dictionary. 11th ed. Springfield (MA): Merriam-Webster; 2005. Retrieved from <http://www.m-w.com/dictionary/predict>.
5. Kahng LS. Patient-dentist-technician communication within the dental team: using a colored treatment plan wax-up. *J Esthet Restor Dent*. 2006;18(4):185-93; discussion 194-5.
6. Nanchoff-Glatt M. Clinician-patient communication to enhance health outcomes. *J Dent Hyg*. 2009;83(4):179.
7. Terry DA, Geller W, Leinfelder K. Aesthetic & restorative dentistry material selection & technique. Hanover Park (IL): Quintessence; 2009. p. 152-3.
8. Christensen GJ. Bonding to dentin and enamel where does it stand in 2005. *J Am Dent Assoc*. 2005;136(9):1299-302.
9. Snow SR. Strategies for successful esthetic dental treatment. *J Calif Dent Assoc*. 2007;35(7):475-84.
10. Simon H, Magne P. Clinically based diagnostic wax-up for optimal esthetics: the diagnostic mock-up. *J Calif Dent Assoc*. 2008;36(5):355-62.
11. Freedman G. Buyers' guide to shade-matching systems. Welcoming a new era of predictability. *Dent Today*. Jun;22(6):128-30, 132. **jCD**

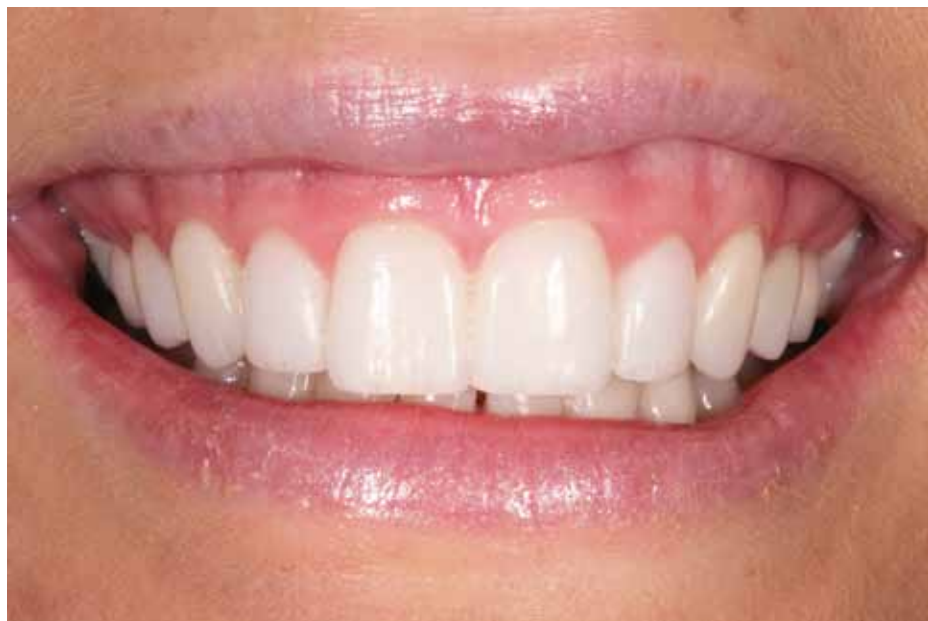

Figure 24: Postoperative smile.



Figure 25: Final postoperative portrait of the patient and her new smile.



Mr. Jones is an AACD Accredited Fellow and operates a boutique laboratory, Smiles, Inc., in Boise, Idaho.



Dr. Huff is a graduate of the University of Minnesota, College of Dentistry, and is the owner of the Center for Contemporary Dentistry in Boise, Idaho.

Disclosure: Mr. Jones gives lectures sponsored by, and receives honoraria from, Ivoclar Vivadent.

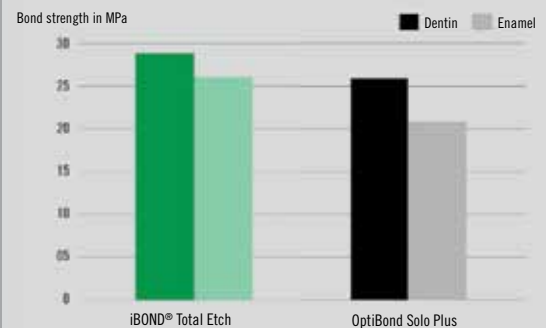
iBOND® Total Etch

Proven to outperform the market leader. Every time.

- Clinically proven to provide reliable and consistent high bond strengths
- Convenient handling with easy application
- Demonstrates reduction in postoperative sensitivity

iBOND® Total Etch is clinically proven to outperform OptiBond® Solo Plus in bond strength.

In a study conducted by REALITY, iBOND Total Etch was shown to have higher bond strengths to dentin and enamel than OptiBond Solo Plus.



Source: REALITY, October 2009. Sponsored by Heraeus. Data on file. OptiBond Solo Plus is not a registered trademark of Heraeus Kulzer GmbH.

Average standard deviation reveals iBOND Total Etch to have a higher, more consistent bond strength to both enamel and dentin.

Call (877) 258-5937 to receive a **FREE SAMPLE** of iBOND Total Etch!




iBOND®

Bonding with Confidence

Lifelike

Characteristics Demonstrating



Predictable Durability

Increasing All-Ceramic Treatment Durability in the Esthetic Zone Using Lithium Disilicate Restorations

George Priest, DMD

Introduction

Restorations in the esthetic zone require fabrication from materials exhibiting the most lifelike characteristics while demonstrating predictable durability. Currently, most veneer restorations are created using stacked feldspathic porcelain, whereas many crowns are either metal-ceramic or all-ceramic with zirconia cores. The use of zirconia substructures as cores for ceramic crowns has provided an obvious esthetic advantage over masking darkened metal cores and frameworks while providing high flexural strength.¹ There are, however, shortcomings to zirconia technology, and lithium disilicate crown and veneer restorations (e.g., IPS e.max, Ivoclar Vivadent; Amherst, NY), offer promise for overcoming many of the obstacles faced with zirconia.

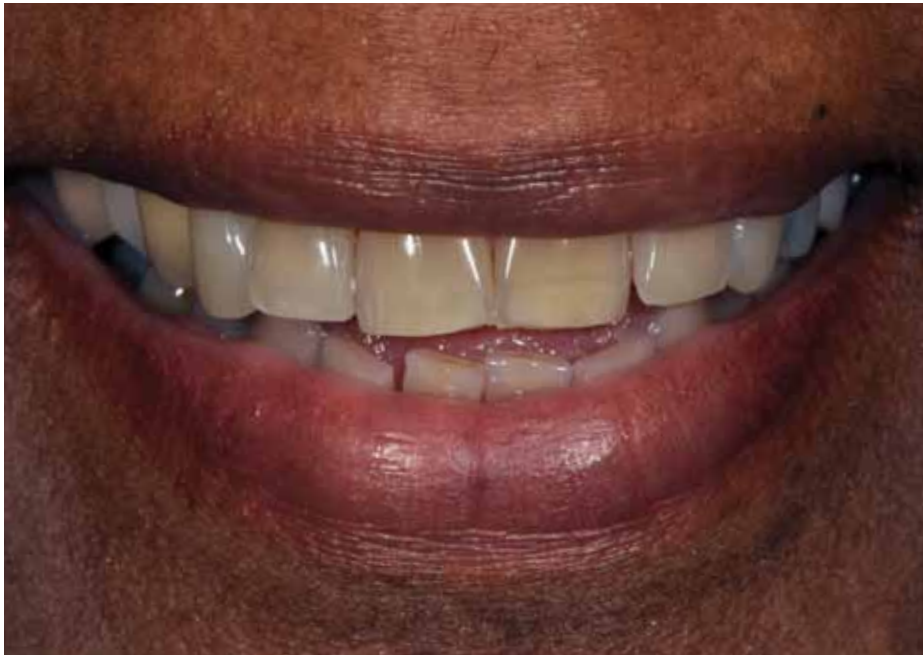

Figure 1: A 57-year-old woman was displeased with the appearance of her smile.

Literature Review

For example, zirconia provides a strong substructure, but the bond between the layering ceramic and zirconia appears to be an "Achilles heel." A problem that has plagued clinical trials of zirconia-cored restorations is a high rate of chipping of the veneering ceramic.^{2,3} In their review of the literature, Donovan and Swift concluded that veneered zirconia crowns should not be used routinely on molars or for multi-unit restorations.⁴ After experiencing veneering fractures on 50% of zirconia three-unit fixed partial dentures, Christensen and Bloeger concluded that veneer ceramics for zirconia need improvement.⁵

In a bench test using a rapid prototyping die, investigators at New York University (NYU) compared fully contoured crowns made with veneered IPS e.max ZirCad/Ceram zirconia cores with crowns made of IPS e.max CAD monolithic lithium disilicate. To simulate mouth motion, an indenter was cyclically slid lingually down the disto-buccal cusp of the samples during step-stress fatigue. Chipping of hand-layered veneered zirconia crowns occurred, whereas none of the computer-aided design/computer-assisted manufacturing (CAD/CAM)-fabricated monolithic lithium disilicate crowns failed during

step-stress of the disto-buccal cusps.⁶ While not quite approaching the flexural strength of monolithic zirconia, the machined lithium disilicate is much stronger than feldspathic ceramics, demonstrating a flexural strength of 400 MPa in pressable form (e.g., IPS e.max Press).⁷ In particular, in an in vitro investigation, Stappert and colleagues⁸ demonstrated failure loads from 1,560 to 1,960 newtons under masticatory fatigue loading for partial-coverage crowns on molars using the pressable form of lithium disilicate. Another in vitro study, by Silva and colleagues at NYU, using the same apparatus as described above, tested first molar crowns cemented onto dies with resin cement and found results similar to Stappert et al. Recorded strength values were 1,719, 1,304, and 631 newtons for lithium disilicate, metal ceramic, and veneered zirconia crowns respectively.⁹ In a private practice setting, Valenti and Valenti demonstrated a 95.5% success rate of 261 IPS Empress 2 anterior and posterior lithium disilicate crowns after 10 years in service. Only eight crowns failed (six due to chipping and two due to core fractures).¹⁰ Additionally, Reich and colleagues reported that 41 chair-side-generated CAD/CAM posterior lithium disilicate crowns in 34 patients

remained in situ after 24 months of observation.¹¹ Unlike zirconia, lithium disilicate is etchable due to its glassy phase, and initial data for bonded single restorations are excellent.^{12,13} The above-referenced studies indicate that lithium disilicate crowns should prove more durable in clinical practice than crowns with zirconia cores.

The inherent opacity of zirconia is another limitation that can have a significant impact on esthetic results.¹⁴ A supposed advantage of all-ceramic materials is improved transmission of light. Zirconia, however, is relatively opaque, and light striking the bright core is actually reflected and scattered.¹⁵ In the author's experience, this opacity creates two additional problems. First, technicians accustomed to opaquing darker metals must relearn their opaquing techniques to compensate for bright zirconia cores. Secondly, if crowns and veneers are combined in the same arch, it is difficult to obtain a shade match and similar optical properties between the dissimilar feldspathic veneers and zirconia-cored crowns.¹⁶

Lithium disilicate, however, provides a distinct advantage in translucency over opaque zirconia, mimicking the light transmission observed in natural teeth. Ingots are produced with varied optical properties: high opacity (HO), medium opacity (MO), low translucency (LT), and high translucency (HT).¹⁷ Secondly, because veneers and crowns can both be made with lithium disilicate, technicians are not burdened with attempting to achieve shade and optical matches between dissimilar materials.

Two case presentations are described here to demonstrate the manner in which all-ceramic restorations for the esthetic zone were treatment planned for lithium disilicate restorations to ensure durability, esthetics, and seamless integration between a combination of restorations.

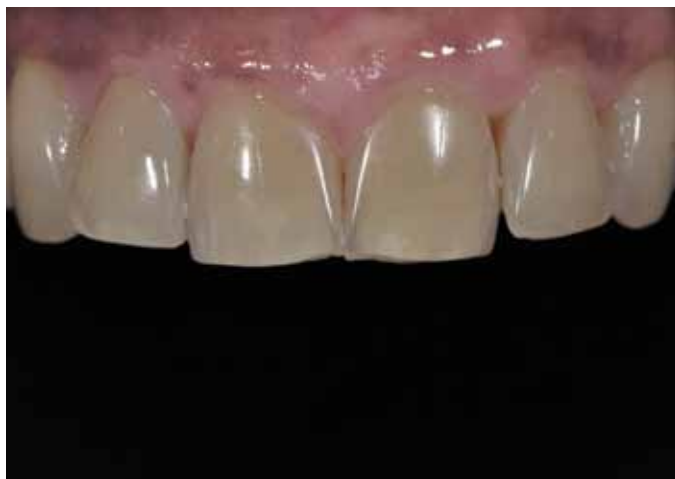

Figure 2: Maxillary anterior teeth were darkened, worn, and disproportionate, and the premolars were discolored.

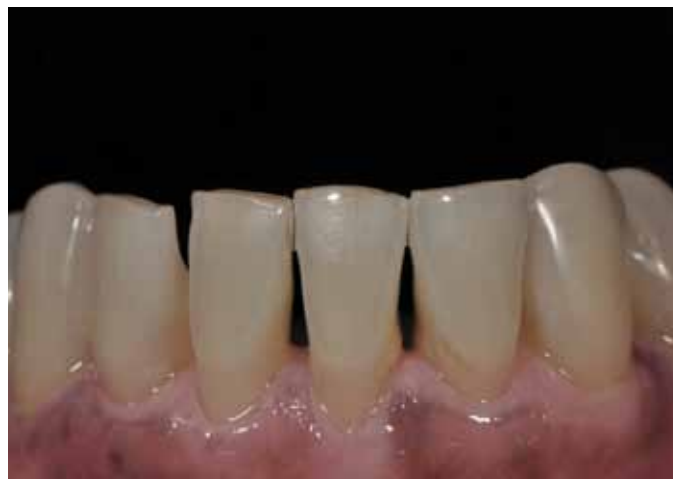

Figure 3: The mandibular teeth displayed gingival erosion and dark triangles between the anterior teeth.

Case Presentation #1

Findings

A 57-year-old woman who was unhappy with the esthetics of her smile presented for treatment (Fig 1). Her anterior teeth were slightly misaligned, darkened, worn, disproportionate, and exhibited black triangles (Figs 2 & 3). Orthodontic therapy had been completed several years earlier, but the patient admitted that she was not compliant in wearing her retainer. Her wide smile also displayed the first premolars, which previously had been restored with metal-ceramic crowns, also to a darkened shade.

Treatment Plan

Following a thorough examination and consultation, several treatment options were discussed. Reinstitution of orthodontics was suggested, but the patient declined. Whitening had been attempted previously with little success, and this option would not address issues of unesthetic contours and the darkened premolars that had been restored earlier. Incisal edge lengthening was required for proportionate contours and the author considered that composite resin restorations would carry a high risk of fracture. The selected treatment plan included veneers on the maxillary and mandibular anterior teeth and intact premolars, and replacement crowns on the previously restored premolars.

Because veneer and crown restorations were required in the same arch, which also had to blend with relatively translucent natural teeth, lithium disilicate was the material of choice for the patient's rehabilitation.

Lithium disilicate crown and veneer restorations...offer promise for overcoming many of the obstacles faced with zirconia.

Treatment

Casts of the patient's existing dentition were made and articulated and a diagnostic wax-up completed to address the patient's esthetic priorities, refine the anterior alignment, and improve her occlusion. The wax-up was duplicated in stone (Figs 4 & 5), and putty matrices were made to serve as preparation guides and to aid in the creation of provisional restorations (Fig 6).

The selected shade for the restorations was agreed upon by the patient and prosthodontist (Fig 7). Maxillary anterior veneer and premolar crown preparations were completed first (Fig 8). Mandibular preparations were undertaken next, and veneers were planned for the anterior teeth. However, even after minimal preparation, significant dentin exposure and insuf-

ficient enamel substrate precluded the use of veneers on the mandibular incisors. Therefore, the preparations were converted to those for full-crown restorations, the intact premolars prepared for veneers, and a single right second premolar was re-prepared for a replacement crown.

A stump shade was selected after preparations were complete (Fig 9). Provisional restorations were made from the diagnostic wax-up using bis-acryl resin (Structur Premium, VOCO America; Briarcliff Manor, NY) and cemented using a self-adhesive cement (Rely X Unicem, 3M ESPE; St. Paul, MN) (Fig 10). The author has used this cement for many years for predictable retention of provisional veneers. Using a hemostat, they are not particularly difficult to remove, and leave a clean and etchable enamel surface that has no untoward effect on cementation of definitive veneers. The patient was instructed to evaluate this esthetic template and report any desired modifications.

Impressions were made and casts sectioned. Maxillary dies included six anterior veneers and two crowns for the first premolars. The fabricated lithium disilicate veneers and crowns demonstrated an intimate interface between the chamfer margins and the restorations (Fig 11). Veneers and crowns for the mandibular dies were designed for ideal arch alignment (Fig 12).

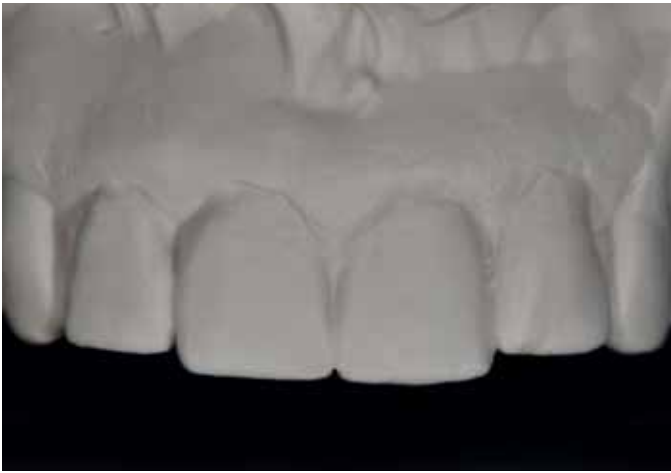


Figure 4: The maxillary teeth were ideally waxed and duplicated in stone.

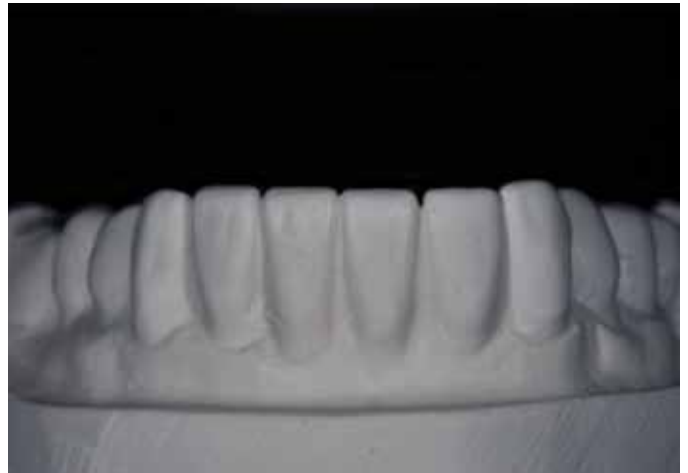

Figure 5: The mandibular teeth were aligned and proximal spaces closed.

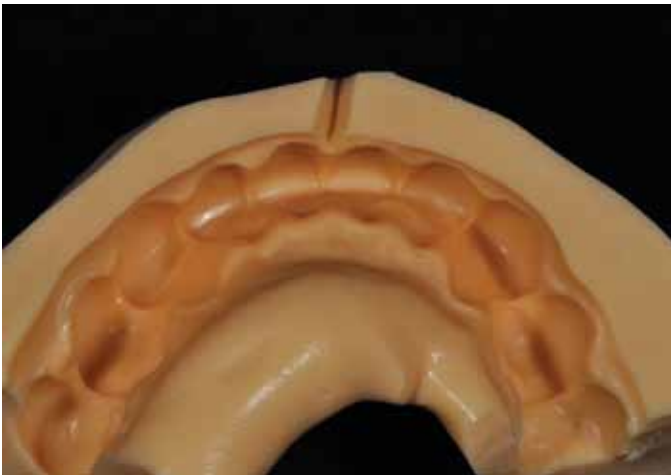

Figure 6: A silicone putty matrix of each arch was made for use as a preparation guide and for making provisional restorations.

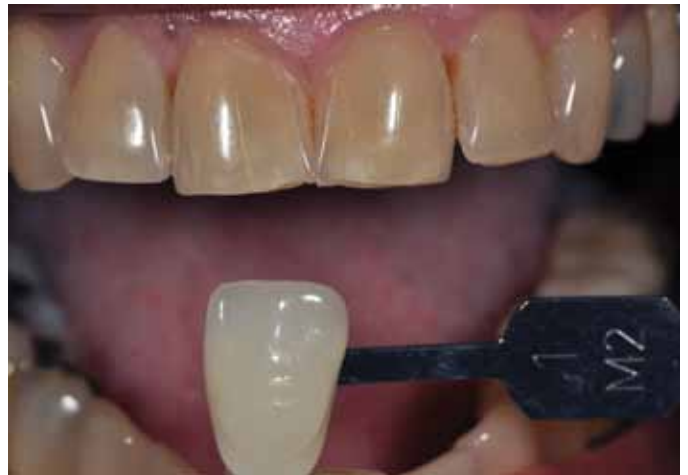

Figure 7: The dentist and patient selected a mutually agreed-upon shade.

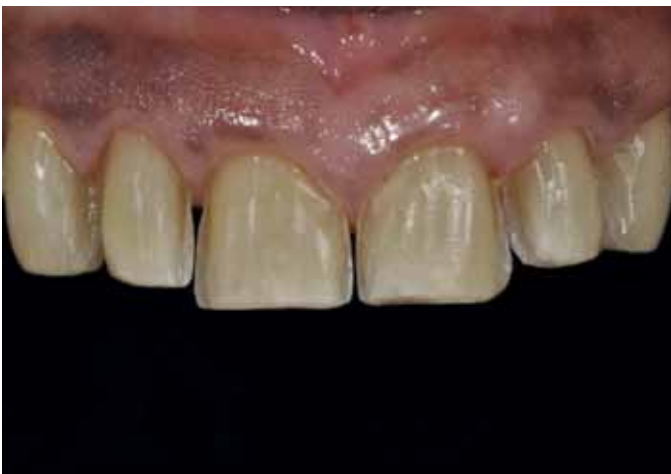

Figure 8: The maxillary anterior teeth were prepared for ceramic veneers and the first premolars for ceramic crowns.

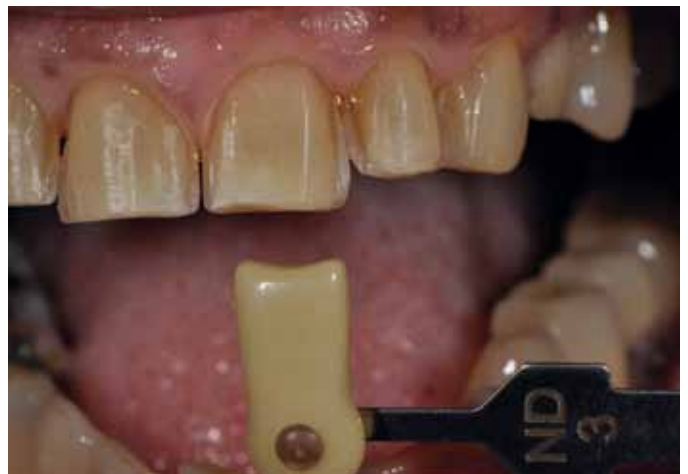

Figure 9: Following tooth preparation, a stump shade was selected.

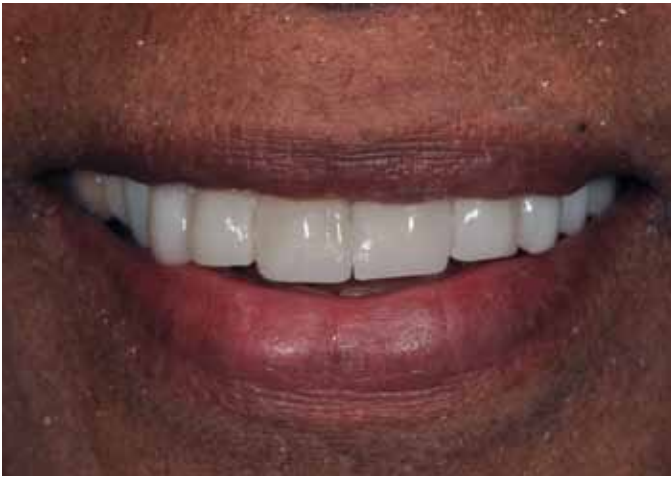

Figure 10: Provisional veneers, predicated on the diagnostic wax-up, were seated with self-etching cement.

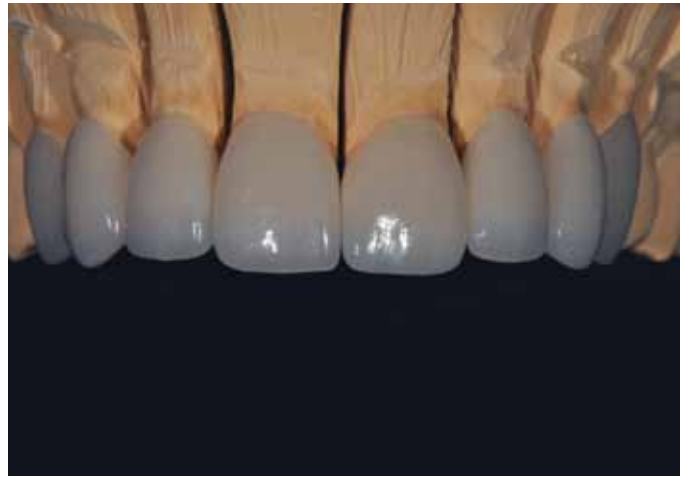


Figure 11: Lithium silicate veneers and crowns were fabricated.

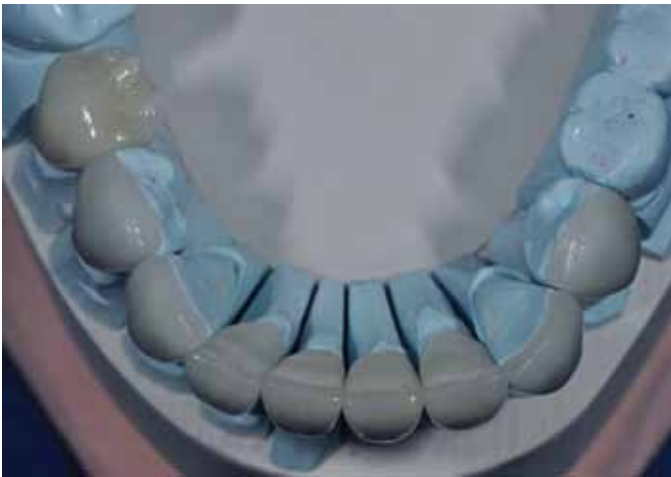

Figure 12: The completed lithium disilicate veneers and crowns on the mandibular arch reestablished the ideal arch form.

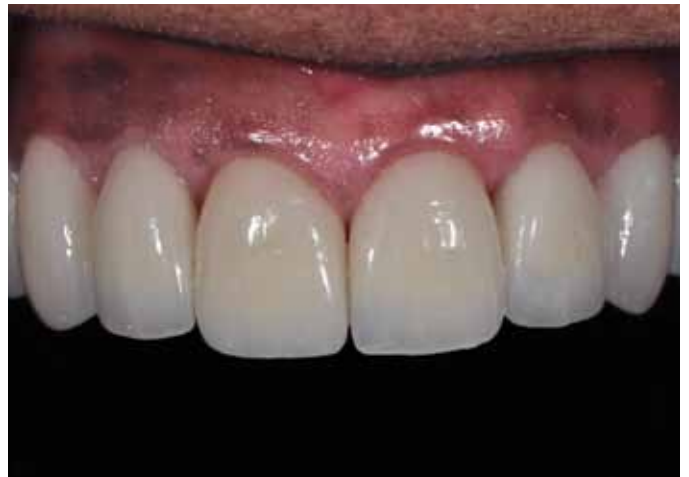

Figure 13: The seated maxillary restorations improved tooth color, contour, proportions, and alignment while maintaining gingival health.

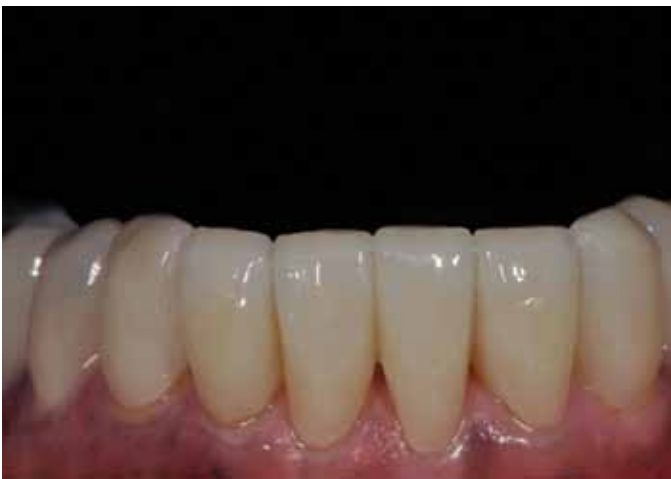

Figure 14: Mandibular veneers and crowns effectively eliminated proximal spaces and established ideal tooth alignment.

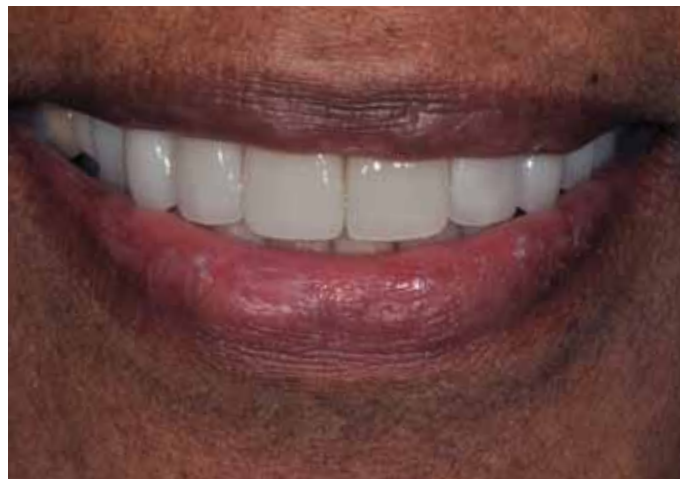

Figure 15: The patient's goal of a more youthful and esthetically balanced smile was achieved.

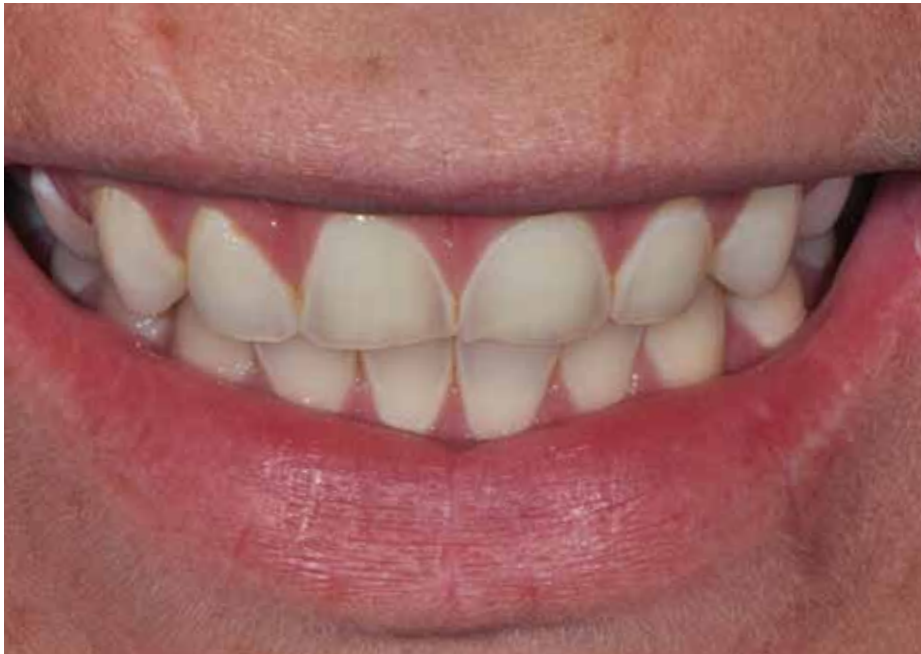

Figure 16: A 25-year-old woman presented with eroded maxillary anterior teeth.

The seated maxillary lithium disilicate crowns and veneers (IPS e.max) maintained the patient's gingival health while creating a youthful and translucent appearance to her smile (Fig 13). The mandibular veneers and crowns achieved the objective of improved arch alignment, closure of interproximal spaces, and corrected maxilla-mandibular relationships (Fig 14). Smile esthetics met the patient's expectations for improved proportions, elimination of spaces, correct alignment, and youthful shade (Fig 15).

Case Presentation #2

Findings

A 25-year-old woman presented with eroded maxillary anterior teeth due to a history of bulimic reflux (Fig 16). Facial enamel and incisal edges of the maxillary incisors were affected (Fig 17). Posterior teeth were unaffected, but the palatal enamel of the incisors was extremely eroded (Fig 18). Radiographically, no apical pathology was noted, and bone levels were normal (Fig 19), but her lower anterior teeth were misaligned.

Treatment Plan

Treatment options included orthodontic therapy, primarily to realign the mandibular anterior teeth and restoration of the maxillary anterior incisors and possibly the canines. Continued monitoring of the erosion without restoration was not an option presented. Tooth loss was excessive, particularly for the patient's age, and renewed esthetics was a patient priority. There was insufficient remaining enamel for composite resin restorations or ceramic veneers. Orthodontic treatment was undertaken and completed, and four lithium disilicate ceramic crowns (IPS e.max) were treatment planned with the objective of restoring lost tooth structure both facially and palatally, as well as esthetically blending the anterior four crowns with the intact remaining teeth. The author and patient decided to monitor the canines for further tooth loss and restore them at a later date if necessary.

Treatment

At the preparation appointment, an appropriate shade was selected (Fig 20). The four maxillary incisors were initially prepared and a stump shade was chosen (Fig 21). Preparations were then

completed without gingival trauma (Fig 22). Predicated on a diagnostic wax-up, a provisional restoration was made with bis-acryl resin and seated using a temporary cement (Fig 23).

Lithium disilicate was chosen primarily because its translucent optical properties would blend best with the young patient's relatively translucent maxillary canines and posterior teeth (Fig 24).

The patient returned after three weeks, at which time the crowns were acid-etched, silanated, and seated using a dual-cure, self-etching adhesive (Panavia F 2.0, Kuraray America; New York, NY) (Fig 25). Cementation of lithium disilicate restorations can be successfully accomplished using traditional cements such as zinc phosphate,¹⁸ but improved bond strengths have been demonstrated with etching with hydrofluoric acid and application of silane primer¹⁹ followed by self-adhesive resin cements.²⁰ Optimal anterior occlusion was established, tissue health was maintained, and the crowns blended seamlessly with the natural dentition (Fig 26). A rejuvenated smile was the patient's ultimate goal (Fig 27).

Conclusion

The availability of a restorative material such as lithium disilicate for the fabrication of durable metal-free restorations suitable for placement throughout the oral environment is a huge leap toward dentistry's goal of optimizing esthetic outcomes using a ceramic material with demonstrated longevity. The cases discussed in this article demonstrate that natural teeth, crowns, and veneers can be nearly indistinguishable when lithium disilicate is the selected ceramic material. Documented long-term durability, the ability to use it for crowns and veneers, and improved optical properties position lithium disilicate as a material for consideration in esthetically critical dental rehabilitations.

IS YOUR WEBSITE Working FOR YOU?

Hiring the right online marketing and design firm can be a tough decision, and trying to manage all of the variables on your own is overwhelming. Which parts and pieces are needed? Which are the best return on your investment? Relax, we'll help you make cents of internet marketing. Contact us for a comprehensive evaluation, Today!



BUDGET



DESIGN



PROMOTE



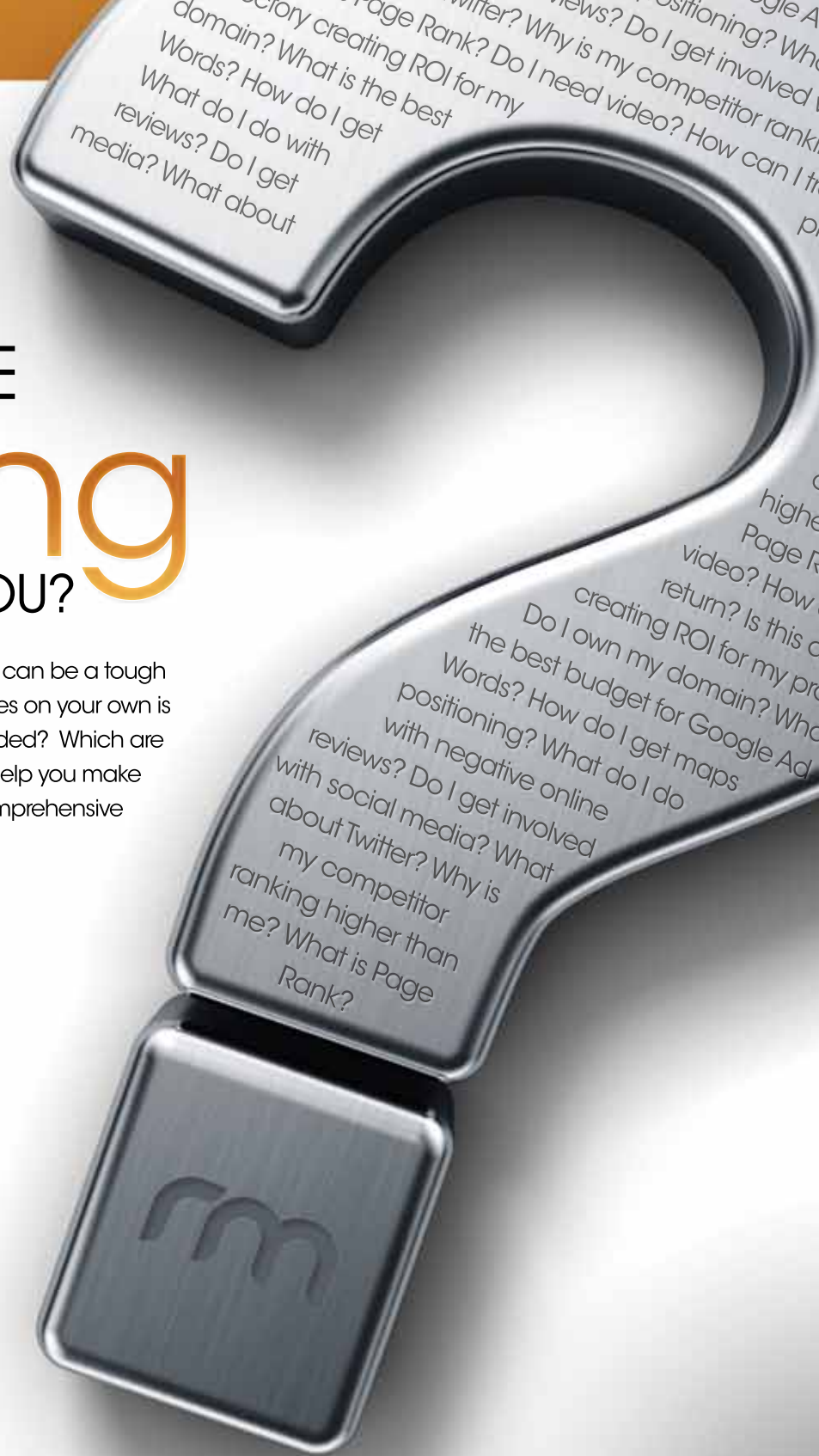TRACK

Performance based web strategies.



1010 Turquoise Street, Suite 201, San Diego, CA 92109
Ph. 800.491.8623
www.rosemontmedia.com
info@rosemontmedia.com
www.facebook.com/rosemontmedia

Call Today:
800.491.8623



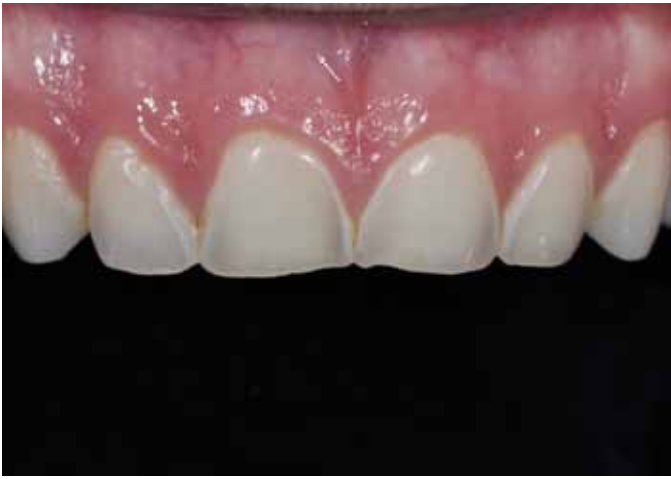

Figure 17: The facial enamel and incisal edges of the maxillary incisors were affected.

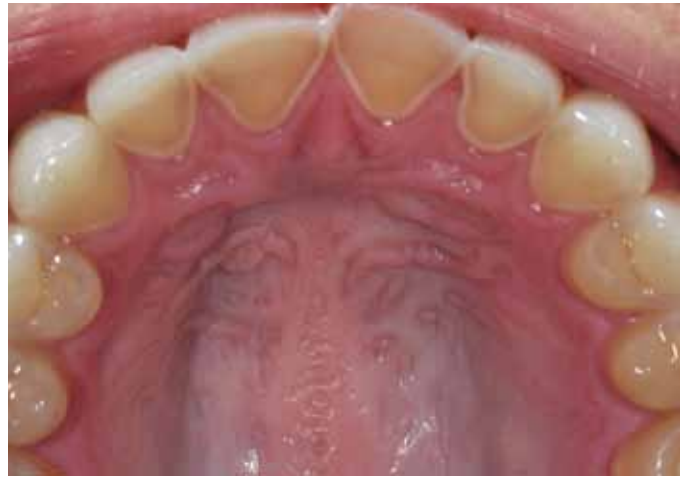

Figure 18: The posterior teeth were unaffected, but the palatal enamel of the incisors was extremely eroded.

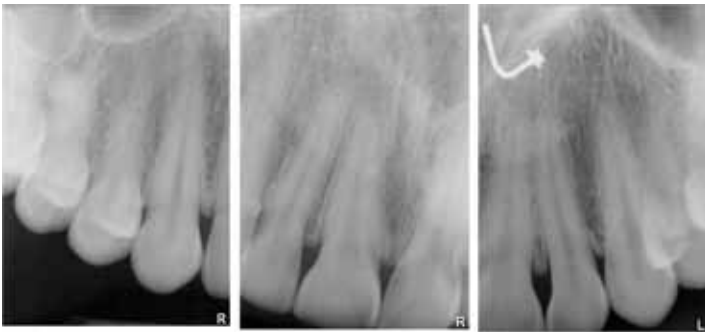


Figure 19: Radiographically, no apical pathology was noted and bone levels were normal.

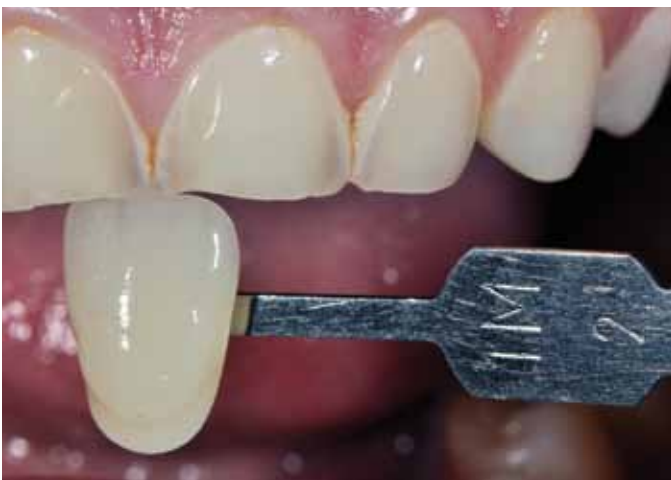

Figure 20: At the preparation appointment, an appropriate shade was selected.

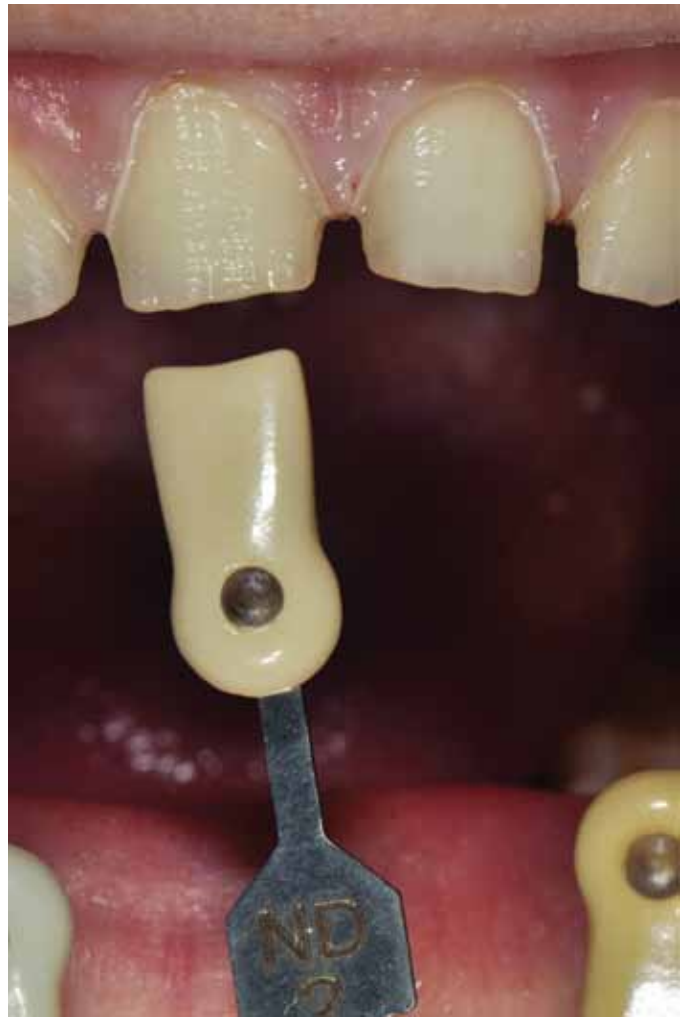

Figure 21: The four maxillary incisors were prepared and a stump shade was chosen.

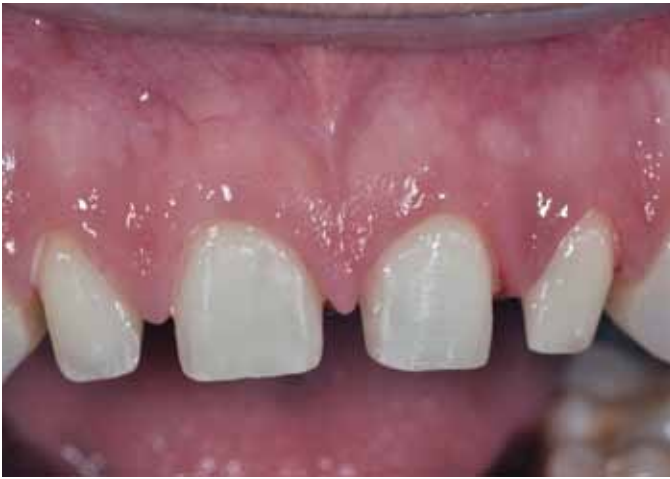

Figure 22: Preparations were then completed without gingival trauma.

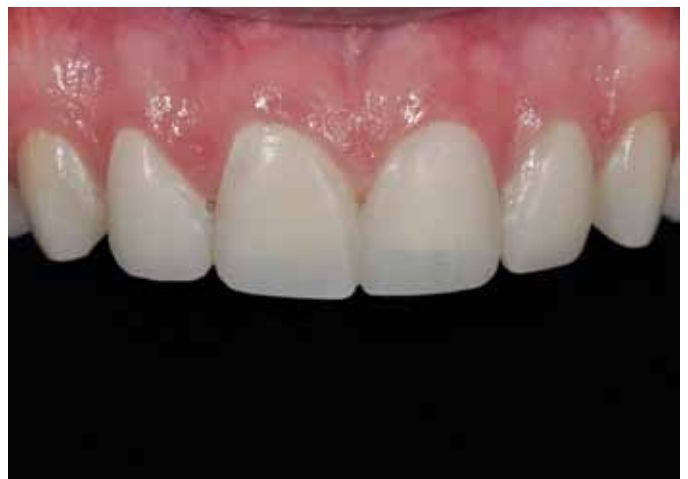

Figure 23: The seated provisional crowns served as a template for the definitive crowns.

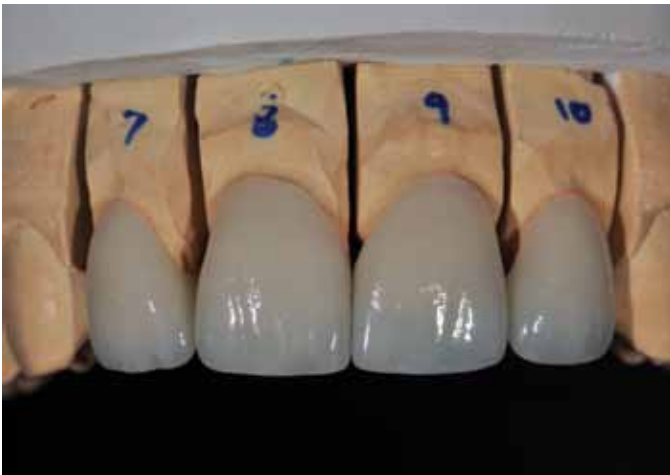

Figure 24: The lithium disilicate crowns demonstrated good marginal fit on the dies.

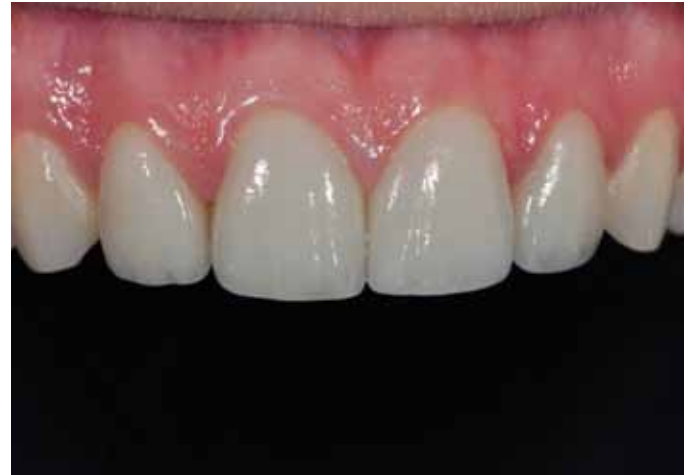

Figure 25: The patient returned after three weeks, at which time the crowns were seated using a self-etching cement.

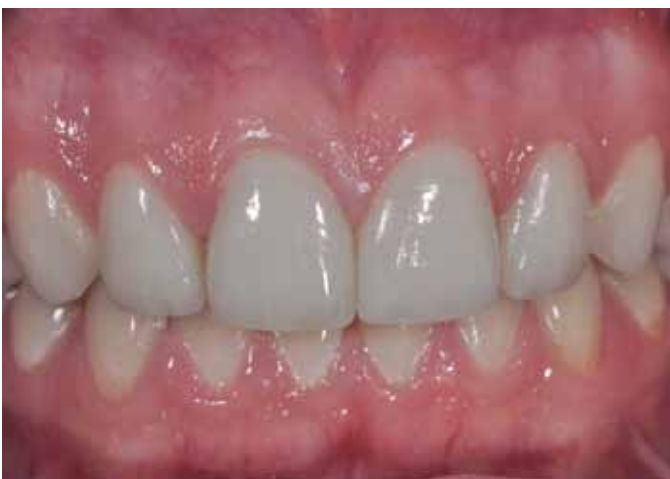

Figure 26: Optimal anterior occlusion was established, tissue health maintained, and the crowns blended seamlessly with the natural dentition.

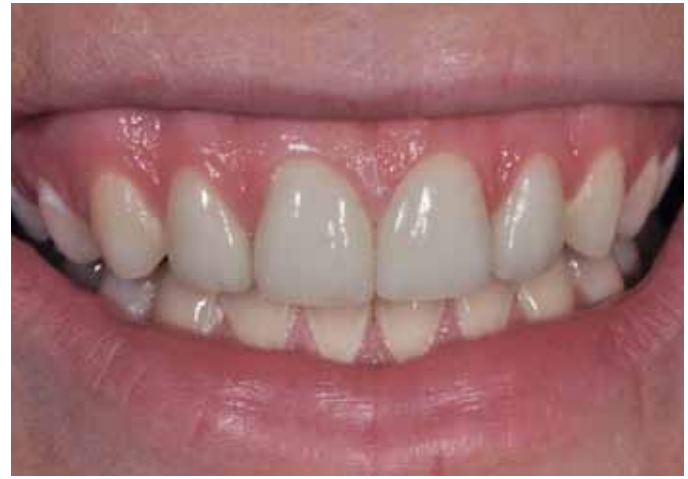

Figure 27: A renewed smile was the patient's ultimate goal.

References

- White SN, Miklus VG, McLaren EA, Lange LA, Caputo AA. Flexural strength of a layered zirconia and porcelain dental all-ceramic system. *J Prosthet Dent.* 2005;94(2):125-31.
- Donovan TE. Factors essential for successful all-ceramic restorations. *J Amer Dent Assoc.* 2008;139(Suppl):14S-18S.
- Özkurt Z, Kazazoglu E. Clinical success of zirconia in dental applications. *J Prosthodont.* 2010;19(1):64-8.
- Donovan TE, Swift EJ. Porcelain-fused-to-metal (PFM) alternatives. *J Esthet Dent.* 2009;21(1):4-6.
- Christensen RP, Bloeger BJ. A clinical comparison of zirconia, metal and alumina fixed-prosthesis frameworks veneered with layered or pressed ceramic. *J Amer Dent Assoc.* 2010;141(11):1317-29.
- Guess PC, Zavanelli RA, Silva NRFA, Bonfante EA, Coelho PG, Thompson VP. Monolithic CAD/CAM lithium disilicate versus veneered Y-TZP crowns: comparison of failure modes and reliability after fatigue. *Int J Prosthodont.* 2010;23(5):434-42.
- Fabianelli A, Goracci C, Bertelli E, Davidson CL, Ferrari M. A clinical trial of Empress II porcelain inlays luted to vital teeth with a dual-curing adhesive system and a self-curing resin cement. *J Adhes Dent.* 2006;8(6):427-31.
- Stappert CJF, Att A, Gerds T, Strub JR. Fracture resistance of different partial-coverage ceramic molar restorations: an in vitro investigation. *J Amer Dent Assoc.* 2006;137(4):514-22.
- Silva NR, Thompson VP, Valverde GB, Coelho PG, Powers JM, Farah JW, Esquivel-Upshaw J. Comparative reliability analyses of zirconium oxide and lithium disilicate restorations in vitro and in vivo. *J Amer Dent Assoc.* 2011;142(4 Suppl):4S-9S.
- Valenti M, Valenti A. Retrospective survival analysis of 261 lithium disilicate crowns in a private general practice. *Quintessence Int.* 2009;40(7):573-9.
- Reich S, Fischer S, Sobotta B, Klapper H-U, Gozdowski S. A preliminary study on the short-term efficacy of chairside computer-aided design/computer-assisted manufacturing-generated posterior lithium disilicate crowns. *Int J Prosthodont.* 2010;23(3):214-6.
- Giordano R, McLaren EA. Ceramics overview: classification by microstructure and processing methods. *Compend Contin Educ Dent.* 2010;31(9):682-8.
- McLaren EA, Phong TC. Ceramics in dentistry—part I: classes of materials. *Inside Dent.* 2009;5(9):94-103.
- Koutayas SO, Vagkopoulou T, Pelekanos S, Koidis P, Strub JR. Zirconia in dentistry: part 2. Evidence-based clinical breakthrough. *Eur J Esthet Dent.* 2009;4(4):348-80.
- McLaren EA, Giordano RA. Zirconia-based ceramics: material properties, esthetics, and layering techniques of a new veneering porcelain, VM9. *QDT.* 2005;28:99-11.
- Cardoso JA, Almeida PJ, Fernandes S, Silva CL, Pinho A, Fischer A, Simões L. Co-existence of crowns and veneers in the anterior dentition: case report. *European J Esthet Dent.* 2009;4(1):12-26.
- Culp L, McLaren EA. Lithium disilicate: the restorative material of multiple options. *Compend Contin Educ Dent.* 2010;31(9):716-25.
- Bindl A, Lathy H, Marmann WH. Strength and fracture pattern of monolithic CAD/CAM-generated posterior crowns. *Dental Mater.* 2006;22(1):29-36.
- Nagai T, Kawamoto Y, Kakehashi Y, Matsumura H. Adhesive bonding of a lithium disilicate ceramic material with resin-based luting agents. *J Oral Rehabil.* 2005;32(8):598-605.
- Piowarczyk A, Lauer H-C, Sorensen JA. In vitro shear bond strength of cementing agents to fixed prosthodontic restorative materials. *J Prosthet Dent.* 2004;92(3):265-73. **jCD**

Lithium disilicate...provides a distinct advantage in translucency over opaque zirconia, mimicking the light transmission observed in natural teeth.



Dr. Priest earned his DMD with honors from Fairleigh Dickinson University School of Dentistry in 1976. He maintains a practice in Hilton Head Island, South Carolina.

Disclosure: Dr. Priest is a consultant for Ivoclar Vivadent and receives an honorarium from them (no financial support was received for this article).



> THE INSIDER'S GUIDE TO A SEXY SMILE | Summer/Fall 2006



> I WANT TO REMOVE STAINS | Winter/Spring 2008



> ECO-FRIENDLY DENTISTRY | Winter/Spring 2010

— THE ONLY —
**BEAUTY MAGAZINE WITH
COSMETIC DENTISTRY
EDITORIAL**
— IN EVERY ISSUE —



NEWBEAUTY[®] & AACD | A BEAUTIFUL PARTNERSHIP

To learn more call **866-NEWBEAUTY** or visit www.newbeauty.com

COLORS, SHAPES, ARRANGEMENTS



Scan this Quick Response (QR) code with your smart phone's QR code reader app to see a video regarding the techniques performed in figures 10-25.



Scan this QR code to see a video regarding the preparation color influence in thin veneers.



The digital version of this article features technique videos providing an in-depth view of key concepts in the article. Look for the play button throughout the Figure captions.



FOR COMPREHENSIVE RESULTS

Esthetic Excellence in Restorations with Ceramics

Matthew R. Roberts, CDT, AAACD
 Franklin Shull, DMD
 James F. Fondriest, DDS
 Thomas F. Trinkner, DDS, AAACD

Introduction

Esthetic values are culturally based and thus vary in different parts of the world.¹ European standards are oriented toward replication of natural dentition, whether young and healthy; or old, discolored, and crazed, with realistic and age-appropriate restorations replacing lost tooth structure.² In contrast, 20 years ago North American dental professionals were driven by ultra-white "Hollywood smiles," creating very bright, straight teeth without considering the patient's age or preexisting dental conditions.^{2,3}

Globalization of communication has led to worldwide "standards."^{3,4} Today's esthetic ideals therefore embrace comprehensive philosophies incorporating orthodontically correct teeth that demonstrate pleasing colors, shapes, and arrangements to meet patient goals and objectives, as well as the dentist's functional requirements.^{4,5} Although most patients desire a more youthful smile from comprehensive treatment, dentists today seek to accomplish this objective in the least invasive way, preserving as much natural tooth structure as possible.^{3,5} By identifying and applying essential esthetic, functional, and material components which, when integrated appropriately, define the treatment plan, predictable, long-term, and functional highly esthetic restorations can be delivered to satisfy patients' demands.^{3,5}



Learning Objectives:

After reading this article, the participant should be able to:

1. Discuss the characteristics attributed to an esthetic smile in harmony with facial structures.
2. Develop a multidisciplinary treatment plan to achieve esthetic as well as functional goals.
3. Improve ability to select appropriate dental materials to achieve these goals based on specific material and dental characteristics.

Harmonizing Dental and Facial Esthetics

For a smile to be attractive, dental features must be in harmony with the esthetics of a patient's facial features.⁶⁻¹⁰ The smile midline must align with the vertical axis of the face, and the incisal plane must align with the facial horizontal axis.¹¹⁻¹³ The gingival architecture should follow the shape of the upper lip, and the incisal smile line must harmonize with the shape and position of the lower lip whenever possible.¹¹⁻¹³ The axial inclination should be oriented slightly toward the facial midline for the most pleasing result, and the teeth need to be sized proportionally to fit the face and harmonize with each other.¹¹⁻¹³ All of these characteristics must be integrated into a functionally sound occlusal relationship, with proper guidance, envelope of function, and ideal positioning of the temporomandibular joints.¹¹⁻¹³

Treatment-Planning Considerations

Developing a multidisciplinary treatment plan to achieve a patient's esthetic objectives and the dentist's functional requirements must incorporate the preexisting clinical conditions. Such a treatment plan addresses the aforementioned components and may require specialists to improve the position of dentition, gingival display, and address surgical or implant placement needs.

After completion of tooth position and gingival architecture preliminary evaluations, a diagnostic wax-up demonstrating necessary additive and reductive changes in tooth shape and position is invaluable for determining individual tooth surfaces that should be involved restoratively.¹⁴⁻¹⁷ Wax-ups also determine the amount of any preparation required to achieve the desired final result.¹⁴⁻¹⁷ For example, wax-ups identify for ceramists and dentists where tooth structure must be removed to achieve ideal shape and position; where more aggressive preparation or further orthodontics is required to

achieve ideal occlusal stability; where ideal contour can be achieved by adding wax (i.e., ultimately affecting the thickness of the restorative material); and where little or no tooth structure needs to be removed to accomplish the ideal esthetic outcome.¹⁴⁻¹⁷

For a smile to be attractive, dental features must be in harmony with the esthetics of a patient's facial features.

Affecting preparation requirements and restorative material selection are the color of the patient's existing dentition and the final desired treatment color.¹⁸⁻²⁰ Much of the final color seen in bonded all-ceramic restorations comes from the underlying tooth structure, which contributes its natural and vital appearance in the mouth. A careful strategy must be developed to assess the desirability of the existing color of the teeth to be restored and control the amount of this color allowed to show through the final restorations.

The greater the color change desired, the thicker the ceramic material must be and the deeper the preparation in areas identified as needing reduction to provide room for the ceramic layering necessary to achieve that result. If the preexisting tooth color approximates the final desired color, thinner and more translucent ceramic materials may be used, greatly reducing the need for restorative thickness.

Ceramic Materials, Their Esthetic Influences, and Their Indications

Ceramic materials can be divided into groups based on the relative opacity of the material, such as opaque ceramics, opaceous dentin ceramics, dentin ceramics, enamel ceramics, and translu-

cent ceramics, with each serving specific functions when creating vital-looking restorations.²¹⁻²³ These ceramics can be combined in sequential layers or used individually to augment shape and color.

When restoring extremely discolored teeth or metal implant abutments, opaque core or metal-based ceramics can still be the best approaches to treatment.²⁴ Today's ceramic technologies include systems with highly opaque core material (e.g., alumina, zirconia) or metal-based substructures requiring opaque ceramic layers to conceal the metal or core material; dentin to establish color; and enamel to impart transition, depth, and translucency to the restoration.²¹⁻²³

Metal or zirconia core materials with full ceramic layering can be used selectively to cover drastically discolored natural teeth, implant abutments, or create bridge substructures.²⁴⁻²⁶ A skilled ceramist layers opaceous dentin, dentin, enamel, and a combination of color modifiers and translucent porcelains to cover metal or zirconia substructures and create restorations that mimic the optical properties of natural teeth. This requires a porcelain working space necessitating 1.5 mm axial and 2 mm incisal tooth reduction.²¹⁻²³

Conversely, when the existing natural dentition demonstrates desirable color, a minimally invasive ceramic augmentation strategy incorporating etched and bonded restorations can achieve ideal esthetic results. Although this appears complex, it can be approached systematically from a conservative perspective. This process is initiated by evaluating existing tooth color and position, identifying desired changes in tooth shape and color, and determining which ceramic layers are required to produce a vital-looking restoration in the ideal position to complement the overall treatment goals for the patient.^{10,11}

This article presents cases demonstrating the varying degrees of influence of underlying tooth color. Material selection, preparation, and fabrication

strategies are discussed to illustrate how ideal esthetics can be achieved in individual clinical situations.

Case Examples

Nice Tooth Color, Undesirable Shape

The easiest clinical situation to restore is one in which the tooth color is nice, but tooth shape is less than desirable (Fig 1). In this case almost no preparation was required with the exception of tooth #9, which underwent a small amount of reduction to provide room for the veneer (Fig 2). By closely evaluating the wax-up, it is apparent that no wax was added to #9, which is an indication that it was to be covered (Fig 3). Here, very thin veneers fabricated from enamel or opal enamel ceramics were used to reshape the teeth and slightly enhance their brightness, which was desired.

Pressable lithium disilicate ceramic (IPS e.max Press, Ivoclar Vivadent; Amherst, NY) can be used to create very thin yet strong restorations to treat such patients. Opalescent enamel ceramics (IPS e.max Opal 2) or high-translucency ingots (IPS e.max HT) can be used. With recent developments in material sciences, lithium disilicate glass ceramics have changed clinicians' and technicians' layering strategies.^{27,28} Lithium disilicate demonstrates a flexural strength of 400 MPa and optical properties similar (and, often, superior) to those of conventional ceramic materials.^{27,28}

As with all cases, the extent of required coverage and preparation is determined by completing an additive-reductive diagnostic wax-up (Figs 3-9).

Selective micro-layering is used to realize more dynamic incisal translucency in restorations while maximizing lithium disilicate's 400 MPa strength for durability. Minimal cutback allows sufficient room for layering in the incisal one-fourth of the restorations; underlying tooth color is still utilized to impart color gradient to the gingival three-fourths of the restoration; and preparation depth is decreased in gingival areas to control this color transition.

However, cases with color and shape changes can be treated with very thin restorations that require an average facial thickness of only .2 mm, as in the case of a 40-year-old woman who presented with a major com-

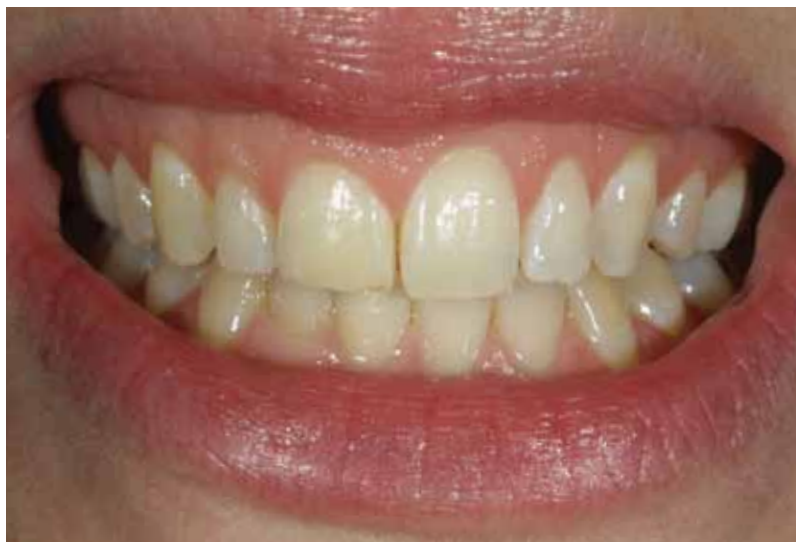

Figure 1: A preoperative image of dentition with nice color, but undesirable shape.

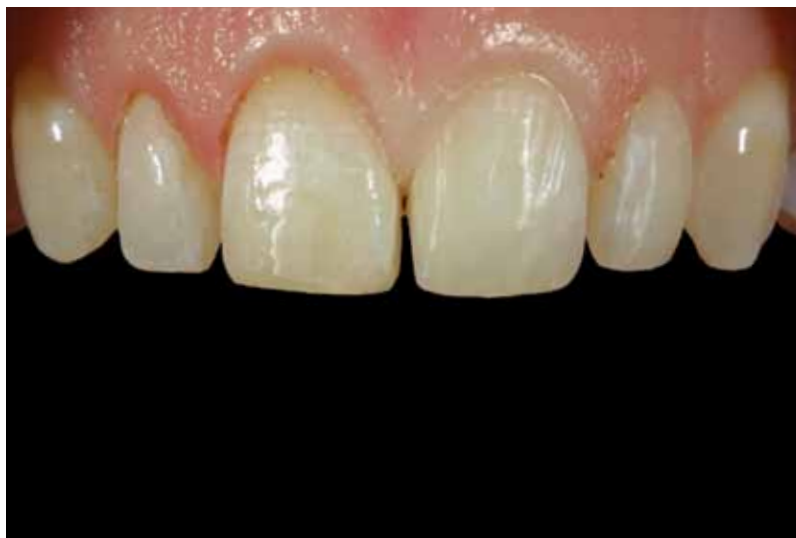

Figure 2: View of minimal preparation and gingival recontouring of tooth #9 prior to impression taking.

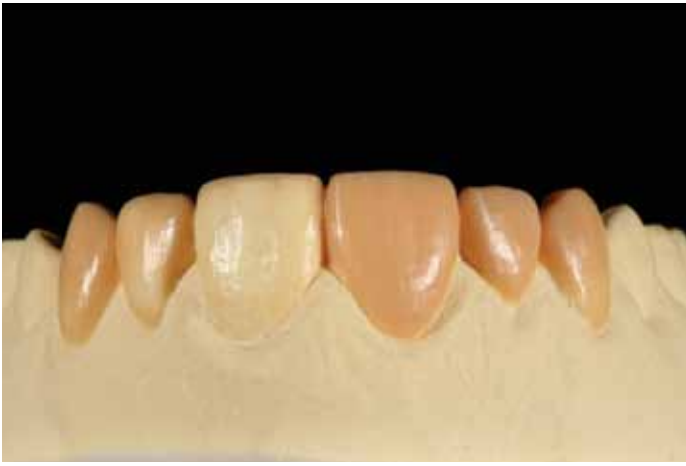

Figure 3: An additive-only wax-up allows fabrication of a matrix that will fit over existing dentition to create an intraoral mock-up.



Figure 4: The wax patterns were invested for pressing.




Figure 5: Image showing the opalescent qualities of the veneers.



Figure 6: View of the mid-facial of the central incisor restoration.



Figure 7: The thickness of the central incisor was .1 mm to .2 mm.

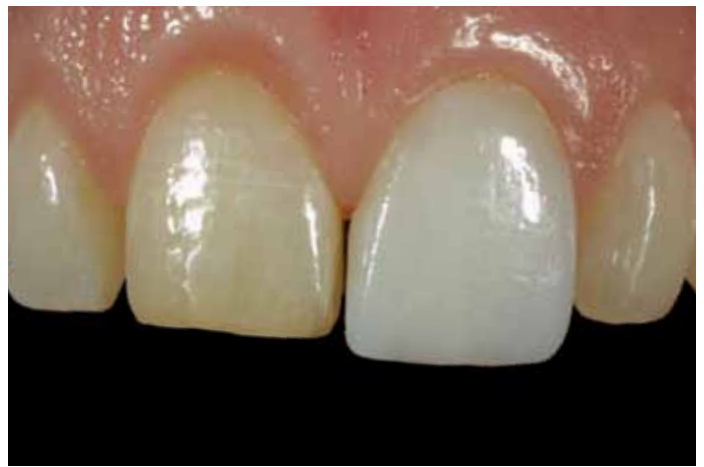

Figure 8: The no-preparation veneers were tried in.

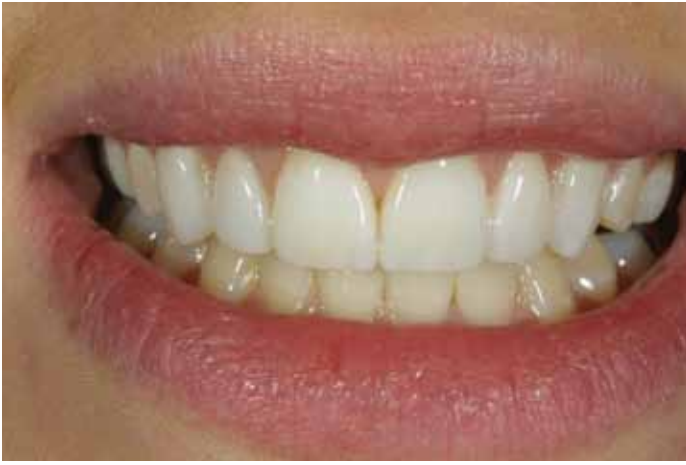

Figure 9: Postoperative view of the completed restorations.
(Figures 3-9: Dentistry by Dr. Trinkner.)

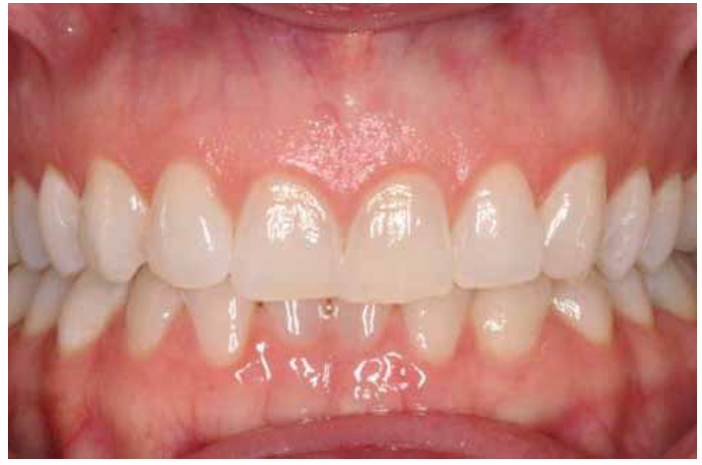

Figure 10: Preoperative frontal view of the anterior teeth.
(Figure 10: Dentistry by Dr. Shull.)

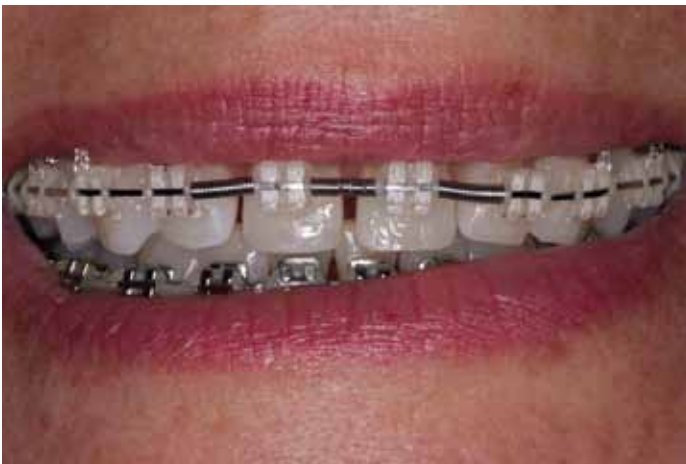

Figure 11: Orthodontic treatment was undertaken to create diastemas.

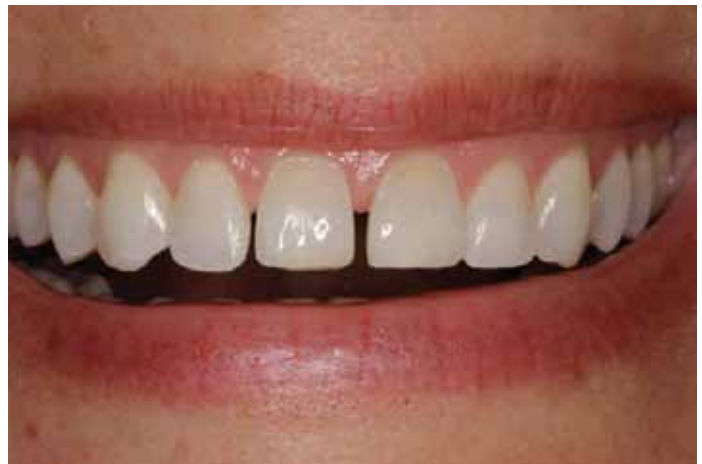

Figure 12: After the orthodontic appliances were removed, the required diastemas were complete.

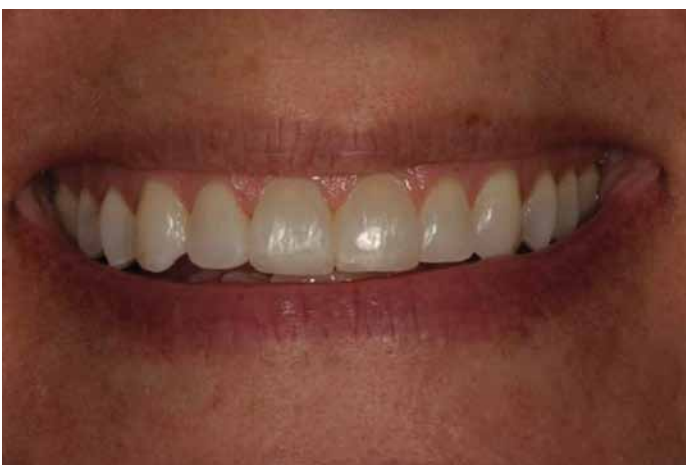

Figure 13: Direct composite was used to satisfy the patients esthetic needs while the diagnostic wax-up was completed.

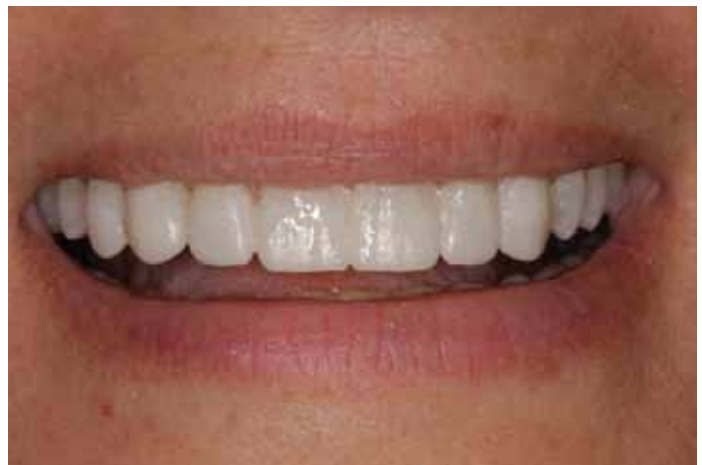

Figure 14: A putty matrix was used to transfer the wax-up to the patient's mouth.

plaint regarding tooth size, wear, and esthetics (Fig 10). The patient agreed to suggested orthodontic treatment to create diastemas that would allow more ideal length and width of the restored teeth (Fig 11), as well as intrusion of the central incisors to create a more esthetic gingival architecture.

During treatment, it was decided to address the lower incisor crowding and, after 18 months of orthodontic treatment, the patient presented large diastemas that would be corrected but were necessary to enable proper esthetic treatment results (Fig 12). Photographs of the patient's dentition, a bite registration, and facebow were taken. Provisional restorations were then directly bonded and diagnostic case information was sent to the ceramist (Fig 13).

The initial temporary material was removed, and an additive wax-up created from a putty matrix and a bis-acrylic provisional material was transferred to the mouth (Fig 14). Because the wax-up was additive, no preparation was required at this stage. Once the length, shape, and midline orientation were confirmed, preparation began. Depth cuts were made through the provisional to preserve as much enamel as possible (Figs 15 & 16).

Final impressions, bite registration, facebow, and stick bite were taken and sent to the ceramist. Provisional restorations were once again fabricated using the wax-up and the putty matrix. The patient was sent home but returned four days later to evaluate esthetics and function of the provisionals. Photographs were taken to communicate any necessary changes, after which the restorations were fabricated (Figs 17-21).

After the definitive restorations were received from the laboratory, they were seated using a fifth-generation bonding agent and a light-cured resin cement (Figs 22-25).

Caveats with Increased Color and Shape Changes: The same material and thickness (HT BL1 at .2 mm) would result in show-through if the prepared teeth exhibited more color and less translucency (Figs 26 & 27). However, by slightly increasing the material thickness (e.g., from .3 mm to .5 mm) and, in this case, performing a fuller contour and a little more preparation, the effect of the

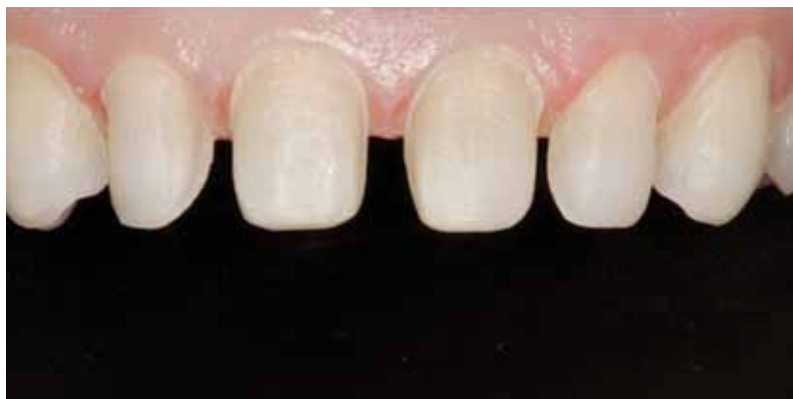

Figure 15: Initial preparations were made to the maxillary anterior dentition, ##5-12.

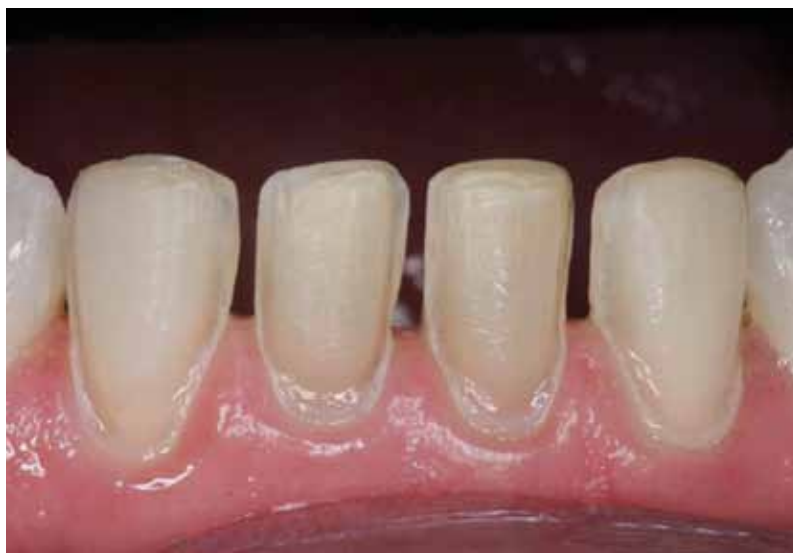

Figure 16: Preparations were made to the lower anterior teeth, ##23-26.

A careful strategy must be developed to assess the desirability of the existing color of the teeth to be restored and control the amount of this color allowed to show through the final restorations.

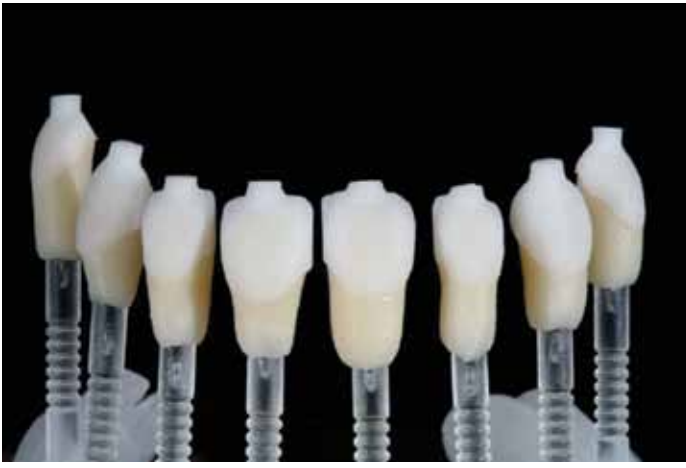

Figure 17: The restorations were pressed from HTBL1 lithium disilicate.

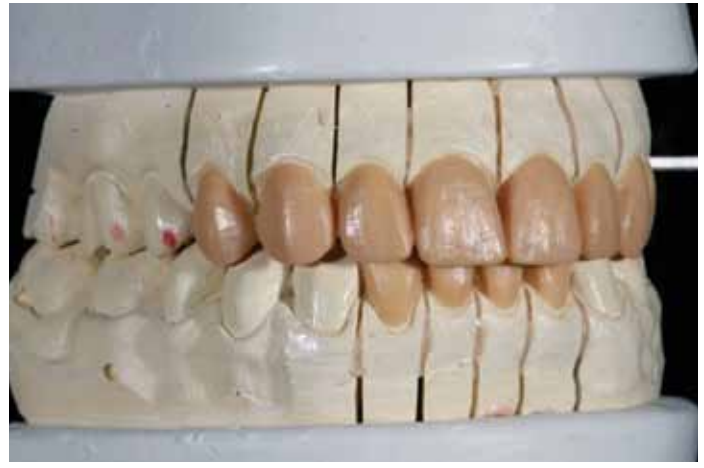

Figure 18: A full-contour wax-up was completed.

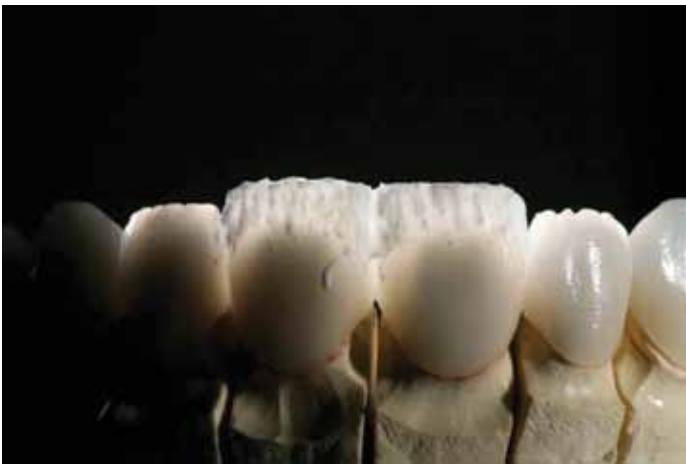

Figure 19: Micro-layering was completed, with lithium disilicate supporting the lingual-incisal edge.

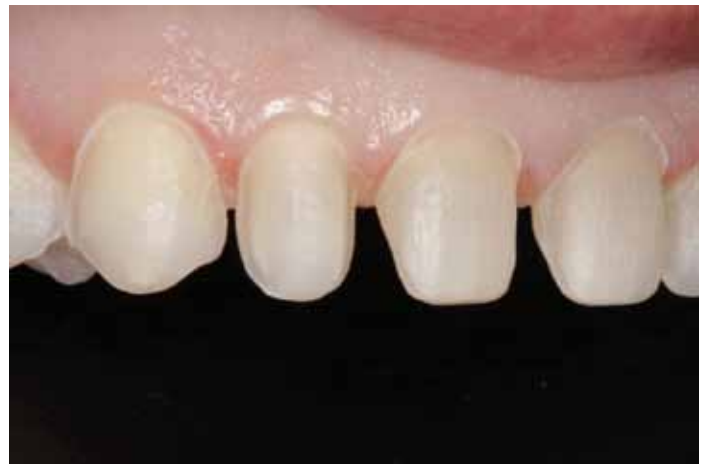

Figure 20: The nice color and translucency of the incisal one-third of the preparations allowed for the use of a very thin layer of ceramic without undesirable show-through.

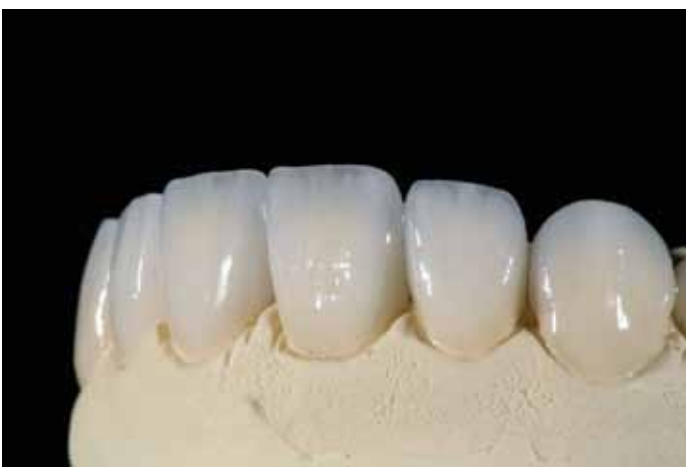

Figure 21: The desired translucency was achieved within the restorations.

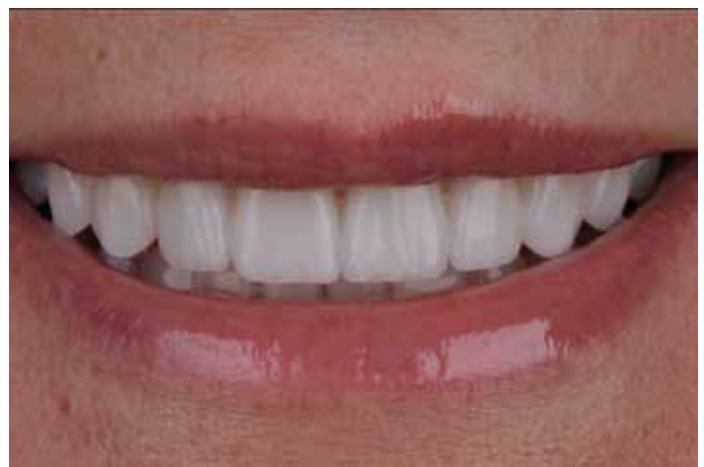

Figure 22: The definitive restorations were cemented using a fifth-generation adhesive bonding agent.

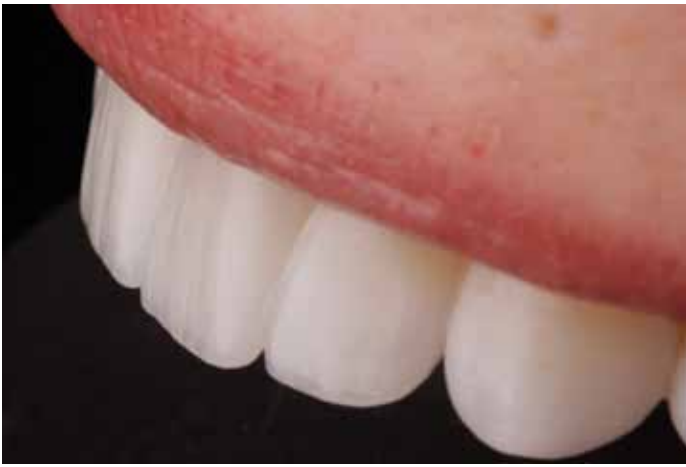

Figure 23: Due to the preparation color and translucency, there was no undesirable color effect in the final HTBL1 restorations, even though they are only .2 mm thick.

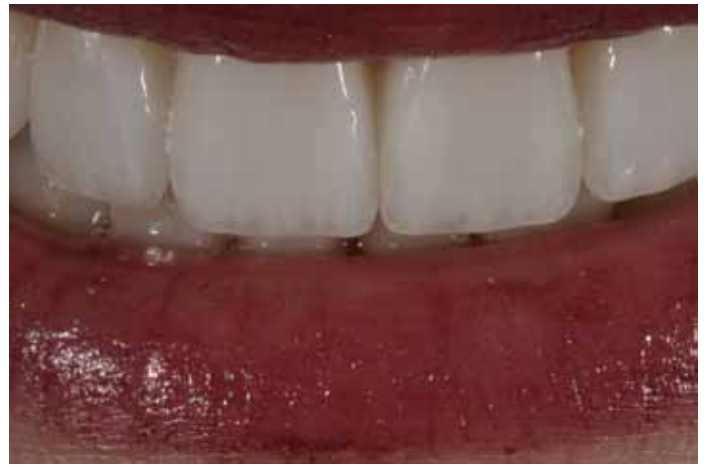

Figure 24: Close-up view of #7-10 following completion of restorative treatment, showing natural shading.

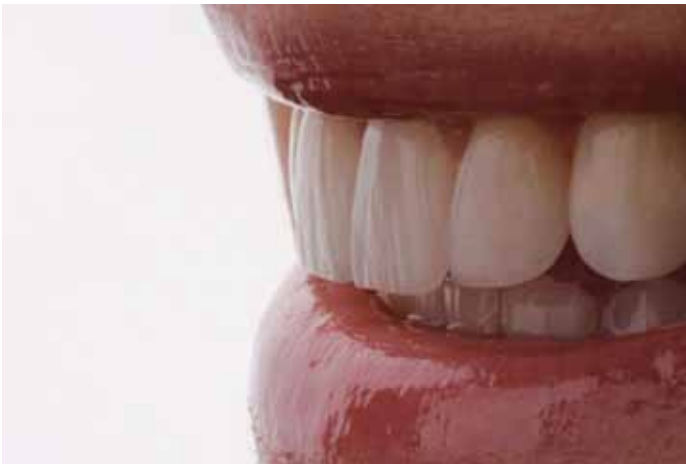

Figure 25: The completed restorations, showing natural translucency and texture.

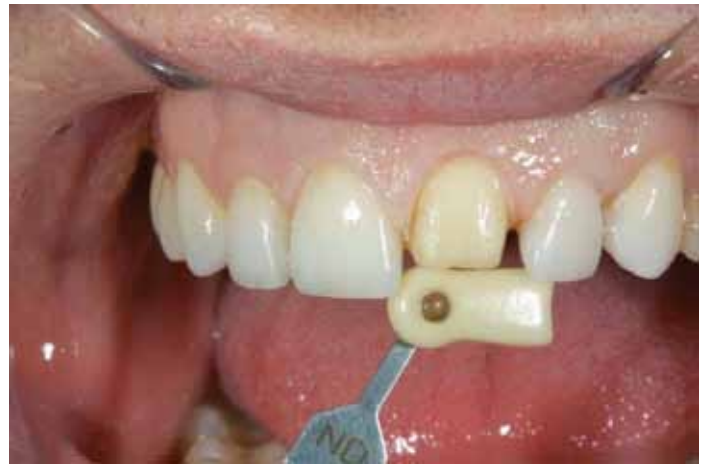

Figure 26: Because the underlying color was more chromatic and dense, the thickness of the ceramic was critical.

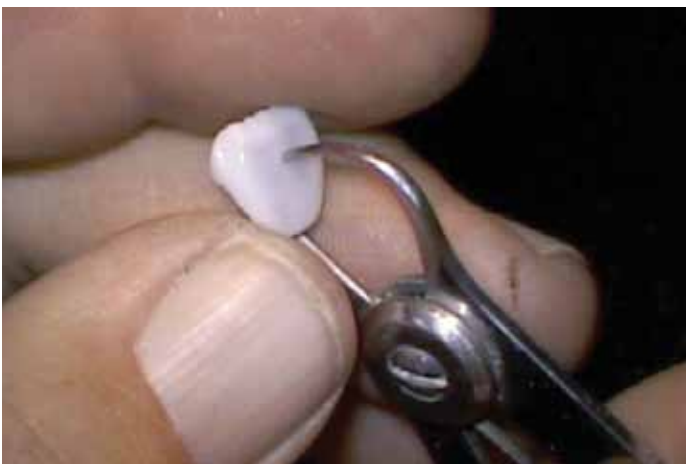


Figure 27: Mid-facial thickness of .2 mm is very translucent in the HTBL1 lithium disilicate. If this is placed over a dark tooth, there will be very little filtering and show-through will occur. 



Figure 28: At a thickness of .2 mm, the HTBL1 material will not provide the masking required to hide the underlying color.

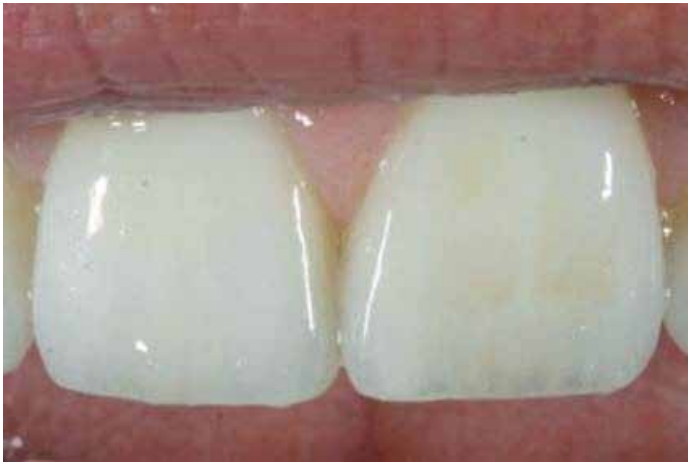


Figure 29: At .2 mm thickness, there is significant undesirable color influence from the underlying tooth. 



Figure 30: When the ceramic is thickened to .5 mm, sufficient masking is accomplished to blend with the rest of the teeth..



Figure 31: Three-tenths of a millimeter makes a very significant difference in the masking ability for the HT ingots.

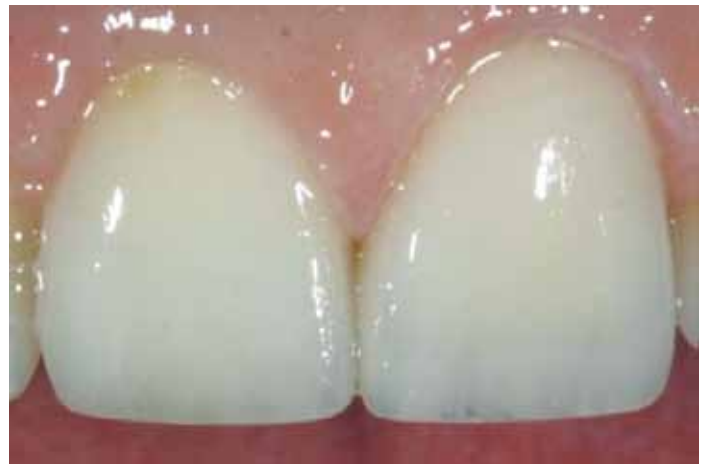

Figure 32: By increasing the restorative thickness to .5 mm, adequate filtering of underlying color was accomplished. (Figures 28-32: Dentistry by Dr. Trinkner.)

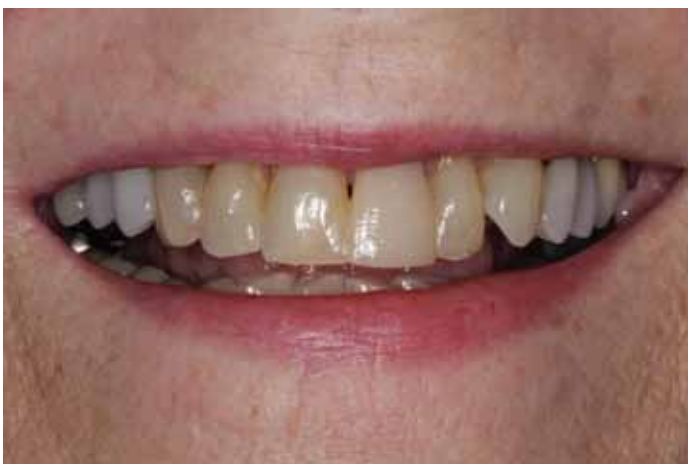

Figure 33: The patient presented with severely darkened central incisors, cuspids, and bicuspids.

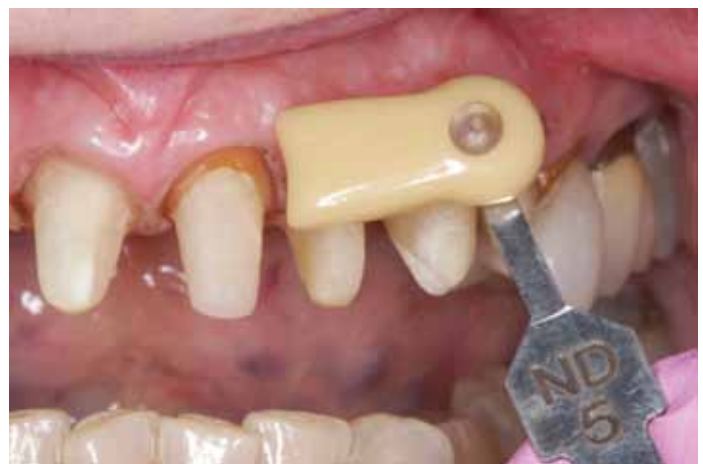

Figure 34: A shade guide was used to communicate color of the prepared teeth to the ceramist. Color of preparations was considered to determine how much material would be needed to filter the underlying color.

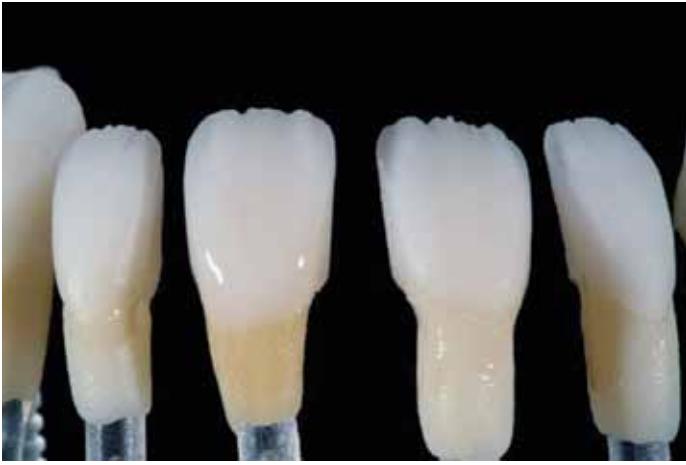

Figure 35: The restorations were contoured and stained where necessary.

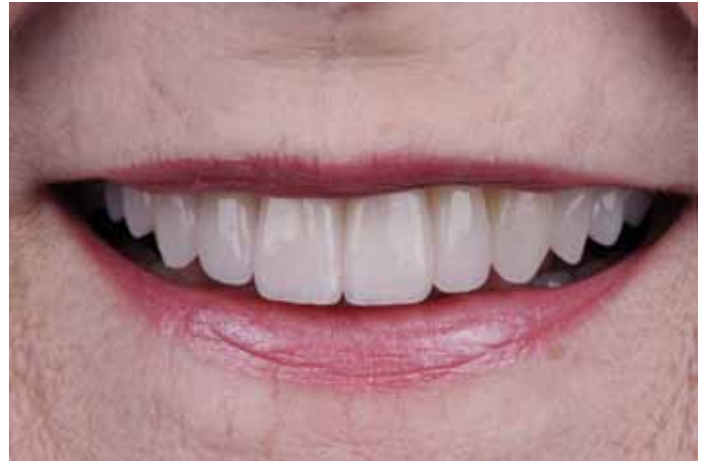

Figure 36: Lithium disilicate in shade HTBL4 was used on teeth ##7-10, while HTB1 was used on the cuspids and bicuspids. Increased thickness covered the underlying color.



Figure 37: Full-facial smile view of the patient after she received her lithium disilicate restorations.

(Figures 33-37: Dentistry by Dr. Shull.)

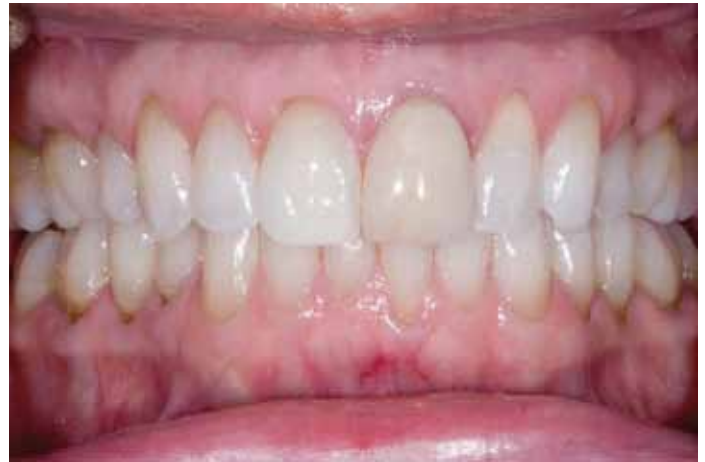

Figure 38: Preoperative condition shows a variety of color, and #9 is dark.

Through extensive case planning and by using the correct diagnostic tools, restorative work can be completed in the most conservative and predictable manner.

underlying dentition was greatly reduced (Figs 28-32).

Darker Underlying Tooth Structure/More Color Change Desired

When existing tooth color is darker and greater color change is desired, thicker enamel-like ceramic layers are required to achieve the shade change. By allowing room for thicker ceramic layers, more filtering of underlying color can be accomplished with the same materials used in the previous case, but slightly more tooth reduction is needed (Figs 33-37).

Evaluating provisional restorations can help detect areas where undesirable color effects from underlying teeth are present. If the provisionals are fabricated prior to taking final impressions, additional preparation in these areas can resolve this issue before esthetic compromises occur.

If the shade of underlying tooth structure is darker and discolored, it may be necessary to remove more tooth structure and use both dentin and enamel ceramics. However, introducing more dentin-like material increases the need to layer powdered enamel ceramics to develop depth and translucency (Figs 38-43).

Individual Discolored Teeth

Cases involving one or two drastically discolored teeth amongst nicely colored teeth can be treated using a combination of strategies. For example, when a patient displays predominantly nice tooth color, with the exception of one discolored lateral (e.g., #10), relatively thin feldspathic veneers may be fabricated on refractory dies and a thin layer of opacified ceramic applied to mask this discoloration (Figs 44-49).

In another case, involving a patient who presented with very dark laterals (Figs 50 & 51), thin gold copings were fabricated for the laterals. The copings were built up with opaque dentin to match the surrounding pleasing tooth color and provide equal restorative room for the adjacent preparations (Figs 52-54). All teeth were then restored with pressed ceramic (IPS Empress) restorations, with the opaqued copings providing the same underlying color effects as the ad-

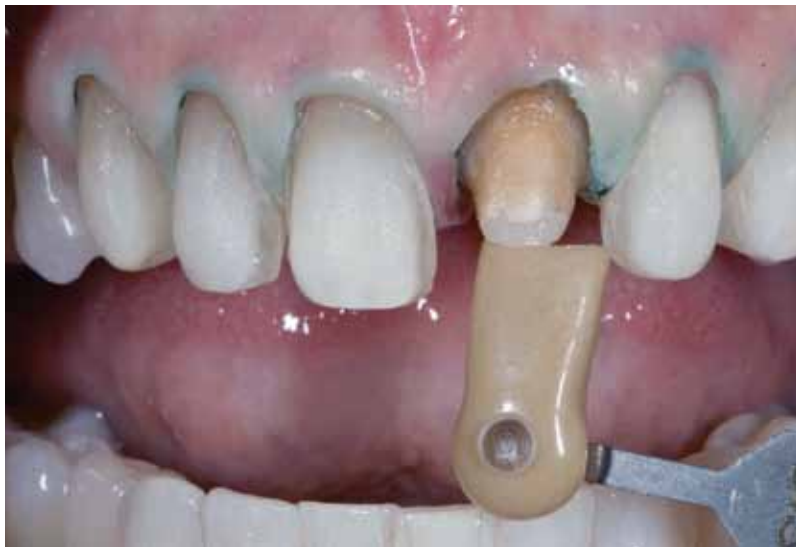

Figure 39: Removal of the previous restoration reveals a very dark preparation on #9. Preparation depth was increased dramatically to provide a thicker ceramic layer to filter the undesirable color. Anticipating the need for more opaque ceramic, all veneers were prepared slightly more aggressively.

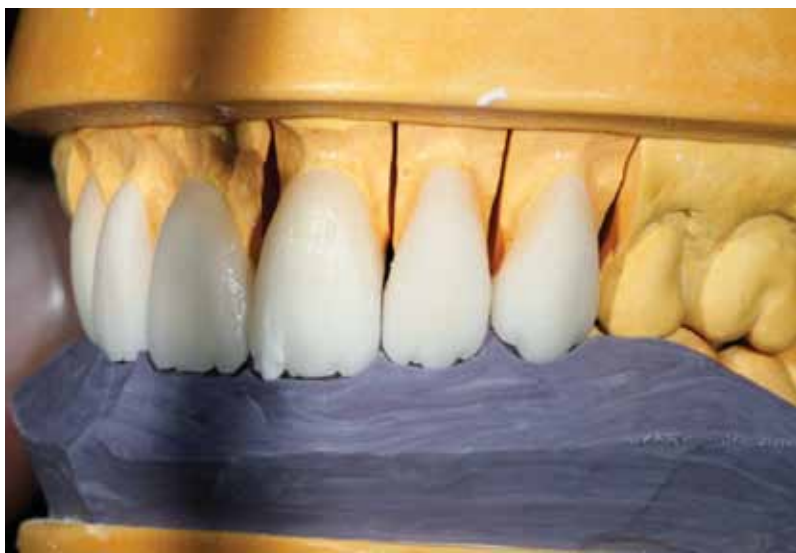

Figure 40: Low-translucency lithium disilicate was selected based on its masking ability. The volume of pressed material is maximized for its 400 MPa strength, while allowing room for a thin layer of enamel to reestablish the appearance of depth and vitality.

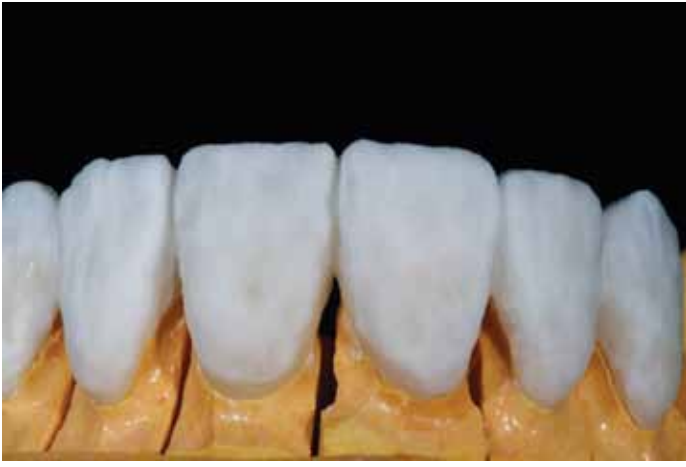

Figure 41: All visible surfaces must be layered with enamel when using a more dense pressable material like the LT ingots.



Figure 42: Portrait of final results.

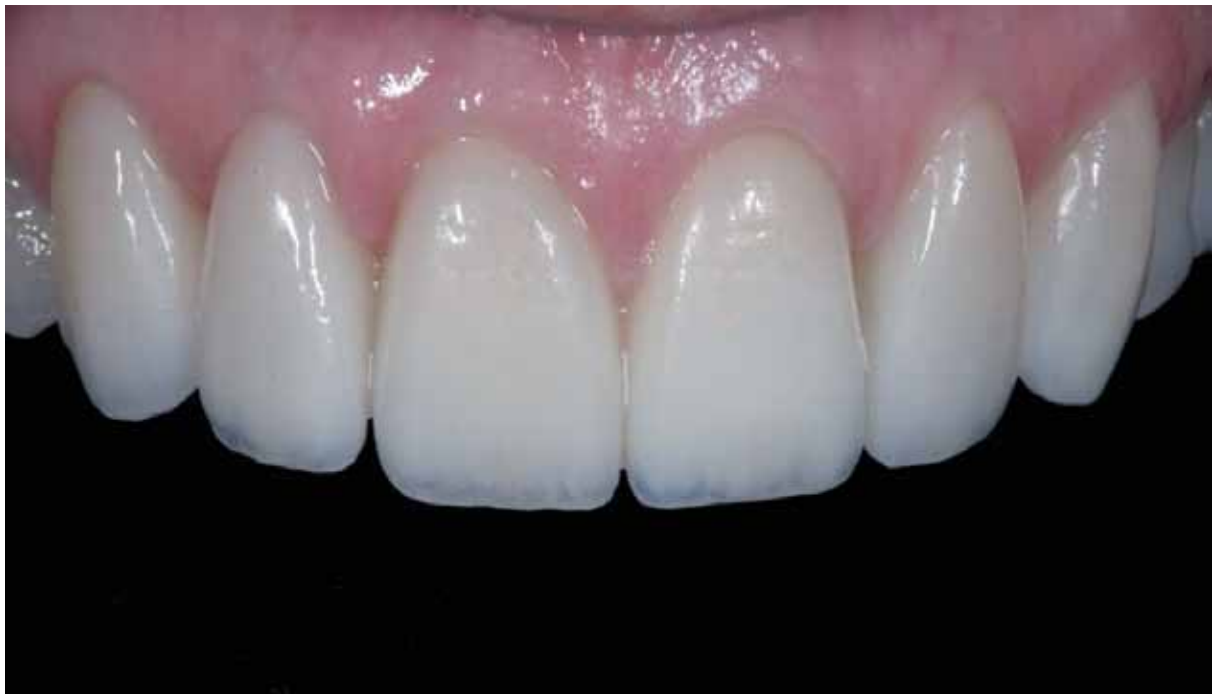

Figure 43: Postoperative view showing the masking with a denser ceramic and layering with enamel ceramics. This approach was appropriate based on the patient's preexisting condition and resulted in great esthetics. However, the removal of more tooth structure to allow room for layering was required. Preparations were still relatively conservative on all teeth except #9.

(Figures 38-43: Dentistry by Dr. Fondriest.)

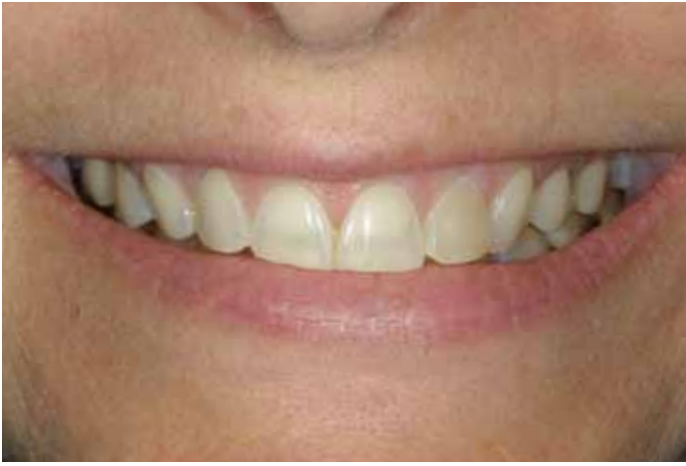

Figure 44: Preoperative view showing worn dentition and discoloration of #10.

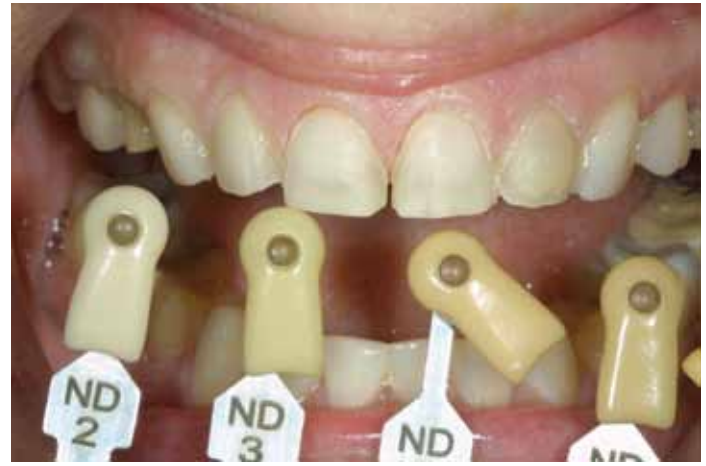

Figure 45: The prepared teeth showed sufficient enamel coverage, with the exception of #5 and #10, which required an extra filtering layer.



Figure 46: The appropriate color of masking ceramic for #10 was chosen to filter the dark underlying tooth structure.

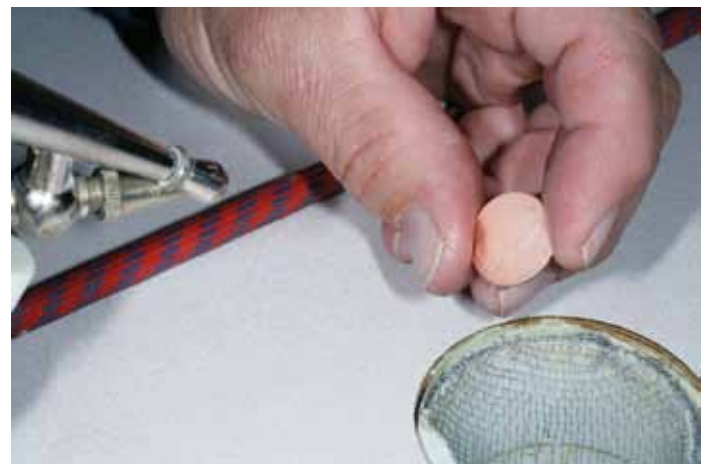

Figure 47: The ceramic was first placed on a penny to determine the required thickness.

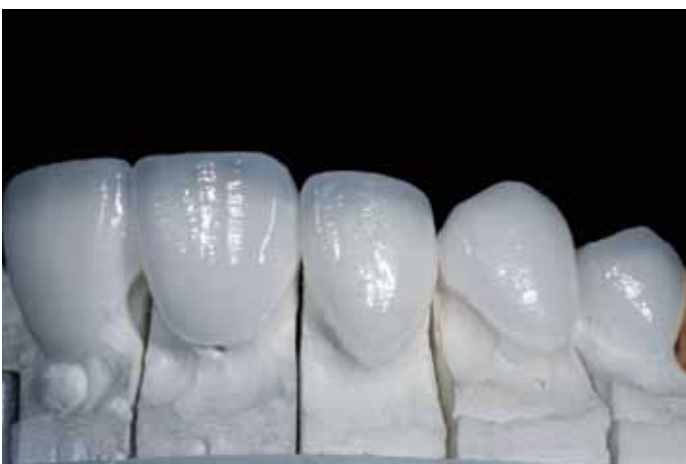

Figure 48: View of the restorations on the refractory die, showing the masking ability of the selected ceramic shade.

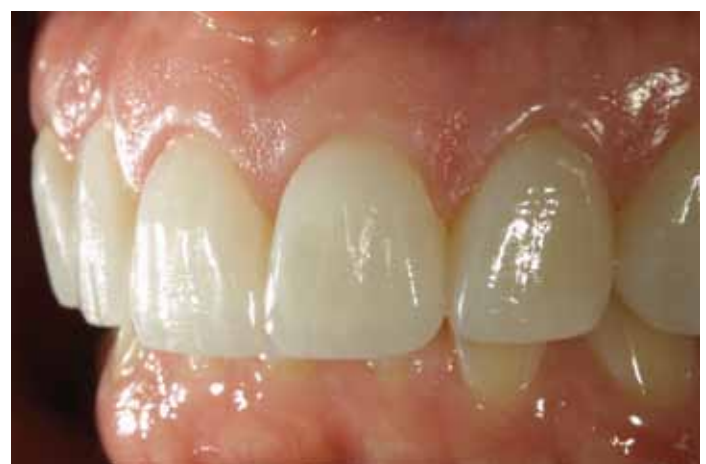

Figure 49: The completed feldspathic veneers on the conservative preparations. Note that the masking layer filtered the underlying color of #5 and #10.

(Figures 44-49: Dentistry by Dr. Trinkner.)

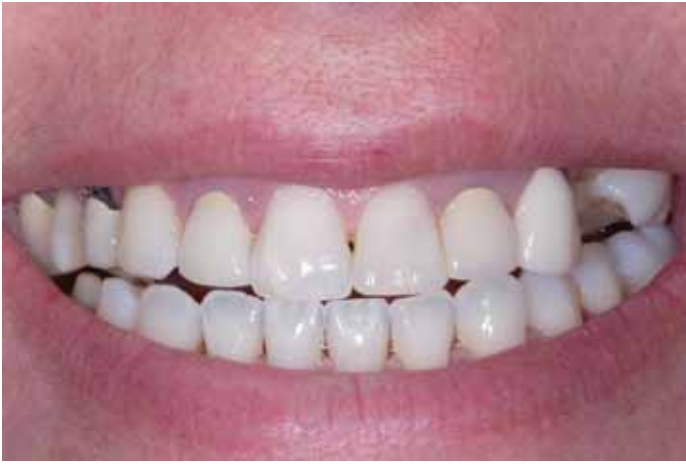

Figure 50: Preoperative view of unesthetic PFM restorations and other concerns.

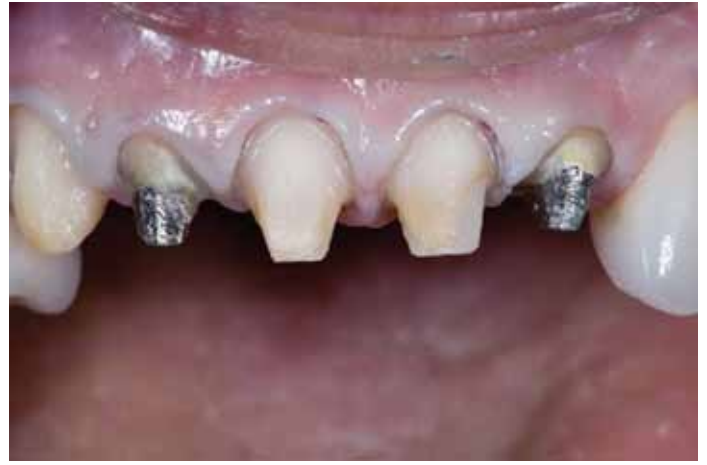

Figure 51: Removal of the old crowns revealed metal posts and cores in the lateral incisors.

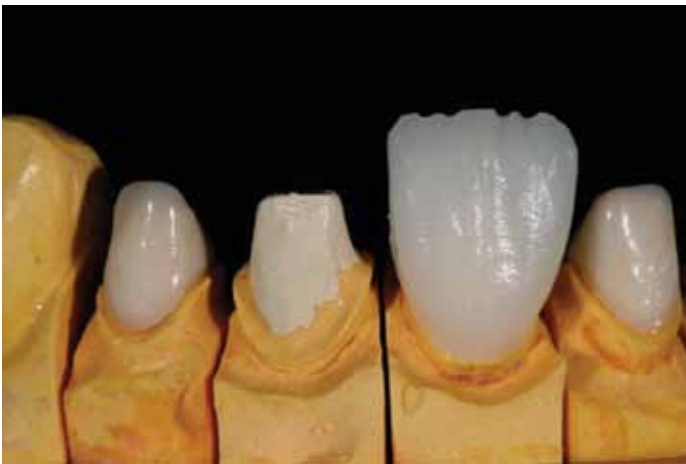


Figure 52: Gold copings were built up with porcelain margins and opaqueous dentin to match the surrounding dentition, and the surfaces were etched to allow for proper bonding.

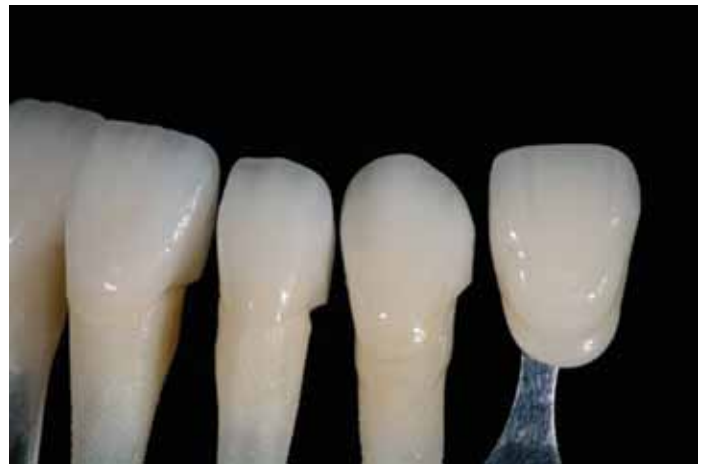

Figure 53: Shading of the laterals with the copings and the leucite-reinforced restorations was confirmed to match the adjacent leucite-reinforced crowns.

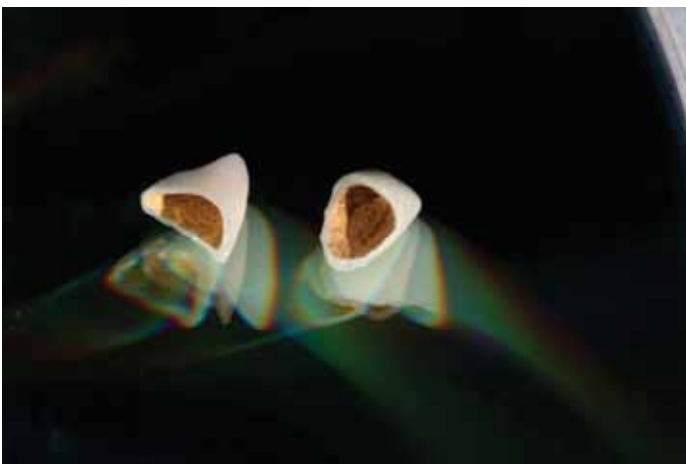


Figure 54: IPS Empress restorations were fabricated to fit over the copings and for all other prepared teeth.

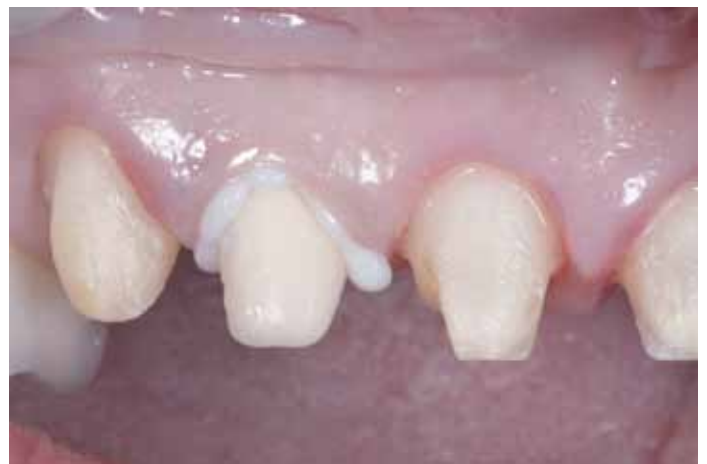

Figure 55: The copings were seated on the preparations. Note the copings were made to match the color and size of the other preparations, thus supplying the same color influence on the overlaid restorations.

adjacent natural teeth (Figs 55 & 56). This approach also can be successful when a zirconia core material is used.

Monolithic Versus Bi-Layered Restoration: Conservative and Esthetic Options

As previously discussed, lithium disilicate ceramic materials enable creative layering strategies, but their physical and optical properties must be understood to maximize their potential. Lithium disilicate exhibits high strength (400 MPa) and variable translucency that is similar and sometimes superior to leucite-reinforced ceramics. The powdered layering ceramics used with this and all other ceramic systems exhibit flexural strengths of ± 90 MPa. As a result, areas where layered ceramics are applied (whether all-ceramic restorations or porcelain-fused-to-metal [PFM]) are more vulnerable to chipping from masticatory forces.²⁹⁻³¹ Although this type of fracture occurs infrequently, they do happen enough to make strategies that eliminate their likelihood desirable.

Such strategies include limiting the use of layering ceramics to specific areas where the highly visible special effects they create are desirable, as well as using more translucent versions of the lithium disilicate material that require little or no layering ceramic for replication of natural dentition.²⁹⁻³¹ Because lithium disilicate is available in multiple opacities, the need for layering ceramic often can be entirely eliminated (Figs 57-59).

Eliminating the need for layering ceramic also lends itself to modern dentistry's conservative approaches to treatment, since many cases now can be restored with very thin enamel replacement restorations that require only incisal micro-layering of the facial surface of the incisors to achieve an esthetic result. The more traditional layering techniques should be used only when covering dark tooth structure in order to create the depth and vitality required over the more opaque core materials used to block the underlying color. In such cases, the higher risk of cohesive chipping of the layering material is worth the reward of achieving an acceptable level of esthetics.³²

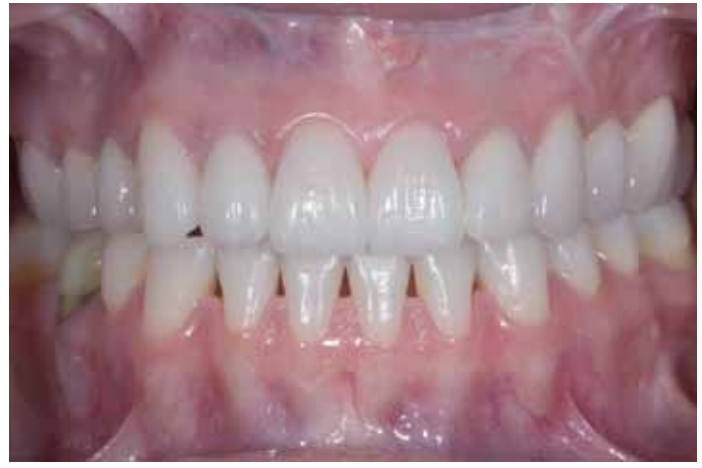

Figure 56: Retracted smile view of the completed restorations. (Dentistry by Dr. Fondriest.)

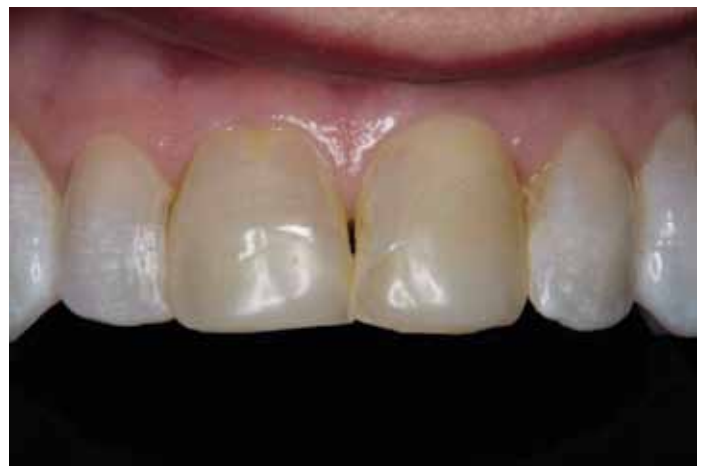

Figure 57: Preoperative view of the darkened central incisors.

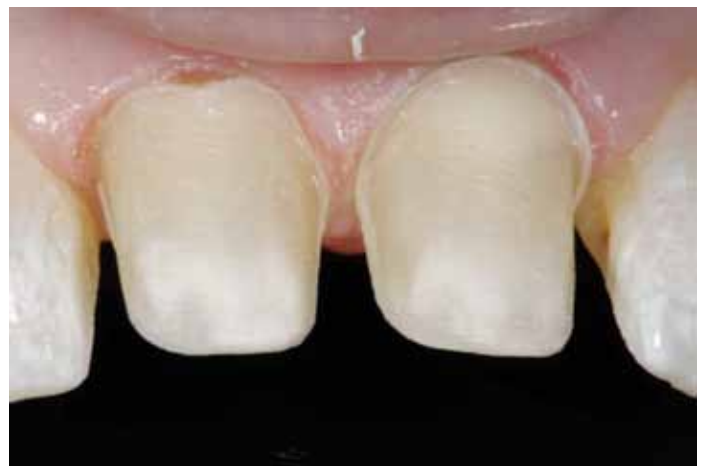

Figure 58: Preparations before placement of monolithic lithium disilicate restorations.

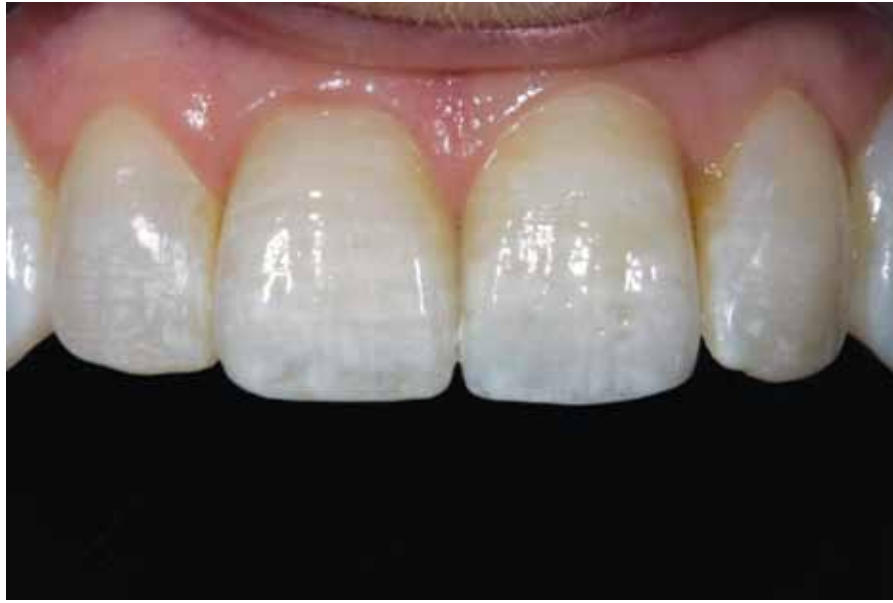

Figure 59: Completed stained and glazed monolithic lithium disilicate restorations.

Although monolithic restorations, like those milled or pressed from lithium disilicate, are much stronger and less likely to chip, the success rates are still very good for fully layered ceramic restorations.³³

Conclusion

Creating harmony between a patient's restorations and facial features requires a multidisciplinary approach, including orthodontically correct dentition that demonstrates pleasing colors, shapes, and arrangements.^{6,7} Through extensive case planning and by using the correct diagnostic tools, restorative work can be completed in the most conservative and predictable manner.^{6,7} When combined with a comprehensive treatment plan, dentists and technicians can provide their patients with esthetically pleasing and fully functioning restorative results.¹¹⁻¹³

References

1. Keenan L. Providing oral health care across cultures. *J Dent Hyg.* 2009;83(4):180-1. Epub 2009 Nov 2.
2. Waldman HB. Dental care needs and services for children: England, Wales, and United States compared. *ASDC J Dent Child.* 1983;50(1):48-54.
3. Ahmad I. Risk management in clinical practice. part 5. ethical considerations for dental enhancement procedures. *Br Dent J.* 2010;209(5):207-14.
4. Petersen PE. Global policy for improvement of oral health in the 21st century—implications to oral health research of World Health Assembly 2007, World Health Organization. *Community Dent Oral Epidemiol.* 2009;37(1):1-8. Epub 2008 Nov 12.
5. Tomar SL, Cohen LK. Attributes of an ideal oral health care system. *J Public Health Dent.* 2010;70(Suppl 1):S6-14.
6. Paiva JB, Attizzani ME, Miasiro Junior H, Rino Neto J. Facial harmony in orthodontic diagnosis and planning. *Braz Oral Res.* 2010;24(1):52-7.
7. Keim RG. Seeking facial harmony. *J Clin Orthod.* 2007;41(2):55-6.
8. LeSage B. Revisiting the design of minimal and no-preparation veneers: a step-by-step technique. *J Calif Dent Assoc.* 2010;38(8):561-9.
9. Donitza A. Creating the perfect smile: prosthetic considerations and procedures for optimal dentofacial esthetics. *J Calif Dent Assoc.* 2008;36(5):355-40, 342.
10. Goldstep F. The intuitive guide to shade selection. *Dent Today.* 2001;20(9):72-5.
11. Okuda WH. Creating facial harmony with cosmetic dentistry. *Curr Opin Cosmet Dent.* 1997;4:69-75.
12. Panossian AJ, Block MS. Evaluation of the smile: facial and dental considerations. *J Oral Maxillofac Surg.* 2010;68(3):547-54.
13. Matthews TG. The anatomy of a smile. *J Prosthet Dent.* 1978;39(2):128-34.
14. Garcia LT, Bohnenkamp DH. The use of diagnostic wax-ups in treatment planning. *Compend Contin Educ Dent.* 2003;24(3):210-2, 214.

15. Dickerson WG. Using diagnostic wax-ups in aesthetic cases. *Dent Today*. 2001;20(3):96-8.
16. Magne P, Douglas WH. Additive contour of porcelain veneers: a key element in enamel preservation, adhesion, and esthetics for aging dentition. *J Adhes Dent*. 1999;1(1):81-92.
17. Donovan TE, Cho GC. Diagnostic provisional restorations in restorative dentistry: the blueprint for success. *J Can Dent Assoc*. 1999;65(5):272-5.
18. Giordano R. A comparison of all ceramic systems. *J Mass Dent Soc*. 2002;50(4):16-20.
19. McLaren EA, LeSage BP. Feldspathic veneers: what are their indications. *Compend Contin Educ Dent*. 2011 Apr;32(3):44-9.
20. McLaren EA, Cao PT. Smile analysis and esthetic design: "in the zone." *Inside Dent*. 2009;5(7):44-48.
21. Duarte Jr S. Opalescence: the key to natural esthetics. *Quint Dent Technol*. 2007;30:7-20.
22. Sensi LG, Araujo FO, Marson FC, Monteiro Jr S. Reproducing opalescent and counter-opalescent effects with direct resin composites. *Quint Dent Technol*. 2007;30:77-86.
23. Duarte S Jr., Perdigão J, Lopes M. Composite resin restoration: natural aesthetics and dynamics of light. *Pract Proced Aesthet Dent*. 2003;15(9):657-64.
24. Okuda WH. Correction of the darkened anterior tooth: a new clear approach to an old problem. *Gen Dent*. 2007;55(7):632-6.
25. DiMatteo AM. Prep vs no-prep: the evolution of veneers. *Inside Dent*. 2009;5(6):72-9.
26. Friedman MJ. A 15-year review of porcelain veneer failure—a clinician's observations. *Compend Contin Educ Dent*. 1998;19(6):625-38.
27. Tysowsky GW. The science behind lithium disilicate: a metal-free alternative. *Dent Today*. 2009 Mar;28(3):112-2.
28. Fasbinder DJ, Dennison JB, Heys D, Neiva G. A clinical evaluation of chairside lithium disilicate CAD/CAM crowns: a two-year report. *J Am Dent Assoc*. 2010 Jun;141(Suppl 2):10S-4S.
29. Anunmana C, Anusavice KJ, Mecholsky JJ Jr. Interfacial toughness of bilayer dental ceramics based on short-bar, chevron-notch test. *Dent Mater*. 2010;26(2):111-7. Epub 2009 Oct 8.
30. Kim JH, Kim JW, Myoung SW, Pines M, Zhang Y. Damage maps for layered ceramics under simulated mastication. *J Dent Res*. 2008;87(7):671-5.
31. Taskonak B, Mecholsky JJ Jr., Anusavice KJ. Residual stresses in bilayer dental ceramics. *Biomaterials*. 2005;26(16):3235-41.
32. Aboushelib MN, Dozic A, Liem JK. Influence of framework color and layering technique on the final color of zirconia veneered restorations. *Quintessence Int*. 2010 May;41(5):e84-9.
33. Griffiths CE, Bailey JR, Jarad FD, Youngson CC. An investigation into the most effective method of treating stained teeth: an in vitro study. *J Dent*. 2008;36(1):54-62. Epub 2007 Dec 3.

jCD



Mr. Roberts has been an Accredited Member of the AACD since 1996. He is on the visiting faculty at the L.D. Pankey Institute and is the owner of CMR Dental Lab in Idaho Falls, Idaho.



Dr. Shull is on the visiting faculty for the Palmetto Richland Hospital General Practice Program, Medical College of Georgia, School of Dentistry and L.D. Pankey Institute. He maintains a private practice in Lexington, South Carolina.



Dr. Fondriest is a visiting assistant professor at the University of Florida. He is on the visiting faculty at the L.D. Pankey Institute and maintains a private practice in Lake Forest, Illinois.



Dr. Trinkner is an AACD Accredited Member. He is on the visiting faculty at the L.D. Pankey Institute and maintains a private practice in Columbia, South Carolina.

Disclosures: The authors did not report any disclosures.

AACD Self-Instruction Continuing Education Information



General Information

This continuing education (CE) self-instruction program has been developed by the American Academy of Cosmetic Dentistry (AACD) and an advisory committee of the *Journal of Cosmetic Dentistry*.

Eligibility and Cost

The exam is free of charge and is intended for and available to AACD members only. It is the responsibility of each participant to contact his or her state board for its requirements regarding acceptance of CE credits. The AACD designates this activity for 3 continuing education credits.

Testing and CE

The self-instruction exam comprises 10 multiple-choice questions. To receive course credit, AACD members must complete and submit the exam and answer at least 70% of the questions correctly. Participants will receive tests results immediately after taking the examination online and can only take each exam once. The exam is scored automatically by the AACD's online testing component. The deadline for completed exams is one calendar year from the publication date of the issue in which the exam appeared. The exam is available online at www.aacd.com. A current web browser is necessary to complete the exam; no special software is needed.

Note: Although the AACD grants these CE credits, it is up to the receiving governing body to determine the amount of CE credits they will accept and grant to participants.

Verification of Participation (VOP)

VOP will be sent to AACD members via their MyAACD account upon pass completion. Log onto www.aacd.com to sign into your MyAACD account.

For members of the Academy of General Dentistry (AGD): The AACD will send the AGD proof of your credits earned on a monthly basis. To do this, AACD must have your AGD member number on file. Be sure to update your AGD member number in your AACD member profile on MyAACD.com.

All participants are responsible for sending proof of earned CE credits to their state dental board or agency for licensure purposes.

Disclaimer

AACD's self-instruction exams may not provide enough comprehensive information for participants to implement into practice. It is recommended that participants seek additional information as required. The AACD Self-Instruction Program adheres to the guidelines set forth by the American Dental Association Continuing Education Recognition Program (CERP), and the AGD Program Approval for Continuing Education (PACE).

Questions and Feedback

For questions regarding a specific course, information regarding your CE credits, or to give feedback on a CE self-instruction exam, please contact the AACD Executive Office by e-mailing meetings@aacd.com or by calling 800.543.9220 or 608.222.8583.



ADA CERP is a service of the American Dental Association to assist dental professionals in identifying quality providers of continuing dental education. ADA CERP does not approve or endorse individual courses or instructors, nor does it imply acceptance of credit hours by boards of dentistry. AACD designates this activity for 3 continuing education credits. Concerns or complaints about a CE provider may be directed to the provider or to ADA CERP at www.ada.org/goto/cerp.

(CE) Exercise No. JCD04

Dental Materials (Basic Science)

AGD Subject Code: 017

The 10 multiple-choice questions for this Continuing Education (CE) self-instruction exam are based on the article, "Colors, Shapes, and Arrangements for Comprehensive Results," by Matthew Roberts, CDT, AAACD, Franklin Shull, DMD, James F. Fondriest, DDS, and Thomas F. Trinkner, DDS, AAACD. This article appears on pages 110-127.

The examination is free of charge and available to AACD members only. AACD members must log onto www.aacd.com to take the exam. **Note that only Questions 1 through 5 appear here in the printed version of the jCD; they are for readers' information only.** The complete, official self-instruction exam is available online only—completed exams submitted any other way will not be accepted or processed. A current web browser is necessary to complete the exam; no special software is needed. The AACD is a recognized credit provider for the Academy of General Dentistry, American Dental Association, and National Association of Dental Laboratories. For any questions regarding this self-instruction exam, call the AACD at 800.543.9220 or 608.222.9540.

1. For a smile to be attractive, the

- axial inclinations should be vertical with the midline.
- incisal plane must align with the facial vertical axis.
- incisal smile line must align with the gingival architecture.
- axial inclinations should incline slightly toward the midline.

2. Much of the color seen in bonded all-ceramic restorations comes from the

- bonding resin.
- underlying tooth structure.
- opaque porcelain layer.
- light reflected from the enamel layer of the restoration.

3. The greater the color change required in a smile makeover, the

- thicker the ceramics must be while the preparation depth remains the same.
- deeper the preparations must be while the ceramic thickness remains uniform.
- thinner the enamel ceramics must be while deeper preparation is required.
- deeper the preparations in areas needing reduction must be to provide room for layering.

4. For a smile to be attractive, the incisal

- plane must align with the facial vertical axis.
- smile line must harmonize with the shape of the lower lip.
- plane must align with the vertical axis of the mandibular dentition.
- smile line must harmonize with the shape of the upper lip.

5. If the preexisting tooth color approximates the final restorative color desired,

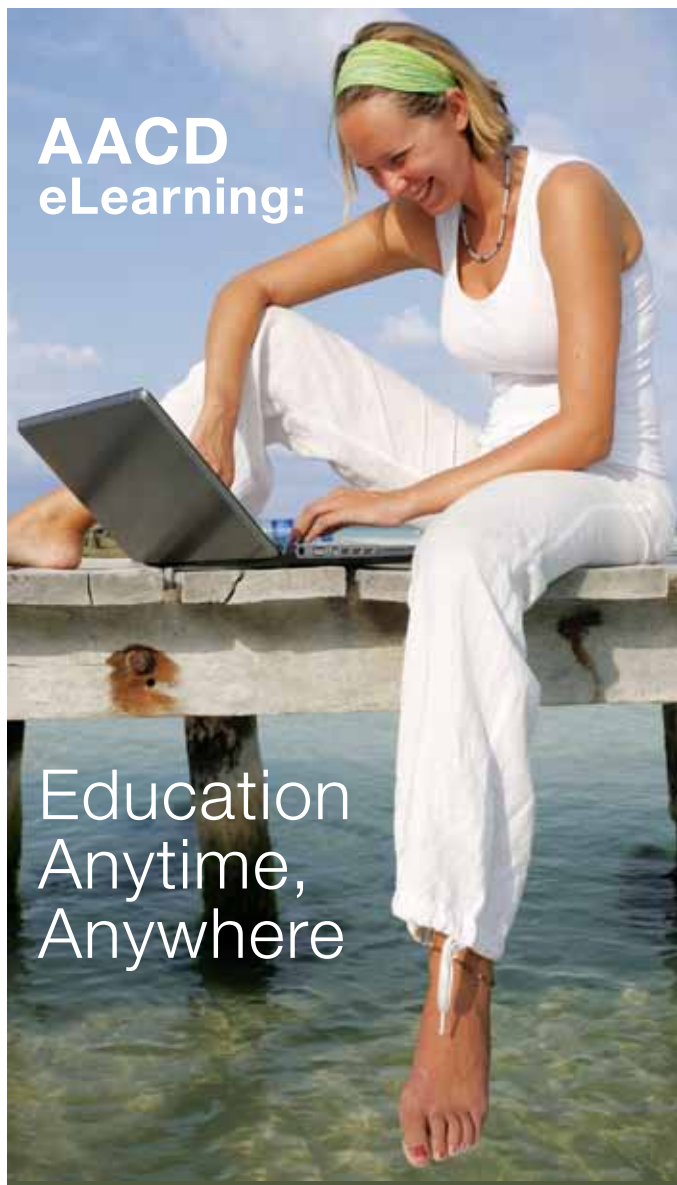
- thinner and more translucent ceramics may be used, reducing the need for restorative thickness.
- the restorations still should block out the color to allow for uniform appearance in body shades.
- the reduction preparations should be uniform and at least 1.0 mm in depth.
- opaque ceramics should be combined in sequential layers to block the color out.

To see and take the complete exam, log onto www.aacd.com.

Advertiser Index

3M ESPE	www.3MESPE.com	45, 77
AACD	www.aacd.com	130
Aurum Ceramic Dental Laboratories	www.aurumgroup.com	25
Brad Jones, Smiles Inc.	www.whoisbradjones.com	13
Dr. Bob Khanna Training Institute	www.drbobkhanna.com	32
Cosmedent	www.cosmedent.com	61
Envision A Smile	www.EnvisionASmile.com	91
Experience Dental Studio	www.experiencedentalstudio.com	85
Heraeus Kulzer	www.heraeusdentalusa.com	7, 97
Ivoclar Vivadent	www.ivoclarvivadent.com	IFC, IBC
Knight Dental Group	www.knightdentalgroup.com	33
LK Dental Studio	www.lkdentalstudio.com	9
MAC, by Dental Technologies Inc.	www.macveneers.com	BC
Micerium S.p.A.	www.micerium.it	53
NewBeauty Magazine	www.newbeauty.com	109
Patient News	www.patientnews.com	5
Rosemont Media	www.rosemontmedia.com	105
Springstone Patient Financing	www.springstoneplan.com	11
Westlund Dental Studio	www.westlunddental.com	65

We Want to Hear from You! AACD is dedicated to making *JCD* a “must-read” for you! We want to know what you like, don’t like, and everything in between. Send your ideas and feedback to publications@aacd.com.



**AACD
eLearning:**

**Education
Anytime,
Anywhere**

We know you’re busy. That’s why we created AACD eLearning—so you can learn online at your convenience through education courses at DentalXP.com and HDiQDental.com. No advance course registration is required—just log in and start learning. Visit: www.aacd.com/learn

You can also learn more about cosmetic dentistry through the AACD Webinar Series, which focuses on pearls from the 27th Annual Scientific Session, at: www.aacd.com/webinarseries

