

# jCD

vol. 31 issue 1

Journal of Cosmetic Dentistry

## Fighting Mediocrity

Mr. Pinhas Adar  
Dr. Cheryl A. Pearson

Facing Challenges—  
jCD Reviewers Share  
Timely Techniques

SPRING 2015

**AACD** American Academy  
of Cosmetic Dentistry

INTRODUCING

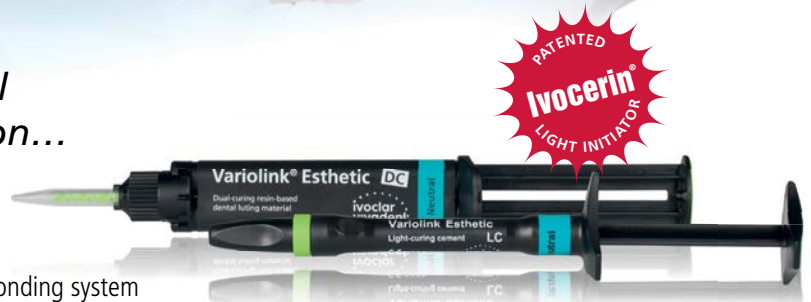# Variolink<sup>®</sup> Esthetic

Adhesive Cementation System

**“Esthetic Cementation  
made Simple!”**

*The adhesive cement for exceptional  
esthetics and user-friendly application...*

- Exceptional handling and easy clean-up
- Amine-free for long-term shade stability
- Reliable bond strength results with a universal, easy to use bonding system



Try Variolink Esthetic today for **FREE!**  
Visit [www.ivoclarvivadent.us/variolink](http://www.ivoclarvivadent.us/variolink)

100% CUSTOMER SATISFACTION  
GUARANTEED!



[ivoclarvivadent.com](http://www.ivoclarvivadent.com)

Call us toll free at 1-800-533-6825 in the U.S., 1-800-263-8182 in Canada.  
© 2015 Ivoclar Vivadent, Inc. Ivoclar Vivadent and Variolink are registered trademarks of Ivoclar Vivadent, Inc.

ivoclar  
vivadent<sup>®</sup>  
passion vision innovation



**EDITOR-IN-CHIEF** Edward Lowe, DMD, AAACD  
Vancouver, BC, Canada, edwardl@aacd.com

**EXECUTIVE DIRECTOR** Barbara J. Kachelski, MBA, CAE, barbk@aacd.com

**MANAGING EDITOR** Tracy Skenandore, tracys@aacd.com

**EDITORIAL ASSISTANT** Denise Sheriff, denises@aacd.com

**ART DIRECTOR** Lynnette Rogers, lynnetter@aacd.com

**GRAPHIC DESIGNER** Sherry Misener, sherrym@aacd.com

**EDITORIAL CONSULTANT** Juliette Kurtz, publications@aacd.com

**MANUSCRIPT DEVELOPMENT LIAISON** Allison DiMatteo, MPS, allison@cremedellacreme.org

**CHIEF MARKETING OFFICER** Michael DiFrisco, michaeld@aacd.com

**ADVERTISING AND SPONSORSHIP DIRECTOR OF STRATEGIC PARTNERSHIPS** Jeff Roach, jeffr@aacd.com

**CONTRIBUTING EDITORS** Julie M. Gillis, DDS, AAACD, Grand Junction, CO  
James H. Peyton, DDS, FAACD, Bakersfield, CA  
J.A. Reynolds, DDS, AAACD, Franklin, TN  
Gregory B. Wright, DDS, FAACD, Southlake, TX

#### EDITORIAL MISSION

The mission of the *Journal of Cosmetic Dentistry* is to educate AACD members, as well as other professionals in the field, on the art and science of cosmetic dentistry. We will endeavor to do this by publishing well-researched, peer-reviewed articles accompanied by high-quality, comprehensive clinical imagery. The objective is to enhance readers' knowledge and skills while showcasing the latest cosmetic techniques and procedures. The *Journal of Cosmetic Dentistry* will strive to help readers become better clinicians, so they can offer their patients the best—and most responsible—treatment possible.

#### ADVERTISING POLICY

All advertising appearing in the *Journal of Cosmetic Dentistry (jcd)* is approved by the editorial team. Advertisements are not endorsed by the *jcd* or AACD.

#### AACD OFFICE

402 West Wilson Street, Madison, WI 53703  
800.543.9220 • 608.222.8583  
fax 608.222.9540 • info@aacd.com • www.aacd.com

---

Advertising: 800.543.9220 • 608.222.8583 or jeffr@aacd.com  
Editorial: 800.543.9220 • 608.222.8583 or publications@aacd.com

---

#### EDITORIAL REVIEW BOARD

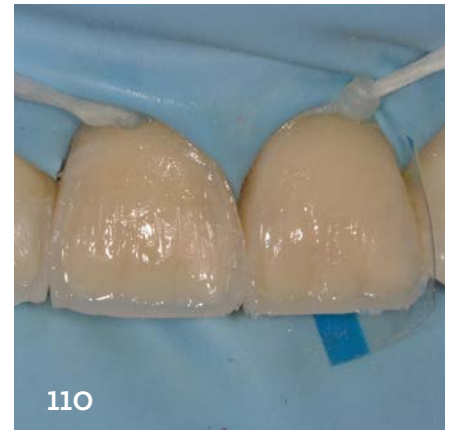
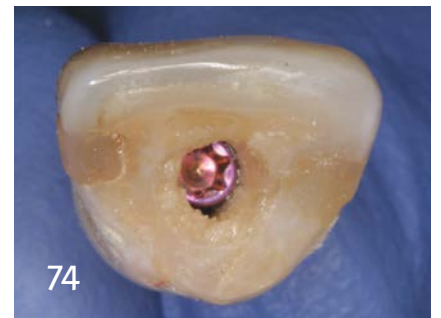
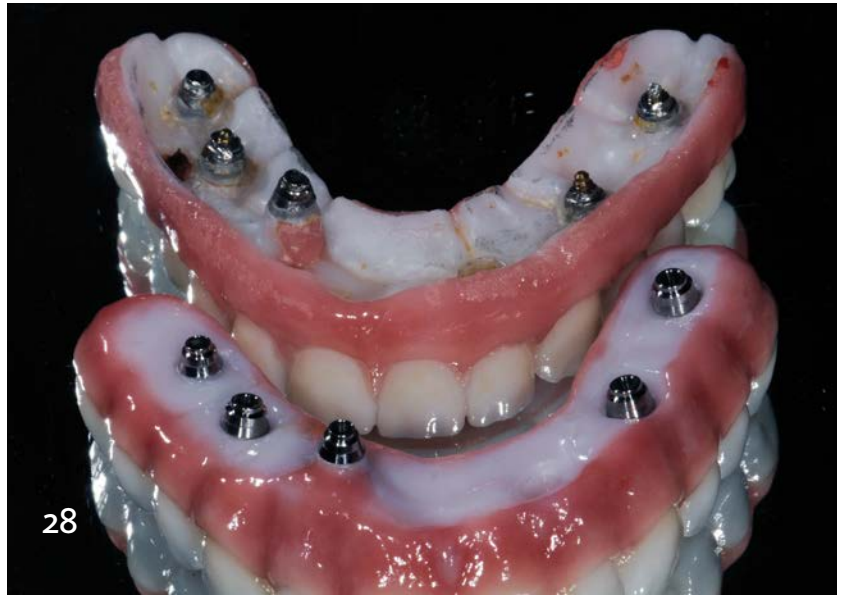Pinhas Adar, MDT, CDT, Atlanta, GA  
Irfan Ahmad, BDS, Middlesex, United Kingdom  
Gary Alex, DMD, AAACD, Huntington, NY  
Edward P. Allen, DDS, PhD, Dallas, TX  
Chad J. Anderson, DMD, MS, Fresno, CA  
Elizabeth M. Bakeman, DDS, FAACD, Grand Rapids, MI  
Lee Ann Brady, DMD, Glendale, AZ  
Ricardo M. Carvalho, DDS, PhD, Vancouver, BC, Canada  
Christian Coachman, DDS, CDT, São Paulo, Brazil  
John C. Cranham, DDS, Chesapeake, VA  
Michael W. Davis, DDS, Santa Fe, NM  
Gerald E. Denehy, DDS, Iowa City, IA  
Newton Fahl Jr., DDS, MS, Curitiba-PR, Brazil  
Jonathan L. Ferencz, DDS, FACP, New York, NY  
Scott W. Finlay, DDS, FAACD, Arnold, MD  
Hugh D. Flax, DDS, AAACD, Atlanta, GA  
David A. Garber, DMD, Atlanta, GA  
Ronald E. Goldstein, DDS, FACD, FICD, Atlanta, GA  
Steve D. Hoofard, CDT, AAACD, Hermiston, OR  
Kenneth Hovden, DDS, AAACD, Daly City, CA  
Nelson Y. Howard, DDS, AAACD, San Marcos, CA  
Ronald D. Jackson, DDS, FAACD, Middleburg, VA  
Sang K. Jun, CDT, Monterey, CA  
Michael J. Koczarski, DDS, AAACD Woodinville, WA  
John C. Kois, DMD, MSD, Seattle, WA  
Gerard Kugel, DMD, MS, PhD, Boston, MA  
Cobi J. Landsberg, DMD, Tel Aviv, Israel  
Ryan Langer, AAACD, Eagle, ID  
David A. Little, DDS, San Antonio, TX  
Robert A. Lowe, DDS, Charlotte, NC  
Robert C. Margeas, DDS, Des Moines, IA  
Frank J. Milnar, DDS, AAACD, St. Paul, MN  
Ricardo Mitrani, DDS, MSD, Mexico City, Mexico  
Carlos A. Munoz, DDS, MSD, Buffalo, NY  
Thomas W. Nabors III, DDS, AAACD, Nashville, TN  
W. Peter Nordland, DMD, MS, La Jolla, CA  
Aikaterini G. Papathanasiou, DDS, Boston, MA  
Gary M. Radz, DDS, Denver, CO  
Christopher D. Ramsey, DMD, AAACD, Jupiter, FL  
Nelson A. Rego, CDT, AAACD, Santa Fe Springs, CA  
Dwight G. Rickert, CDT, AAACD, Indianapolis, IN  
Robert G. Ritter, DMD, Jupiter, FL  
Matthew R. Roberts, CDT, AAACD, Idaho Falls, ID  
Henry Salama, DMD, Atlanta, GA  
Maurice A. Salama, DMD, Atlanta, GA  
Michael R. Sesemann, DDS, FAACD, Omaha, NE  
Michael Sonick, DMD, Fairfield, CT  
Rhys D. Spoor, DDS, AAACD, Seattle, WA  
Thomas T. Teel, DDS, Fort Wayne, IN  
Thomas F. Trinkner, DDS, AAACD, Columbia, SC  
Eric Van Dooren, DDS, Antwerp, Belgium  
Marcos A. Vargas, DDS, Iowa City, IA  
Nondas Vlachopoulos, CDT, Athens, Greece  
Dennis J. Wells, DDS, AAACD, Brentwood, TN  
Barbara Warner Wojdan, CDT, AAACD, Oldsmar, FL

## Reprints

High-quality reprints with possible customization are available for authors and advertisers. Please contact Hope.robinson@sheridan.com, Content Sales Specialist who will work with you to get the exact reprint you would like for your presentations, lectures, or patient literature.

Features

- 28 Clinical Cover Case  
The Proof is in the Laboratory ✦  
*Pinhas Adar, MDT, CDT, AAACD*  
*Cheryl A. Pearson, DMD, AAACD, FAAID*
- 46 Life-Changing Diastema Closure ✦  
*Aikaterini Papathanasiou, DDS, CAGS, FIADFE, FICD*  
*Charilaos Asikis, DDS, CAGS, FICD*
- 58 Overcoming Surgical and Prosthetic Challenges ✦  
*Cobi Landsberg, DMD*  
*Elie Sawdayee, DMD, CDT*
- 74 Immediate Extraction and Placement of an Implant ✦  
*Robert C. Margeas, DDS*
- 88 Eliminating an Implant Level Impression ✦  
*Nelson Y. Howard, DDS, AAACD*
- 102 The Importance of Keratinized Tissue Around Implants ✦  
*Anastasia Kelekis-Cholakis, DMD, DIP.Perio, FRCD(C)*  
*Reem N. Atout, BDS, DDS, MS, FRCD(C)*
- 110 Clinical Research  
Clinical Performance of Direct and Indirect  
Adhesive Restorations (CE article) ✦  
*Marleen Peumans, PhD, DDS*
- 128 AACD Self-Instruction  
Continuing Education ✦
- 130 Book Review  
High-Strength Ceramics: Interdisciplinary Perspectives ✦



HAVE YOU MOVED? ARE YOU PLANNING TO? LET US KNOW!

Do you have a new address? Please help us to deliver your *Journal of Cosmetic Dentistry (jCD)* in a timely fashion. If you have a new mailing address, contact: [publications@aacd.com](mailto:publications@aacd.com) and let us know where we should deliver your copy of *jCD*. Thank you!



Column

- 8 Editor's Message  
Thank you, *jCD* Reviewers!  
*Edward Lowe, DMD, AAACD*





# Welcome to the more possibilities Club.

## Introducing a new concept in patient financing: More.

- **True No-Interest Plans<sup>1</sup>**—no retroactive interest at the end of the promotional period avoids unwelcome surprises for your patients
- **Extended Plans<sup>2</sup>**—fixed APR as low as 3.99% based on term length and applicant's credit, with financing up to \$50K
- **Expanded Credit Policy**—for more patient approvals than ever before

All so you can **treat more patients.**

Springstone Patient Financing<sup>SM</sup>, known for offering patient-friendly products and excellent customer service, has joined Lending Club, the world's largest online credit marketplace, and is now Lending Club Patient Solutions.

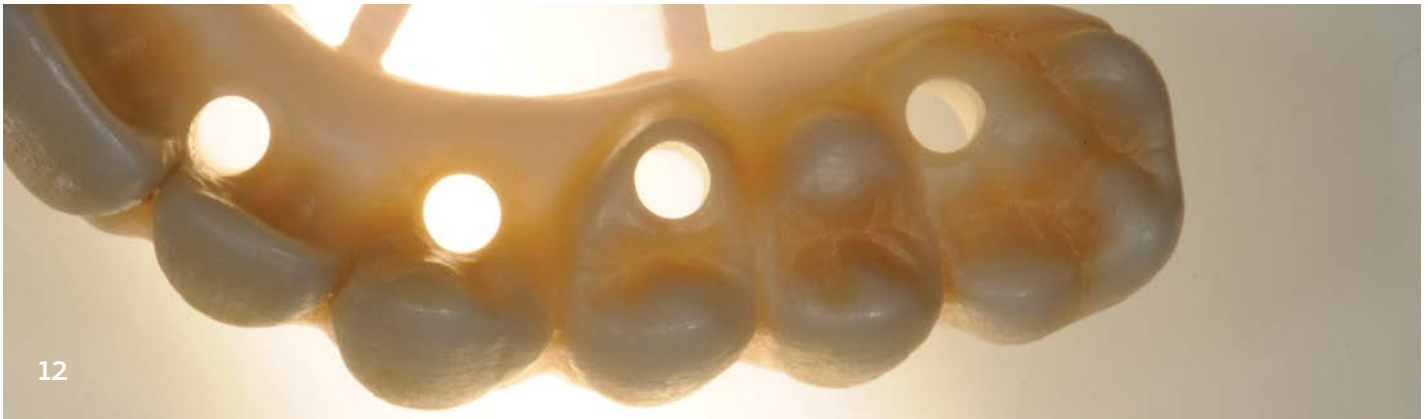To learn more, call 844-DOMORE3 or visit [www.lendingclub.com/providers](http://www.lendingclub.com/providers).



<sup>1</sup>No Interest for 6, 12, 18 or 24 months, after that 22.98% variable APR. Interest will be charged to your account at the standard variable APR of 22.98% (based on the Prime Rate) from the end of the promotional period on the remaining balance if the purchase balance is not paid in full within the promotional period. Minimum monthly payments for this plan during the promotional period will be the greater of: the amount of the purchase divided by the number of months in the promotional period (rounded up to the nearest \$1.00); or \$5. Required minimum purchase of \$499 for the 6-month plan; \$999 for the 12-month plan; \$1,499 for the 18-month plan; \$2,499 for the 24-month plan. Lending Club Patient Solutions Credit Accounts are offered by Comenity Capital Bank who determines qualifications for credit and promotion eligibility. Minimum Interest Charge is \$1.00 per credit plan. Standard variable APR of 22.98%.

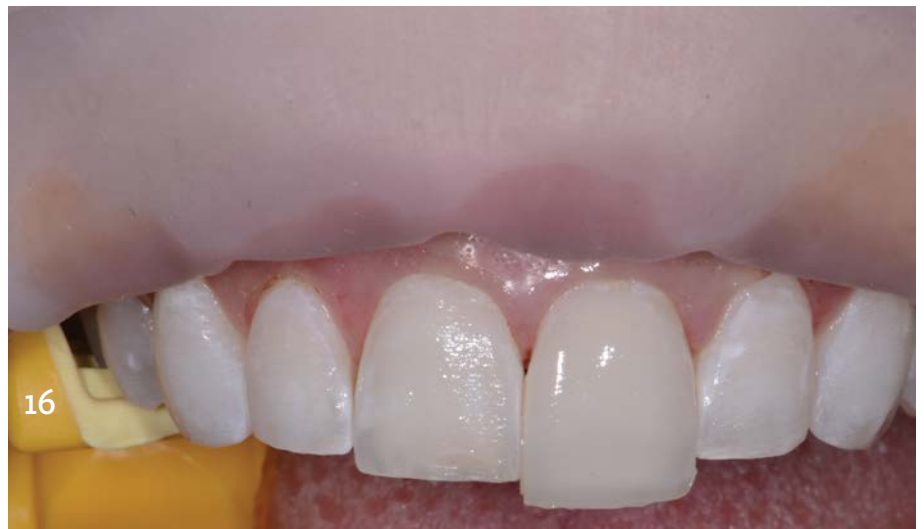<sup>2</sup>Rates range from 3.99% to 19.99% APR. Terms available based on amount financed and credit history. All Extended Plan loans made by NBT Bank, N.A. member of FDIC Equal Housing Lender. Please visit [lendingclub.com/healthcare](http://lendingclub.com/healthcare) for current rate information.

© 2015 Lending Club Patient Solutions products and services provided through Springstone Financial LLC, a subsidiary of LendingClub Corporation. Payment plans made by issuing bank partners. [lendingclub.com/providers](http://lendingclub.com/providers).



## Departments

- 12 Behind the Cover  
**Fighting Mediocrity** ♦  
*Pinhas Adar, MDT, CDT, AAACD*
- 14 Scientific Session  
**Content You Can't Afford to Miss!** ♦
- 16 Accreditation Essentials  
**Conservative Transitional Bonding** ♦  
*Nicholas C. Marongiu, DDS*
- 23 AACD Newly Accredited Announcement
- 24 Examiners' Commentary  
**Case Type V: The Ability to Deliver Responsible Esthetics** ♦  
*J.A. Reynolds, DDS, AAACD*



### AACD MISSION STATEMENT

The American Academy of Cosmetic Dentistry is dedicated to advancing excellence in the art and science of cosmetic dentistry and encouraging the highest standards of ethical conduct and responsible patient care.



The *Journal of Cosmetic Dentistry* (ISSN 1532-8910), USPS (10452), published quarterly. \$200 per year (U.S. & Canada) or \$240 per year (All other countries), single issues available upon request, by the American Academy of Cosmetic Dentistry®, 402 West Wilson Street, Madison, WI 53703. 800.543.9220 OR 608.222.8583. Periodicals postage paid in Madison, WI, and additional offices.

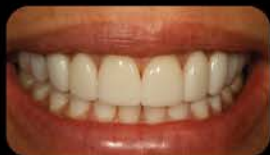POSTMASTER: send address changes to:  
*Journal of Cosmetic Dentistry*  
American Academy of Cosmetic Dentistry  
402 West Wilson Street  
Madison, WI 53703

Peer-reviewed articles are denoted with the following symbol: ♦

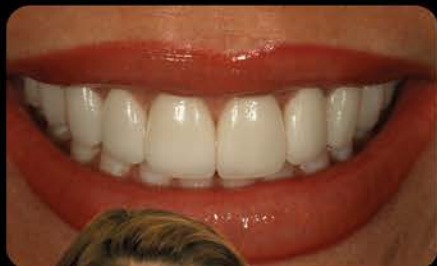Statements of fact and opinion are the responsibility of the authors alone and do not imply an opinion on the part of the officers of the AACD. Materials may not be reproduced without written permission. Contents© 2015 American Academy of Cosmetic Dentistry®

The *Journal of Cosmetic Dentistry* maintains signed patient release forms for all articles featuring clinical or other patient photography.

# ELEVATE YOUR PRACTICE BEYOND THE STANDARD



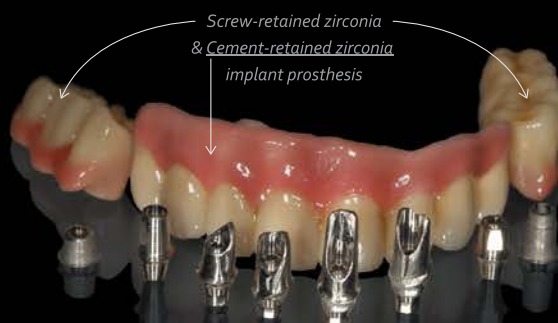Before



After

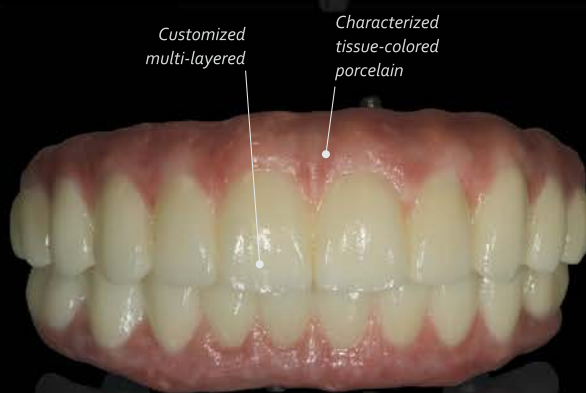

Actual patient: Michelle  
Case courtesy of Tyson Frenzel, DDS, Bolingbrook, IL



Screw-retained zirconia  
& Cement-retained zirconia  
implant prosthesis

Custom designed & milled titanium abutments  
Case courtesy of Michael Tramel, DDS, Jackson, MS



Customized  
multi-layered  
Characterized  
tissue-colored  
porcelain

Case courtesy of Abraham E. Stein, DMD, Skokie, IL


## ZEN Zirconia Enamel™

- Creates more translucency than regular full zirconia
- Natural beauty with flexural strength of zirconia (more than 600 MPa)
- Recommended for posterior crowns, inlays, onlays & anterior veneers
- Can utilize traditional cement and glass ionomer cement
- Highly recommended as a replacement for lithium disilicate
- We accept STL files

## SG Implant Layered Zirconia

- Exceptional resistance to chips, fractures and stains
- Customized characterization and cosmetic shade color options
- Precise and detailed occlusal design
- Expeditious case completion with predictable turnaround times
- Full quality control and fabrication through In-house milling center
- Industry-leading knowledge and experience restoring all types of implant systems

Call for more  
info and  
our current  
promotions



Improve your shade  
matching with our  
exclusive Ceramic  
Shade Guide System

[ChairsideShadeGuide.com](http://ChairsideShadeGuide.com)



Visit our website [LSK121.com](http://LSK121.com) for more information about our services

[info@lsk121.com](mailto:info@lsk121.com) | 888.405.1238

One Lab, One Resource, Ultimate Solution

LSK121 Oral Prosthetics utilizes the

initial ceramic system

© 2015 LSK121 Oral Prosthetics. All rights reserved.



# Thank you, jCD Reviewers!

“Production of the journal would not be possible without your support and passion; you all make my role as Editor-in-Chief extremely gratifying.”



From the inaugural 1985 issue to this Spring 2015 issue, the transformation of the *Journal of Cosmetic Dentistry* (originally the *AACD Journal*) has largely been due to hard-working individuals who have dedicated their time and energy to continually improving the publication.

The *jCD* editorial staff members at the AACD office in Madison, Wisconsin, along with Contributing Editors and Editorial Review Board members, all commit countless hours of their time to ensure that every quarterly issue of the *jCD* comprises the highest-quality content.

The young American Academy of Cosmetic Dentistry published its first journal issue in 1985. A mere six pages, it was more a trade newsletter than a scientific journal. Who could have imagined that 30 years later, the *jCD* would grow to 130-150 pages and also be available in digital format to reach a worldwide readership? The Winter 2015 issue had a print circulation of 6,800+ and the digital edition had a total of 114,529 page views within three weeks of publication!

The small original publication committee of 1985 has evolved into a prestigious group of more than 50 prominent clinicians from around the world who make up our Editorial Review Board. This highly regarded group, responsible for reviewing manuscripts for originality, importance to cosmetic dentistry, scientific accuracy, and quality of photographic documentation, has the most significant impact on the quality of papers that reach the readers.

In addition to the people who make the *jCD* what it is, the journal has implemented an online peer-review system. This has streamlined the editorial process, facilitating better communication and quicker submission-to-publication times, especially when considering the diverse geographic locations of our reviewers.

The Spring and Summer issues of the *jCD* are featuring articles by Editorial Review Board members who have offered to share some of their clinical experiences with you. I know you will enjoy what they have to say and hope that it enhances your knowledge base.

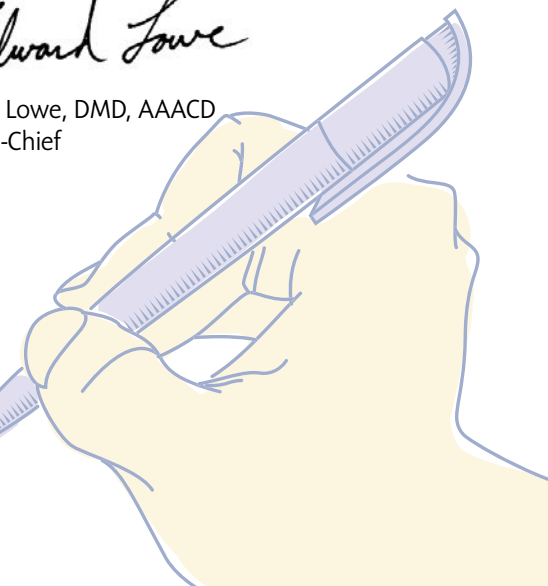
Thank you from the bottom of my heart to all of you who volunteer your time and expertise to uphold the *jCD*'s standard of excellence. Production of the journal would not be possible without your support and passion; you all make my role as Editor-in-Chief extremely gratifying. I hope to continue to nurture and grow our professional relationship in the years to come.

A stylized, hand-drawn signature of Edward Lowe in blue ink.

Edward Lowe, DMD, AAACD  
Editor-in-Chief

The word 'Thank' written in a large, blue, hand-drawn, sketchy font.

The word 'you' written in a large, blue, hand-drawn, sketchy font, positioned below 'Thank'.



# WHO'S YOUR LAB?

DR. MARTY ZASE

*AACD Past President  
AACD Accredited Member  
Colchester, CT*

DR. WAYDE FAWCETT

*AACD Member  
Houston, TX*

DR. ERIC BURGESS

*AACD Member  
Jacksonville Beach, FL*

DR. STEPHEN CHAFKIN

*AACD Sustaining Member  
Newton, MA*

DR. JOSEPH GRASSO

*AACD Member  
Dublin, CA*

DR. PETER AUSTER

*AACD Accredited Member  
ESACD Founding Member & President  
New York, NY*

DR. WES URICH

*AACD Accredited Member  
The Woodlands, TX*

DR. JOHN SULLIVAN

*AACD Past President  
AACD Accredited Member  
Tulare, CA*

DENTAL  STUDIO

LKDENTALSTUDIO.COM

CALL 866-550-3522

*Laura Kelly*

 2007-2008 PRESIDENT  
American Academy  
of Cosmetic Dentistry  
ACCORDING TO

A **GLOBAL** Approach to Excellence

**DESIGN.**

**IMPLEMENTATION.**

**REALIZATION.**

**AACD2016**

Toronto

**April 27-30, 2016**

**[www.aacd.com](http://www.aacd.com)**

**You're Invited to Attend the 32nd Annual**

The program is sure to raise the bar on AACD's already high education standards in comprehensive cosmetic dentistry, with innovative and progressive programming, top-notch educators, and a rapid-fire approach to learning that you won't get anywhere else.





## **AACD Scientific Session in Toronto, Canada.**

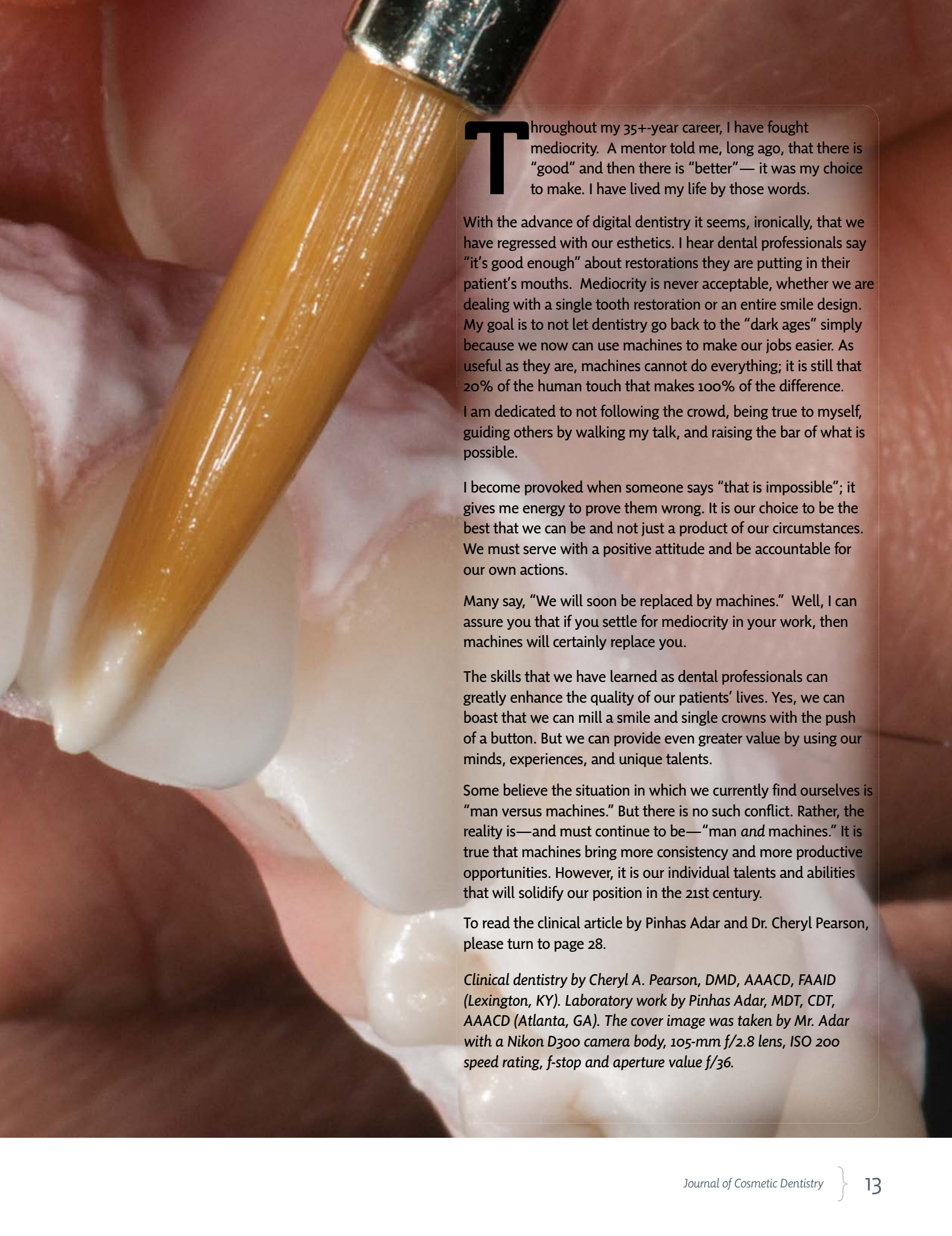Toronto is Canada's largest city, the fourth largest in North America, and home to a diverse population of 2.8 million people. Yes, you'll need a passport, but you'll learn so much for your tuition dollar and make memories for a lifetime.



# Fighting Mediocrity

Pinhas Adar, MDT, CDT, AAACD

“As useful as they are, machines cannot do everything; it is still that 20% of the human touch that makes 100% of the difference.”



**T**hroughout my 35+-year career, I have fought mediocrity. A mentor told me, long ago, that there is “good” and then there is “better” — it was my choice to make. I have lived my life by those words.

With the advance of digital dentistry it seems, ironically, that we have regressed with our esthetics. I hear dental professionals say “it’s good enough” about restorations they are putting in their patient’s mouths. Mediocrity is never acceptable, whether we are dealing with a single tooth restoration or an entire smile design. My goal is to not let dentistry go back to the “dark ages” simply because we now can use machines to make our jobs easier. As useful as they are, machines cannot do everything; it is still that 20% of the human touch that makes 100% of the difference.

I am dedicated to not following the crowd, being true to myself, guiding others by walking my talk, and raising the bar of what is possible.

I become provoked when someone says “that is impossible”; it gives me energy to prove them wrong. It is our choice to be the best that we can be and not just a product of our circumstances. We must serve with a positive attitude and be accountable for our own actions.

Many say, “We will soon be replaced by machines.” Well, I can assure you that if you settle for mediocrity in your work, then machines will certainly replace you.

The skills that we have learned as dental professionals can greatly enhance the quality of our patients’ lives. Yes, we can boast that we can mill a smile and single crowns with the push of a button. But we can provide even greater value by using our minds, experiences, and unique talents.

Some believe the situation in which we currently find ourselves is “man versus machines.” But there is no such conflict. Rather, the reality is—and must continue to be—“man *and* machines.” It is true that machines bring more consistency and more productive opportunities. However, it is our individual talents and abilities that will solidify our position in the 21st century.

To read the clinical article by Pinhas Adar and Dr. Cheryl Pearson, please turn to page 28.

*Clinical dentistry by Cheryl A. Pearson, DMD, AAACD, FAAID (Lexington, KY). Laboratory work by Pinhas Adar, MDT, CDT, AAACD (Atlanta, GA). The cover image was taken by Mr. Adar with a Nikon D300 camera body, 105-mm f/2.8 lens, ISO 200 speed rating, f-stop and aperture value f/36.*



# Content

# You Can't Afford to Miss!

## AACD 2015

You still have time to join us at AACD 2015 in San Francisco, May 6-9. Attendees will have access to hard-hitting, topical, and timely courses that will transform the way you think about continuing dental education—and your dental practice. We look forward to hosting you soon!

Here is a glimpse of some of the educational sessions you will experience at the 31st Annual AACD Scientific Session.

### Wednesday, May 6



#### Course-L116

*Writing Case Presentations for Peer-Reviewed Publications*

9:30 a.m. - 12:30 p.m.

Allison DiMatteo, BS, MPS

1. Recognize manuscript components required by editors for peer-reviewed case presentations.
2. Learn how to organize thoughts and topics in your article for clarity.
3. Create a working first draft of an article for further development.

### Thursday, May 7



#### Course-L211

*White and Pink Esthetics in Restorative and Implant Dentistry*

9:15 a.m. - 12:15 p.m.

Eric Van Dooren, DDS

Victor Clavijo, DDS, MS, PhD

1. Comprehend esthetic diagnostic tools and smile design.
2. Understand interdisciplinary treatment plans.
3. Learn about new trends in esthetic implant treatment.

### POWER SESSION



#### Course-L231

*Dental Photography: You'll Get the Picture!*

2:30 p.m. - 5:30 p.m.

Stephen Snow, DDS, AAACD

1. Learn easy-to-understand strategies for controlling exposure, color, and file formatting.
2. Gain confidence and efficiency in image storage organization, retrieval speed, view convenience, duplication ease, internet communication, and treatment plan a case presentation.
3. Learn the esthetic foundations.

### Thursday POWER SESSION continued

#### *Perfect Smile Design*

1. Learn the esthetic foundations and principal knowledge of smile design.
2. Understand how to recognize esthetic problems, causes and effects, as well as basic treatment principles with respect to smile design.
3. Learn how to communicate effectively to help the patient achieve their perfect smile.

# educate | inspire | connect

## Friday, May 8



### Course-L315

*Full Ceramic Aesthetic Restorations*

9:15 a.m. - 12:15 p.m.

*Nondas Vlachopoulos, CDT*

1. Understand framework design and its importance in increasing pressable restorations' aesthetics.
2. Learn about internal stain technique and fluorescent increase on zirconia restorations.
3. Discuss step-by-step layering of feldspathic veneers with the "One-Bake Technique."

## POWER SESSION



### Courses-L310 & L326

*Complex Decision Making for Teeth and Implants in the Esthetic Zone Using the Interdisciplinary Team*

9:15 a.m. - 12:15 p.m. (cont'd 2:00 p.m. - 3:30 p.m.)

*Dennis Tarnow, DDS*

1. Know when it is proper to place implants into immediate sockets both in the esthetic zone and molars.
2. Understand the proper surgical and restorative integration for ultimate esthetic success.
3. Know when to use the patient's own tissue or find a restorative solution with pink ceramics.

## Saturday, May 9



### Course-L412

*A Systematic Treatment Evaluation Protocol Utilizing a Customized PowerPoint Template for Comprehensive Planning*

9:30 a.m. - 12:30 p.m.

*Joseph Passaro, DDS*

*James Wooddell, DDS*

1. Learn a systematic treatment evaluation protocol that provides a framework for diagnosis and determining treatment options.
2. Observe a customized template to determine desired dental and gingival contours.
3. Learn the importance of using photographs and PowerPoint to develop treatment plans and communicate to the patient, members of the interdisciplinary team, and dental laboratory.



# Conservative Transitional Bonding

## Supporting Eroded Anterior Teeth: Case Type V, Direct Resin Veneers

Nicholas C. Marongiu, DDS

**Direct resin veneers on ##4-13 were chosen to replace the eroded enamel and fill out the patient's smile.**

**Key Words:** resin veneer, conservative, polishing and finishing, erosion, Digital Smile Design, Case Type V

### Introduction

When most people hear the term *cosmetic dentistry*, they tend to immediately associate it with porcelain veneers. Although porcelain is a great restorative material, transitional bonding with resin can also produce very esthetic and long-lasting restorations. This article presents the case of a patient with esthetic dental concerns for whom direct resin veneers were completed to achieve the desired result.

### Case Report

#### Chief Complaints

A 29-year-old female presented at the office stating that she disliked her teeth. She said her smile did not look full and that her front teeth were very thin and had been chipping at the edges. She mentioned that her upper teeth had not been like this until high school. She also reported having completed orthodontics as an adolescent but she had not worn retainers since high school and now had lower crowding. The patient's chief complaints were her smile's lack of fullness, her thin upper teeth, and the orthodontic relapse with the lower crowding (Figs 1-3).

#### Examination and Diagnosis

A complete intra- and extraoral examination was completed with evaluation of hard/soft tissues, temporomandibular joints, caries risk, periodontal health, occlusion, attrition, orthodontic class, crowding, and condition of existing dental restorations. Radiographs were obtained to evaluate supporting structures, existing dental restorations, and caries assessment. A photographic series was taken with study models for records of preoperative conditions and evaluation.

The patient was in good overall oral health and had no discomfort. Her periodontal health was good (all periodontal pocketing was 1 to 3 mm without any bleeding on probing). Mild attrition was present; the patient was in Class I molar and canine occlusion and presented with post-orthodontic relapse with lower anterior crowding. Recurrent occlusal caries at #14 was discovered during the examination and the patient was informed.

The upper anterior teeth presented with moderate facial erosion on ##7-10. No lingual erosion was present (Fig 4).

Upon discussion with the patient it was discovered that the erosion of the front teeth likely was due to swimming.<sup>1,2</sup> The patient had been a competitive swimmer throughout high school and reported having spent several hours a day in the pool through all four years.

#### Orthodontics and DSD

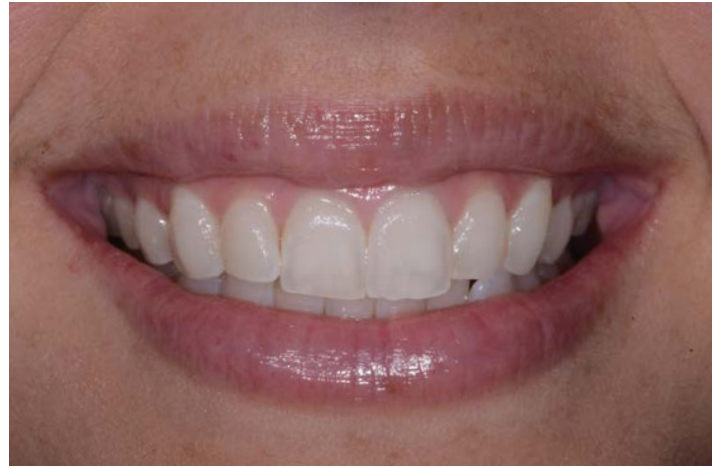After determining the cause of the facial erosion and making sure it had been eliminated, the restorative case was planned. The patient was initially sent to an orthodontist for correction of the lower anterior crowding. After correction of the orthodontic relapse, a Digital Smile Design (DSD) was designed to predict treatment.<sup>3</sup> In addition to the acid erosion of the facial enamel and collapse of buccal corridor, there was also asymmetry in gingival zeniths. All these concerns were addressed in the DSD and a wax-up of the upper 10 teeth (##4-13) was completed (Figs 5 & 6).

The patient returned to the office for presentation of the DSD and try in of the wax-up. Treatment of the upper six versus the upper 10 teeth was discussed and tried in. The patient was also offered the options of direct resin veneers or indirect porcelain veneers, as well as a combination of the two. Both options addressed the patient's chief complaint of the thin front teeth; however, the upper 10 addressed both the fullness of the smile and the thinness of the front teeth. The asymmetry of the gingival zeniths was explained to the patient using the DSD. Based on the cosmetic mock-up and discussion with the patient, it was decided to treat the upper 10 teeth with direct resin veneers and adjust gingival zeniths where needed with a gingivectomy.<sup>4,5</sup>

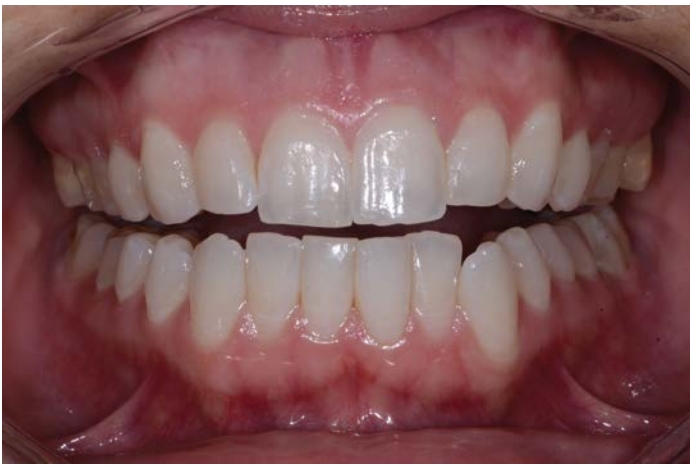



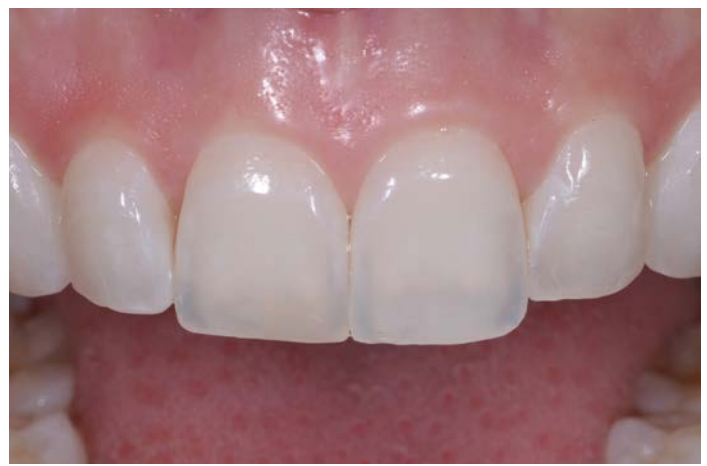**Figure 1:** Preoperative full-face smile, 1:10 view.




**Figure 2:** Preoperative smile, frontal 1:2 view.



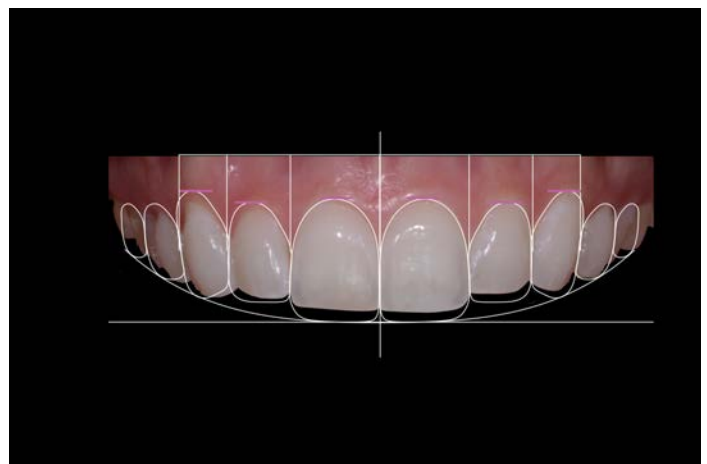
**Figure 3:** Preoperative retracted image, frontal 1:2 view.



**Figure 4:** Preoperative condition after orthodontics but before composite veneers, 1:1 view.



**Figure 5:** Digital Smile Design, full-face image showing facial midline, incisal edge position, interpupillary line, and jaw line.



**Figure 6:** Digital Smile Design displaying outlines of tooth forms #4-13, "golden proportion" scale, gingival zenith position, and lip form.

## Treatment Plan

Once the orthodontic relapse was corrected, the restorative treatment options were presented. Direct resin veneers on ##4-13 were chosen to replace the eroded enamel and fill out the patient's smile. A gingivectomy was planned to correct the asymmetrical gingival zeniths on #6 and #7. The recurrent occlusal caries on #14 would be filled with a composite filling after the cosmetic case was completed. This treatment would allow for creation of a full smile and support the eroded anterior teeth that were weakened by enamel erosion.

## Treatment

### Preoperative Record-Taking

Preoperative photographs were taken along with shade photographs of the hydrated enamel and recorded as B1 (VITA Classical Shade Guide, Vident; Brea, CA). A silicone putty stent (AnaxDENT; Stuttgart, Germany) was made of the diagnostic wax-up and used to transfer the wax-up to the patient's mouth. The stent was loaded with Protemp Plus shade A1 (3M ESPE; St. Paul, MN) and seated in the mouth for five minutes. The stent was removed and excess material carefully removed with a friction-grip high-speed flame diamond bur (Two Striper Fine 263.8, Premier Dental; Plymouth Meeting, PA).

The occlusion, including excursive, and protrusive movements, was verified and adjusted as needed. Incisal edge position and phonetics were verified. The lip line, smile line, lips in repose, and buccal corridor were verified and modified as needed.<sup>6,7</sup> Once the esthetics of the mock-up were agreed upon, AnaxDENT silicone putty was used to create a lingual/incisal edge guide and a facial contour guide. A set of photographs was taken to record the mock-up.

### Gingivectomy

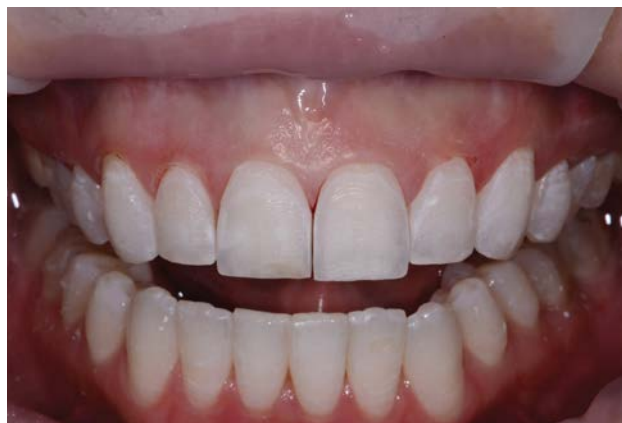A solution of 4% Septocaine with 1:100,000 epinephrine (Septodont; Lancaster, PA) was administered to ensure patient comfort during the procedure. While the mock-up was in place, the gingival contours of #6 and #7 were marked using a periodontal probe (American Eagle Instruments; Missoula, MT). The mock-up was removed and the extent of gingivectomy needed on #6 and #7 was shown by the marks left from the perio probe. Teeth #6 and #7 were then sounded using the perio probe on the facial to ensure adequate space to perform a gingivectomy without compromising biologic width.<sup>8</sup> Using a soft tissue diode laser (AMD Lasers; Indianapolis, IN) with light irrigation, the gingivectomy was completed on #6 and #7.<sup>9,10</sup>

### Preparation

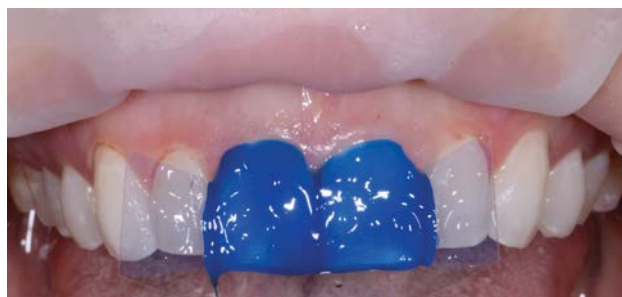Minimal preparation of the teeth was carried out to allow creation of ideal contours (Fig 7). This was made possible by using the previously made lingual/incisal edge guide and facial contour guide. The existing resin on #8 and #9 also was removed. The composite resin veneers were then layered in pairs, beginning with the centrals.<sup>11</sup>

### Etching and Bonding

Clear mylar strips were placed on the distal of the centrals to isolate the centrals from the laterals. Teeth #8 and #9 were etched with 35% phosphoric acid (Scotchbond Etchant, 3M ESPE) for 15 seconds and rinsed and blotted to remove excess moisture (Fig 8). A fifth-generation bonding material (Adper Single Bond Plus Adhesive, 3M ESPE) was chosen for its good bond strength, excellent marginal seal in enamel, low microleakage, and ease of use.<sup>12-16</sup> Two layers of Single Bond Plus were placed and air-thinned, then light-cured for 20 seconds (Elipar S10, 3M ESPE).



**Figure 7:** Retracted frontal view showing minimal preparation and gingivectomy on #6 and #7.

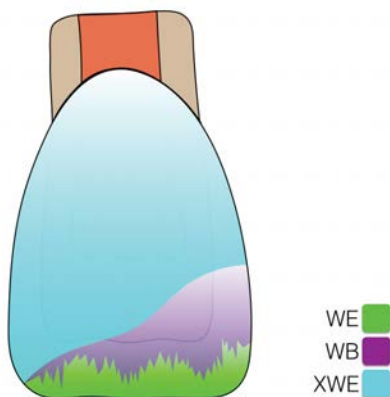


**Figure 8:** Retracted frontal view showing use of mylar strips to separate teeth being treated.

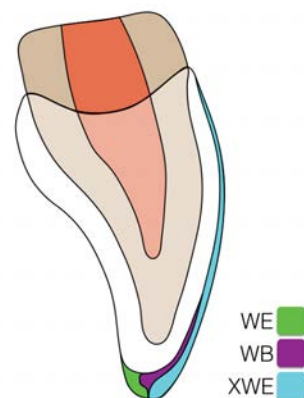
### Composite Layering and Placement

A nanocomposite (Filtek Supreme Ultra, 3M ESPE) was chosen for the entire case due to its high flexural strength, wear resistance, and polish retention.<sup>17</sup> A color map was designed and followed throughout the case; it consisted of an enamel shade lingual shell, a body shade to help blend the natural tooth junction, and a final enamel layer to create the proper contours (Figs 9 & 10). The lingual/incisal edge guide was first seated in the mouth and served as a stent to place a 0.3-mm lingual and incisal composite shell using white enamel (WE) and light-cured for 20 seconds (Fig 11). The stent was removed and white body (WB) composite was placed at the junction of the lingual shell and natural tooth structure and light-cured for 20 seconds (Fig 12). The final layer of composite, extra white enamel (XWE), was rolled in a small ball and tamped into position with finger pressure.<sup>18</sup> The composite was then molded into position using an interproximal carver, a Woodson carver (both American Eagle), and composite brushes (Cosmedent; Chicago, IL) (Fig 13). Once the desired shape and contours were achieved, the composite was light-cured for 20 seconds. The above procedure was carried out for all composite resin veneers #4-13 and completed in contralateral pairs: centrals, laterals, canines, first premolars, and second premolars (Fig 14).

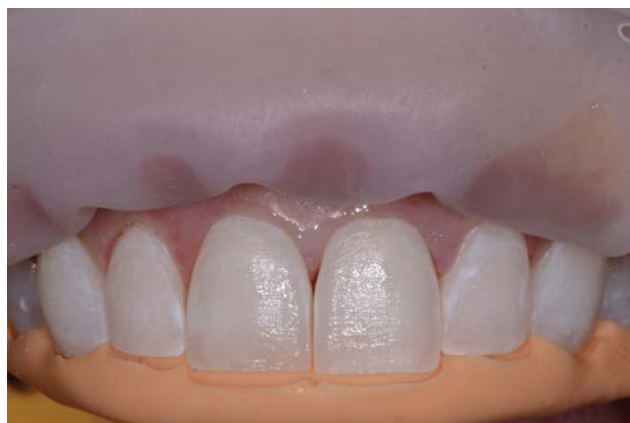Once all the composite veneers were placed, a #12 scalpel blade (Hu-Friedy; Chicago, IL) was used to remove excess resin flash under microscope vision. A friction-grip high-speed flame finishing diamond was used to refine shape, contour, and line angles using the facial contour guide for reference. A retracted photograph was taken; it was analyzed and evaluated for line angles, anatomy, light reflection, symmetry, axial inclinations, and embrasures (Fig 15). The necessary adjustments were then made.



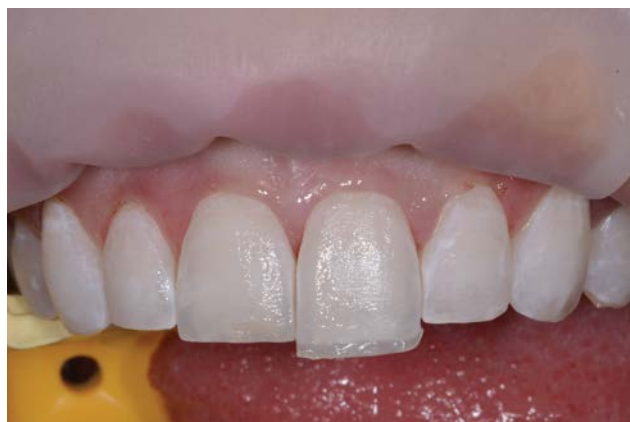**Figure 9:** Color map showing frontal view of the resin layers.



**Figure 10:** Color map showing sagittal view of the resin layers.

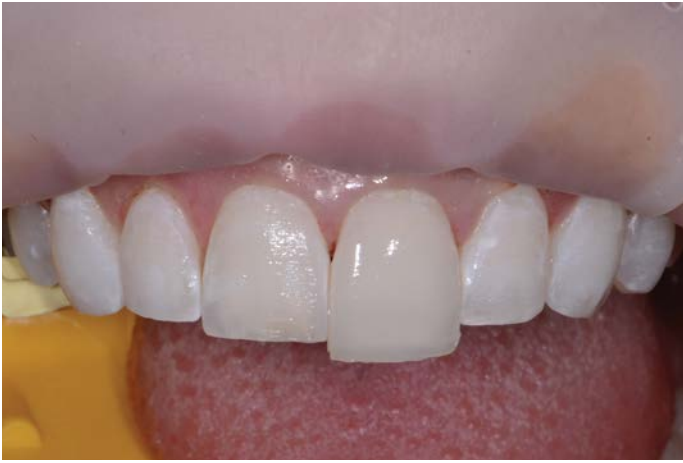

**Figure 11:** Retracted frontal view with silicone lingual/incisal matrix in place and placement of the 0.3-mm lingual shell of WE resin.



**Figure 12:** Retracted frontal view with placement of WB resin on lingual shell.



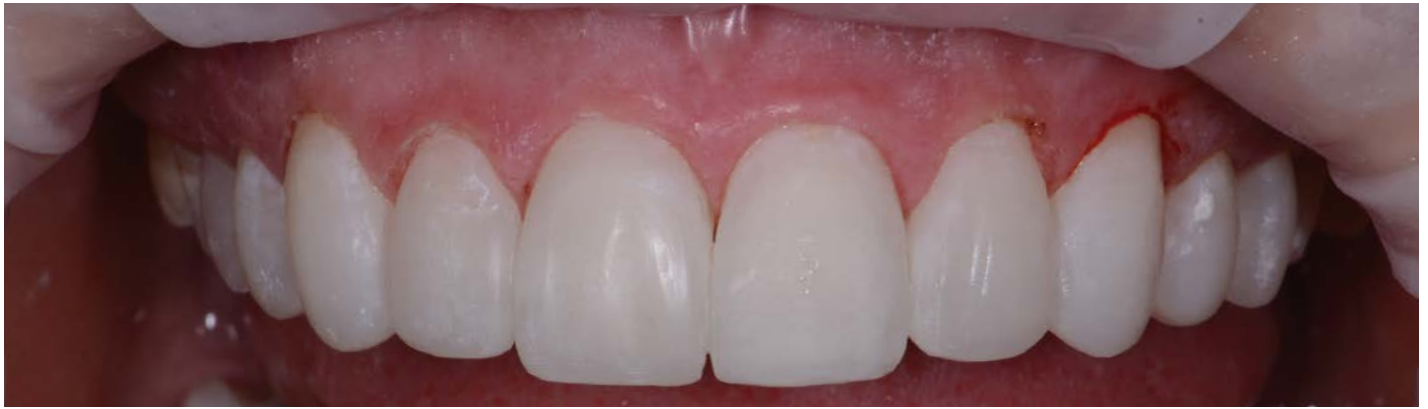

**Figure 13:** Retracted frontal view with placement of XWE resin to full contour.

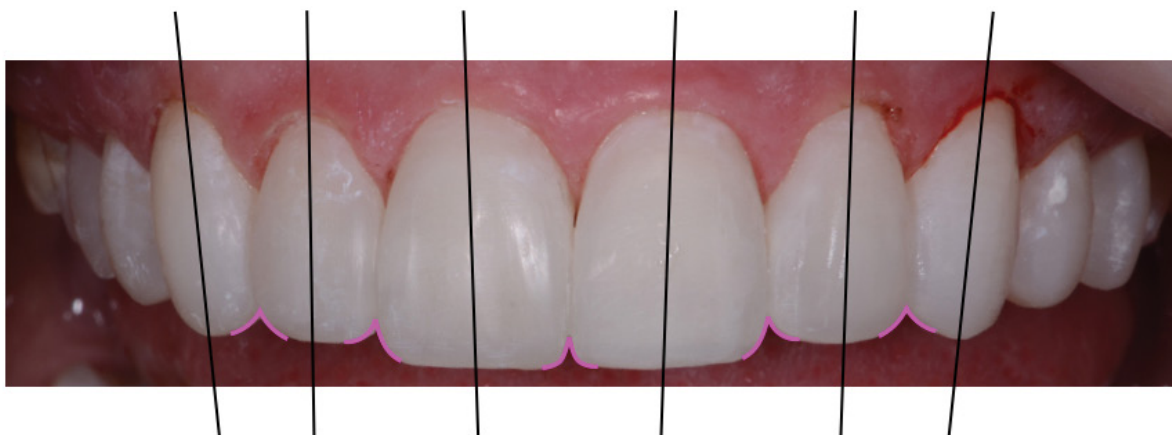### Polishing and Finishing

After achieving the desired contours, polishing was started with Sof-Lex finishing/polishing discs and strips (3M ESPE) with light irrigation. During all polishing steps, care was taken to ensure the rotational direction was always from composite to natural tooth to blend any margins.<sup>19</sup> Sof-Lex Spiral finishing/polishing wheels were then used with light irrigation. Final polish was achieved with a FlexiBuff wheel and Enamelize polishing paste (both Cosmedent) without irrigation with a slow-speed handpiece.<sup>20</sup> The occlusion, including excursive and protrusive movements, was then verified.

The patient returned two weeks later for follow-up and cosmetic polish. The postoperative cosmetic photographs were taken two weeks after that (Figs 16-19).



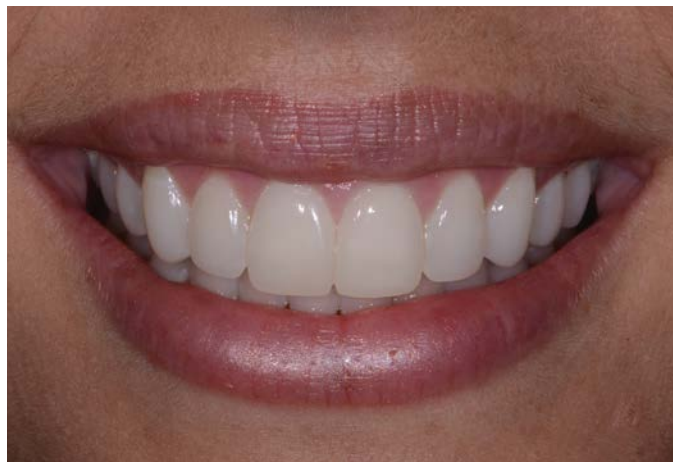**Figure 14:** Retracted frontal view of resin veneers ##4-13 before polishing.



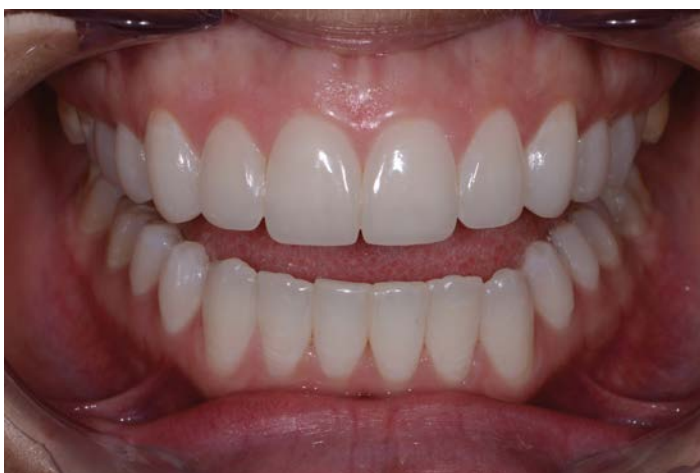**Figure 15:** Analysis of line angles, anatomy, light reflection, symmetry, axial inclinations, and embrasures.



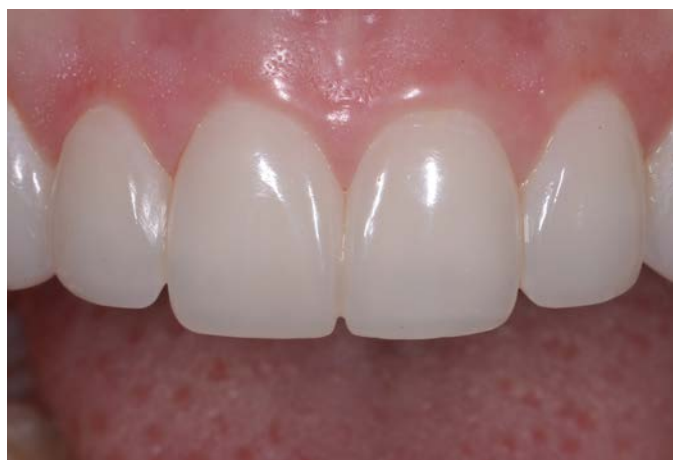**Figure 16:** Postoperative full-face smile, 1:10 view.



**Figure 17:** Postoperative smile, frontal 1:2 view.



**Figure 18:** Postoperative retracted image, frontal 1:2 view.



**Figure 19:** Postoperative anterior, frontal 1:1 view.

## Summary

Direct resin veneers can be a very good alternative to porcelain veneers and can produce a highly esthetic and long-lasting restoration. In this case, the patient was not happy with her smile and had chipping teeth, but she could not afford porcelain veneers. With minimal gingival adjustment and minimal tooth preparation, direct resin veneers on the upper 10 anterior teeth were completed and the patient was able to obtain a smile that made her feel confident. Although resin will not last as long as porcelain, transitional bonding can be a great restorative option until patients are ready to move forward with porcelain.

## Acknowledgment

*The author thanks Mr. Todd Cochran, AAACD (Horizon Dental Studio; San Diego, CA), for fabricating the wax-up of teeth ##4-13.*

**// Direct resin veneers can be a very good alternative to porcelain veneers and can produce a highly esthetic and long-lasting restoration. //**

## References

1. Dawes C, Boroditsky C. Rapid and severe tooth erosion from swimming in an improperly chlorinated pool. *J Can Dent Assoc.* 2008 May;74(4):359-61.
2. Buczkowska-Radlinska J, Lagocka R, Kaczmarek W, Gorski M, Nowicka A. Prevalence of dental erosion in adolescent competitive swimmers exposed to gas-chlorinated swimming pool water. *Clin Oral Investig.* 2013 Mar;17(2):579-83.
3. Coachman C, Calamita M. Digital Smile Design: a tool for treatment planning and communication in esthetic dentistry. *QDT* 2012. Hanover Park (IL): Quintessence Pub.; 2012. p. 1-9.
4. Chu SJ, Tan JH, Stappert CE, Tarnow DP. Gingival zenith positions and levels of the maxillary anterior dentition. *J Esthet Dent.* 2009;21(2):113-20.
5. Rigolin Ferreira FJ, Vasconcellos AA, Miranda ME, Santini E, Bocabella L. Conservative restorations combined with gingival zenith contour technique. *Quintessence Int.* 2014 Nov-Dec;45(10):813-8.
6. Small BW. Location of incisal edge position for esthetic restorative dentistry. *Gen Dent.* 2000 Jul-Aug;48(4):396-7.
7. Oshagh M, Zarif NH, Bahramnia F. Evaluation of the effect of buccal corridor size on smile attractiveness. *Eur J Esthet Dent.* 2010 Winter;5(4):370-80.
8. Fletcher P. Biologic rationale of esthetic crown lengthening using innovative proportion gauges. *Int J Periodontics Restorative Dent.* 2011 Sept-Oct; 31(5):523-32.
9. Magid KS, Strauss RA. Laser use for esthetic soft tissue modification. *Dent Clin North Am.* 2007 Apr;51(2):525-45.
10. Lee EA. Laser-assisted gingival tissue procedures in esthetic dentistry. *Pract Proced Aesthet Dent.* 2006 Oct;18(9):suppl 2-6.
11. Fahl N Jr. Step-by-step approaches for anterior direct restorative challenges. *J Cosmetic Dent.* 2011 Winter;26(4):42-55.
12. Farah J, Powers J. Adhesive technology review. *Dent Advisor.* 2008 May;25(4):1-8.
13. Gallo JR, Comeaux R, Haines B, Xu X, Burgess JO. Shear bond strength of four filled dentin bonding systems. *Oper Dent.* 2001 Jan-Feb;26(1):44-7.
14. Castelnuovo J, Tjan AH, Liu P. Microleakage of multi-step and simplified-step bonding systems. *Am J Dent.* 1996 Dec;9(6):245-8.
15. Schmitt DC, Lee J. Microleakage of adhesive resin systems in the primary and permanent dentitions. *Pediatr Dent.* 2002 Nov-Dec;24(6):587-93.
16. Hamouda IM, Samra NR, Badawi MF. Microtensile bond strength of etch and rinse versus self-etch adhesive systems. *J Mech Behav Biomed Mater.* 2011 Apr;4(3):461-6.
17. Barkmeier W, Takamizawa T, Erickson R, Tsujimoto A, Latta M, Miyazaki M. Localized and generalized simulated wear of resin composites. *Oper Dent.* 2015 Feb 23. (Epub ahead of print).
18. Beddis HP, Nixon PJ. Layering composites for ultimate aesthetics in direct restorations. *Dent Update.* 2012 Nov;39(9):630-2, 634-6.
19. St-Pierre L, Bergeron C, Qian F, Hernandez MM, Kolker JL, Cobb DS, Vargas MA. Effect of polishing direction on the marginal adaptation of composite resin restorations. *J Esthet Restor Dent.* 2013 Apr;25(2):125-38.
20. Mopper KW. Contouring, finishing, and polishing anterior composites. *Inside Dent.* 2011;7(3):62-70. **jCD**

**Direct resin veneers can be a very good alternative to porcelain veneers and can produce a highly esthetic and long-lasting restoration.**



Dr. Marongiu is a cosmetic and restorative dentist. He is a junior partner at Scripps Center for Dental Care in La Jolla, California.

Disclosures: The author did not report any disclosures.



# Congratulations to AACD's Newly Accredited Members!

Since 1986, AACD Accreditation has provided an exceptional opportunity for dentists and laboratory technicians to enhance their professional skills and knowledge in cosmetic and restorative dentistry. It requires these specialists to implement and demonstrate what they have learned at a high level of proficiency.

AACD Accreditation is an honor, a sign of one's commitment to cosmetic dentistry. Often, Accredited Members say it's not really about the credential; rather, it's about the learning, the professional growth, and the confidence that come from the journey along the way.

Please join us at AACD 2015 in San Francisco, where the 2015 newly Accredited Members will be recognized for their achievement.



Jenine M. Arab O'Malley, DDS  
Halifax, Nova Scotia, CAN  
Member since 2012



Sarah A. Aylard, DDS  
Napa, CA  
Member since 2000



Leslie A. Barrilleaux, DMD  
Huntsville, AL  
Member since 1999



Stephen E. Edgerton, DDS  
Wilmington, NC  
Member since 1995



Sarah J. Jebreil, DDS  
Irvine, CA  
Member since 2008



Cheryl A. Malcamp, CDT  
Niwot, CO  
Member since 2006



Alberto J. Meza, DDS  
San Jose, Costa Rica  
Member since 2005



Tracey T. Nguyen, DDS  
Lansdowne, VA  
Member since 2006



Vaughn M. Wright, CDT  
Nampa, ID  
Member since 2006

# Examiners' Commentary

## Case Type V: The Ability to Deliver Responsible Esthetics

**// The Academy's philosophy of responsible esthetics is evident in this case submitted by Dr. Marongiu, as he was able to achieve the patient's esthetic goals of adding length and fullness to her smile using a very conservative approach. //**

J.A. Reynolds, DDS, AAACD

Accreditation Case Type V has long been considered the benchmark for evaluating a clinician's knowledge and ability to deliver conservative, beautiful esthetic dentistry. It requires a good understanding of the characteristics existing in nature from global to micro esthetics. This case type often involves restoring a smile that has been ravaged by the processes of decay, wear, and trauma. However, many times composite resins can be used to enhance a smile emulating subtle smile design principles outlined in the AACD's Accreditation criteria guide.<sup>1</sup> The Academy's philosophy of responsible esthetics is evident in this case submitted by Dr. Marongiu, as he was able to achieve the patient's esthetic goals of adding length and fullness to her smile using a very conservative approach. Walking through all esthetic and functional needs using a mock-up made from a wax-up, he verified the final outcome before placing any final restorative resin. It is important to know where the incisal edge position will be to ensure correct thickness of each layered material and to adhere to correct functional parameters.<sup>2</sup>

Case Type V is all about creating an optimal esthetic result using direct composite resins on six or more maxillary anterior teeth. One must remember that all elements of smile design and overall esthetics are evaluated and the restorations must blend well with the natural dentition. The examiners noted only these minor deductions:

- Criterion #53: *Is the color (hue, value, chroma) selection appropriate/natural, not monochromatic?* The restorations appeared somewhat monochromatic and low in value in some areas.
- Criterion #82: *Is the midline appropriate?* A slight midline cant to the patient’s right was evident (Figs 1 & 2).

Dr. Marongiu was successful in addressing all aspects of smile design, embrasure form, labial anatomy, and surface texture. The photography was well done with the exception of excess moisture in some views. All members in the process should refer to the AACD’s photography guide to verify correct angles and magnification for their case images.<sup>3</sup> The examiners appreciate the time and effort it takes to attain a successful result for this case type and enjoy evaluating submissions done as nicely as this. Congratulations to Dr. Marongiu.

References

1. American Academy of Cosmetic Dentistry (AACD). A guide to Accreditation criteria. Madison (WI): AACD; 2014. p. 6-24.
2. Fahl N Jr. A polychromatic composite layering approach for solving a complex Class IV/ direct veneer diastema combination: part I. Pract Proced Aesthet Dent. 2006 Nov-Dec;18(10):641-5.
3. American Academy of Cosmetic Dentistry (AACD). Photographic documentation and evaluation in cosmetic dentistry: a guide to Accreditation photography. Madison (WI): AACD; 2015. **jCD**

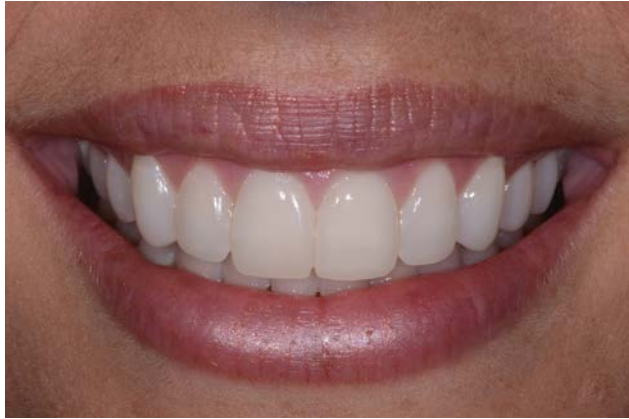

Figure 1: Postoperative smile, frontal 1:2 view.

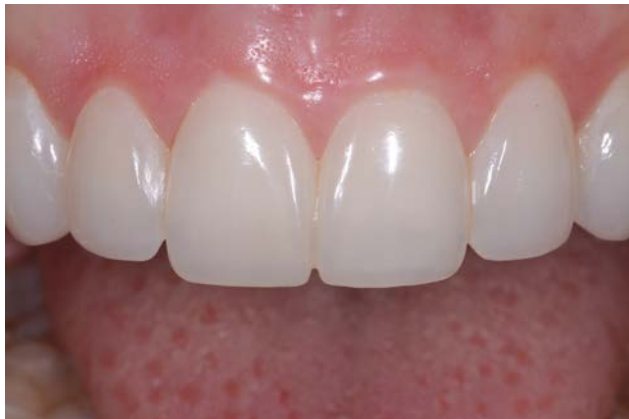

Figure 2: Postoperative anterior, frontal 1:1 view.



Dr. Reynolds is an AACD Accredited Member and has been an AACD Accreditation Examiner since 2003. Dr. Reynolds practices in Franklin, Tennessee.

Disclosure: The author did not report any disclosures.





ELITE SMILE CARE

PATIENT LOGIN NEW PATIENT FORMS

10545 VICTORY BLVD. 818-945-0711  
NORTH HOLLYWOOD, CA 91606

HOME ABOUT US DENTAL PROCEDURES SMILE GALLERY PATIENT REVIEWS CONTACT US

### COMPLETE AND COMPREHENSIVE DENTAL WELLNESS

At [Elite Smile Care](#), our team of experienced dental professionals cares for every patient with a compassionate approach that is specific to their needs. We help each patient understand their dental health while developing individualized treatment plans to work toward, and accomplish, total dental wellness. In addition to general and [preventative](#) care, we can also provide optimal smile aesthetics through conservative [cosmetic dentistry](#). Enjoy life with a smile that lasts a lifetime.

LEARN MORE

SCHEDULE AN APPOINTMENT



## AACD 2015

### Learn

Web & Social Marketing for the Aesthetic Practice – Expert Panel

7 Thursday  
MAY 2:30 pm - 5:30 pm

Keith Humes, CEO  
Panelist

### Socialize

Exhibit Hall Social Sponsored by RM

7 Thursday  
MAY 5:30 pm - 7:00 pm

# BOOST YOUR WEBSITE CONFIDENCE

## website confidence

[web-sahyt] [kon-fi-duh ns] (*noun*) The feeling or belief that one's website clearly and beautifully represents his or her work ethic, philosophy, and passion as a dentist. • *After my redesign project launched, my **website confidence** increased ten-fold. I now feel that my online image is perfectly in tune with my practice.*

**synonyms:** digital trust, online credence

RESPONSIVE WEB DESIGN • SEO • CONTENT MARKETING • SOCIAL MEDIA MARKETING

Say Hello  
at Booth #1808



**800.491.8623**

[www.rosemontmedia.com](http://www.rosemontmedia.com)

[info@rosemontmedia.com](mailto:info@rosemontmedia.com)

[www.facebook.com/rosemontmedia](http://www.facebook.com/rosemontmedia)



# The Proof is in the Laboratory

## Comparison of Maxillary Full-Arch Implant-Supported Zirconia



See jCD's digital edition to access the video that accompanies this case.


Pinhas Adar, MDT, CDT, AAACD  
Cheryl A. Pearson, DMD, AAACD, FAAID

### Abstract

The purpose of this case study was to compare the esthetics and oral hygiene compatibility of two laboratory-fabricated, full-arch, implant-supported zirconia (FAISZ) prostheses for the same patient. When fabricating a FAISZ, the dentist and the technician have two absolute goals: create a beautiful cosmetic result, and still allow for optimal oral hygiene compatibility. The patient had six implants placed and four months after implant installation the initial zirconia prosthesis (Zirconia A) was seated with compromised esthetics and oral hygiene incompatibility. The patient was followed at two-month intervals for one year. Chronic mucositis and early peri-implantitis were observed and a decision was made to utilize a second laboratory to fabricate a new zirconia prosthesis. The final prosthesis (Zirconia B) was seated two years after implant placement and has been followed at three-month intervals.

**Key Words:** full-arch implant-supported zirconia (FAISZ), oral hygiene compatibility, mucositis, all-zirconia

Unlike a conventional denture, the full-arch implant-supported prosthesis cannot be removed by the patient, as they are physically unable to access the concavities of the ridge lap design.





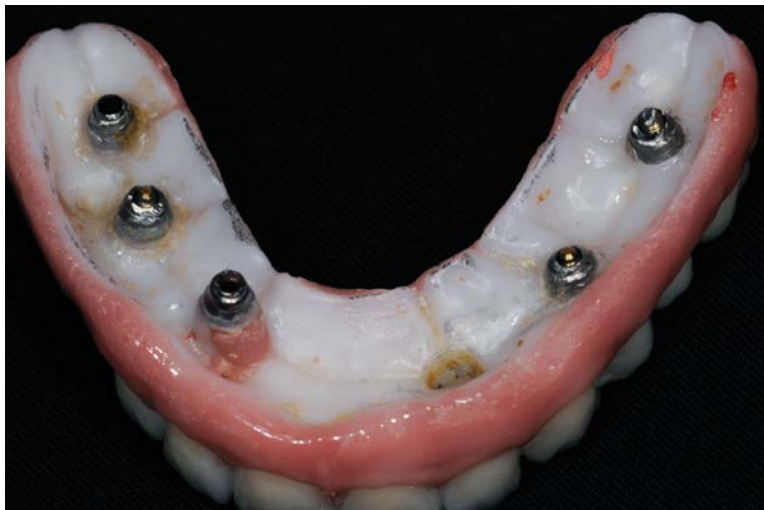# CLINICAL COVER CASE

## Introduction

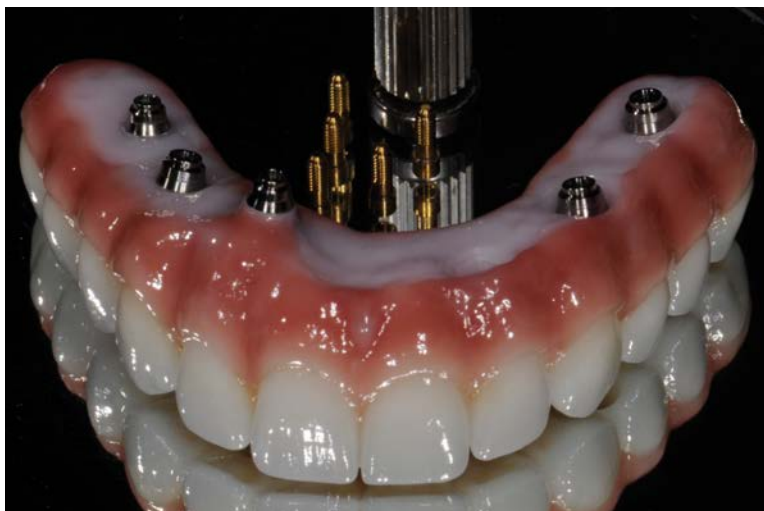
As implant dentistry has evolved, the full-arch implant-supported prosthesis has become a standard option for oral rehabilitation due to the increased success of implant survival and the profound increase in the patient's ability to function.<sup>1,2</sup> Early designs of the full-arch fixed hybrid consisted of either cast or milled titanium or cast cobalt-chrome frameworks combined with pink acrylic and denture teeth.<sup>3</sup> Open palates were also a benefit of fixed hybrid prostheses because extended surface area was not necessary for retention.<sup>4</sup> Facial esthetics were addressed in much the same way as a conventional denture by utilizing pink acrylic volume for lip support and bulk in vertical gingival height to accommodate the appropriate size tooth for the patient. Initially, the intaglio surface of the fixed hybrid prosthesis mimicked the conventional denture and lay intimately on the alveolar keratinized tissue, preventing air from collecting while the patient spoke and ate, and food particles and bacteria from collecting when he ate (Fig 1). The intaglio surface was a ridge lap or concave pontic design by default. Unlike a conventional denture, the full-arch implant-supported prosthesis cannot be removed by the patient, as they are physically unable to access the concavities of the ridge lap design. The solution introduced here was to create a highly polished intaglio surface that forms a modified ovate-like surface fitted to a surgically enhanced soft tissue bed (Fig 2).

## Patient History and Complaints

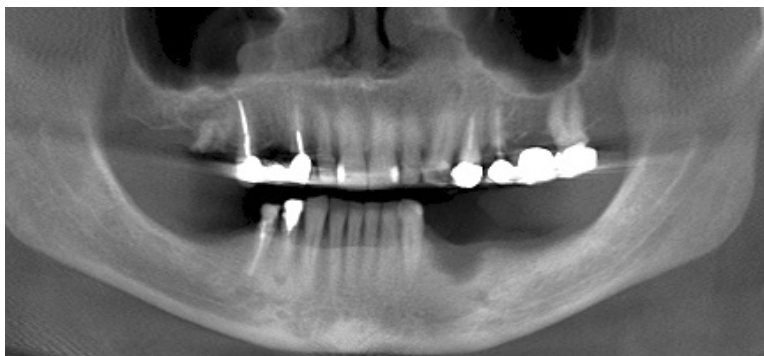
The patient, a healthy 52-year-old female, requested treatment options for her "failing dental work" in May 2012. She was a non-smoker, was unaware of possible parafunctional habits or sleep apnea, and reported taking only over-the-counter medications for hay fever and pain relief. There were no contraindications to dental treatment or to implant surgery. Initially she presented with extensive complex restorative treatment approximately 15 years old and had sought only episodic care for specific problems (Fig 3). Now, however, she could not eat without pain but had postponed seeking dental care for fear she would lose all her teeth. She was opposed to wearing a removable prosthesis and wanted to explore options with implants. Her expectations to chew well and have a natural and beautiful smile were realistic. After a frank discussion considering the extraction of the maxillary teeth and an implant-supported prosthesis with the associated time demands and cost, the patient was offered a diagnostic appointment.



**Figure 1:** Initial prosthesis. The ridge lap design demonstrates concave areas that the patient was unable to clean; this resulted in food debris and bacteria.



**Figure 2:** A full-arch, implant-supported zirconia restoration. Five implants were screw-retained and the sixth implant with a custom abutment was inserted into the zirconia.

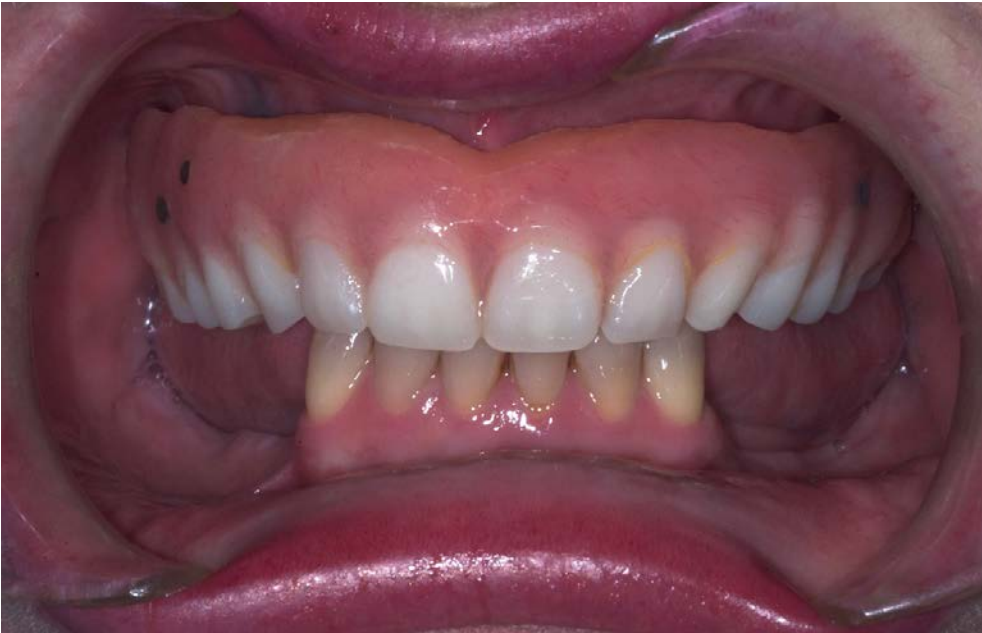

**Figure 3:** Cone-beam computed tomography taken at the initial consultation. Note the preoperative condition of existing teeth.

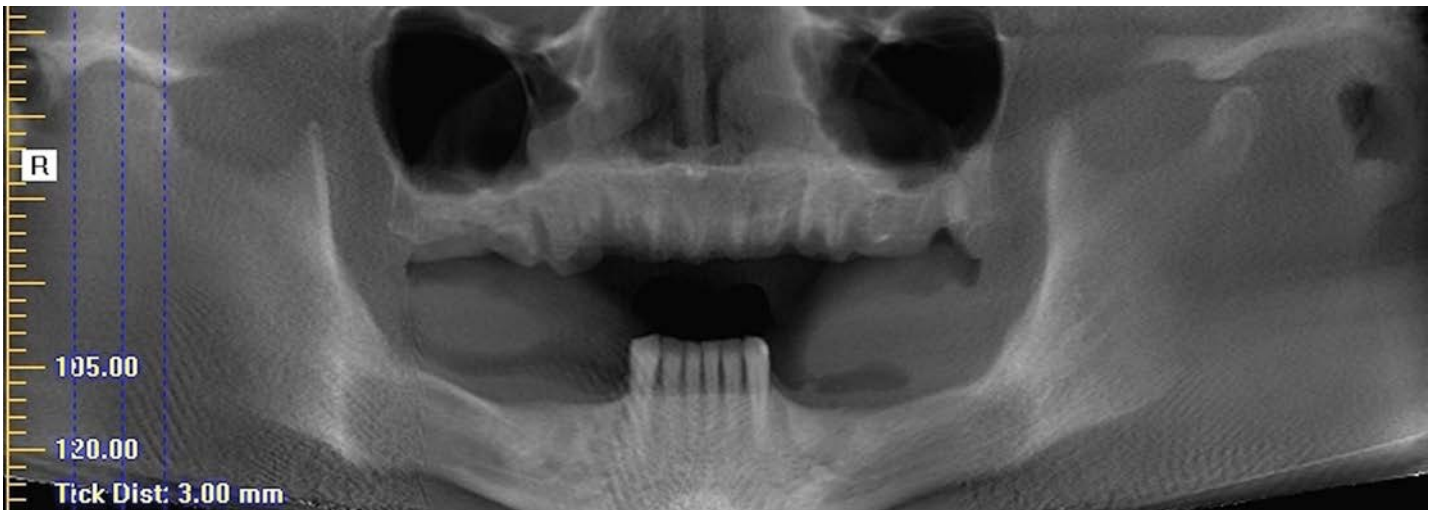


She declined the diagnostic appointment and sought a second opinion. This dentist convinced her that extracting her maxillary teeth and placing an immediate denture without plans for future implants would be adequate and less expensive. She proceeded with this recommended treatment. Approximately eight weeks after the extractions she returned to us with a maxillary immediate denture, and with no apparent ridge preservation. She reported a total loss of function as well as unhappiness with the denture's esthetics. She was physically in pain and emotionally distressed (Figs 4 & 5).

To please our patients it is imperative not to become complacent because of technology and say, "it is good enough."



**Figure 4:** Immediate denture eight weeks after extractions. Note the teeth are clinically short and square and the absence of posterior occlusion.



**Figure 5:** CBCT eight weeks after extraction, no ridge preservation. Note the irregular topography of the alveolar process and the height discrepancy of the bone in the right canine lateral area.

## Diagnostic Report

Obtaining accurate comprehensive diagnostic information for planning and executing this case was of paramount importance.<sup>5,6</sup> The concepts of bone modeling and remodeling of the maxillary alveolus are not within the scope of this article but clinicians must be aware of the complexity of bone topography. Maxillary arch forms, the trajectory of the premaxillary alveolus, and the biomechanics of implants under lateral and anterior cantilever forces must be considered for a favorable long-term prognosis.<sup>7</sup> When planning this case, a cone-beam computed tomography (CBCT) of the patient wearing an ideal scanning prosthesis was studied for implant installation and related anatomical structures (Fig 6). Information from the CBCT demonstrated adequate height and width of alveolar bone for the placement of six implants. Clinical observation of a high smile line in relationship to the crest of the alveolus dictated a fixed prosthesis (FP-3) to replace teeth and a significant area of alveolus and gingival anatomy or pink esthetics with the prosthetic transition line planned completely under the lip. Short lip lines and hypermobile upper lips can be problematic; transition lines must be invisible and not impinge upon the movement of the lip, especially during a full smile.

Photographs and an extraoral examination provided information regarding asymmetry of the face and deviation of the midline. The midline in the upper two thirds of the face canted left of the center of Cupid's bow and chin. The existing teeth on the immediate denture were clinically short and square and inappropriately small compared with the patient's facial dimensions.<sup>8</sup> Moderate gingivitis was present but the periodontal examination demonstrated the

absence of periodontal disease. The initial occlusion was a Class II canine relationship with a 60% overjet. Prior to the placement of the immediate denture, a measurement of 10 mm of intra-arch distance was noted with a decrease in vertical dimension, likely due to the premature loss of mandibular posterior molars. While at rest, the incisal edge was hidden. The maxillary and mandibular skeletal and dental relationships, temporomandibular dynamics, and facial and occlusal dimensions in both the vertical and horizontal planes were analyzed to develop appropriate facial and dental esthetics. Photography, diagnostic reports, mounted casts, and the anticipated treatment plan were shared with the laboratory technician who fabricated the final prosthesis.

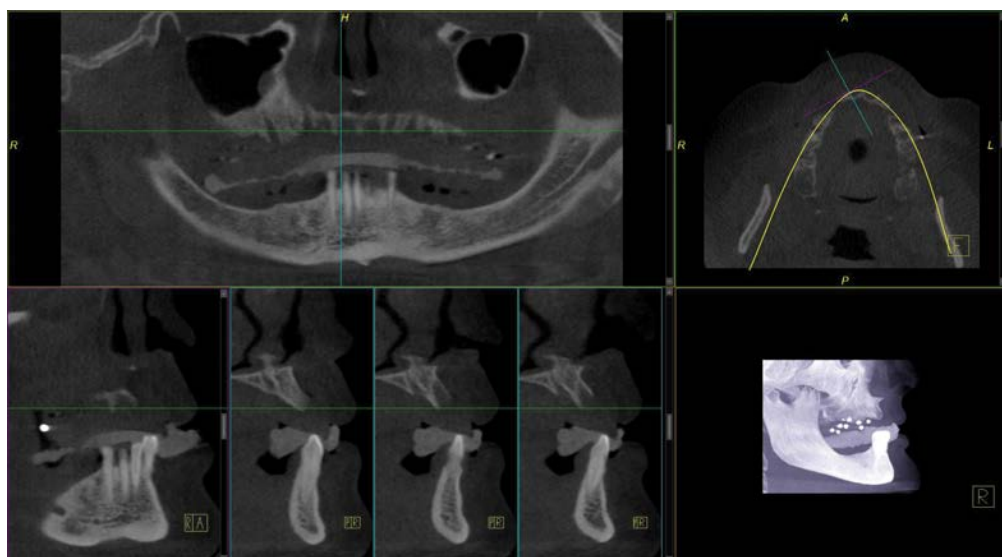
The diagnoses were premature loss of teeth, diminished ability to function, nonrestorable maxillary partial dentition, chronic dental infection, and related pain.

## Materials and Properties

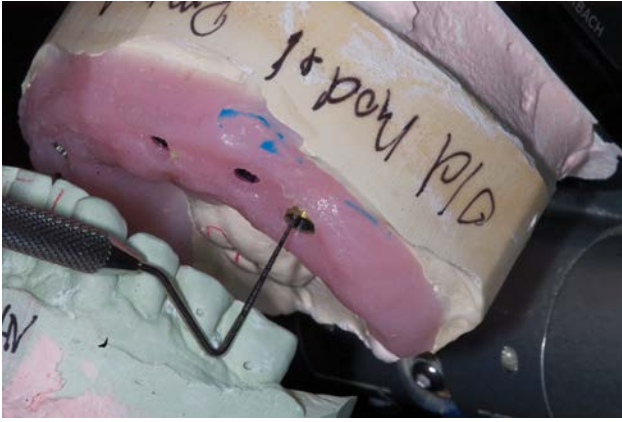Important considerations for selecting an all-zirconia final prosthesis are the material's strength, wear resistance, biocompatibility, and esthetics; and that it be computer-aided design/computer-aided manufacturing (CAD/CAM)-generated, have a predictable prototype, and be compatible with good oral hygiene. The final prosthesis used in this case was a full-arch implant-supported zirconia (FAISZ) (Prettau, Zirkon Zahn; Gais, Italy).

## Strength

Prettau has maximum strength and fracture resistance at a thickness of at least 12 mm. Full-arch implant-supported (FAIS) acrylic hybrids require intra-arch distance to accommodate thickness of the abutment height, metal framework, pink acrylic covering the framework, and denture teeth equaling 15 to 18 mm.<sup>9</sup> Frequent prosthetic failures such as debonding of denture teeth or fracturing of pink acrylic are a result of inadequate intra-arch distance and/or failure of mechanical retention.<sup>10</sup> The monolithic zirconia has much greater strength and requires much less thickness in an environment that is already limited<sup>11</sup> (Fig 7).



**Figure 6:** Software for CBCT studies allows not only surgical planning but also prosthetic planning. Note the trajectory of the premaxilla and the thin buccal plate.



**Figure 7:** Intra-arch distance required is less than the conventional hybrid. Space often is very limited. Opening the vertical dimension may be part of the plan to achieve at least 12 mm.

### Wear Resistance

Zirconia occlusal surfaces are extremely wear-resistant.<sup>12</sup> The use of zirconia eliminates the need for tooth replacement protocols common with acrylic hybrids. The proper occlusal schematic for implant-supported acrylic hybrids is a well-balanced occlusion that provides stability and health of the supporting implants. Fixed implant-supported acrylic arches opposing natural or fixed dentitions demonstrate significant posterior denture tooth wear, creating an overall decrease in vertical dimension, which results in an increased anterior overbite with subsequent protrusive guidance. Anterior cantilever forces are generated that place the supporting implants at risk. Recommendations call for the replacement of denture teeth approximately every seven years (lecture, "The maxillary implant-supported hybrid," by Edward Mills, DDS; Atlanta, GA, 2014 Dec 3; unreferenced).

### Biocompatibility

The smooth and highly polished surface of the Prettau is less susceptible to the collection of debris and bacteria when compared to an acrylic surface, which has a much higher porosity.<sup>13</sup> In the authors' opinion, the smooth zirconia surface appears to be very biocompatible and adapts well without causing increased mucositis or irritation.

### Superior Esthetics

The use of conventional precious and non-precious metals in FAIS prostheses has often contributed to cosmetic failure; underlying metal can cause shadowing or unsightly bleed-through, necessitating the use of opaqueing materials or an increased acrylic thickness of the overall appliance. In contrast, zirconia is one solid block without variations in color and is accepted by many clinicians as a superior esthetic material when in the right hands.<sup>14</sup>

### CAD/CAM Technology

The Prettau is computer-generated and milled. There is no casting distortion inherent with metal casting techniques. Computer files of the patient's prosthesis are saved as a contingency for future exact duplicates.<sup>15</sup>

### Precise Working Prototype

The working prototype is composed of milled polymethyl methacrylate (PMMA). It is seated in the patient's mouth and functions over a period of at least eight weeks.<sup>16</sup> If issues arise during this stage a new PMMA can be fabricated. Another advantage of the PMMA is the manipulation of the intaglio surface to promote maximum oral hygiene compatibility. Once the PMMA is perfect, the final prosthesis is copy-milled and delivered.<sup>17</sup>

### Treatment Goals

The treatment goals for this case were as follows:

- establish the proper plane of occlusion and proper vertical dimension of occlusion (VDO)
- maintain keratinized tissues and bone for implant installation
- surgically place six implants and seat an immediate-load provisional
- fabricate the prosthesis.

Establishing the proper planes of occlusion and VDO was extremely significant to the overall outcome of this case. An ideal denture and a lower partial denture were fabricated to open the vertical dimension and enhance facial esthetics as well as to provide proper function and comfort. Cases without ridge preservation six weeks after extraction are a concern and pose the possibility of a second (frequently avoidable) surgery. It is the authors' opinion that maintaining as much natural keratinized tissue and bone directly influences the most favorable prognosis of implants and maxillary full-arch prostheses.

### Treatment

#### Pre-Implant Surgical Protocol

The initial surgery consisted of making an incision slightly lingual to the crest of the ridge extending from the maxillary first molar to the contralateral first molar area. Conservative reflection of the soft tissue exposed sharp points around the extraction sites, which were smoothed with rongeurs. Caution was used to avoid reduction in the height of bone and a 50/50 mixture of mineralized freeze-dried bone and demineralized freeze-dried bone was placed in extraction sockets, followed by careful manipulation with osteotomes to encourage bone expansion and the development of the osteotomies. Collagen was placed over the allograft material and the soft tissue was loosely sutured back in place. The maxillary ideal denture was relined with tissue conditioner and seated with an opposing mandibular removable partial denture.

CT studies at the end of four months demonstrated readiness for the placement of implants. A duplicate of the existing denture was fabricated with a silicone putty matrix. Pink acrylic and Venus provisional material (Heraeus Kulzer; Armonk, NY) were utilized to



# CLINICAL COVER CASE

fabricate the scanning appliance. Venus is radiopaque and reveals the ideal tooth position needed for the planning of the surgical guide and final prosthesis.<sup>18</sup>

## Implant Placement Protocol

A flapless surgical approach utilizing a CT-generated guide was the planned protocol the day of implant placement.<sup>19,20</sup> Soft tissue punches were made in six planned locations and the guide stabilized with three-point pin fixation. Initial pilot drills established the location and angulation for the osteotomies, followed by the use of osteotomes in increasing diameter that condensed and widened the alveolar ridge as the osteotomies were developed. The osteotomies were slightly undersized and six PrimaConnex implants (four 3.5 diameter and two 4.1 diameter, Keystone Dental; Burlington, MA) were installed.

## Prosthetic Protocol

The prosthetic component of treatment began immediately after placement of the implants. Impression posts were placed on the implants and a polyvinyl silane (PVS) open tray impression (Aquasil Ultra Monophase, Dentsply Caulk; Milford, DE) was made (Fig 8). Analogs were placed on the post and Snap-Stone gypsum (Whip Mix; Louisville, KY) was used to pour the impression. While the impression was setting, the immediate denture the patient had been wearing was altered by removing the palate and buccal flanges, and developing access holes strategically over the implants (Fig 9). Non-engaging temporary titanium abutments were used to retain the provisional. Once the alterations were made on the denture, the abutments were placed on the patient's implants and any interference in seating the denture or verifying the occlusion was eliminated (Fig 10). ERA PickUp material (Sterngold Dental; Attleboro, MA) was flowed around the abutments and allowed to set while the patient lightly held the proper occlusal position. Once the material was set, the provisional was removed and voids, short areas, and excess were finished and polished ready for delivery. The patient was dismissed with an immediate-load FAIS provisional prosthesis, which she wore for a period of four months.<sup>21,22</sup>

After four months of healing, engaging impression posts were seated on the implants and verified radiographically. The posts were tied together with dental floss and then luted with temporary composite material. A master impression was made using Impregum polyether material (3M ESPE; St. Paul, MN) and an open tray technique.<sup>23,24</sup> Occlusion rims were utilized to develop the correct vertical dimension, midline, buccal corridors, facial dimensions, tooth shape and



Figure 8: The fixture level impression.

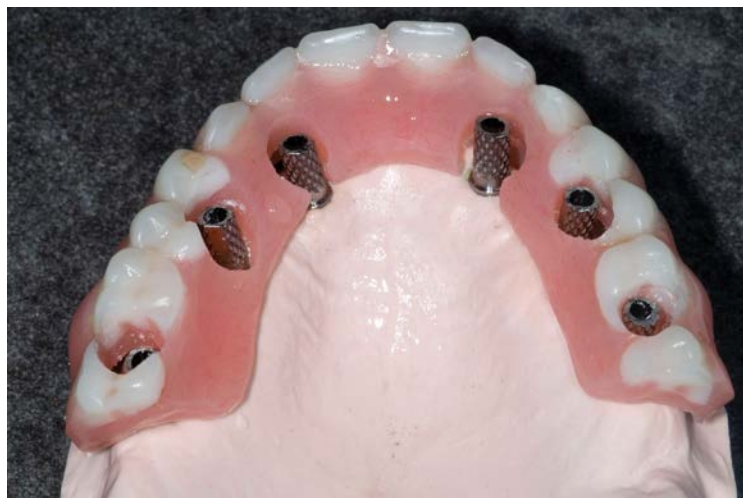

Figure 9: Note alteration of the existing denture to the fixture level impression. When seated intraorally, ERA PickUp material is flowed around the cylinders.

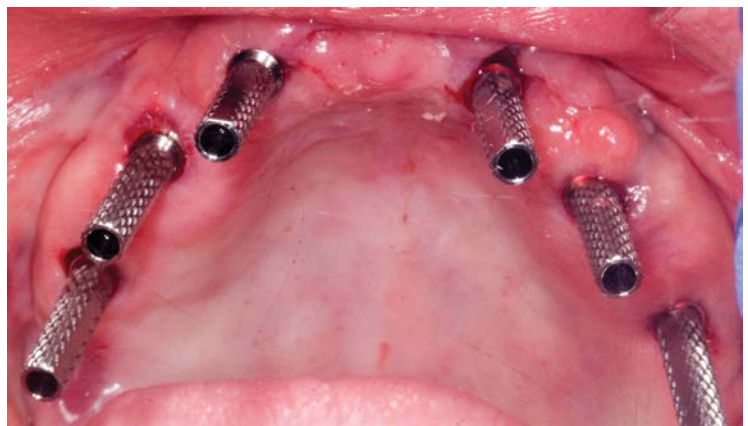

Figure 10: The day of surgical implant placement titanium non-engaging cylinders are seated and used to retrofit the existing denture.

# COSMECORE™

## Core Build-up Material



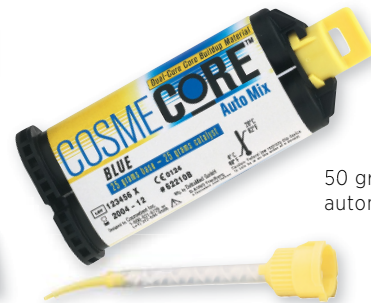### Top clinicians agree

COSMECORE outperforms other leading core materials in all aspects. Designed to provide high strength in core build-ups, COSMECORE is the only automix composite material that actually cuts like dentin. Easy to use, COSMECORE eliminates the need for hand mixing, has excellent flowability with no slump and preps exactly like tooth structure.



**NEW**  
8 GRAM  
syringe

Popular COSMECORE is now available in convenient 8 gram automix syringes.



50 gram  
automix cartridges

Available Shades:  
A2, Blue & White

### BETTER *for* DENTISTS

- Solves the problem of gouging and ditching during prep
- Sets hard and cuts like dentin
- Ideal working time
- Excellent flowability with no slump

### BETTER *for* PATIENTS

- High strength resists breaking
- Long lasting and wear resistant
- Less chairtime — preps quickly and accurately
- Low exotherm

Helping you succeed with quality products and dedicated support.

Call us at: 800 . 621 . 6729

[www.cosmedent.com](http://www.cosmedent.com)



# 5 minutes in chair. 4 shades whiter.\*

Introducing the new Philips Zoom  
QuickPro whitening varnish

There's a revolutionary way to get noticeable whitening results in minimal time. Philips Zoom QuickPro whitening varnish:

- Breakthrough two-layer technology seals in hydrogen peroxide
- Whitens four shades\* – with just a five-minute application
- Virtually no sensitivity

Once you're done, send your patients on their way and instruct them to simply brush or wipe off the varnish in 30 minutes.

Professional whitening has never been so quick... or so effortless.



innovation  you

For a free demonstration  
call **(800) 422-9448** or visit  
**[philipsoralhealthcare.com](http://philipsoralhealthcare.com)**

\*Average shade improvement

**PHILIPS**  
**ZOOM!**



size, as well as the proper dental occlusion. At the second appointment, a laboratory-fabricated verification jig was seated to ensure the accuracy of the master impression. The importance of passivity cannot be understated and implant abutments must be radiographically verified.<sup>25</sup> At this same appointment, a wax denture setup similar to a conventional denture was tried in and held in place by three of the six implants. The occlusion was again verified and a bite registration was captured. The patient approved the esthetic design.

### The PMMA

The gathered information and wax denture setup were sent to the laboratory ("Laboratory A"), scanned into a computer, and saved as a file. The PMMA was milled from the file image, delivered in early December 2012, and worn approximately eight weeks by the patient as a prototype. The patient was encouraged to function, talk, and smile normally, and to follow strict oral hygiene instructions.<sup>26</sup> The patient presented at two-week intervals for a total of eight weeks for observation and minor occlusal adjustments and an esthetic evaluation was approved by the patient and clinician. Laboratory A was sent a PVS impression of the PMMA with minor adjustments and a request to mill the final FAISZ. The initial Prettau FAISZ ("Zirconia A") was milled and delivered to the patient in early February 2013. A noticeable difference in dental esthetics, facial midline to dental midline confluence, and shape of the intaglio surface in comparison to its companion PMMA were observed. This may have been indicative of errors such as communication between the laboratory and dentist, technical computer errors, or technique errors in materials or skills used by the dentist and/or the laboratory technician.<sup>27</sup> The digital file somehow changed prior to Laboratory A milling Zirconia A (Fig 11).

At one year, observation of the soft tissues under Zirconia A revealed the continued presence of inflammation, redness, and swelling. Irregular healing had occurred and space developed between the surface of the prosthesis and the soft tissue, which caused the collection of bacteria and debris. The patient also complained of problems with phonetics; these were directly caused by the slope and bulk on the palatal surfaces in the maxillary anterior segment of Zirconia A (Fig 12).

Obtaining accurate comprehensive diagnostic information for planning and executing this case was of paramount importance.

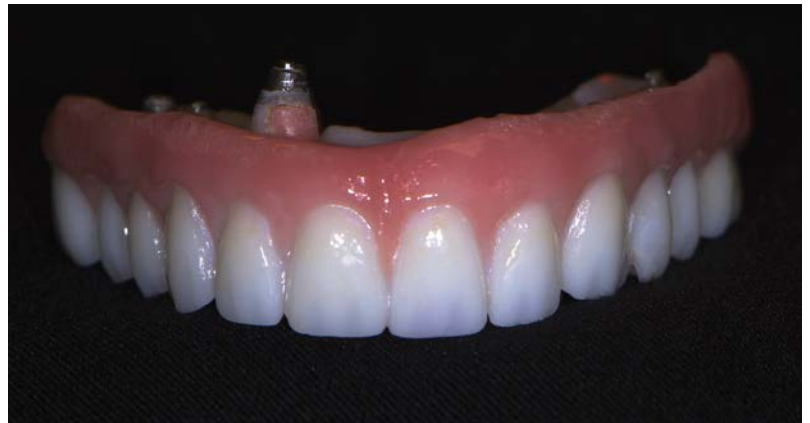

Figure 11: Zirconia A prior to seating.

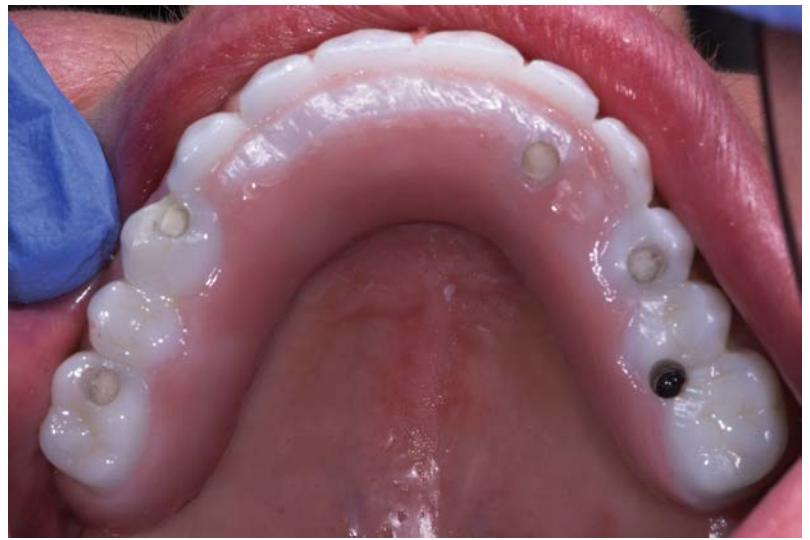

Figure 12: Zirconia A one year after seating. The patient complained of problems with phonetics, which were directly caused by the slope and bulk of palatal contour.

# CLINICAL COVER CASE

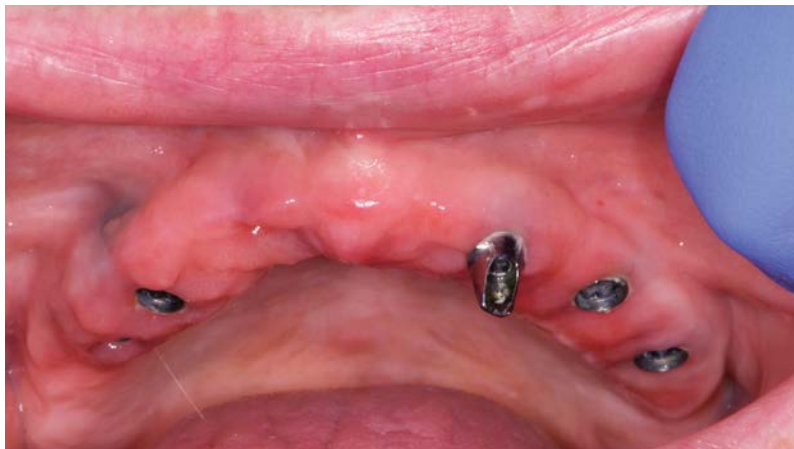## Laboratory Issues

At this point a decision was made to utilize a different laboratory (“Laboratory B”) due to the frustration associated with communication between Laboratory A and the clinician, conflicting vision of quality esthetic design, and the need to follow the prescribed design of the intaglio surface. The clinician’s time when using Laboratory A was excessive due to many corrections required, lost appointments when the case was not sent on time, and inadequate communication. Time is an extremely valuable commodity for the patient, the clinician, and the laboratory technician. In this case, it became clear that although Laboratory A’s fees were lower, adding the cost of 12 hours of wasted chair time in fabricating Zirconia A ultimately increased the clinician’s cost approximately threefold. In addition, Zirconia A’s compromised design and esthetics would serve as a negative advertisement. Laboratory B (of which the clinician had initially been unaware) was chosen to fabricate Zirconia B due to its proven systems, fabrication protocols, and great ability to create an artistic, lifelike esthetic outcome. Although Laboratory B’s fee was higher, the decreased fabrication time (three hours, which included 20 minutes for the final seating) actually realized a significant cost savings. The ultimate esthetic outcome of Zirconia B demonstrated the clinician’s ability and confidence and the patient’s pride in her appearance.

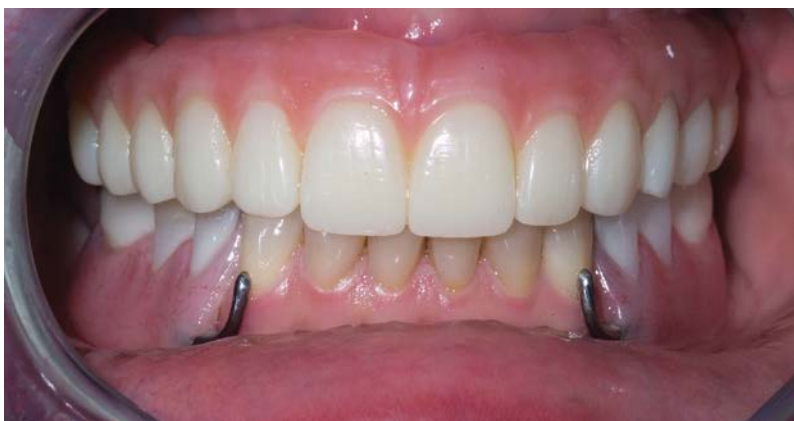## Intaglio Surface Management

After wearing Zirconia A for approximately one year, the patient exhibited all the hallmarks associated with mucositis, and in the upper right canine area 6-mm probing depths with bleeding were recorded around the implant. The clinical appearance of the tissue was irregular, edematous, and red, predominantly under the prosthesis (Fig 13).<sup>27</sup> The patient was unable to floss adequately under several areas of the prosthesis and when she did it was painful. The goal of surgical modification of the soft tissue was to create a flat, keratinized, firm surface to which the Zirconia B prosthesis would intimately contact and mold, much like an ovate pontic.

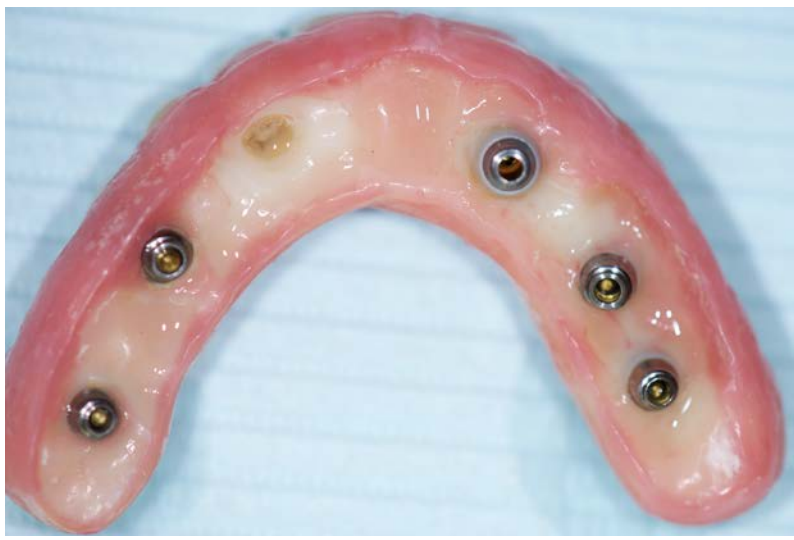The first step in the healing process was to remove Zirconia A and seat a redesigned PMMA. The new design shape fit the patient’s face and created superior anatomic tooth and soft tissue esthetics that rendered a very natural-looking appearance (Fig 14). The patient was asked to assess the esthetic components and provide final approval. During this phase, both the surgical modification of keratinized tissue and the modification of the intaglio surface of the PMMA were performed to resolve the persistent mucositis and be-



**Figure 13:** Compromised soft tissues under Zirconia A (ridge lap design). There is inflammation, bleeding, and pocketing around the implant in the upper right lateral/canine area with irregular and redundant tissue present.



**Figure 14:** New PMMA seated and in function. Evaluation of occlusion, function, oral hygiene, esthetics, and modifications to the intaglio surface can be made if needed.



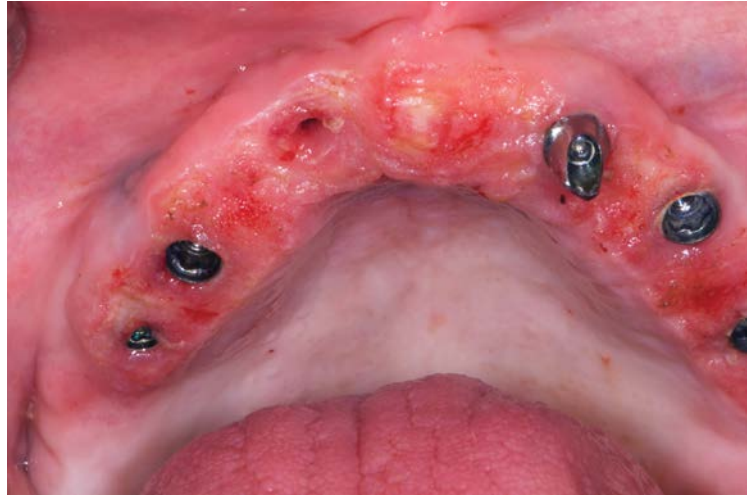
**Figure 15:** In preparation for incremental layering of composite, the PMMA intaglio surface is treated with hydrofluoric acid. Once the etch is washed off and the surface is dry, an adhesive is applied.



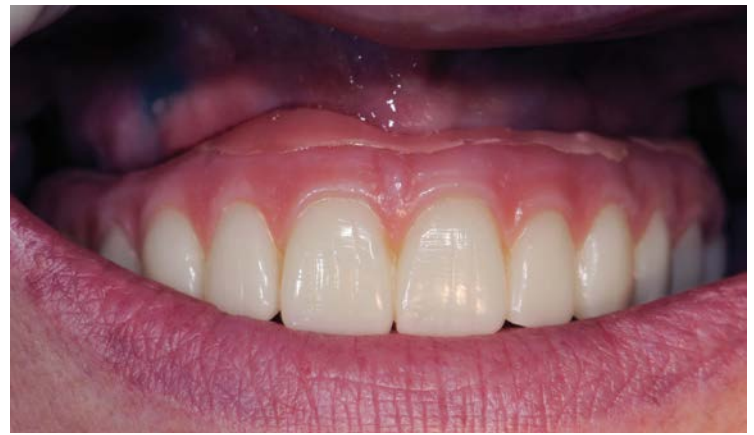ginning peri-implantitis. The goal of these modifications was to create a flat, keratinized, firm surface upon which Zirconia B would intimately contact to form an ovate-like pontic effect. The patient was asked to critically test function, comfort, and ability to perform oral hygiene easily.

Six weeks after PMMA delivery the soft tissue demonstrated a significant reduction of inflammation and swelling, resulting in a space developing between the alveolar ridge tissues and the prosthesis. Probing depths were still present in the upper right canine area and the topography of the tissue remained irregular. The intaglio surface of the PMMA was prepared with 9.6% hydrofluoric acid (Porcelain Etch Gel, Pulpdent; Watertown, MA), followed by application of Scotchbond Universal Adhesive (3M ESPE) and light-curing (Fig 15). Local anesthesia was administered to the maxillary soft tissues and bone sounding was performed with a periodontal probe to evaluate the thickness of tissue positioned directly under the PMMA. A bipolar electrosurgery unit was used to reduce height of the abundant tissue to no greater than 3 mm and to create a flat to slightly concave shape (Fig 16). Once the soft tissues were modified, the PMMA surface was modified by adding increments of AnaxGUM gingiva composite shade brown/pink (AnaxDENT; Stuttgart, Germany), light-cured, and tried in until the proper shape and contact with the tissue were achieved (Fig 17). The ideal shape of the intaglio surface was slightly convex and at medial and distal intervals adjacent to the implants space was maintained for the introduction of a floss threader.

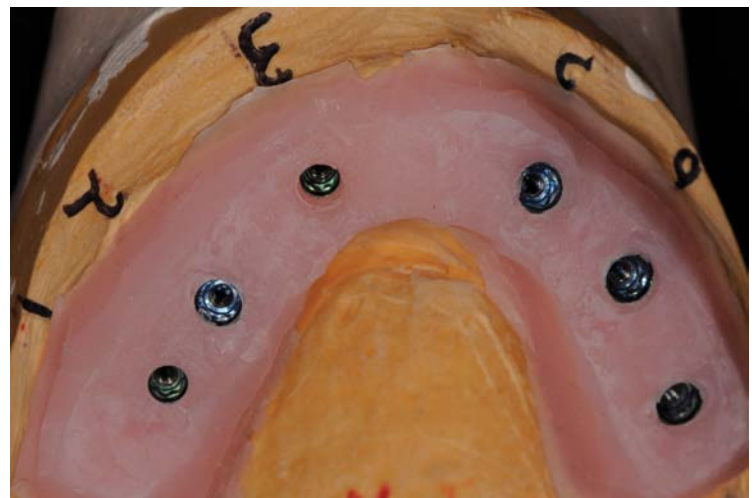After eight weeks of healing, a new tissue model was recorded by removing the modified PMMA from the patient's mouth and placing it on the master cast without the existing soft tissue model present. All implant abutments were seated and screwed into the correct position. A new tissue model was fabricated by flowing Gingifast CAD soft silicone (Zhermack; Badia Polesine [RO], Italy) material (Fig 18) between the PMMA and stone cast. Once set, the PMMA was removed from the master cast and again seated in the patient's mouth to serve as a provisional during the final prosthesis fabrication. The new soft tissue model was sent to the laboratory and merged with the existing file to fabricate the exact intaglio shape desired for the final zirconia bridge. The Zirconia B was completed and delivered; it was seated in September 2014 and evaluated for esthetics, occlusal harmony, phonetics, and comfort. The patient was given specific instructions on oral hygiene protocol and scheduled for an initial one-month recall followed by four three-month recalls, after which, depending upon the patient's overall implant and prosthesis health, a permanent schedule will be designed.



**Figure 16:** Soft tissue modification performed by flattening the tissue surface and reducing tissue height around all implants to no greater than 3 mm. Note upper left canine implant with custom abutment in place.



**Figure 17:** Contour of the PMMA intaglio surface after modification. Note right lateral area where tissue reduction was significant.



**Figure 18:** Soft tissue model captured by placing the PMMA on the master cast, then flowing Gingifast CAD soft silicone between the modified intaglio surface and the adjacent cast.



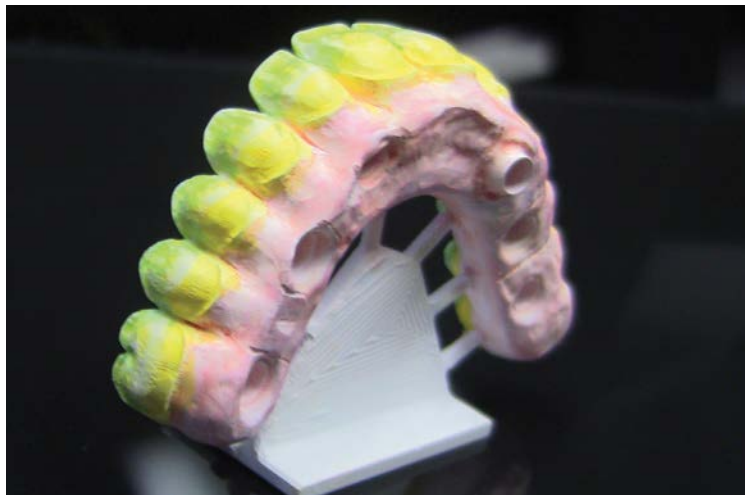# CLINICAL COVER CASE

## Comparison of Zirconia A and Zirconia B

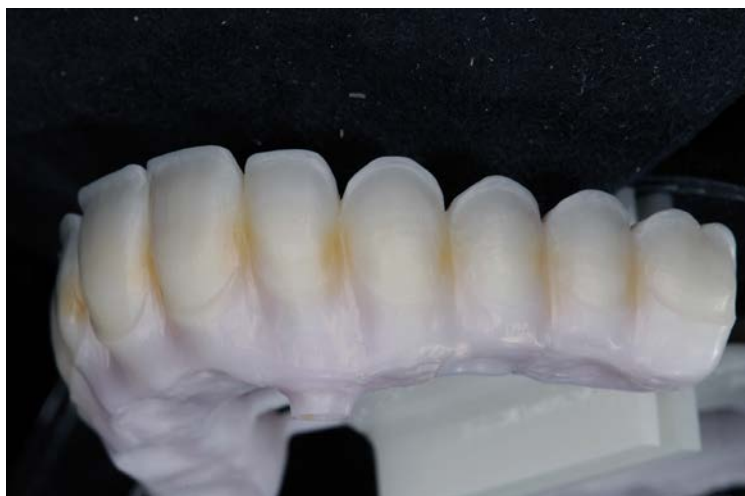Patients need to feel that technology is an enhancement to the human experience, not a replacement for humans. Some manufacturers and service providers believe that if you have the same machine, you will have the same outcome. This is completely false. Acceptable esthetics can be accomplished with a monolithic prosthesis fabricated from a milled block of zirconia that the technician then shapes and texturizes artistically. He or she subsequently stains it in the green stage to create a foundation shade before sintering and then completing the surface staining to achieve the desired esthetic outcome.

To maximize the three-dimensional appearance in this case, the zirconia was stained in the green stage with Zirkozahn's water-based liquid Tissue A, and between the root eminence with liquid Tissue B. Critical evaluation of the attached gingiva, marginal gingiva, and to the cervical tooth structure and staining vary among laboratory technicians (Fig 19). The technician can minimally cut back the milled and sintered zirconia in non-stress bearing areas only, and then fire the porcelain directly to the zirconia. Minimal layering of porcelain allows for additional micro esthetics (Fig 20).

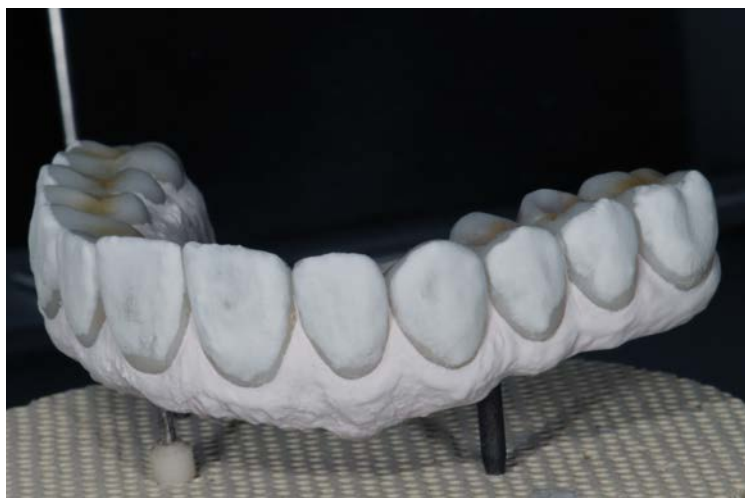Based on the patient's natural shade, Laboratory B utilized three different tissue ceramics. First, a dark pink Creation Zi-CT G1 (Jensen Dental; North Haven, CT) was used for the background, then bonded and baked at a high temperature. Creation Zi-CT G2 and G3 were used for the final buildup. For the final bake the same porcelain was used and highlighted with PS-0 and a mixture of PS-0 with HT-51. It is possible to layer compatible zirconia porcelain directly to the zirconia frame, which gives more depth, vibrancy, and a lifelike appearance (Fig 21). Zirconia A (Fig 22) was monolithic, whereas Zirconia B (Fig 23) was minimally layered with porcelain on the facial aspect of the teeth. Because Zirconia A did not fill out the buccal corridors, shadowing was present when the patient smiled (Fig 24). In Zirconia A, the size of the arch was not congruent with the size and shape of the patient's face. This caused an exaggeration of the overall fullness of the patient's face and was less attractive. In contrast, Zirconia B's correct midline and inclinations of the laterals and premolars provide a softer, feminine silhouette; the labial incisal inclination of the anterior teeth is lifelike and esthetically superior (Fig 25). Layering of porcelain allows for additional micro esthetics, and the amount of gingiva shown when the patient is in full smile as well as retracted appears as if she was born with it. Figure 26 shows the two different bridges superimposed to illustrate the differences when the patient smiles.



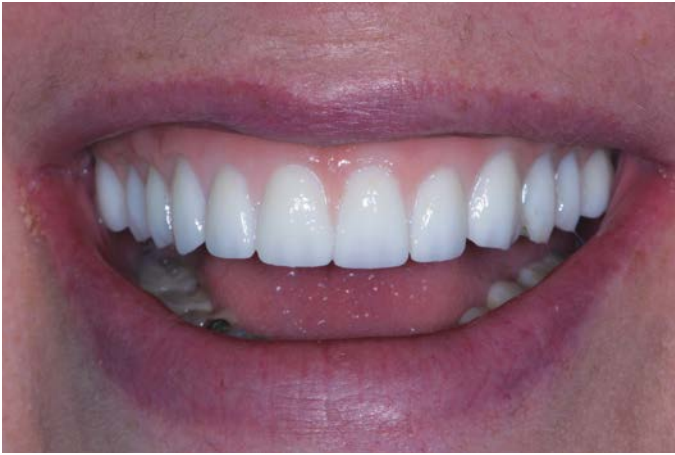**Figure 19:** Zirconia was stained in the green stage with an acid-free water based color liquid.



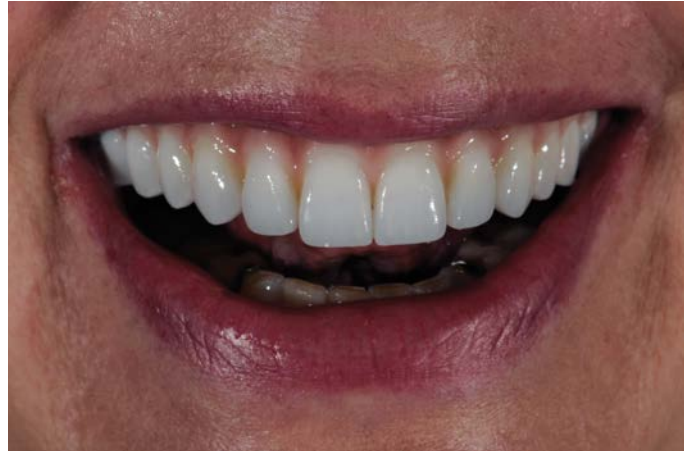**Figure 20:** Minimally cut back in the green stage and sintered zirconia in non-stress bearing areas only.



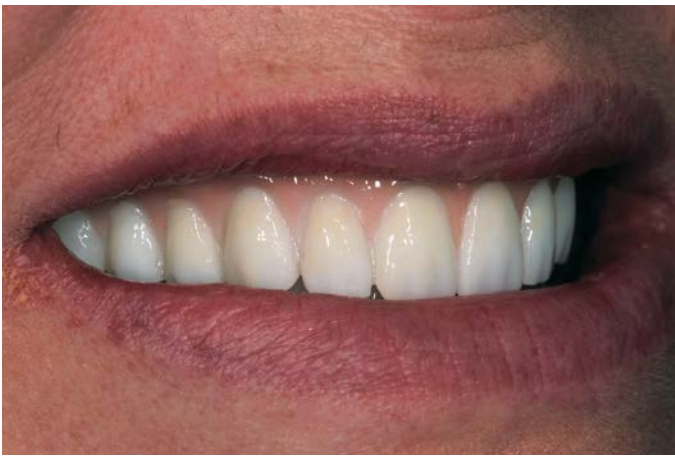**Figure 21:** Ceramic layering, which gives more depth, vibrancy, and a lifelike appearance.



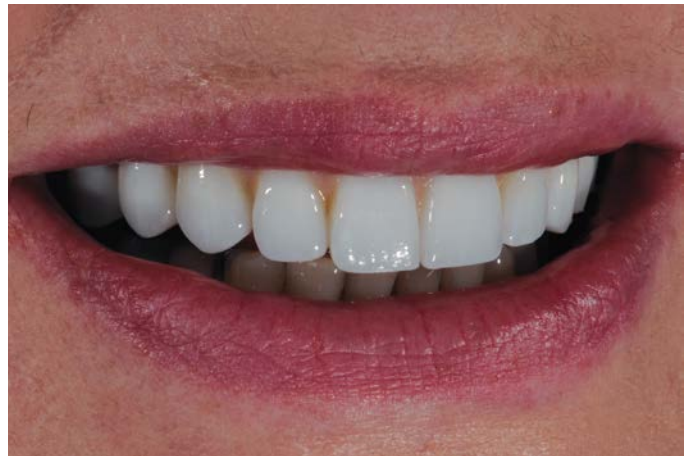**Figure 22:** Zirconia A; deficient buccal corridors and incisal edges of maxillary teeth do not follow the lip lines during smiling. The occlusal plane is flat and gingival tissue lacks anatomy.



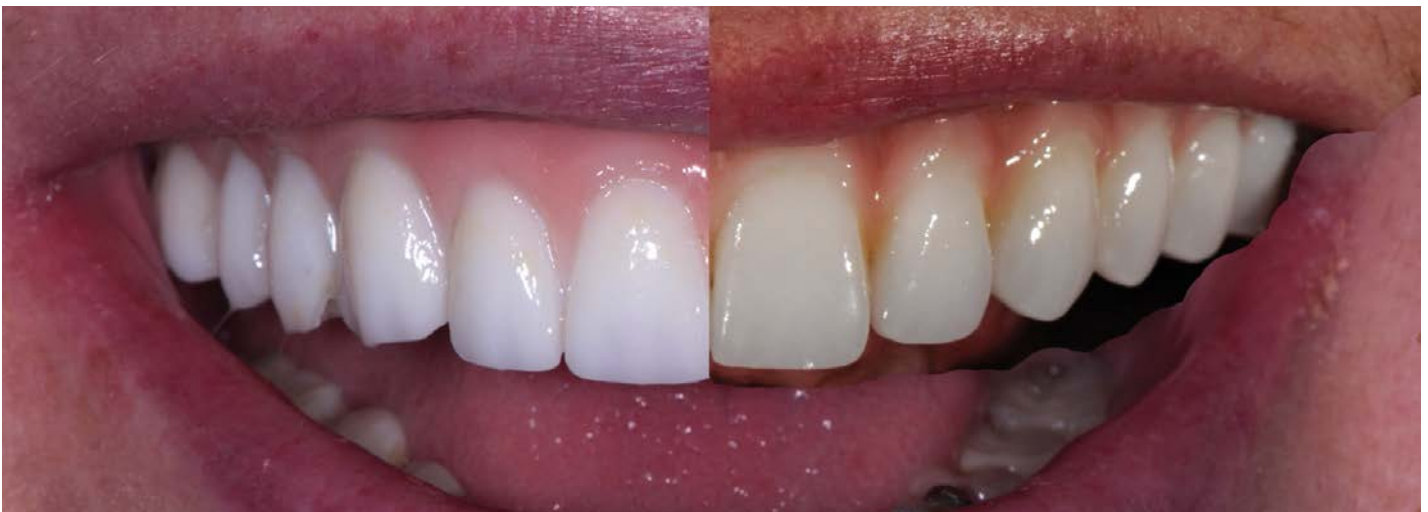**Figure 23:** Zirconia B; full buccal corridor and the incisal edge mimic the smiling lip line. Note the development of marginal and attached gingival tissues.



**Figure 24:** Zirconia A; deficient labial fullness of the soft tissue one-third to incisal one-third give a flat two-dimensional appearance. The occlusal plane drops posteriorly, impinging on the lower lip during smile. Soft tissues are poorly defined and unnatural.



**Figure 25:** Zirconia B; correct labial and incisal fullness, and the occlusal plane travels upward and follows the lower lip line.



**Figure 26:** The two different zirconia prostheses superimposed to illustrate the differences when the patient smiles. Notice the difference in the buccal corridor and shadowing. Note the modification of the incisal edge position and three-dimensional quality of Zirconia B.



# CLINICAL COVER CASE

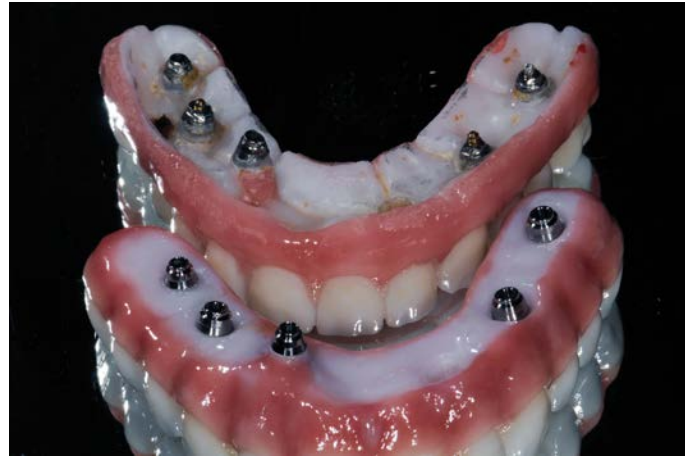With Zirconia A, a flapless surgical protocol and the placement of a ridge lap-shaped prosthesis resulted in increased mucositis and peri-implantitis. **Figure 27** shows the comparison of the intaglio surfaces in the old and new restorations. Surgically modified soft tissue healed to the ideally shaped PMMA and resulted in healing similar to an ovate-like pontic, with probing depths around the implants of no greater than 3 mm and minute spaces adjacent to the implant abutments for a floss threader (**Fig 28**). Combining the widely accepted design of the slightly convex intaglio surface with the surgical soft tissue modification presented in this article resulted in elimination of chronic inflammation and allowed the patient to practice effective oral hygiene while wearing the final FAISZ (Zirconia B) (**Fig 29**).

## Summary

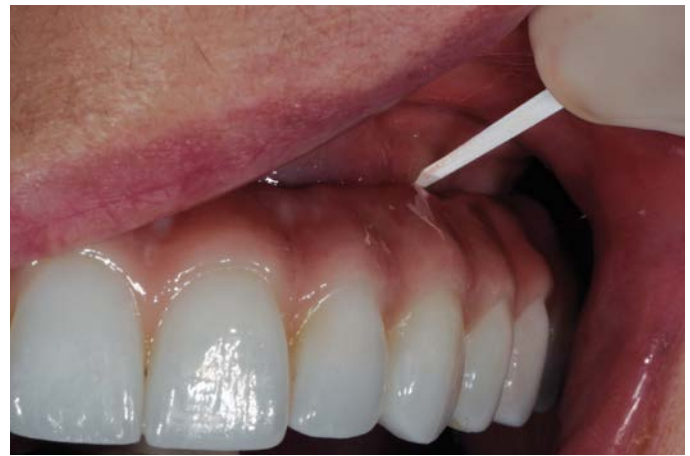The essentials for achieving quality esthetic and impeccable oral hygiene compatibility for the Prettau FAISZ prosthesis are many (**Figs 30 & 31**). Diagnostic records and detailed reports on the existing conditions of facial dimension, dental occlusion, bone and soft tissue topography, and nuances of the patient's smile are all components critical to success. Developing a clear and precise plan prior to beginning the surgical treatment eliminates potential disasters. The use of all-zirconia material allows biocompatible enhancement as well as the advantage of a milled rather than cast framework with greater wear resistance and less intra-arch space required. The survival of the implants is related directly to the proper prosthetic form, and utilizing a PMMA as a soft tissue management tool to decrease mucositis and potential peri-implantitis is invaluable for a favorable long-term prognosis. The last and most significant factor is the ability to collaborate with like-minded team members who understand the patient's desires.<sup>28</sup> High standards and a clear vision of what is possible are needed to exceed patients' expectations. To please our patients it is imperative not to become complacent because of technology and say, "it is good enough." It is the laboratory technician's artistic responsibility to bring life to modern dentistry and use CAD/CAM technology as a tool and not as a panacea<sup>29</sup> (**Fig 32**).

## Acknowledgments

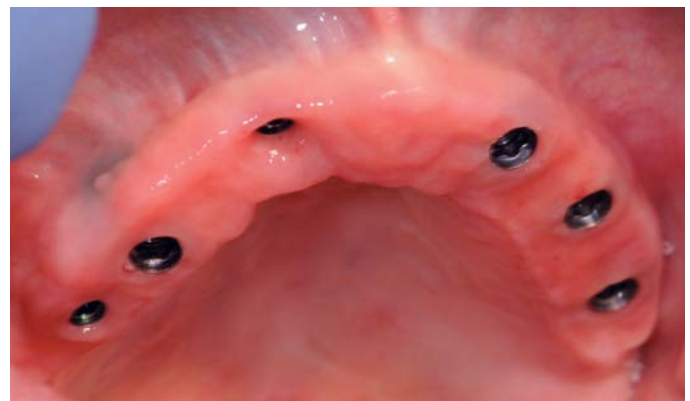*The authors thank Alessandro Cucchiaro, Lien Huynh, Katana Kinsey, and Ashley Wayne Michalec at Zirkozahn for their generosity and assistance with the screw-retained implant Prettau zirconia. In addition, thanks go to Dr. Laura Justice (Lexington, KY) and her assistant, Kristi Sharpe, for their clinical support and esthetic vision. Dr. Pearson also expresses gratitude to Dr. Edward Mills (Atlanta, GA) for being a patient and generous teacher; and to her colleagues in the Advanced Dental Implant Studies group.*



**Figure 27:** Comparison of intaglio surfaces of Zirconia A and Zirconia B.

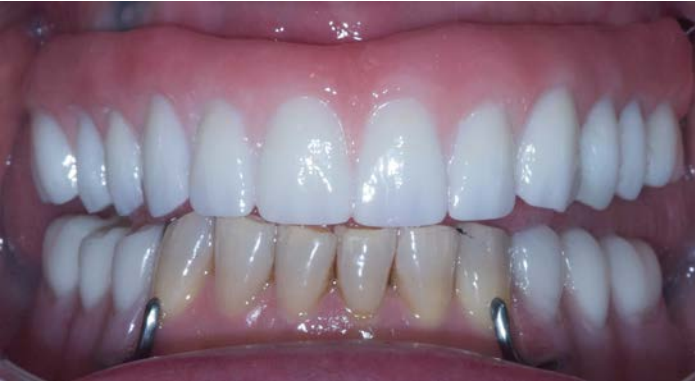

**Figure 28:** The patient uses a floss threader and an oral irrigator.

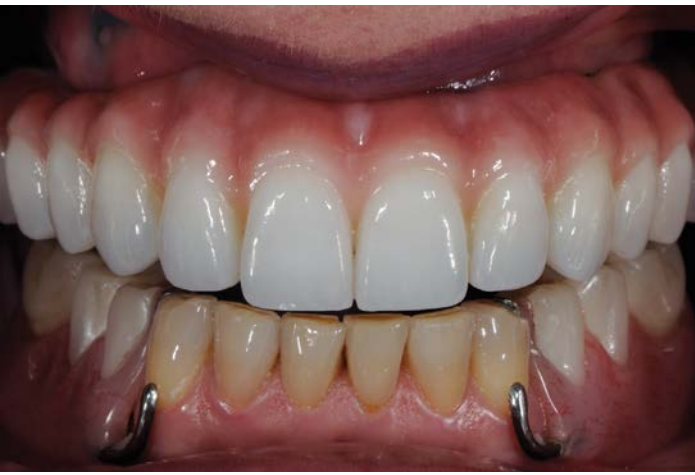

**Figure 29:** Clinical appearance 12 weeks after seating of Zirconia B. The tissue healed intimately to the convex intaglio surface.

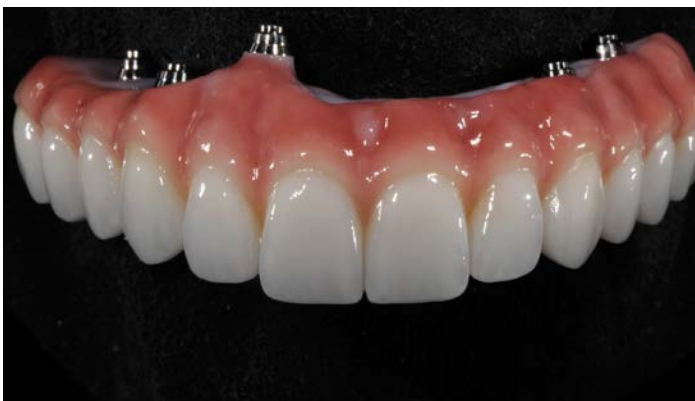



**Figure 30:** Zirconia A.



**Figure 31:** Zirconia B.



**Figure 32:** Image showing the artistic ability of Laboratory B and what is truly possible.

## References

1. Yan C, Ye L, Zhen J, Ke L, Gang L. Neuroplasticity of edentulous patients with implant-supported full dentures. *Eur J Oral Sci.* 2008 Oct;116(5):387-93.
2. Yi SW, Ericsson I, Kim CK, Carlsson GE, Nilner K. Implant-supported fixed prostheses for the rehabilitation of periodontally compromised dentitions: a 3-year prospective clinical study. *Clin Implant Dent Relat Res.* 2001 2001;3(3):125-34.
3. Hjalmarsson L. On cobalt-chrome frameworks in implant dentistry. *Swed Dent J Suppl.* 2009;(201):3-83.
4. Jacobson TE, Krol AJ. A contemporary review of the factors involved in complete dentures. Part II: stability. *J Prosthetic Dent.* 1983 Feb;49(2):165-72.
5. Sanz M, Naert I. Biomechanics/risk management (Working Group 2). *Clin Oral Implants Res.* 2009 Sep;20 Suppl 4:107-11.
6. Anchieta RB, Archangelo CM, Rocha EP, Martin M Jr., Gil NR, de Almeida EO, Freitas AC Jr. Complications in implant dentistry. *Int J Clin Dent.* 2013;6(2):97-111.
7. Misch CE. *Contemporary implant dentistry.* 2nd ed. St. Louis: Mosby; 1999. p 67-71.
8. Nold SL, Horvath SD, Stampf S, Blatz MB. Analysis of select facial and dental esthetic parameters. *Int J Periodontics Restorative Dent.* 2014 Sep-Oct;34(5):622-9.
9. Misch CE, Dietsch-Misch F. Diagnostic casts, pre-implant prosthodontics, and surgical templates. In: Misch CE, editor. *Contemporary implant dentistry.* 2nd ed. St. Louis: Mosby; 1999. p. 135-50.
10. Patil SB, Naveen BH, Patil NP. Bonding acrylic teeth to acrylic resin denture bases: a review. *Gerodontology.* 2006 Sep;23(3):131-9.
11. Helvey G. Zirconia and computer-aided design/computer-aided manufacturing (CAD/CAM) dentistry. *Inside Dent.* 2008 Apr;4(4). Available from: <https://www.dentalaegis.com/id/2008/04/clinical-treatment-options-zirconia-and-computer-aided-design-computer-aided-manufacturing-cad-cam-dentistry>.
12. Albashaireh ZS, Ghazal M, Kern M. Two-body wear of different ceramic materials opposed to zirconia ceramic. *J Prosthet Dent.* 2010 Aug;104(2):105-13.
13. Pappaspyridakos P, Lal K. Computer-assisted design/computer-assisted manufacturing zirconia implant fixed complete prostheses: clinical results and technical complications up to 4 years of function. *Clin Oral Implants Res.* 2013 Jun;24(6):659-65.

14. Rojas-Vizcaya F. Full zirconia fixed detachable implant-retained restorations manufactured from monolithic zirconia: clinical report after two years in service. *J Prosthodont.* 2011 Oct;20(7):570-6.
15. Raigrodski A. Managing prosthetic challenges with a CAD/CAM zirconia restoration. *J Cosmetic Dent.* 2014 Summer;30(2):40-52.
16. Güth JF, Almeida E, Silva JS, Beuer FF, Edelhoff D. Enhancing the predictability of complex rehabilitation with a removable CAD/CAM-fabricated long-term provisional prosthesis: a clinical report. *J Prosthet Dent.* 2012 Jan;107(1):1-6.
17. Zinner ID, Markovits S, Jansen CE, Reid PE, Schnader YE, Shapiro HJ. Sequential provisional implant prosthodontics therapy. *Gen Dent.* 2012 Nov-Dec;60(6):508-18.
18. Schneider D, Marquardt P, Zwahlen M, Jung RE. A systematic review on the accuracy and the clinical outcome of computer-guided template-based implant dentistry. *Clin Oral Implants Res.* 2009 Sep;20 Suppl 4:73-86.
19. Hultin M, Svensson KG, Trulsson M. Clinical advantages of computer-guided implant placement: a systematic review. *Clin Oral Implants Res.* 2012 Oct;23 Suppl 6:124-35.
20. van Steenberghe D, Glauser R, Blomback U, Andersson M, Schutyser F, Pettersson A, Wendelhag I. A computed tomographic scan-derived customized surgical template and fixed prosthesis for flapless surgery and immediate loading of implants in fully edentulous maxillae: a prospective multicenter study. *Clin Implant Dent Relat Res.* 2005;7 Suppl 1:S111-20.
21. Komiyama A, Klinge B, Hultin M. Treatment outcome of immediately loaded implants installed in edentulous jaws following computer-assisted virtual treatment planning and flapless surgery. *Clin Oral Implants Res.* 2008 July;19(7):677-85.
22. Peñarrocha-Oltra D, Covani U, Aparicio A, Ata-Ali J, Peñarrocha-Diago M, Peñarrocha-Diago M. Immediate versus conventional loading for the maxilla with implants placed into fresh and healed extraction sites to support a full-arch fixed prosthesis: nonrandomized controlled clinical study. *Int J Oral Maxillofac Implants.* 2013 Jul-Aug;28(4):1116-24.
23. Pozzi A, Tallarico M, Mangani F, Barlattani A. Different implant impression techniques for edentulous patients treated with CAD/CAM complete-arch prostheses: a randomised controlled trial reporting data at 3 years post-loading. *Eur J Oral Implantol.* 2013 Winter;6(4):325-40.
24. Rutkunas V, Ignatovic J. A technique to splint and verify the accuracy of implant impression copings with light-polymerizing acrylic resin. *J Prosthet Dent.* 2014 Mar;111(3):254-6.
25. Busayan MM, Yunus NB. Passive fit in screw retained multi-unit implant prosthesis understanding and achieving: a review of the literature. *J Indian Prosthodont Soc.* 2014 Mar;14(1):16-23.
26. Lang NP, Tonetti MS. Peri-implantitis: etiology, pathogenesis, prevention, and therapy. In: Froum SJ, editor. *Dental implant complications.* Chichester, West Sussex (UK): Wiley-Blackwell; 2010. p. 119-33.
27. Agnini A, Dondi L, Dondi M, Agnini AM. Complex case rehabilitation in light of new technologies. *J Cosmetic Dent.* 2014 Winter;29(4):18-30.
28. Adar P. Communication: the ultimate in synergy. *Inside Dent.* 2005 Oct;1(1):82-3.
29. Adar P. Incorporating the human touch in restorative outcomes. *Inside Dent Technol.* 2014 Dec;(4):52-6. **jCD**

---

Maxillary arch forms, the trajectory of the premaxillary alveolus, and the biomechanics of implants under lateral and anterior cantilever forces must be considered for a favorable long-term prognosis.

---



Mr. Adar owns a private laboratory in Atlanta, Georgia. He is an adjunct clinical professor at Tufts University School of Dental Medicine, a Fellow of the American Academy of Esthetic Dentistry, and an AACD Accredited Member.



Dr. Pearson has been in private practice for more than 30 years in Lexington, Kentucky. She is an AACD Accredited Member and a fellow of the AAID.

Disclosures: The authors did not report any disclosures.



**SimplePay**™  
No Credit Check Financing

**Introducing the Latest  
AACD Member Benefit**

**AACD** American Academy  
of Cosmetic Dentistry®  
BUSINESS PARTNER

**FINANCE 100% OF YOUR PATIENTS!**

SimplePay supplements your existing financing options by giving you the ability to approve the patients who are being declined or are simply not applying.

**Your Patients Gets**

No Credit Check Approval  
No Interest to Pay, Ever!  
Affordable Payments

**You Get**

Increased Treatment Acceptance  
Guaranteed Stream of Income  
Happy Patients

As a valued AACD Member, you get access to SimplePay's Patient Financing as a benefit to your membership. Saving you \$199/month!

**Activate Your AACD Member Benefit Today!**

Call our AACD Line  
(480) 787-5065

Visit Online  
[SimplePay.com/AACD](http://SimplePay.com/AACD)



# Life-Changing Diastema Closure

Direct Composite Restorations with Minimal Intervention

Aikaterini Papathanasiou, DDS, CAGS, FIADFE, FICD  
Charilaos Asikis, DDS, CAGS, FICD

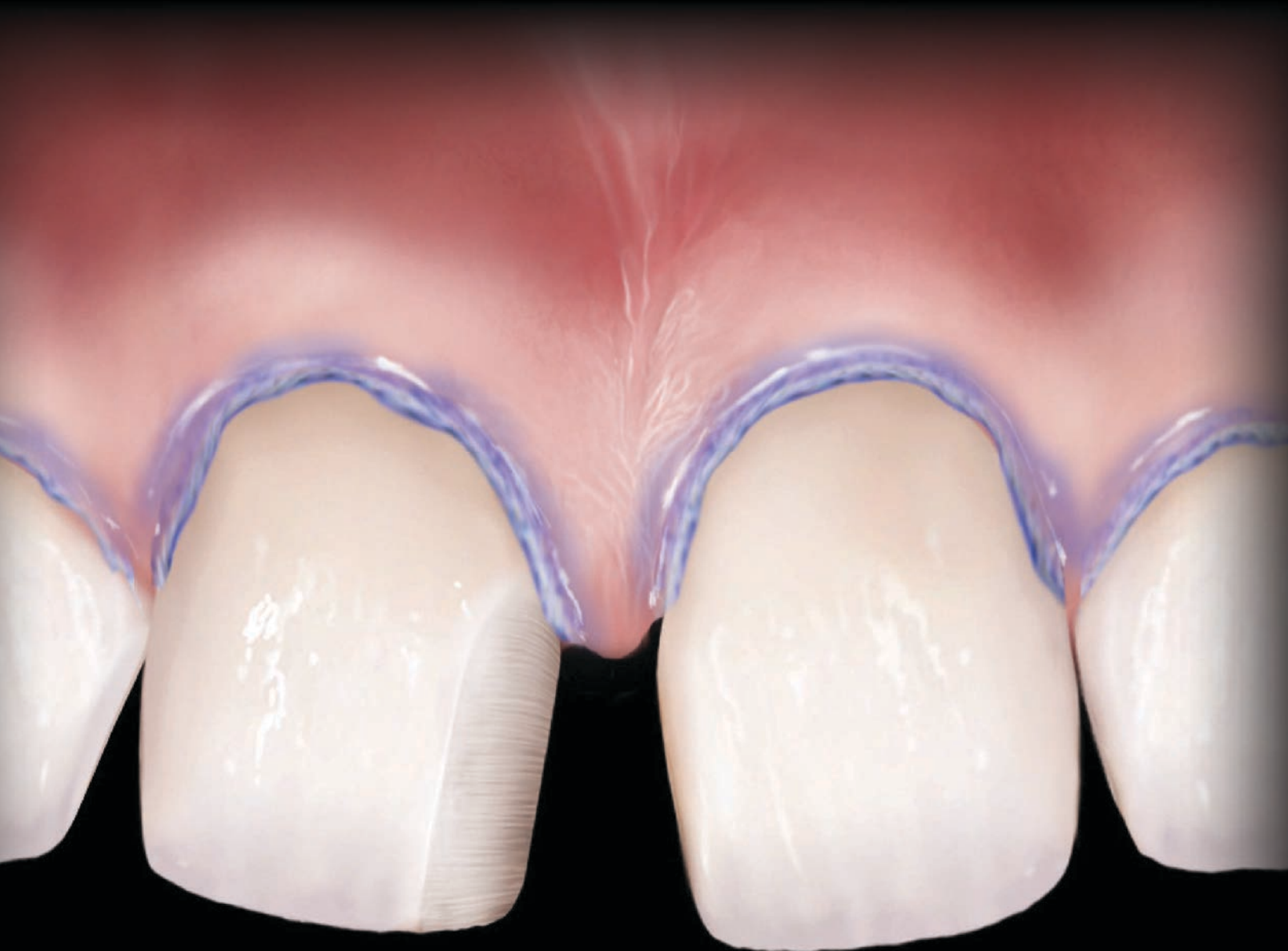
## Abstract

In today's esthetics-conscious society, an unesthetic smile can cause many social, emotional, and psychological issues for an individual. Many patients do seek restorative treatment to improve their smile, choosing to maintain a cautious and conservative approach. This article describes the treatment of a patient with large diastemata between his discolored maxillary anterior teeth. The treatment consisted of a combination of in-office and take-home tooth whitening, followed by direct composite resin restorations. This case demonstrated exceptional results with the most minimally invasive treatment approach.

**Key Words:** diastema closure, direct composite, minimally invasive dentistry, esthetic dentistry, composite veneer

## Introduction

Cosmetic dentistry professionals are well aware of the social, emotional, and psychological effects that having an unesthetic smile can cause many individuals to endure throughout their lives. Facial esthetics has been shown to significantly affect self- and social perceptions,<sup>1</sup> and concern over facial appearance and social attractiveness can influence psychological development from childhood to adulthood.<sup>2,3</sup> Yet, whether due to dental anxiety or the financial and time commitments necessary for dental intervention, many do not seek restorative treatment to correct the dental problems negatively affecting their smile.



**“ ...concern over facial appearance and social attractiveness can influence psychological development from childhood to adulthood. ”**

## Diastemata Treatments

Diastemata, a common condition causing unesthetic smiles, can significantly influence patients' perception of themselves. One of the most frequent reasons why patients seek treatment,<sup>4</sup> these interdental spaces ultimately compromise dentofacial harmony, interfering with smile attractiveness.<sup>5-7</sup> In adult populations, the reported incidence of anterior spaces ranges from 1.7 to 38% in different populations.<sup>8-12</sup>

When patients do seek restorative treatment to improve their smile, they often want a cautious and conservative approach. The minimally invasive treatment approach results in destroying less healthy tooth structure and avoiding a cycle of restoration treatments.<sup>13</sup> This approach has also been shown to meet the esthetic results patients and clinicians desire.<sup>14</sup> Restorative treatments therefore strive to close diastemata by establishing adequate interproximal contact and achieving an esthetic emergence profile of the affected teeth, with the interdental papilla filling the space appropriately underneath the contact area.<sup>15</sup> Given the combined esthetic, functional, and periodontal implications associated with treating diastemata, common techniques to correct them have traditionally included orthodontics, indirect prosthodontic treatments, direct composite restorations, or a combination of these.<sup>16</sup>

### Orthodontics

Orthodontic treatment to close diastemata requires no tooth reduction, causes minimal trauma to the pulp, and the teeth maintain their original shape and color.<sup>17</sup> However, orthodontics typically involves a lengthy treatment time with many appointments, and includes the placement of brackets and wires, which deters many adult patients. Orthodontics also is often the most costly treatment for diastemata. Furthermore, depending on the size of the diastemata, orthodontic treatment may incorporate other interventions if the arches are larger than the tooth dimensions.<sup>17</sup>

### Indirect Prosthodontics

Although indirect prosthodontic treatment also involves significant financial expense,<sup>16</sup> these restorations can be accomplished relatively quickly to provide a highly esthetic result. Compared to direct restorations, indirect restorations (i.e., veneers) typically last a long time and are stronger than composite.<sup>17</sup> Porcelain veneers also resist staining and avoid shade changes over time, but achieving the anticipated results can be challenging, since detailed communication between the patient, clinician, and laboratory is required.<sup>17</sup> Additionally, indirect restorative treatments typically require the removal of tooth structure, an irreversible procedure.<sup>18</sup>

“In addition to minimal intervention, patients appreciate other advantages of direct composite restorations, including reversibility of the procedure, lower cost, and relative ease of altering materials when necessary.”

Today's esthetic restorative principles advocate treating as conservatively as possible; this is in the patient's best interests as it avoids the unnecessary removal of healthy tooth structure.<sup>19</sup>

### Direct Composite

Among the myriad options for more conservative closing of diastemata is the use of proximally applied composite, which provides a more practical and responsible treatment.<sup>15,20</sup> Not surprisingly, the practice of recontouring teeth with direct composite resin buildups has increased due to the esthetic, functional, and biologically sound nature of these restorations, which also have demonstrated clinically promising survival rates.<sup>21</sup> In addition to minimal intervention, patients appreciate other advantages of direct composite restorations, including reversibility of the procedure, lower cost, and relative ease of altering materials when necessary.<sup>22</sup> This technique contours the tooth shape, providing a pleasingly symmetrical and harmonious tooth arrangement,<sup>23</sup> and restores esthetic balance between the soft and hard tissues.<sup>24</sup>

However, while direct composite techniques can be economical and successful, they present unique challenges in achieving satisfactory proximal contacts and contours, and clinical and esthetic results.<sup>16,18</sup> The resin composite can stain, change color over time, and not last as long as porcelain.<sup>17</sup> Additionally, due to its fragile nature, patient habits such as grinding need to be eliminated.<sup>17</sup>

Therefore, dentists must demonstrate specific placement skills to close a diastema and achieve functional and esthetic results, after first selecting the ideal material. Many skilled clinicians utilize freehand application of composite; however, that requires experience and proficiency. For the novice, using silicone indices from a diagnostic wax-up may prove useful.

Universal nanohybrid composite can provide the strength and long-term esthetics required for diastema closure with a direct restorative technique. With improved working time and handling characteristics, this type of material allows the clinician ample time to shape and contour the restorations to ideal anatomical form. Additionally, some nanocomposites (e.g., Tetric EvoCeram, Ivoclar Vivadent; Amherst, NY) provide a “chameleon” effect, as its natural shades blend with the surrounding dentition to best mimic nature and ensure esthetic harmony. This material's handling characteristics and strength ensure functional durability and restoration longevity.

Yet even with the ideal direct composite material, dentists must have an accurate understanding of the patient's ultimate esthetic desires. Since many patients have waited years to improve the appearance of their smile, it is vital for clinicians to listen to and take into account all of their preferences, including timeline, financial considerations, tooth conservation, and final overall esthetics. This frequently requires use of an intraoral mock-up to ensure clear communication of expectations and visualization of anticipated results.



## Case Presentation

A 37-year-old male presented with the chief complaints of dissatisfaction with his smile and the gaps between his teeth (Fig 1). The patient exhibited very low self-esteem, along with some psychological and emotional issues due to his smile. He recalled being bullied in school by his classmates because of his unattractive smile, and he stated that his smile made him unhappy. After feeling intimidated about smiling for most of his life, he decided to inquire about restorative treatment.

The patient consulted prosthodontists, orthodontists, and general dentists about potential options, which included orthodontics, crowns, prophylactic endodontic treatment, extractions, and implant placement. After meeting with the primary author, who suggested the most conservative treatment possible, the patient selected minimal intervention to redesign his smile. Although orthodontics was recommended as the treatment of choice for his condition, the patient refused this option, as he felt that braces would further negatively influence his appearance.

### Treatment Planning

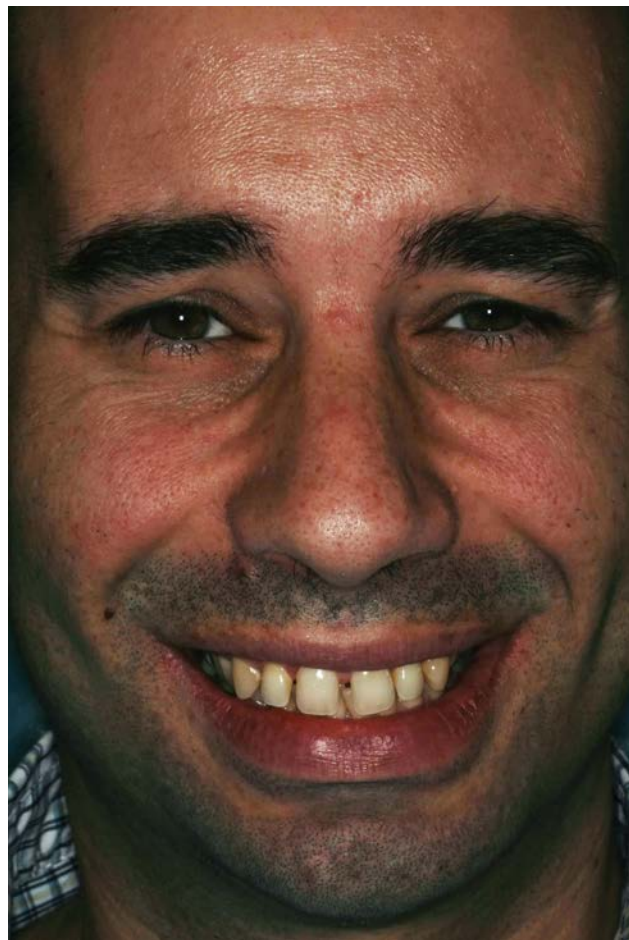When the patient returned for a comprehensive oral examination, preoperative photographs were taken (Fig 2). The patient exhibited a deep bite, facially positioned teeth, and Class II malocclusion (Figs 3 & 4). To provide highly esthetic results with minimal intervention, tooth whitening and diastema closure with mesial composite on teeth #6-12 were planned.

An intraoral mock-up was completed to determine whether leaving small diastemata would be necessary to ensure a natural-looking smile and avoid unesthetically wide anterior teeth (Figs 5 & 6). Composite resin of the initial tooth shade was placed without preparing the teeth, using etchant, or a bonding agent, then light-cured for two to five seconds. This intraoral mock-up allowed the dentist and patient to visualize the desired final results, after which the composite was easily removed with a dental instrument.

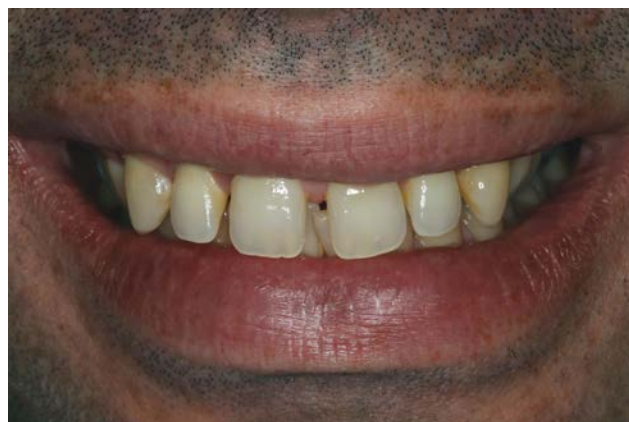Following the intraoral mock-up, the patient and dentist discussed the pros and cons of treatment, including diastema and occlusion considerations, such as protrusive and lateral excursions. Although the patient exhibited malocclusion, the mock-up revealed that treatment would not affect his bite and that no diastemata would be necessary for a natural-looking smile. By placing composite out of occlusion, the restorations would avoid the direct effects of mastication forces and last and function longer. The patient decided to begin this most conservative and inexpensive option, knowing he could always choose a more aggressive treatment plan if the restorations failed or the esthetics were not as expected.

### Clinical Protocol

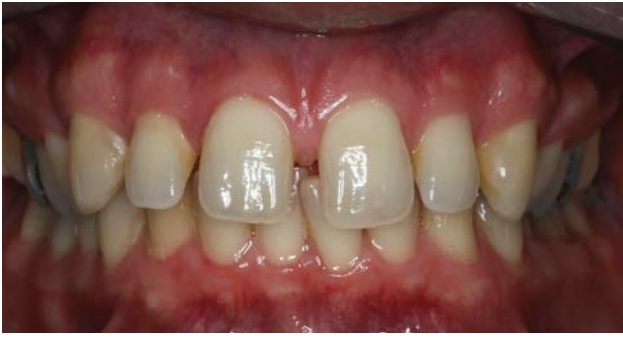The patient returned for prophylaxis and alginate impressions for fabricating the bleaching tray. In-office tooth whitening with a bleaching gel (Opalescence Boost, Ultradent Products; South Jordan, UT) was performed at the next visit. Initial tooth shades were A3 and A3.5 (Vita Shade Guide, VITA; Bad Säckingen, Germany). After the in-office whitening, the patient received take-



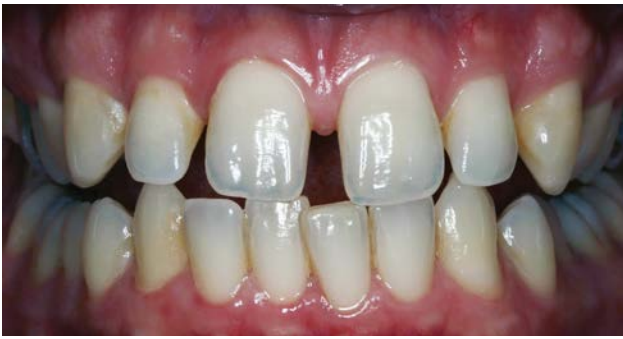**Figure 1:** The patient presented with the chief complaints of gaps in his teeth and dissatisfaction with his smile.



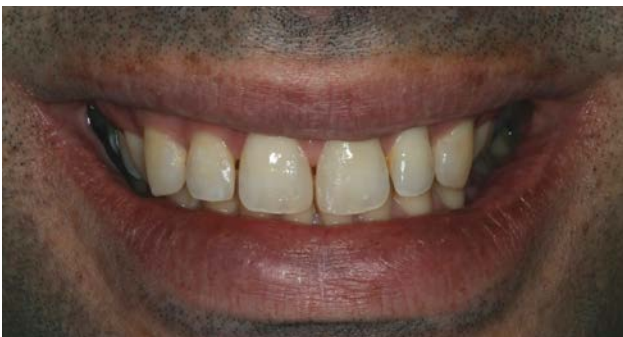**Figure 2:** Preoperative full-smile view.



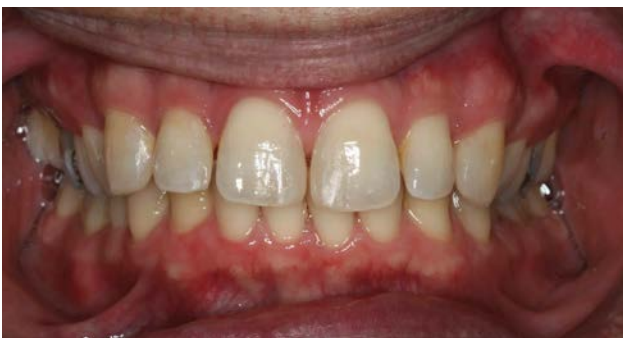**Figure 3:** Retractors were used to capture images of the patient's tooth positions, angles, and diastemata widths.



**Figure 4:** During the initial evaluation, the protrusion was checked and the occlusion evaluated.



**Figure 5:** The initial intraoral mock-up was completed to help the patient and clinician visualize different results.



**Figure 6:** The intraoral mock-up involved no tooth preparation to demonstrate anterior diastema closure.

home whitening materials (Opalescence PF10%) to be used for seven days (Fig 7).

The patient returned after the seven days to evaluate the results of the combination of in-office and at-home whitening, which produced a final shade lighter than B1 (Fig 8). The widths of the teeth and diastemata were then measured, and another intraoral mock-up was finalized based on facial symmetry. Due to the oxidizing effects of whitening on teeth and bond strengths, final composite placement would not be performed until 10 to 14 days later.<sup>25,26</sup>

After two weeks, the patient returned for composite placement on the mesial surfaces of #6-12. As mentioned earlier, the desired dimensions of each tooth had already been determined during the intraoral mock-up. A single cord (Ultrapak E Cord #00, Ultradent) was placed subgingivally for rapid tissue displacement (Fig 9). A flame-shaped fine diamond bur (57F) and carbide bur (7104) were used to create a bevel of a 2- to 3-mm width on the mesial buccal line angles of #6-12 (Fig 9). The diastema between #8 and #9 was treated first. Tooth #8 was total-etched with a 35% phosphoric acid etchant (Ultra-Etch, Ultradent) on the enamel for 30 seconds, rinsed, and dried (Fig 10). A bonding agent (Prime & Bond NT, Dentsply; York, PA) was then applied and light-cured for 15 to 20 seconds (Fig 10). A universal nano-hybrid composite (Tetric EvoCeram) in shade B2 Dentin was then placed in two layers on the mesial aspect, starting from the lingual surface using a freehand method (Fig 11). Each layer was light-cured for 30 seconds. Shade Bleach L was then placed facially in 1- to 2-mm increments to create the desired tooth width and the most natural-looking esthetics (Fig 12). Each increment was light-cured for 30 seconds.

To finalize the restoration, the composite was finished with fine diamonds (57F), (5F) (Fig 13) and polishing discs (Super-Snap Buff Disk, Shofu Dental; San Marcos, CA) (Fig 14). A stretched polytetrafluoroethylene tape was placed around #8 to protect it from the etchant, allowing a better perception of #9's anatomy and helping to create the ideal emergence profile along the interdental papilla, immediately before starting to restore #9.<sup>23,27</sup> Tooth #9 was then treated following the exact same steps as described for #8. All mesial surfaces of #6, #7, and #10-12 were then restored following the exact same steps, starting from the laterals, followed by the canines, and finishing with the premolar.


Prior to the final finishing and polishing procedures all cords were removed. Proximal finishing and polishing was achieved with the use of composite polishing strips (Epitex strips, GC America; Alsip, IL). Final finishing and polishing for all seven restorations was finalized using fine diamonds (57F, 5F), polishing discs (Super-Snap, Shofu), and a high-gloss polishing point (Astropol HP, Ivoclar Vivadent) and disc (SuperBuff, Shofu) to obtain the ideal surface finish.

The completed direct composite restorations successfully closed the diastemata and demonstrated lifelike esthetics and ideal functionality (Figs 15 & 16). The patient was extremely satisfied with the esthetic results and immensely grateful (Fig 17).



# CONTACTEZ<sup>®</sup>

Ultimate Interproximal Solution



## Restorative Strip System

adjust | clean | polish

Give every patient comfortable, superior aesthetic restorations.

Try our **IPR Strip System** for Invisalign<sup>®</sup>, ClearCorrect and other clear aligners

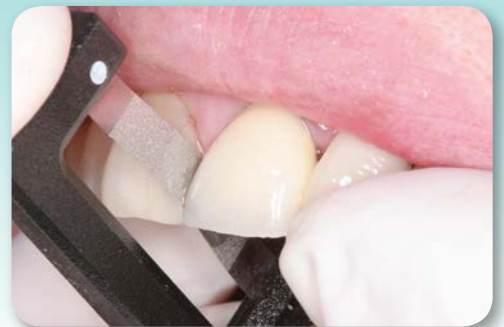Take part in the **innovative experience** that has improved thousands of cosmetic dental practices worldwide.



Separate Fused Veneers

Clean Trapped Cement

Perfect Crown Seating



AACD 2015  
San Francisco

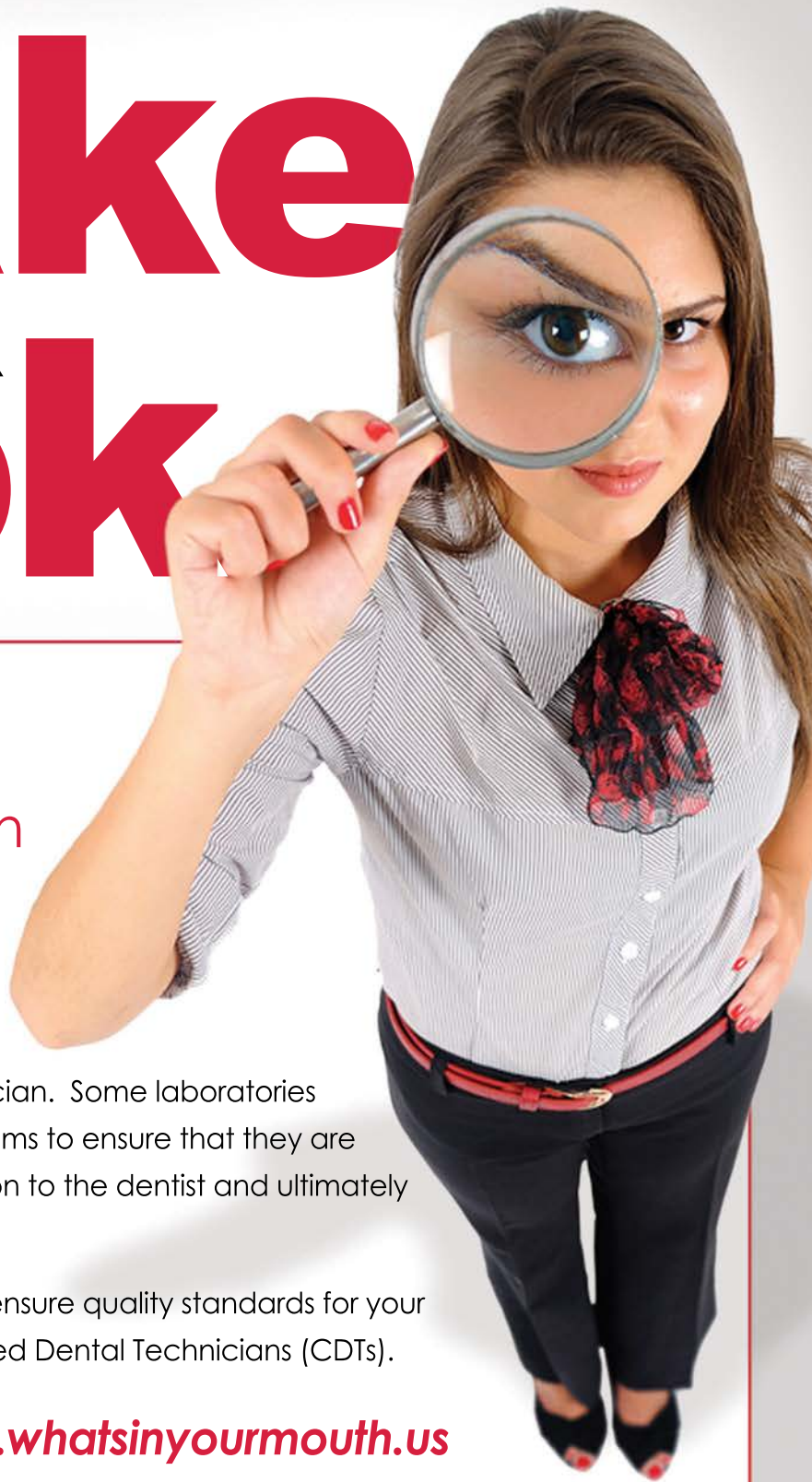Booth **1237**

Visit us for  
Special

360.694.1000 [contactEZ.com](http://contactEZ.com)



# LET'S **Take** A CLOSER **Look**



## **The simple truth...**

Your liability stays with you indefinitely.

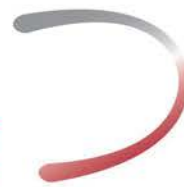3 out of 4 states have no minimum requirements to operate a dental laboratory or work as a dental technician. Some laboratories engage in voluntary standards programs to ensure that they are providing the highest quality restoration to the dentist and ultimately to the patient.

Ask your dental laboratory how they ensure quality standards for your restorations and if they employ Certified Dental Technicians (CDTs).

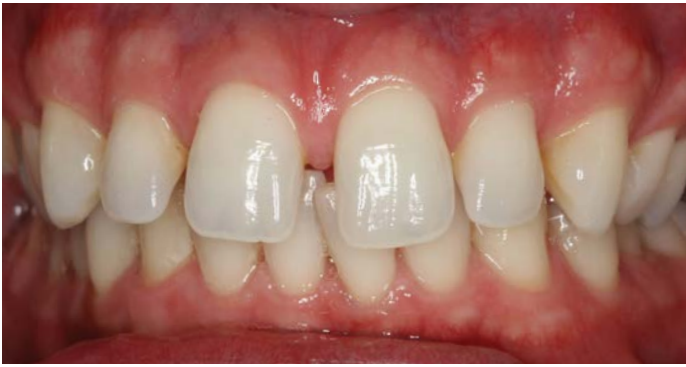**To learn more: Visit [www.whatsinyourmouth.us](http://www.whatsinyourmouth.us)**



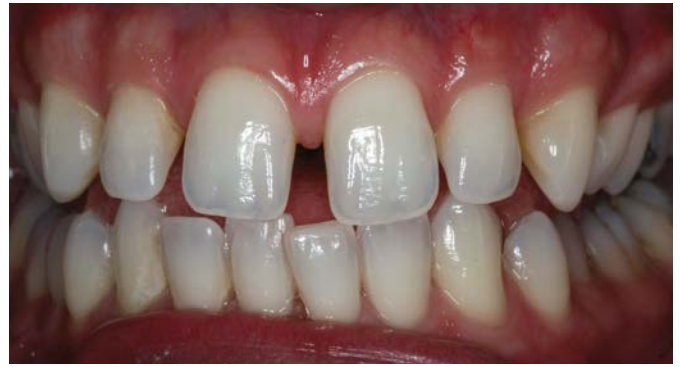NADL  
National Association of  
Dental Laboratories



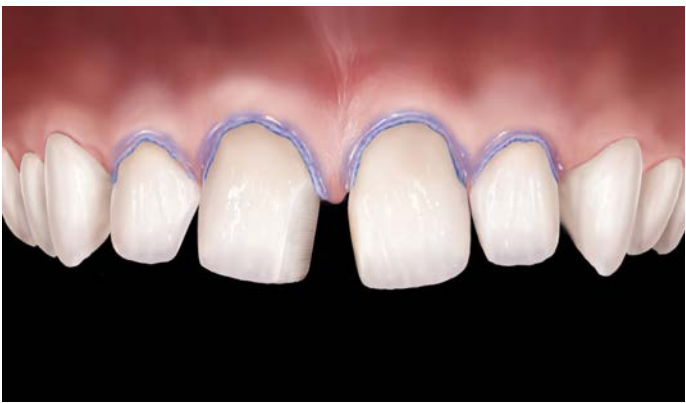
Visit us at [www.whatsinyourmouth.us](http://www.whatsinyourmouth.us)



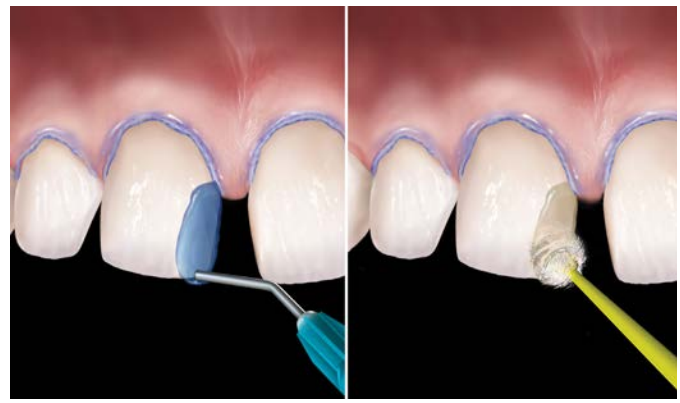
**Figure 7:** The patient's teeth were whitened using an in-office whitening treatment, followed by seven days of at-home whitening.



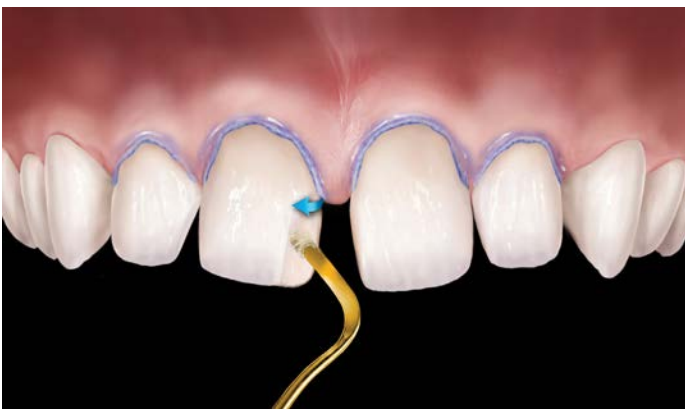
**Figure 8:** The initial shades of the teeth were A3 and A3.5, with the final whitening results in a shade lighter than B1.



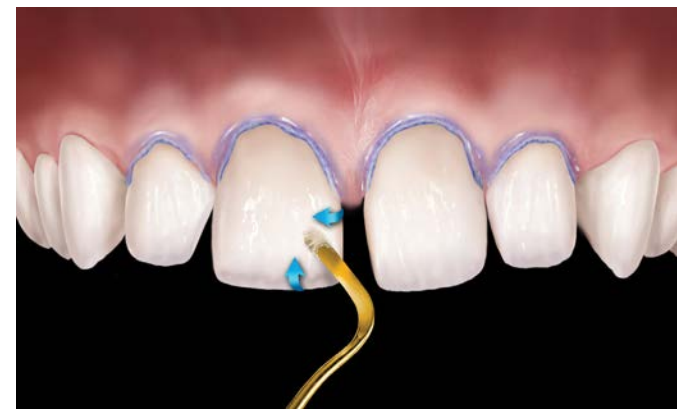**Figure 9:** A single cord was placed subgingivally for rapid tissue displacement and a flame fine diamond bur (57F) and carbide bur (7104) were used to create a 2- to 3-mm wide bevel on the mesial buccal line angles of ##6-12.



**Figure 10:** Tooth #8 was total etched with a 35% phosphoric acid etchant on the enamel for 30 seconds, rinsed, and dried.

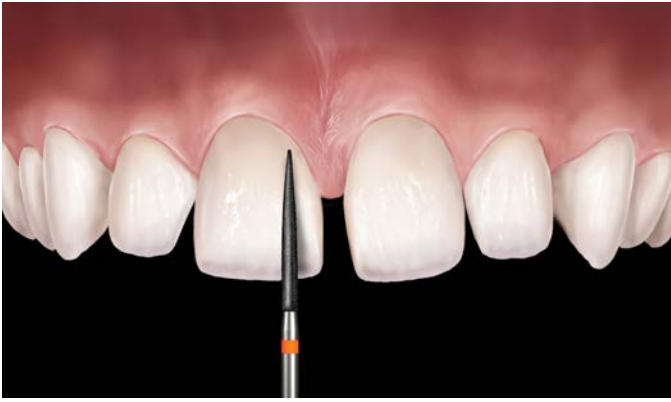

**Figure 11:** A universal nanohybrid composite in shade B2 Dentin was placed in two layers on the mesial aspect, starting from the lingual surface using a freehand method.

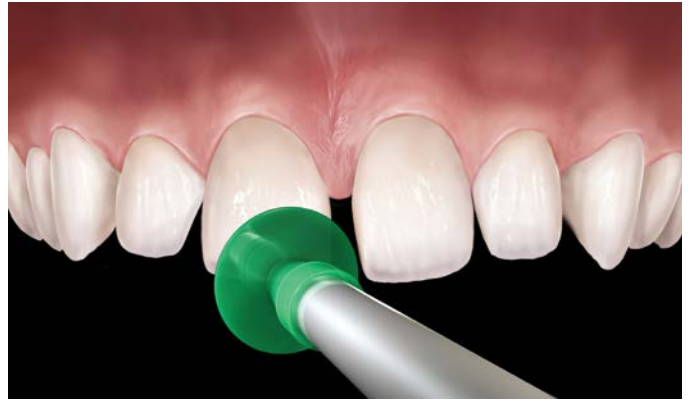

**Figure 12:** Shade Bleach L was placed facially in 1- to 2-mm increments.





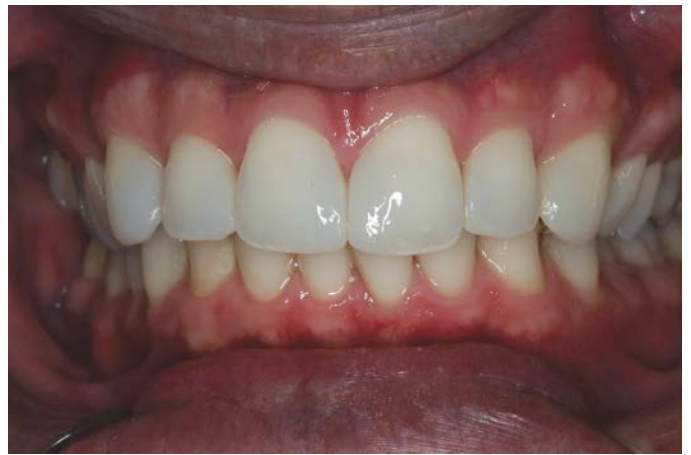**Figure 13:** To finalize the restoration, the composite was finished with fine diamonds.



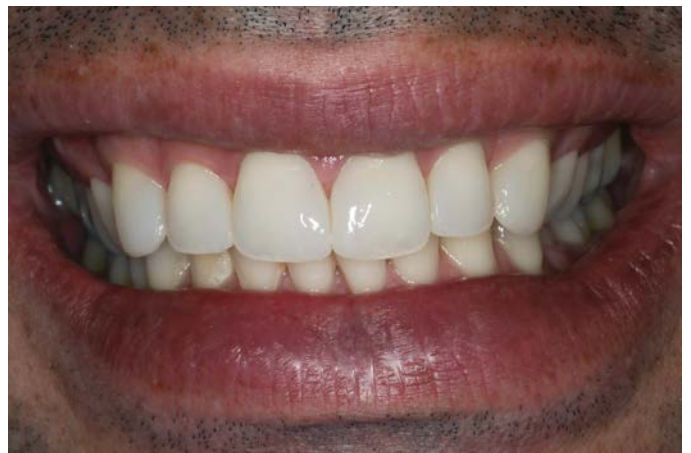**Figure 14:** The composite was then finished with polishing discs.



**Figure 15:** Postoperative view of the final direct composite restorations.



**Figure 16:** The freehand direct composite layering technique closed the patient's diastemata both functionally and esthetically.



**Figure 17:** The patient was extremely satisfied with the esthetic results.



## Summary

Diastemata, if left uncorrected, can cause patients a lifetime of poor facial esthetics and emotional and psychological challenges. Although diastemata can be treated using a variety of techniques, direct composite restorations offer predictable, conservative, and cost-effective esthetic solutions. By understanding patients' functional and esthetic desires and requirements, as well as their timeline and treatment preferences, clinicians are better equipped not only to enhance their patients' smiles, but also to bring hope and healing into their lives. In this case, the mesially placed composite enabled the dentist to provide a life-changing diastema closure treatment to a patient whose desires included a quick treatment time, minimal intervention, and highly esthetic results. After the treatment, he knew his life would be forever changed, as his smile gave him overwhelming confidence and pride.

## Acknowledgment

*The authors thank AEGIS Media (Newtown, PA) for creating the illustrations for this article.*

## References

1. Bos A, Hoogstraten J, Prah-Andersen B. Expectations of treatment and satisfaction with dentofacial appearance in orthodontic patients. *Am J Orthod Dentofacial Orthop.* 2003;123(2):127-32.
2. Tung AW, Kiyak HA. Psychological influences on the timing of orthodontic treatment. *Am J Orthod Dentofacial Orthop.* 1998;113(1):29-39.
3. Arndt EM, Travis F, Lefebvre A, Niec A, Munro IR. Beauty and the eye of the beholder: social consequences and personal adjustments for facial patients. *Br J Plast Surg.* 1986;39(1):81-4.
4. Bernabé E, Flores-Mir C. Influence of anterior occlusal characteristics on self-perceived dental appearance in young adults. *Angle Orthod.* 2007;77(5):831-6.
5. Furuse AY, Franco EJ, Mondelli J. Esthetic and functional restorations for an anterior open occlusal relationship with multiple diastemata: a multidisciplinary approach. *J Prosthet Dent.* 2008;99(2):91-4.
6. Gardiner JH. Midline spaces. *Dent Pract Dent Rec.* 1967;17(8):287-97.
7. Witt M, Flores-Mir C. Laypeople's preferences regarding frontal dentofacial esthetics: periodontal factors. *J Am Dent Assoc.* 2011;142(8):925-37.
8. Lavelle CL. Crowding and spacing within the human dental arch of different racial groups. *Arch Oral Biol.* 1970;15(11):1101-3.

**“ The completed direct composite restorations successfully closed the diastemata and demonstrated lifelike esthetics and ideal functionality. ”**

9. McVay TJ, Latta GH Jr. Incidence of the maxillary midline diastema in adults. *J Prosthet Dent.* 1984;52(6):809-11.
10. Richardson ER, Malhotra SK, Henry M, Little RG, Coleman HT. Biracial study of the maxillary midline diastema. *Angle Orthod.* 1973;43(4):438-43.
11. Steigman S, Gershkovitz E, Harari D. Characteristics and stability of spaced dentition. *Angle Orthod* 1985;55(4):321-8.
12. Taylor JE. Clinical observations relating to the normal and abnormal frenum labii superioris. *Am J Orthod Oral Surg.* 1939;25:646-50.
13. Burke FJ. From extension for prevention to prevention of extension: (minimal intervention dentistry). *Dent Update.* 2003;30(9):492-8, 500, 502.
14. Christensen GJ. The advantages of minimally invasive dentistry. *J Am Dent Assoc.* 2005;136(11):1563-5.
15. Lenhard M. Closing diastemata with resin composite restorations. *Eur J Esthet Dent.* 2008;3(3):258-68.
16. Lacy AM. Applications of composite resin for single-appointment anterior and posterior diastema closure. *Pract Periodontics Aesthet Dent.* 1998;10(3):279-86; quiz 288.
17. Chalifoux PR. Diastema closure. *Inside Dent.* 2010;6(8):62-70.
18. Signore A, Kaitsas V, Tonoli A, Angiero F, Silvestrini-Biavati A, Benedicenti S. Sectional porcelain veneers for a maxillary midline diastema closure: a case report. *Quintessence Int.* 2013;44(3):201-6.
19. McLaren EA, Whiteman YY. Treatment planning with ceramics: a systematic approach in material selection. *Inside Dent Tech.* 2012;3(9):42-9.
20. Kim YH, Cho YB. Diastema closure with direct composite: architectural gingival contouring. *J Korean Acad Conserv Dent.* 2011;36:515-20.
21. Wolf D, Kraus T, Schach C, Pritsch M, Mentel J, Staehle HJ, Ding P. Recontouring teeth and closing diastemata with direct composite buildups: a clinical evaluation of survival and quality parameters. *J Dent.* 2010;38(12):1001-9.

22. Heymann HO, Hershey HG. Use of composite resin for restorative and orthodontic correction of anterior interdental spacing. *J Prosthet Dent.* 1985;53(6):766-71.
23. Hwang SK, Ha JH, Jin MU, Kim SK, Kim YK. Diastema closure using direct bonding restorations combined with orthodontic treatment: a case report. *Restor Dent Endod* 2012;37(3):165-9.
24. De Araujo EM Jr, Fortkamp S, Baratieri LN. Closure of diastema and gingival recontouring using direct adhesive restorations: a case report. *J Esthet Restor Dent* 2009;21(4):229-40.
25. Chuang SF, Chen HP, Chang CH, Liu JK. Effect of fluoridated carbamide peroxide gels on enamel microtensile bond strength. *Eur J Oral Sci.* 2009;117(4):435-41.
26. Barbosa CM, Sasaki RT, Flório FM, Basting RT. Influence of in situ post-bleaching times on resin composite shear bond strength to enamel and dentin. *Am J Dent.* 2009;22(6):387-92.
27. Brown DE. Using plumber's teflon tape to enhance bonding procedures. *Dent Today.* 2002 Jan;21(1):76-8. **jCD**

“ Although diastemata can be treated using a variety of techniques, direct composite restorations represent predictable, conservative, and cost-effective esthetic solutions. ”



Dr. Papathanasiou is an assistant professor, Department of Prosthodontics and Operative Dentistry, Tufts University School of Dental Medicine, in Boston, Massachusetts.



Dr. Charilaos Asikis is a clinical assistant professor and practice leader, Pre-Doctoral Treatment Center, Henry M. Goldman School of Dental Medicine, Boston University.

Disclosure: The authors did not report any disclosures.



**November 6-7, 2015**

**ADES**  
Academy of Dental Esthetics and Sciences

*ADES Proudly Presents:*

**The Esthetic Zone Inside and Out  
- with Dr. Gerard J. Chiche**

Led by Dr. Gerard J. Chiche, this special interactive program will present a step-by-step approach to treat esthetic rehabilitations with improved esthetics, and predictable, functional results. Earn 12 CE credits as you explore The Esthetic Zone with this world-renowned master.

Set by the beach in beautiful Ponte Vedra Beach, you'll enjoy an intimate group setting in which Dr. Chiche will share invaluable practical tips from setting up the case all the way to ceramics management, cementation selection, and step-by-step bonding techniques. Early registrants will be randomly selected to receive "Smile Design", co-authored by Dr. Gerard J. Chiche & Hitoshi Aoshima, RDT.

Seats are limited, reserve NOW!  
[www.academyofdes.org](http://www.academyofdes.org) / [info@academyofdes.org](mailto:info@academyofdes.org) / 781.388.0016



**12 CE Credits**

\$2100/Early Registration before 10/1/15

\$1300 (Lecture only - before 10/1/15)

\$2400/Registration after 10/2/15

\$1500 (Lecture only - after 10/2/15)

\$680/Technician (Lecture only - before 10/1/15)

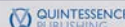

\$830/Technician (Lecture only - after 10/2/15)

Contact ADES for group discount rate.

*ADES combines intensive education with the ultimate vacation for golf and beach enthusiasts!*



Sponsors:



ADES, The Educational Division of Cusp Dental

# Philips Sonicare FlexCare Platinum

More innovation. Less plaque between teeth.



## INTERCARE BRUSH HEAD TECHNOLOGY



- Deeper interdental cleaning
- Removes up to 7x more plaque between teeth<sup>1</sup>

## INNOVATIVE PRESSURE SENSOR



- Resonates when too much pressure is applied
- Interactive guidance for proper brushing technique

## ADJUSTABLE MODES AND INTENSITY SETTINGS



- Clean: Low, Medium and High
- White: Low, Medium and High
- Gum Care: Low, Medium and High

Philips Sonicare FlexCare Platinum removes significantly more plaque than Oral-B Professional Care 5000 in all areas of the mouth.<sup>2</sup>

Contact your Sonicare representative to set up a demonstration or to purchase a specially priced trial unit.

[philipsoralhealthcare.com](http://philipsoralhealthcare.com) (800) 422-9448

**PHILIPS**  
**sonicare**

<sup>1</sup> Than a manual toothbrush. Ward, W, Jenkins, K, Argosino, S, Souza, M, Nelson, J, Milleman, K, R, Milleman. Assessment of a Sonic Toothbrush on Plaque and Gingivitis. J Dent Res 92 (Spec IssA):3753, 2013.

<sup>2</sup> Defenbaugh J, Liu T, Souza S, Ward M, Jenkins W, Colgan P. Comparison of Plaque Removal by Sonicare FlexCare Platinum and Oral-B Professional Care 5000 with Smart Guide. Data on file, 2013.

Not yet verified by peer-reviewed research.

© 2015 Philips Oral Healthcare, Inc. All rights reserved. PHILIPS and the Philips shield are trademarks of Koninklijke Philips N.V. Sonicare, the Sonicare logo, DiamondClean, FlexCare Platinum, FlexCare, FlexCare+, ProResults, Sonicare For Kids and AirFloss are trademarks of Philips Oral Healthcare.



# Overcoming Surgical and Prosthetic Challenges

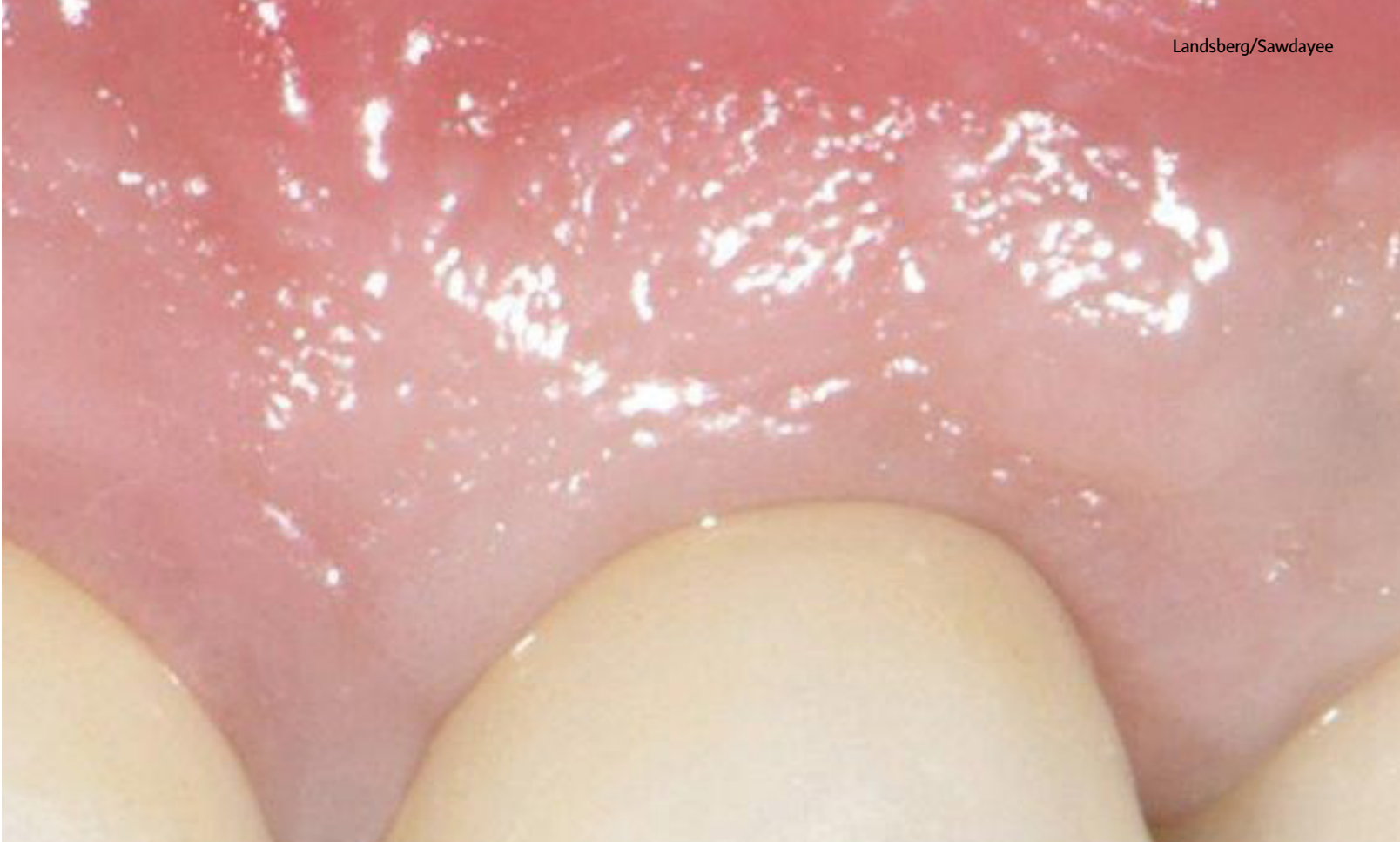
## Planning and Implementing a Maxillary Central-Lateral Implant Restoration

Cobi Landsberg, DMD  
Elie Sawdayee, DMD, CDT

### Abstract

The maxillary central-lateral implant restoration presents a unique and multifaceted dilemma for the professional team. Achieving a functional and esthetic implant restoration in this area may become extremely challenging due to its specific anatomical characteristics. This case report emphasizes the importance of detailed planning and use of advanced and challenging surgical and prosthetic procedures to overcome the obstacles typical to this area.

**Key Words:** lateral-central restoration, implants, bone regeneration, soft tissue augmentation, esthetics, emergence profile



Reconstruction of both the horizontal and vertical ridge dimensions may be predictably achieved. However, the preservation or restoration of the original interproximal papilla between two adjacent implants is still considered nearly impossible.



## Introduction

Extraction of two or more adjacent teeth may cause flattening and narrowing of the alveolar ridge, with almost complete disappearance of the interdental papillae. These changes occur as a result of disruption of attached connective tissue fibers that normally support the function and form of hard and soft tissues around the teeth.<sup>1</sup>

Reconstruction of both the horizontal and vertical ridge dimensions may be predictably achieved. However, the preservation or restoration of the original interproximal papilla between two adjacent implants is still considered nearly impossible.<sup>2,3</sup>

In the maxillary central-lateral tooth area, it is especially difficult to restore the interproximal papilla.<sup>4,5</sup> This is mainly due to inevitable partial resorption of the narrow and mostly cortical interdental septum usually found between the two extracted teeth. Further insult to the interproximal tissues may occur if two standard implants are placed to support the two-unit restoration. This is because the edentulous ridge is usually too short to maintain the minimum 4-mm inter-implant distance necessary to prevent crestal resorption.<sup>1,6</sup>

Several surgical and prosthetic solutions have been proposed to overcome this problem; they include placing narrow<sup>7</sup> or switched platform implants,<sup>8</sup> connecting small diameter concave abutments,<sup>9,10</sup> using scalloped implants,<sup>11,12</sup> or placing a single implant supporting a cantilevered bridge.<sup>4,5,7</sup>

The presented case addresses a variety of surgical and prosthetic considerations and methods to achieve the best possible functional and esthetic outcomes in this challenging central-lateral area.

In the maxillary central-lateral tooth area, it is especially difficult to restore the interproximal papilla.

## Case Presentation

A 45-year-old male presented wanting to replace his loose upper front bridge with an esthetic and well-functioning restoration. Clinical examination revealed a skeletal Class II with Angle Class II, Division 1 and 2 occlusion with pronounced overbite and overjet in the anterior dentition. There were no occlusal contacts of teeth #7-10 in maximum intercuspation, and lateral and anterior movements were canine-protected and anteriorly guided, respectively. Significant deterioration of function and esthetics of the maxillary anterior teeth were noted. The entire sextant was involved, with moderate gingival recession and interdental papillae loss. Tooth #7 was slightly tilted labially. Teeth #8 and #10 displayed darkened roots, which were clearly visible above, and reflected below the recessed gingival margins. A Class I<sup>13</sup> residual ridge defect (i.e., mainly horizontal resorption) was present at site 9 (Fig 1). Radiographic examination revealed early to moderate alveolar bone resorption. A root canal filling had been performed at #8 approximately 15 years previously. A wide radiographic shadow mesial of the tooth suggested the existence of a relatively wide incisive nerve and canal. Severe root decay was found in #10 (Figs 2a-2e).

## Treatment Objectives

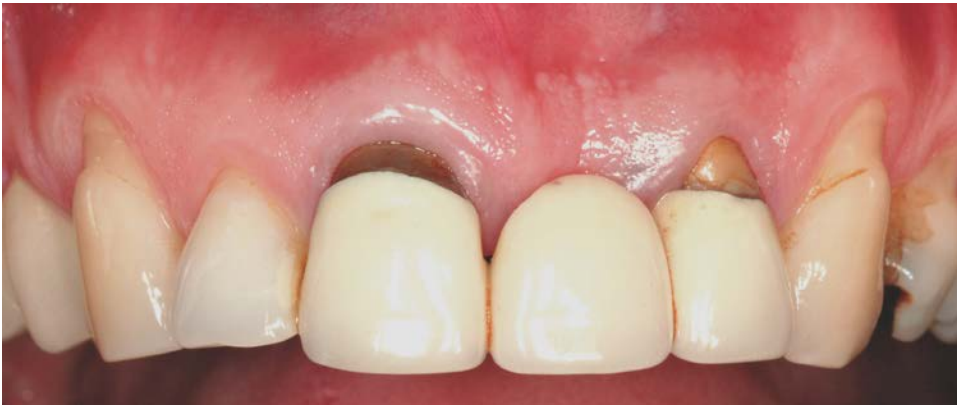As the patient rejected correction of the skeletal Class II malocclusion with orthognathic surgery, the remaining treatment goal was to restore function and esthetics to the maxillary front dentition by fulfilling the following objectives:

- extraction of #10
- central and lateral (sites 9 and 10) implant restoration with optimal physiological topography of the gingival margins and interproximal papillae
- crown replacement of #8
- masking of dark-colored root of #8 with a new crown and connective tissue graft
- uprighting of #7
- partial root coverage of #6 and #11.

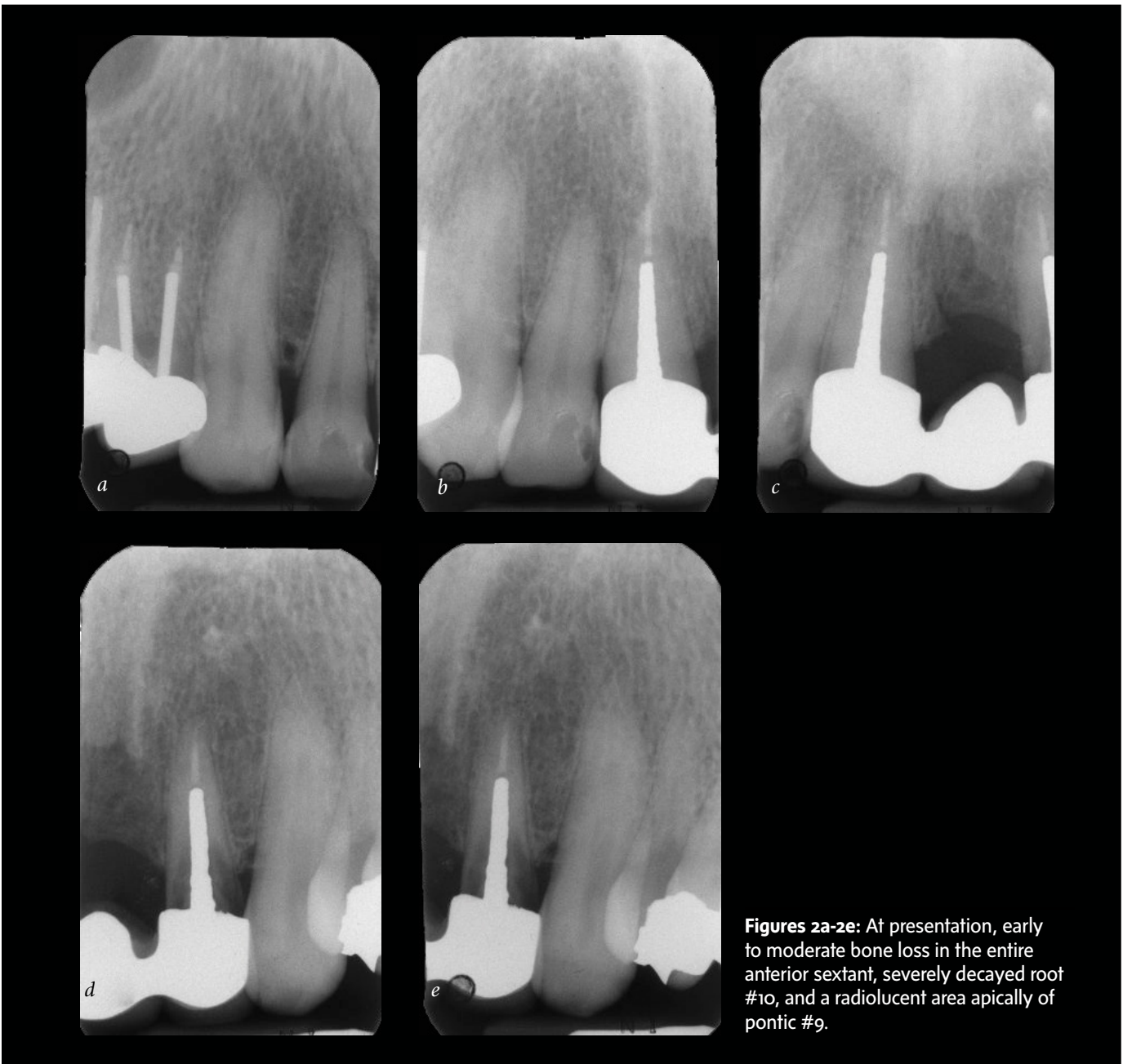After discussing the steps necessary to achieve his functional and esthetic goals, the patient agreed to the proposed surgeries, except for the possibility of intervening with the incisive nerve and blood vessels (which might be necessary for safe implant placement in site 9). Therefore, other restorative options limited to a single implant placement in site 10 (i.e., cantilevered bridge, or connecting implant 10 with tooth #8, etc) were considered. The patient also declined any orthodontic treatment. Thus, it was decided to restore the crown with direct composite restoration to blur the misangulation of tooth.<sup>7</sup>

It was also explained to the patient that on #6 and #11, only partial root coverage might be expected due to reduced bone level and papillae heights present interproximally on those teeth.<sup>14,15</sup>





**Figure 1:** At presentation, the three-unit bridge was loose. Note recessed gingiva of the whole anterior sextant and horizontal ridge defect at site 9.



**Figures 2a-2e:** At presentation, early to moderate bone loss in the entire anterior sextant, severely decayed root #10, and a radiolucent area apically of pontic #9.

## Clinical Procedures

### Extraction of #10 and Provisional Bridge

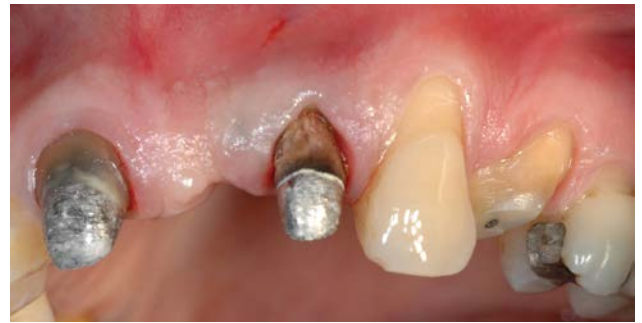Extraction of #10 necessitated an immediate tooth-supported temporary restoration. To avoid unnecessary preparation of the left canine, the moderately decayed #12 was prepared to support, along with #8 and a metal rest on #11, a metal-reinforced acrylic temporary bridge (Figs 3-5). Immediate preservation of the fresh extraction site by bone and soft tissue grafting was not implemented, because the entire edentulous area was planned for hard and soft tissue augmentation in the subsequent two months.

### Implant Placement in Site 10 and Ridge Augmentation in Sites 9 and 10

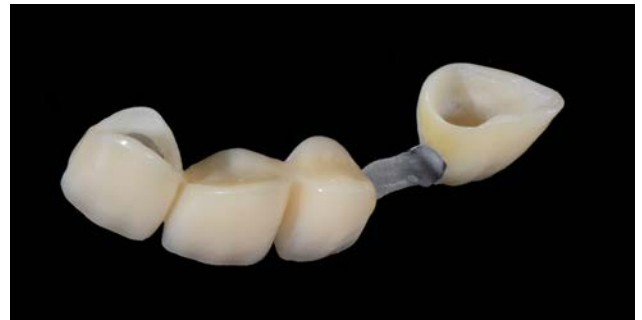After two months, marked horizontal concavity of the edentulous area was noted (Fig 6). Wide full thickness labial and palatal flaps with vertical releasing incisions in the distal region of #6 and #12 were elevated, exposing a mostly thin and concave alveolar ridge and a large incisive canal opening (Fig 7). A prefabricated surgical stent (Fig 8) clearly indicated that implant (4-mm wide, 3i, Biomet; Palm Beach Gardens, FL) placement was feasible at this stage only in site 10 (Fig 9). It was calculated that placing a relatively wide-diameter implant at site 10 would be advantageous if, despite the efforts to augment the ridge, site 9 would ultimately be found unsuitable for implant placement.

The ridge was augmented using bovine bone mineral (Bio-Oss, Geistlich Pharma GA; Wolhusen, Switzerland) and a resorbable x-linked collagen membrane (Ossix-Plus, Datum Dental; Lod, Israel) (Figs 10 & 11). To further increase the overall dimensional changes of the ridge, a subepithelial soft tissue graft harvested from the palate was placed and sutured on top of the membrane using resorbable 4-0 polyglactin sutures (Vicryl Rapide, Ethicon/Johnson & Johnson; Somerville, NJ) (Fig 12). The labial flap was coronally advanced and sutured using nonresorbable 6-0 polyamide sutures (Ethilon, Ethicon/Johnson & Johnson) to the palatal flap for complete coverage of the grafted tissues.<sup>16</sup> Root coverage of #6 and #11 was carried out concomitantly (Fig 13). Healing was uneventful, and at six months marked vertical and horizontal ridge augmentation had been achieved (Fig 14). However, the dimensions necessary to obtain the desired soft tissue topography around the future crowns had not been reached (Fig 15). CT scans of the area revealed an appreciable horizontal gain of hard tissue, which seemed suitable for implant placement at site 9 (Fig 16).

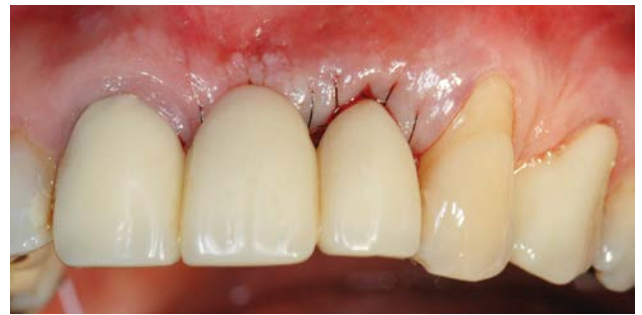It was predicted that additional bone gain, both horizontally and vertically for improved soft tissue support, would be unachievable mainly due to anatomic limitations (reduced crest level mesially of #11 and a wide incisive canal).



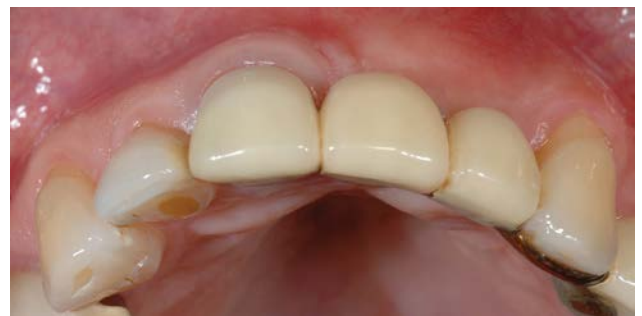**Figure 3:** Tooth #12 was prepared. Note vertical fracture of #10 and moderate gingival recession of #11.



**Figure 4:** A transitional bridge composed of acrylic crowns for #8 and #12, a metal rest on #11, and two pontics for sites 9 and 10.

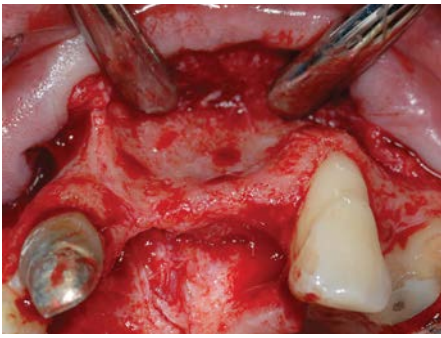


**Figure 5:** The left lateral tooth was removed. A transitional bridge is supported by #8 and #12, and a metal rest on #11.

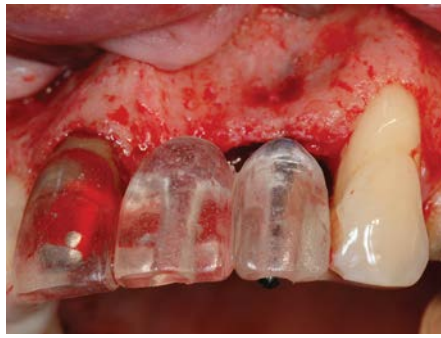

**Figure 6:** After two months, a marked horizontal ridge deficiency was noted in the area of pontics #9 and #10.

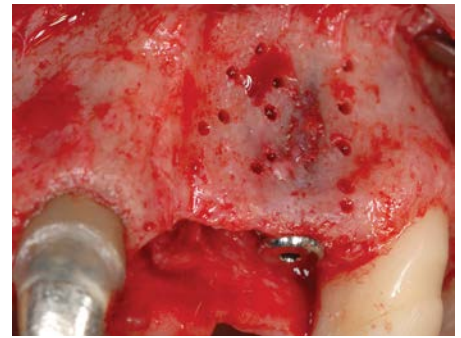




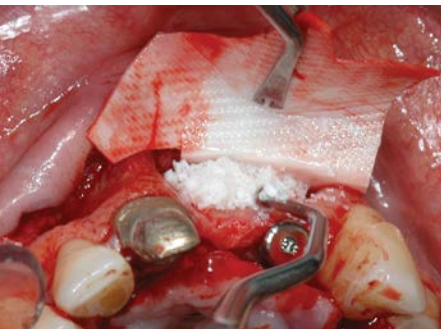
**Figure 7:** Wide flaps are elevated showing severe horizontal bone defect and wide incisive canal, significantly compromising future implant placement in site 9.



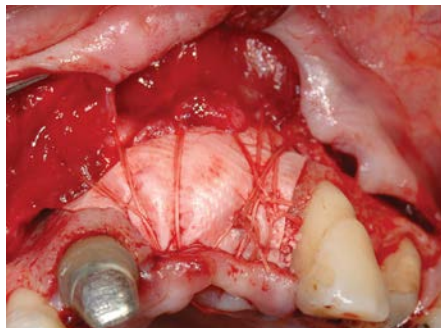
**Figure 8:** The surgical stent that mimics the planned screw-retained final crowns is well situated.



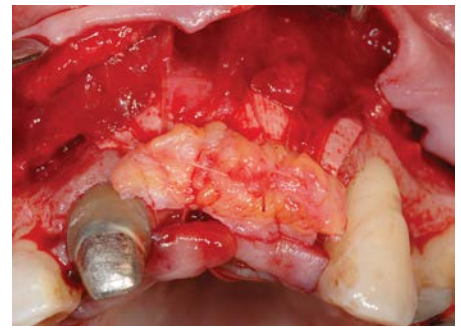
**Figure 9:** Residual bone is decorticated by multiple drill penetrations. A standard-diameter (4.1 mm) implant is placed at site 10 close to the labial bony plate.



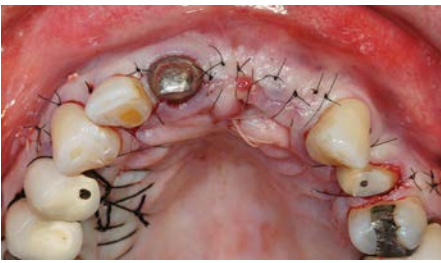
**Figure 10:** Bovine bone particles are placed underneath an x-linked resorbable collagen membrane to increase buccal bone volume.



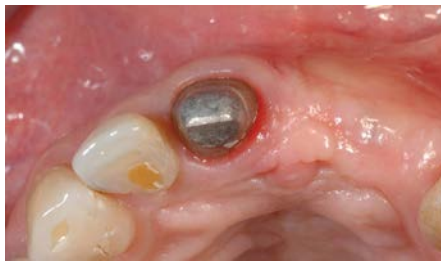**Figure 11:** The membrane is fixed by 4-0 resorbable sutures anchored to the deep periosteum buccally and to the palatal flap.



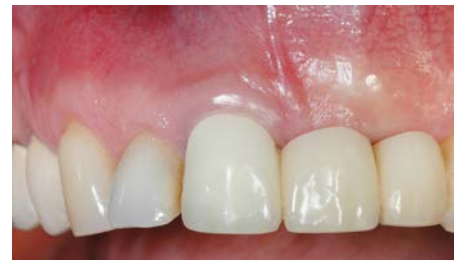**Figure 12:** A subepithelial soft tissue graft harvested from the palate is placed on top of the membrane and fixed by 4-0 resorbable sutures.



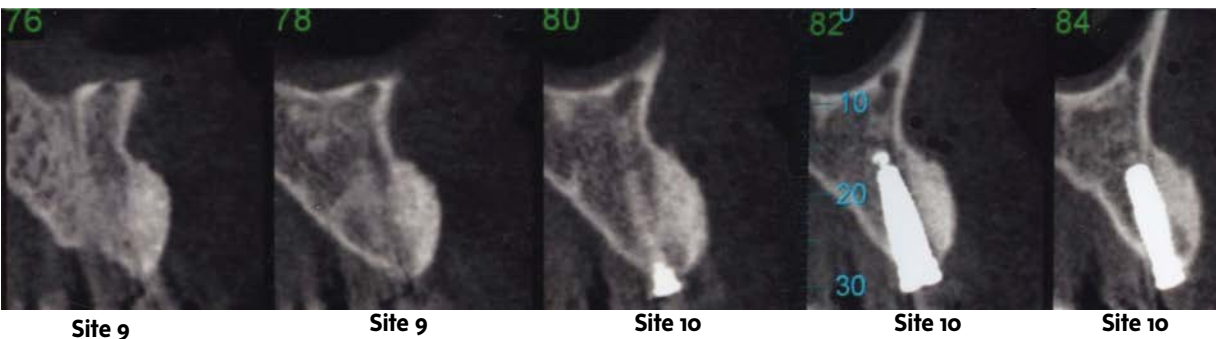
**Figure 13:** The augmented area is completely covered by the coronally advanced labial flap and the palatal flap using 6-0 polyamide sutures.



**Figure 14:** At six months, the ridge demonstrates horizontal and vertical gain.



**Figure 15:** Pontics #9 and #10 are shortened to accommodate the increased vertical ridge dimension. However, insufficient horizontal ridge width was noted.

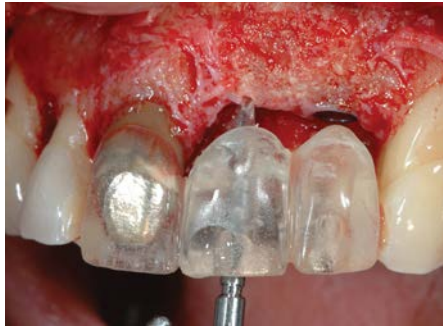

**Figure 16:** At six months, CT scans show a significant gain in bone volume horizontally. Note site 9 is suitable for narrow implant placement.

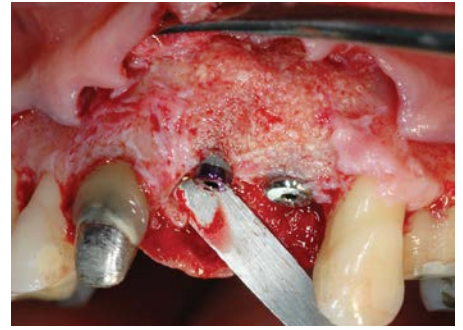


### Implant Placement at Site 9 and Soft Tissue Enhancement

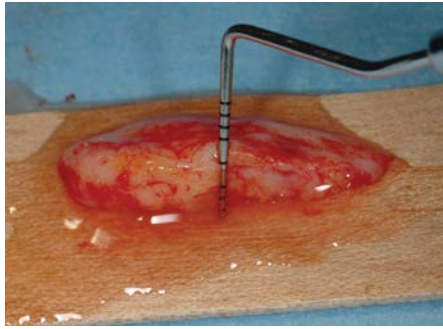
After six months, buccal and palatal full thickness flaps were elevated, exposing newly sound regenerated bone and a well-integrated implant at site 10. A narrow-diameter (3.25 mm) implant was placed at site 9 using the original surgical guide. As a 4-mm wide implant had previously been placed at site 10, the achieved inter-implant distance was only 3.2 mm (Figs 17 & 18). A large soft tissue graft, harvested from the same donor site in the palate, was placed to augment the ridge both horizontally and vertically, and to partly increase the marginal gingiva width of #11 (Figs 19 & 20). The labial flap was advanced once again to completely cover the augmented ridge (Fig 21). Healing was uneventful, and three months after surgery the tissue topography in both vertical and horizontal dimensions seemed adequate for surgical implant exposure (Fig 22). However, significant coronal advancement of the less desired non-keratinized mucosa was evident (Fig 23).



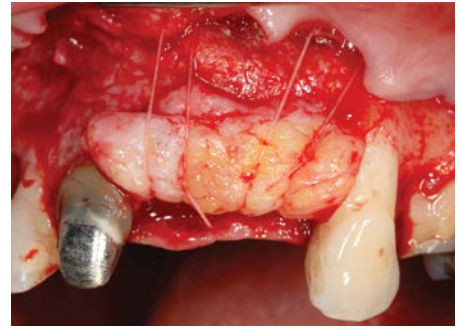
**Figure 17:** Using the original surgical stent, site 9 is suitable for implant replacement six months after guided bone regeneration.



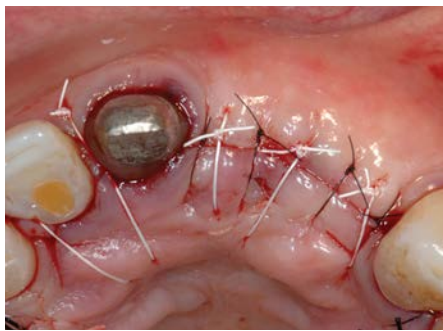**Figure 18:** A narrow-diameter (3.25 mm) implant is placed at site 9.



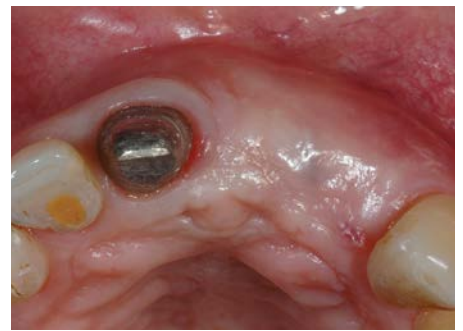**Figure 19:** An additional large soft tissue graft is harvested from the same donor in the palate.



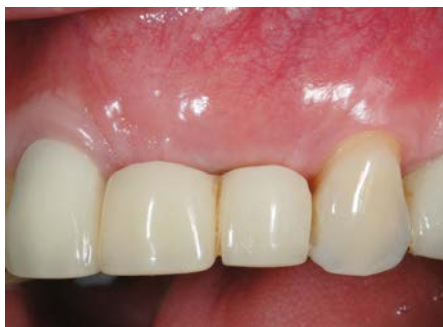**Figure 20:** The soft tissue graft is placed at the occluso-labial aspect of the ridge and fixed with 4-0 resorbable periosteal sutures.



**Figure 21:** The labial flap is coronally advanced to achieve complete coverage of the grafted tissues.



**Figure 22:** After three months, there is a significant increase in ridge volume, both in coronal and labial dimensions.

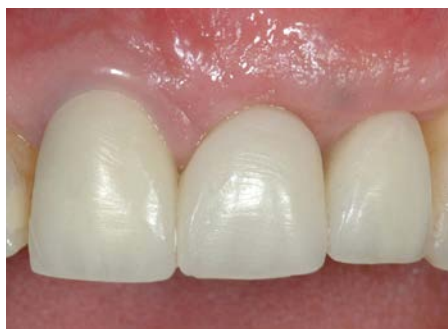

**Figure 23:** The pontics at sites 9 and 10 are shortened. Note lack of adequate keratinized band at the labial aspect due to labial flap coronal advancements.

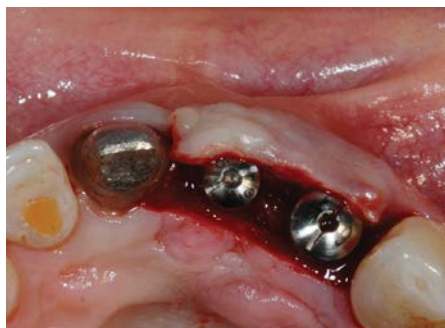Restoration of two missing maxillary central and lateral teeth with a functional and esthetic implant-supported prosthesis is still one of the most challenging procedures in implant dentistry.

### Healing Abutment Connection and Transmucosal Tissue Profile Development

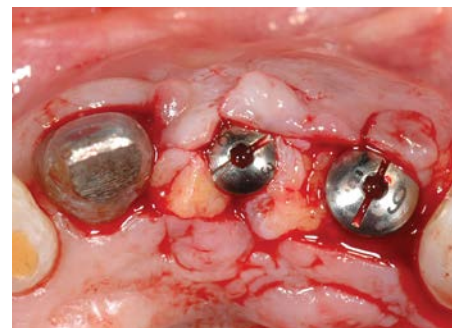After three months, a palatal horizontal incision was made that enabled healing abutment connection and transposition of a significant amount of keratinized tissue, both buccally and coronally (Fig 24). Small pieces of connective tissue harvested from the palate filled the created interproximal soft tissue gaps. Semicircular small pedunculated labial flaps were rotated to protect these tissue grafts and to further enhance the interproximal tissues (Figs 25-27).<sup>17</sup> After three months of healing, individual screw-retained temporary acrylic crowns were connected to the implants. Initially, these interim crowns were prepared to be narrow in their transmucosal part to avoid pressure on the peri-crown soft tissues that presented typical cylindrical long and narrow profiles. However, every few weeks, light pressure on the surrounding tissues was exerted gradually by adding small acrylic increments circumferentially on the cervical portions of the crowns. This achieved a gradual improvement in proportions and appearance of the crowns and the tissues around them (Fig 28). The desired crown designs with "all-around" concave transmucosal profiles were finally achieved six months after they were first connected to the implants (Figs 29-31).



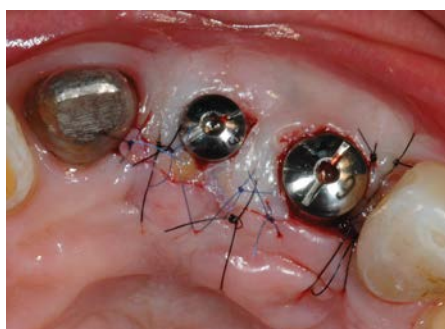**Figure 28:** After two months, provisional crowns during the process of redesigning the transmucosal tissue profiles.



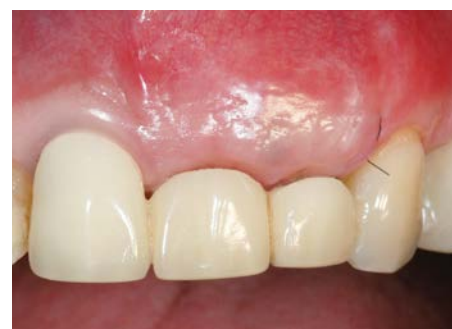**Figure 24:** At implant exposure, a palatal straight horizontal incision enables further corona-labial positioning of the labial flap.



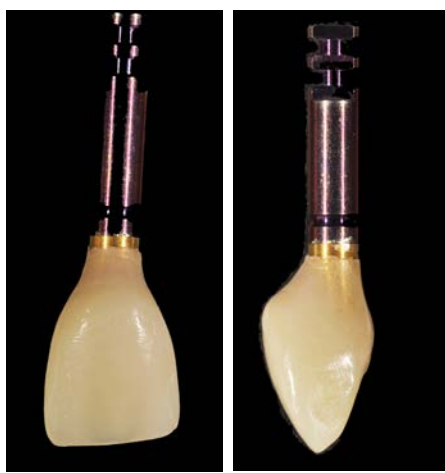**Figure 25:** Small soft tissue grafts harvested from the palate are placed in the interproximal gaps created upon flap elevation. Mini pedunculated flaps are prepared in the labial flap.



**Figure 26:** The mini-flaps are rotated to fully cover the grafted soft tissue and to further augment the interproximal tissues.

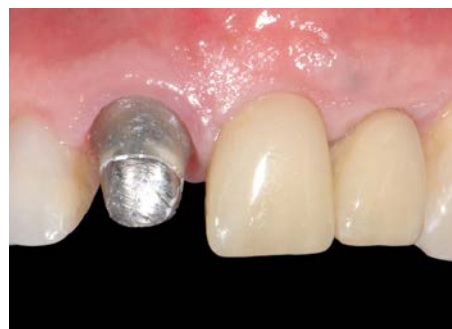

**Figure 27:** After one week, there is significant increase in ridge volume and reestablishment of adequate band of keratinized tissue with a straight mucogingival line.



**Figure 29:** After five months, ultimate provisional restoration of #9 before its connection to the implant (buccal view). Note concave emergence profiles.

**Figure 30:** After five months, ultimate provisional restoration of #9 before its connection to the implant (lateral view). Note concave emergence profiles.



**Figure 31:** After six months, ultimate provisional restorations of #9 and #10, having all-around concave profiles, are screw-retained as single units.



### Final Crown Restorations

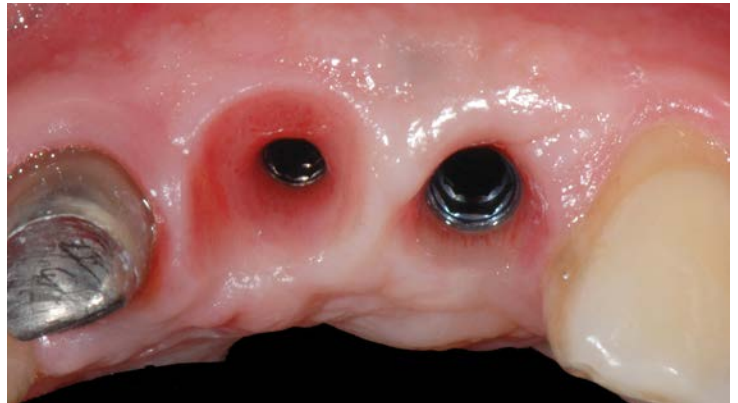
The final transmucosal profiles achieved around the provisional restoration were perfectly transferred to the laboratory using a technique recently developed by the secondary author (Figs 32 & 33). In this technique, the provisional restoration is mounted on the working model, thereby allowing accurate fabrication of a soft tissue replica.

Cast gold abutments exactly matching the concave transmucosal profiles of sites 9 and 10 were fabricated and tested in situ (Fig 34). Using dual-cured adhesive resin cement (Panavia F 2.0 CT, Kuraray; Tokyo Japan), zirconia crowns were bonded to the gold abutments to become one-piece prosthetic units (Fig 35), which were screw-retained separately to implants 9 and 10. A single zirconia crown was cemented (Panavia) to the existing gold post of #8. Choosing identical prosthetic materials (zirconia cemented to gold) for the three crown restorations defined their desired similar esthetic characteristics. Therefore, other options (e.g., porcelain-fused-to-gold screw-retained crowns) for the implants were not considered. Teeth #6 and #11 regained almost natural anatomic proportions by combining partial root coverage and cervical composite restorations. Tooth #7 received a bonded composite restoration in an attempt to blur its labial angulation. Well-aligned esthetic crowns were achieved in healthy tissue housing with nicely contoured soft tissue margins (Fig 36).

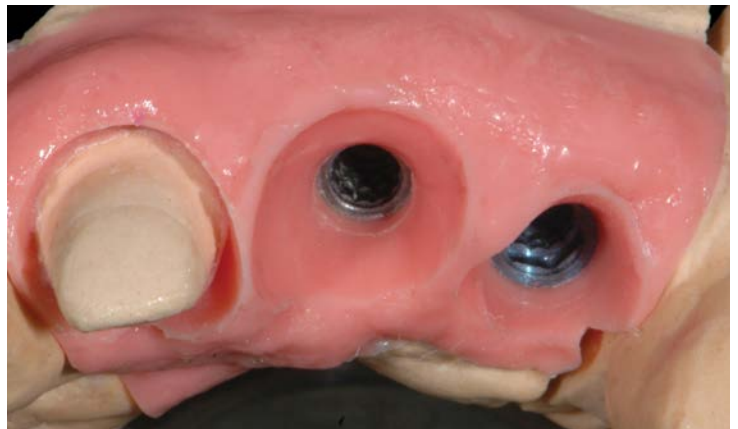
Radiographically, the implants demonstrated proper "implant-tooth" distances; however, there was less than ideal "implant-implant" space with bone profiles typically found around straight, wide-headed implants (Figs 37a & 37b).

After one month, the patient received a new composite restoration to enhance the appearance of #7. At six months, a slight vertical eruption of #8 was discovered. Therefore, the tooth was intruded back to its natural position utilizing a transparent acrylic plate and finally splinted with orthodontic wires and a composite.

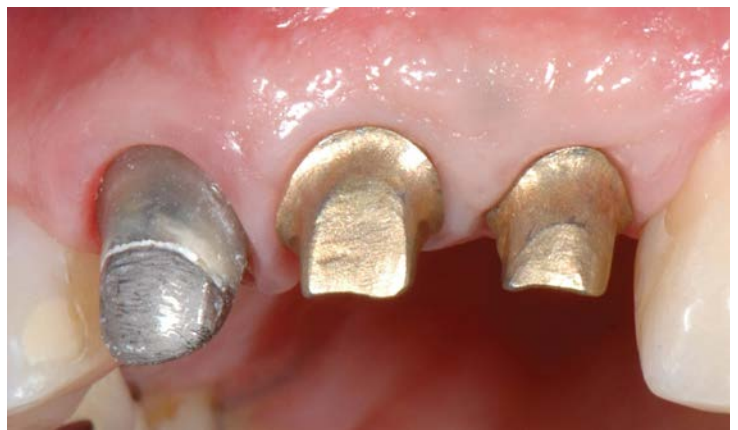The patient has been seen in both periodontal and prosthetic clinics every three to four months since completing active treatment. At the three-year follow-up it was evident that both bony and soft tissue housings around the implant restoration remained completely stable (Figs 38-39b). A slight marginal gingiva edema on #7 and #8 was noted. This was related to possible inefficient plaque control and compromised connective tissue attachment to the imperfect darkened treated root #8. Subgingival curettage under local anesthesia was performed and the need to improve adherence to the oral hygiene instructions and maintenance program was emphasized to the patient.



**Figure 32:** At removal of ultimate provisional restorations of #9 and #10, the transmucosal tissues show the maximum desired morphology.

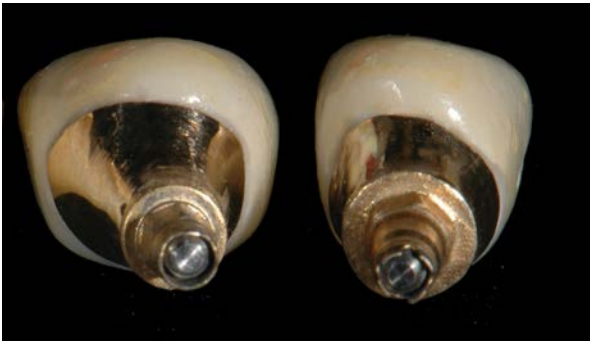

**Figure 33:** The transmucosal tissue profiles are accurately transferred to the laboratory using a silicone-based material.

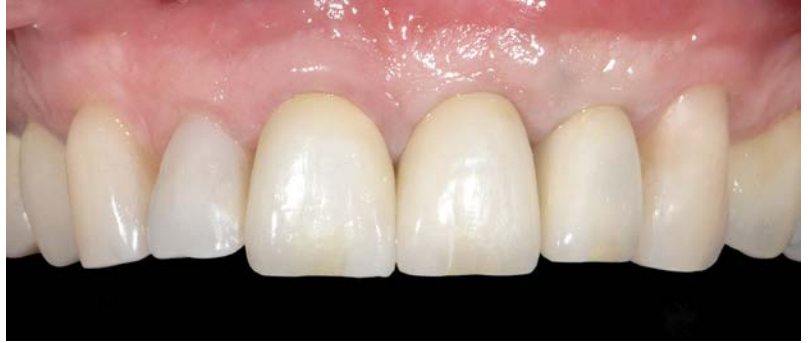

**Figure 34:** Cast gold abutments are connected to implants #9 and #10 and tested for their adequate relationship with the peri-implant mucosa.

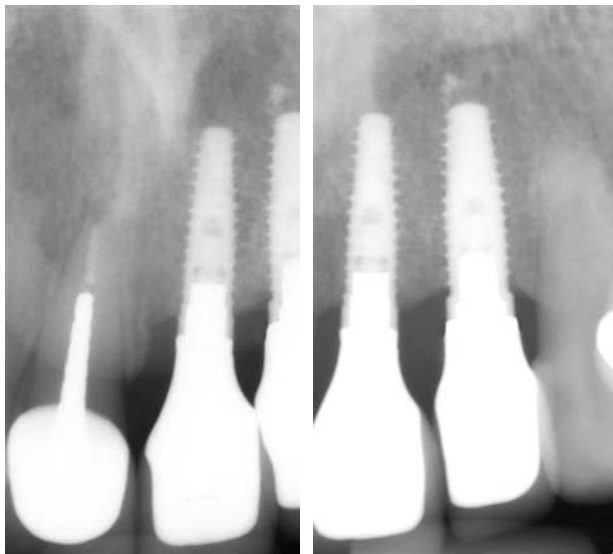




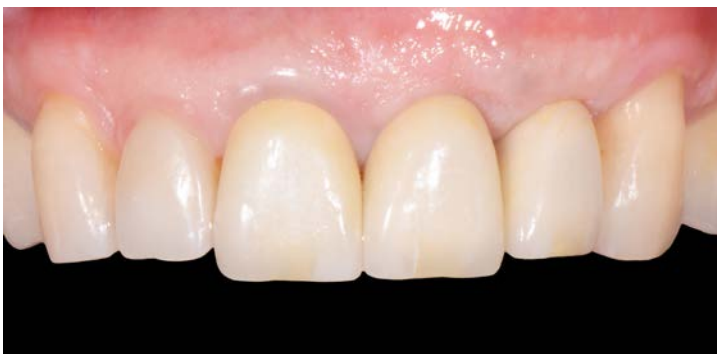**Figure 35:** Zirconia crowns are bonded to the gold abutments to become one-piece screw-retained crowns.



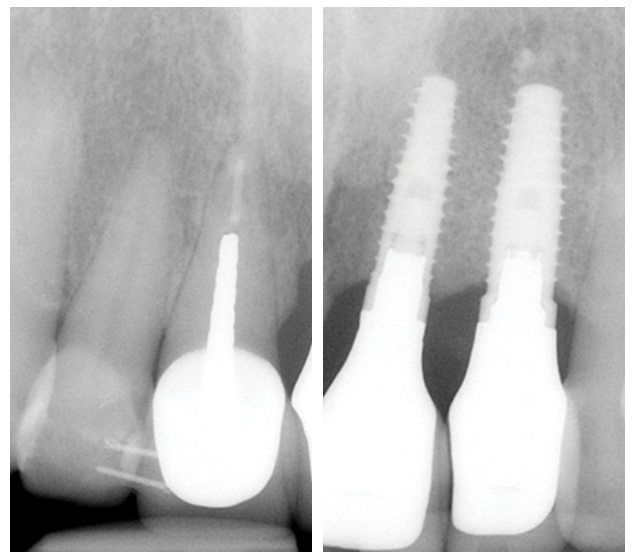
**Figure 36:** At the end of treatment, the final crowns appear to be surrounded by healthy and well-contoured soft tissue.



**Figures 37a & 37b:** At the end of treatment, both concave abutment transmucosal profiles and solid interproximal bone profiles are shown.



**Figure 38:** At the three-year follow-up, stable soft tissue topography is evident. Note slight marginal tissue cyanosis at #7 and #8.



**Figures 39a & 39b:** At the three-year follow-up, radiographic views demonstrate stable hard tissue profiles around the teeth and implants. Note splinting between #7 and #8.

## Discussion

Restoration of two missing maxillary central and lateral teeth with a functional and esthetic implant-supported prosthesis is still one of the most challenging procedures in implant dentistry. The reasons are threefold: the usually too-short ridge span, the multiple differences in the three-dimensional position of the implants, and the expectation that the implant-supported restoration would mimic its neighboring counterpart across the midline. The following surgical and prosthetic clinical guidelines were used when planning the presented case.

### Implant Placement Must be Prosthetically Driven

A clinician may find it very frustrating when trying to calculate and plan the correct three-dimensional implant positioning in this area. The generally known and accepted implant-to-implant<sup>2,6</sup> and implant-to-teeth<sup>2,18,19</sup> distances (> 4 mm and > 1.5 mm, respectively), as well as other pertinent dimensions, are calculated mainly for two-dimensional implant placement situations. In the central-lateral area, which is unique and different in its three-dimensional morphology for each patient, poor esthetics may result if these measurements are arbitrarily applied. To overcome this difficulty, it is necessary to use a prosthetically driven surgical stent, which should give almost no freedom of interpretation as to the exact positioning of the implants.<sup>20</sup> The acrylic surgical stent chosen for this case was fabricated as an exact copy of the provisional bridge. For stabilization, palatal rests were prepared on existing proximal #8 and #11. The surgical stent was planned for screw-retained crowns, while providing guidance for the desired three-dimensional positioning of the implants. During surgery, this stent design may allow for minute changes in final implant positioning. This is in contrast to a fully computerized surgical stent, which rigidly dictates only one implant position.

### Two Implants are Better Than One to Support a Central-Lateral Implant Restoration

Sufficient load-bearing capacity is usually provided by placing two medium-diameter (3.3 to 3.5 mm) implants in both a lateral and central incisor tooth position or, preferably, by a standard-diameter (3.7 to 4.1 mm) implant in the central tooth position and a medium-diameter implant in the lateral incisor tooth position. Additionally, the authors have experienced that recapturing an interproximal papilla of reasonable height is more predictably achieved between two adjacent implants, rather than between an implant and a pontic, provided bone level and quality are

For an esthetic implant-supported restoration mainly in the maxillary anterior area, both its bony and soft tissue housing should be of premium quality and sufficient quantity.

similar in both clinical situations. This is likely due to the ability of the prosthetic transmucosal parts to push and support the interproximal soft tissues significantly better than the supramucosal pontic.

In many cases, however, because the ridge is relatively short, the clinician may find it necessary to place only small-diameter implants (3.0 to 3.25 mm), use platform-switched abutment connections, place only one implant to hold a cantilevered bridge, or connect between a tooth and an implant. Only a few case reports have shown successful results, although short-term, using the above imperfect solutions.<sup>4,5,7,8</sup> The use of small-diameter implants or platform switching, and definitely cantilevering a single implant, may hold the potential risk of implant or abutment fractures. A well-thought-out clinical solution was recently suggested<sup>21</sup> in which the canine tooth is moved to the lateral position, thereby converting the “central-lateral dilemma” to a single incisor implant case. Also suggested was the maintenance of a root submerged under a single implant cantilevered pontic to enhance the soft tissue morphology.<sup>21</sup> In the presented case, the decision to place a standard-diameter implant in the lateral tooth position was based on the concerns that implant placement in the central tooth position would become unachievable (due to the challenging ridge anatomy), and that a cantilevered two-unit bridge would have to be constructed. In retrospect this approach was mistaken, as augmenting the ridge first might have allowed placement of a medium- or small-diameter implant, as is the preferred implant size in the lateral tooth position. This eventually would have resulted in delivery of separated central and lateral crowns supported by small- to medium-diameter implants.

### Soft Tissue May Significantly Compensate for Partially Missing Bone

For an esthetic implant-supported restoration mainly in the maxillary anterior area, both its bony and soft tissue housing should be of premium quality and sufficient quantity.<sup>1,22-28</sup> Reconstruction of both horizontal and vertical ridge dimensions around properly placed prosthetically driven dental implants may be predictably achieved. Nevertheless, to date, one of the most challenging goals of implant dentistry is the preservation or restoration of inter-implant papillae. Research has shown that, with or without special surgical manipulations, tissue thickness on top of the inter-implant crestal bone ranges from 2 to 4 mm.<sup>3</sup> This is because current implant designs may not allow for the reestablishment of a collagen fiber system similar to that normally found between adjacent teeth. Thus, support and maintenance of the inter-implant papilla may be dependent upon the physical support gained from the underlying bone and the approximating artificial crown surfaces, as well as on the physical properties of the papilla.<sup>1</sup> In the presented case, the regenerated bone height was definitely limited by the reduced peak of crestal bone at the mesial aspect of the left canine, the undesired resorption pattern around the wide and straight-

# Blueprints for Success: Achieving True Restoratively Driven Implant Dentistry



Presented by  
**Scott D. Ganz, DMD**  
in partnership with  
Valley Dental Arts

## “It’s not the Scan, It’s the Plan<sup>®</sup>”

Learn from one of the world’s leading experts on 3-D planning and interactive treatment planning in a collaborative, study club atmosphere. From single tooth to full-mouth reconstruction, this course will provide you with the tools you need to develop the best treatment plans for your patients, and create your own **Blueprints for Success**.

### Learn the latest in:

- 3D Imaging
- Computer Aided Implantology
- Dental Implant Prosthetics
- CAD CAM Technology

### Three, two-day intensive and interactive sessions Friday/Saturday:

- September 11–12
- November 6–7
- December 11–12

### For registration contact:

Connie Halfen  
Valley Dental Arts  
1.800.328.9157  
1.651.439.2855

**Location:**  
The Amara Institute at  
Valley Dental Arts,  
Minneapolis/St. Paul, MN

Attendees will receive  
42 continuing education  
(CE) credits



Approved PACE program Provider  
FAGD/MAGD Credit.  
Approval does not imply acceptance by a  
state or provincial board of dentistry or AGD  
endorsement. 08/01/2011 to 07/31/2015  
Provider ID# 218343



# Experience the Beauty and Precision!


Brilliant Esthetics... World Class Precision...  
Ultimate Performance... **For Every Indication!**

For aesthetically sensitive cases, no materials perform like IPS Empress® Esthetic, IPS e.max® and IPS e.max® CAD. No other laboratory can match Aurum Ceramic® in making the most of your Advanced Cosmetic restorations.

- A perfect fit in your practice... for strength, precision and aesthetics throughout the mouth.
- Beautiful, durable all-ceramic restorations - Crafted by the leader in Comprehensive Aesthetic and Implant Dentistry.
- Unique optical techniques create the ultimate esthetic result.
- Indicated for everything from single units to full mouth aesthetic cases.  
IPS e.max® is also a great choice for 3 unit anterior bridges (from 2nd bi-cuspid forward).

**Learn about IPS Empress® Esthetic, IPS e.max® and IPS e.max® CAD  
from Aurum Ceramic. Request your information package today!**


Visit our redesigned website at [www.aurumgroup.com](http://www.aurumgroup.com)

Connect with us on  @aurumgroup



Call your closest Aurum Ceramic Laboratory TOLL FREE

Nevada, Utah, New Mexico And Arizona: 1-877-254-5334  
Washington, Oregon, Montana And Idaho: 1-800-423-6509  
Other North American Locations: 1-800-661-1169

\*Designed and Manufactured in North America 



headed implants,<sup>29</sup> and other possible weaknesses of materials or methods in the bone regenerative procedure, as had been implemented. To compensate for the missing ideal configuration of the regenerated bone, it was necessary to augment the soft tissue component of the ridge more than is usually needed. Indeed, harvesting of the palatal connective tissue graft was performed three times, and together with flap advancements and other manipulations, adequate soft tissue ridge topography was finally achieved. No recession of the peri-implant tissues was noted three years after final crown connection and approximately three and a half years after final soft tissue augmentation. Evidently, the reduced crestal height was significantly compensated long term by the increased volume and quality of augmented soft tissue. Of special interest was the fact that a supracrestal 7- to 8-mm long central-lateral inter-implant papilla formed and was maintained at the three-year follow-up.

#### **Transmucosal Profiles Should be Gradually Developed**

The implant head is completely round and narrow when compared to the natural root of a given tooth. Consequently, the tissue around the healing abutment attains a similar round and narrow transmucosal configuration. However, the desired emerging tissue profiles must follow the natural tooth anatomy, which is mostly elliptical and wider.<sup>22,23</sup> This may be achieved with gradual pressure on the surrounding tissues by the provisional acrylic restorations.<sup>22,23,30</sup> The desired tissue profiles may be reached by adding small acrylic increments at two- to three-week intervals, taking care not to cause permanent tissue ischemia. These tissue profiles should remain supported and unchanged for at least two months by the final configuration of the provisional restorations to achieve advanced tissue maturation and stability before impression-taking for the final prosthesis.

#### **Transmucosal Emergence Profiles Should be Accurately Transferred to the Laboratory**

Once the desired topography of the peri-implant mucosa has been achieved, it is advisable to transfer the exact tissue profiles to the dental laboratory. This may become problematic, as the peri-implant soft tissues tend to partially collapse once the provisional restorations are removed for impression-taking. Advanced impression techniques have been proposed to overcome this tissue collapse.<sup>31-39</sup> In the presented case, a simplified method was used in which a precise soft tissue replica was achieved, leaving no place for guesswork in fabricating the emergence profiles of the final prosthesis.

## **Summary**

In implant dentistry, restoring the lateral-central edentulous ridge with implant-supported porcelain crowns may well be considered a unique esthetic challenge. It necessitates a variety of prosthetic and surgical considerations, many of which are unique to this area—and, of course, to the individual patient. Meticulous occlusal and prosthetic analysis, together with thorough periodontal assessment, must precede the treatment plan. The treatment plan, in turn, must include advanced bone and soft tissue regenerative procedures and laboratory techniques (and, obviously, well-constructed and designed implant surgical and prosthetic parts). The case presented demonstrates the difficulties that characterize the central-lateral area and ways to optimally overcome them. In these cases, the professional team's dedication and the patient's utmost cooperation are necessary to achieve satisfactory results.

## **References**

1. Landsberg CJ. Preservation of the interdental papilla in the esthetic zone. In: Romano R, editor. *The art of the smile: integrating prosthodontics, orthodontics, periodontics, dental technology, and plastic surgery in esthetic dental treatment*. Surrey (UK): Quintessence Pub.; 2005. p. 298-320.
2. Salama H, Salama MA, Garber D, Adar P. The interproximal height of bone: a guidepost to predictable aesthetic strategies and soft tissue contours in anterior tooth replacement. *Pract Periodontics Aesthet Dent*. 1998 Nov-Dec;10(9):1131-41.
3. Tarnow D, Elian N, Fletcher P, Froum S, Magner A, Cho SC, Salama M, Salama H, Garber DA. Vertical distance from the crest of bone to the height of the interproximal papilla between adjacent implants. *J Periodontol*. 2003 Dec;74(12):1785-8.
4. Barreto M, Francischone CE, Filho HN. Two prosthetic crowns supported by a single implant: an esthetic alternative for restoring the anterior maxilla. *Quintessence Int*. 2008 Oct;39(9):717-25.
5. Schoenbaum TR, Klokkevold PR, Chang YY. Immediate implant-supported provisional restoration with a root-form pontic for the replacement of two adjacent anterior maxillary teeth: a clinical report. *J Prosthet Dent*. 2013 May;109(5):277-82.
6. Tarnow DP, Cho SC, Wallace SS. The effect of inter-implant distance on the height of inter-implant bone crest. *J Periodontol*. 2000 Apr;71(4):546-9.
7. Tymstra N, Raghoebar GM, Vissink A, Meijer HJ. Dental implant treatment for two adjacent missing teeth in the maxillary aesthetic zone: a comparative pilot study and test of principle. *Clin Oral Implants Res*. 2011 Feb;22(2):207-13.
8. Nevins M, Nevins M, Gobbato L, Lee HJ, Wang CW, Kim DM. Maintaining interimplant crestal bone height via a combined platform-switched, Laser-Lok implant/abutment system: a proof-of-principle canine study. *Int J Periodontics Restorative Dent*. 2013 May-Jun;33(3):261-7.

9. Delgado-Ruiz RA, Calvo-Guirado JL, Abboud M, Ramirez-Fernandez MP, Maté-Sánchez JE, Negri B, Gomez-Moreno G, Markovic A. Connective tissue characteristics around healing abutments of different geometries: new methodological technique under circularly polarized light. *Clin Implant Dent Relat Res.* 2013;10:1-14.
10. Rompen E, Raepsaet N, Domken O, Touati B, Van Dooren E. Soft tissue stability at the facial aspect of gingivally converging abutments in the esthetic zone: a pilot clinical study. *J Prosthet Dent.* 2007 Jun;97(6 Suppl):S119-25.
11. Holt RL, Rosenberg MM, Zinser PJ, Ganeles J. A concept for a biologically derived, parabolic implant design. *Int J Periodontics Restorative Dent.* 2002 Oct;22(5):473-1.
12. Wöhrle PS. Nobel Perfect esthetic scalloped implant: rationale for a new design. *Clin Implant Dent Relat Res.* 2003;5(Suppl 1):64-73.
13. Siebert JS. Reconstruction of deformed, partially edentulous ridges, using full thickness onlay grafts. Part 1. Technique and wound healing. *Compend Cont Educ Dent.* 1983 Sep-Oct;4(5):437-53.
14. Miller PD Jr. A classification of marginal tissue recession. *Int J Periodontics Restorative Dent.* 1985;5(2):8-13.
15. Zucchelli G, Mele M, Stefanini M, Mazzotti C, Mounssif I, Marzadori M, Montebugnoli L. Predetermination of root coverage. *J Periodontol.* 2010 Jul;81(7):1019-26.
16. Landsberg CJ. Complete flap coverage in augmentation procedures around dental implants using the everted crestal flap. *Pract Periodontics Aesthet Dent.* 1995 Mar;7(2):13-22.
17. Palacci P. Aesthetic treatment of the anterior maxilla: soft and hard tissue considerations. *Oral Maxillofac Surg Clin North Am.* 2004 Feb;16(1):127-37.
18. Esposito M, Ekstubby A, Gröndahl K. Radiological evaluation of marginal bone loss at tooth surfaces facing single Brånemark implants. *Clin Oral Implants Res.* 1993 Sep;4(3):151-7.
19. Buser D, Martin W, Belser UC. Optimizing esthetics for implant restorations in the anterior maxilla: anatomic and surgical considerations. *Int J Oral Maxillofac Implants.* 2004;19 Suppl:43-61.
20. Garber DA, Belser UC. Restoration-driven implant placement with restoration-generated site development. *Compend Contin Educ Dent.* 1995 Aug;16(8):796, 798-802, 804.
21. Salama AM. The central-lateral replacement dilemma in esthetic implant dentistry: clinical alternatives and case management. Seattle Study Club National Symposium; 2009 Jan 25; Scottsdale, AZ.
22. Bichacho N, Landsberg CJ. Single implant restorations: prosthetically induced soft tissue topography. *Pract Periodontics Aesthet Dent.* 1997 Sep;9(7):745-52.
23. Bichacho N, Landsberg CJ. A modified surgical/prosthetic approach for an optimal single implant-supported crown. Part II. The cervical contouring concept. *Pract Periodontics Aesthet Dent.* 1994 May;6(4):35-41.
24. Phillips K, Kois JC. Aesthetic peri-implant site development. The restorative connection [review]. *Dent Clin North Am.* 1998 Jan;42(1):57-70.
25. Touati B, Guez G, Saadoun A. Aesthetic soft tissue integration and optimized emergence profile: provisionalization and customized impression coping. *Pract Periodontics Aesthet Dent.* 1999 Apr;11(3):305-14; quiz 316.
26. Smukler H, Castellucci E, Capri D. The role of the implant housing in obtaining aesthetics: generation of peri-implant gingivae and papillae—part 1. *Pract Proced Aesthet Dent.* 2003 Mar;15(2):141-9.
27. Smukler H, Castellucci E, Capri D. The role of the implant housing in obtaining aesthetics: part 2. Customizing the peri-implant soft tissue. *Pract Proced Aesthet Dent.* 2003 Jul;15(6):487-90.
28. Ishikawa T, Salama M, Funato A, Kitajima H, Moroi H, Salama H, Garber D. Three-dimensional bone and soft tissue requirements for optimizing esthetic results in compromised cases with multiple implants. *Int J Periodontics Restorative Dent.* 2010 Oct;30(5):503-11.
29. Pozzi A, Agliardi E, Tallarico M, Barlattani A. Clinical and radiological outcomes of two implants with different prosthetic interfaces and neck configurations: randomized, controlled, split-mouth clinical trial. *Clin Implant Dent Relat Res.* 2014 Feb;16(1):96-106.
30. Wittneben JG, Buser D, Belser UC, Brägger U. Peri-implant soft tissue conditioning with provisional restorations in the esthetic zone: the dynamic compression technique. *Int J Periodontics Restorative Dent.* 2013 Jul-Aug;33(4):447-55.
31. Papadopoulos I, Pozidi G, Goussias H, Kourtis S. Transferring the emergence profile from the provisional to the final restoration. *J Esthet Restor Dent.* 2014 May-Jun;26(3):154-61.
32. Parpaiola A, Sbricoli L, Guazzo R, Bressan E, Lops D. Managing the peri-implant mucosa: a clinically reliable method for optimizing soft tissue contours and emergence profile. *J Esthet Restor Dent.* 2013 Oct;25(5):317-23.



33. Elian N, Tabourian G, Jalbout ZN, Classi A, Cho SC, Froum S, Tarnow DP. Accurate transfer of peri-implant soft tissue emergence profile from the provisional crown to the final prosthesis using an emergence profile cast. *J Esthet Restor Dent.* 2007;19(6):306-14.
34. Azer SS. A simplified technique for creating a customized gingival emergence profile for implant-supported crowns. *J Prosthodont.* 2010 Aug;19(6):497-501.
35. Mojon P, Oberholzer JP, Meyer JM, Belser UC. Polymerization shrinkage of index and pattern acrylic resins. *J Prosthet Dent.* 1990 Dec;64(6):684-8.
36. Chee WW, Cho GC, Ikoma MM, Arcidiacono A. A technique to replicate soft tissues around fixed restoration pontics on working casts. *J Prosthodont.* 1999 Mar;8(1):44-6.
37. Chee WW1, Cho GC, Ha S. Replicating soft tissue contours on working casts for implant restorations. *J Prosthodont.* 1997 Sep;6(3):218-20.
38. Bain CA, Weisgold AS. Customized emergence profile in the implant crown—a new technique. *Compend Contin Educ Dent.* 1997 Jan;18(1):41-5.
39. Simeone P, De Paoli C, De Paoli S, Leofreddi G, Sgrò S. Interdisciplinary treatment planning for single-tooth restorations in the esthetic zone. *J Esthet Restor Dent.* 2007;19(2):79-88. **jCD**

To compensate for the missing ideal configuration of the regenerated bone, it was necessary to augment the soft tissue component of the ridge more than is usually needed.



Dr. Landsberg maintains a private practice limited to periodontics and implant and regenerative surgery in Tel Aviv, Israel.



Dr. Sawdayee maintains private practices in Jerusalem and Tel Aviv, Israel.

Disclosures: The authors did not report any disclosures.



# Immediate Extraction and Placement of an Implant


## Using a Natural Tooth as a Screw-Retained Provisional

Robert C. Margeas, DDS

### Abstract

Implants have become a common restorative option and clinical research has shown the benefits of immediate provisionalization in the maintenance of papilla and the development of an ideal emergence profile. This article offers clinicians another option for immediate implant loading and provisionalization and suggests a unique technique for the utilization and modification of the extracted tooth as an immediate temporary. This technique can produce ideal results for the patient.

**Key Words:** natural tooth screw-retained provisional, anterior implant, immediate provisionalization, natural tooth abutment



Immediate implant placement using a single-stage surgical approach can reduce the duration of treatment, preserve papilla, and limit apical migration of the free gingival margin.



## Introduction

The loss of a tooth in the anterior esthetic region as a result of periodontal disease, trauma, endodontic failure, or root resorption can be a traumatic experience. Traditional implant therapy often required two to three months of alveolar ridge remodeling after tooth extraction and an additional six months of non-loaded healing for implant osseointegration to be successful.<sup>1-3</sup> Esthetic single-tooth implant placement using a traditional two-stage surgery has been well documented in the literature.<sup>4-6</sup> Many complications can occur during the healing phase, including loss of papilla as a result of flap elevation or blunting of the papilla caused by provisionalization with a removable appliance that is not stable. Bone and gingival tissue loss after maxillary anterior tooth extraction and implant surgery may present additional esthetic challenges.<sup>7</sup> Clinical and histologic studies have demonstrated that non-submerged implants osseointegrate as well as submerged implants and function comparably under load over extended periods.<sup>8-11</sup> Immediate implant placement using a single-stage surgical approach can reduce the duration of treatment, preserve papilla, and limit apical migration of the free gingival margin. Several studies have shown successful bone regeneration in extraction sites around immediately placed implants with clinical results similar to two-stage procedures.<sup>12-15</sup>

## Factors to Consider

Treatment that utilizes extraction, implant placement, and provisionalization combines surgical and restorative principles for tooth replacement. The advantages to this approach include better patient acceptance and comfort, and increased esthetics. When using a fixed provisional, the patient's phonetics are much better than when using a removable appliance. Immobile immediate provisionalization can enhance soft tissue management as well.<sup>16-18</sup>

When using a flapless, one-stage approach, soft tissue healing and maturation can occur simultaneously with implant integration. In addition, implant placement into a fresh extraction site provides an adequate blood supply to the wound and allows sufficient bone maintenance as resorption and remodeling have not yet occurred. Raising a surgical flap compromises the bone vascularization and may result in marginal bone loss<sup>19</sup> and soft tissue recession with collapse of the interdental papillae, particularly in the presence of thin, scalloped gingiva.<sup>11</sup>

## Gingival Margin

As with traditional implant treatment, approximately 1 mm of gingival recession may occur at the free gingival margin after placement of the definitive restoration.<sup>20,21</sup> This can be attributed to the biologic width formation after repeated removal and replacement of the implant components during impression making, try in, and fitting of the restoration.<sup>22,23</sup>

If a failing tooth has a free gingival margin positioned more incisally compared to the adjacent tooth, it will allow the final free gingival margin to be similar following apical migration of 1 mm after implant placement. A hopeless tooth with the free gingival margin positioned ideally or more apically would benefit from orthodontic extrusion before extraction.<sup>24,25</sup>

## Gingival Scallop

The form of the periodontium plays an important part in the final esthetics of the implant restoration.<sup>26</sup> The three categories of gingival scallop are high, normal, and flat. Based upon a clinical survey of 100 patients, the average or normal gingival scallop is positioned 4 to 5 mm more incisally than the free gingival margin.<sup>27</sup> The high or long gingival scallop will have a much higher risk for gingival loss or flattened papilla after extraction versus the normal or flat scallop. The flat scallop has less volume of papilla in the interproximal area; therefore, it is much more predictable and maintainable after extraction. One of the principal advantages of the immediate technique is the prevention of post-extraction bone resorption. Bone loss can affect approximately 23% of the anterior alveolar crests during the six months after extraction.<sup>7</sup>

The adjacent teeth had not been restored previously, so the patient chose to have an implant-supported restoration to avoid preparation of the adjacent teeth.

## FACTORS TO CONSIDER

- Patient's acceptance and comfort
- Patient's phonetics
- Soft tissue management
- Implant integration
- Sufficient bone maintenance
- Gingival margin
- Gingival scallop
- Infection

Approximately 85% of the population present with thick, flat periodontal forms; the periodontal architecture of the remaining population is thin and scalloped.

### Infection

Infection affecting the tooth being extracted can be a contraindication to the immediate technique, as it is most often accompanied by apical or lateral bone loss that can impair primary stability. This must be evaluated on a case-by-case basis. Primary stability after implant placement is important when provisionalizing immediately. Drilling 3 mm to 5 mm beyond the apical limit (in a palatal direction) can ensure sufficient stability.<sup>28</sup>

### Research

The success rates achieved using this single-stage approach contradict the basic tenets of the original Brånemark technique, which was to allow the implants to be covered and to protect the implant against early loading. It appears that it is not early loading that creates the effect of fibrous encapsulation, but rather a certain degree of micro movements at the bone-implant interface<sup>29</sup> resulting from inadequate primary stability. Various experimental studies indicate that the range of tolerance of these micro movements is approximately 50 to 150  $\mu$  for rough surfaces<sup>30-32</sup> and about 100  $\mu$  for smooth, machined surfaces.<sup>33</sup> Thus, the implant surface is not an indifferent factor in the process of bone healing. Rough surfaces appear to tolerate greater micro movements and, therefore, could be placed under load at an earlier time.<sup>34</sup>

Research on the preservation of the tissue architecture, reduction of surgical sequences, enhancement of patient comfort during provisionalization, and greater esthetic requirements<sup>35</sup> has led many practitioners to consider immediate replacement of the missing or freshly extracted tooth.

Care must be taken when an immediate single-tooth implant restoration is planned in the anterior region. Successful esthetic results ultimately may be determined by the patient's presenting anatomy rather than the clinician's ability to manage state-of-the-art procedures.<sup>26</sup>

## Case Presentation

### Patient History

A 50-year-old female presented with a failing root canal of her maxillary left central incisor. Available restorative options were presented to the patient; these included a removable partial denture, a fixed bridge, or an implant-supported restoration. The adjacent teeth had not been restored previously, so the patient chose to have an implant-supported restoration to avoid preparation of the adjacent teeth. The patient also did not want to wear a removable appliance during the implant healing phase. There was no active infection present. Periodontal evaluation revealed a thick, normally scalloped periodontal biotype.

### Discussion

Approximately 85% of the population present with thick, flat periodontal forms; the periodontal architecture of the remaining population is thin and scalloped.<sup>36</sup> Although the amount of postoperative soft tissue modifications is generally minimal for patients with thick and flat gingiva, significant changes have been observed in those with thin and scalloped biotypes.<sup>25</sup>

The projected interproximal tissue height depends upon the interproximal bone height of the adjacent teeth. Bone sounding of the teeth adjacent to the failing tooth can ascertain predictable interproximal tissue height.

In this patient, a normal osseous crest was revealed after bone sounding. Gingival tissue was approximately 3 mm from the osseous crest facially and 4 mm interproximally. The risks and benefits of treatment were presented to the patient, and an implant was selected for immediate placement and fixed provisionalization using the patient's natural tooth as a screw-retained provisional. Using the natural tooth as a provisional will allow tissue support and create an emergence profile similar to the pre-extraction condition. This will support the peri-implant mucosa and maintain the papilla height, gingival outline, and tissue form throughout the osseointegration phase. Wöhrle has described several reports with simultaneous provisionalization on an implant placed into an extraction socket.<sup>37</sup>

Maintenance of gingival tissues and papillae can be a demanding task when using a full periosteal flap reflection. Several reports have proposed implant placement without flap elevation to minimize bone loss.<sup>38,39</sup> The lack of direct visibility in flapless surgery may present limitations that require careful evaluation of the osseous topography as well as meticulous surgical execution.<sup>40</sup>



### Treatment

The patient presented at my office following a traumatic removal of her left central incisor and placement of a bone level implant (Straumann USA; Andover, MA) with a healing abutment (Fig 1). The implant insertion torque was 45 Ncm, which allowed us to provisionalize immediately (if the insertion torque is below 40 Ncm, I am reluctant to place a fixed provisional). The healing abutment was removed (Fig 2). Figure 3 shows the intact natural tooth. A Straumann Meso polyether ether ketone (PEEK) abutment was placed and lightly tightened (Fig 4). The abutment was marked in the mouth, outlining the free gingival margin and then removed for contouring (Fig 5). A diamond bur (KS2, Brasseler USA; Savannah, GA) was used to prepare the abutment out of the mouth, similar to a crown preparation (Fig 6). The root was then removed with a new KS2 diamond bur and hollowed out, and a lingual access opening was placed through the enamel (Figs 7 & 8). The tooth was placed on the abutment to determine whether the access opening was in the right place and the screw would exit the lingual (Fig 9). To prevent the relining material entering the screw access channel, a cotton stick applicator was placed and lubricated with petroleum jelly (Fig 10). The shell of the tooth was filled with Snap acrylic (Parkell; Edgewood, NY), placed onto the abutment, and allowed to set (Figs 11 & 12). Once set, a screwdriver was placed into the screw access hole and the tooth was removed along with the abutment that had the reline material attached to it (Fig 13). Most of the time the tooth needs to be relined because the margins cannot be accurately obtained with the acrylic material (Fig 14). It is very important to accurately capture the margins by bead brushing the margins to fill in the gaps (Fig 15). Once the margins were captured with the acrylic and allowed to set, the provisional was trimmed and polished, creating a flat or concave emergence profile on the facial (Figs 16-18). The tooth was screw-retained into the implant and tightened as much as possible by hand (Fig 19). The tooth on the day it was placed is seen in Figure 20. The tooth was taken out of occlusion and the patient was instructed not to bite directly on it.

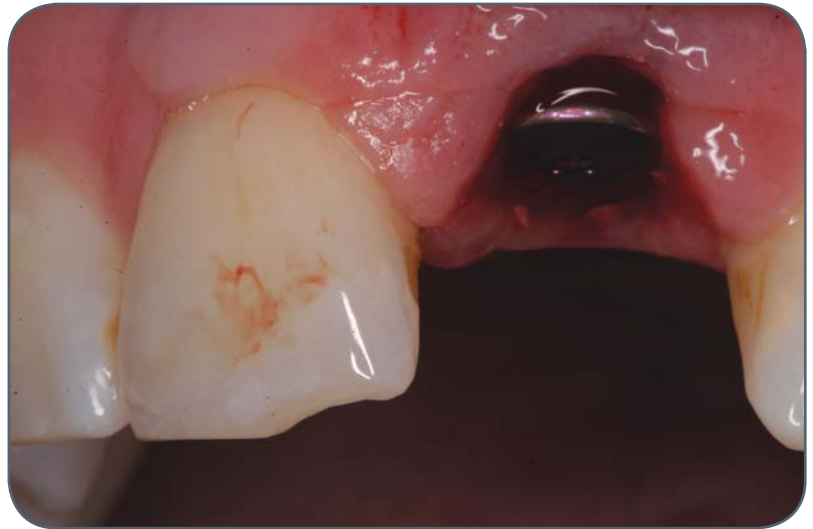

Figure 1: Implant placed with healing abutment.

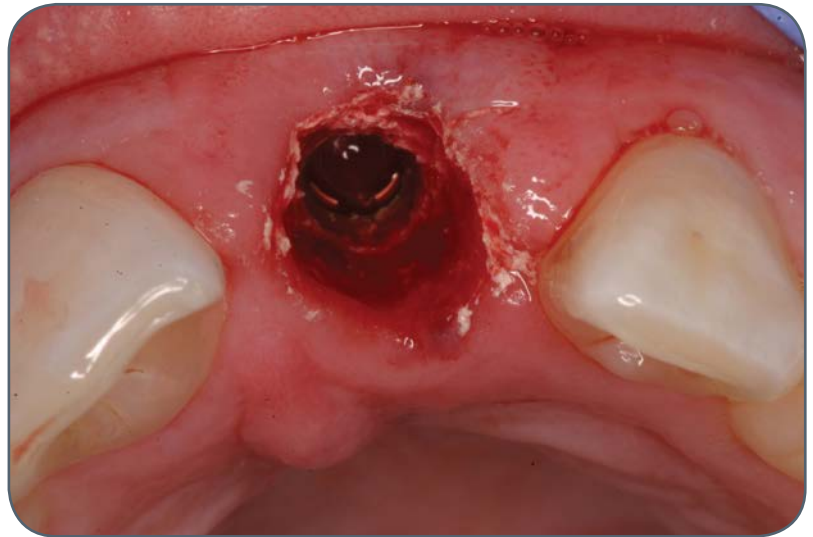
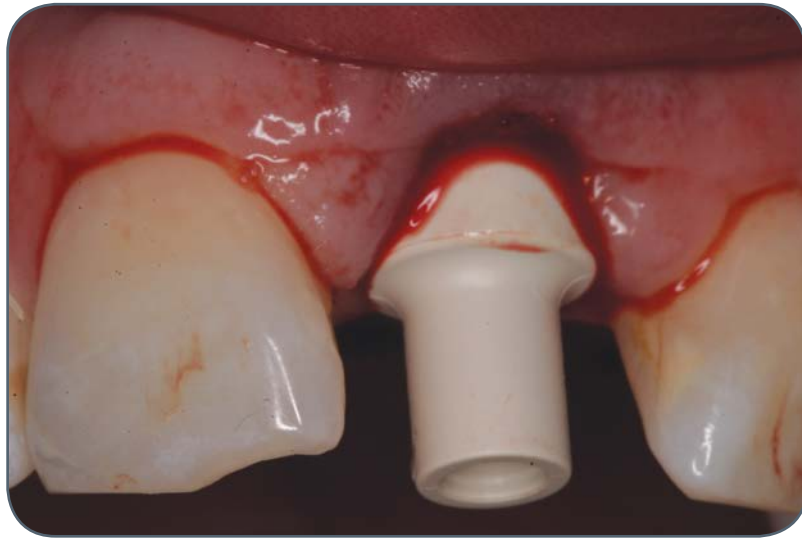


Figure 2: Abutment removed.

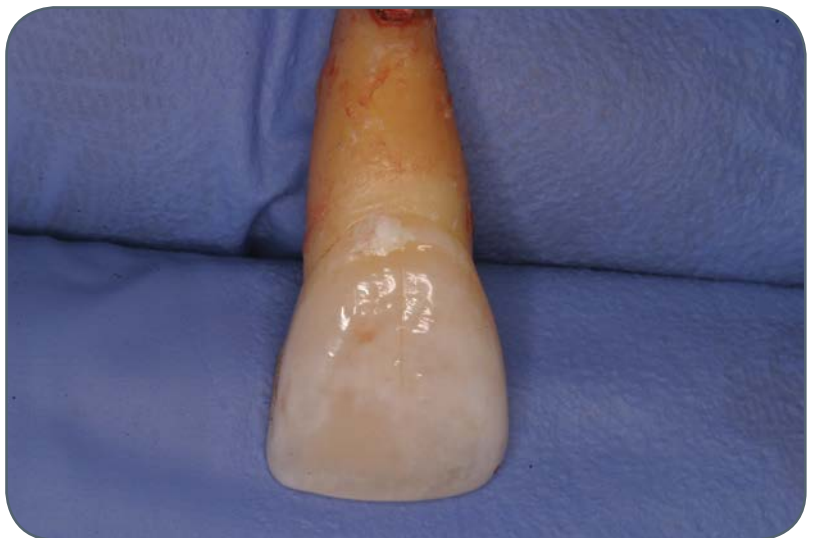


Figure 3: Extracted tooth.



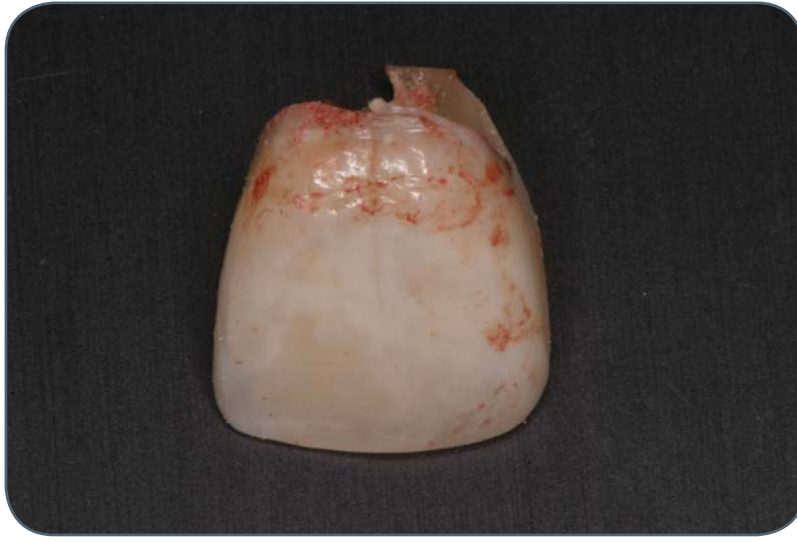**Figure 4:** Preparable abutment placed.



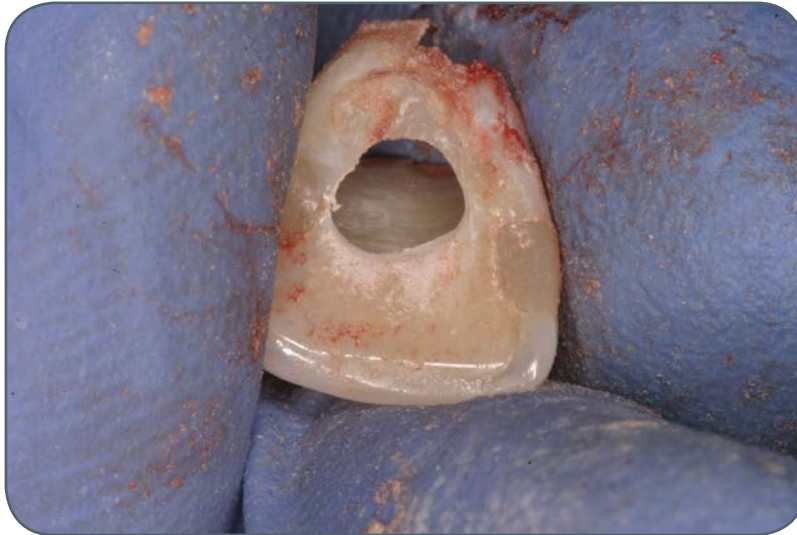**Figure 5:** Abutment marked and removed from the mouth.



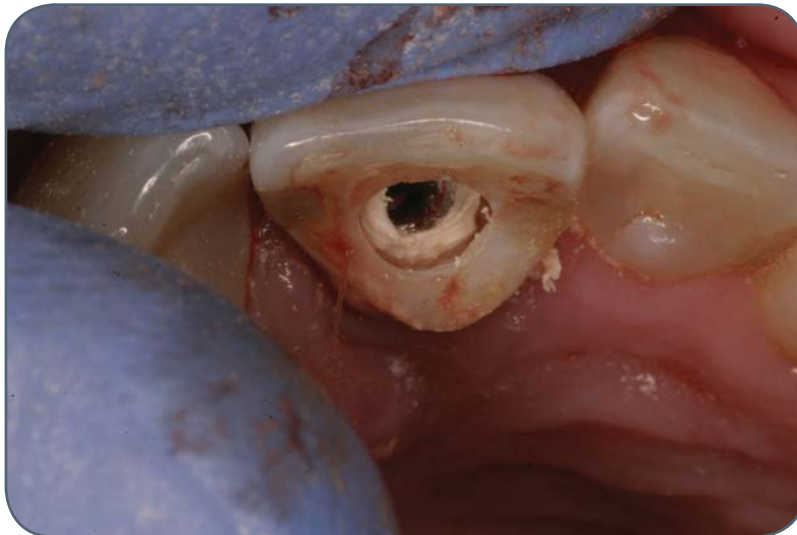**Figure 6:** Abutment prepared outside the mouth.



**Figure 7:** Root cut off at cemento-enamel junction and hollowed out.

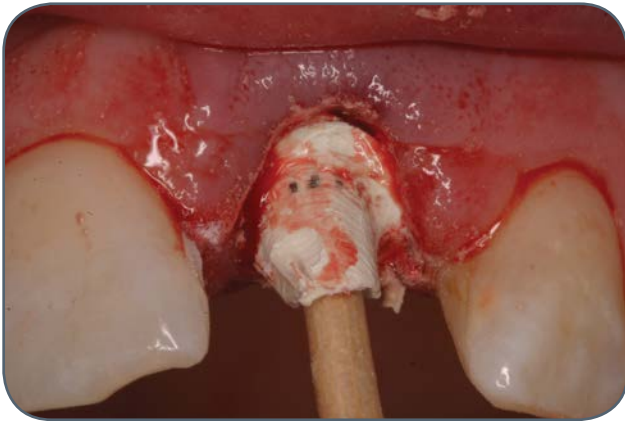


**Figure 8:** Hole prepared on lingual for screw access.

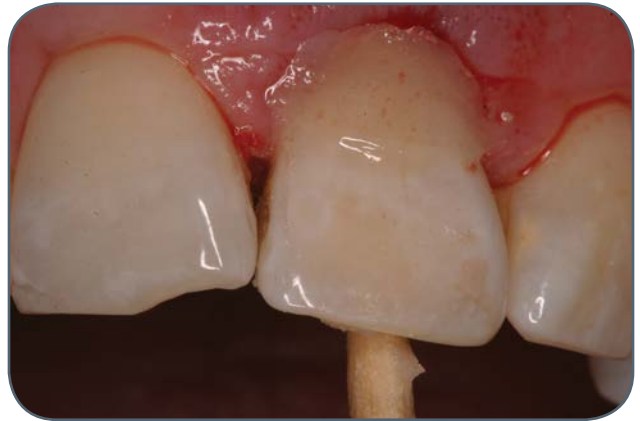

**Figure 9:** Tooth fit over abutment.

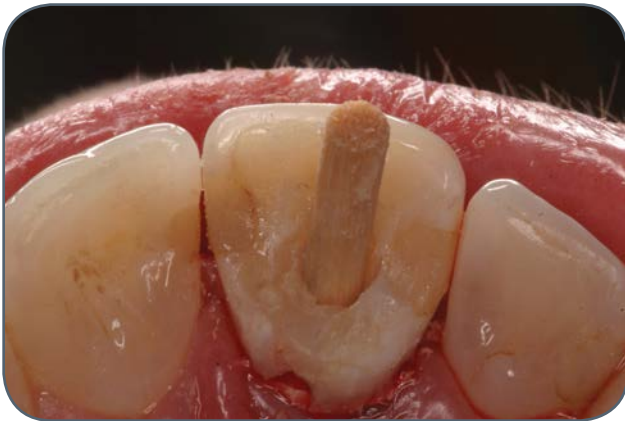



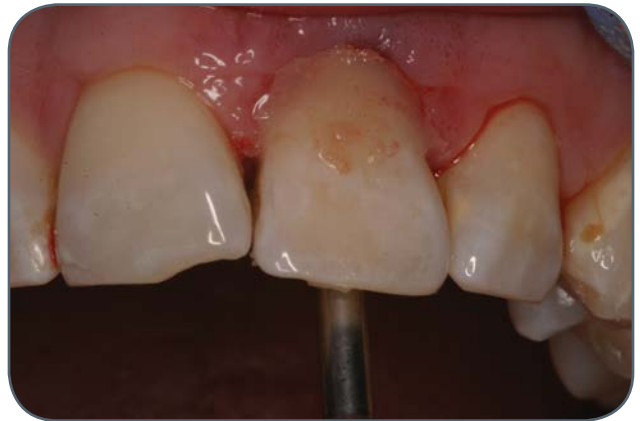**Figure 10:** Cotton stick applicator placed in abutment to prevent screw from being locked in.



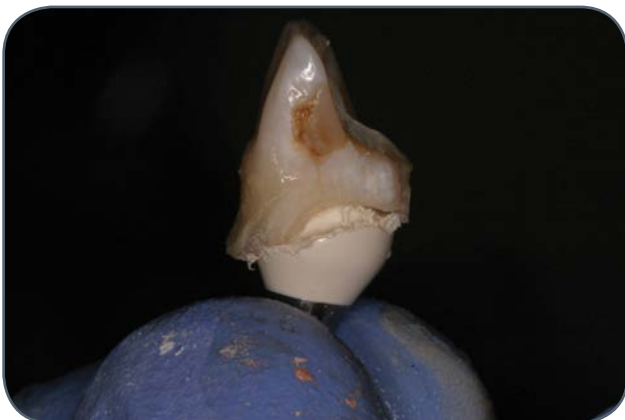**Figure 11:** Acrylic placed in tooth and fit onto abutment.



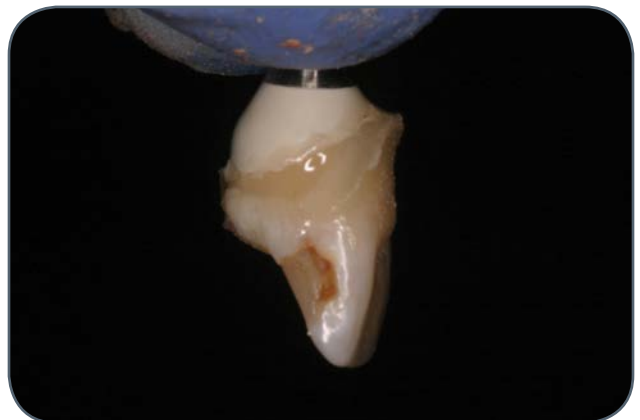**Figure 12:** Lingual view of access.



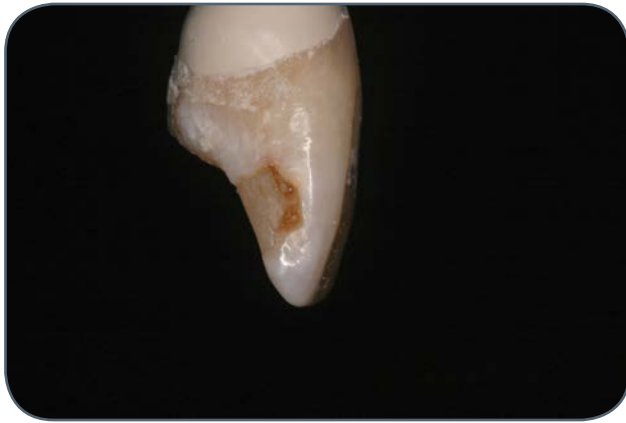**Figure 13:** Screwdriver placed to remove restoration.



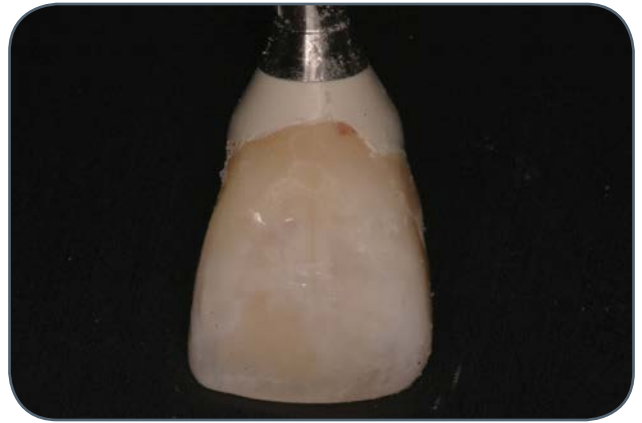**Figure 14:** Tooth on abutment needing reline.



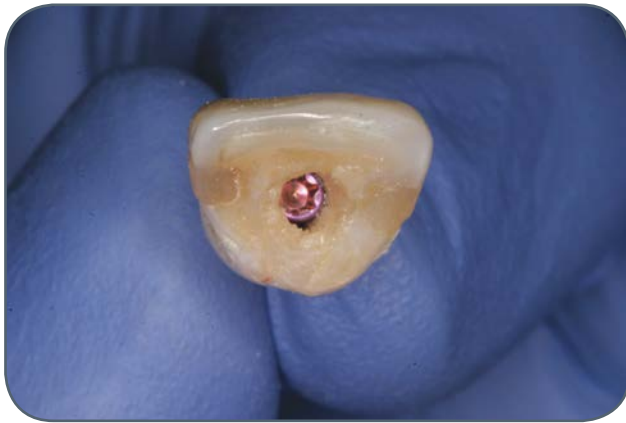**Figure 15:** Reline material added.



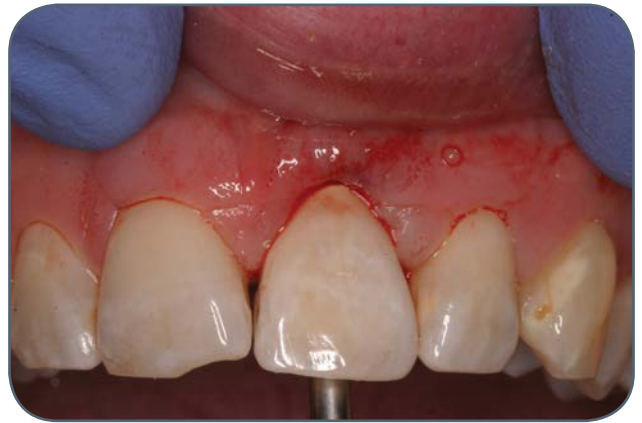**Figure 16:** Tooth polished at margins.



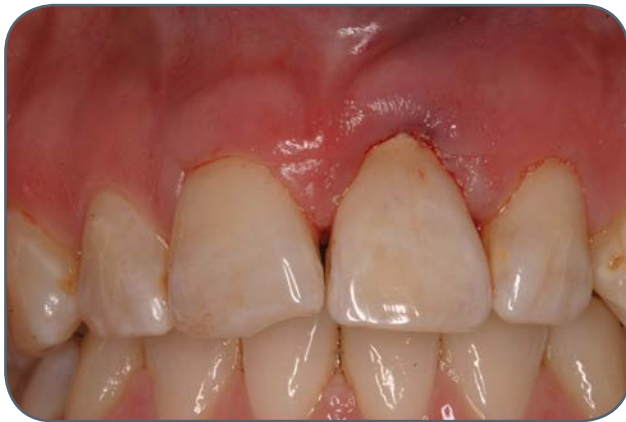**Figure 17:** Tooth polished at margins.



**Figure 18:** Lingual view showing screw access.



**Figure 19:** Tooth being screwed in on day of surgery.



**Figure 20:** Tooth screwed in and taken out of occlusion.

The projected interproximal tissue height depends upon the interproximal bone height of the adjacent teeth.

## Treatment Tips

- If the implant insertion torque is below 40 Ncm, the author is reluctant to place a fixed provisional.
- Place the tooth on the abutment to determine whether the access opening is in the right place and the screw will exit the lingual.
- Use a cotton stick applicator lubricated with petroleum jelly to prevent the relining material entering the screw access channel.
- Keep in mind that most of the time the tooth needs to be relined because the margins cannot be accurately obtained with the acrylic material.
- It is very important to accurately capture the margins by bead brushing the margins to fill in the gaps.

### Postoperative

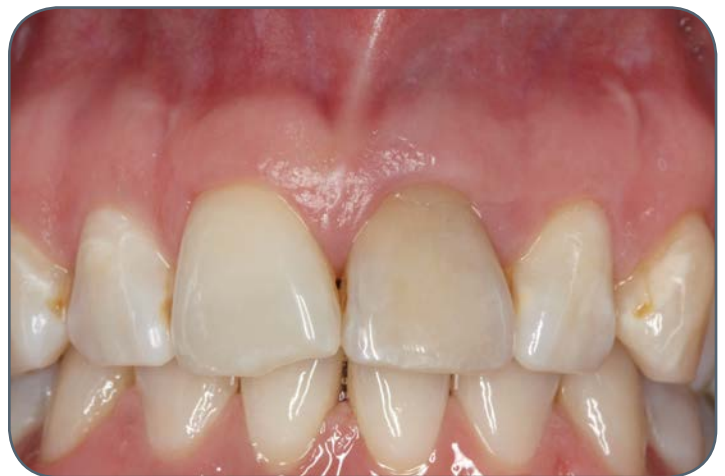The patient returned for the final impressions three months after surgery. The tooth appears to have served its purpose, based upon the excellent appearance of the provisional and the free gingival margin (Fig 21). The tooth was removed, revealing a nice gingival scallop (Fig 22). An impression coping was placed (Fig 23) and a final impression was made for a screw-retained restoration. The patient returned three weeks later and the final restoration was screw-retained into the implant (Fig 24). The lingual access (Fig 25) was filled with polytetrafluoroethylene tape and composite resin to seal. Final postoperative images are shown in Figures 26 and 27.

### Summary

Immediate provisional restorations placed on immediate implants in extraction sockets enhance the preservation of the soft and hard tissue contour. Use of the natural tooth on the abutment will provide an emergence profile similar to the pre-existing condition. This is particularly advantageous for the thin periodontium, where there is greater chance for bone and tissue recession. It is important to evaluate the patient thoroughly before attempting this technically demanding procedure.

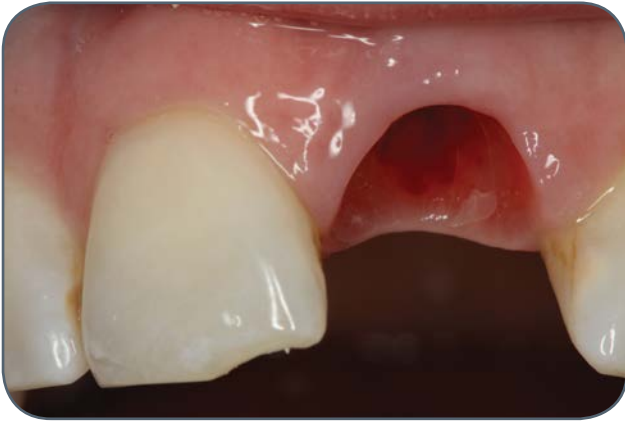
### Acknowledgments

*The author thanks oral surgeon John Maletta, DDS, MS (Des Moines, IA) and laboratory technician Freddy Char (Elite Dental Studio; Des Moines, IA) for their help and work on this case.*

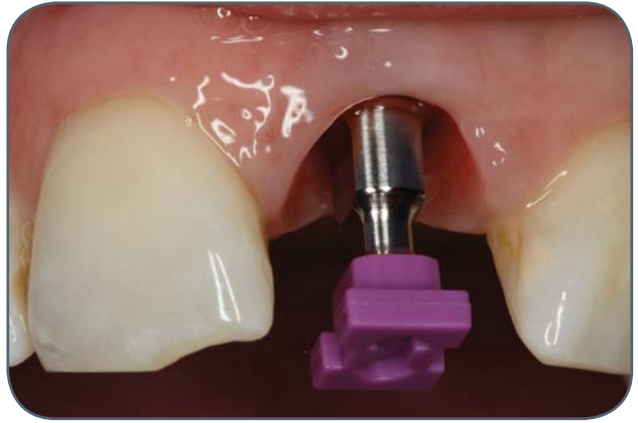

**Figure 21:** Tooth three months after surgery.

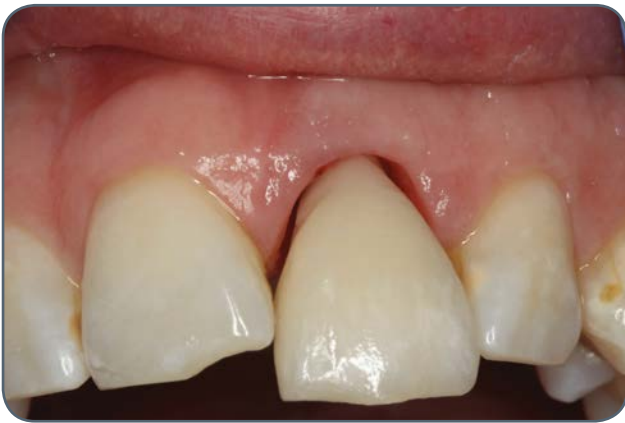



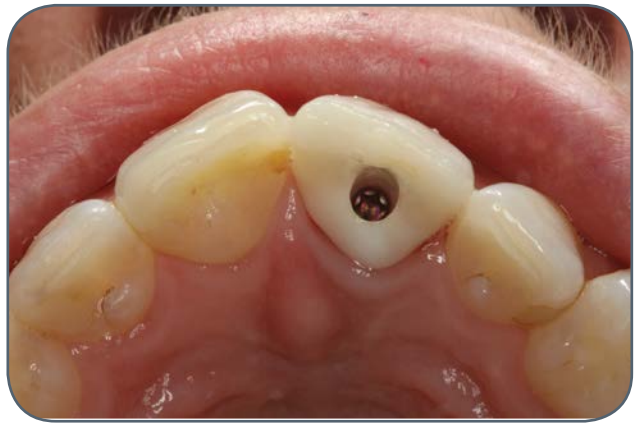**Figure 22:** Tooth removed, ready for impression.



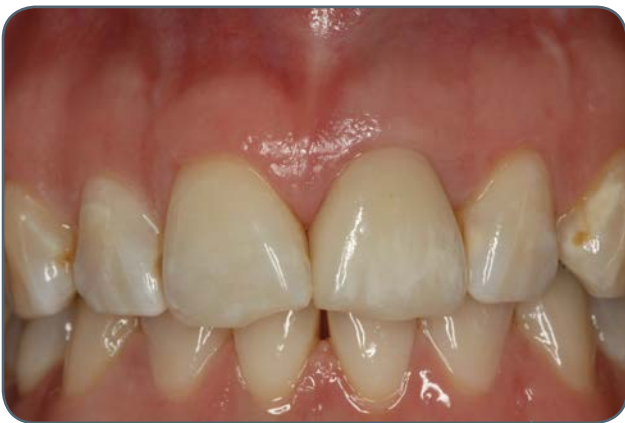**Figure 23:** Impression post placed.



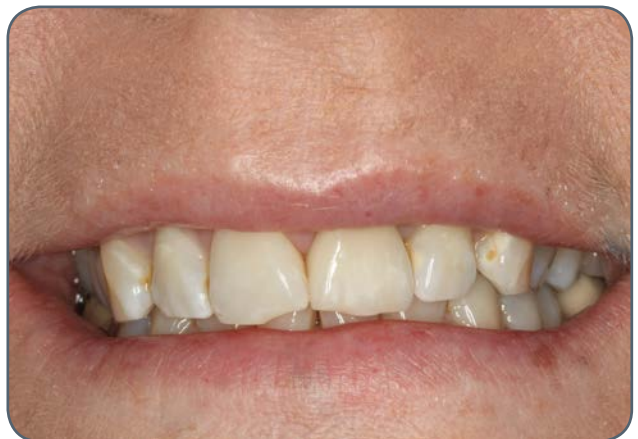**Figure 24:** Final screw-retained restoration being placed.



**Figure 25:** Lingual view.



**Figure 26:** Final screw-retained restoration.



**Figure 27:** Final postoperative image.

## References

1. Andersson B, Odman P, Lindvall AM, Lithner B. Single-tooth restorations supported by osseointegrated implants: results and experiences from a prospective study after 2 to 3 years. *Int J Oral Maxillofac Implants*. 1995 Nov-Dec;10(6):702-11.
2. Avivi Arber L, Zarb GA. Clinical effectiveness of implant-supported single-tooth replacement: the Toronto Study. *Int J Oral Maxillofac Implants*. 1996 May-Jun;11(3):311-21.
3. Brånemark PI. Osseointegration and its experimental background. *J Prosthet Dent*. 1983 Sep;50(3):399-410.
4. Becker W, Becker BE. Flap designs for minimization of recession adjacent to maxillary anterior implant sites: a clinical study. *Int J Oral Maxillofac Implants*. 1996 Jan-Feb;11(1):46-54.
5. Israelson H, Plamons JM. Dental implants, regenerative techniques, and periodontal plastic surgery to restore maxillary anterior esthetics. *Int J Oral Maxillofac Implants*. 1993;8(5):555-61.
6. Mathews DP. Soft tissue management around implants in the esthetic zone. *Int J Periodontics Restorative Dent*. 2000 Apr;20(2):141-9.
7. Carlsson GE, Bergman B, Hedegard B. Changes in contour of the maxillary alveolar process under immediate dentures. A longitudinal clinical and x-ray cephalometric study covering 5 years. *Acta Odontol Scand*. 1967 Jun;25(1):45-75.
8. Leimola-Virtanen R, Peltola J, Oksala E, Helenius H, Happonen RP. III titanium plasma-sprayed screw implants in the treatment of edentulous mandibles: a follow-up study of 39 patients. *Int J Oral Maxillofac Implants*. 1995 May-Jun;10(3):373-8.
9. Buser D, Mericske-Stern R, Bernard JP, Behneke A, Behneke N, Hirt HP, Belser UC, Lang NP. Long-term evaluation of non-submerged III implants. Part 1: 8-year life table analysis of a prospective multi-center study with 2359 implants. *Clin Oral Implants Res*. 1997 Jun;8(3):161-72.
10. Vassos DM. Single-stage surgery for implant placement: a retrospective study. *J Oral Implantol*. 1997;23(4):181-5.
11. Becker W, Becker BE, Israelson H, Lucchini JP, Handelsman M, Ammons W, Rosenberg E, Rose L, Tucker LM, Lekholm U. One-step surgical placement of Brånemark implants: a prospective multicenter clinical study. *Int J Oral Maxillofac Implants*. 1997 Jul-Aug;12(4):454-62.
12. Grunder U, Polizzi G, Goené R, Hatano N, Henry P, Jackson WJ, Kawamura K, Köhler S, Renouard F, Rosenberg R, Triplett G, Werbit M, Lithner B. A 3-year prospective multicenter follow-up report on the immediate and delayed immediate placement of implants. *Int J Oral Maxillofac Implants*. 1999 Mar-Apr;14(2):210-6.
13. Becker BE, Becker W, Ricci A, Geurs N. A prospective clinical trial of endosseous screw-shaped implants placed at the time of tooth extraction without augmentation. *J Periodontol*. 1998 Aug;69(8):920-6.
14. Rosenquist B, Grenthe B. Immediate placement of implants into extraction sockets: implant survival. *Int J Oral Maxillofac Implants*. 1996 Mar-Apr;11(2):205-9.
15. Schwartz-Arad D, Grossman Y, Chaushu G. The clinical effectiveness of implants placed immediately into fresh extraction sites of molar teeth. *J Periodontol*. 2000 May;71(5):839-44.
16. Bain CA, Weisgold AS. Customized emergence profile in the implant crown—a new technique. *Compend Contin Educ Dent*. 1997 Jan;18(1):41-5.
17. Chee WW, Donovan T. Use of provisional restorations to enhance soft-tissue contours for implant restorations. *Compend Contin Educ Dent*. 1998 May;19(5):481-6, 488-9.
18. Markus SJ. Interim esthetic restorations in conjunction with anterior implants. *J Prosthet Dent*. 1999 Aug;82(2):233-6.
19. Brägger U, Häfeli U, Huber B, Hammerle CH, Lang NP. Evaluation of postsurgical crestal bone levels adjacent to non-submerged dental implants. *Clin Oral Implants Res*. 1998 Aug;9(4):218-24.
20. Grunder U. Stability of the mucosal topography around single-tooth implants and adjacent teeth: 1-year results. *Int J Periodontics Restorative Dent*. 2000 Feb;20(1):11-7.
21. Small PN, Tarnow DP. Gingival recession around implants: a 1-year longitudinal prospective study. *Int J Oral Maxillofac Implants*. 2000 Jul-Aug;15(4):527-32.
22. Hermann JS, Buser D, Schenk RK, Higginbottom FL, Cochran DL. Biologic width around titanium implants. A physiologically formed and stable dimension over time. *Clin Oral Implants Res*. 2000 Feb;11(1):1-11.
23. Hermann JS, Buser D, Schenk RK, Schoolfield JD, Cochran DL. Biologic width around one and two-piece titanium implants. *Clin Oral Implants Res*. 2001 Dec;12(6):559-71.
24. Salama H, Salama M, Garber D, Adar P. Developing optimal peri-implant papillae within the esthetic zone: guided soft tissue augmentation. *J Esthet Dent*. 1995;7(3):125-9.

25. Salama H, Salama M. The role of orthodontic extrusive remodeling in the enhancement of soft and hard tissue profiles prior to implant placement: a systematic approach to the management of extraction site defects. *Int J Periodontics Restorative Dent*. 1993 Dec;13(4):312-33.
26. Kois J. Predictable single tooth peri-implant esthetics: five diagnostic keys. *Compend Contin Educ Dent*. 2001 Mar;22(3):199-206.
27. Kois J. Altering gingival levels: the restorative connection part 1: biologic variables. *J Esthet Dent*. 1994 Jan;6(1):3-9.
28. Schwartz-Arad D, Chaushu G. Placement of implants into fresh extraction sites: 4 to 7 years retrospective evaluation of 95 immediate implants. *J Periodontol*. 1997 Nov;68(11):1110-6.
29. Szmukler-Moncler S, Piattelli A, Favero GA, Dubruille JH. Considerations preliminary to the application of early and immediate loading protocols in dental implantology. *Clin Oral Implants Res*. 2000 Feb;11(1):12-25.
30. Cameron CE. The cracked tooth syndrome: additional findings. *J Am Dent Assoc*. 1976 Nov;93(5):971-5.
31. Søballe K. Hydroxyapatite ceramic coating for bone implant fixation. Mechanical and histological studies in dogs. *Acta Orthop Scand Suppl*. 1993;255:1-58.
32. Vaillancourt H, Pilliar RM, McCammond D. Finite element analysis of crestal bone loss around porous-coated dental implants. *J Appl Biomater*. 1995 Winter;6(4):267-82.
33. Brunski JB. Biomechanical factors affecting the bone-dental implant surface. *Clin Mater*. 1992;10(3):153-201.
34. Taborelli M, Jobin M, Francois P, Vandaux P, Tonetti M, Szmukler-Moncler S, Simpson JP, Descouts P. Influence of surface treatments developed for oral implants on the physical and biological properties of titanium. (I) Surface characterization. *Clin Oral Implants Res*. 1997 Jun;8(3):208-16.
35. Touati B, Guez G, Saadoun A. Aesthetic soft tissue integration and optimized emergence profile: provisionalization and customized impression coping. *Pract Periodontics Aesthet Dent*. 1999 Apr;11(3):305-14.
36. Olson M, Linghe J. Periodontal characteristics in individuals with varying form of the upper central incisors. *J Clin Periodontol*. 1991 Jan;18(1):78-82.
37. Wöhrle PS. Single-tooth replacement in the aesthetic zone with immediate provisionalization: fourteen consecutive case reports. *Pract Periodontics Aesthet Dent*. 1998 Nov-Dec;10(9):1107-14.
38. Wilderman MN. Exposure of bone in periodontal surgery. *Dent Clin North Am*. 1964;3:23-36.
39. Landsberg CJ, Bichacho N. Implant placement without flaps. a single-stage surgical protocol—part 1. *Pract Periodontics Aesthet Dent*. 1998 Oct;10(8):1033-9.
40. al-Ansari BH, Morris RR. Placement of dental implants without flap surgery: a clinical report. *Int J Oral Maxillofac Implants*. 1998 Nov-Dec;13(6):861-5. **jCD**

Using the natural tooth as a provisional will allow tissue support and create an emergence profile similar to the pre-extraction condition.



Dr. Margeas is an adjunct professor, Department of Operative Dentistry, University of Iowa College of Dentistry & Dental Clinics, Iowa City. He maintains a private practice focusing on comprehensive restorative and implant dentistry in Des Moines, Iowa.

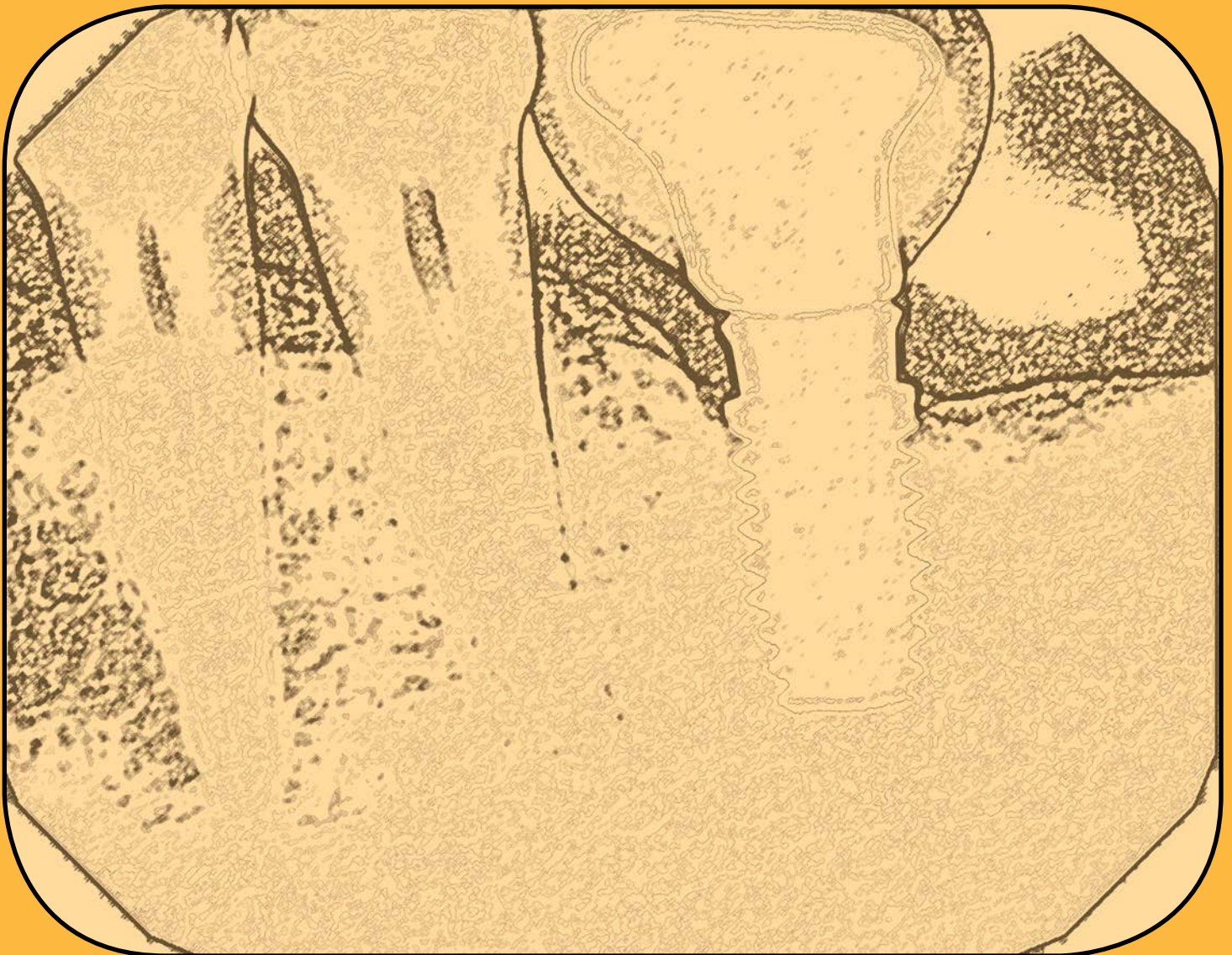Disclosure: The author did not report any disclosures.



# Eliminating an Implant Level Impression

---

Case Report of a Digitally Designed Implant Abutment



The potential for clinical or laboratory error increases with the number of procedural and material components for each particular implant restorative case.

Nelson Y. Howard, DDS, AAACD

### Abstract

Implant dentistry has become a significant part of our daily practice. Today's clinician has to be well versed in this area of dentistry and have increased knowledge to provide patients with the best possible treatment modality and successful result. This article presents one implant system's method of delivering a patient-specific restoration that has the appropriate margin height and natural emergence contours for the patient while eliminating the need for an implant level impression. Because the gingival tissues were healed at the time of the healing abutment impression, the final abutment margin design has the ideal placement and contour relative to the alveolar and gingival tissues.

**Key Words:** healing abutment, digital design, patient-specific, traditional impression technique, esthetic outcome

## Introduction

Implant restorative dentistry has evolved over the years to become a simplified yet technique-sensitive process utilizing several different clinical steps along with, at times, multiple implant impression and restorative components. The potential for clinical or laboratory error increases with the number of procedural and material components for each particular implant restorative case.

Implant success has many different factors: selection of the proper implant system to use for the particular intraoral condition; accurate placement of the implant; management of the surrounding alveolar bone and gingival tissues; precise impression-taking procedures to create less disruption to these tissues; final restorative abutment design, material and type; and the final restoration design and selection.

Dental implants require healthy soft tissue mucosa for long-term osseous integration and successful maintenance of all components involved. A well-attached mucosal sulcus around the implant abutment is essential for limiting or reducing both oral cavity debris and bacterial infiltration into the surrounding tissue sulcus to the abutment-implant interface area.<sup>1</sup>

The BellaTek Encode Impression System (Biomet 3i; Palm Beach Gardens, FL) is designed to eliminate the need for implant level impressions, thereby helping to streamline the treatment process.<sup>2,3</sup> With this system, it is not necessary to remove the healing abutment prior to the final placement of both the final abutment and restoration. Scanning codes embedded on the occlusal surface of the Encode healing abutment relay specific abutment design and computerized milling information. These codes also communicate the collar height, implant hex-orientation, platform diameter, and interface of the implant. With less disruption of and to the peri-abutment mucosal sulcus interface, this delicate tissue around the implant is preserved with less trauma and the ability to achieve a well-sealed final abutment-to-implant interface is better maintained. The regular removal and replacement of the healing abutment during the entire implant restoration process has been shown to contribute to the loss of crestal alveolar bone and negatively affect the peri-abutment mucosal sulcus tissues.<sup>4</sup> The progression of crestal alveolar bone loss around the implant can lead to compromised restorative esthetics from exposed abutment and crown margins associated with gingival recession surrounding the implant.<sup>5,6</sup> The overall longevity of both implants and implant restorations has been attributed to well-fitting implant restorative components.<sup>7-11</sup>

## Case Report

### Patient History and Complaints

A 62-year-old male in good health presented with a six-and-a-half-year-old implant crown on #19, which demonstrated poor esthetics, fractured porcelain at the distolingual cusp (Figs 1 & 2), and clinically and radiographically open marginal adaptation to the implant abutment (Fig 3). A 4.1 mm x 8.5 mm implant (NIIOS, Biomet 3i) had been placed in 2008. Mesial bone loss measuring approximately 0.5 mm was noted around the implant from the defective marginal adaptation of the crown to the implant abutment, due to the circumferential accumulation of food and bacterial debris at the open margin-to-abutment interface (Fig 4). A periodontal examination around the implant showed 2- to 4-mm probing depths, with the gingival margin tissues around the implant inflamed from the effects of the impacted debris on the implant abutment margin. The patient had noted problems with the crown since its placement, including difficulty in flossing, food impaction between the implant crown and the natural tooth #20, and an unpleasant odor emanating from the area. The patient had returned to his previous dentist several times since the crown was placed (but prior to the crown porcelain fracturing) but the dentist had told him there was nothing wrong with the crown. The patient was frustrated by his ongoing difficulty in keeping the area around the crown clean, as well as the ongoing odor he experienced. In addition, the porcelain had fractured over time at the distolingual aspect of the crown.

### Treatment Plan

After a thorough clinical, periodontal, and radiographic examination, as well as a lengthy discussion with the patient of the examination findings, the following treatment plan was presented regarding tooth/implant #19:

- remove the defective porcelain-to-metal crown
- evaluate the existing implant abutment design for a new, porcelain-fused-to-high-noble-metal implant crown (PFGIC)
- or, replace the existing abutment with a new, custom-designed and milled implant abutment to support a new PFGIC.

The patient accepted treatment and scheduled for the crown to be removed.

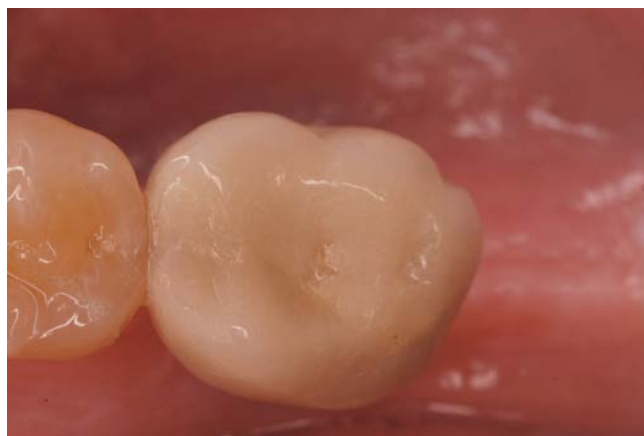
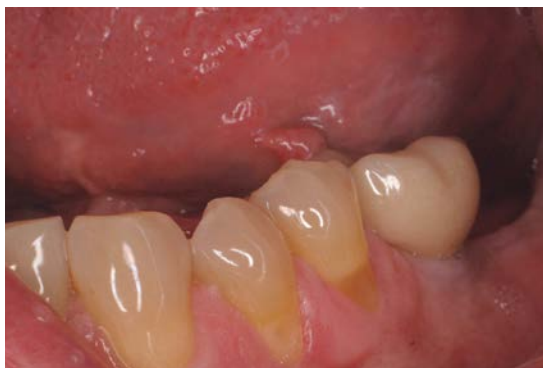
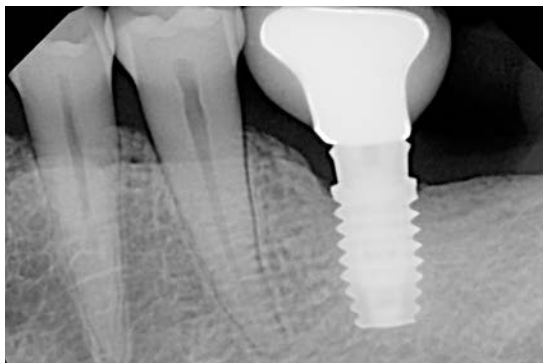Figure 1: Pretreatment, close-up occlusal view of #19.

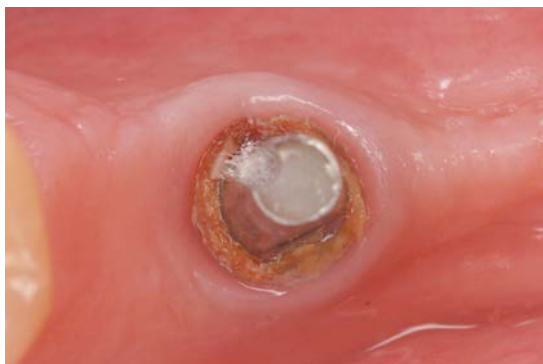



**Figure 2:** Pretreatment, retracted view of #19.



**Figure 3:** Pretreatment, periapical radiograph showing open mesial and distal margins of #19.



**Figure 4:** Occlusal view after PFM #19 was removed, showing a 360-degree ring of bacterial and food debris around the abutment margin.



**Figure 5:** Image after the abutment and debris were removed.

## Clinical Findings and Treatment Protocol

### Chairside Procedures

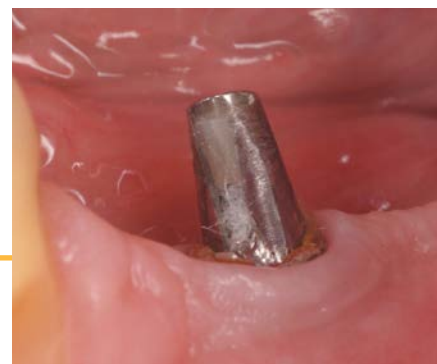Blood pressure readings were taken prior to the administration of 1.8 ml 2% lidocaine with 1:100,000 epinephrine. After removal of the implant crown, extensive impaction of hardened bacterial and food debris was seen around the base of the abutment (**Fig 5**). Bacterial plaque ingrowth was also noted inside the abutment-to-implant interface after the abutment was removed. This bacterial plaque ingrowth was the result of an inaccurate microscopic abutment-to-implant connection that occurred at the time the abutment was placed. This particular implant uses the Certain Implant and Abutment System and QuickSeat Connection (both Biomet 3i). This connection produces an audible and tactile “click” that confirms placement of both abutments and impression copings. The extension-like projections or “fingers” at the bottom of the abutment provide added retention that engages the internal aspect of the implant, resulting in a “click” before the final seat screw is torqued into position (**Fig 6**).

Examination of the existing implant abutment (**Fig 7**) showed a short, conical, cylindrical-shaped design lacking proper anti-rotational support for a crown restoration. When evaluated against the patient’s opposing dentition, the abutment height clearance measured in excess of 4 mm. With 0.5 mm of metal coping and 2 mm of layered porcelain for strength considered the ideal standard, and based upon all the clinical findings, a mutual decision was reached to design a new, ideally designed implant abutment followed by the placement of a new PFGIC.

// The patient was frustrated by his ongoing difficulty in keeping the area around the crown clean... //



**Figure 6:** Implant abutment inner “fingers” at the implant connection zone.

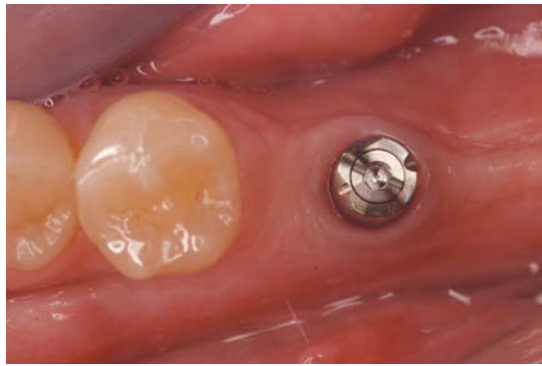

**Figure 7:** Lateral view of existing abutment showing the short, conical, cylindrical-shaped design lacking proper anti-rotational support for a crown restoration.

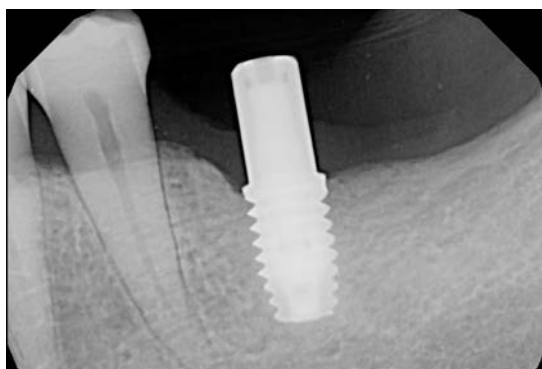
### Cast Mounting

The implant abutment was removed using a hand-held .48 hex driver tip, as it was not tightly held in place. The new abutment was placed manually (Fig 8) and a periapical radiograph was taken to confirm the correct seating placement into the implant (Fig 9). A full-arch vinyl polysiloxane impression was taken to accurately capture the position of the healing abutment (Figs 10 & 11). The Stratos Articulator Facebow Transfer System (Ivoclar Vivadent; Amherst, NY) was used per the manufacturer's specific laboratory recommendations so the casts could be mounted with Adesso split mounting plates (Baumann Dental GmbH; Baden-Wurttemberg, Germany), also per the manufacturer's recommendations. It is important prior to the cast mounting that the vertical occlusal pin rest on the incisal guide table and be set at zero so that the optical abutment scanner can read the codes on the healing abutment when the casts are mounted centered on the Adesso plates.<sup>1,2</sup>

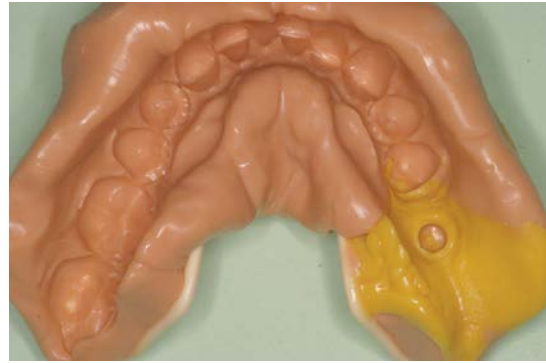
The impression was sent to a dental laboratory, poured up in low expansion die stone,<sup>12</sup> and mounted (Figs 12 & 13) per the manufacturer's specific checklist and instructions for laboratories.



**Figure 8:** Occlusal view of the abutment in the implant.



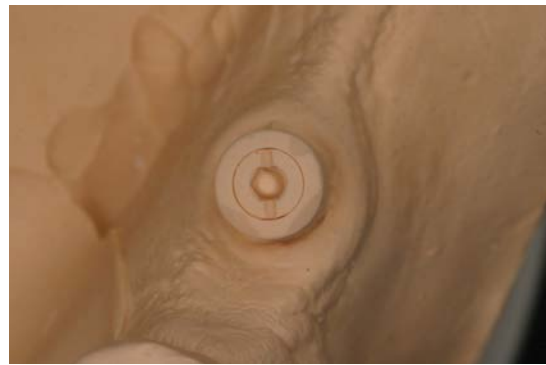**Figure 9:** Periapical radiograph of the abutment in the implant to verify accurate placement prior to the final impression.



**Figure 10:** Final full-arch impression showing the abutment.



**Figure 11:** Close-up of the abutment in the final impression.



**Figure 12:** Close-up of a stone model of the abutment.



**Figure 13:** Lateral view of a stone model of the abutment.

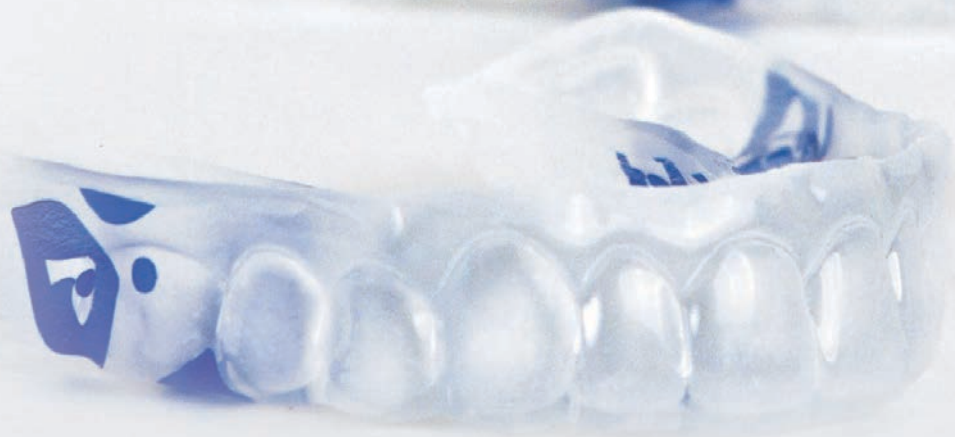THE PERIO TRAY® BY PERIO PROTECT:

LOCALIZED ARCH DELIVERY INTO PERIODONTAL POCKETS

MAKES ALL THE DIFFERENCE IN PATIENT RESULTS

“Perio Protect is our therapeutic 'silver bullet' to control the biofilm and the subsequent inflammation in all of our restorative and cosmetic rehabilitations.”

GREG L. GIST, DDS, SOUTHLAKE, TX



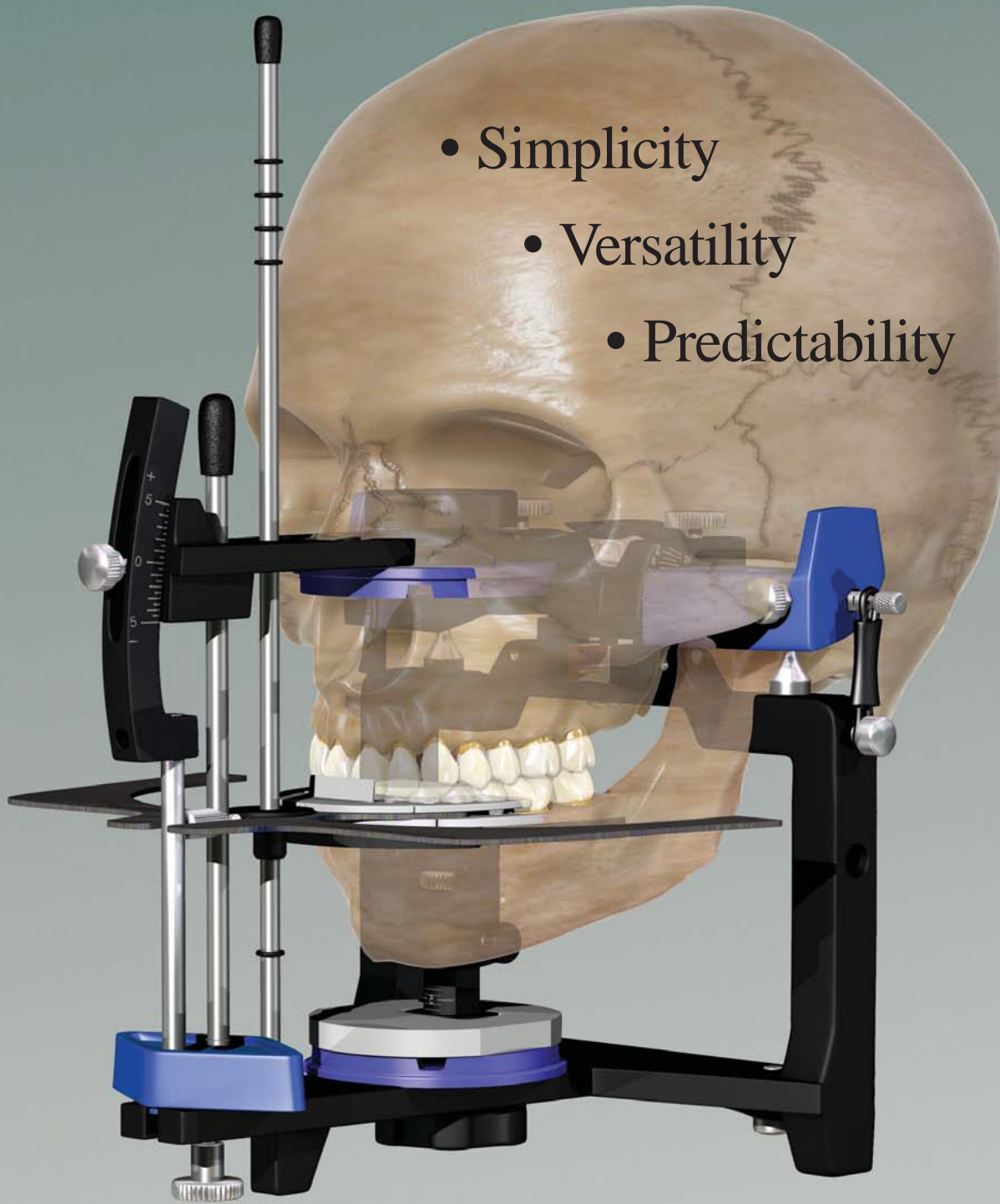
REGISTER NOW: [PerioProtect.com/training](http://PerioProtect.com/training)

PerioProtect   
877-434-GUMS (4867)



**KOIS DENTO-FACIAL ANALYZER**

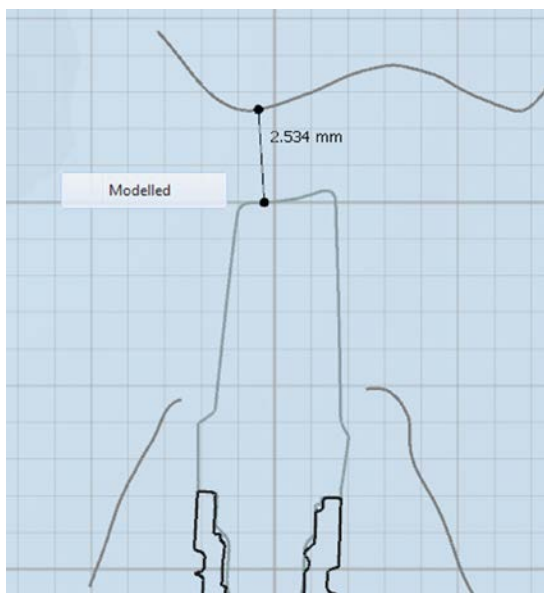
*Combining Esthetics & Function*



- Simplicity
- Versatility
- Predictability

### CAD/CAM Abutment Design

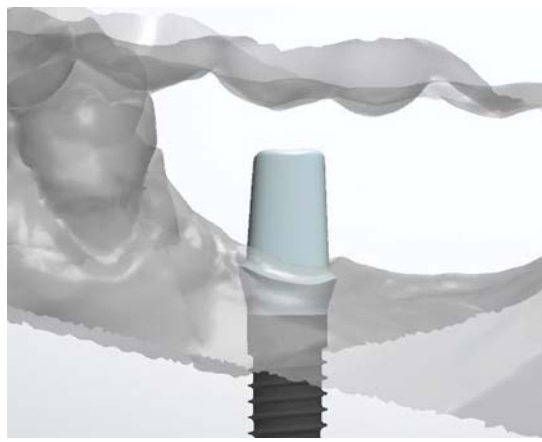
Using the manufacturer's online work order form, all aspects of the patient-specific, custom-milled abutment were designed by the author, with a design review request to be viewed prior to the final completion by the manufacturer's milling laboratory. The work order form was sent to this laboratory with the mounted models for design fabrication of the implant abutment (Figs 14-18).




**Figure 14:** Abutment digital design, buccal-lingual view.



**Figure 15:** Abutment digital design, buccal-lingual view.



**Figure 16:** Abutment digital design, buccal view.



**Figure 17:** Implant analog digital design, occlusal view.



**Figure 18:** Abutment digital design, occlusal view.

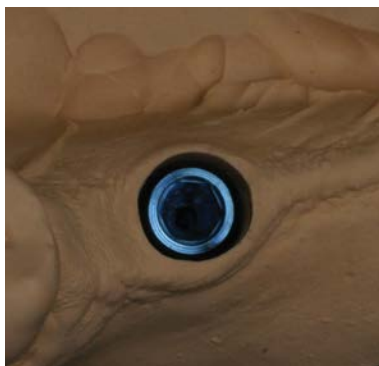### "Robotic" Replacement

When clinicians or laboratories use Encode's healing abutments, they can request that Biomet 3i's milling laboratory incorporate the placement of a lab implant analog into the stone model sent for scanning. The Robocast computer program, based upon the codes found on the occlusal aspect of the healing abutment used, precisely places the analog into the stone model to the exact depth, alignment, angulation, emergence profile, and position of the patient's implant where the healing abutment was located on the stone model (Fig 19). The Robocast "robot" also has the ability to relieve the precise amount of gingival clearance around the abutment margins, based upon the requirements the clinician determines on the work order form. Although not a necessary requirement for fabrication of the final digitally designed implant abutment, the placement of the analog in the stone model is a distinctive feature of this system that does not require taking an implant level impression.

Upon review and acceptance of the abutment design parameters, the final custom-designed and milled titanium abutment was completed and returned for patient try in (Figs 20 & 21).

### Traditional Impression

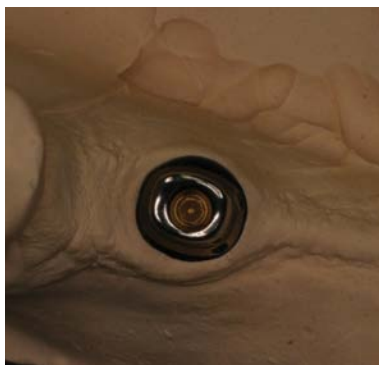At the time of the final impression, a comparison traditional impression technique was performed using a standard closed tray implant impression coping placed in the implant (Fig 22). After removal from the implant, a matching implant analog was connected to the implant impression coping and placed accurately in the impression, according to the side groove pattern of the implant impression post (Fig 23). The impression was poured up with a soft tissue material around the implant analog to replicate the gingival architecture present. This model aids the laboratory technician by enabling comparison of the PFGIC emergence contours off the abutment margins as they appear in the mouth versus on the stone Robocast implant analog model from the milling laboratory.



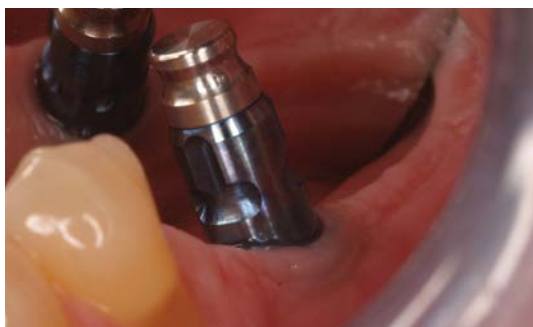**Figure 19:** Occlusal close-up view of the robotically-placed implant analog in the original stone model.



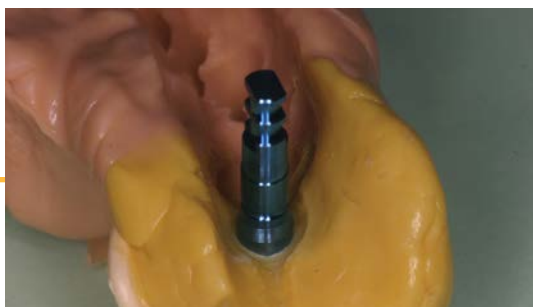**Figure 20:** Lateral view of the final patient-specific abutment.



**Figure 21:** Occlusal view of the final patient-specific abutment.



**Figure 22:** View of the closed tray implant impression coping in the implant.

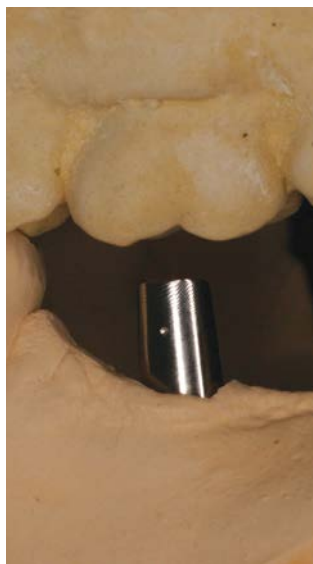

**Figure 23:** Laboratory analog attached to the closed tray impression coping in the final impression.



### Final Abutment Verification

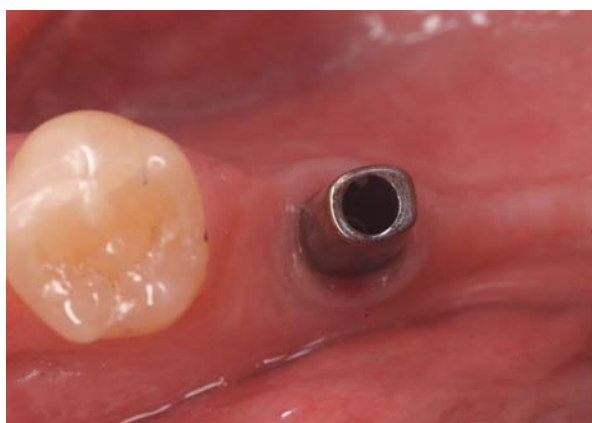The patient returned for a try in of the implant abutment (Figs 24 & 25) per the author's specifications on the work order form. For ideal occlusal clearance between the top of the abutment and the opposing dentition, 2.5 mm of clearance is needed to compensate for 0.5 mm of PGFIC coping metal and 2.0 mm of layered porcelain. The new abutment was placed in the implant until a "click" was heard (Fig 26). A periapical radiograph was taken to verify the placement of the custom-milled abutment (Fig 27). A bite registration of the new implant abutment was taken. Upon its intraoral removal, the new abutment was placed on the soft tissue laboratory comparison model and the position of the abutment was confirmed using the bite registration (Fig 28). The patient's existing abutment and temporary were placed back on the implant, and the patient was scheduled for his final abutment and PFGIC placement. The model work and new bite registration were sent to the laboratory along with final shade selection for the PFGIC.



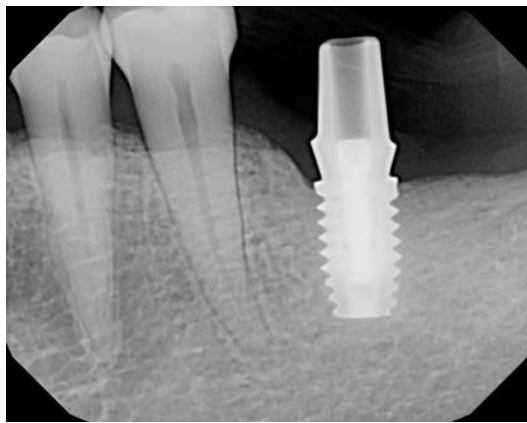
**Figure 24:** Lateral view of the digitally designed milled abutment on robotic model.



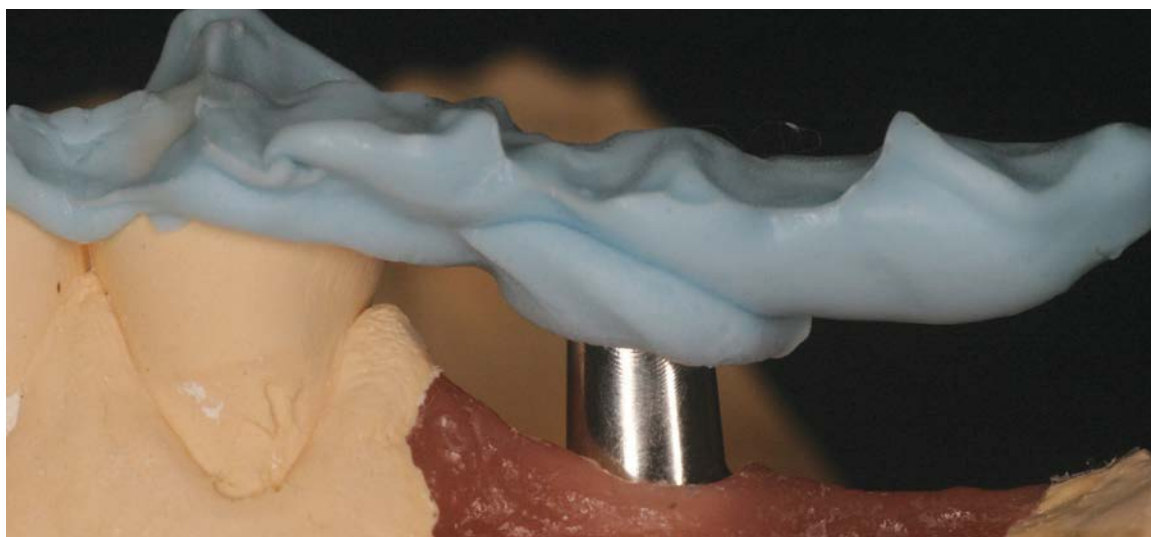**Figure 25:** Lateral view of the new abutment showing an ideal 2.5-mm occlusal clearance for the porcelain-fused-to-high-noble-metal (PFGIC) implant crown.



**Figure 26:** Occlusal view of the abutment at patient try in.



**Figure 27:** Periapical radiograph of the abutment at patient try in.



**Figure 28:** Bite registration on the traditional impression soft tissue model.

### Final Placement Appointment

At the final abutment and PFGIC placement appointment, the patient's temporary crown and existing implant abutment were removed. The internal aspect of the implant was cleaned with Concepis (Ultradent Products; South Jordan, UT) in a microbrush applicator. The internal aspect was air-dried and microbrush-tip-dried before placing the digitally designed final implant abutment. The new abutment was placed in the implant until a "click" was heard, and the accompanying Certain Gold-Tite hexed abutment screw was torqued to 20 Ncm, as recommended by the manufacturer. The top of the hexed screw was covered with a small cotton pellet and sealed with a light-cured temporary filling material (Fermit, Ivoclar-Vivadent). The PFGIC restoration (Figs 29-32) was seated into position after all clinical margins to the abutment were verified, along with the interproximal contact and occlusion to the opposing dentition. A periapical radiograph was taken to further verify the overall PFGIC-abutment-implant integrity (Fig 33). Upon confirmation of clinical and radiographic acceptance, the PFGIC was cemented to the new abutment with Temp Bond Clear (Kerr; Orange, CA) after Concepis was applied. The abutment was then rinsed and air-dried.

Use of temporary cement initially with a cemented-to-the-abutment versus screw-retained crown allows the patient to evaluate the crown for form, function, and shading (if applicable) until the patient is completely satisfied. It also allows the clinician to retorque down the abutment screw, if necessary, after the patient has had sufficient time to use the crown, without damaging the crown's integrity. This is particularly important if the abutment were to become loose after the crown was cemented permanently, thus preventing an easier removal of the crown to reconnect the abutment to the implant. After a sufficient period of evaluation time, the final PFGIC can then be cemented permanently to the Encode abutment.

// The new abutment was placed manually and a periapical radiograph was taken to confirm the correct seating placement into the implant. //

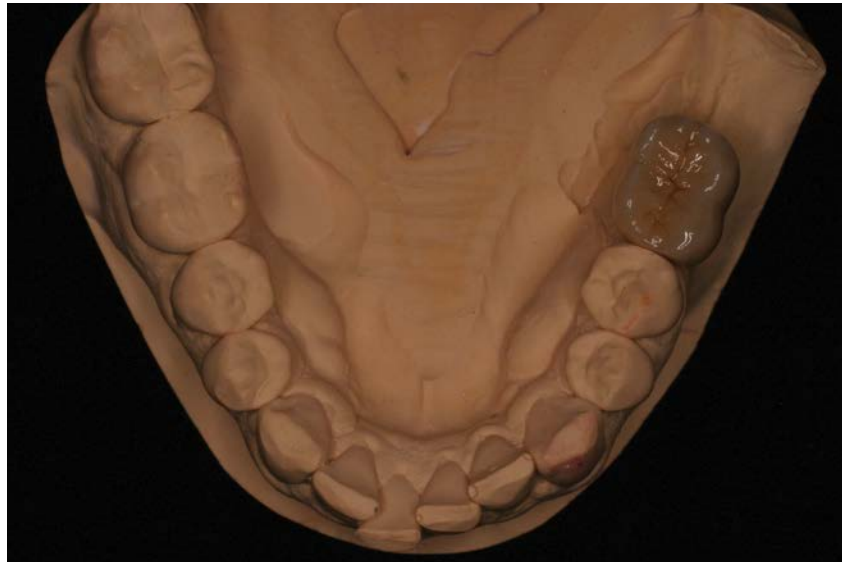

Figure 29: Occlusal view of PFGIC on the Robocast model.

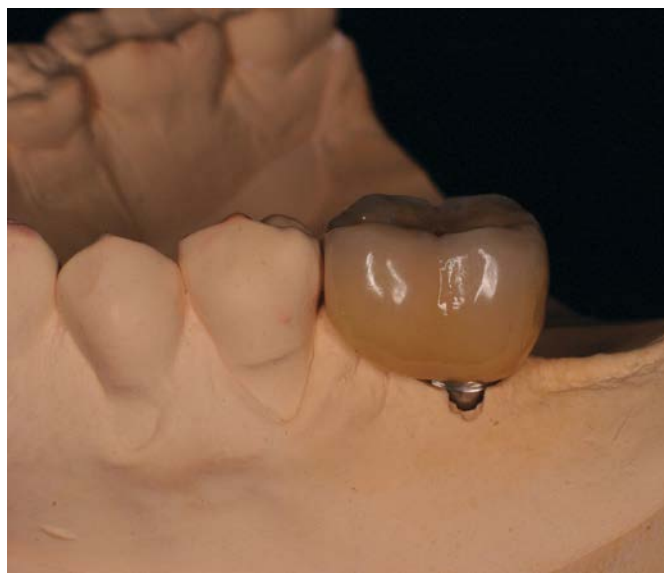
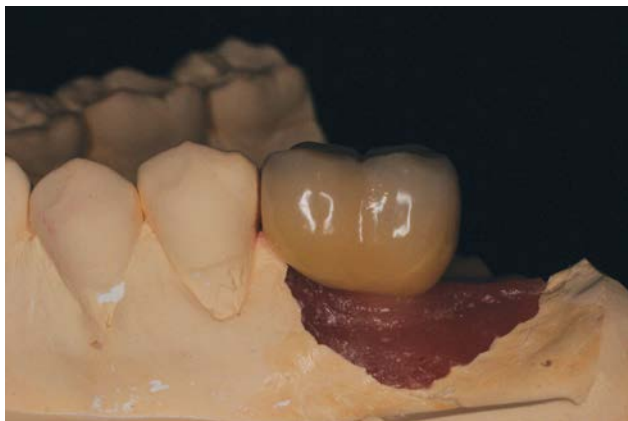
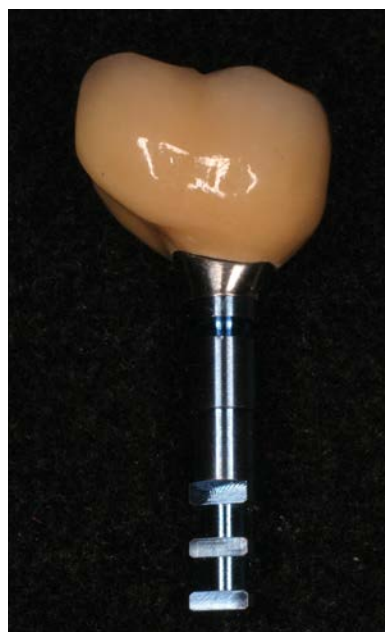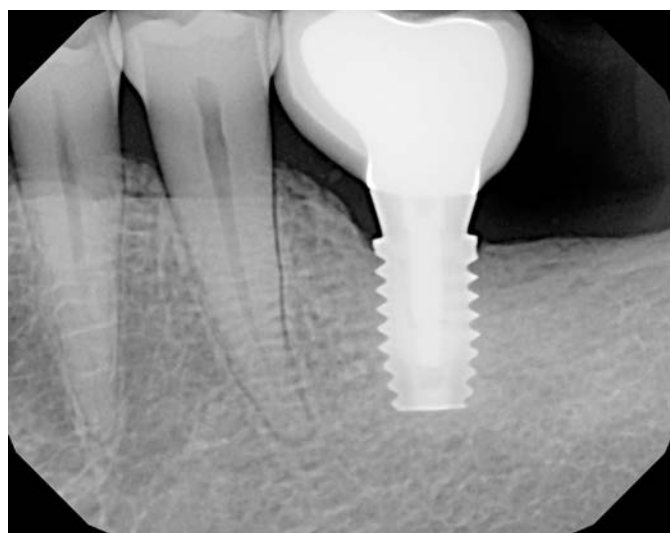Figure 30: Lateral view of the PFGIC on the Robocast model.



**Figure 31:** Lateral view of the PFGIC on the soft tissue model.



**Figure 32:** Close-up lingual view of the PFGIC abutment on the analog to verify marginal adaptation accuracy.



**Figure 33:** Periapical radiograph of the PFGIC abutment-implant connection.

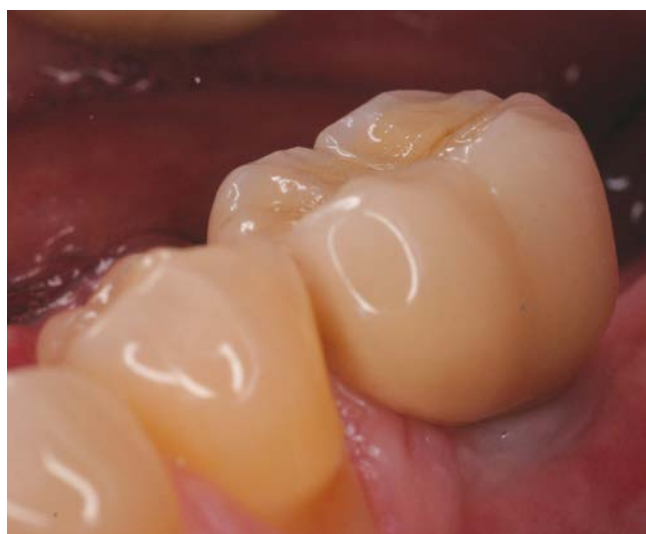The final implant PFGIC restoration demonstrated excellent esthetics, form, and contours (Fig 34). The patient was very pleased with the esthetic and functional outcome after having endured years of odor and difficulty in flossing around the previous abutment and crown.

## Summary

This article described a simplified way to achieve a patient-specific, custom-milled implant abutment without having to use impression copings or implant level impressions. Encode is specific for Biomet 3i's internal and external hex implant systems and not applicable for every implant system currently available. In the case presented, the restorative outcome was easier and more efficient for the surgeon, laboratory technician, and restorative clinician, and more comfortable for the patient.

## Acknowledgment

*The author thanks Marc Hodges and Gretchen Wilson of Biomet 3i for their informational assistance and product support. He also thanks Julie Nichols, CDT, owner of Pearl Dental Studio (Escondido, CA), for her excellent laboratory work in the fabrication of all the clinical models and final PFGIC restoration for the patient.*



**Figure 34:** Lateral view of the final PFGIC restoration cemented in place.



## References

1. Drago C, O'Connor G, Peterson T. Robot analog placement and CAD/CAM abutments. *J Dent Technol*. 2009 Aug-Sept;23-8.
2. Vafiadis DC. Computer-generated abutments using a coded healing abutment: a two year preliminary report. *Pract Proced Aesthet Dent*. 2007 Aug;19(7):443-8.
3. Schupbach P, Glauser R. The defense architecture of the human periimplant mucosa: a histological study. *J Prosthet Dent*. 2007 Jun;97(6 Suppl):S15-25.
4. Abrahamsson I, Berglundh T, Lindhe J. The mucosal barrier following abutment dis/reconnection. An experimental study in dogs. *J Clin Periodontol*. 1997 Aug;24(8):568-72.
5. Hartman GH. Initial implant position determines the magnitude of crestal bone remodeling. *J Periodontol*. 2004 Apr;75(4):572-7.
6. Hartlev J, Kohberg P, Ahlmann S, Gotfredsen E, Andersen NT, Isidor F, Schou S. Immediate placement and provisionalization of single-tooth implants involving a definitive individual abutment: a clinical and radiographic retrospective study. *Clin Oral Implants Res*. 2013 Jun;24(6):652-8. DOI: 10.1111/j.1600-0501.2012.02442.
7. Binon PP. Evaluation of machining accuracy and consistency of selected implants, standard abutments, and laboratory analogs. *Int J Prosthodont*. 1995 Mar-Apr;8(2):162-78.
8. Binon PP. The effect of implant abutment hexagonal misfit on screw joint stability. *Int J Prosthodont*. 1996 Mar-Apr;9(2):149-60.
9. Jemt T, Book K. Prosthesis misfit and marginal bone loss in edentulous implant patients. *Int J Oral Maxillofac Implants*. 1996 Sep-Oct;11(5):620-5.
10. May KB, Edge MJ, Russell MM, Razzoog ME, Lang BR. The precision of fit at the implant prosthodontic interface. *J Prosthet Dent*. 1997 May;77(5):497-502.
11. Byrne D, Houston F, Cleary R, Claffey N. The fit of cast and premachined implant abutments. *J Prosthet Dent*. 1998 Aug;80(2):184-92.
12. De Bruyn H, Vandeweghe S. Increasing implant dentistry in undergraduate education using new technology: A pilot project. *J Implant Reconstr Dent*. 2010;2(1):40-5.

## Sources

BellaTek Encode Impression System: laboratory recommendations. West Palm Beach Gardens (FL): Biomet 3i; 2012.

BellaTek Encode Impression System: optimization by design. West Palm Beach Gardens (FL): Biomet 3i; 2013. **jCD**

**//** In the case presented, the restorative outcome was easier and more efficient for the surgeon, laboratory technician, and restorative clinician, and more comfortable for the patient. **//**



Dr. Howard owns and operates private practices in San Marcos and Rancho Bernardo, California.

Disclosure: The author received material support from Biomet 3i for the impression and abutment parts mentioned in this article.

# Exceptional Patient Care Starts in the Waiting Room



LIMITED-TIME OFFER ON DEAR DOCTOR TV

## Try For 30 Days — Risk Free!

Sign up at [www.DearDoctorTV.com](http://www.DearDoctorTV.com) or call 866-821-5458



A close-up photograph of a person's hand, specifically the index finger, which has a dental implant. The implant is a small, rectangular, metallic-looking object attached to the side of the finger. The skin around the implant appears slightly reddened and textured. The background is a dark, textured surface, possibly a piece of fabric or paper.

**There is controversy in the literature as to whether augmentation of soft tissue around dental implants should be performed to obtain an added band of keratinized tissue.** \_\_\_\_\_



# The Importance of Keratinized Tissue Around Implants

## Enhancing Soft Tissue Parameters Around a Single Tooth Implant

Anastasia Kelekis-Cholakis, DMD, DIP. Perio, FRCD(C)  
Reem N. Atout, BDS, DDS, MS, FRCD(C)

### Abstract

Controversy exists over the need to augment or add keratinized tissue around implant fixtures. This case report illustrates the use of a connective tissue graft to augment the zone of keratinized gingiva and the resultant stability of the soft tissue margin and decrease in discomfort for the patient when brushing over the implant area.

**Key Words:** dental implant, connective tissue graft, keratinized tissue, oral hygiene, mucogingival

## Introduction

There is controversy in the literature as to whether augmentation of soft tissue around dental implants should be performed to obtain an added band of keratinized tissue. In the natural dentition, the periodontium has a wide defense mechanism that contributes to its health; this includes the gingival and oral sulcular epithelium, the epithelial attachment, and the connective tissue attachment. A complex array of gingival connective tissue fibers forms well-defined bundle groups: interdental fibers, dentogingival fibers, circular fibers, and alveolar crest fibers. Some of these fibers insert into the root cementum between the alveolar crest and the cemento-enamel junction; they therefore are part of the protective mechanism of the periodontium around teeth.<sup>1,2</sup>

Implants, on the other hand, have fewer anatomical barriers when compared to teeth. An implant has by definition a transmucosal element (an abutment, neck of the implant, or restoration) that protrudes through the overlying mucosa, which heals and adapts around it without an inserting fiber/cementum attachment.<sup>2</sup> Although there are some reports of circular fibers existing around the implant transmucosal element, it is understood that the barrier function of the peri-implant tissue is more delicate than that of natural teeth.<sup>3</sup>

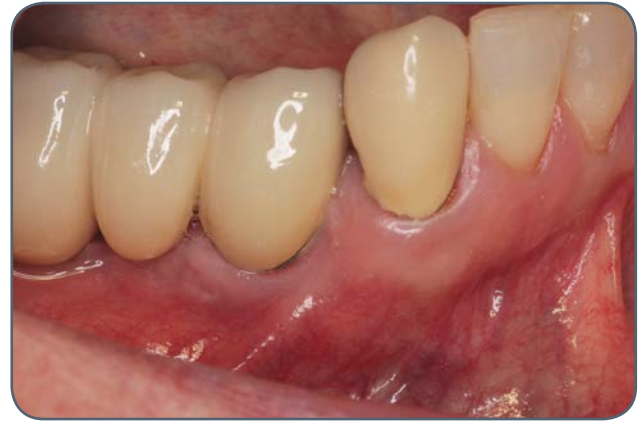The importance of having sufficient keratinized tissue around dental implants is emphasized considering the poor suitability of the mucosa to provide an adequate seal between the oral environment and the implant body. In patients with poor plaque control, this may become more of an issue, as inflammation may distend the mucosa more readily and render the area more uncomfortable to oral hygiene efforts.

## Patient History

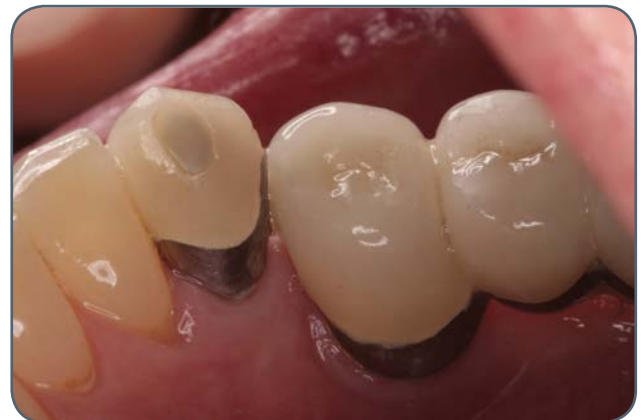A healthy 63-year-old female presented with a chief complaint of sensitivity and bleeding upon brushing around her anterior implant abutment in the mandibular first bicuspid area, part of a three-unit implant-supported bridge. The implants had been placed three years earlier.

Clinical examination revealed inflamed and tender peri-implant tissues with bleeding upon probing but with clinical probing depths not exceeding 3 mm circumferentially. A sinus tract was present on the distobuccal aspect of the implant at the level of the mucogingival margin. Lingual tissues were equally inflamed.

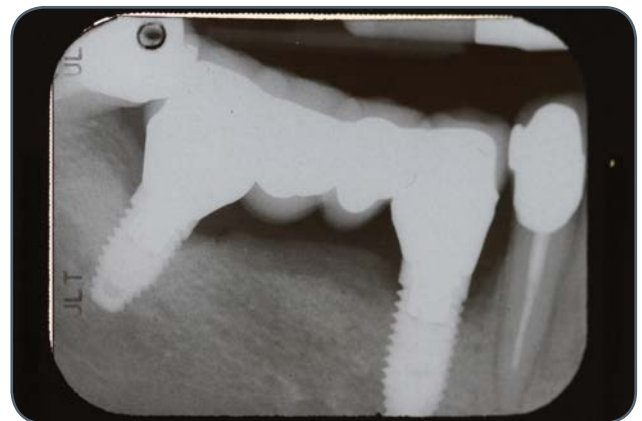A 1.5-mm band of keratinized tissue was noted on the buccal aspect of the implant in conjunction with a high frenal attachment (Fig 1). Bleeding upon probing was elicited on the lingual aspect of the implant (Fig 2). Occlusal contacts were within normal limits with canine guidance on excursions. Radiographic examination revealed normal peri-implant bone remodeling (Fig 3).



**Figure 1:** Buccal aspect of the mandibular first bicuspid implant with high inserting frenal attachment and localized inflammation. A sinus tract was present on the distobuccal aspect at the level of the mucogingival junction.



**Figure 2:** Lingual aspect of peri-implant tissues.



**Figure 3:** Radiographic examination revealed normal peri-implant bone remodeling.

## Diagnosis and Treatment

### Initial Therapy

After a diagnosis of peri-implant mucositis was made, the area was debrided, followed by placement of a local antibiotic (Atridox [doxycycline hyclate] 10%, Tolmar; Fort Collins, CO) in the site. The patient was then instructed in a peri-implant oral hygiene protocol.

Gingival tissues were reevaluated three months later; clinical examination revealed persistence of bleeding upon probing and sensitivity upon brushing, with an increase in clinical probing depths to 4 mm as well as persistence of the sinus tract. The patient's plaque control had improved with no visible plaque deposits in the area.

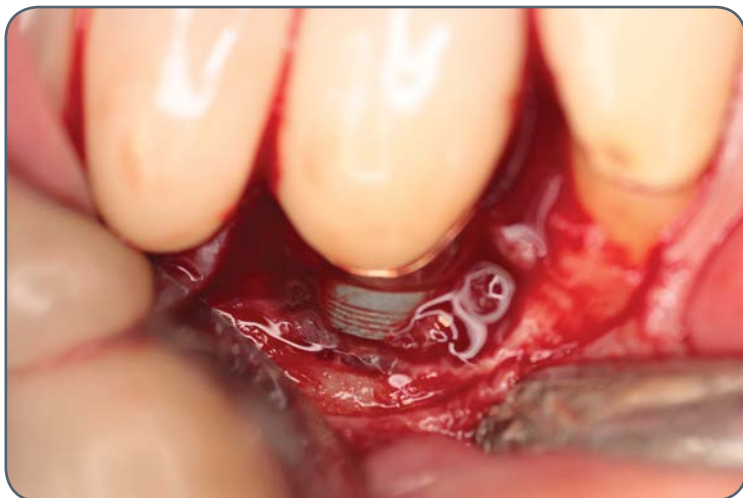### Surgical Therapy

The area was next treated surgically with administration of three carpules of lidocaine (1:100,000 epinephrine) and the elevation of a full thickness mucoperiosteal flap on the buccal and lingual aspects. The procedure was performed with the use of a dental microscope (Fig 4).

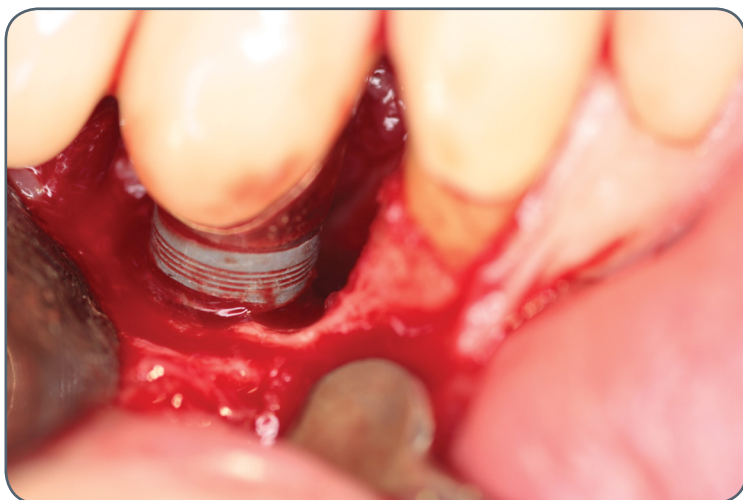
The defect and implant surface were mechanically debrided with polytetrafluoroethylene-coated curettes and an air abrasive, and subsequently irrigated with saline and a 2% doxycycline solution.

After the area and the implant surface were debrided, an assessment of the bony architecture revealed no bone loss past the rough collar of the flat-topped abutment/implant interface (Fig 5).

Consequently, no regenerative treatment was deemed necessary and a subepithelial connective tissue graft was harvested from the maxillary right anterior hard palate at the level of the maxillary first bicuspid and cuspid.<sup>4</sup> A horizontal incision was made approximately 5 to 6 mm from the gingival margins of the maxillary to the full depth to bone. A second parallel horizontal incision was made 1 mm coronal



**Figure 4:** Intrасulcular incisions, full thickness buccal flap elevation with granulation tissue still in place.



**Figure 5:** Debridement of the defect revealed physiologic bone remodeling up to the first thread of the implant.

**Although there are some reports of circular fibers existing around the implant transmucosal element, it is understood that the barrier function of the peri-implant tissue is more delicate than that of natural teeth.**



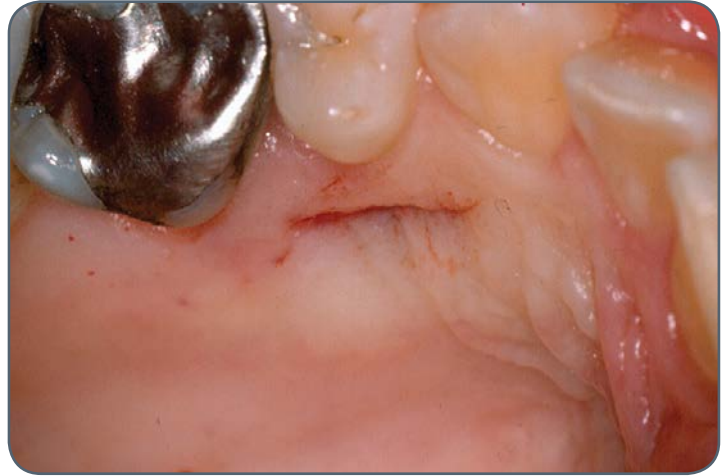to the first incision. It was continued apically until it met the base of the original incision. Vertical incisions were made on either side of the horizontal incisions from inside the pouch. The connective tissue and epithelium between the two horizontal incisions were excised and all adipose tissue was removed (Figs 6 & 7).

The graft was then de-epithelialized and sutured with one 6-0 circumferential and two interrupted polypropylene sutures. Every effort was made to coronally advance the flap so as to passively and completely cover the soft tissue graft (Fig 8).

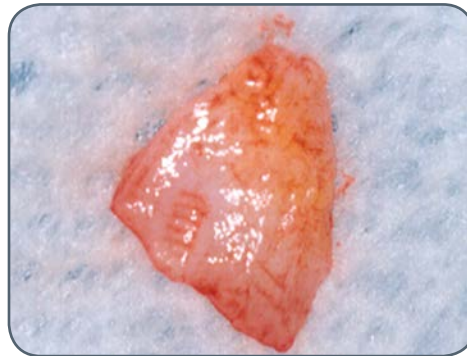
The patient was prescribed 500 mg amoxicillin three times daily for one week postoperatively and ibuprofen 600 mg every four to six hours as needed. A 2% chlorhexidine gluconate solution was given to the patient to use for the first two weeks.

The sutures were removed three weeks after surgery and the patient was provided with a soft toothbrush to reinstate oral hygiene measures.

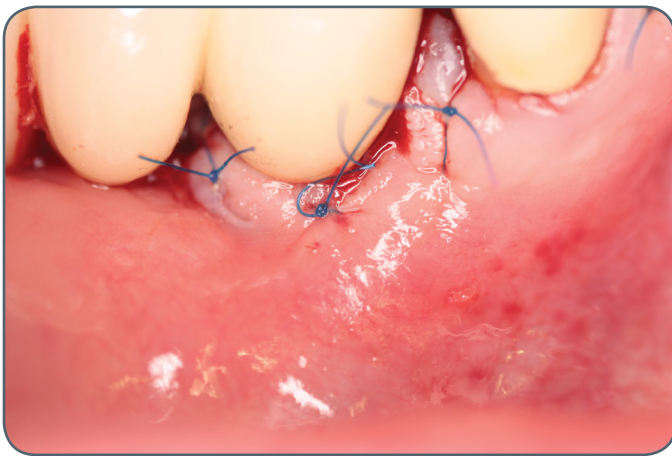
One month after surgery the site appeared healthy with no bleeding upon probing, no sensitivity when brushing, and elimination of the sinus tract. There was, however, a deficiency in keratinized tissue on the mesiobuccal aspect of the implant as well as an apparent increase in recession (Fig 9).



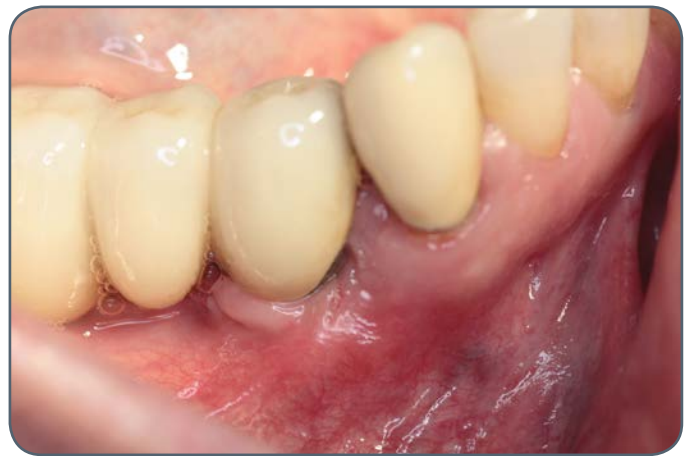**Figure 6:** Right hard palate, double incision donor site of connective tissue graft.



**Figure 7:** Subepithelial connective tissue graft harvested from the right hard palate.



**Figure 8:** Flap and graft sutured with polypropylene sutures. The flap was coronally advanced to fully cover the subepithelial connective tissue graft.



**Figure 9:** At four weeks postoperative the area exhibited adequate healing with elimination of the sinus tract, a decrease in bleeding, and elimination of sensitivity upon brushing. A 0.5-mm increase in recession in the mesiobuccal aspect was noted.

The patient was placed on regular periodontal maintenance appointments every six months and the area was monitored. At her four-year recall appointment, an increase in the volume of keratinized tissue was noted with stable and healthy peri-implant tissues. Clinical probing depths were under 3 mm circumferentially with no bleeding upon probing (Figs 10a & 10b).

## Discussion

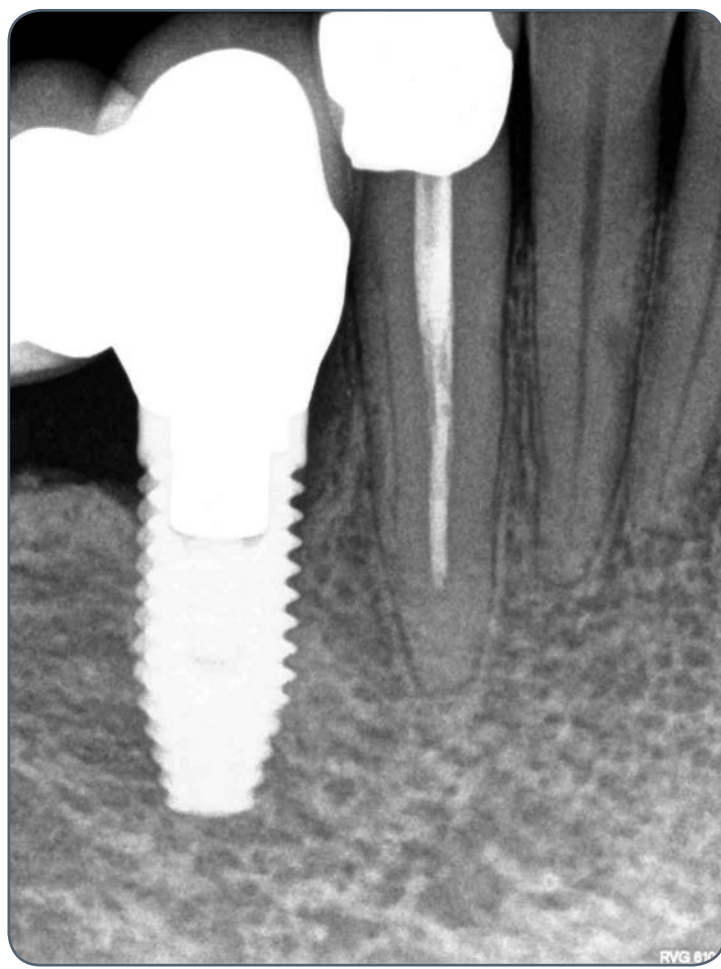
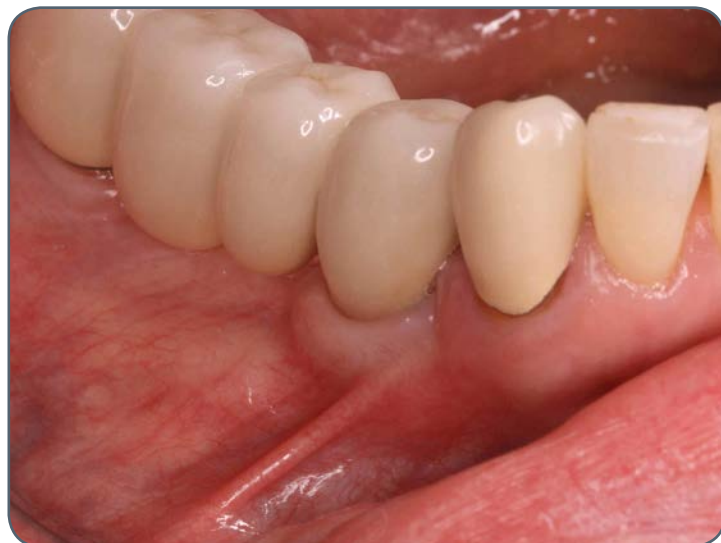A number of clinical studies suggest associations among an adequate width of keratinized tissue, higher survival rates of dental implants, health of the peri-implant mucosa and an improved esthetic outcome.<sup>1,5,6</sup> Based upon three systematic reviews, this association could not be validated and it was concluded that there is insufficient evidence regarding the influence of the width of keratinized tissue on the survival rate and future mucosal recessions.<sup>7-9</sup>

Schluger and colleagues stated that, "every free gingival graft becomes important in conjunction with fixed restorative dentistry."<sup>10</sup> Considering the importance of enough band of keratinized tissue around teeth going through a fixed restorative treatment, this might be considered as a valid prerequisite around osseointegrated dental implants. In the case presented, a de-epithelialized connective tissue was sutured on the buccal surface of the implant and the flap was coronally positioned to completely cover the graft. Thickness of the tissue increased at one year follow-up and continued to mature over the following four years, resulting in a very stable, healthy peri-implant tissue; no signs of inflammation; and no additional discomfort when brushing.

Despite the observation in many studies that the lack of keratinized tissue might not influence implant survival,<sup>11,12</sup> the careful management of the soft tissue and the preservation and/or reconstruction of keratinized mucosa around dental implants may be advocated to facilitate restorative procedures, and to improve esthetics and plaque control during oral hygiene.<sup>13,14</sup> Several expert opinions/case series proposed different techniques to augment peri-implant keratinized mucosa.<sup>11,12</sup>

Management of the soft tissue around dental implants can be done at different stages: before implant placement, simultaneous with implant placement, or at the second stage after implant placement.<sup>15,16</sup>

Different techniques are also presented in the literature on how to augment tissue around dental implants.<sup>17,18</sup> Expert opinions<sup>19,20</sup> suggest techniques to obtain adequate amounts of keratinized tissue around two-stage implants, mainly based upon the preserva-



**Figures 10a & 10b:** At four years postoperative the area exhibits an increase in volume of keratinized tissue and stable peri-implant attachment.

tion of keratinized tissue over the edentulous ridge. At the time of implant exposure, apically positioned flaps (using a mid-crestal or a lingually positioned incision) or laterally positioned flaps were proposed to reconstruct an adequate width of keratinized tissue around dental implants. When the amount of keratinized tissue over the edentulous ridge is minimal, use of a free gingival graft has also been suggested.<sup>19,20</sup>

## Summary

This case report addressed the use of connective soft tissue grafting on the buccal aspect of an implant with peri-implant mucositis; a sinus tract and inflammation had rendered the area difficult for the patient to maintain. Although the necessity of having keratinized tissue around implant fixtures is still debatable, the provision of such tissue by means of soft tissue grafting may be of value long term, in select cases, in terms of peri-implant stability and patient comfort during oral hygiene procedures.

## References

- Artzi Z, Tal H, Moses O, Kozlovsky A. Mucosal considerations for osseointegrated implants. *J Prosthet Dent.* 1993 Nov;70(5):427-32.
- Palmer R. Teeth and implants. *Br Dent J.* 1999 Aug;187:183-8.
- Weber HP, Cochran DL. The soft tissue response to osseointegrated dental implants. *J Prosthet Dent.* 1998 Jan;79(1):79-89.
- Raetzke PB. *J Periodontol.* Covering localized areas of root exposure employing the "envelope" technique. 1985 Jul;56(7):397-402.
- Adell R, Lekholm U, Rockler B, Branemark PI, Lindhe J, Eriksson B, Sbordone L. Marginal tissue reactions at osseointegrated titanium fixtures (I). A 3-year longitudinal prospective study. *Int J Oral Maxillofac Surg.* 1986 Feb;15(1):39-52.
- James RA. Peri-implant considerations. *Dent Clin North Am.* 1980 Jul;24(3):415-20.
- Cairo F, Pagliaro U, Nieri M. Soft tissue management at implant sites. *J Clin Periodontol.* 2008 Sep;35(8 Suppl):163-7.
- Espósito M, Grusovin MG, Maghaireh H, Coulthard P, Worthington HV. Interventions for replacing missing teeth: management of soft tissues for dental implants. *Cochrane Database Syst Rev.* 2007 Jul;18(3):CD006697.
- Wennström JL, Derks J. Is there a need for keratinized mucosa around implants to maintain health and tissue stability? *Clin Oral Implants Res.* 2012 Oct;23 Suppl 6:23:136-46.
- Schluger S, Yuodelis R, Page RC, Johnson RH. *Periodontal diseases.* 2nd ed. Philadelphia: Lea & Febiger; 1990. p. 560-78.
- Wennström JL, Bengazi F, Lekholm U. The influence of the masticatory mucosa on the peri-implant soft tissue condition. *Clinical Oral Implants Res.* 1994 Mar;5(1):1-8.
- Bengazi F, Wennström JL, Lekholm U. Recession of the soft tissue margin at oral implants. A 2-year longitudinal prospective study. *Clin Oral Implants Res.* 1996 Dec;7(4):303-10.
- Block MS, Kent JN. Factors associated with soft- and hard-tissue compromise of endosseous implants. *J Oral Maxillofac Surg.* 1990 Nov;48(11):1153-60.
- Buser D, Weber HP, Lang NP. Tissue integration of non-submerged implants. 1-year results of a prospective study with 100 ITI hollow-cylinder and hollow screw implants. *Clin Oral Implants Res.* 1990 Dec;1(1):33-40.
- Grunder U, Spielman HP, Gaberthüel T. Implant-supported single tooth replacement in the aesthetic region: a complex challenge. *Pract Periodontics Aesthet Dent.* 1996 Nov-Dec;8(9):835-42.
- Nemcovsky CE, Artzi Z, Moses O. Rotated split palatal flap for soft tissue primary coverage over extraction sites with immediate implant placement. Description of the surgical procedure and clinical results. *J Periodontol.* 1999 Aug;70(8):926-34.
- Bianchi AE, Sanfilippo F. Single tooth replacement by immediate implant and connective tissue graft: a 1-9-year clinical evaluation. *Clin Oral Implants Res.* 2004 Jun;15(3):269-77.
- Grunder U. Stability of the mucosal topography around single-tooth implants and adjacent teeth: 1-year results. *Int J Periodontics Restorative Dent.* 2000 Feb;20(1):11-17.
- Langer B, Sullivan DY. Osseointegration: its impact on the interrelationship of periodontics and restorative dentistry: part I. *Int J Periodontics Restorative Dent.* 1989;9(2):84-105.
- Langer B, Langer L. Overlapped flap: a surgical modification for implant fixture installation. *Int J Periodontics Rest Dent.* 1990;10(3):208-15. **JCD**



Dr. Kelekis-Cholakis is head, Division of Periodontics, and graduate director, Periodontology, University of Manitoba College of Dentistry (UMCD) in Winnipeg, Manitoba, Canada.



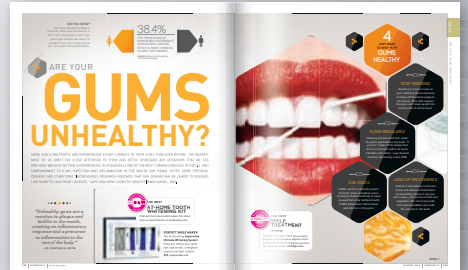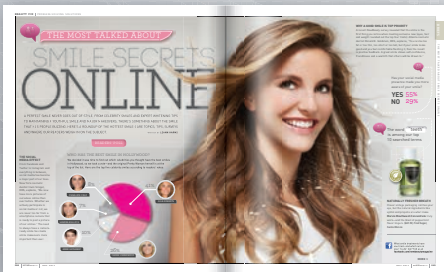Dr. Atout is an assistant professor, Division of Periodontics, Department of Dental Diagnostic and Surgical Sciences, UMCD.

Disclosures: The authors did not receive any financial support for this article.



# HAVE YOUR PRACTICE FEATURED IN **NEWBEAUTY MAGAZINE** WHERE **EDUCATED CONSUMERS** TURN FOR EXPERT ADVICE

GUM LIFT | IN-OFFICE WHITENING | BRACES | INVISALIGN | BONDING | VENEERS  
DENTAL IMPLANTS | CROWNS | GUM RECONTOURING | TOOTH CONTOURING

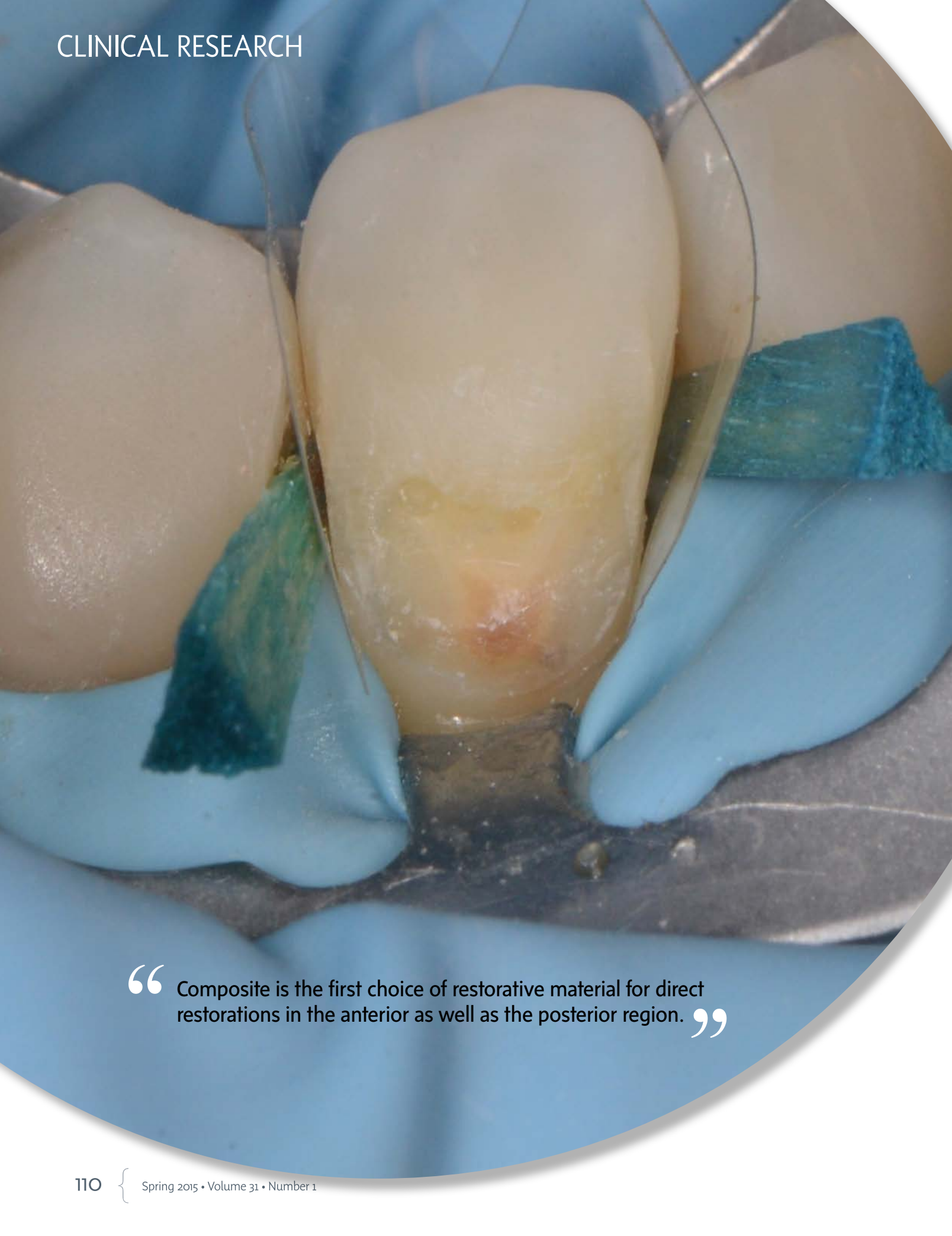


THE ONLY NATIONAL BEAUTY MAGAZINE WITH  
COSMETIC DENTISTRY EDITORIAL IN EVERY ISSUE!

NEWBEAUTY & AACD | A BEAUTIFUL PARTNERSHIP

To have your practice featured, call **866-NEWBEAUTY** or visit **newbeauty.com**





“ Composite is the first choice of restorative material for direct restorations in the anterior as well as the posterior region. ”

# Clinical Performance of Direct and Indirect Adhesive Restorations

## Longitudinal Medium- to Long-Term Results

Marleen Peumans, PhD, DDS

### Abstract

Continual improvements in adhesive restorative materials and techniques have expanded the indication field of direct and indirect adhesive restorations, resulting in a greater overlap between both restoration types. The goal of this article is to analyze the current status regarding clinical performance of common types of direct and indirect adhesive restorations. The literature was searched for longitudinal medium- and long-term clinical trials. Obviously, more and longer-term clinical trials were available for the indirect partial ceramic restorations, showing lower annual failure rates compared to their similarly sized direct composite restorations. Nevertheless, a highly clinically acceptable result can be obtained with complex direct composite restorations. In addition, these restorations can function quite well in the medium and even long term. Patient and operator are the most important factors determining the longevity of adhesive restorations, followed by the materials and maintenance of the restorations.

**Key Words:** clinical trials, direct composite restoration, adhesive, direct composite veneer, indirect partial ceramic restoration



### Learning Objectives

After reading this article, the participant should be able to:

1. Compare the factors affecting the longevity of direct composite restorations as compared to indirect partial ceramic restorations.
2. Based on the results of longitudinal medium- to long-term clinical trials, gain insight into what factors determine the success and failure of these restorations in clinical circumstances.
3. Compare the clinical performance of direct adhesive restorations serving different purposes such as Class II and IV restorations, non-cariou cervical lesion restorations, and restorations to treat generalized tooth wear.



- “ The adhesives were classified into four different categories:
- three-step etch-and-rinse adhesives (3E&Ra)
  - two-step etch-and-rinse adhesives (2E&Ra)
  - two-step self-etch adhesives (2SEa)
  - one-step self-etch adhesives (1SEa). ”

## Introduction

Composite is the first choice of restorative material for direct restorations in the anterior as well as the posterior region. This is widely accepted for small restorations (Class I, II, III, IV, V, veneers) where enough of the natural tooth structure is left to durably bond the restoration. Due to continual improvements of adhesive systems and composite materials, the indications for direct composite restorations have been stretched toward more complex restorations (correction of tooth form and/or position, cusp or crown buildup, treatment of generalized tooth wear, and even replacement of missing teeth). This causes an overlap between direct and indirect adhesive restorations. The latter (facings, onlays, partial crowns) are preferred if the patient wishes to have a more durable and optimal esthetic result. In this context, a number of questions need to be considered. First, it is not yet clear what can be expected regarding the clinical performance of different types of direct and indirect adhesive restorations after several years of clinical functioning. Second, it would obviously benefit clinical practice to have an insight into what factors determine the success and failure of these restorations in clinical circumstances. The objective of this article is to formulate an answer to these questions based upon the results of longitudinal medium- to long-term clinical trials.

## Clinical Trials Evaluating Adhesive Restorations

The clinical performance and durability of the following types of adhesive restorations is discussed.

- restoration of non-carious cervical lesions (NCCLs)
- Class IV direct composite restoration
- direct composite veneer versus indirect ceramic veneer
- Class II direct composite restoration
- large direct composite restorations in the posterior region versus indirect partial ceramic crowns
- treatment of generalized tooth wear with direct composite restorations.

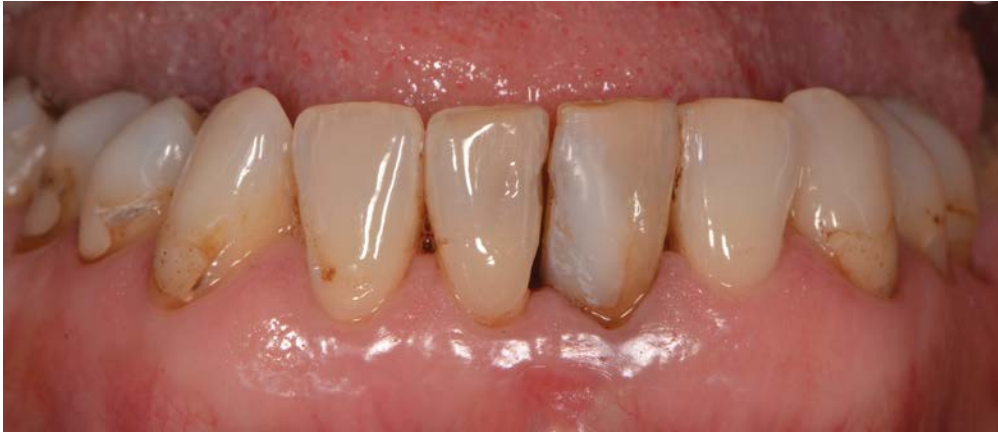The literature was searched for longitudinal medium-term (3 to 5 years) and long-term (> 5 years) retrospective and prospective clinical trials evaluating the longevity of these restorations. Their durability is expressed as the percentage of restorations that failed with time (Annual Failure Rate [AFR]). There was large variability in study design among the selected clinical trials, which required careful interpretation of the results. For NCCL restorations and Class II direct composite restorations, longevity data were based on recently published systematic reviews. Factors determining the durability of the restorations are discussed.

### Restoration of Non-Cariou Cervical Lesions

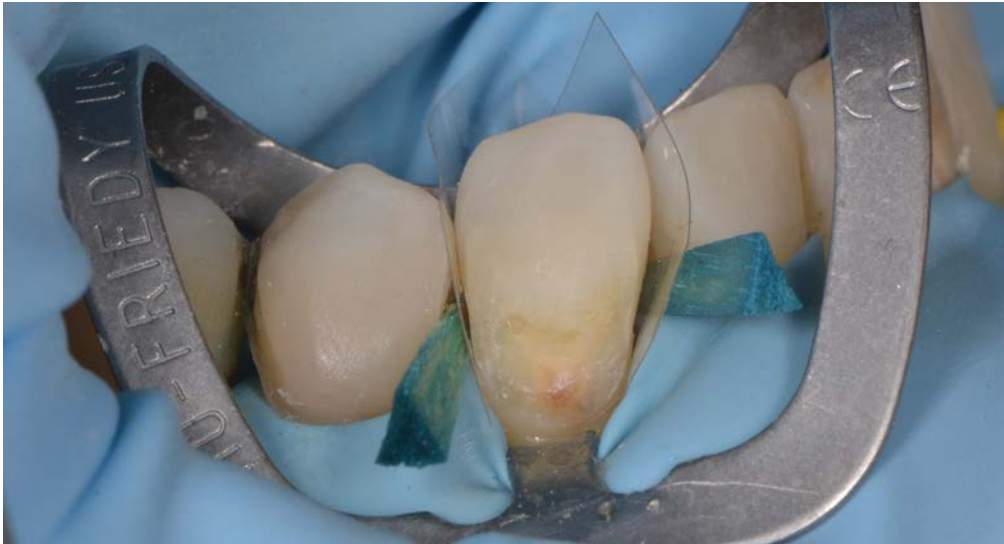NCCLs are frequently seen in today's general practice. Restorative treatment of NCCLs is indicated if 1) the structural integrity of the tooth is threatened; 2) the exposed dentin is hypersensitive; 3) the defect is esthetically unacceptable for the patient and 4) pulpal exposure is likely to occur.<sup>1</sup> The least invasive, most esthetic way to restore these lesions is with a direct composite restoration (Figs 1-3). A large number of Class V clinical trials are discussed in the literature, as NCCLs are the best lesions with which to test clinical effectiveness of adhesives. The major portion of tooth surface to bond to consists of dentin, while at the incisal side the restoration margin ends in enamel. These lesions do not provide any or only minimal macro retention, by which the bonding effectiveness of the adhesive can be tested efficiently. A recently published extensive systematic literature review evaluated the clinical effectiveness of contemporary adhesives in NCCL clinical trials.<sup>2</sup> The adhesives were classified into four different categories:<sup>3</sup>

- three-step etch-and-rinse adhesives (3E&Ra)
- two-step etch-and-rinse adhesives (2E&Ra)
- two-step self-etch adhesives (2SEa)
- one-step self-etch adhesives (1SEa).

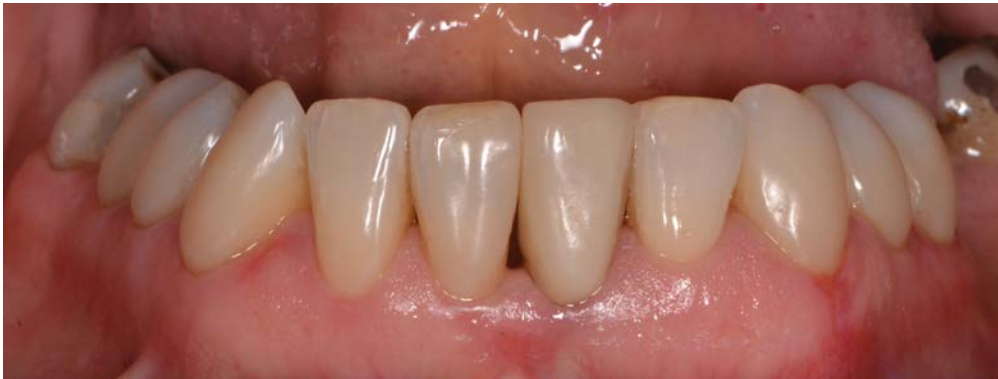Both 2SEa and 1SEa were further subdivided into “mild and intermediately strong” (1/2SEa-m), with a pH  $\geq$  1.5 (+ functional monomers with chemical bonding potential); and “strong” (1/2SEa-s), with a pH < 1.5 (no chemical bonding potential).<sup>4</sup> Data analysis showed that failure of the restoration occurs rarely because of clinically unacceptable marginal defects, severe marginal discoloration, or caries. The only parameter on the basis of which differences were observed in bonding efficiency between the different adhesive categories and adhesives was loss of retention in function of time.



**Figure 1:** Before treatment: old Class V composite restorations with unacceptable marginal discoloration, marginal adaptation, and loss of anatomical form. Replacement is required.



**Figure 2:** Tooth preparation on the right lower canine after rubber dam isolation. The dentin surface was roughened with a carbide bur, and an enamel bevel (1 to 2 mm) was prepared to increase retention of the composite restoration.



**Figure 3:** Final result after placement and finishing of the cervical composite restorations. A direct composite veneer was placed on the left central incisor. A microhybrid composite was used.

In each adhesive category, AFR ( $\pm$  standard deviation) by loss of retention was calculated. For the adhesive category, the best results were obtained by milder types of SEAs (2SEa-m:  $2.5 \pm 1.5$ ; 1SEa-m:  $3.6 \pm 4.3$ ). The chemical bonding potential of these adhesives seems to be important for the quality and durability of the bond in NCCLs. 3E&Ras ( $3.1 \pm 2$ ) also showed favorable bonding efficiency. Inadequate bonding effectiveness was noticed for 2E&Ras ( $5.8 \pm 4.9$ ) and SEa-s (1SEa-s:  $5.8 \pm 4.8$ ; 2SEa-s:  $8.4 \pm 7.9$ ). In addition to the adhesive strategy, the dentist should select a product with a good proven clinical performance, as there is wide variation among adhesives of the same approach. The best-performing adhesives were the 3E&Ra Optibond FL (Kerr; Orange, CA), the 2SEa-m Clearfil SE Bond (Kuraray Noritake; Tokyo, Japan), and the 1SEa-m G-Bond (GC; Tokyo, Japan). The first two adhesives, considered the golden standard of adhesive systems, also showed the best bonding performance in a systematic review of bond strength tests.<sup>5</sup>

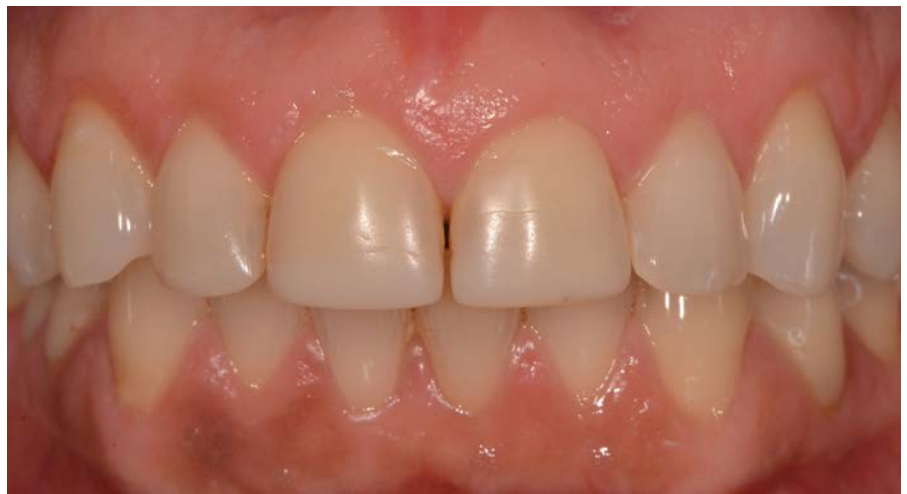Using a SEa-m, selective etching of enamel with phosphoric acid prior to application of the adhesive resulted in a lower frequency of small marginal defects and superficial marginal discoloration at the incisal enamel side. Consequently, selective enamel etching is advisable when bonding to a larger enamel surface (Class IV, veneer) as these minor shortcomings in marginal integrity can negatively influence the esthetic performance of the composite restoration.

The type of composite (hybrid, microfilled, or flowable composite) did not have an influence on the bonding performance of adhesives in NCCLs. This can be explained by the fact that NCCLs have a relatively small C-factor, causing the mechanical properties of the composite to be less important to the outcome than the actual performance of the adhesive.

## Class IV Composite Restoration

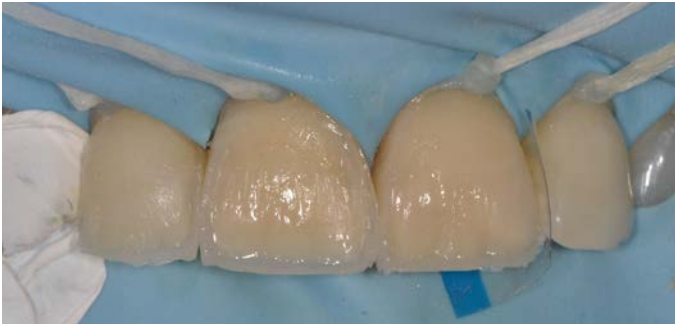
In contrast to a NCCL restoration, the bonding procedure for a Class IV restoration (buildup of incisal edge) is easier as a large part of the bonding surface consists of enamel. The most difficult step in the clinical procedure is to imitate the color and form of the natural tooth (Figs 4-7).

The longevity of Class IV restorations was evaluated in only a few medium- to long-term clinical trials with a study design that was not optimal.<sup>6-9</sup> These studies showed a large variation in AFR (0.8 to 8.6%) (Table 1). A high AFR (8.6%) was recorded in older clinical trials using chemical cure composites in combination with an enamel adhesive.<sup>7,8</sup> Fracture of the restoration was the main reason for failure in most studies. The risk of fracture was significantly higher when a microfilled composite was used (compared to a hybrid composite)<sup>7,8</sup> and in patients with bruxism.<sup>9</sup> This means that physico-mechanical properties of the composite material are important for the durability of a Class IV restoration. A small-particle hybrid composite is the material of choice for these restorations. A distinction can be made between microhybrid (contains anorganic filler with an average particle size of 0.4 to 1  $\mu$  and 40-nm silicon dioxide particles), nanofilled (average particle size below 100 nm), and nanohybrid composites (combination of microhybrid and nanofilled).<sup>10</sup> These composite materials can be used in the anterior region as well as in the posterior region. Although in vitro studies show that physico-mechanical properties of the nanohybrid and nanofilled composites are somewhat lower compared to that of microhybrid composites, these differences are not clinically relevant.<sup>10,11</sup> As to polishability, a recent systematic review concluded that there is no in vitro evidence that one of these three categories showed better surface smoothness even after surface challenges.<sup>12</sup> The choice of the composite material for anterior restorations will mainly be determined by shade availability, handling characteristics of the material and preference of the practitioner.

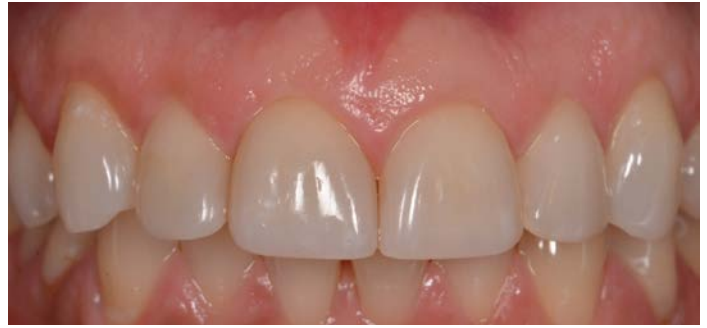

**Figure 4:** 10-year-old Class IV composite restorations on both upper central incisors and right lateral incisor. A slight change in color match, some loss of surface gloss, and wear of the composite can be noticed. A small diastema became visible between both central incisors. The patient was no longer satisfied with the result and asked for replacement of the restorations.

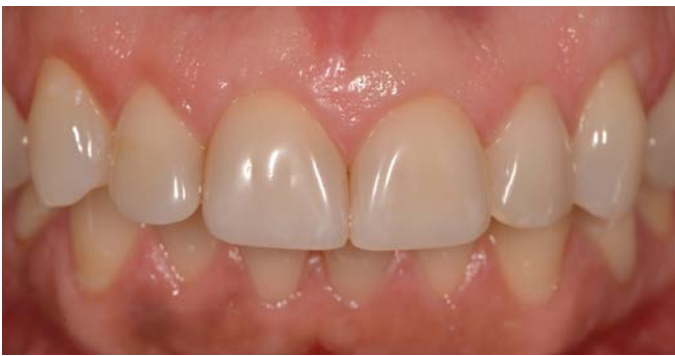



**Figure 5:** Composite buildup of the three incisors according to the natural layering technique using a nanohybrid composite (enamel composite, dentin composite, opalescent composite, white tint).



**Figure 6:** Result after final finishing and polishing. Color, form, and surface gloss of the restored teeth are harmonious with the natural dentition.



**Figure 7:** Restorations two years later. A slight loss of surface gloss can be noticed.

Table 1. Medium- to Long-Term Clinical Trials Evaluating Class IV Restorations

Author Study type	Patients/ Restorations	Materials	Duration	Failure (%) AFR (%)	Main reasons for failure
de Moura et al. <sup>6</sup> <i>Retrospective</i>	-/28	2E&Ra MHC	3 yrs	22% 7.3%	loss of restoration
Smales & Gerke <sup>7</sup> <i>Retrospective</i>	-/38	enamel adhesive CC: macrofilled/ MC/HC	5 yrs	43% 8.6%	-
Tyas <sup>8</sup> <i>Prospective</i>	-/102	enamel adhesive CC: microfilled, hybrid LC: microfilled, hybrid	3 yrs	26% 8.6%	fracture MC > HC
van Dijken & Pallesen <sup>9</sup> <i>Prospective</i>	-/43	2E&Ra HC (small particle)	8-14 yrs	35% 3.7%	fracture

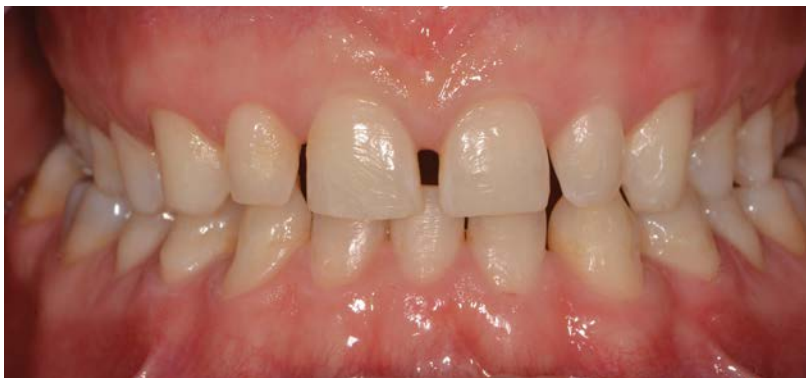- = Information not available; MHC=microhybrid composite; CC = chemical cure; LC = light cure; MC = microfilled composite; HC = hybrid composite; 2E&Ra = two-step etch-and-rinse adhesive

Two clinical trials showed main reasons for failure other than fracture. In the clinical trial of de Moura and colleagues, 22% of restorations failed after three years.<sup>6</sup> Most of the failed restorations were lost. The restorations were placed by undergraduate students, emphasizing the importance and experience of the operator. A very low AFR (0.5%) was noticed in a 20-year retrospective study of anterior composite restorations (168 Class III and 51 Class IV) placed by an experienced operator in a group of patients with high socio-economic status.<sup>13</sup> The main reasons for failure were shortcomings in esthetics and loss of anatomic form due to wear. This means that in the long term, inadequate color stability and wear resistance of the composite will limit the lifespan of anterior composite restorations in this patient population, which has good oral hygiene, low caries risk, and visits the dentist regularly.

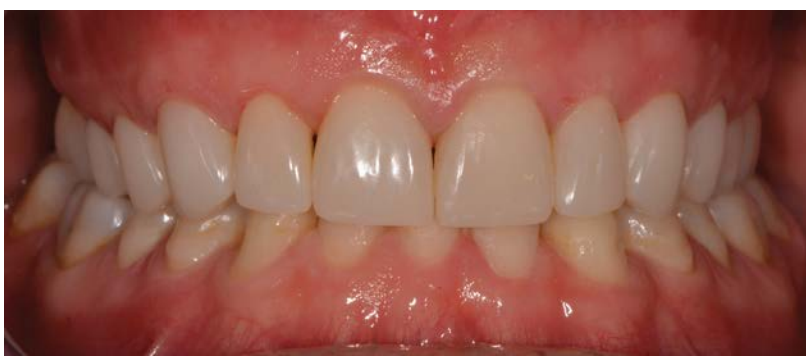### Direct Composite Veneer Versus Indirect Ceramic Veneer

Veneers are placed to improve esthetics (correction of tooth form, color and/or position) in the anterior region. If a direct composite restoration is made, a distinction should be made between a direct composite addition and a direct composite veneer. Direct composite additions are placed when closing diastemata, masking the palatoversion of a tooth, buildout of peg-shaped laterals, etc. These restorations require no tooth preparation or only roughening of the enamel surface. The composite material is bonded to a complete enamel surface, the most ideal tooth substrate to bond to (Figs 8-10). For a direct composite veneer, tooth reduction at the vestibular side is needed; for example, to mask tooth discoloration or a rotated tooth, to replace old composite veneers.

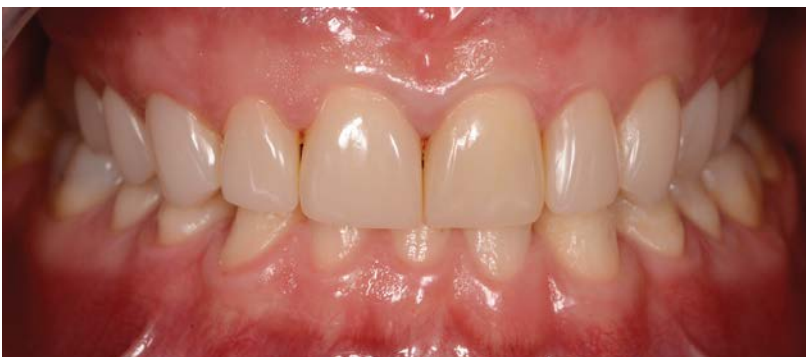Although both restoration types are frequently placed in daily practice, only five medium-term and one long-term clinical trial evaluated their clinical performance (Table 2). The AFR of the direct composite additions varied from 0.5 to 3%.<sup>14-16</sup> The main reasons for failure were fracture (due to chipping) and loss of anatomical form (due to wear). Most failed restorations were repairable. This means that by using state-of-the-art repair techniques, including surface-roughening, silica-coating or silanization, and intermediate adhesive resin application, the lifespan of the restorations can be increased.<sup>17-19</sup>



**Figure 8:** A young male patient with microdontia asked for esthetic improvement of his upper anterior teeth. Minimally invasive treatment with direct composite additions was proposed.



**Figure 9:** Result after correction of tooth form and position with direct composite additions on all upper teeth. A nanofilled composite was used. Tooth preparation consisted of roughening of the enamel surface with sandblasting (27- $\mu$  aluminum oxide).



**Figure 10:** Result two years later shows that after repolishing the restorations with a rubber polishing point, these extreme direct composite restorations are still highly clinically acceptable.

Table 2. Medium- to Long-Term Clinical Trials Evaluating Direct Composite Additions and Direct Composite Veneers

Author Study type	Patients/Restorations	Materials	Duration	Failure (%) AFR (%)	Main reasons for failure
Alonso & Caserio <sup>14</sup> <i>Retrospective</i>	21/21 <i>composite addition</i>	3E&Ra, 2E&Ra MC, MHC	12.5 yrs 4-18 yrs	5% 0.4%	fracture
Frese et al. <sup>15</sup> <i>Retrospective</i>	58/176 <i>composite addition</i>	3E&Ra MHC	5 yrs 3-9 yrs	16% 3.7%	fracture/chipping
Peumans et al. <sup>16</sup> <i>Prospective</i>	23/87 <i>composite addition</i>	3E&Ra MHC	5 yrs	11% 2.2%	fracture/chipping loss of anatomical form
Gresnigt et al. <sup>20</sup> <i>Prospective</i>	23/96 <i>composite veneer</i>	2SEa+ selective enamel etch/2E&Ra MHC	3-5 yrs	13% 3.7%	fracture debonding
Meijering et al. <sup>21</sup> <i>Prospective</i>	95/59 <i>composite veneer</i>	- MC	2.5 yrs	26% 10.4%	fracture/chipping
Welbury <sup>22</sup> <i>Prospective</i>	66/224 <i>composite veneer</i>	enamel bonding MC	3 yrs 10-36 months	14% 4.7%	partial or complete loss of the restoration

- = Information not available; M = microfilled composite; MHC = microhybrid composite; 3E&Ra = three-step etch-and-rinse adhesive; 2E&Ra = two-step etch-and-rinse adhesive; 2Sea = two-step self-etch adhesive

For the direct composite veneer AFR was obviously higher: 3.7 to 10.4%.<sup>20-22</sup> The main reasons for failure were total or partial debonding and fracture of the restoration. The debondings and incisal chip fractures can be explained by the use of a less-than-optimal adhesive system<sup>22</sup> and/or the use of a microfilled composite.<sup>21,22</sup> For the hybrid composite materials, an acceptable but not optimal surface smoothness was observed.<sup>14-16,20</sup> In all clinical trials surface roughness, slight marginal defects, and slight marginal discoloration were not refinished and/or repolished during recall sessions. The practitioner should be encouraged to follow this maintenance procedure as this will also lengthen the lifespan of the restorations.<sup>19</sup>

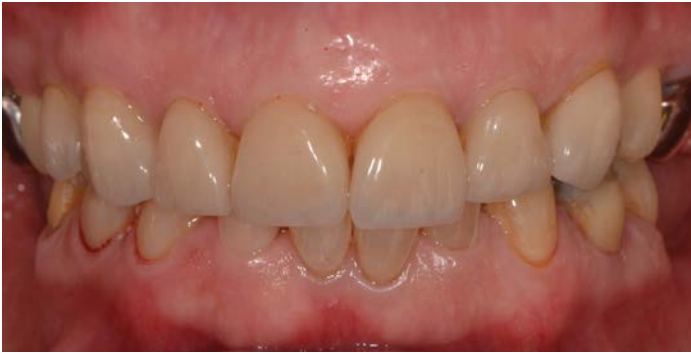In contrast to the direct composite veneer, bonded ceramic veneers are one of the most studied adhesive restoration types. Several long-term clinical trials, carried out by experienced operators following a meticulous clinical procedure, show that ceramic veneers are the most esthetic and durable adhesive restorations in the anterior region (Table 3; Figs 11 & 12). AFR in all these clinical trials was low: 0.1 to 3.2%.<sup>23-30</sup> In addition, most of the failed restorations were repairable. High AFR (5.3 to 11%) was noticed in a few other clin-

“ A large number of Class V clinical trials are discussed in the literature, as NCCLs are the best lesions with which to test clinical effectiveness of adhesives. ”

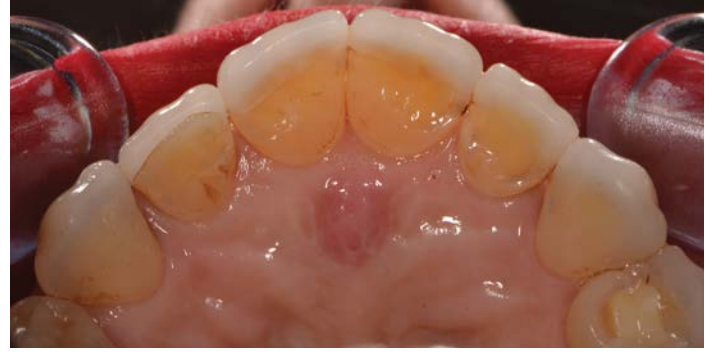

Table 3. Long-Term Clinical Trials Evaluating Ceramic Veneers

Author <i>Study type</i>	Patients/ <i>Restorations</i>	Materials	Duration	Failure (%) <i>AFR (%)</i>	Main reasons for failure
Beier et al. <sup>23</sup> <i>Retrospective</i>	-/298	leucite-reinforced ceramic lithium disilicate glass feldspathic ceramic	10 yrs 1-20 yrs	9% 0.9%	fracture
D'Arcangelo et al. <sup>24</sup> <i>Prospective</i>	30/119	feldspathic ceramic	7 yrs	2.5% 0.4%	caries loss of vitality
Dumfahrt & Schäffer <sup>25</sup> <i>Retrospective</i>	65/191	feldspathic ceramic	5 yrs 1-10 yrs	4% 0.8%	fracture
Fradeani et al. <sup>26</sup> <i>Retrospective</i>	46/182	leucite-reinforced ceramic (143) feldspathic ceramic (39)	6-12 yrs	6% 0.7%	fracture
Guess et al. <sup>27</sup> <i>Prospective</i>	25/66	leucite-reinforced ceramic	7 yrs	1% 0.1%	debonding
Gurel et al. <sup>28</sup> <i>Retrospective</i>	66/590	leucite-reinforced ceramic (217) lithium disilicate glass (320) feldspathic ceramic (43)	1-12 yrs	7% 1%	fracture debonding
Layton & Walton <sup>29</sup> <i>Prospective</i>	138/424	feldspathic ceramic	1-21 yr	4% 0.4%	gingival recession adversely affecting esthetics fracture
Peumans et al. <sup>30</sup> <i>Prospective</i>	25/87	feldspathic ceramic	10 yrs	34% 3.4%	fracture large marginal defects



**Figure 11:** Image of 22-year-old feldspathic veneers on seven upper anterior teeth (from left canine to first right premolar). Color and gloss of the veneered teeth is still the same as that of the natural teeth. Superficial marginal discoloration was noticed at some cervical veneer margins that ended in dentin.



**Figure 12:** Palatal view of the ceramic veneers. Slight marginal defects can be noticed at the palato-incisal margin due to wearing out of the luting composite. On the right lateral incisor, a fracture line was present due to a shortcoming in preparation design (long palato-incisal overlap with chamfer).

ical trials, where patients were not carefully selected (for factors such as bruxism, bad oral hygiene, large existing composite restorations, severe crowding, and high caries risk) and veneers were placed by inexperienced operators.<sup>31,32</sup> This means that the procedure for placement of ceramic veneers is highly technique-sensitive and carries a high probability of failure. Porcelain fracture was recorded as the main reason for failure, followed by debonding of the restoration. Failure due to caries, unacceptable marginal defects and/or marginal discoloration occurred less frequently.

An important factor determining the longevity of porcelain veneers is the quality of the bonded tooth surface (the amount of enamel and dentin). It is clearly shown in vivo that the success rate of porcelain veneers is highest when the veneer is bonded to a complete enamel surface.<sup>25,28,30</sup> When more than 50% of the bonded tooth surface consists of dentin, the risk of failure increases significantly. Therefore, it is important to have optimal control during tooth reduction by using a diagnostic wax-up, making a direct mock-up before preparation and, finally, checking the amount of tooth reduction with silicone keys made on the diagnostic wax-up.

Regarding the presence of composite restorations, more failures were observed in a 10-year clinical trial when veneers were bonded to teeth with large existing composite restorations.<sup>30</sup> The failures presented as an unacceptable marginal defect and severe marginal discoloration at the transition between the porcelain veneer and the composite restoration. These failed restorations were repairable. It was shown in vitro that pretreatment of composite restorations by air abrasion with CoJet Sand (3M ESPE; St. Paul, MN) followed by application of silane increased the bonding efficiency of the veneers to existing composite restorations.<sup>33</sup> The

“ The type of composite (hybrid, microfilled, or flowable composite) did not have an influence on the bonding performance of adhesives in NCCLs. ”

positive influence of this pretreatment procedure on the long-term clinical performance of ceramic veneers bonded to teeth with existing composite restorations still has to be proven.

Shortcomings in tooth preparation design can also result in increased failure risk. One should avoid sharp transition lines as these lead to stress concentration in the porcelain, resulting in crack lines or even fracture of the porcelain. As to incisal preparation, incisal reduction (1.5 to 2 mm) with a butt joint at the palatal side results in lower stress concentration and, consequently, in a lower fracture risk.<sup>34</sup>

Another well-known factor limiting the lifespan of veneers is bruxism.<sup>25,35</sup> Wear of a nightguard will decrease the fracture risk of veneers. Restorations on non-vital teeth also showed significantly more failures than veneers on vital teeth.<sup>23</sup>

The luting composite did not have a significant influence on the clinical performance of restorations in the above-mentioned clinical trials.

### Class II Composite Restoration

Posterior resin composites are widely considered as the first-choice material for posterior direct restorations. Their survival rate is very good (reviews have concluded that mean AFR ranges between 1% and 3%).<sup>36-38</sup> In clinical trials carried out by experienced operators the longevity of direct posterior composite restorations is similar or even superior to that of amalgam restorations, even for the larger composite restorations.<sup>39,40</sup> It is obvious that the experience of the operator in adhesive techniques plays a critical role in the clinical performance of posterior composite restorations.<sup>38</sup>

The longevity of these restorations is influenced by several other factors. The patient factor seems to be very important as secondary caries is the main reason for failure in patients with caries risk, whereas fracture is the main reason in patients with occlusal stress risk.<sup>41</sup>

Larger restorations have a higher risk of failure, since every extra surface included in a restoration increases the risk by 30 to 40%.<sup>38</sup> This process may be triggered by factors such as heavy occlusal loading, bruxing, or clenching. Therefore, it is important to keep tooth preparations as minimally invasive as possible.

Posterior composite restorations placed in endodontically treated teeth have a reduced survival rate (AFR 2 to 12.4%, AFR vital teeth 1 to 3%), which is explained by the extensive loss of tooth substance that these teeth suffer (due to caries, attrition, erosion, etc.).<sup>36</sup>

The failure risk of restorations in molars is higher than that of restorations in premolars.<sup>38</sup> In addition, restorations ending below the cemento-enamel junction showed a higher failure risk.<sup>42</sup>

The material properties of the restorative composite for the posterior area seem to have only a minor effect on the longevity of restorations, provided that hybrid materials are used. These materials have been shown to perform well and even excellently when used in posterior composite restorations. The resin composite material (filler load of the hybrid composite) had a limited effect on the survival of the restorations.<sup>13,38,43</sup> This was noticed only after extended periods of observation.<sup>13,43</sup> Today, failure of restorations related to wear of these materials in the posterior region seems almost nonexistent and may be restricted to bruxing and clenching patients.

Regarding the more recently introduced composite materials (bulk-fill and low-shrinkage composites), it is unlikely that these materials will provide a significant improvement,<sup>44</sup> as good results have already been achieved with the currently available posterior composites. However, long-term clinical trials are needed to prove their suitability.

If a posterior composite restoration fails, repair should be preferred over replacement if possible. Two clinical trials showed that repair considerably enhances the longevity of dental restorations.<sup>18,45</sup> Repair on restorations failing due to caries had a better prognosis compared to repairs on restorations failing due to fracture.<sup>45</sup>

“The longevity of Class IV restorations was evaluated in only a few medium- to long-term clinical trials with a study design that was not optimal.”

## Large Direct Composite Restorations in the Posterior Region Versus Indirect Partial Ceramic Crowns

As mentioned previously, the size of a Class II composite restoration determines its longevity. Therefore, the question arises whether placement of a direct composite cusp or crown buildup on a molar or premolar is justified. These large direct composite restorations are often placed because of their lower cost. However, anatomical form, proximal contact points, marginal adaptation, and polymerization shrinkage are much more difficult to control. Their clinical performance was evaluated in only three medium-term clinical trials (Table 4). Fennis and colleagues noticed no significant difference in failure rate between direct (10%) and indirect (17%) composite cusp buildups on premolars after five years of clinical service.<sup>46</sup> In addition, two other clinical trials evaluating direct composite buildups on molars/premolars showed an acceptable clinical performance after three years (AFR 0.1% and 4%).<sup>47,48</sup> More fractures were observed in the study where a nanofilled composite was used<sup>47</sup> compared to a study where a more heavily filled hybrid composite was used.<sup>48</sup> This again confirms that for larger direct composite restorations, a heavily filled hybrid composite is preferred.

The more durable, more esthetic alternative to the large direct composite buildup is the indirect bonded partial ceramic crown. This was shown in several long-term clinical trials reporting an AFR ranging from 0.1 to 2.2% (Table 5).<sup>49-53</sup>

The main reason for failure in all these studies was fracture and debonding of the restoration. Information regarding the influence of patient-related factors on the clinical performance of these restorations is scarce. Again, more failures were observed in non-vital teeth and in patients with bruxism.<sup>53</sup> In a 12-year clinical trial of ceramic inlays/onlays,<sup>54</sup> fractures occurred in two phases. In the first phase, fatigue fractures induced by adjustments with rotary instruments occurred between three and four years of clinical service. This emphasizes the importance of care-



Table 4. Medium-Term Clinical Trials Evaluating Direct Composite Cusp Builds

Author Study type	Patients/ Restorations	Materials	Duration	Failure (%) AFR (%)	Main reasons for failure
Fennis et al. <sup>46</sup> <i>Prospective – split mouth</i>	157/176 <i>premolars</i>	direct: 3E&Ra HC (70 vol%) indirect: 1SEa + selective enamel etch HC (82 vol%)	5 yrs	direct: 10% 2% indirect: 17% 3.4%	direct: fracture tooth/composite indirect: debonding
Laegreid et al. <sup>47</sup> <i>Prospective</i>	74/74 <i>molars</i>	2E&Ra NC (59 vol%)	3 yrs	12% 4%	fracture composite
Scholtanus et al. <sup>48</sup> <i>Prospective</i>	88/118 <i>premolars/ molars</i>	3E&Ra HC (71 vol%)	3.5 yrs 7-96 months	3.5% 1%	endodontic complication

HC = hybrid composite; NC = nanofilled composite; 3E&Ra = three-step etch-and-rinse adhesive;  
2E&Ra = two-step etch-and-rinse adhesive; 1SEa = one-step self-etch adhesive

Table 5. Long-Term Clinical Trials Evaluating Partial Ceramic Crowns

Author Study type	Patients/ Restorations	Materials	Duration	Failure (%) AFR (%)	Main reasons for failure
Federlin et al. <sup>49</sup> <i>Prospective</i>	22/22	feldspathic ceramic	5.5 yr	11% 2%	debonding fracture caries
Felden et al. <sup>50</sup> <i>Retrospective</i>	22/42	leucite- reinforced ceramic	6 months - 7 yrs	14% 2.7%	fracture
Guess et al. <sup>51</sup> <i>Prospective</i>	25/80	leucite- reinforced ceramic lithium disilicate glass	7 yrs	2.5% 0.1% 0% 0%	fracture -
Roggendorf et al. <sup>52</sup> <i>Retrospective</i>	25/59	feldspathic ceramic leucite- reinforced ceramic	7 yrs	13% 1.8%	fracture caries endodontic treatment
van Dijken & Hasselrot <sup>53</sup> <i>Retrospective</i>	105/228	leucite- reinforced ceramic	12.5 yrs 11-15 yrs	24% 1.9%	debonding fracture caries

ful polishing of these roughened areas. The second phase of fractures occurred after 10 years, due to the fact that the adjacent enamel was abraded significantly more than the ceramic, resulting in positive ceramic steps.<sup>55</sup> If these step formations are not adjusted, initial cracks are initiated at exactly these points of unsupported ceramic. In another clinical trial evaluating ceramic inlays/onlays, the clinical experience of the operator was clearly proven.<sup>56</sup> Regarding the luting systems, only slight differences were noticed between different luting agents. Finally, in the clinical study of Guess and colleagues,<sup>51</sup> none of the pressable lithium disilicate glass-ceramic partial crowns (e.max Press, Ivoclar Vivadent; Schaan, Liechtenstein) failed after seven years. This excellent clinical performance can be explained by the high flexural strength (440 MPa) and the favorable physico-mechanical properties reported *in vitro*.<sup>57-59</sup>

## Treatment of Generalized Tooth Wear with Direct Composite Restorations

Generalized tooth wear is a problem commonly seen in general practice. Restorative treatment is indicated if there is loss of vertical dimension, if there are esthetic complaints, in case of hypersensitivity, and shine-through of the pulp. In most wear cases, restorative treatment must be combined with an increase in vertical dimension of occlusion.<sup>60</sup> If enough tooth structure is left for bonding, different treatment options with adhesive restorations are possible:

- All teeth are restored with direct composite restorations. Advantages are the minimally invasive preparations and the lower cost compared to indirect adhesive restorations (Figs 13-18).
- A combination of direct composite restorations and indirect partial adhesive restorations to restore teeth with larger defects.
- Indirect adhesive partial restorations are placed on (almost) all teeth.

Although the most durable result is expected with the last treatment option, no clinical trials are available to confirm this. The only restorative treatment option that has been studied in medium-term clinical trials is total rehabilitation with direct composite restorations (Table 6).<sup>61-63</sup> Bartlett and colleagues<sup>62</sup> concluded that direct and indirect microfilled composite restorations are contraindicated for treatment of severe tooth wear, as very high failure rates were recorded after three years (direct, 44%; indirect, 56%). These results differ from the results of two more recent clinical trials carried out by experienced operators.<sup>61,63</sup> A highly filled hybrid composite was used. AFR was

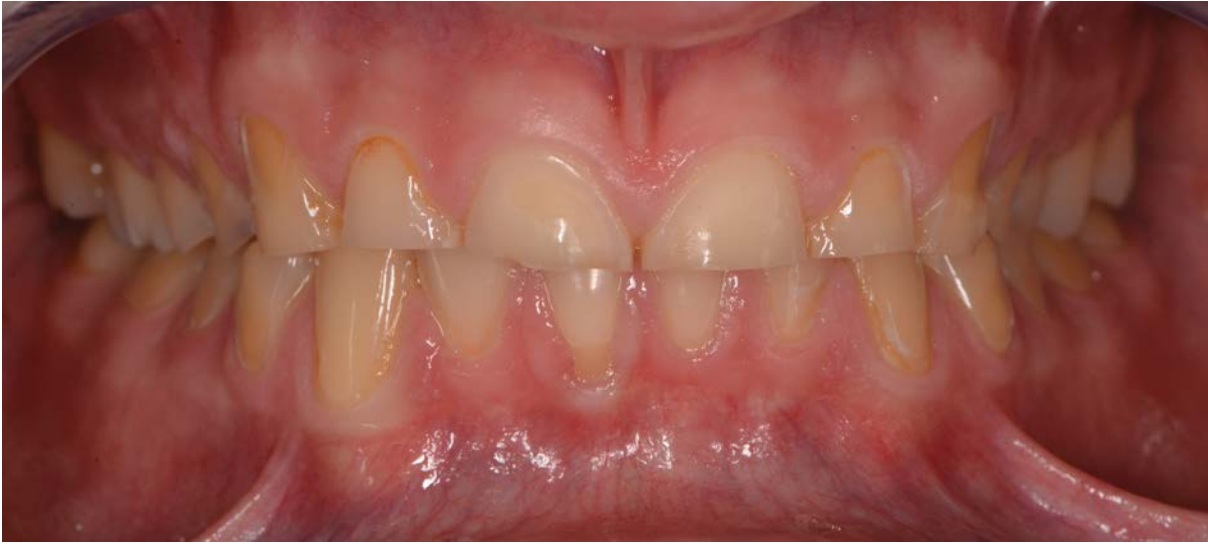favorable (1.5%). The most common reason for failure was fracture. Several restorations showed an acceptable deterioration of the margins and surface texture. These last two studies concluded that direct composite restorations are successful in the treatment of severe tooth wear in the medium term.

## Conclusions

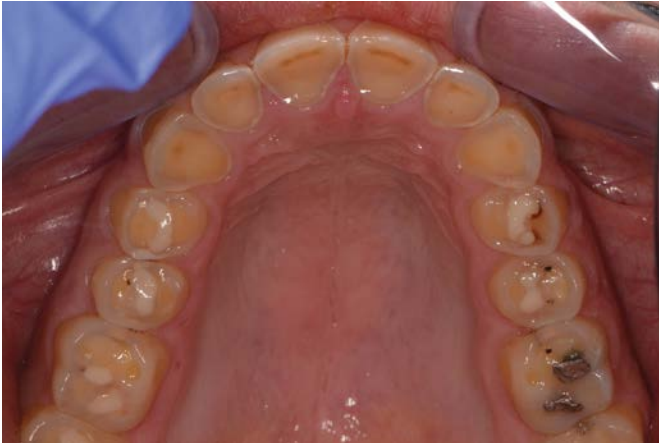At present, direct composite materials are no longer limited to small restorations. Enough clinical proof is available that placement of more complex direct composite restorations is justified. A number of factors will determine the choice between a direct composite and an indirect bonded ceramic restoration. Direct composite restorations are preferred if the dentist would like to treat as minimally invasively as possible, obtaining an acceptable esthetic result. In addition, repair of the restorations is easy and will lengthen their lifespan. Direct composite restorations placed by an experienced operator guarantee success in the medium to long term. The influence of the patient factor on the clinical performance of direct composite restorations should not be underestimated.

An indirect bonded ceramic restoration is selected if the patient would like to have a more durable and optimal esthetic result. The procedure for placement of indirect adhesive restorations is more technique-sensitive, which results in a higher probability of failure. Moreover, the operator plays an important role. He/she must select the correct materials and ensure that all steps of the clinical procedure are carried out correctly. Under these conditions, indirect adhesive restorations guarantee long-term success.

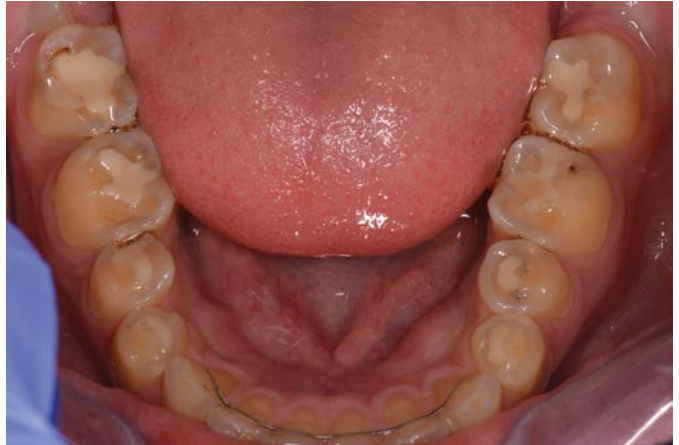“ In contrast to the direct composite veneer, bonded ceramic veneers are one of the most studied adhesive restoration types. ”



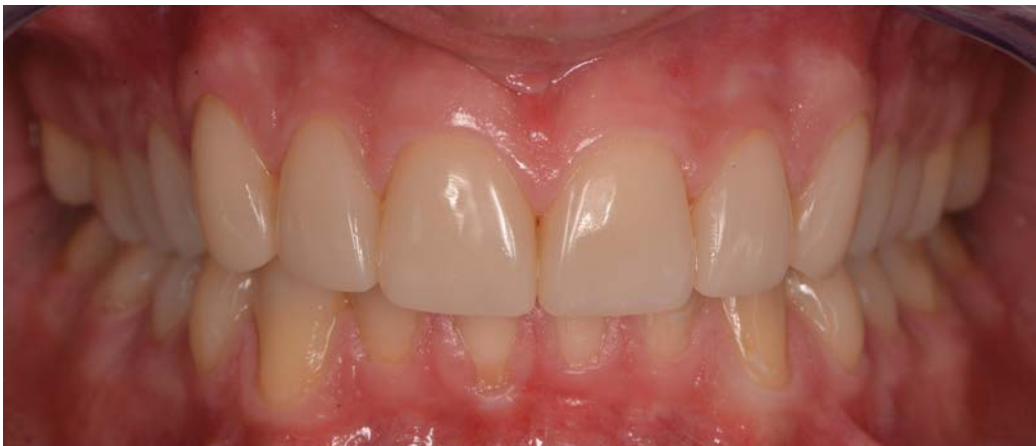**Figure 13:** Image of a 23-year-old male patient with severe generalized tooth wear due to a combination of excessive intake of acidic drinks (cola, sport drinks) and bruxism. The patient complained about esthetics and increased tooth sensitivity. The treatment consisted of total rehabilitation with direct composite restorations.



**Figure 14:** Initial presentation: occlusal view of upper jaw showing extreme tooth wear with dentin exposure on all teeth.

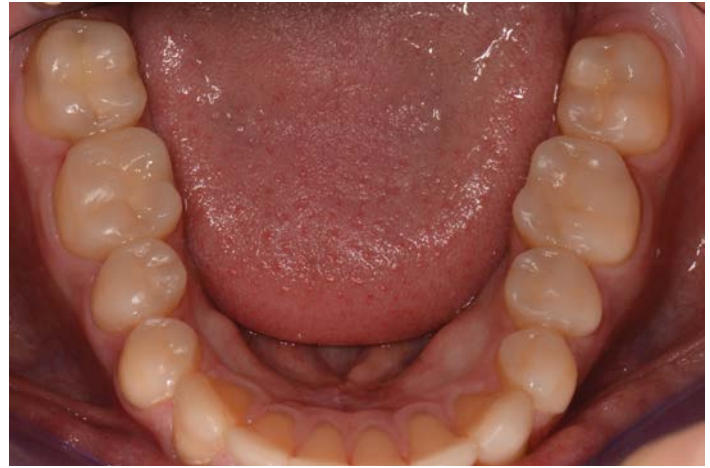
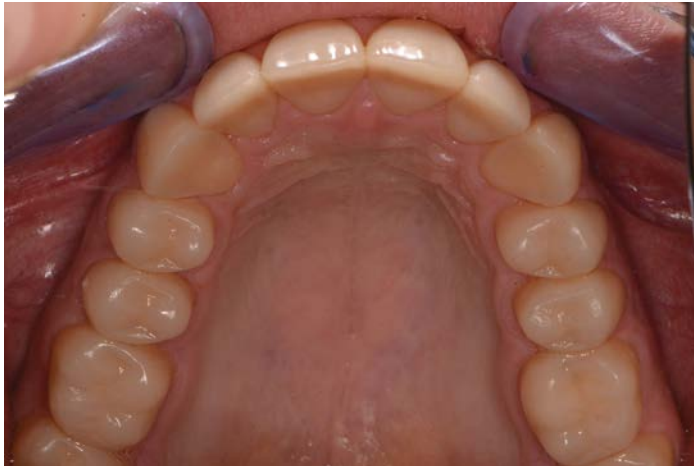
**Figure 15:** Initial presentation: occlusal view on lower jaw showing extreme tooth wear and some interproximal caries lesions.



**Figure 16:** Final result after placement of direct composite restorations on all upper and lower teeth. Regarding tooth preparation, the dentin surface was roughened with a diamond bur and the enamel by sandblasting. A nanofilled composite was used. A highly clinically acceptable result was obtained with a good prognosis in the medium term.





**Figure 17:** Final result of the occlusal view of the upper jaw.

**Figure 18:** Final result of the occlusal view of the lower jaw.

**Table 6. Medium-Term Clinical Trials Evaluating Direct Composite Restorations for Treatment of Generalized Tooth Wear**

Author <i>Study type</i>	Patients/ <i>Restorations</i>	Materials	Duration	Failure (%) <i>AFR (%)</i>	Main reasons for failure
Attin et al. <sup>61</sup> <i>Retrospective</i>	7/75 premolars/ molars	3E&Ra fine HC (58 vol%)	5.5 yrs	1% 0.2%	fracture
Bartlett & Sundaram <sup>62</sup> <i>Prospective</i>	16/32 premolars/ molars	3E&Ra MC	3 yrs	direct: 44% 14.6% indirect: 56% 18.6%	fracture loss of restoration
Hamburger et al. <sup>63</sup> <i>Retrospective</i>	18/332 all teeth	3E&Ra fine HC (70 vol%)	4 yrs 6 months- 12 yrs	7% 1.7%	fracture

MC = microfilled composite; HC = hybrid composite; 3E&Ra = two-step etch-and-rinse adhesive

## References

1. Levitch LC, Bader JD, Shugars DA, Heymann HO. Non-cariou cervical lesions. *J Dent.* 1994 Aug;22 (4):195-207.
2. Peumans M, De Munck J, Mine A, Van Meerbeek B. Clinical effectiveness of contemporary adhesives for the restoration of non-cariou cervical lesions. A systematic review. *Dent Mater.* 2014 Oct;30(10):1089-103.
3. Van Meerbeek B, De Munck J, Yoshida Y, Inoue S, Vargas M, Vijay P, Van Landuyt K, Lambrechts P, Vanherle G. Buonocore Memorial Lecture. Adhesion to enamel and dentin: current status and future challenges. *Oper Dent.* 2003 May-Jun;28(3):215-35.
4. Van Meerbeek B, Yoshihara K, Yoshida Y, Mine A, De Munck J, Van Landuyt KL. State of the art of self-etch adhesive. *Dent Mater.* 2011 Jan;27(1):17-28.
5. De Munck J, Mine A, Poitevin A, Van Ende A, Cardoso MV, Van Landuyt KL, Peumans M, Van Meerbeek B. Meta-analytical review of parameters involved in dentin bonding. *J Dent Res.* 2012 Apr;91(4):351-7.
6. de Moura FR, Romano AR, Lund RG, Piva E, Rodrigues Júnior SA, Demarco FF. Three-year clinical performance of composite restorations placed by undergraduate dental students. *Braz Dent J.* 2011;22(2):111-6.
7. Smales RJ, Gerke DC. Clinical evaluation of four anterior composite resins over five years. *Dent Mater.* 1992 Jul;8(4):246-51.
8. Tyas MJ. Correlation between fracture properties and clinical performance of composite resins in Class IV cavities. *Aust Dent J.* 1990 Feb;35(1):46-9.
9. van Dijken JW, Pallesen U. Fracture frequency and longevity of fractured resin composite, poly-acid modified resin composite, and resin-modified glass ionomer cement Class IV restorations: an up to 14 years of follow-up. *Clin Oral Invest.* 2010 Apr;14(2):217-22.
10. Ferracane JL. Resin composite—state of the art. *Dent Mater.* Jan;27(1):29-38.
11. Ilie N, Rencz A, Hickel R. Investigations towards nano-hybrid resin-based composites. *Clin Oral Investig.* 2013 Jan;17(1):185-93.
12. Kaizer MR, de Oliveira-Ogliari A, Censi MS, Opdam NJ, Moraes RR. Do nanofill or submicron composites show improved smoothness and gloss? A systematic review of in vitro studies. *Dent Mater.* 2014 Apr;30(4):e41-78.
13. Baldissera RA, Corrêa MB, Schuch HS, Collares K, Nascimento GG, Jardim PS, Moraes RR, Opdam NJ, Demarco FF. Are there universal composites for anterior and posterior teeth? *J Dent.* 2013 Nov;41(11):1027-35.
14. Alonso V, Caserio M. A clinical study of direct composite full-coverage crowns: long-term results. *Oper Dent.* 2012 Jul-Aug;37(4):432-41.
15. Frese C, Schiller P, Staehle HJ, Wolff D. Recontouring teeth and closing diastemas with direct composite buildups: a 5-year follow-up. *J Dent.* 2013 Nov;41(11):979-85.
16. Peumans M, Van Meerbeek B, Lambrechts P, Vanherle G. The 5-year clinical performance of direct composite additions to correct tooth form and position. II. Marginal qualities. *Clin Oral Investig.* 1997 Feb;1(1):19-26.
17. Blunck U. Pretreatment of composite resin surfaces for repair: why and how. *J Adhes Dent.* 2013 Dec;15(6):592.
18. Fernández E, Martín J, Vildosola P, Oliveira Junior OB, Gordan V, Mjor I, Bersezio C, Estay J, de Andrada ME, Moncada G. Can repair increase the longevity of composite resins? Results of a 10-year clinical trial. *J Dent.* 2015 Feb;43(2):279-86.
19. Hickel R, Brühshaver K, Ilie N. Repair of restorations—criteria for decision making and clinical recommendations. *Dent Mater.* 2013 Jan;29(1):28-50.
20. Gresnigt MM, Kalk W, Özcan M. Randomized controlled split-mouth clinical trial of direct laminate veneers with two micro-hybrid resin composites. *J Dent.* 2012 Sep;40(9):766-75.
21. Meijering AC, Creughers NH, Roeters FJ, Mulder J. Survival of three types of veneer restorations in a clinical trial: a 2.5-year interim evaluation. *J Dent.* 1998 Sep;26(7):563-8.
22. Welbury RR. A clinical study of a microfilled composite for labial veneers. *Int J Paediatr Dent.* 1991 Apr;1(1):9-15.
23. Beier US, Kapferer I, Burtscher D, Dumfahrt H. Clinical performance of porcelain laminate veneers for up to 20 years. *Int J Prosthodont.* 2012 Jan-Feb;25(1):79-85.
24. D'Arcangelo C, De Anglis F, Vadini M, D'Amario M. Clinical evaluation on porcelain laminate veneers bonded with light-cured composite: results up to 7 years. *Clin Oral Invest.* 2012 Aug;16(4):1071-9.
25. Dumfahrt H, Schäffer H. Porcelain laminate veneers. A retrospective evaluation after 1 to 10 years of service: part II—clinical results. *Int J Prosthodont.* 2000 Jan-Feb;13(1):9-18.
26. Fradeani M, Redemagni M, Corrado M. Porcelain laminate veneers: 6- to 12-year clinical evaluation—a retrospective study. *Int J Periodontics Restorative Dent.* 2005 Feb;25(1):9-17.

27. Guess PC, Setz CF, Voulgarakis A, Stampf S, Stappert CFJ. Prospective clinical study of press-ceramic overlap and full veneer restorations: 7-year results. *Int J Prosthodont.* 2014 Jul-Aug;27(4):355-8.
28. Gurel G, Morimoto S, Calamita MA, Coachman C, Sesma N. Clinical performance of porcelain laminate veneers: outcomes of the aesthetic pre-evaluative temporary (APT) technique. *Int J Periodontics Restorative Dent.* 2012 Dec;32(6):625-35.
29. Layton DM, Walton TR. The up to 21-year clinical outcome and survival of feldspathic porcelain veneers: accounting for clustering. *Int J Prosthodont.* 2012 Nov-Dec;25(6):604-12.
30. Peumans M, De Munck J, Fieuw S, Lambrechts P, Vanherle G, Van Meerbeek B. A prospective ten-year clinical trial of porcelain veneers. *J Adhes Dent.* 2004 Spring;6(1):65-76.
31. Burke FJ, Lucarotti PS. Ten-year outcome of porcelain laminate veneers placed within the general dental services in England and Wales. *J Dent.* 2009 Jan; 37(1):31-8.
32. Shaini FJ, Shortall AC, Marquis PM. Clinical performance of porcelain laminate veneers. A retrospective evaluation over a period of 6.5 years. *J Oral Rehabil.* 1997 Aug;24(8):553-9.
33. Gresnigt MM, Özcan M, Kalk W, Galhano G. Effect of static and cyclic loading on ceramic laminate veneers adhered to teeth with and without aged composite restorations. *J Adhes Dent.* 13(6):569-77.
34. Da Costa DC, Coutinho M, de Sousa AS, Ennes JP. A meta-analysis of the most indicated preparation design for porcelain laminate veneers. *J Adhes Dent.* 2013 Jun;15(3):215-20.
35. Granell-Ruiz M, Agustin-Panadero R, Fons-Font A, Román-Rodríguez JL, Solá-Ruiz MF. Influence of bruxism on survival of porcelain laminate veneers. *Med Oral Patol Oral Cir Bucal.* 2014 Sep 1;19(5):e426-32.
36. Demarco FF, Corrêa MB, Cenci MS, Moraes RR, Opdam NJ. Longevity of posterior composite restorations: not only a matter of materials. *Dent Mater.* 2012 Jan;28(1):87-101.
37. Heintze SD, Rousson V. Clinical effectiveness of direct Class II restorations—a meta-analysis. *J Adhes Dent.* 2012 Aug;14(5):407-31.
38. Opdam NJ, van de Sande FH, Bronkhorst E, Cenci MS, Bottenberg P, Pallesen U, Gaengler P, Lindberg A, Huysmans MC, van Dijken JW. Longevity of posterior composite restorations: a systematic review and meta-analysis. *J Dent Res.* 2014 Oct;93(10):943-9.
39. Opdam N, Bronkhorst EM, Roeters JM, Loomans BA. A retrospective clinical study on longevity of posterior composite and amalgam restorations. *Dent Mater.* 2007 Jan;23(1):2-8.
40. Opdam NJM, Bronkhorst EM, Loomans BAC, Huysmans MC. 12-year survival of composite vs. amalgam restorations. *J Dent Res.* 2010 Oct;89(10):1063-7.
41. van de Sande FH, Opdam NJ, Da Rosa Rodolpho PA, Correa MB, Demarco FF, Cenci MS. Patient risk factors' influence on survival of posterior composites. *J Dent Res.* 2013 Jul;92(7 Suppl):78S-83S.
42. Kuper NK, Opdam NJ, Bronkhorst EM, Huysmans MC. The influence of approximal restoration extension on the development of secondary caries. *J Dent.* 2012 Mar;40(3):241-7.
43. Da Rosa Rodolpho PA, Donassollo TA, Cenci MS, Loguercio AD, Moraes RR, Bronkhorst EM, Opdam NJ, Demarco FF. 22-year clinical evaluation of the performance of two posterior composites with different filler characteristics. *Dent Mater.* 2011 Oct;27(10):955-63.
44. Leprince JG, Palin WM, Vanacker J, Sabbagh J, Devaux J, Leloup G. Physico-mechanical characteristics of commercially available bulk-fill composites. *J Dent.* 2014 Aug;42(8):993-1000.
45. Opdam NJ, Bronkhorst EM, Loomans BA, Huysmans MC. Longevity of repaired restorations: a practice-based study. *J Dent.* 2012 Oct;40(10):829-35.
46. Fennis WM, Kuijs RH, Roeters FJ, Creughers NH, Kreulen CM. Randomized control trial of composite cuspal restorations: five-year results. *J Dent Res.* 2014 Jan;93(1):36-41.
47. Laegreid T, Gjerdet NR, Johansson AK. Extensive composite molar restorations: 3 years clinical evaluation. *Acta Odontol Scand.* 2012 Jul;70(4):344-52.
48. Scholtanus JD, Özcan M. Clinical longevity of extensive direct composite restorations in amalgam replacement: up to 3.5 years follow-up. *J Dent.* 2014 Nov;42(11):1404-10.
49. Federlin M, Hiller KA, Schmalz G. Controlled, prospective clinical split-mouth study of cast gold vs. ceramic partial crowns: 5.5 year results. *Am J Dent.* 2010 Jun;23(3):161-7.
50. Felden A, Schmalz G, Hiller KA. Retrospective clinical study and survival analysis of partial ceramic crowns: results up to 7 years. *Clin Oral Invest.* 2000 Dec;4(4):199-205.
51. Guess PC, Selz CF, Steinhart YN, Stampf S, Strub JR. Prospective clinical split-mouth study of pressed and CAD/CAM all-ceramic partial-coverage restorations: 7-year results. *Int J Prosthodont.* 2013 Jan-Feb;26(1):21-5.
52. Roggendorf MJ, Kunzi B, Eber J, Roggendorf HC, Frankenberger R, Reich SM. Seven-year clinical performance of CEREC-2 all-ceramic CAD/CAM restorations placed within deeply destroyed teeth. *Clin Oral Investig.* 2012 Oct;16(5):1413-24.



53. van Dijken JW, Hasselrot L. A prospective 15-year evaluation of extensive dentin-enamel-bonded pressed ceramic coverages. *Dent Mater*. 2010 Sep;26(9):929-39.
54. Frankenberger R, Taschner M, Garcia-Godoy F, Petschelt A, Krämer N. Leucite-reinforced glass ceramic inlays and onlays after 12 years. *J Adhes Dent*. 2008 Oct;10(5):393-8.
55. Krämer N, Kunzelmann KH, Taschner M, Mehl A, Garcia-Godoy F, Frankenberger R. Antagonist enamel wears more than ceramic inlays. *J Dent Res*. 2006 Dec;85(12):1097-100.
56. Frankenberger R, Reinelt C, Petschelt A, Krämer N. Operator vs. material influence on clinical outcome of bonded ceramic inlays. *Dent Mater*. 2009 Aug;25(8):960-8.
57. Guess PC, Shultheis S, Wolkewitz M, Zhang Y, Strub JR. Influence of preparation design and ceramic thicknesses on fracture resistance and failure modes of premolar partial coverage restorations. *J Prosthet Dent*. 2013 Oct;110(4):264-73.
58. Magne P, Schlichting LH, Maia HP, Baratieri LN. In vitro fatigue resistance of CAD/CAM composite resin and ceramic posterior occlusal veneers. *J Prosthet Dent*. 2010 Sep;104(3):149-57.
59. Magne P, Paranhos MP, Schlichting LH. Influence of material selection on risk of inlay fracture during pre-cementation functional occlusal tapping. *Dent Mater*. 2011 Feb;27(2):109-13.
60. Muts E, van Pelt H, Edelhoff D, Krecji I, Cune M. Tooth wear: a systematic review of treatment options. *J Prosthet Dent*. 2014 Oct;112(4):752-9.
61. Attin T, Filli T, Imfeld C, Schmidlin PR. Composite vertical bite reconstructions in eroded dentitions after 5.5 years: a case series. *J Oral Rehabil*. 2012 Jan;39(1):73-9.
62. Bartlett D, Sundaram G. An up to 3-year randomized clinical study comparing indirect and direct resin composite used to restore worn posterior teeth. *Int J Prosthodont*. 2006 Nov-Dec;19(6):613-7.
63. Hamburger JT, Opdam NJ, Bronkhorst EM, Kreulen CM, Roeters JJ, Huysmans MC. Clinical performance of direct composite restorations for treatment of severe tooth wear. *J Adhes Dent*. 2011 Dec;13(6):585-93. **JCD**

“ In most wear cases, restorative treatment must be combined with an increase in vertical dimension of occlusion. ”



Dr. Peumans is a professor, KU Leuven - BIOMAT, Department of Oral Health Sciences, KU Leuven & Dentistry, University Hospitals Leuven, Leuven, Belgium. She can be contacted at [marleen.peumans@med.kuleuven.ac.be](mailto:marleen.peumans@med.kuleuven.ac.be).

Disclosure: The author did not report any disclosures.

# AACD Self-Instruction Continuing Education Information



## General Information

This continuing education (CE) self-instruction program has been developed by the American Academy of Cosmetic Dentistry (AACD) and an advisory committee of the *Journal of Cosmetic Dentistry*.

## Eligibility and Cost

The exam is free of charge and is intended for and available to AACD members only. It is the responsibility of each participant to contact his or her state board for its requirements regarding acceptance of CE credits. The AACD designates this activity for 3 continuing education credits.

## Testing and CE

The self-instruction exam comprises 10 multiple-choice questions. To receive course credit, AACD members must complete and submit the exam and answer at least 70% of the questions correctly. Participants will receive test results immediately after taking the examination online and can only take each exam once. The exam is scored automatically by the AACD's online testing component. The deadline for completed exams is one calendar year from the publication date of the issue in which the exam appeared. The exam is available online at [www.aacd.com](http://www.aacd.com). A current web browser is necessary to complete the exam; no special software is needed.

Note: Although the AACD grants these CE credits, it is up to the receiving governing body to determine the amount of CE credits they will accept and grant to participants.

## Verification of Participation (VOP)

VOP will be sent to AACD members via their MyAACD account upon pass completion. Log into [www.aacd.com](http://www.aacd.com) to sign into your MyAACD account.

For members of the Academy of General Dentistry (AGD): The AACD will send the AGD proof of your credits earned on a monthly basis. To do this, AACD must have your AGD member number on file. Be sure to update your AGD member number in your AACD member profile on MyAACD.com.


All participants are responsible for sending proof of earned CE credits to their state dental board or agency for licensure purposes.

## Disclaimer

AACD's self-instruction exams may not provide enough comprehensive information for participants to implement into practice. It is recommended that participants seek additional information as required. The AACD Self-Instruction Program adheres to the guidelines set forth by the American Dental Association Continuing Education Recognition Program (CERP), and the AGD Program Approval for Continuing Education (PACE). Exams will be available for a maximum of 3 years from publication date.

## Questions and Feedback

For questions regarding a specific course, information regarding your CE credits, or to give feedback on a CE self-instruction exam, please contact the AACD Executive Office by e-mailing [info@aacd.com](mailto:info@aacd.com) or by calling 800.543.9220 or 608.222.8583.



ADA CERP is a service of the American Dental Association to assist dental professionals in identifying quality providers of continuing dental education. ADA CERP does not approve or endorse individual courses or instructors, nor does it imply acceptance of credit hours by boards of dentistry. AACD designates this activity for 3 continuing education credits. Concerns or complaints about a CE provider may be directed to the provider or to ADA CERP at [www.ada.org/goto/cerp](http://www.ada.org/goto/cerp).

The 10 multiple-choice questions for this Continuing Education (CE) self-instruction exam are based on the article, "Clinical Performance of Direct and Indirect Adhesive Restorations" by Marleen Peumans, PhD, DDS. This article appears on pages 110-127.

The examination is free of charge and available to AACD members only. AACD members must log onto [www.aacd.com](http://www.aacd.com) to take the exam. **Note that only Questions 1 through 5 appear in the printed and digital versions of the jCD; they are for readers' information only.** The complete, official self-instruction exam is available online only—completed exams submitted any other way will not be accepted or processed. A current web browser is necessary to complete the exam; no special software is needed. The AACD is a recognized credit provider for the Academy of General Dentistry, American Dental Association, and National Association of Dental Laboratories. For any questions regarding this self-instruction exam, call the AACD at 800.543.9220 or 608.222.8583.

1. In comparing direct and indirect adhesive restorations, literature has shown which of the following to be true?
  - a. Current long-term clinical trials show that indirect partial ceramic restorations demonstrate a higher annual failure rate (AFR) compared to their similarly sized direct composite restorations.
  - b. Current clinical trials show that indirect partial ceramic restorations demonstrate a lower AFR compared to their similarly sized direct composite restorations.
  - c. More long-term clinical trials are available for direct composite restorations than for indirect composite restorations.
  - d. More medium- and long-term clinical trials are available for partial ceramic restorations than for full-ceramic crowns or porcelain veneers.
2. What is the most critical factor affecting the longevity of direct composite restorations?
  - a. The filler content of the direct composite.
  - b. The patient's home care of the restoration.
  - c. The human factor (patient and operator).
  - d. The type of adhesive used.
3. Class V non-cariou cervical lesion restorations have which of the following characteristics?
  - a. The border of the lesion is enamel or cementum, which bond equally to the restorative material.
  - b. The major portion of tooth surface to bond to consists of eburnated dentin.
  - c. The restorative surface of the lesion is predominantly roughened enamel, which leads to the high success rate of these restorations.
  - d. These lesions provide only a minimal amount of macro retention.
4. Selective etching of enamel with phosphoric acid prior to application of the adhesive had what result in Class V composite restorations?
  - a. Lower frequency of small marginal defects.
  - b. Higher frequency of large marginal defects.
  - c. Lower frequency of superficial marginal discoloration at the gingival junction of the restoration.
  - d. Higher frequency of superficial marginal discoloration at the enamel junction of the restoration.
5. Studies comparing Class II, IV, and V composite restoration have found which of the following?
  - a. The bonding procedure for a Class IV restoration is most complicated by the large amount of bonding surface that is dentin compared to Class II and V restorations.
  - b. The mechanical properties of the composite are less important to the outcome than the actual performance of the adhesive in non-cariou cervical lesions.
  - c. Microfilled composites can be used with equal success in Class II, IV, and V restorations.
  - d. A small-particle hybrid composite is the material of choice for the majority of Class II, IV, and V restorations.

To see and take the complete exam, log onto [www.aacd.com/jcdce](http://www.aacd.com/jcdce), and log in.



# jCD Book Review

The *Journal of Cosmetic Dentistry's* Book Review is an opinion piece by jCD reviewers. It highlights works that are currently available from publishers in the dental industry.

**Title:** *High-Strength Ceramics: Interdisciplinary Perspectives*  
**Editors:** Jonathan L. Ferencz, DDS; Nelson R.F.A. Silva, DDS, MS, PhD;  
 José Manuel Navarro, DDS, MS  
**Publisher:** Quintessence Publishing


*High-Strength Ceramics: Interdisciplinary Perspectives* comprises contributions from an impressive lineup of world-renowned clinicians, ceramists, and researchers. The book is divided into 13 chapters, with the first 3 chapters dedicated to theoretical and research aspects of various high-strength ceramics, including lithium disilicate and zirconia. The subsequent chapters apply this knowledge to clinically relevant scenarios, ranging from inlays/onlays and veneers on natural teeth, to abutments and definitive restorations on implants, plus novel approaches such as monolithic zirconia oral rehabilitation and zirconia implants. The book concludes with a chapter on CAD/CAM workflow for indirect ceramics from inception of digital impressions to delivery of the fabricated units.

The book's research is comprehensive, particularly that relating to the practice-based research network (PBRN) trials, the ultimate test for any dental material in the hostile oral environment. In addition, the last few decades have seen many metal-free substitutes zealously marketed by dental manufacturers, which have proved catastrophic failures; one of the valuable aspects of this book is that it redresses the commercial hype with scientific and clinical-based realities. Having numerous authors from different disciplines adds diversity and variety, and allows assimilation of a single topic in a single chapter.

The book could have been improved by including clinical examples of ceramic failures. This omission is particularly relevant for elective ceramic "smile makeovers," which are time-consuming for the clinician and costly for the patient. The beautiful results shown are just a few weeks or months post-treatment; it would have been useful to show some medium- to long-term failures, and more importantly, the management of such consequences. Furthermore, some of the anterior esthetic case studies, with impeccable postoperative results, may be considered as "overtreatment" by disciples of direct, minimally invasive restorations.

In summary, this is a laudable book that addresses the benefits and limitations of indirect ceramic restorations. The clinical work is inspirational and the theoretical knowledge impeccable. It will serve as a useful text for those wishing to update themselves on the latest possibilities for using ceramics in clinical practice.

**“The clinical work is inspirational and the theoretical knowledge impeccable.”**



**5 Indirect Ceramic Choices for Teeth**

**TABLE 5-1 Possible choices of cement for complete crowns made of different substrates**

Substrate	ZrO <sub>2</sub>	SiC	Al <sub>2</sub> O <sub>3</sub>	SiC-ZrO <sub>2</sub>	SiC-SiO <sub>2</sub>	SiC-SiO <sub>2</sub> -ZrO <sub>2</sub>
Resin cements	✓	✓	✓	✓	✓	✓
Resin cements with silane	✓	✓	✓	✓	✓	✓
Resin cements with silane and silane coupling agent	✓	✓	✓	✓	✓	✓
Resin cements with silane and silane coupling agent and silane coupling agent	✓	✓	✓	✓	✓	✓
Resin cements with silane and silane coupling agent and silane coupling agent and silane coupling agent	✓	✓	✓	✓	✓	✓

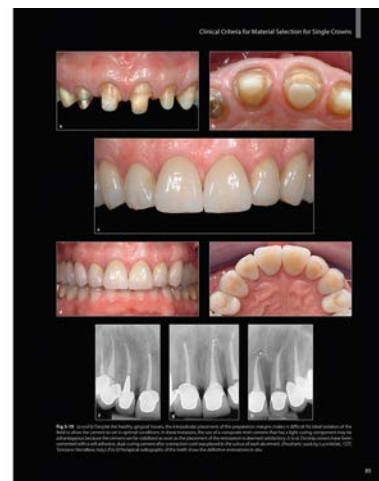**Concentration of single cements**

Although cementation procedures and materials for high-strength ceramics are discussed in chapter 5, it is important to emphasize key aspects of the cementation procedures for single-unit, high-strength ceramic restorations. Cement selection and the ability to isolate the abutment to perform the cementation procedure properly are critical factors that directly influence the selection of crown material.<sup>11-13</sup> Table 5-1 shows a guideline for the cementation of indirect ceramic restorations. It is important to provide the proper conditions for the luting agent to optimally function. A clinician interested in taking advantage of the greater translucency of glass-ceramics, zirconia, or zirconia-reinforced lithium silicate cements must be able to select such a material if the preparation margin is not appropriate for the glass-ceramic or zirconia-reinforced lithium silicate cements and porcelain veneer application. In addition, the preparation margin must be appropriate for the application of the cementation procedure, and indirect luting cements must be used. The preparation and glass-ceramic cements, the issue of selecting the best luting agent for immediate preparation with a diamond burs during crown preparation, a luting agent should be used, among others, since luting requirements provide the substrate with the necessary strength to resist its dissolution, prevent high-strength inlays, onlays, and crowns from being

readily subjected to wear and setting forces. In long-term, acceptable, and the attempts to seal the interface between porcelain and tooth to avoid bacterial infiltration.<sup>14-16</sup> The aim is to ensure that the cementation should not come in contact with saliva or blood during setting because part of the cement may be transported back into the tooth. The cement should be applied to the margin of the preparation margin, and the seal at the margin may be compromised. If the preparation margin is marginally irregular or at the gingival margin, leaving a residual luting agent (see Fig. 5-10). If the margin is irregular, residual luting agent may be a very time-consuming procedure and one that will not be patient friendly (see Fig. 5-11).

Traditionally, metal-ceramic crowns have been cemented with zinc phosphate or glass-ionomer cements. These cements have been replaced by resin cements, which are able to cement alumina and zirconia. The main drawback of these cements is their poor wetting ability. In the early 1990s, the use of silane coupling agents was introduced. The use of silane is difficult to apply, and the strength of the bond is not as strong as that of the resin cements. The advantage of the resin cements is that they are better in terms of wetting ability and have a higher bond strength to both the porcelain and glass-ceramic cements. Some clinicians feel that metal-ceramic crowns can provide a more reliable marginal seal even in less than ideal conditions.

Although there is no scientific evidence of an optimal seal, it is necessary to increase the frequency of a restoration, the risk of such a seal is to increase the frequency of the

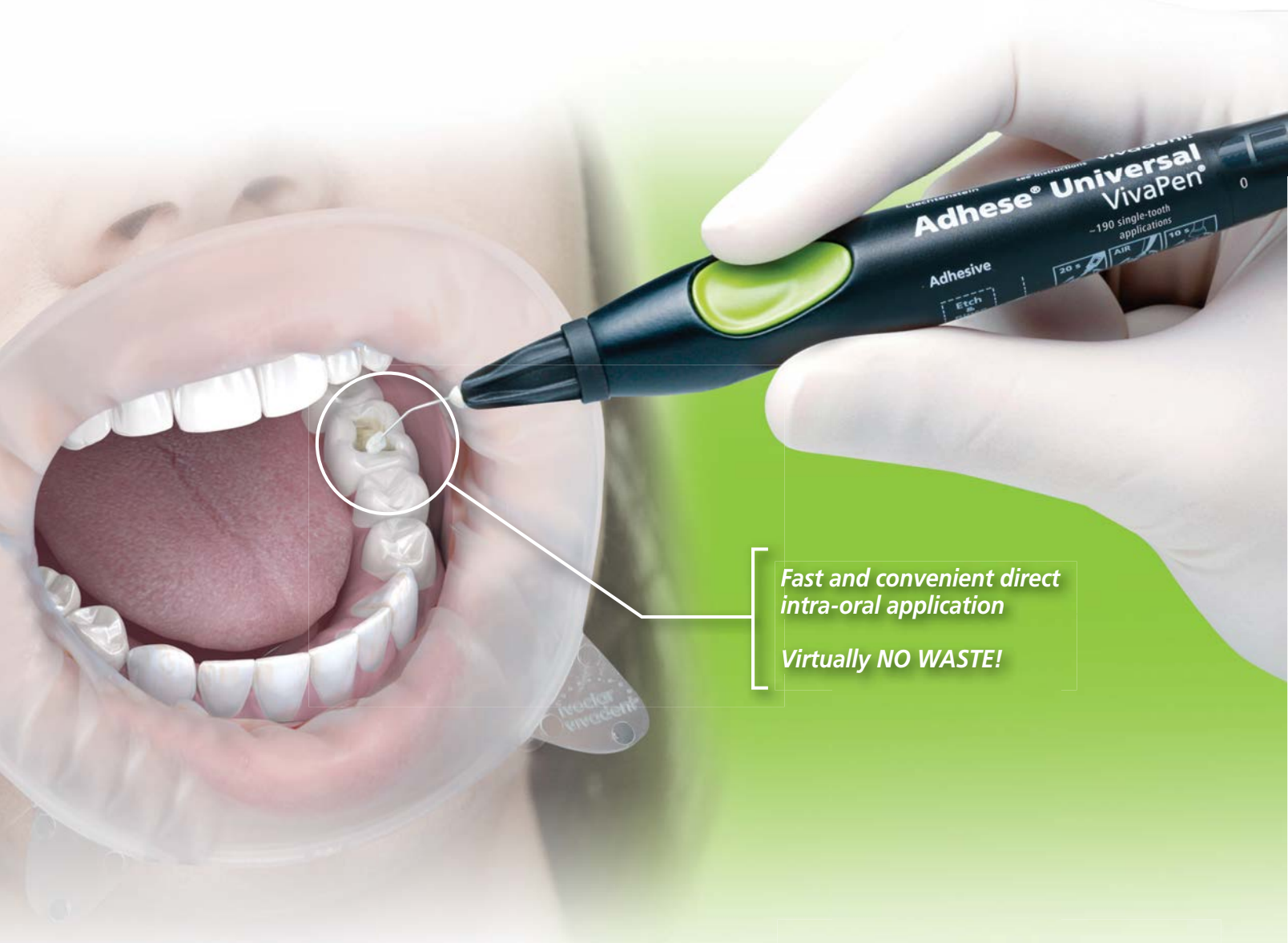

**A Special Gift for jCD Readers:**

Take advantage of a special offer from Quintessence Publishing! As an AACD member, you can receive a preview download of *High-Strength Ceramics* and 25% off the regular price. Simply enter promo code JCD2015 at checkout. To take advantage of this discount, visit: <http://www.quintpub.com/jcd/>

# Adhese® Universal

Light-curing dental adhesive



- **Efficient VivaPen® delivery** - 3X more applications per ml compared to bottles
- **Universal application** - Developed for all bonding and etching techniques
- **Predictable results** - High bond strength and virtually no sensitivity



100% CUSTOMER SATISFACTION  
GUARANTEED!



[ivoclarvivadent.com](http://ivoclarvivadent.com)

For more information, call us at 1-800-533-6825 in the U.S., 1-800-263-8182 in Canada.  
© 2015 Ivoclar Vivadent, Inc. Ivoclar Vivadent, VivaPen and Adhese are registered trademarks of Ivoclar Vivadent, Inc.

ivoclar  
vivadent®  
passion vision innovation



Anita W.  
MACSTUDIO MODEL SEARCH  
NATIONAL GRAND PRIZE WINNER

DENTISTRY BY  
Dr. Alan Montrose, Beaverton, OR  
AACD ACCREDITED MEMBER

## MACSTUDIO BY MICRODENTAL LABORATORIES

Developed 15 years ago by dentists and MicroDental, Macstudio restorations are the leading choice for dentists who are committed to life-changing dentistry.

Dr. Montrose's treatment plan began with Anita's concern for the space between her two front teeth, as well as worn incisors and inclined anteriors and premolars. With the goal in mind of lengthening and broadening the smile, Dr. Montrose collaborated with the Macstudio Team to have Anita preview her new smile in temporary veneers. With a few shape alterations, the final restorations were fabricated and placed. Anita now has the smile she has always dreamed of.

From full-mouth rejuvenations to single tooth restorations; MACVENEERS™ to crowns, bridges, implants and removables; Macstudio restorations can create A SMILE FOR EVERY STORY™.

**MACSTUDIO**  
BY MICRODENTAL LABORATORIES

**AACD** American Academy  
of Cosmetic Dentistry  
CORPORATE MEMBER



**SMILES MATTER™**  
MicroDental.com/macstudio  
800.229.0936

**MICRODENTAL**  
LABORATORIES