

PREDICTABLE SMILE DESIGN



by Andre Michel, CDT, AACD
Accredited Member (AAACD)
Dana Point, CA
www.andresdentalstudio.com

ABSTRACT

This article describes a ceramic layering technique using both a translucent and high-strength pressable ceramic. Additionally, principles of smile design, case planning, and glamour photography are touched upon; these can be used to increase patient acceptance of what a smile makeover can do for them.

Before the restorative process could begin, the patient received four-quadrant scaling and root planing and was educated on the importance of good daily oral hygiene habits.

PATIENT HISTORY AND CASE OBJECTIVES

The 35-year-old male patient presented with tooth #11 sheared off at the gum line; and #4, #8, and #10 had severe decay. Tooth #3 was missing a previous full-coverage restoration. Before the restorative process could begin, the patient received four-quadrant scaling and root planing and was educated on the importance of good daily oral hygiene habits. It was determined that #11 would receive a buildup on preparation day. The patient's chief complaint was lack of confidence in social situations (Fig 1). There were three objectives to this case: To restore the broken and decayed teeth, brighten the smile, and create restorations that blended seamlessly into the oral environment.

MEETING THE CASE OBJECTIVES

Predictable results for smile design cases begin with a diagnostic wax-up, where function and esthetics can be worked out. A diagnostic wax-up helps plan preparation design, using minimal reductions where possible; and identifies margin placement to achieve the desired result. In this case, the teeth were in good arch form and the gingival architecture was ideal on ##6-11.



Figure 1: Preoperative portrait.

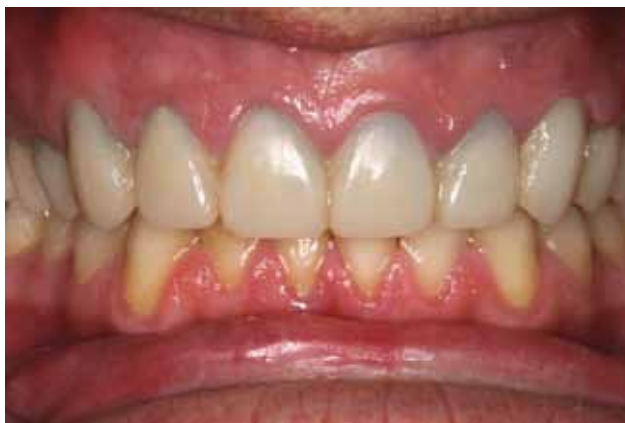

Figure 2: Provisionals.

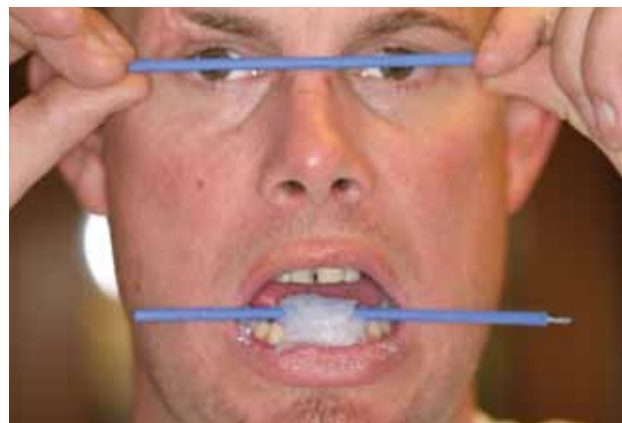

Figure 3: Stick bite.

Crown lengthening was proposed for #4, #5, #12, and #13 to improve the gingival heights in the buccal corridor, but this treatment was not accepted because the patient did not feel it important enough to justify the cost. The wax-up was all additive, there were no rotations or misalignments to correct; it was simply a matter of replacing decay and wear and then fine-tuning the form.

After being prepared, this wax-up was transferred to the patient as a provisional (Fig 2) on preparation day through the use of a silicone putty matrix. The restorative dentist provided a comprehensive labora-

tory prescription that included the goals of the case; detailed shade mapping; desired lengths of centrals, laterals, and cuspids; master impression with good tissue capture; opposing impression; transfer jig; diagnostic wax-up; preoperative impressions; and impression of the patient-approved provisional. Also important were the 12 standard AACD photographs, and the natural smile of the provisional not numb, stick bite in place (Figs 3 & 4). At a follow-up appointment three days later, photographs were taken of the provisionals with a natural smile and a profile shot in repose.


WAXING AND PRESSING

The model and photography of the provisional were reviewed; no changes were necessary. A silicone matrix was created over the model and placed in a pressure vessel at 40 psi (this produces excellent adaptation). This matrix was placed on the master die model and was used as a mold to inject wax on the master model (on which the dies had not been trimmed) (Fig 5). With this technique, the emergence profile and interproximal embrasures can be perfected with all of the soft tissue features in place. The margins were trimmed, and then the occlu-

Prep Shade:

#s All teeth	St. A3
#s	St.
#s	St.

Body Shade A1 _____
 Gingival Shade A2 _____
 Incisal Shade _____
 Occlusal Staining _____



Lengths:

Centrals 10.5 _____ mm
 Laterals _____ mm
 Canines _____ mm

Gingival Recontouring:

Specific changes to be made from provisionals (e.g., midline, lengths, incisal edge position, shapes, occlusion, etc.):
 Please copy provisionals-no changes

Incisal Translucency: Minimal Moderate Maximum
Shade of Translucency: Clear Smoke Frosted Amber
Surface Texture : High Medium Light Smooth
Surface Finish : High Glaze Polished Gloss Satin Low Gloss

Figure 4: Laboratory prescription.

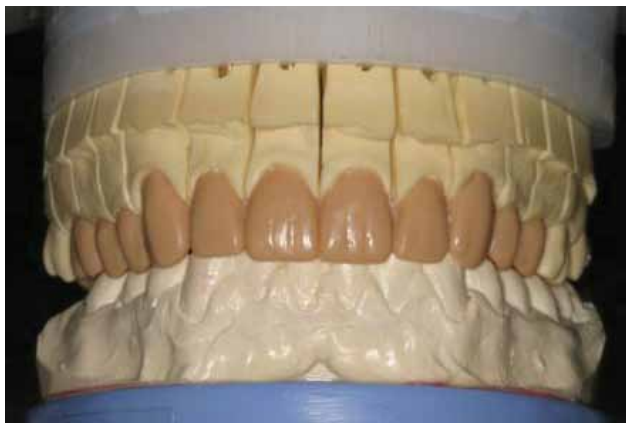

Figure 5: Master die model wax-up with soft tissue features in place.

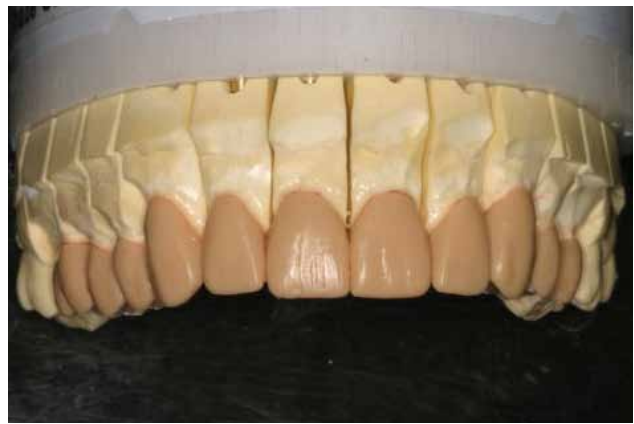

Figure 6: Master die model with dies trimmed.

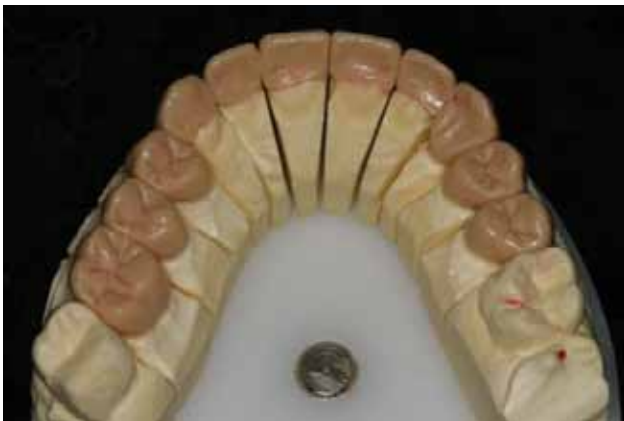

Figure 7: Occlusal view of wax-up.

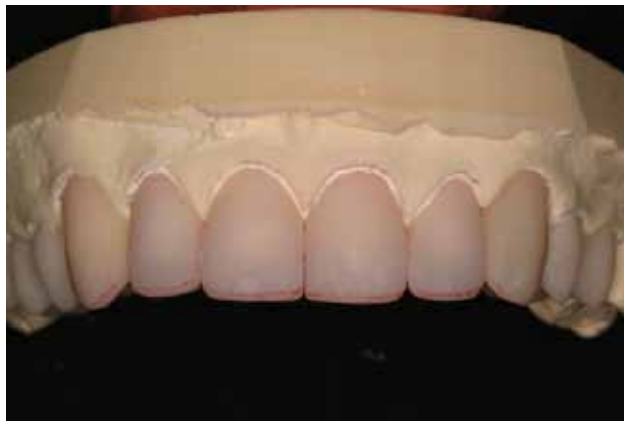

Figure 8: Vertical reduction.

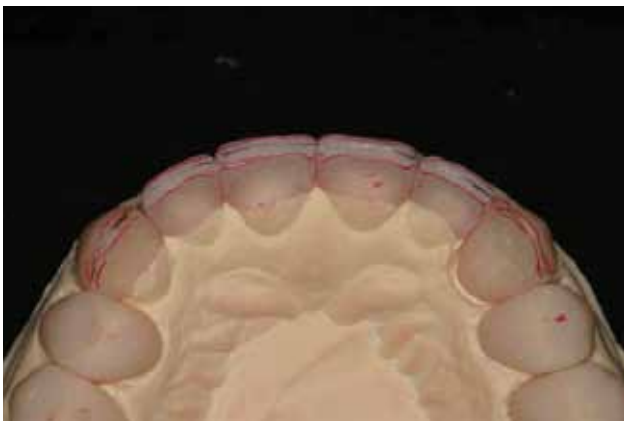


Figure 9: Incisal taper.

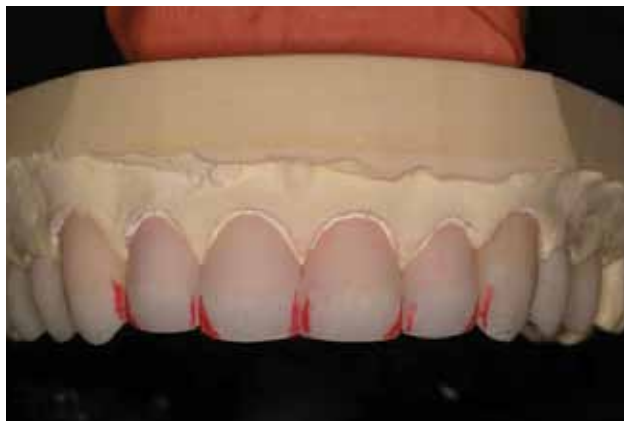

Figure 10: Mesial and distal troughs.

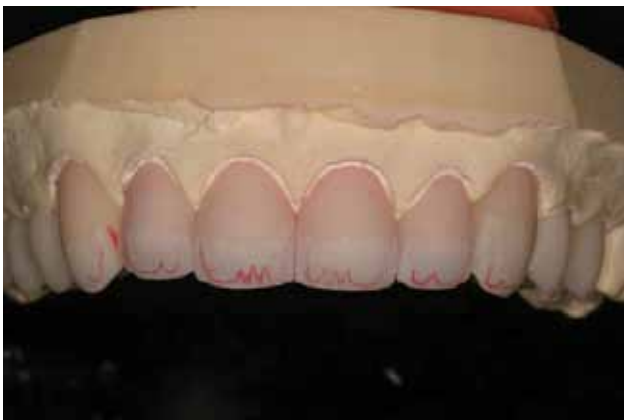

Figure 11: Mammelon structures.

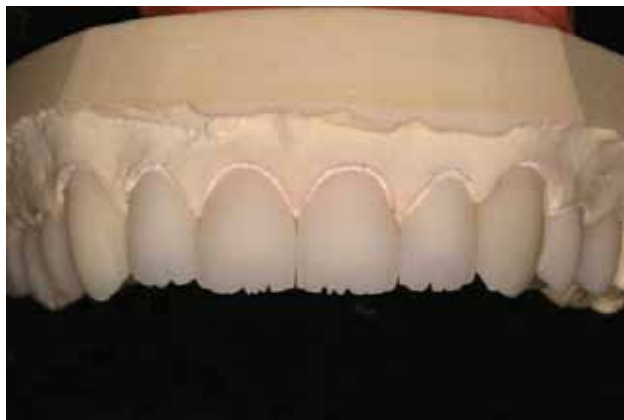

Figure 12: Mammelon structures.

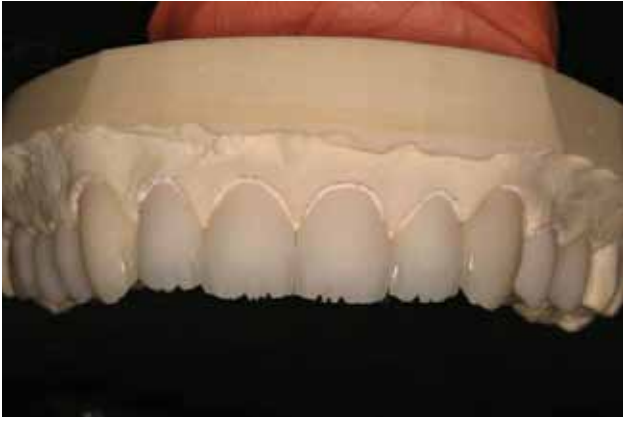

Figure 13: Internal staining.

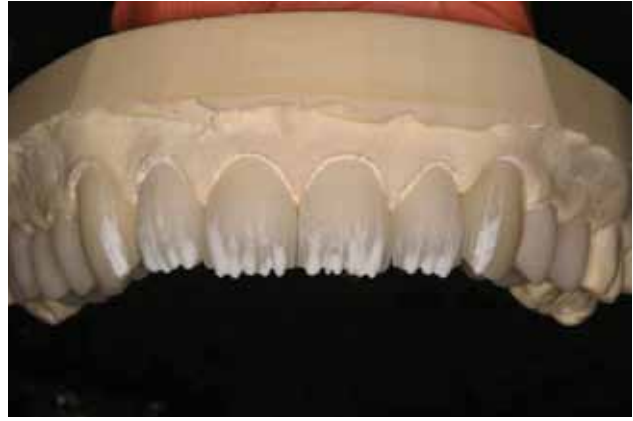

Figure 14: Internal effects powders.

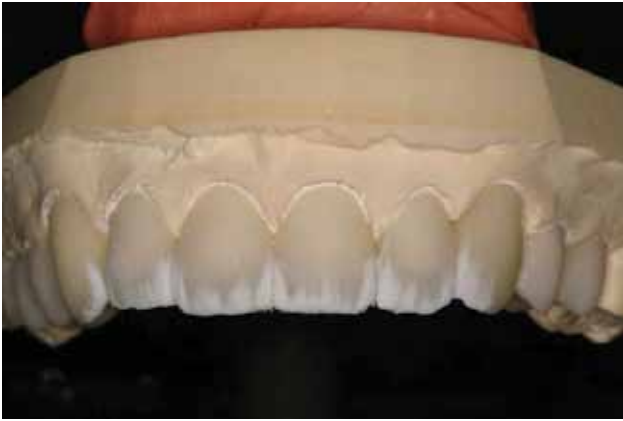

Figure 15: Contrasting opals.

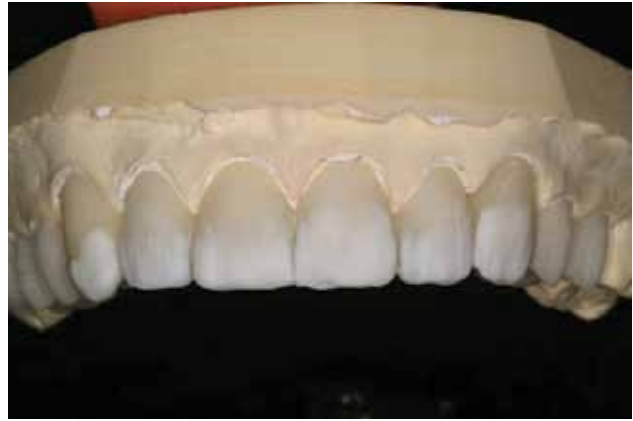

Figure 16: Layered to contour.

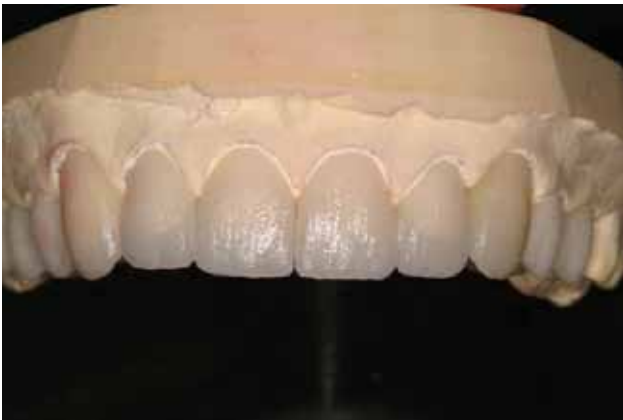

Figure 17: Ready for final contouring.

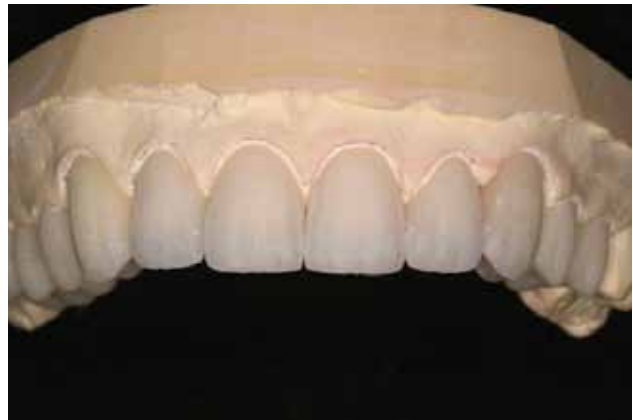

Figure 18: Ready for glazing.

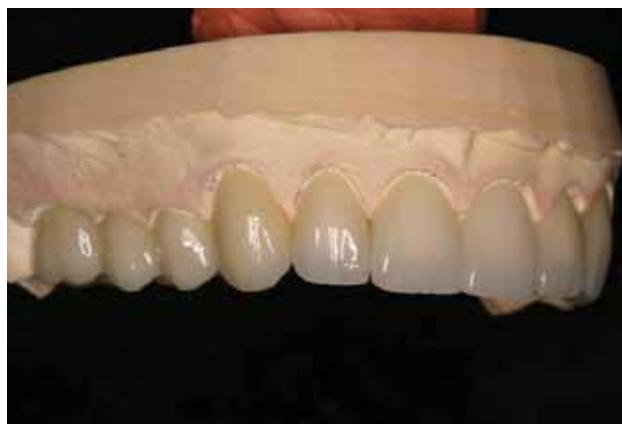

Figure 19: Final glaze and polish.

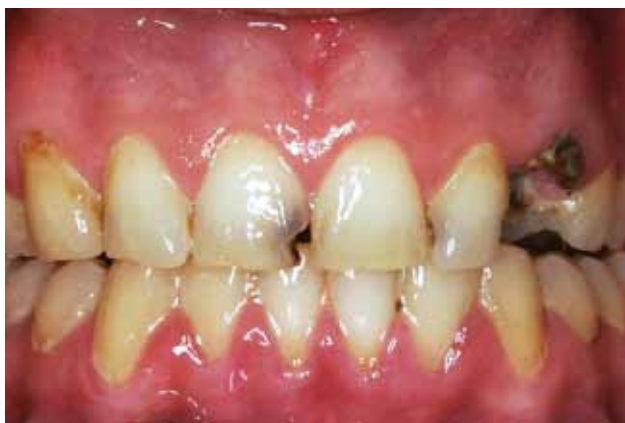

Figure 20: Preoperative view.

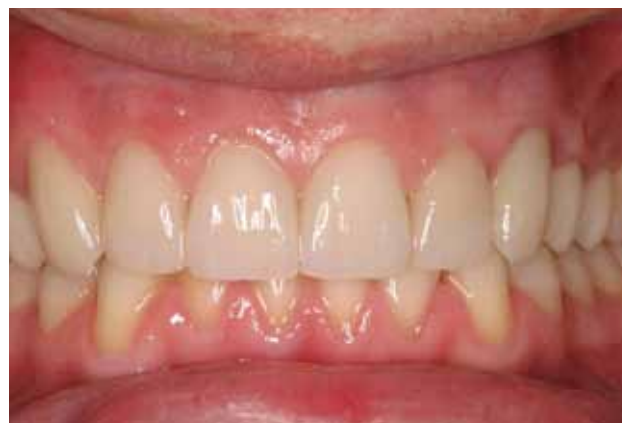

Figure 21: Postoperative view.

sion and esthetics were perfected (Figs 6 & 7).

MATERIALS

The materials chosen for this case were Authentic pressable ceramic (Microstar Dental; Lawrenceville, GA) for anterior ##6-11 and e.Max (Ivoclar Vivadent; Amherst NY) for ##3-5, #12, and #13. Authentic is a translucent material that has a full complement of enamels and effects powders that allow a ceramist to create the "inner life" of a tooth. The ingots are translucent enough to pick up the preparation shade; this allows the restorations to "disappear" in the oral environment.

E.max lithium disilicate is a translucent high-strength pressable ceramic that is well suited for posterior occlusal forces and has a very tooth-like appearance.

CUTBACK

Once the units were devested and fitted, the pressings were measured to see that they matched the lengths of the provisional model. Next, the incisal edge was reduced vertically 0.3 mm on ##7-10 (Fig 8). The perimeter of this area was outlined with a red pencil, and then a thin black line was drawn 0.5 mm from the facial (Fig 9). The incisal edge was then beveled back, gradu-

ally reducing from 0.5 mm to 0.2 mm down to the midfacial of ##6-11. A straight groove in the mesial-incisal edge and a curved groove in the distal-incisal edge were created to hold the low-value porcelain on ##6-11 (Fig 10). Next, the internal lobe formation was created to mimic lobe formations studied from an anonymous central incisor sliced in half (Figs 11 & 12).

STAINING AND EFFECTS POWDERS

A blue stain (Authentic) was placed in the mesial and distal troughs, and a salmon stain (Creation, Jensen Industries; North Haven, CT) was applied to one of the

MICHEL

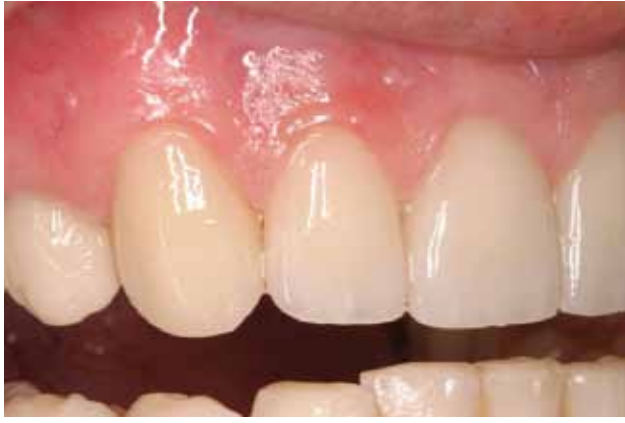

Figure 22: Postoperative view.



Figure 23: Glamour shot.

middle lobes and then fired to set the stain. Effects powders Pearl and Orange Fluorescence (Authentic) were placed over the core lobe details and then fired (Figs 13 & 14). After firing and evaluating the effects, the mesial and distal troughs were filled with Opal 3 and Opal 2 (Authentic) was placed between the lobes, which contrasted well with the effects. After firing, the contrasting Opals were evaluated and then the restorations were brought to full contour using Opal 2, while being careful to place back only what was removed in the cutback (Figs 15 & 16).

FINAL CONTOURS AND GLAZE

The restorations were then shaped, paying close attention to the deflective and reflective zones. The lobe formations and surface

texture were developed. The restorations were then rubber-wheeled (Brasseler USA; Savannah, GA) on the surface. Then the perikymata were developed using a fresh tapered diamond (850.11.016, Brasseler). A thin, even coat of fluorescing glaze (Authentic) was applied and fired. Finally, the restorations were rubber-wheeled and then polished with Diashine diamond paste (VH Technologies; Bellevue, WA) and a felt wheel and chamfered hard 22 mm, to bring up a natural-looking luster (Figs 17-19).

CONCLUSION

Through the use of wax injection and matrices, I was able to maintain the shapes and contours created in the diagnostic wax-up and provi-

sionals all the way through to the final restorations (Figs 20-22).

Finally, after exceeding the patient's expectations it is important to have some professional photographs taken of the finished case and its beautiful results to help with future patient acceptance during case presentation (Fig 23).

Acknowledgment

The author thanks Dr. Jeffery Barrera, who performed the dentistry for the case discussed in this article.

AACD Acknowledgment

The American Academy of Cosmetic Dentistry recognizes Andre Michel as an AACD Accredited Member (AAACD) and a member of the AACD Board of Directors.



the new address of
marketing success

GPM

GOLDEN PROPORTIONS MARKETING

GOLDENPROPORTIONS.COM