

ELIMINATING A GUMMY SMILE WITH SURGICAL LIP REPOSITIONING



by Ziv Simon, D.M.D., M.Sc.; Ari Rosenblatt, D.D.S., D.M.D.; William Dorfman, D.D.S., F.A.A.C.D.

Dr. Simon is a periodontist who completed his specialty training and obtained his Master of Science degree at the University of Toronto. He is a Diplomate of the American Academy of Periodontology, as well as a Fellow of the Royal College of Dentists of Canada. He maintains a practice limited to periodontics, dental implants, and reconstructive surgery in Beverly Hills, California; and taught as a clinical assistant professor at the University of Southern California. Dr. Simon lectures nationally as well as internationally, and was featured on ABC's "Extreme Makeover."

Dr. Rosenblatt is a periodontist who completed his specialty training at Tufts University. He has served on the dental school faculties of Tufts University, UCLA, and the University of Southern California. He is a member of the American Academy of Periodontology, the American Academy of Oral Medicine, the American Dental Association, the Academy of Osseointegration, and the Beverly Hills Academy. Dr. Rosenblatt maintains a practice limited to periodontics, dental implants, and reconstructive surgery in Beverly Hills. Dr. Rosenblatt was the featured periodontist on ABC's "Extreme Makeover."

Dr. Dorfman is a 1983 graduate of University of the Pacific Dental School and has been practicing cosmetic dentistry for more than 23 years in the Beverly Hills area. He is the founder of Discus Dental and publishes and lectures worldwide. As the featured dentist on ABC's "Extreme Makeover," he has helped bring cosmetic dentistry to international recognition. He has recently appeared on numerous other television programs and is the author of the New York Times best-seller Billion Dollar Smile. Dr. Dorfman is the recipient of five lifetime achievement awards from some of dentistry's most noted organizations.

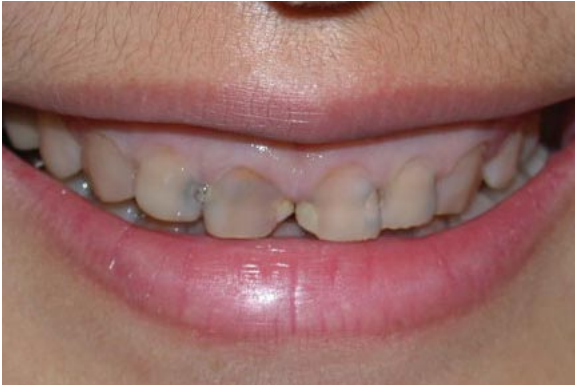

Figure 1: Preoperative smile showing delayed eruption, caries, and tetracycline discoloration.

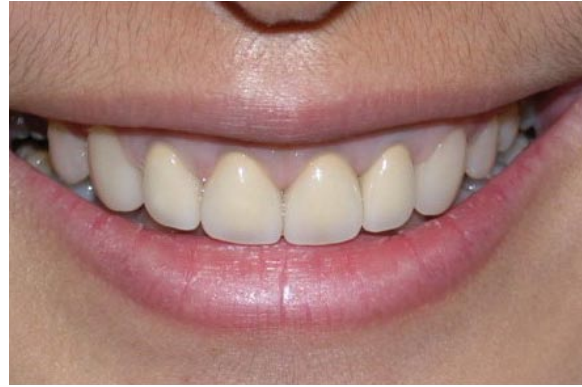

Figure 2: Postoperative smile after an esthetic crown lengthening and restorative treatment.

Dentistry, University of Southern California (USC) School of Dentistry.

ABSTRACT

Excessive gingival display, commonly referred to as a “gummy smile,” can be a source of embarrassment for some patients. Delayed eruption and tooth malpositioning can be predictably treated with resective surgery and orthodontics. In patients with jaw deformities, orthognathic surgery can be performed, but this requires hospitalization and entails significant discomfort. The case presented here describes a surgical technique for lip repositioning to reduce gingival display. The procedure restricts the muscle pull of the elevator lip muscles by shortening the vestibule, thus reducing the gingival display when smiling. In our experience this procedure is safe, predictable with minimal risk or side effects, and is an alternative treatment modality in esthetic treatment.

INTRODUCTION

One objective of restorative dentistry is to create ideal esthetics for the patient’s smile. Advances in dental materials and laboratory techniques have led to excellent mimicry of the natural dentition with crowns, veneers, and composite restorations. However, some patients who present with gingival and skeletal deformities may require more complex esthetic rehabilitation. For these challenging patients, a multidisciplinary approach can be beneficial to enhance the balance and harmony between all three components of the smile: Lips, teeth, and gingivae.

An excessive gingivae-to-lip distance of 4 mm or more is classified as “unattractive” by lay people and general dentists.

Excessive gingival display can be a major cause of patient embar-

rassment. In the so-called “gummy smile,” the gingivae are the dominant feature when compared to the lips and teeth. At least 50% of patients exhibit some form of gingival display in a normal smile.¹ However, exaggerated or forced smile patterns in up to 76% of all patients may exhibit gingivae. In absolute numbers, a normal gingival display between the inferior border of the upper lip and the gingival margin of the anterior central incisors during a “normal” smile is 1-2 mm.² In contrast, an excessive gingivae-to-lip distance of 4 mm or more is classified as “unattractive” by lay people and general dentists.³

FOUR ETIOLOGIES

Excessive gingival display has four possible etiologies. First, it may be a result of delayed eruption in which the gingivae fail to complete the apical migration over the max-

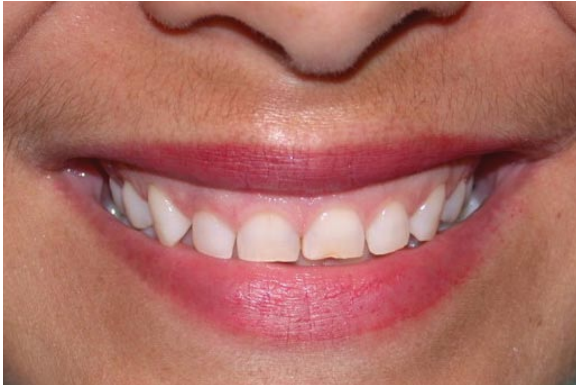

Figure 3: Excessive gingival display due to attrition and compensatory eruption.

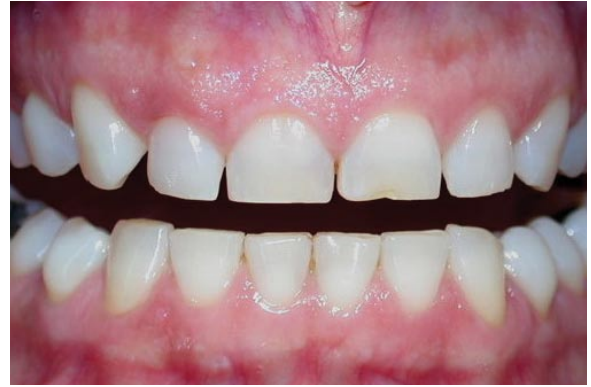

Figure 4: Retracted view, demonstrating signs of attrition and compensatory eruption.

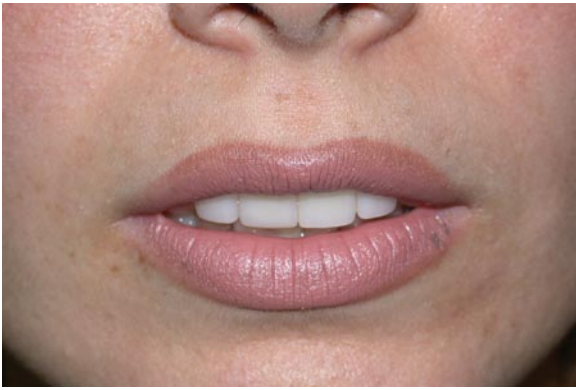

Figure 5: Rest position of a patient with vertical maxillary excess demonstrating "incompetent" lips.
Dentistry, University of Southern California (USC) School of Dentistry.

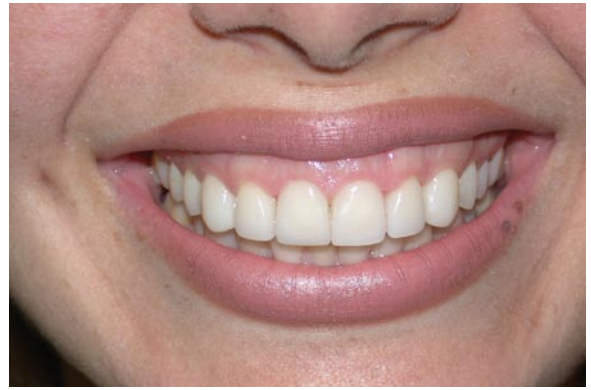

Figure 6: Smile view of a patient with vertical maxillary excess.
Dentistry, University of Southern California (USC) School of Dentistry.

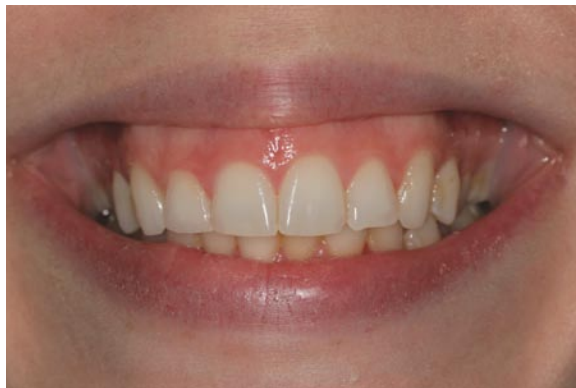

Figure 7: Preoperative smile with excessive gingival display.

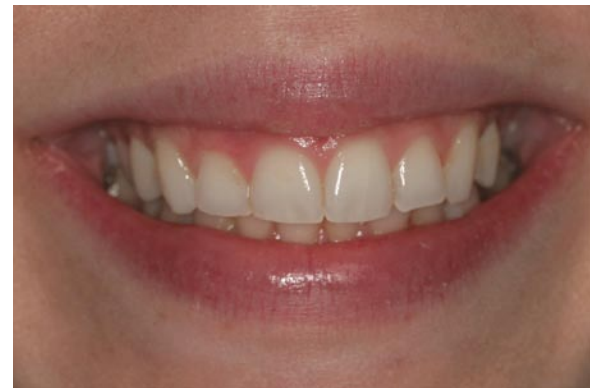

Figure 8: Postoperative smile after three months.

illary teeth to a position that is 1 mm coronal to the cemento-enamel junctions.^{4,5} In these patients, restoring the normal dentogingival relationships can be achieved with an esthetic crown lengthening, which is a well-documented treatment modality that is highly effective in treating patients with delayed eruption.^{6,7} The procedure involves moving the gingival margins apically through soft and possibly hard tissue resection (Figs 1 & 2).

The second possible cause is compensatory eruption of the maxillary teeth with concomitant coronal migration of the attachment apparatus, which includes the gingival margins (Figs 3 & 4). Orthodontic leveling of the gingival margins of the maxillary teeth may be considered in this situation.⁸ Resective surgery is also possible but may expose the narrow root surface and necessitate a restoration.

The third possibility is vertical maxillary excess in which there is an enlarged vertical dimension of the midface and "incompetent" lips (Figs 5 & 6). Treatment involves orthognathic surgery to restore normal inter-jaw relationships and to reduce the gingival display⁹; this involves hospitalization and significant side effects for patients.

Finally, when the patient smiles, if the upper lip moves in an apical direction and exposes the dentition and excessive gingivae, then surgical lip repositioning may be utilized to reduce the labial retraction of the elevator smile muscle and minimize the gingival display. This procedure was first described in the plastic

surgery literature in 1973¹⁰ and was recently published in the dental literature.¹¹

During patient examination, it is important to establish the etiology responsible for the excessive gingival display. A diagnosis of delayed eruption, tooth malpositioning, and excessive skeletal deformities might best be treated by crown lengthening, orthodontics, and/or orthognathic surgery. Lip repositioning is suggested as an additional treatment modality for patients with lip hypermobility exposing undesired gingivae in a smile. The objectives of this article are to present a case in which the surgical technique of "lip repositioning" was used to reduce gingival display, and to suggest the technique's use as an alternative treatment modality.

It is important to establish the etiology responsible for the excessive gingival display.

CASE REPORT

The patient, a healthy 25-year-old female, presented to our private practice with a chief complaint of a "gummy smile" (Fig 7). She wanted a procedure that would reduce the gingival display when she smiled. Her teeth had normal dimensions, and the width-to-height ratio was normal. A diagnosis of moderate vertical maxillary excess was made. An alternate treatment option of orthognathic surgery by an oral and maxillofacial surgeon was discussed with the patient. She preferred a

less invasive procedure to address her chief complaint, and informed consent for a lip repositioning procedure was obtained.

Under local anesthetic (three carpules of Lidocaine [Lidocaine HCl 2%, 1:100,000 epinephrine] and two carpules of Marcaine [Bupivacaine HCl, 1:200,000 epinephrine]), the lip repositioning procedure was performed and is described in the next section.

Immediately after surgery, the patient reported "tightness" of her upper lip when she smiled and mild swelling that subsided after two days. The site healed uneventfully and loose sutures were removed over a period of four weeks. The remaining sutures were left to be resorbed. The patient was pleased with the esthetic outcome. Figure 8 shows the patient at her three-month follow-up. A one-year follow-up photograph (Fig 9) shows stable results.

The procedure limits the retraction of the smile elevator muscles, thus reducing the gingival display shown in a smile.

PROCEDURE

Patients undergoing this procedure should be healthy, with no periodontal disease or apparent pathology. The surgical site is anesthetized with a conventional anesthesia between the first maxillary molars. The local infiltration is administered in the buccal vestibule, with additional infiltration for hemostasis purposes. The incision outline is marked with a sterile pencil on the dried tissues. A partial-thickness incision is made

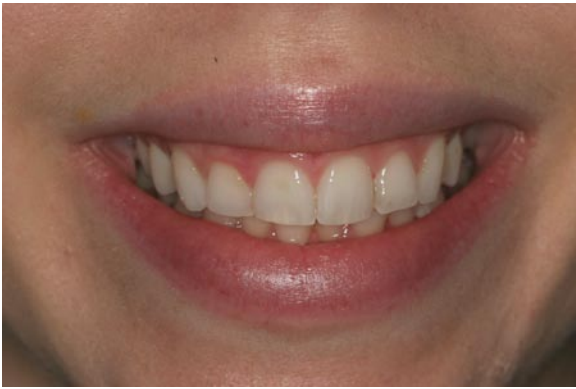

Figure 9: Postoperative smile after one year, displaying stable results.

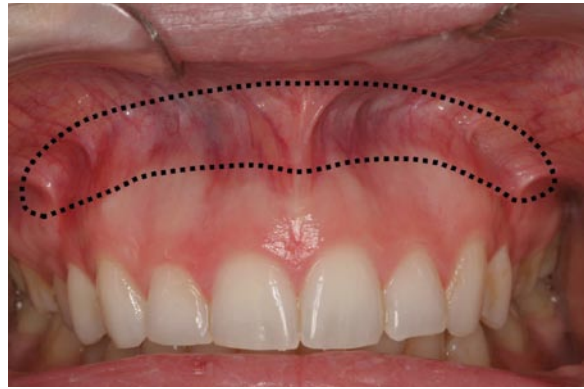


Figure 10: Retracted view with digitally created incision outline.

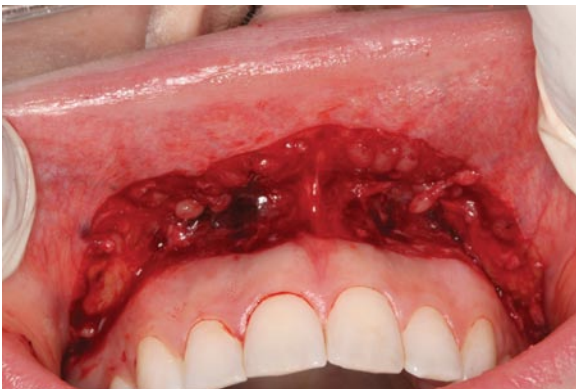

Figure 11: Exposed submucosa after removal of the epithelial discard.

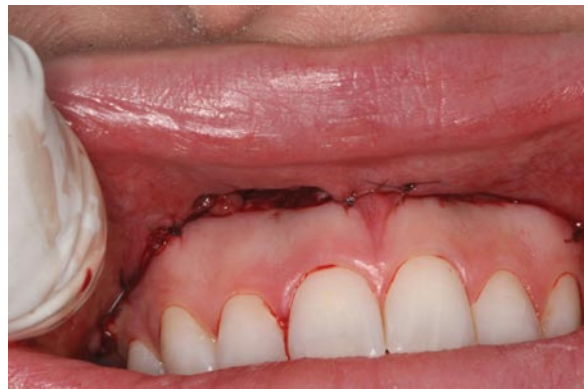

Figure 12: Stabilization sutures in place.

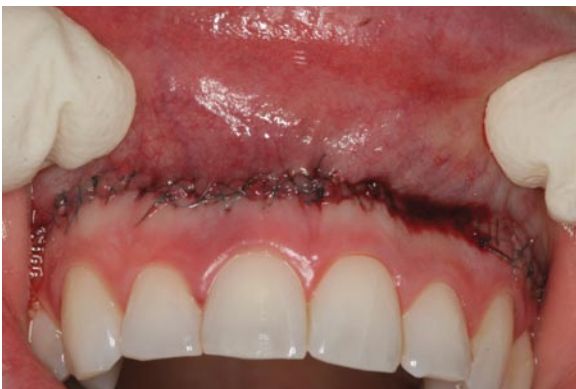

Figure 13: Continuous interlocking suturing.

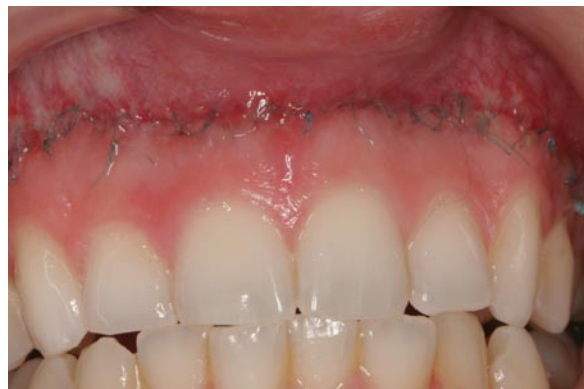

Figure 14: Postoperative retracted view after one week.

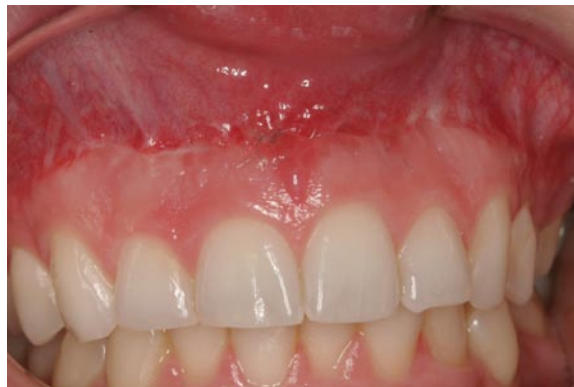

Figure 15: Postoperative retracted view showing scar formation.

along the mucogingival junction. A second parallel incision is made at the labial mucosa at approximately 10-12 mm distance from the first incision. The two incisions are connected at the mesial line angles of the right maxillary first molar and the left maxillary first molar to create an elliptical outline (Fig 10). In the authors' experience, the amount of tissue excision should be double the amount of gingival display that needs to be reduced, with a maximum of 10-12 mm of tissue excision. The epithelium is removed in the incision outline, leaving the underlying submucosa exposed (Fig 11). Bleeding can be controlled by an additional local anesthesia infiltration and the use of electrocoagulation. The two incision lines are approximated with Maxon 6/0 stabilization sutures (United States Surgical, Tyco Healthcare Group; Norwalk, CT) (Fig 12). Care should be taken regarding proper alignment of the midline of the first and second incision lines (lip midline and teeth midline). Once the flaps are stabilized, an additional continuing interlocking suture is used to secure complete closure. Pressure is applied until hemostasis is achieved (Fig 13).

Nonsteroidal anti-inflammatory medications (and occasionally, oral antibiotics) are administered postoperatively. Patients are instructed to use ice compresses for several hours and to minimize lip movement for one week. A one-week uneventful healing pattern is shown in Figure 14.

Postoperative symptoms usually include some mild discomfort for several days and a feeling of "tension" when the patient smiles. Loose sutures are removed over a period of four weeks and the remaining sutures are left to be resorbed on their own. Follow-up examinations should reveal reduced gingival display (Fig 8). After several weeks of healing, a scar formation can be observed (Fig 15). Another patient treated with surgical lip repositioning in conjunction with an esthetic crown lengthening is shown in Figure 16 and Figure 17.

The procedure is safe and has minimal side effects. Reports in the literature¹² and the authors' experience have shown postoperative bruising, discomfort, and swelling of the upper lip to be minimal. The authors have encountered mucocele formation due to severing of the mi-

nor salivary glands in one of their cases. This complication resolved on its own as observed at the four-week follow-up.

Variations in surgical lip repositioning have been reported in the medical literature. Several articles advocate severing the smile muscle attachment to prevent relapse of the smile muscle into its original position¹³⁻¹⁵; this may also minimize the flap tension during suturing.

Surgical lip repositioning ... holds promise as an alternative treatment modality in esthetic rehabilitation.

Patients with minimally attached gingivae may not be ideal candidates for this procedure due to potential difficulties in flap approximation and suturing. Severe skeletal deformities are also contraindications for this procedure, and should ideally be treated with orthognathic surgery.

CONCLUSION

Surgical lip repositioning is an effective procedure to reduce gingival display by positioning the upper lip in a more coronal location. The long-term stability of the results re-




Figure 16: Preoperative smile of a patient with moderate maxillary excess and delayed eruption.



Figure 17: Postoperative smile after a lip repositioning procedure and an esthetic crown lengthening.

Cosmetic dentistry by Dr. William Dorfman.

mains to be seen, but it holds promise as an alternative treatment modality in esthetic rehabilitation.

References

1. Crispin BJ, Watson JE. Margin placement of esthetic veneer crowns. Part I: Anterior tooth visibility. *J Prosthet Dent* 45:278-282, 1981.
2. Vig RG, Brundo GC. The kinetics of anterior tooth display. *J Prosthet Dent* 39: 502-504, 1978.
3. Kokich VO Jr, Kiyak HA, Shapiro PA. Comparing the perception of dentists and lay people to altered dental esthetics. *J Esthet Dent* 11:311-324, 1999.
4. Garguilo A, Wenz F, Orban B. Dimensions and relations at the dentogingival junction in humans. *J Periodontol* 132:261-267, 1961.
5. Maynard JG Jr, Wilson RD. Physiologic dimensions of the periodontium significant to the restorative dentist. *J Periodontol* 50:170-174, 1979.
6. Lee EA. Aesthetic crown lengthening: classification, biologic rationale, and treatment planning considerations. *Pract Proced Aesthet Dent* 16:769-778, 2004.
7. Chu SJ, Karabin S, Mistry S. Short tooth syndrome: diagnosis, etiology, and treatment management. *J Calif Dent Assoc* 32:143-152, 2004.
8. Kokich VG. Esthetics: the orthodontic-periodontic restorative connection. *Semin Orthod* 2:21-30, 1996.
9. Ezquerra F, Berrazueta MJ, Ruiz-Capillas A, Arregui JS. New approach to the gummy smile. *Plast Reconstr Surg* 104:1143-1150; discussion 1151-1152, 1999.
10. Rubinstein AM, Kostianovsky AS. Cirugia estetica de la malformacion de la sonrisa. *Pren Med Argent* 60:952, 1973.
11. Rosenblatt A, Simon Z. Lip Repositioning for Reduction of Excessive Gingival Display: A Clinical Report. *Int J Perio Rest Dent* 26:433-437, 2006.
12. Kamer F. "How do I do it"—Plastic surgery, practical suggestions on facial plastic surgery, smile surgery. *Laryngoscope* 89:1528-1532, 1979.
13. Cachay-Velasquez H. Rhinoplasty and facial expression. *Ann Plast Surg* 28:427-433, 1992.
14. Miskinyar SAC. A new method for correcting a gummy smile. *Plast Reconstr Surg* 72:397-400, 1983.
15. Litton C, Fournier P. Simple surgical correction of the gummy smile. *Plast Reconstr Surg* 63:372-373, 1984. *Ad*



**Place Your Classified Ad With
the AACD!**

Contact Tracy Skenandore @ 800.543.9220 or e-mail: advertising@aacd.com