


Properly Contoured and Tight Contacts in the Maxillary Anterior Dentition


Ingrida Ivance, DDS, AAACD

Abstract

The clinical case documented in this article demonstrates an approach to direct composite veneers with the buildup of proximal contact areas achieved using the individualized matrix technique. Working in a clinical setting, this matrix technique facilitates the accurate buildup of physiological proximal contact areas without overhangs of composite resin in the cervical region and with a close fit at the margins. This technique gives a high degree of reliability and produces controlled, predictable results.

Key Words: Direct composite restoration, tight proximal contacts, conservative, anterior esthetics



 Bonus content!

See the digital edition of the *jCD* for a technique video that demonstrates key concepts in this article.

Introduction

Providing successful direct composite restorations, especially in the esthetic zone, requires several things from the clinician, including a thorough understanding of the dental anatomy as well as the colors and materials involved. One of the main challenges is achieving properly contoured and tight proximal contacts.

Different methods can help the clinician to restore a tight, well-contoured proximal contact surface correctly. Various matrices and techniques such as freehand modeling, use of a silicone index alone or combined with Teflon tape, Mylar pull through, anterior transparent matrix, anterior/posterior metallic matrices, have been described to aid practitioners in obtaining predictable results.¹⁻⁸ More recently, true anatomical matrix systems (e.g., Bioclear, Bioclear Matrix Systems; Tacoma, WA and Uvener, Ultradent; South Jordan, UT) as well as the injectable molding technique and others, bring esthetic restorations within everyone's capability because of their simplicity and versatility, allowing the dentist to capture the final contour and volume of the material used.⁹⁻¹¹

The restoration of a functionally and morphologically correct tooth shape and proximal contact areas allows the formation of harmonious interdental papillae, keeping food from packing between the teeth, and helps stabilize the dental arches through the combined anchorage of all the teeth in positive contact with each other.¹² In the literature, the terms *contact point* and *contact area* have been used interchangeably. Research suggests that between maxillary anterior teeth, proximal contact areas (PCAs) are observed, not contact points.¹³ Contact points appear when contacting surfaces exhibit perfect curvatures and are commonly observed in young patients with newly erupted teeth.¹² The dimensions of anterior PCAs should be taken into consideration when restoring teeth in a clinical setting (Figs 1a & 1b).¹³

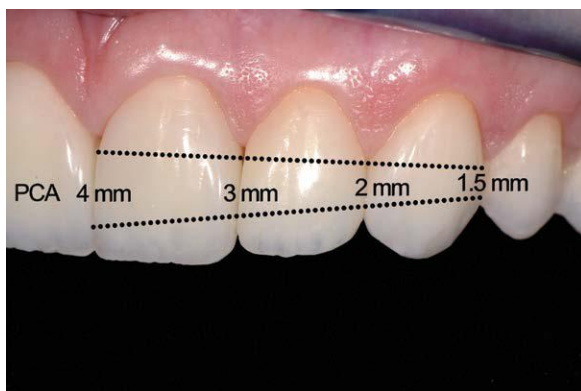


Figure 1a: The 4-3-2-1.5 rule of the PCA. The apicoincisal extent of PCA between the eight maxillary anterior teeth.

The shape of each contact area of maxillary anterior teeth depends on the anatomical shape of the teeth (rectangular, triangular, oval), the type (canines, laterals, central incisors), the surface location (lateral, mesial), and the distance between the teeth (diastemas, crowding, loss of interproximal space due to poor restorations). Due to the number of initial conditions that must be present, it is essential to have a large variety of anatomically preformed matrices at one's disposal. The author uses the technique described below, wherein the matrices can easily be made chairside.⁶

Custom Proximal Contact Area Matrices

The individual shaping and subsequent fitting of the transparent matrix allows for the accurate construction of the specific outline of the proximal contact area.¹⁴ First, the dentin core and the palatal and vestibular surfaces are constructed. This is followed by the construction of the interproximal contacts. If multiple anterior teeth are restored, then the order of restoration of contact areas should be from the canines to the center.

Fabricating a Preformed Contour Matrix

A long, contoured stainless steel strip was used to fabricate a contour matrix. Called the "wave" because of its shape, this device can be made by a dental technician and installed on an accessible corner of dental furniture (Fig 2a). To fabricate a preformed matrix, a transparent strip (Hawe Striproll, Kerr; Orange, CA) with a 10-mm width and 0.05-mm thickness should be pressed on a working surface of the "wave." This is done by first applying pressure to define the contact contour and then by gradually reducing the pressure, completing the formation of the required proximal curvature (Figs 2b & 2c).

The matrix should be less convex for anterior teeth with a rectangular or triangular shape, incisors, mesial surfaces, cases of crowded teeth, or cases with a loss of distance between the teeth due to failing restorations. The matrix should be more

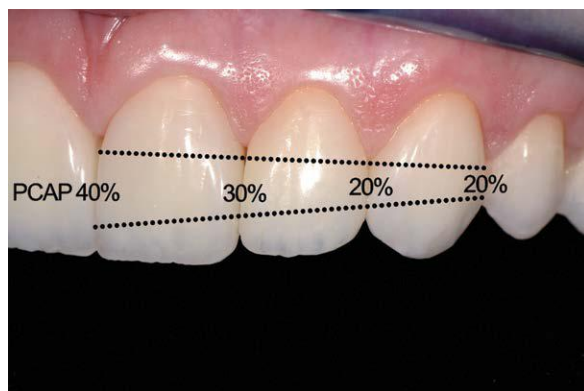

Figure 1b: The proximal contact area proportion (PCAP) refers to the percentage ratio of mesial PCA to individual crown length.


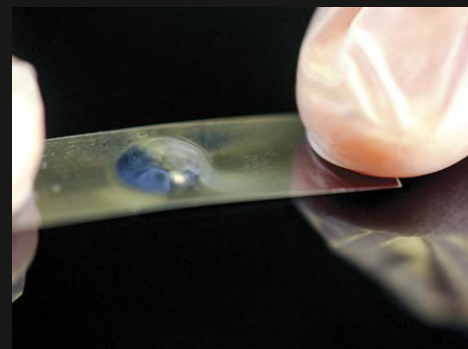


Figure 2a: A wave-shaped chairside device for the fabrication of a preformed contour matrix.



Figures 2b & 2c: The individual shaping and subsequent fitting of the transparent strip allows the accurate construction of the specific outline of the proximal contact area.



Figure 3: Preoperative full-smile view.

convex for oval teeth, canines, distal surfaces, or when closing diastemas. If teeth are longer (e.g., with periodontal pathology), it is advisable to use two overlapping matrices.

The use of thicker matrices is not recommended due to a significant wedging of teeth to obtain tight contacts. The more wedging is done, the more painful the procedure becomes. The use of transparent wedges (Luciwedges Soft, small, or medium, KerrHawe; Bioggio, Switzerland) facilitates visibility in the operation field and allows composite polymerization in approximal surfaces.

Clinical Case Report

History, Evaluation, and Treatment Plan

A healthy 34-year-old female presented to the author's practice at the end of her orthodontic treatment expressing esthetic concerns about her teeth. She wanted a warm, brighter, natural-looking smile to enhance her appearance (Fig 3). She did not want any invasive treatment. In addition to the orthodontic treatment, her dental history included routine fillings and endodontic treatment on tooth #9.

The initial clinical examination included intraoral analysis of preexisting restorations, occlusion, periodontal health, and digital radiography and photography (Figs 4a-4d). Root canal treatment and a core buildup with a fiber post and composite resin for #9, implantation of #3, and laser gingival recontouring for #4, #5, #12, and #13 were planned. Taking into consideration the patient's age, sound tooth structure, and the patient's preference for additive, minimally invasive procedures, direct resin veneers were chosen as the treatment modality for teeth #6-#11. During the final month of orthodontic treatment, the patient was seen several times to emphasize teeth position, especially maxillary, to the orthodontist.

Treatment

Composite: A nanohybrid composite based on a natural layering concept¹⁵ with only two layers (dentin and enamel) to mimic the tooth structure and appearance¹⁶ was chosen to enhance the patient's smile (inspiro direct, Edelweiss DR; Zug, Switzerland) (Fig 5).

Under local anesthesia, the old composite was removed from #9 and the mesial aspect of #8. No preparation was done for teeth #6, #7, #10, and #11. When giving the preparation its final inspection, any unstable or overhanging enamel structures were removed using an extra-fine diamond bur (7803, Shofu Dental; San Marcos, CA), as these overhangs have a negative effect on the adhesive bond of the restoration (Fig 6a). Weak enamel structures left untrimmed at the margins lead to the so-called "prism effect" once composite is applied.¹⁷

Acid-etching and adhesion: The rubber dam was applied from teeth #4 to #13 for better working field isolation¹⁸ and for a full-smile view. A clamp (#212, Hu-Friedy; Chicago, IL) was placed to facilitate access to tooth #9. The prepared #9 was sandblasted with 27- μ aluminum oxide (PrepStart, Danville Materials; San Ramon, CA) to clean the preparation and enhance adhesion.¹⁹

Clear Mylar strips were used in the interproximal areas to confine acid-etching only to the tooth currently being treated.

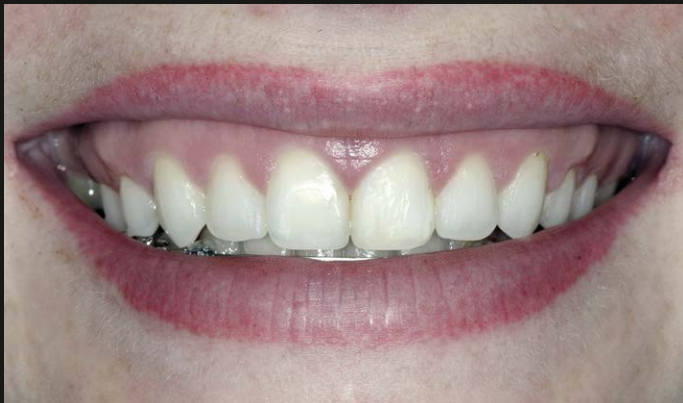
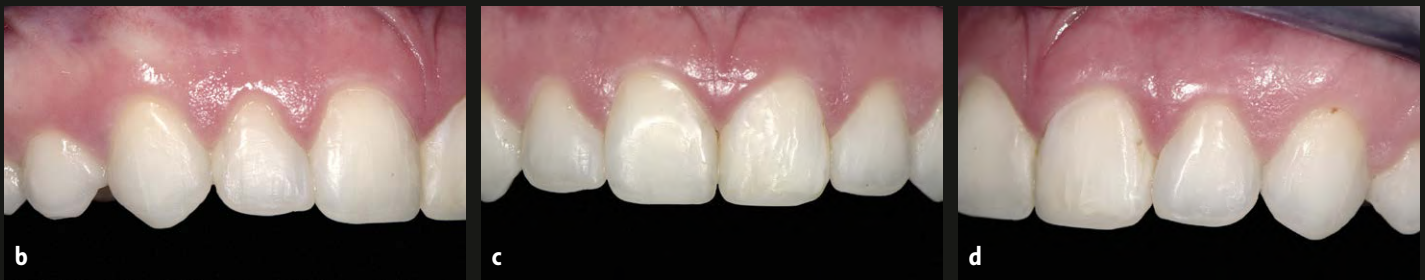
Figure 4a: Preoperative 1:2 smile view: note an excessive gingival display at teeth #4, #5, #12, and #13.



Figures 4b-4d: Preoperative 1:1 close-up images revealing insufficient facial enamel volume, composite restorations interproximally and at the incisal edges, and a medium-sized Class IV defect on #9.

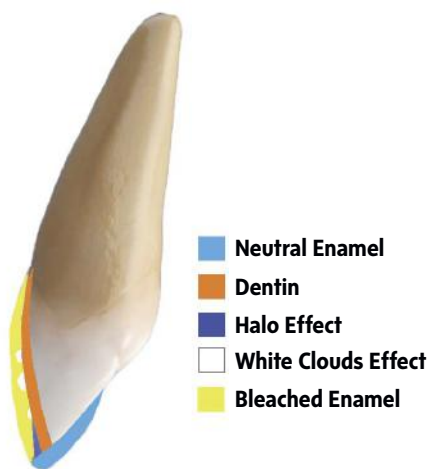


Figure 5: Side view of composite veneer showing color and thickness map.

Acid-etching with 38% phosphoric acid (Etch-Rite, Pulpdent; Watertown, MA) was performed over the enamel for 30 seconds and the dentin for 15 seconds. This was done to remove the smear layer that forms after dentin preparation and to open collagen fibers. Subsequently, adhesive (Adhese Universal, Ivoclar Vivadent; Amherst, NY) was rubbed²⁰ into the enamel and dentin for 20 seconds, air-thinned, and light-cured for 10 seconds.

Composite placement: The lingual shelf enamel wall was modeled freehand using a neutral enamel shade (Skin Neutral, inspiro). This layer replicates the lingual layer of enamel and serves as a foundation upon which subsequent layers are formed (Fig 6b). The dentin shade (Body i1, inspiro) was applied in the cervical middle half of the tooth and extended into the incisal third to start the development of the dentinal lobes. The string-like projections of the mamelons were brought toward the halo area to complete mamelon creation.² The layer was light-cured for 20 seconds (Fig 6c).

An artist's brush (#1, Cosmedent; Chicago, IL) was used to apply a little halo effect tint (Effect Shade Azur, inspiro) in be-

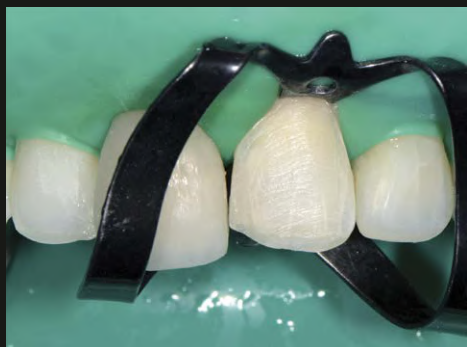

Figure 6a: Prepared surfaces of #9. Any unstable or overhanging enamel structures were removed.

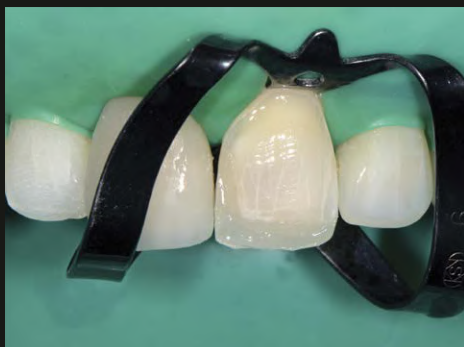

Figure 6b: The palatal thin enamel wall was modeled freehand using a semitranslucent enamel shade.

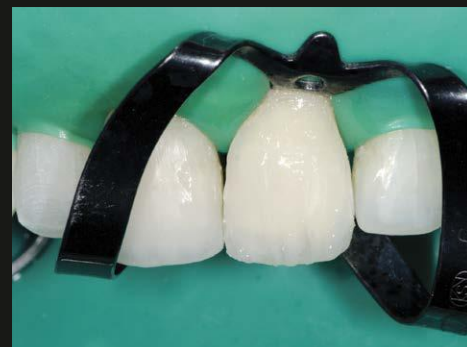

Figure 6c: View showing the extent of the completed dentin core and the effect tints. Space has been left for the facial enamel mass.

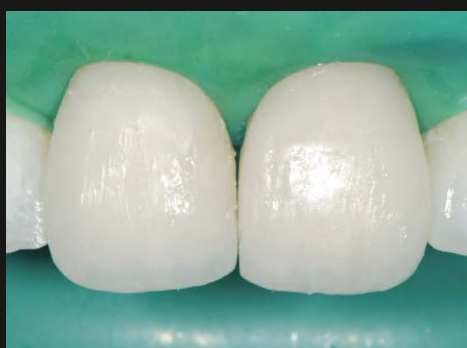

Figure 6d: View of the completed essential stages of restoration. Space has been left for the contact enamel mass.

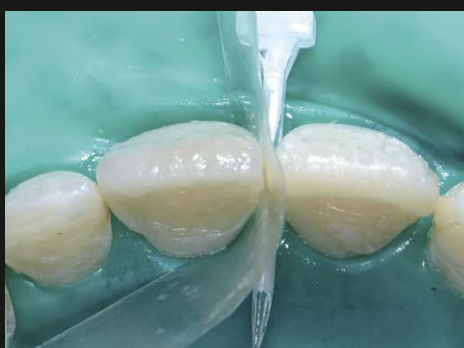

Figure 7: The two contact surfaces were separated using a wedge and transparent matrix.

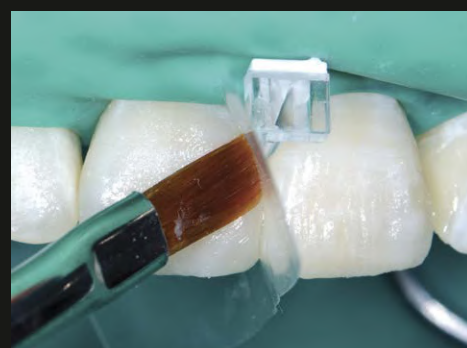

Figure 8: The semitranslucent enamel mass applied against the shaped matrix in a layer 0.5 mm thick.

tween the mamelons to achieve an opalescent incisal effect. A white tint (Effect Shade Ice, inspiro) spread into “clouds”¹ over the labial surface of the dentin created diffused white areas and elevated the value of the tooth (Figs 5, 6c).

A final enamel layer of bleached enamel shade (Skin Bleach, inspiro) was applied to cover the facial aspect of the tooth. The final layer should be about 10% over contoured. During finishing, this layer is removed to reach ideal volume and contour.² All layers were light-cured for 20 seconds (Fig 6d).

The completion of the essential stages of restoration was followed by the construction of mesial and distal contacts.

Matrix placement and composite application: The preformed individual matrix was placed in the subgingival area between the rubber dam and the surface of the tooth. The teeth were separated by positioning the interdental wedge so that the cervical part of the strip did not move during the formation of the contact area. It is critical to carefully adapt the matrix in the cervical region, especially from the palatal side. This ensures the close fit of the composite resin at the margins without overhangs and decreases finishing procedures (Fig 7).

One of the benefits of the transparent strip is the absence of an oxygen inhibition layer at the interface with the gingival tissue. The composite cured against a Mylar strip leaves a highly polished surface,²¹ eliminating the need to use rotary instruments below the free gingival margin for finishing.

Acid-etching was performed, and the surface was rinsed and air-dried. The adhesive was applied and air-thinned. The surface was light-cured for 20 seconds. Self-etch adhesives also can be employed in this step. Transparent, neutral, or another shade of composite corresponding to the opacity of the enamel surface can be used. Stiff composites are contraindicated due to the resistance they may impart in this technique. To reduce viscosity, increase flowability, and improve physical and mechanical properties, composite preheating using composite warmers has been suggested.²² In this case, neutral enamel shade (inspiro Skin Neutral) was used.

The composite was distributed along the contact surface with a thin spatula (IPCT, Cosmedent). An artist’s brush (#3, Cosmedent) helped to adapt and smooth the composite (Fig 8). Modeling liquid (Composite Wetting Resin, Ultradent; South

“

It is critical to carefully adapt the matrix in the cervical region, especially from the palatal side. This ensures the close fit of the composite resin at the margins without overhangs and decreases finishing procedures.”

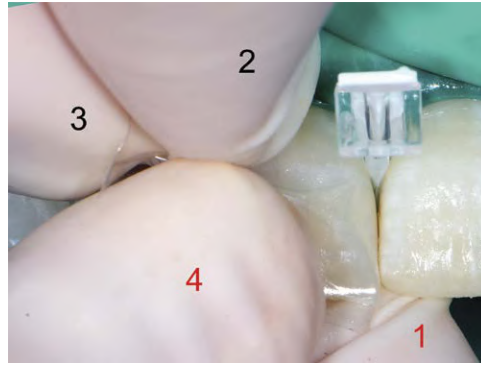


Figure 9a: The sequence and combination of fingers during the contact modelling of the mesial contact of #8: 1, right index; 2, left index; 3, left thumb; 4, right thumb.

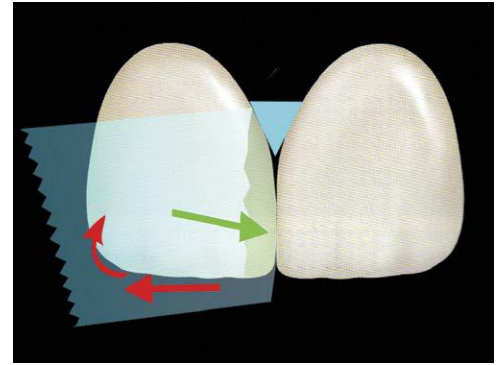


Figure 9b: Tightly holding the matrix in the cervical area (fingers 1-3), stretch it downward and mesially until the matrix contact with the neighboring surface reaches the required height of the contact area (green arrow). Form a fold using finger 4 (red arrows). The part of the matrix located below the fold forms the corner of the incisal edge.

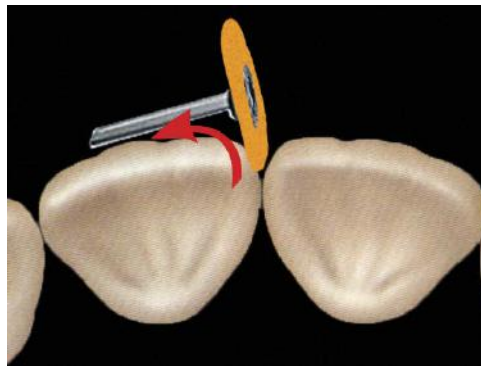


Figure 10a: Work on each transition line.

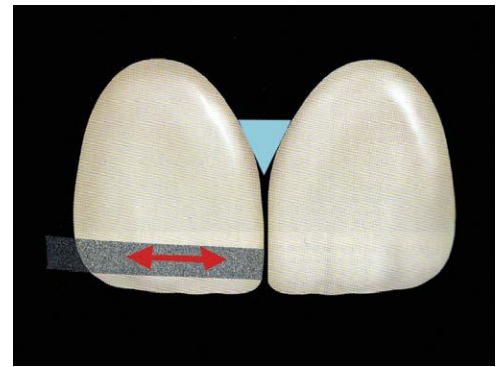


Figure 10b: The glossy layer is removed from the contact surface with diamond strips of different abrasive grades.

Jordan, UT) was used carefully to give the brush an optimal moisture and consistency that prevents composite from sticking to it and maintains the bristles' uniformity.¹ These instruments enable modeling in narrow spaces and even penetrating them from side to side.

The composite was pushed under the matrix from the vestibular side until it appeared on the palatal surface. It is necessary to keep condensing until there is excess material showing on the palatal side. If needed, an additional increment of composite can be placed from the palatal side. The composite was then rubbed to the surface along the cervix, toward the contact surface, and along the corner of the incisal edge.

Contact surface modeling: The palatal part of the matrix was pulled down slightly and fixed, and the vestibular part of the matrix was stretched downward and mesially until the matrix contact

with the neighboring surface reached the required height of the contact area. Once the matrix was stretched, the composite shifted from the interdental wedge toward the incisal edge. A fold was formed along the vestibular surface at the same time a contact area was being established. Due to fold formation, the part of the matrix located below the fold formed the corner of the incisal edge. In this process, the excess composite shifts below the incisal edge (Figs 9a & 9b).

The achieved result of the contact surface formation is fixed by polymerization for 10 seconds per vestibular and palatal sides.

Tip: When performing contact surface modeling, the clinician is best positioned by pulling the matrix toward himself or herself. The sequence and combination of fingers during the contact modelling of the mesial contact of #9 would be:

1, left index; 2, right index; 3, right thumb; 4, left thumb. The clinician would be on the patient's left side.

Removing the excess and modeling a corner: An extra-coarse disc (Sof-Lex, 3M; St. Paul, MN [or finishing bur 806 314 250 016, Acurata; Thurmansbang, Germany]) was used to remove the composite excess at the transition of the contact surface into the palatal and vestibular surfaces. It also was used at the fold along the vestibular surface and at the corner of the incisal edge (Fig 10a).

The composite excess at the incisal corner was removed with the above-mentioned disc/finishing bur. The interdental wedge must be inserted beforehand to protect the neighboring surface. Then, the glossy layer was also removed from the contact surface with fine and super-fine diamond strips (Brasseler; Savannah, GA) (Fig 10b). The smoothness of the contact surfaces was checked with dental floss.

Tip: After one interproximal wall and incisal angle is done, the protocol is repeated for the neighboring tooth. When working on the middle line between #8 and #9, it is recommended to begin restoring contact from the tooth that appears narrower.

Contouring, finishing, and polishing: After an initial evaluation of the primary anatomy, a Sof-Lex extra-coarse composite polishing disc and red-striped, flame-shaped fine and yellow-striped, flame-shaped extra-fine diamonds (8859-010 and 859EF-010, Brasseler) were used to remove excess material, recontour, and establish outline forms and the facial planes. Facial surfaces of the restoration were obtained respecting the transitions and inclinations between the cervical, middle, and incisal thirds, along with the transitional line angles. Contouring of the mesial proximal transitional surfaces should be completed meticulously prior to adjusting the distal surface.²³

The flame-shaped burs in a red slow-speed contra-angle handpiece were worked along the axis of the teeth from mesial to distal to create the macro texture details and form perikymata on the surfaces (Figs 11a & 11b). Excess material on the palatal sides was removed using a football-shaped fine diamond (806 314 277 023, Acurata).

The central incisors were checked with a digital caliper (Dentagauge, Erskine Oral Care; Macksville, NSW, Australia) to verify symmetrical mesiodistal widths. The proximal surfaces were polished with finishing strips of different abrasive grades (Edenta AG; St. Gallen, Switzerland; and Sof-Lex Finishing Strips Coarse Medium).

The interproximal zone was inspected using unwaxed dental floss to verify adequate contact and the absence of resin composite tags or gingival overhangs.¹¹ The proximal contact area should not be left rough or it will cause plaque accumulation.²⁴ The contact between #8 and #9 was measured through the sounding of the most coronal interproximal bone level, which was at 4 mm, to ensure

Tips

Beginner

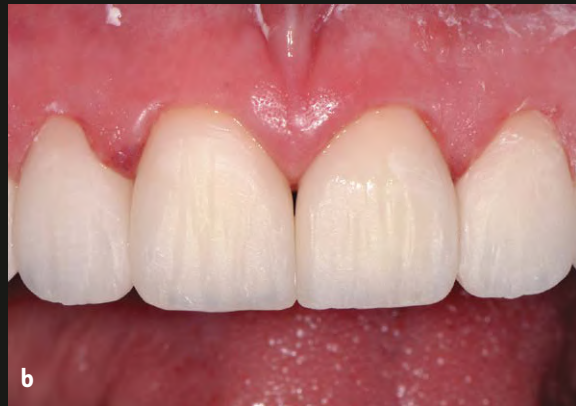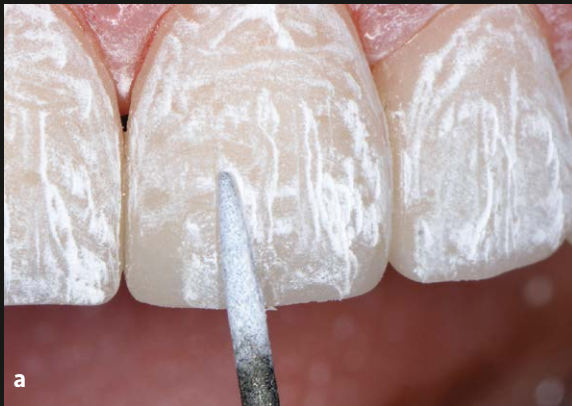- Undetectable integration of composite resin with natural tooth structure requires the use of correct composite materials, as well as the application of a consistent protocol.
- Take a comprehensive hands-on workshop course to gain more in-depth knowledge of the composite restorations.

Intermediate

- Perfect your technique on the model first.
- The best position for the clinician is when the matrix is pulled toward them.
- Stiff composites are contraindicated due to the resistance they may impart in this technique.
- When working on the middle line between #8 and #9, begin restoring contact from the tooth that appears narrower.
- The technique is executed with the help of a dental assistant. After the doctor finishes modeling, the assistant cures the composite.
- Use the red slow-speed contra-angle hand piece for finishing and macro texture of the surface.

Advanced

- Paying careful attention to every detail makes up the essential beauty of the work.



Figures 11a & 11b: The flame-shaped burs were worked along the axis of the teeth to create the macro texture details and produce perikymata on the surfaces.

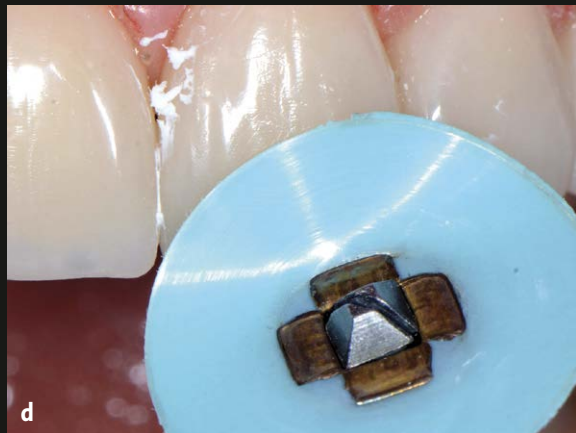
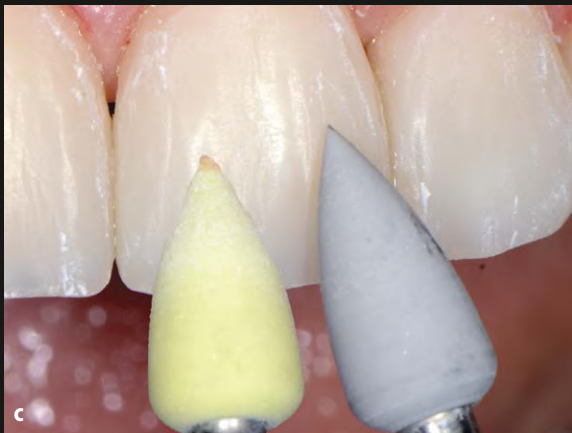
Figure 11c: Polishing with yellow and gray polishing points.

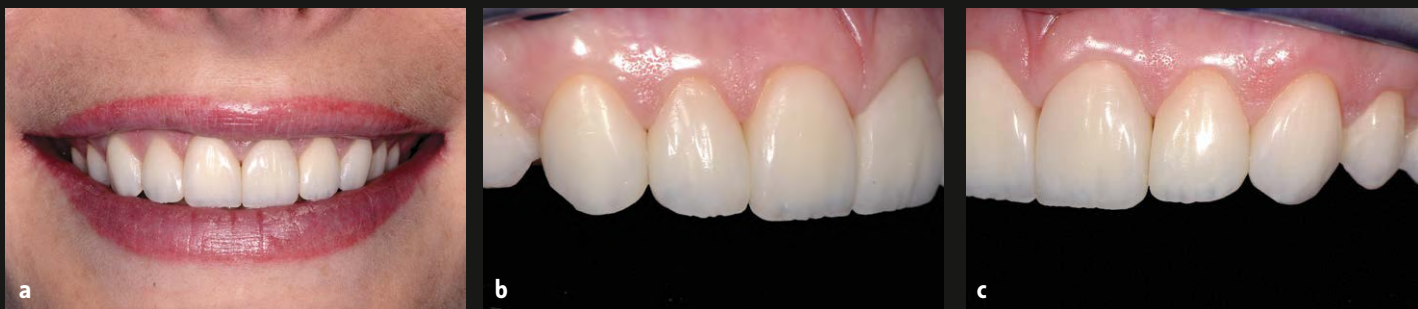Figure 11d: The final gloss was accomplished by applying polishing paste with a felt wheel.

that the open gingival embrasure would close over time.²⁵ Facial and palatal surfaces were modeled with ultra-fine diamonds (T&F Hybrid Points LT2, 7406, Shofu Dental; San Marcos, CA).

Proper lingual contours were designed by simulating functional postures and movements. Evaluating dynamic relationships in the clinical setting requires an approach that more closely mimics the outside/in functional pathways.²⁶ Using this method, static and dynamic occlusions were checked with 200-, 20-, and 8- μ articulating papers (Bausch; Nashua, NH). In the upright position, the incisors should allow 8- μ shimstock to slide through when the teeth are in maximum intercuspation.²⁶

If the lingual contours are not appropriately developed, unfavorable consequences can occur, including chipped restorations, sore muscles and joints, tooth mobility, cement fatigue, and attrition.²⁷ All surfaces were polished using yellow and gray polishing points (Identoflex Composite Polishers, Kerr) and Flexidiscs (Cosmedent) (Fig 11c). Labial surface texture is determined by how long the yellow point is applied and by the amount of pressure used.

Before the final polishing, the restorations were covered with a water-soluble glycerin gel to prevent the oxygen-inhibited layer (Liquid Strip, Ivoclar Vivadent). Final polymerization was then carried out with 20-second cycles on the palatal and facial



Figures 12a-12c: Postoperative anterior images. The precise contact areas of required height and tightness allow the formation of interdental papillae, keeping food from packing between the teeth.

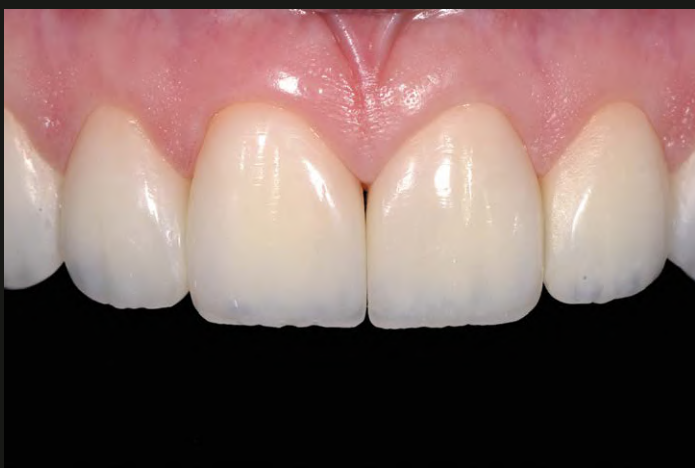

Figure 12d: Postoperative retracted close-up view. The width of the central incisors appears symmetrical.



Figure 12e: Postoperative full-smile portrait view of the very satisfied patient.

sides to obtain the maximum monomer conversion in the uppermost layer of composite material, normally inhibited by oxygen.²⁸ Prior to polishing, the glycerin was rinsed off; the result was a harder composite surface that was easier to finish.²⁹ The final gloss was obtained by polishing surfaces with a Flexibuff disc and Enamelize paste (Cosmedent) (Fig 11d).

The patient was given home care instructions and scheduled to return three days later for a final check of function and esthetics, and to complete photographic documentation (Figs 12a-12e). During this appointment, the patient was encouraged to return for maintenance procedures, such as refinishing and/or repolishing surface roughness, slight marginal defects, and slight marginal discoloration, as these will lengthen the lifespan of the restorations.^{31,32}

Summary

Achieving physiologically tight contacts is a significant challenge when restoring anterior teeth. The individualized matrix technique offers a method to accurately produce controlled functional, esthetic, and long-lasting outcomes.

Acknowledgments

The author is grateful to Dr. Serhiy Radlinsky (Poltava, Ukraine), Dr. Didier Dietchi (Geneva, Switzerland), and Dr. Newton Fahl (Curitiba, Brazil) for their inspiration and mentorship in direct composite restorations.

References

1. Manauta J, Salat A. *Layers: an atlas of composite resin stratification*. Milan: Quintessence Pub.; 2017. p. 114-6.
2. Fahl N. Step-by-step approaches for anterior direct restorative challenges: mastering composite artistry to create anterior masterpieces—part 2. *J Cosmetic Dent*. 2011 Winter;26(4):42-55.
3. LeSage B, Milnar F, Wohlberg J. Achieving the epitome of composite art: creating natural tooth esthetics, texture, and anatomy using appropriate preparation and layering techniques. *J Cosmetic Dent*. 2008 Fall;24(3):132-41.
4. Denehy G. Simplifying the Class IV lingual matrix. *J Esthet Dent*. 2005 Sep;17(5):312-9.
5. Meiser HP. Case report: the margin perfect matrix – a predictable technique for the fabrication of direct composite veneers. *Oral Health*. Available from: <https://www.oralhealthgroup.com/features/case-report-margin-perfect-matrix-predictable-technique-fabrication-direct-composite-veneers/>
6. Radlinsky S. Restoration of proximal contact areas in the maxillary anterior dentition. 2008. Russian. Available from: [DentArt. http://dentart.org/?p=558](http://dentart.org/?p=558).
7. Lazar D. Class IV restoration with Unica anterior. Available from: <https://www.styleitaliano.org/class-iv-restoration-with-unica-anterior/>
8. Manauta J. Synchro matrix. Available from: <https://www.styleitaliano.org/synchro-matrix/>
9. Clark D. Advanced techniques for diastema closure: a microscopic perspective. *Contemp Esthet*. 2007 Sep;36-41. Available from: <https://www.endoexperience.com/documents/ContempEsthetBioclearDiast.pdf>
10. Lowe RA. Uvener: simplifying artistic direct composite veneering. *Dent Today*. May 2015:1-5. Available from: <https://www.dentistrytoday.com/k2/item/803-uvener-simplifying-artistic-direct-composite-veneering>
11. Terry DA. *Restoring with flowables*. Hanover Park (IL): Quintessence Pub.; 2017. p. 65-67.
12. Nelson SJ. *Wheeler's dental anatomy, physiology, and occlusion*. 10th ed. New York: Elsevier; 2014. p. 102-27.
13. Stappert CF, Tarnow DP, Tan JH, Chu SJ. Proximal contact areas of the maxillary anterior dentition. *Int J Periodontics Restorative Dent*. 2010 Oct;30(5):471-7.
14. Ness JC. *Anterior anatomy and the science of a natural smile*. Morgan Hill (CA): Productivity Training Corp; 2011-2015. p. 96-101.
15. Dietschi D. Optimising aesthetics and facilitating clinical application of free-hand bonding using the 'natural layering concept'. *Br Dent J*. 2008 Feb 23;204(4):181-5.
16. Inspiro product brochure. Available from: <https://edelweissdr.com>
17. Hugo B. *Esthetics with resin composite: basics and techniques*. Berlin: Quintessence Pub.; 2008. p. 19-20.
18. Heintze SD, Rousson V, Hickel R. Clinical effectiveness of direct anterior restorations—a meta-analysis. *Dent Mater*. 2015 May;31(5):481-95.
19. Mujdeci A, Gokay O. The effect of airborne-particle abrasion on the shear bond strength of four restorative materials to enamel and dentin. *J Prosthet Dent*. 2004 Sep;92(3):245-9.
20. Zander-Grande C, Ferreira SQ, da Costa TR, Loguercio AD, Reis A. Application of etch-and-rinse adhesives on dry and rewet dentin under rubbing action: a 24-month clinical evaluation. *J Am Dent Assoc*. 2011 Jul;142(7):828-35.
21. Yazici AR, Tuncer D, Antonson S, Onen A, Kilinc E. Effects of delayed finishing/polishing on surface roughness, hardness and gloss of tooth-coloured restorative materials. *Eur J Dent*. 2010 Jan;4(1):50-6.
22. Lucey S, Lynch CD, Ray NJ, Burke FM, Hannigan A. Effect of pre-heating on the viscosity and microhardness of a resin composite. *J Oral Rehabil*. 2010 Apr;37(4):278-82.
23. Kataoka S, Nishimura Y, Sadan A. *Nature's morphology: an atlas of tooth shape and form*. Hanover Park (IL): Quintessence Pub.; 2002. p. 59-65.
24. Ichimaru T, Saito S, Matsuzaki A, Ando Y, Furukawa K. [Plaque accumulation (S. mutans) in various dental restorative materials and fluoro-resins (in vitro)]. *Shika Zairyo Kikai*. 1989 May;8(3):337-48.
25. Tarnow DP, Magner AW, Fletcher P. The effect of the distance from the contact point to the crest of bone on the presence or absence of the interproximal dental papilla. *J Periodontol*. 1992 Dec;63(12):995-6.
26. M. Bakeman EM, Kojs J. The myth of anterior guidance. 10 steps in designing proper clearance for functional pathways. *J Cosmetic Dent*. 2012 Fall;28(3):56-62.
27. Dawson PE. *Evaluation, diagnosis, and treatment of occlusal problems*. 2nd ed. St Louis: Mosby; 1989. p. 2-32.
28. Gauthier MA, Stangel I, Ellis TH, Zhu XX. Oxygen inhibition in dental resins. *J Dent Res*. 2005 Aug;84(8):725-9.

29. Park HH, Lee IB. Effect of glycerin on the surface hardness of composites after curing. *J Korean Acad Conserv Dent*. 2011 Nov;36(6):483-9.
30. Fernández E, Martín J, Vildósola P, Oliveira Junior OB, Gordan V, Mjor I, Bersezio C, Estay J, de Andrade MF, Moncada G. Can repair increase the longevity of composite resins? Results of a 10-year clinical trial. *J Dent*. 2015 Feb;43(2):279-86.
31. Hickel R, Brühaver K, Ilie N. Repair of restorations—criteria for decision making and clinical recommendations. *Dent Mater*. 2013 Jan;29(1):28-50.
32. Peumans M. Clinical performance of direct and indirect adhesive restorations: longitudinal medium- to long-term results. *J Cosmetic Dent*. 2015 Spring;31(1):110-27. **JCD**



Dr. Ivance is an AACD Accredited member. She practices in Vilnius, Lithuania.

Disclosure: The author did not report any disclosures.

“
Evaluating dynamic relationships in the clinical setting requires an approach that more closely mimics the outside/in functional pathways.”

