

jcd

Journal of Cosmetic Dentistry

vol. 26 issue 3

Journal of Cosmetic Dentistry

Direct Esthetic Challenges Solved
Learn from Fahl and Vanini
NEW! Earn CE

FALL 2010

AACD American Academy
of Cosmetic Dentistry

ZOOM

DASH!

POW

THE DYNAMIC DUO OF IN-OFFICE WHITENING!

Premium light-activated

ZOOM!

- speed of light activation for maximum results
- new kit makes procedure easier, faster, safer
- average of 8 shades in one office visit
- take home maintenance included



Affordable non-light-activated

dash

- speed of an immediate in-office solution
- quickness and ease of an all-inclusive kit
- no mixing, no refrigeration
- economical option for patients on a budget



**GIVING YOUR PATIENTS OPTIONS
MAKES YOU A HERO!**

Call today:
(800) 422-9448
or visit discusdental.com

©2010 Discus Dental, LLC. All rights reserved.
For use by a dental professional only.

jcd

vol. 26 issue 3
Journal of Cosmetic Dentistry

A PUBLICATION OF THE
AMERICAN ACADEMY OF COSMETIC DENTISTRY

CHIEF EXECUTIVE OFFICER

Ed Simeone

EDITOR

Edward Lowe, DMD, AAACD, Vancouver, BC, Canada

MANAGING EDITOR

Tracy Skenandore, tracys@aacd.com

PUBLICATIONS ASSISTANT

Denise Sheriff, denises@aacd.com

ART DIRECTOR

Lynnette Rogers, lynnetter@aacd.com

EDITORIAL CONSULTANT

Juliette Kurtz, publications@aacd.com

MANUSCRIPT

DEVELOPMENT LIAISON

Allison DiMatteo, MPS, adimatteo720@centrainy.twcbc.com

MEMBERSHIP

AND MARKETING DIRECTOR

Michael DiFrisco, michaeld@aacd.com

ADVERTISING AND SPONSORSHIP

DIRECTOR OF STRATEGIC PARTNERSHIPS

Jeff Roach, jeffr@aacd.com

EDITORIAL REVIEW BOARD

Pinhas Adar, MDT, CDT, Marietta, CA

T. Gary Alex, DMD, AAACD, Huntington, NY

Edward Pat Allen, DDS, PhD, Dallas, TX

Elizabeth M. Bakeman, DDS, FAACD, Grand Rapids, MI

Oliver Brix, MDT, Kelkheim, Germany

Michael W. Davis, DDS, Santa Fe, NM

Hugh D. Flax, DDS, AAACD, Atlanta, GA

Ronald Goldstein, DDS, FACD, FICD, Atlanta, GA

Dan Holtzclaw, DDS, MS, Austin, TX

Steve D. Hoofard, CDT, Hermiston, OR

Nelson Y. Howard, DDS, AAACD, San Marcos, CA

Ronald D. Jackson, DDS, FAACD, Middleburg, VA

Michael J. Koczarski, DDS, Woodinville, WA

John C. Kois, DMD, MSD, Seattle, WA

Gerard Kugel, DMD, MS, Lexington, MA

Trevor R. Laingchild, RDT, AAACD, Burlington, ON, Canada

Robert A. Lowe, DDS, Charlotte, NC

Ricardo Mitrani, DDS, MSD, Mexico D.F., Mexico

Michael T. Morris, CDT, FAACD, Lexington, KY

Thomas W. Nabors III, DDS, AAACD, Nashville, TN

W. Peter Nordland, DMD, MS, La Jolla, CA

Christopher Orr, BDS, London, UK

Paul S. Petrunaro, DDS, North Oaks, MN

Gary M. Radz, DDS, Denver, CO

Christopher D. Ramsey, DMD, AAACD, Jupiter, FL

Nelson A. Rego, CDT, AAACD, Santa Fe Springs, CA

Dwight G. Rickert, CDT, AAACD, Indianapolis, IN

Robert G. Ritter, DMD, Jupiter, FL

Jean-François Roulet, DDS, PhD, Schann, Liechtenstein

Maurice Salama, DMD, Atlanta, GA

Michael R. Sesemann, DDS, FAACD, Omaha, NE

Rhys D. Spoor, DDS, AAACD, Seattle, WA

Thomas T. Teel, DDS, Fort Wayne, IN

Thomas F. Trinkner, DDS, AAACD, Columbia, SC

Dennis J. Wells, DDS, AAACD, Brentwood, IN

EDITORIAL MISSION

The mission of the *Journal of Cosmetic Dentistry* is to educate AACD members, as well as other professionals in the field, on the art and science of cosmetic dentistry. We will endeavor to do this by publishing well-researched, peer-reviewed articles accompanied by high-quality, comprehensive clinical imagery. The objective is to enhance readers' knowledge and skills while showcasing the latest cosmetic techniques and procedures. The *Journal of Cosmetic Dentistry* will strive to help readers become better clinicians, so they can offer their patients the best—and most responsible—treatment possible.

AACD OFFICE

402 West Wilson Street, Madison, WI 53703

800.543.9220 • 608.222.8583

fax 608.222.9540 • info@aacd.com • www.aacd.com

CONTRIBUTING EDITORS

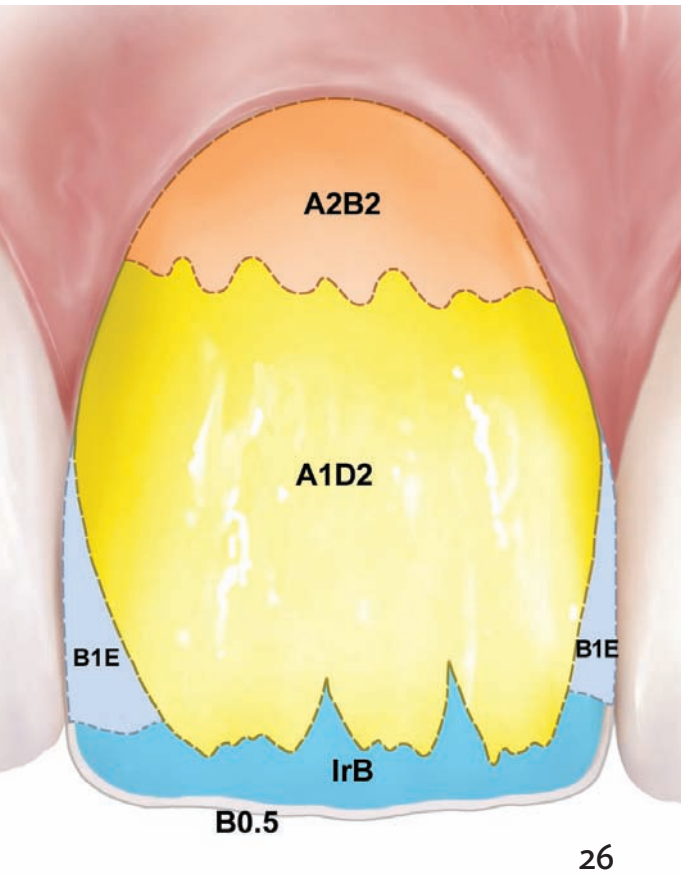
Scott W. Finlay, DDS, FAGD, FAACD, Arnold, MD

James H. Hastings, DDS, AAACD, Placerville, CA

James H. Peyton, DDS, FAACD, Bakersfield, CA

Nelson A. Rego, CDT, AAACD, Santa Fe Springs, CA

Advertising: 800.543.9220 • 608.222.8583 or jeffr@aacd.com
Editorial: 800.543.9220 • 608.222.8583 or publications@aacd.com



Columns

6 Editor's Message
We Take Our Fun Seriously! ♦
Edward Lowe, DMD, AAACD

8 Up Front
**Faster, Easier, More Convenient,
 but Better?** ♦
Jean-François Roulet, DDS, PhD

Departments

10 Behind the Smiles ♦
Kevin M. Brown, DDS

12 Speaker Spotlight
**Inside the Mind of
 Willi Geller—Part 2** ♦
Pinhas Adar, MDT, CDT

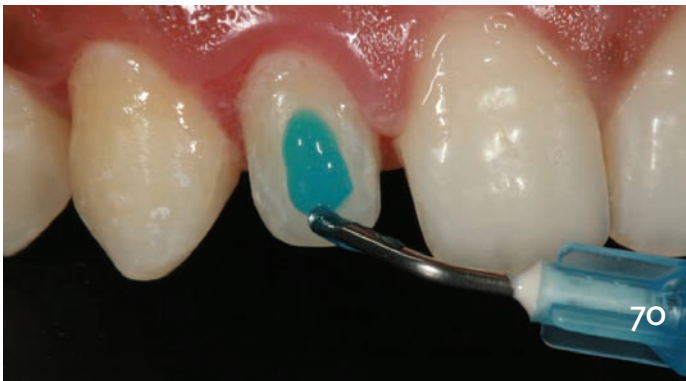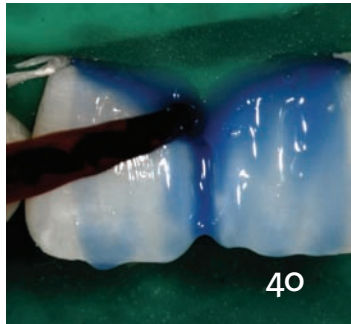
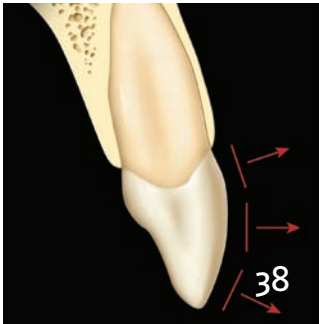
20 Give Back a Smile™
Regaining Self-Respect ♦
Tony L. Guilbeau, DDS, MAGD

26 Accreditation Essentials
**Preserving Natural Tooth
 Structure with Composite Resin** ♦
Prashant Hatkar, BDS, MDS

33 Accreditation Q & A
**Preserving Natural Tooth
 Structure with Composite Resin** ♦
James H. Peyton, DDS, FAACD

35 Examiners' Observations
**Mastering the Criteria for Ac-
 creditation Case Type V** ♦
Scott Finlay, DDS, FAGD, FAACD

38 Strengthening Your Bond
**Practical Tips for Accreditation
 Case Type V** ♦
James H. Peyton, DDS, FAACD



AACD MISSION STATEMENT

The American Academy of Cosmetic Dentistry is dedicated to advancing excellence in the art and science of cosmetic dentistry and encouraging the highest standards of ethical conduct and responsible patient care.



Features

40 Visually Speaking
A Step-by-Step Approach to A
Diastema Closure ♦
Marcos Vargas, DDS, MS

47 Clinical Cover Story—
Anterior Direct Bonding
for Identical Twins ♦
Kevin M. Brown, DDS

56 A Solution for Everyday Direct
Restorative Challenges ♦
Newton Fahl Jr., DDS

70 20 Tips on Bonding ♦
Edward J. Swift Jr., DMD, MS


74 Simple, Successful
Composite Repairs ♦
Corky Willhite, DDS, FAGD, AAACD

80 Conservative Composite
Restorations that Mimic Nature ♦
Lorenzo Vanini, DDS, MD

100 AACD Self-Instruction
Continuing
Education Information ♦

102 Reading List

102 Advertising Index



74



80

New AACD Member Benefit:
CE, 3 Hours Credit, page 100

Statement of Ownership, Management and Circulation, required by Title 39, United States Code 3685. Title of publication: *Journal of Cosmetic Dentistry*. Date of filing: September 9, 2010. Publication number: 1532-8910, USPS# 10452. Frequency of issue: quarterly. Annual subscription price: members, included in the membership dues; non-members/subscribers, \$135.00 (US and Canada), \$160.00 (All other countries) by the American Academy of Cosmetic Dentistry®, 402 West Wilson Street, Madison, WI 53703. 800.543.9220 OR 608.222.8583. Periodicals postage paid in Madison, WI and additional offices.

Mailing address of publisher: American Academy of Cosmetic Dentistry, 402 West Wilson Street, Madison, WI 53703. County: Dane. Name and address of the Editor: Edward Lowe, DMD, 402 West Wilson Street, Madison, WI 53703. Name and address of the Managing Editor: Tracy Skenandore, 402 West Wilson Street Madison, WI 53703. Average number of copies each issue during preceding 12 months: Total number of copies (net press run): 7926; mailed outside-county paid subscriptions stated on PS Form 3541: 6338 paid distribution by other classes of mail through the USPS: 8; Total paid distribution: 6346; Free or nominal rate copies mailed at other classes through the USPS: 107; Free or nominal rate distribution: 73; Total free or nominal rate distribution: 180; Total distribution: 6526; copies not distributed: 1400; Percent paid: 97%. Number of copies of single issue published nearest to filing date: Total number of copies (net press run): 6656; mailed outside-county paid subscriptions stated on PS Form 3541: 5396; paid distribution by other classes of mail through the USPS: 1; Total paid distribution: 5397. Free or nominal rate copies mailed at other classes through the USPS: 0; Free or nominal rate distribution outside the mail: 25; Total free or nominal rate distribution: 25; Total distribution: 5422; copies not distributed: 1234; Percent paid: 99%. I certify that all information furnished is correct and complete. Signed Tracy Skenandore, Managing Editor.

POSTMASTER: send address changes to: *Journal of Cosmetic Dentistry*, American Academy of Cosmetic Dentistry, 402 West Wilson Street, Madison, WI 53703. Peer-reviewed articles are denoted with the following symbol ♦. Statements of fact and opinion are the responsibility of the authors alone and do not imply an opinion on the part of the officers of the AACD. Materials may not be reproduced without written permission. Contents© 2010 American Academy of Cosmetic Dentistry®

The *Journal of Cosmetic Dentistry* maintains signed patient release forms for all articles featuring clinical or other patient photography.

We Take Our Fun Seriously!



I have been asking a number of AACD colleagues what they thought of the *Journal of Cosmetic Dentistry* (JCD). Some told me the publication was predictable and needed to be improved. As a result of that feedback, along with validation from a recent survey indicating how important the *Journal* is to our members, we are dedicated to improving it—starting with this issue.

The AACD...has never rested on its laurels, often entertaining new ideas and exploring possibilities—this is what sets us apart

Is it better to fit in or stand out in the crowd? I believe that it is healthy to do a little of both. We all desire to be different and significant, yet we often hesitate to leave our "comfort zone." The AACD, however, has never rested on its laurels, often entertaining new ideas and exploring possibilities—this is what sets us apart.

As the season changes and the landscape transforms, it is a fitting time to introduce the "new" JCD! A fresh graphic design is the first indicator of some of the exciting changes, which include enhanced clinical content as well as continuing education (CE) credit.

The focus of this issue is on the building blocks of good cosmetic dentistry: bonding and composite restorations. Our main features highlight two of today's master composite resin artists. Dr. Newton Fahl discusses solutions for everyday restorative challenges that will enhance your skills in composite dentistry. Dr. Lorenzo Vanini, in the JCD's first CE offering, describes a step-by-step technique for composite placement that you should not miss.

Some of the other features in this issue include: Dr. Ed Swift's tips on adhesion and its clinical significance, and Dr. Marcos Vargas' pictorial approach to a diastema closure.

We also are honored to have Dr. Jean-François Roulet launch the new "Up Front" feature with his views on adhesion.

Serving as the JCD's Editor is a responsibility that I take very seriously. The Journal is constantly evolving, so I look forward to exploring other possibilities to bring you a publication that proudly exemplifies what the AACD is all about.

Never settle for mediocrity; always strive to be outstanding in your field. Or in my case, the only jack-o'-lantern in the all-female pumpkin patch!

Cheers,

Edward Lowe, DMD, Editor
AACD Accredited Member

Do You Want Powerful Solutions to help you succeed?



"PNP delivers a superior quality product, stellar customer service, and a direct marketing solution that works! I've known this company for years and they're tops in my books. I highly recommend you give them a call!"

– Dr. John Jameson, pictured here with Cathy Jameson, Jameson Management, Inc., Oklahoma City OK



"The newsletter had delivered great patients consistently. These are not patients who want limited treatment, but are looking for great treatment with superior service. I would feel comfortable saying that the patients delivered by Patient News Publishing are the best in our practice."

– Dr. Christopher Hussin, Valley Forge PA



"After five years of talking to Karen and Joanne at various trade shows, I finally decided to proceed. After mailing our first newsletter, a small mailing of just 3,500 pieces, we received at least ten quality new patients, PLUS 10-15 of our patients of record, after reading about *Invisalign*® in that same newsletter, have either booked treatment or a consultation. I am impressed with Patient News, both product quality and customer service, and can attest to the fact that they deliver what they say they will!"

– Drs. Johnn & Dianna Griffith, Naples FL

"We take great pride in the results we are consistently able to realize for clients who regularly provide us with feedback about our exceptional and diverse article library, high-quality and professional marketing products, and friendly knowledgeable team."

Karen Galley, President, Patient News



Call 800.667.0268 Today for your Exciting Free Trial!

PATIENT ACQUISITION

Best Practices, Expert Advice, & Tools That Work

PATIENT RETENTION

More Effectively Connect & Engage Your Patients

MARKETING GUIDANCE

Strategies To Address Your Challenges

Faster, Easier, More Convenient, but Better?



Jean-François Roulet, DDS, PhD
Editor, *Journal of Adhesive Dentistry*

If enamel were developed today it would never make it to market!

It would fail immediately, because it does not fulfil the ISO specification for ceramics. So why does it work so well that teeth last for a lifetime? Over millions of years, nature has fine-tuned this composite material: The enamel is firmly bonded to the dentin. (Have you ever seen a tooth that has delaminated its enamel?) So it was a

We should maintain as much sound enamel as possible, which forces us to follow the most minimally invasive approach.

great step forward when dentistry moved into adhesion. We must thank pioneer Drs. Oskar Hagger, Michael Buonocore, and Nobuo Nakabayashi, who profoundly changed the way dentistry is performed. Initially we were bonding exclusively to enamel, knowing that it works there only if all the steps are performed meticulously. Then we focused more and more on bonding to dentin. For this purpose, the systems were increasingly simplified, which strongly follows the market trend: faster, easier, and more convenient. Yes, it is possible to get a reliable bond to dentin, at least initially, with all-in-one adhesives, but why should we compromise the good result by applying a large volume of composite (bulk filling) and curing it in as few seconds

as possible? This composite application technique probably generates more stress at the interface. In addition, we have learned two more things: (1) the bond to dentin may deteriorate over time, which can be minimized by finishing tooth preparation margins in enamel whenever possible; and (2) self-etching adhesives do not yield as good a bond to enamel as etch-and-rinse adhesives.

Using this knowledge, we should maintain as much sound enamel as possible, which forces us to follow the most minimally invasive approach. Ceramic is not the only restorative material available; with modern composites we can accomplish excellent, long-lasting esthetic results. Furthermore, for functional reasons, instead of merely following the "fast track" we should select any adhesive that requires etching the enamel in order to obtain a perfect seal of the margins. This will also enhance the esthetic outcome.

That we do all these steps with meticulous care is of course fully within the guiding principles of good adhesive dentistry.

UP FRONT provides a guest editorial forum for influential educational leaders to share their opinions. In this issue, we welcome Dr. Jean-François Roulet. Editor of *The Journal of Adhesive Dentistry*, Prof. Roulet has published more than 400 articles in national and international journals. His main subjects of interest are composites, ceramic inlays, esthetic dentistry, and preventive dentistry (application concepts).

Author Disclosure: The author did not report any disclosures.

MEET *Juan Olivier.*

After studying with some of the best master technicians in dentistry, our amazing Juan Olivier has become known for his extraordinary dental technology skills. And his credentials back up our boasting: he is a Certified Dental Technician and Master Ceramist. He is a graduate master technician from the Las Vegas Institute, a Pac-Live master technician and Fellow of the Academy of Comprehensive Esthetics (ACE). Juan is proud to be a Sustaining Member of the AACD, as well as to have been chosen as a premier and head master ceramist by the Academy of Comprehensive Esthetics. Imagine what a difference working with Juan could make on your cases.

"I am always available to you and your staff to answer any questions and assist in comprehensive case planning. My goal is to work with like minded dentists, who are committed to excellence in dentistry." Juan

To begin working with LK Dental Studio's "A Team" call 866-550-3522 or log on to LKDentalStudio.com.

"Finding a great ceramist is the key to your practice success, especially if you are focused on functional & aesthetic dentistry. In over 24 years of dental practice, Juan Olivier is one of the best that I've ever had the pleasure of working with. From our communication on cases to his understanding of several different philosophies of occlusion, I know that the restorations that Juan creates will be exactly what I expect and the patient wants. Having Juan as part of my team allows me to change lives, enjoy dentistry and have the peace of mind that comes with providing exceptional care."

MICHAEL MAROON
D.M.D., F.A.C.E.
CONNECTICUT

DENTAL **LK** STUDIO

WE DON'T HAVE A B TEAM.

ROCKSAND GROGAN

CERAMIST & GENERAL MANAGER,
LK DENTAL STUDIO
AACD MEMBER

TODD FONG

MASTER CERAMIST,
LK DENTAL STUDIO
CDT, F.A.C.E.

JUAN OLIVIER

MASTER CERAMIST,
LK DENTAL STUDIO
LVI MASTER TECHNICIAN, CDT, MDT, F.A.C.E.
AACD SUSTAINING MEMBER

LAURA KELLY

PRESIDENT, LK DENTAL STUDIO
AACD PRESIDENT 2007-2008
AACD ACCREDITED MEMBER

DAVE STOHLMAN

MASTER TECHNICIAN,
LK DENTAL STUDIO
AACD MEMBER

DANNY EVANSON

LEAD TECHNICIAN &
CERAMIST,
LK DENTAL STUDIO



...we concluded that direct resin veneers would be the best and most conservative treatment for their situation.



Behind the *Smiles*



Identical twins Megan and Morgan had just completed orthodontic treatment and faced the common dilemma of residual space in the maxillary anterior due to peg maxillary lateral incisors. Immediately after having their braces removed, the girls presented for comprehensive examinations, with the specific goal of correcting the spaces in their smiles.

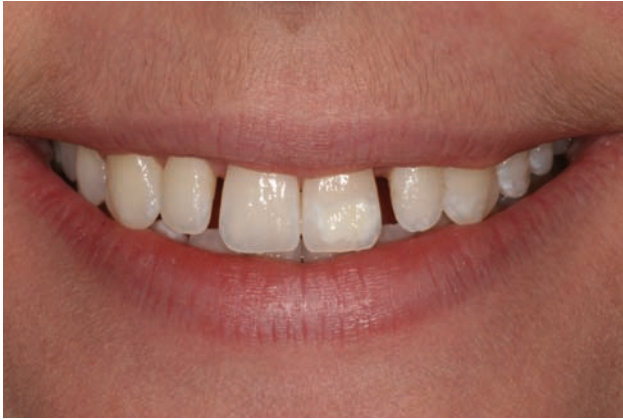The two treatment options presented to Megan, Morgan, and their mother were minimal preparation porcelain veneers versus direct resin veneers. After considering the benefits and risks of each option, we concluded that direct resin veneers would be the best and most conservative treatment for their situation.

The AACD is well known for the high caliber of instruction and hands-on courses that prepare dentists to predictably and esthetically layer composite resin using a diagnostic wax-up and a silicone putty index. In the case of Megan and Morgan and their near-identical mouths, it was a perfect opportunity to illustrate just how predictable this method truly is.

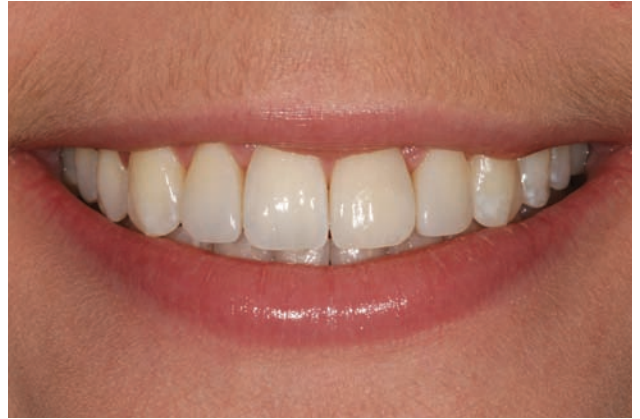The sisters were relaxed as four different composite shades were carefully layered, contoured, and polished. It was fun to watch them enthusiastically examine the other's smile after we finished. They returned the following week for evaluation and final photographs. Portraits were also done in our office photography studio; these were later framed and given to the sisters as our way of saying "thank you for trusting us with your smiles."

For more information on the treatment of these twin patients, please see the Clinical Cover Story, beginning on page 47.

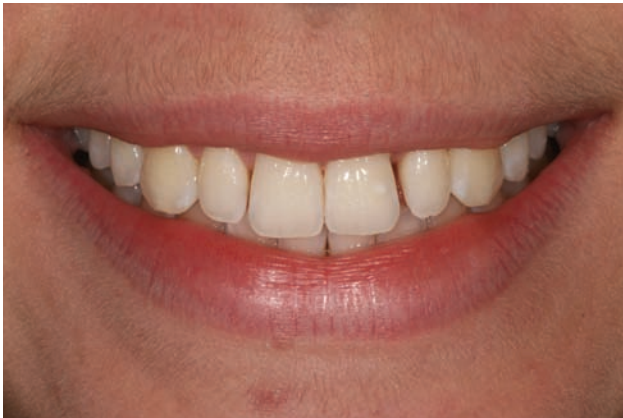Megan Preoperative



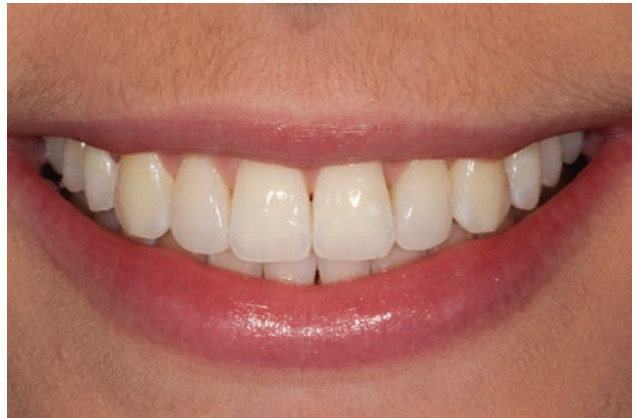Megan Postoperative



Morgan Preoperative



Morgan Postoperative



Restoring Dentist: Kevin M. Brown, DDS (Bellevue, WA).
Photographer: Anson Gessel (Redmond, WA).

Inside the Mind of Willi Geller—Part 2

with Pinhas Adar, MDT, CDT

Discovering True Happiness When Nurturing a Passion

Willi Geller, MDT (Zurich, Switzerland), is known around the world as a master in the dental industry. In this interview he shares candidly with one of his former students, Pinhas Adar, MDT, CDT (Atlanta, GA), his views on the future role of laboratory technicians, and offshore laboratories, among other topics.

Mr. Geller will be presenting at the 27th Annual AACD Scientific Session in Boston, Massachusetts, May 18-21, 2011. Save the date and register online today at AACD.com.

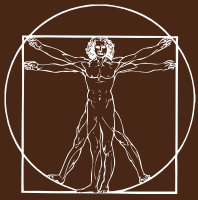
My achievement, I think, is to just keep growing.



PA: Dental manufacturers as well as many clinicians believe that the future will be about computer-assisted design/computer-assisted manufacturing (CAD/CAM) and the digital ability to create lifelike ceramic restorations without using a dental technician. What are your feelings on the future role of the dental technician, and will this job become obsolete in the future?

WG: It is a fact that manufacturers want it to happen, but people also are afraid of this development. Society has always worried about change. I think there is no reason to worry about this technology. In my opinion, the most progress comes from the dental chair or the dental technician's bench. We can do many good things with CAD/CAM, but the creativity of a machine can never match that of humans. And CAD/CAM does not give you the final product. Also with the shade-taking technologies, the manufacturer tells you that you will never have the wrong color. That is just not true. It is a tool that people can use, but it is just a guide, a reference point.

The technician's role will be totally different 20 years from now, but that's okay. I think it's the connection, the relationships with people that are really the key.



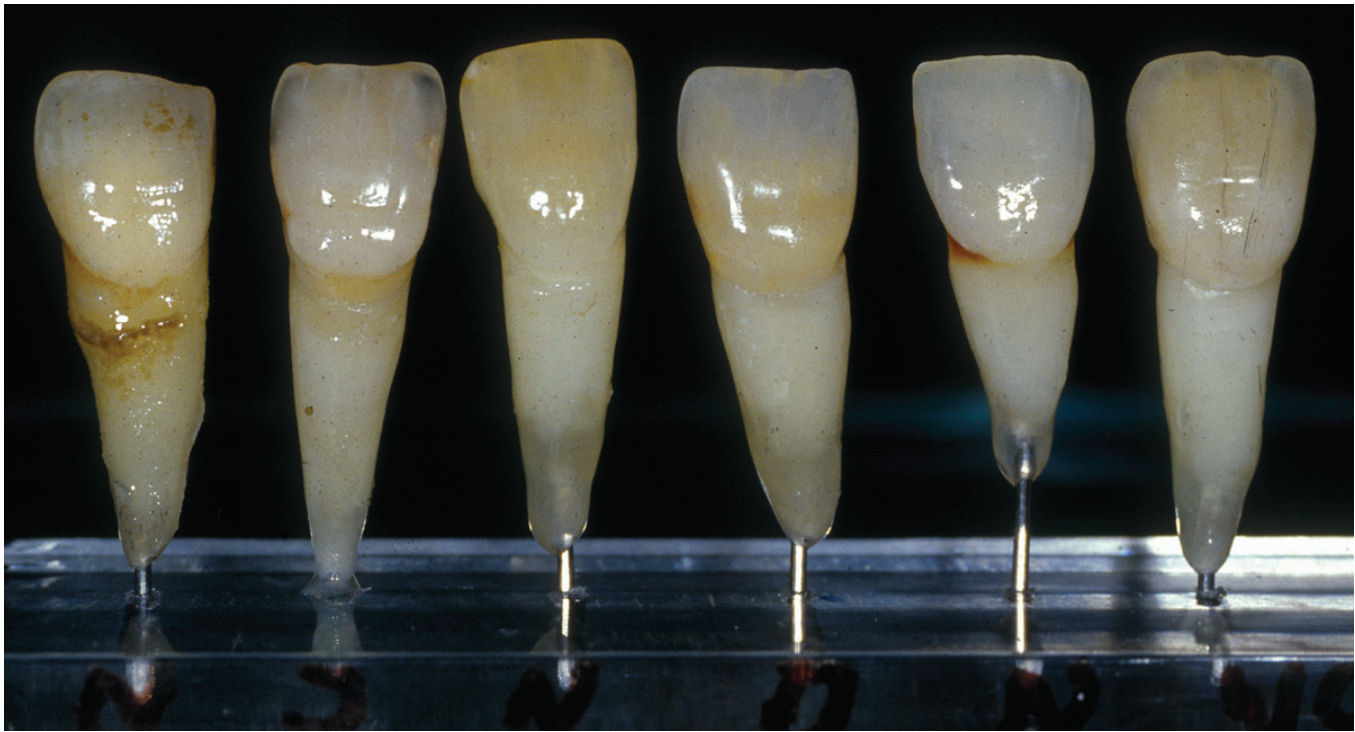
The daVinci National Patient Referral Advertising Program is only one of the ways we are helping you to build your practice. New patients can be made aware of, and contact you through our nationally placed ads. (See this month's New Beauty Magazine). To be a part of the program give us a call at: **800.874.7239**

DAVINCI SMILE.COM


BE A PART OF OUR **FREE**
NATIONAL PATIENT REFERRAL
ADVERTISING PROGRAM.



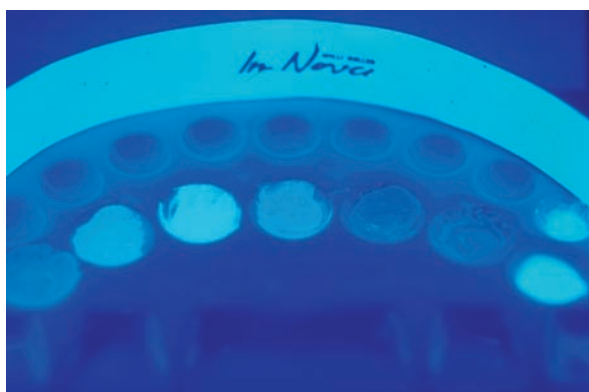daVinci DENTAL STUDIOS
FOR THE SMILE OF A LIFETIME



First effect for translucent root. Mr. Geller created this effect with Dicor castable glass. Different types of ceramic restorations are bonded on extracted teeth, showing the elimination of gray.



Cross section of a Geller glass ceramic tooth with light being transmitted to illustrate the natural translucency on both the crown of the tooth and the root.



Creation In Nova stains with fluorescent quality shown with a blue light.

PA: So, the tools and the advances in technologies are just the extension of our ability, an extension of our fingertips.

WG: Yes. We have to always grow and progress, of course.

PA: There are still obvious differences between European esthetics and American cosmetics, but the gap seems to be closing. Where do you feel the line is currently being drawn?

WG: Europeans often say that Americans have no culture, but that is not true; it is just a different type of culture. Beauty is a personal expression—it is very subjective in general.

Many Europeans say that they don't want "Chiclet white." More Europeans want to have natural-looking white, not overly straight teeth.

PA: I feel that creating white teeth that appear natural and bright is really harder to do than just "natural" teeth.

The technician's role will be totally different 20 years from now, but... I think it's the connection, the relationships with people that are really the key.

WG: It is very hard to do. I can sometimes do it, but only sometimes, and I don't understand why it is not consistent even with the same material. Maybe it is the wrong day or the wrong moment, I don't know. But creating white teeth that look natural is difficult.

PA: What, in terms of European esthetics, makes a smile beautiful? What are the principles that, for you, make a smile beautiful?

WG: It is difficult to convey the concept of beauty. I think a smile should be in harmony with the person; even a smile that is whiter than what nature makes, when in harmony with the person, can be beautiful. But harmony, in my opinion, is critically important in esthetics.

PA: Can you offer a short list of parameters that define esthetics?

WG: What really is a parameter of esthetics? Health, certainly. Vitality is a parameter; strength, beauty, and happiness also are parameters. When a person is not physically beautiful, but is kind and good you still feel that person is beautiful. So, there can be many parameters.

PA: Does form always follow function, or do you feel that is sometimes not true?

WG: There are instances where it is not true. Most of the time it is, but we see many different kinds of people and often they were not born with ideal smiles. So we try to correct that.

PA: This next point is one that most laboratory technicians have and one that you mentioned in Part 1 of this interview (Editor's note: Please see the Summer 2010 issue of the *JCD*, page 20.) You said that you are not a businessman, but your laboratory is a business.

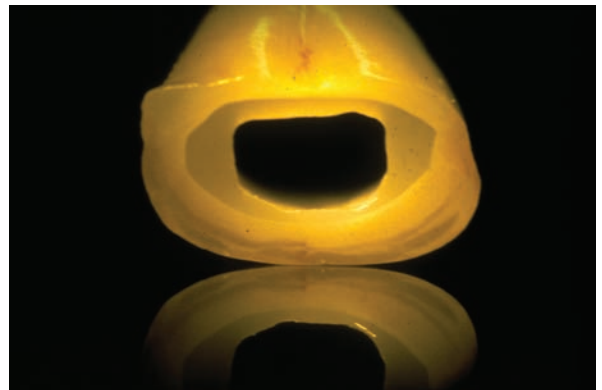
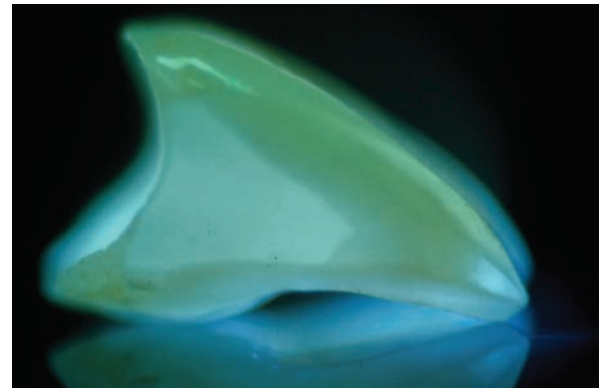

To survive, you have to be respected, as well as compensated for your time. Are there ways to help technicians learn how not to be just an artist, but to also be a good businessperson?

WG: "Compensation" should not only be about money. No one can give you back your time. When you are recognized and appreciated, that is additional "payment" for your growth. This gives you the power to continue to become better; it is the satisfaction of personal and professional growth. We have a wonderful profession; many of us truly love it and feel as though it is a gift rather than a job because it does not feel like work. We do it because we actually love it. It is rare for someone to have a passion and get paid for it; nothing can be more rewarding than that.

PA: What do you see in the future for esthetic and restorative dentistry?

WG: I believe that cosmetic dentistry will have strong growth partly because Americans have healthy teeth and usually a healthy oral situation. Also, the economy in areas such as Russia and Eastern Europe is growing, so more and more people can afford cosmetic improvements. Less invasive procedures to preserve the teeth as much as possible will play a big part in the cosmetic dentistry of the future.

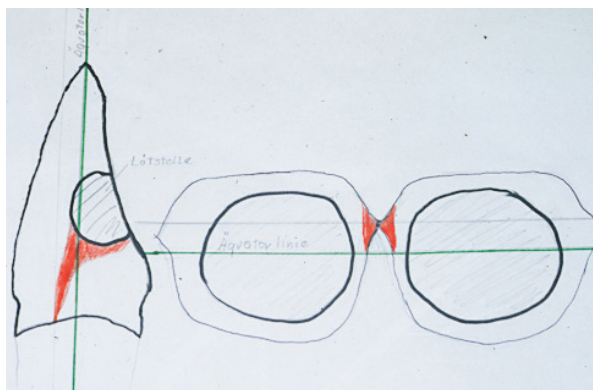
PA: What are some things that you see from dentists that



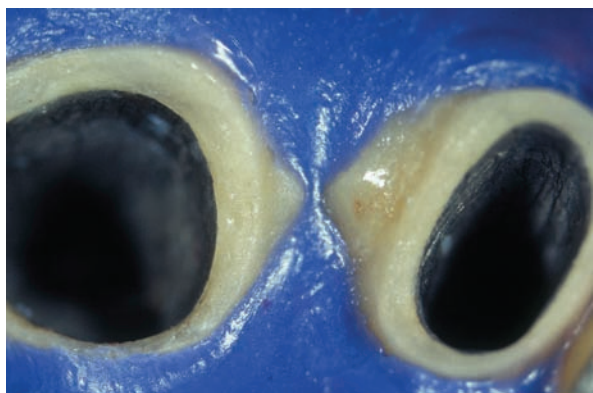
Geller's glass concept cross section of crowns with Dicolor substructure and luminous ceramic overlay.

make your job harder or easier?

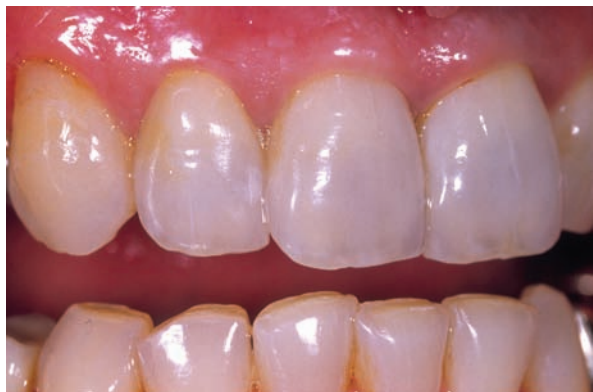WG: I don't know. Maybe it is really up to me, because one day sometimes is simply better than the next. However, when a dentist is a perfectionist it can really be hard. The perfectionist can engage in "analysis until paralysis" and that makes it difficult.



The axis of the recommended position of interproximal closure to avoid black triangles.



Pick-up impression with the crowns to finalize the restoration and to ensure accuracy of interproximals.



Final porcelain-fused-to-metal crowns with optimal tissue health with interproximal closure.

PA: How do you determine the value of a restoration? I believe this is a significant issue for many technicians.

WG: We talked previously about partnership (Editor's note: Please see the Summer 2010 issue of the *JCD*.); a real

partnership shares in the quality of work that they do as well as in the money they make. The payment to the technician should be fair and not four times less than the doctor gets paid. My payment is usually 50/50 with the dentist.

PA: In the U.S., a lot of people, including myself, add the laboratory fees separately to the doctor fees. The patient then pays directly or indirectly to the laboratory.

WG: That is fair, of course.

PA: But, as you know it's not all about the money. To recognize others' efforts is also important and will inspire people to do better. Not all technicians get to see the patient. So, after the seat, the doctor should call the technician and discuss what the experience was like while he was seating the restoration. The doctor should not call only when something goes wrong.

WG: Yes, usually when they call it's with a complaint. But that is human nature. Perhaps the dentists don't think about it.

PA: What areas do you feel are most relevant to modern dental ceramics?

WG: I think education, communication, and networking are key. Some individuals do not have direct access to people and communicate only through e-mails. But by networking with other labs and working with them on development and not

fearing them as competition they can exchange information and grow. Communication is important to help each other. It's good when there are a lot of good technicians together and not just a few. When we have good technicians around us we grow even faster.

PA: I like that. You've already mentioned that machines are not the solution because we will still need ceramists for personal touch, personal communication, and relationships. However, as CAD/CAM technology takes an ever-increasing role in dental ceramics, what role will the future individual master ceramist play?

WG: I do not have a mobile phone, but I'm not really an example for today. That's just my personal decision, but the younger generation has grown up with technology—the computer is like a pencil for them. You really don't need to be "modern," but you must be "contemporary"; technicians cannot avoid this. But it is also essential that we do not let technology "control" us—there always needs to be balance. It is important that we keep our sensitivities, sensibilities, and normal human behavior.

PA: In the U.S., as well as in some other countries, many dental professionals are outsourcing dental laboratory work to offshore operations in China, India, etc. A lot of lab owners have had to close their businesses because of this.

What role do you think this situation will play in the future of our profession?

WG: This is a disaster. I am against outsourcing business because we should protect the profession and the marketplace in our own countries. This is a foundation of social responsibility. Patients also have the right to know if this outsourcing is being done. Doctors should be proud to be “elite” in their profession and provide the best possible treatment and dental restorations through sources and talent available to support their own countries’ economy. We should protect what economically, intellectually, and spiritually belongs to our culture.

PA: **Some dentists actually do not know that the laboratory they send their work to is then sending that work to China, for example.**

WG: Then that is even worse. I am not against the Chinese or other cultures to which work is outsourced, please don’t misunderstand me; it is just that you have to care about your people and your social system.

PA: **It is about responsibility. I think that’s the biggest word of the future.**

WG: I call it social responsibility. It’s like paying taxes—we have to pay them because otherwise we wouldn’t have good streets, good schools, etc. It’s the same thing.

PA: **I know you do a lot of porcelain-fused-to-metal restorations. Have you seen**

the international increase in the price of gold impact dentistry? Do you think that really changes the landscape of dentistry?

WG: It hasn’t affected my work, personally; I am very careful with my superstructure design, but I still use high-quality

We have a wonderful profession; many of us truly love it and feel as though it is a gift rather than a job because it does not feel like work.


ity gold. I will not put steel or garbage underneath. But we can use chrome cobalt, which is a fine material. Perhaps 40 years ago, maybe more, they used a lot of chrome cobalt in the university here in Switzerland. But because we did not have good ceramics for

this material you could see the gray of the cobalt underneath. But today, with our new materials, the color does not bleed through.

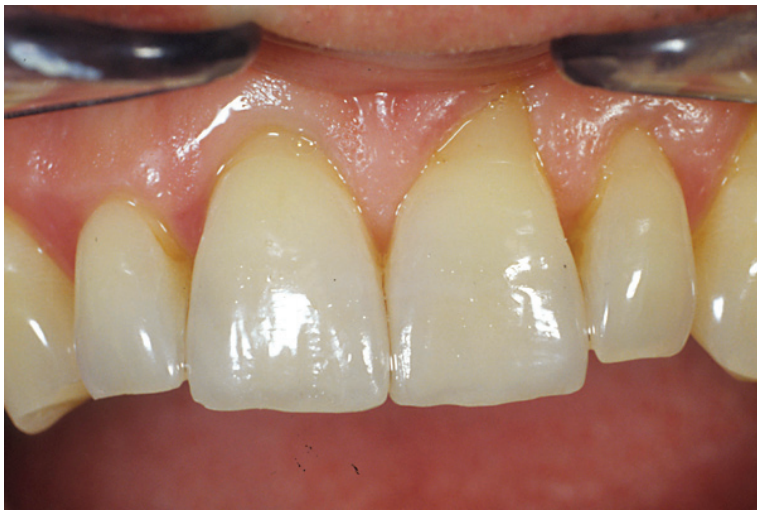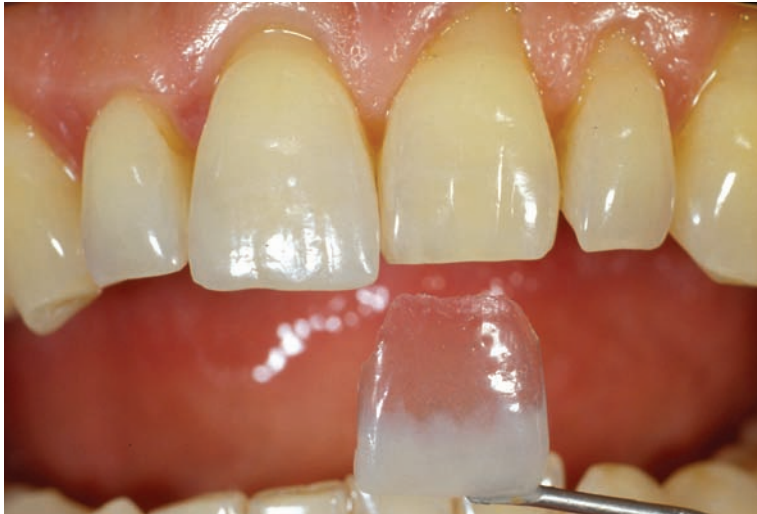PA: **Interesting. Which areas of dentistry excite you?**

WG: It is always good to see beautiful work from talented people. But, to be honest, I have noticed a trend where we often see beautiful restorations in publications with perfect tissue and ceramic, but we don’t always see this same success in the mouth.

To get back to your previous question...one thing I would like to discuss is zirconium. There are so many articles and symposia about this material, and now it is getting a bad reputation. I believe that zirconium is a good thing, but case selection is the key; you must have the right patient and the right tooth structure. You must also select the correct zirconium block to use. When it goes to



Internal structure must be created just as in a natural tooth. Light transmission allows us to see the segmental buildup and internal characterization of the ceramic restoration.



The invisible ceramic restoration with a non-invasive veneering concept.

the milling center things can go wrong with the way it is infiltrated there and you won't know that has happened when you get it back. A lot can also go wrong in the baking process.

Research claimed that ceramic was too hard for the opposing tooth structure but now, with zirconium, even full-contour crowns are being milled. This totally goes against the principles that the research claimed before that. That is insane.

Too many speakers talk about zirconium based on a manufacturer's influence and support, and

many of them lack an understanding of the product. In my opinion zirconium will fade away because of the failures and lack of understanding and the lack of proper case selection. Manufacturers recommend materials to us and then tell us how to use it, yet they have never worked with it. Some manufacturers are now starting to mill other products; for them, it is just about business. I really feel it is a shame that our industry is leaning toward lowering our standards.

PA: Very interesting overview—thank you for sharing that. On another topic, what do you feel has been

your greatest achievement in dental ceramics?

WG: My own achievement?

PA: Yes, the greatest achievement—one thing that really changed, and then everything else happened because of that.

WG: I really don't know how to answer that. I can tell you that I feel really good because sometimes, restorations are so easy for me to do. This also helps me to help other people; that is what makes me happy. My achievement, I think, is to just keep growing. When one thing is done, another takes its place. When something comes to me intuitively it makes me happy. Maybe it will never happen again, or maybe it will happen many more times. Maybe it will tomorrow or maybe tonight, but I really don't think about me.

PA: In his book *The Greatest Secret in the World*, Og Mandino says, "I will always announce my goals to the world, yet never will I proclaim my accomplishments. Let the world, instead, approach me with the praise, and may I have the wisdom to receive it in humility." That actually describes you. People always ask me about you and wonder what is your secret to success—can you answer that?

WG: I have no "secret"—my success is a result of all my experiences. I am very honest; I don't keep lies in my mind that I always have to remember. That makes it very easy to live in the moment.

PA: Well, you definitely paved the way for the rest of us. I can't thank you enough for everything you've done for me and for so many others, either directly or in-

directly. You have inspired the entire industry.

We are so looking forward to having you as one of the keynote speakers at the Academy's Annual Scientific Session in Boston next year. You are going to give a presentation with Dr. Giuseppe Allais, who is an outstanding clinician, in which you will share how you work together.

You are an expert in many fields—the word “expert” comes from the Latin word *experiri* and means “one who helps you try something new.” Experts help to shorten the learning curve for those they guide. You do all of those things and you are always looking for something

new; you always try and grow yourself.

WG: I am fortunate that things just come to me. Things will come to you; you don't have to look for them. If you look for them, maybe you won't find them and then you will be disappointed.

PA: You are not just a coach, but are really a guru to many, taking us from darkness into the light. Thank you so much for your time and the wisdom you have passed on to us.

WG: It has been my great pleasure. Thank you for allowing me to share my thoughts. jCD

I have no “secret”—my success is a result of all my experiences.

About the Author: Pinhas Adar, MDT, CDT, owns and operates a laboratory in Atlanta, Georgia, and is a guest presenter at the Harvard School of Dental Medicine. **Author Disclosure:** The author did not report any disclosures



Master ceramist Willi Geller, MDT, has owned and operated Oral Design Group in Zurich, Switzerland, for 25 years. He has lectured and taught many courses worldwide.



I am a survivor. I am beautiful. I am strong.

AACD CHARITABLE FOUNDATION ANNUAL REPORT NOW AVAILABLE!

The Annual Report is available for immediate viewing at www.aacd.com/aacdcfreport

AACD Charitable Foundation, Inc. | Give Back a Smile
American Academy of Cosmetic Dentistry Charitable Foundation

Regaining Self-Respect

Mending a Smile and Confidence with Dentures

Tony L. Guilbeau, DDS, MAGD

The AACD Charitable Foundation's Give Back a Smile™ (GBAS) program restores the smiles of domestic violence survivors at no cost. In response to crucial volunteer feedback, the GBAS guidelines have been updated to move away from full-mouth reconstruction cases and focus on injuries incurred to the smile zone.

This section shares the triumphs of the GBAS program. Please visit www.givebackasmile.com for more information on how you can help restore a smile.

Introduction

We met "Tricia" (not her real name) when one of my long-time patients asked if I could help her co-worker regain her smile (Fig 1). Tricia, a survivor of domestic violence and a single parent with five children to support, lost her last complete denture (CD) five years ago and, along with it, her self-esteem. After multiple visits, including three try-in appointments to complete her denture, I was able to provide not just a smile, but a smile to fit her personality. Upon completion of her case, there was a noticeable spring in her step as she regained some of the self-esteem that had vanished due to the loss of her teeth.

Patient History

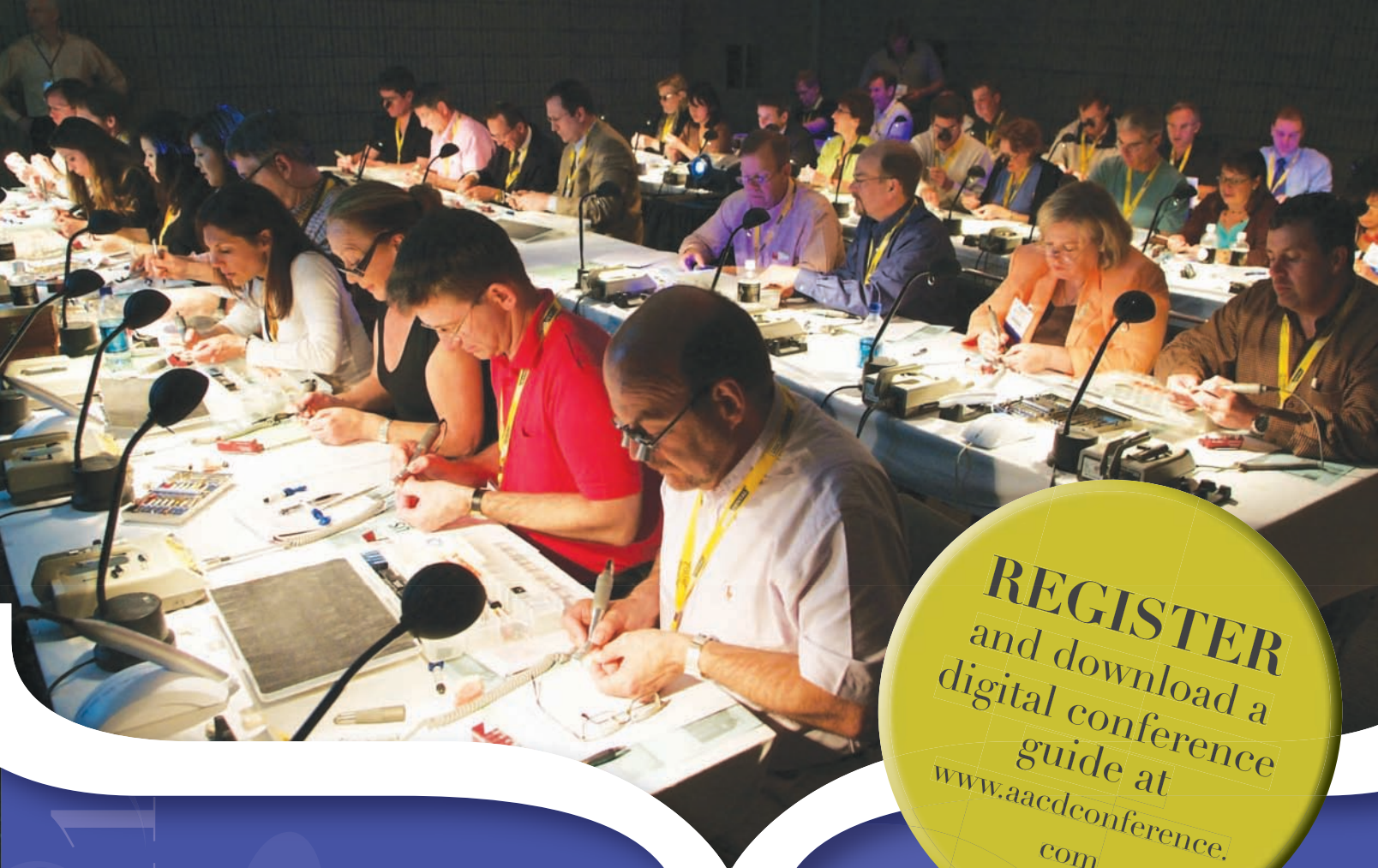Tricia was 49 years old and had no noted major medical conditions. She was a pack-a-day smoker, which was discussed as part of her oral health problems. She had endured 25 years of abuse from her former husband, an alcoholic. The births of her five children led to a calcium deficiency, affecting her teeth. Dental care was not a priority.

Clinical Findings

Tricia presented with an edentulous maxilla with a moderate amount of bone remaining; anteriorly, the gingiva was mildly spongy so I anticipated a potential stability problem (Figs 2-4). Her mandible had eight remaining teeth; all exhibited decay and mild-to-moderate periodontal disease involvement. The periodontal conditions were more pronounced on teeth #24 and #25, with Class I mobility noted (Fig 5).

Upon completion of her case, there was a noticeable spring in her step as she regained some of the self-esteem that had been vanished due to the loss of her teeth.

While discussing her treatment plan, Tricia was concerned about the maxillary CD being too bulky anteriorly. I assured her that this "complication" was actually an advantage due to her severely deficient lip protrusion. A fuller lip profile would provide her with a more youthful appearance. After she heard this she had no further objections.



REGISTER
and download a
digital conference
guide at
www.aacdconference.com

Being the best in your field TAKES COLLABORATION

Find it at the 27th Annual AACD Scientific Session, May 18-21, 2011

*The RISE of
COLLABORATION: Feel it!*



Giuseppe Allais, DDS



Stephen Chu, DMD



Newton Fahl, Jr., DDS



Willi Geller, MDT



Harald Heymann, DDS, MEd



Frank Spear, DDS, MSD



Dennis Tarnow, DDS



Dennis Wells, DDS

*Educators are subject to change. View the complete program online.





Figure 1: Preoperative full-facial view; note the patient's closed smile

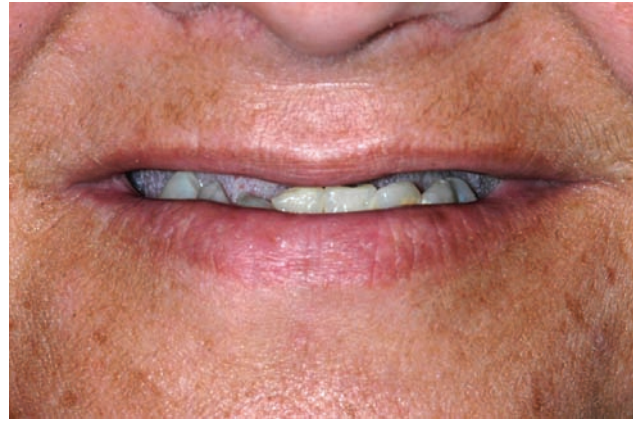

Figure 2: Preoperative unretracted view, revealing no maxillary CD and remaining teeth.

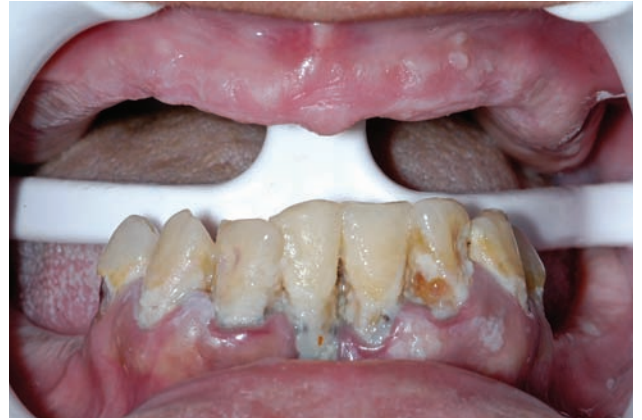

Figure 3: Preoperative retracted view, showing edentulous maxilla and condition of mandibular teeth.

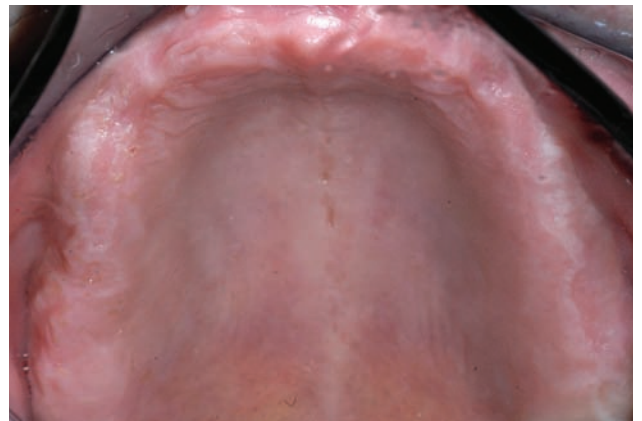

Figure 4: Edentulous maxillary arch.

Treatment

After the evaluation appointment, alginate study models were taken. I decided to focus on the maxillary complete denture, as the patient who had introduced us suggested Tricia might not tolerate having two prostheses fitted simultaneously. Therefore, initially fabricating the maxillary CD was prudent, as the mandibular problems were treated.

The maxillary CD final impression was completed using a custom acrylic tray (Stern TEK, Sterngold Restorative Systems; Attleboro, MA) and impression material (Aquasil Ultra Xtra, Dentsply Caulk; Milford, DE). The bite record was fabricated with light-cured acrylic (Stern TEK) and wax. Using colored pencils and a ruler, I determined a satisfactory closing in centric relation (CR). There were no existing maxillary teeth or existing denture to use as a guide, only a CR position. Due to Tricia's time constraints, only teeth ##21-23 were restored at first (##24-28 were completed at a subsequent appointment). The composite resin restorations were completed using Vit-escence material shade (Ultradent; South Jordan, UT) of a VITA shade C-3. The deeper restorations required a Vitrebond base (3M ESPE; St. Paul, MN). Tooth #28 ultimately exhibited pathological symptoms, leading to

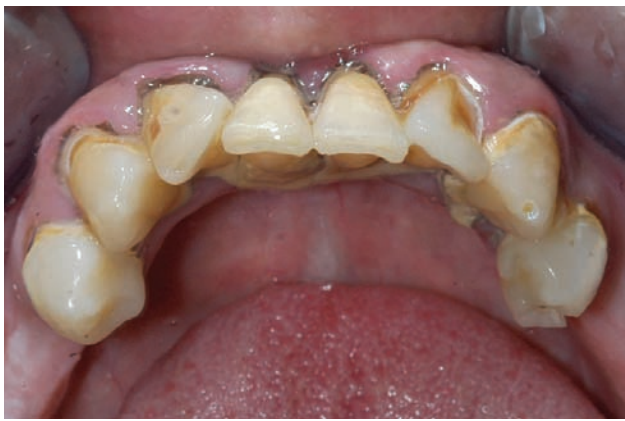

Figure 5: Preoperative retracted view of remaining mandibular teeth.

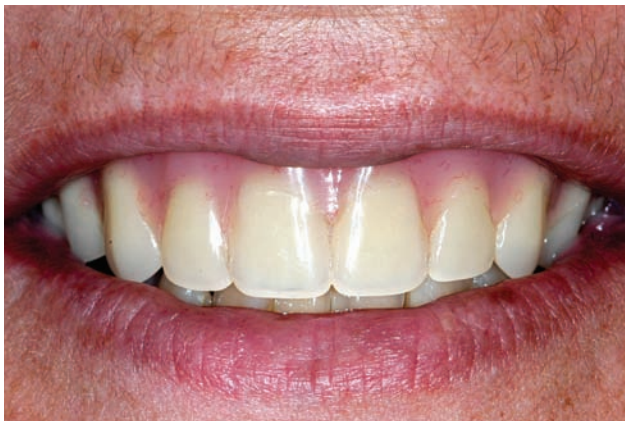

Figure 6: Postoperative natural smile view of new maxillary CD and restored mandibular arch.

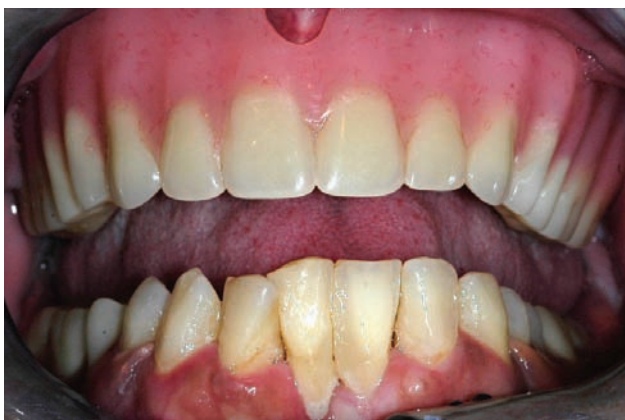

Figure 7: Postoperative retracted view of both arches restored; oral hygiene still needs improvement.



Figure 8: Postoperative image.

endodontic treatment. This was provided using ProTaper rotary treatment files (Dentsply Tulsa Dental; Johnson City, TN), sodium hypochlorite, and obturation with EndoREZ resin-coated gutta-percha points (Ultradent) and EndoREZ resin-based sealer. The tooth was restored with Vit-l-escence composite resin, as there was sufficient enamel remaining to contraindicate a crown.

While Tricia was under anesthesia, an ultrasonic scaler was used to remove the majority of calculus buildup, followed by scaling and root planing in an attempt to restore the gingival health of these remaining teeth.

The try-in appointments were more challenging than expected, as the midline had been set incorrectly at the first appointment.¹ The second appointment went well and the CD was sent for processing.

When the finished CD was received from the laboratory, I noticed the gingival color was far too light to be attractive; it resembled the gingiva of an out-of-control leukemia patient.² A rebase, with an accompanying gingival shade tab, was requested from the laboratory to show exactly what I had in mind. The next version was acceptable and quite attractive. It was delivered two months after the initial impression and not without some drama. The suction was now inadequate, so a relines was done

using Hydro-Cast tissue treatment and functional impression material (Sultan Healthcare; Hackensack, NJ) and immediately poured in Die-Keen green Type V stone material (Heraeus Kulzer; South Bend, IN). There was still a lack of suction. I was puzzled as to why, in the morning, the impression showed great suction, but by the afternoon the relined CD lacked suction. I felt the gingival compression from the morning had rebounded; after Tricia wore the relined CD for several minutes, suction was indeed achieved.

After gingival healing, a final impression of the mandible was completed (in a similar fashion as the maxilla) to fabricate a flexible removable partial denture (Valplast International; Long Island City, NY) to replace the missing ##18-20 and ##29-31.

After two adjustment appointments, Tricia was thrilled with her new smile. She also was able to speak and chew

properly, which she had not been able to do for many years (Figs 6-8).

Discussion

This patient's life had been compromised by very difficult circumstances; I admire her resolve to regain her self-respect. When Tricia now looks in the mirror, she sees a different person, one who can smile with confidence!

After two adjustment appointments, Tricia was thrilled with her new smile.

The AACD provides excellent continuing education to its members. This, in turn, benefits our patients with quality care. This care is portrayed in cosmetic and functional excellence for the patients we are privileged to treat.

Acknowledgments

The author thanks Red Wing Dental Arts (Red Wing, MN) and B and L Dental Laboratory (Lafayette, LA) for their assistance with this case.

References

1. Chiche GJ, Pinault A. Esthetics of anterior fixed prosthodontics. Hanover Park (IL): Quintessence Publishing; 1994. 25 p.
2. Neville BW, Damm DD, White DK, Waldron CA. Color atlas of oral pathology. Malvern (PA): Lee & Febiger; 1991. 323 p. **JCD**

About the Author: Dr. Guilbeau graduated from the Louisiana State University School of Dentistry in 1989, and holds a Fellowship and Mastership in the Academy of General Dentistry. He has been in private practice in Lafayette, Louisiana, for 21 years.

Author Disclosure: The author did not report any disclosures.



HOW MANY OF YOUR PATIENTS HAVE CROOKED TEETH?

"This is on of the best Orthodontic courses I have been to. If you have not taken this course, RUN, don't walk to the next available course!"

—Dr. Howard Farran, Dental Town

"This is an absolute 'no brainer' for dentists working to increase productivity."

—Dr. Bruce Baird, Productive Dentist Academy

"The Six Month Smiles® patient kits with indirect bonding trays are brilliant. They make ortho for GPs much easier and more profitable ... and you know I like that."

—Dr. Woody Oakes, The Profitable Dentist

SHORT TERM ORTHO FOR THE GENERAL DENTIST

SEMINAR SCHEDULE

Oct. 15-16..... Houston, TX
 Nov. 5-6..... Tampa, FL
 Nov. 19-20..... Las Vegas, NV
 Dec. 3-4..... Los Angeles, CA
 Jan. 7-8..... San Francisco, CA

Visit 6MonthSmiles.com for full schedule.

\$2,450 for Doctors
\$650 for Staff



SEMINAR INCLUDES:

- 2 days of training (includes hands-on)
 - training manual
 - marketing photos
 - office forms/consent forms
 - posters, brochures, logo, website listing
 - picture book, and much more!
- (16 CE Credits)

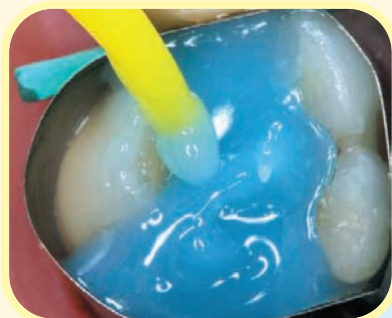REGISTER 4 WEEKS EARLY & GET 1ST PATIENT TRAY KIT™ FREE (\$518 VALUE)



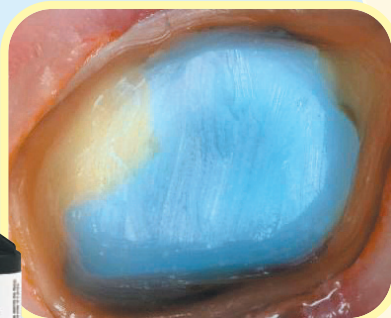
1-866-957-7645
www.6MonthSmiles.com

The Only Core Material That Preps Exactly Like Dentin!

INJECTION OF COSMECORE



FINAL PREPARATION FOR CROWN



Dentistry by Robert Margeas, D.D.S., F.A.G.D.

COSMECORE's excellent flowability makes dispensing easy.



COSMECORE is available in 3 versatile shades: White, A2, Blue.

COSMECORE™

A Powerful Dual-Cure Automix Resin Core Material

For high strength in core build-ups COSMECORE™ is it! COSMECORE is the only core material that actually cuts like dentin. Easy to use, COSMECORE eliminates the need for hand-mixing, has excellent flowability with no slump and preps exactly like tooth structure.

- The #1 rated Resin Core Material in dentistry
- Incredible strength for long-lasting results
- High depth of cure: saves you chairtime!
- Stacks well, cuts cleanly and preps like dentin
- Economical: one core build-up pays for whole tube
- Long working time, so it won't set up in the tube

What Clinicians Are Saying:

- "The very best core buildup material that I've tried!"
- "I want to report my clinical experience with COSMECORE. It is fantastic!"
- "Simulates dentin better than any core buildup material I have tried."
- "Excellent delivery and ease of mix."
- "Sets hard and cuts nicely." • "Used it, and loved it!"

COSMEDENT®

Spreading Smiles™

TRY OUR 30 DAY
RISK-FREE GUARANTEE.

to order **COSMECORE**
800-621-6729

WWW.COSMEDENT.COM

FOLLOW US ON FACEBOOK. 

Preserving Natural Tooth Structure with Composite Resin

Prashant Hatkar, BDS, MDS

Accreditation Clinical Case Report, Case Type V: Six or More Direct Resin Veneers

AACD Accreditation recognizes excellence in cosmetic dentistry. To obtain Accreditation, one must pass a written examination, submit clinical cases, and pass an oral examination. Cases encompass a broad range of treatment. Each case requires pre- and postoperative images and a written report. To pass, cases must meet standards set by the American Board of Cosmetic Dentistry. This section's objective is to support your goal of becoming Accredited.

Introduction

Scientific and technological advances in restorative materials and adhesive technology continue to enhance the practice of dentistry. Selecting the correct treatment option, based on patient age and functional requirements, will determine which treatment modality will be successful. Conserving tooth structure in young patients is paramount; therefore, the best treatment alternative to fulfill their restorative and esthetic needs usually is composite resin bonding.

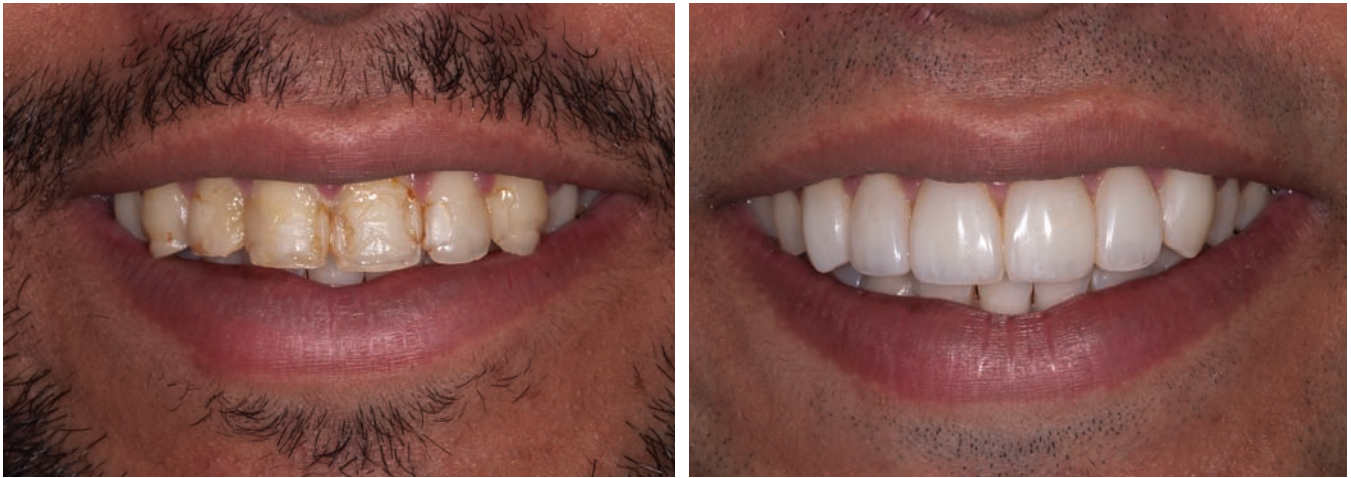Patient History

The patient was a 22-year-old male with no relevant medical history. His overall health was excellent, but he was very unhappy with the "unsightly" appearance of his smile. He had a history of substandard composite restorations, which included direct resin veneers placed on his front teeth by his previous dentist several years earlier. His chief complaint was that his front teeth appeared discolored, with irregular and rough surfaces. He desired whiter teeth and a new smile to "kick start" his professional career after graduation from college.

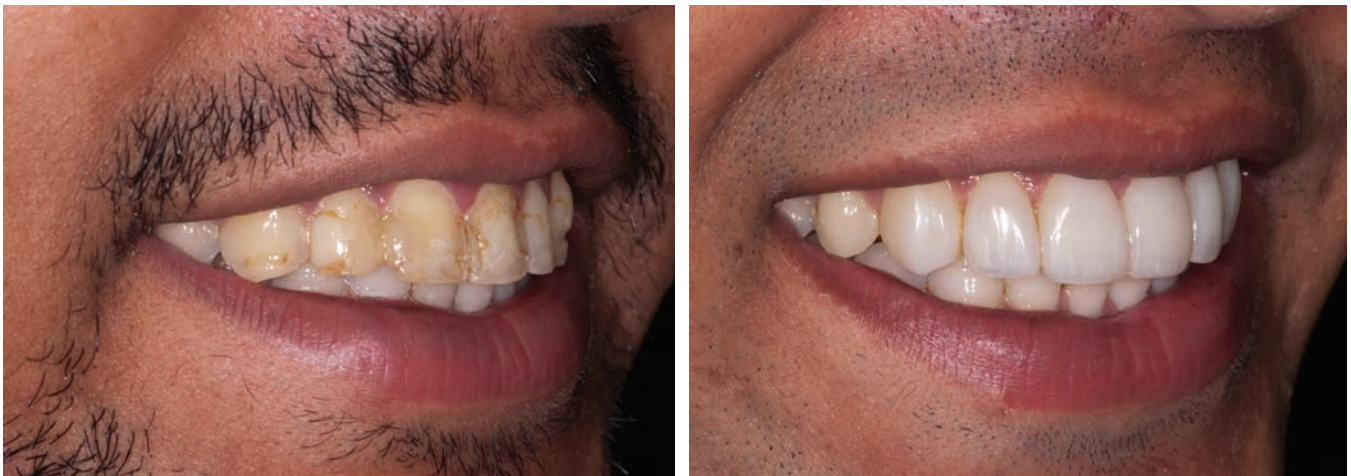This treatment modality was chosen because the patient was young and there was more than enough enamel remaining for excellent bonding.

Clinical Findings

The patient received a comprehensive examination and a full-mouth series of radiographs. The occlusal relationship of his teeth was Class I, with normal overjet and overbite with mild occlusal and incisal wear. His temporomandibular joints were asymptomatic, with no audible sounds and a normal range of motion. The patient's periodontal health was good, with no pocketing and no tooth mobility. There was mild marginal gingivitis associated with poorly placed com-



Figures 1a & 1b: Preoperative and postoperative frontal smile view displaying optimum esthetic plane following the lower lip curvature.



Figures 2a & 2b: Preoperative and postoperative right lateral smile view.

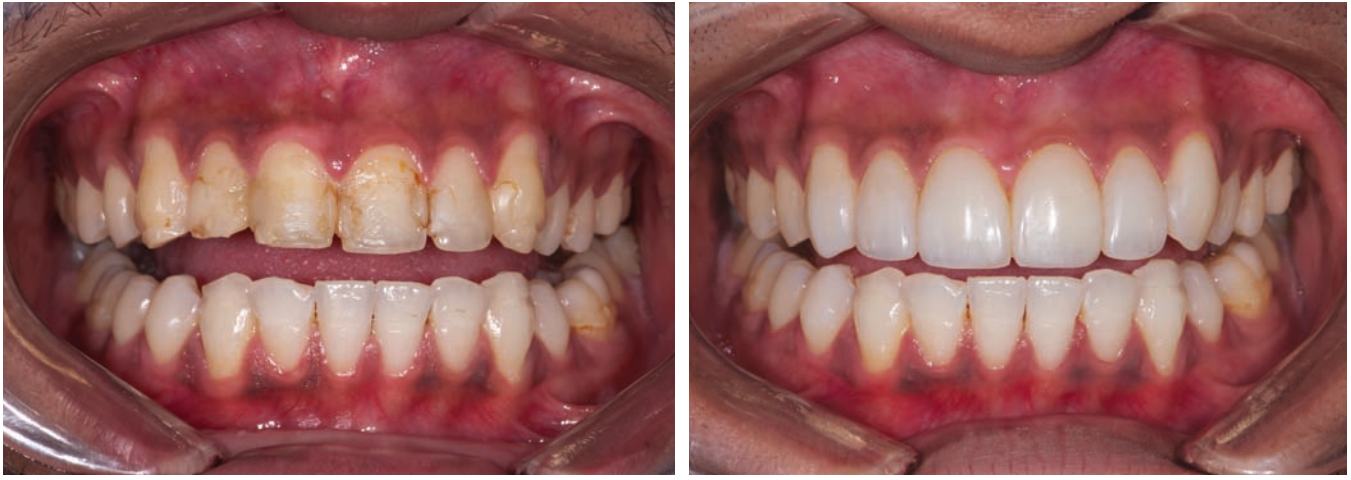posites in the region of ##6-9. Active carious lesions were present in several posterior teeth (##2, 3, 12-15, 18, 19, 30, and 31). The intraoral and extraoral soft tissues were normal in appearance (Figs 1a & 1b, 2a & 2b).

The preoperative esthetic analysis using smile design principles and AACD criteria¹ revealed the following findings:

- The smile display was adequate, with a well-developed buccal corridor.
- The smile line was incorrect, with #11 impinging on the lower lip in the smile view.
- There was inadequate symmetry and proportion between ##7-10.
- Teeth ##6, 8, 9, and 11 exhibited some form of enamel hypoplasia with notch-like defects bilaterally, especially in the incisal third.
- The mid-line appeared slightly canted and not perpendicular to the incisal plane.
- The axial inclination of all four upper incisors was incorrect, which gave them a flared appearance (Figs 3a & 3b).
- The interproximal contact areas apico-incisally between ##6-11 were too long due to faulty restorations, creating inadequate cervical embrasure forms and subsequent gingival inflammation between ##8 and 9.
- The shape and contour of ##6-11 were not properly developed.
- There was no evidence of surface characterization, polychromicity, and incisal translucency of the upper incisors.
- Incisal embrasures were improperly developed, with no progression in size from centrals to canines.
- There were several stained, chipped, and failing Class III composite restorations in ##6-11.

Treatment Plan

Because all the teeth were vital, it was decided to replace the old discolored and chipped composite restorations



Figures 3a & 3b: Preoperative and postoperative retracted frontal view showing correct axial inclinations and harmonious tooth proportion.

first and then conservatively restore the patient's smile with six direct composite resin veneers. This treatment modality was chosen because the patient was young and there was more than enough enamel remaining for excellent bonding. Direct resin veneers were chosen due to the conservative nature of the procedure. Since all the planned teeth had some previous bonding done, bleaching was not considered, as it would not have affected the outcome.

The final treatment plan was as follows:

- Remove and replace all failing restorations in anterior ##6-11.
- Restore all active carious lesions in posterior ##2, 3, 12-15, 18, 19, 30, and 31.
- Equilibrate to ensure occlusal stability and longevity of all restorations.
- Carry out direct intraoral mock-up of ##6-11.
- Fabricate a palatal silicone putty index.
- Place direct composite veneers on ##6-11.

Diagnostic Intraoral Mock-up

A higher-opacity dentin body material was used to mask the existing Class III restoration and create a base shade for subsequent resin buildups. A hybrid nano-filled composite was selected for this because of optical properties similar to

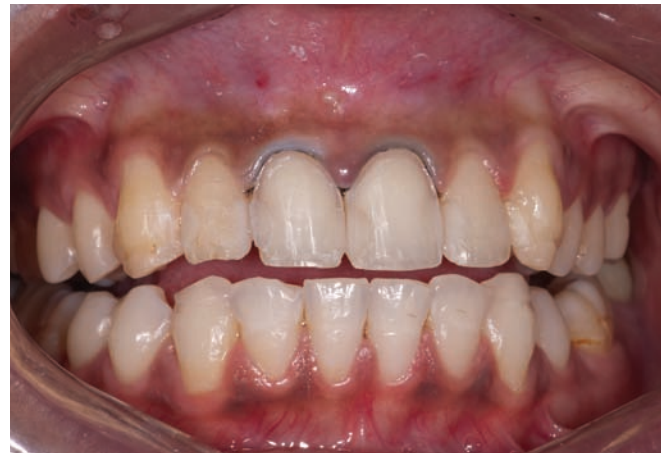

Figure 4: Retracted 1:2 view showing conservatively prepared central incisors with shallow chamfer gingival margin.

The preparations were very conservative, with gross axial reduction of 0.5 to 0.75 mm.

dentin. A slightly higher-chroma dentin material was used for the cervical thirds to impart polychromy. Incisally, a translucent microhybrid was applied to provide incisal depth. An enamel nano-composite was used as the final surface layer due to high surface wear resistance and long-term polish retention. All deficient areas were augmented using composites and proper incisal

form, and embrasures were developed. The incisal edge positions were checked for smile line improvement. After the necessary occlusal adjustments, a palatal index was intraorally fabricated using a polyvinyl siloxane putty material, which makes it possible to carry this incisal edge information to the patient's mouth during fabrication of composite veneers.²

The mock-up helped to evaluate the gross treatment outcome, to confirm choice of restorative materials and shade selection for the composite veneers, and to enable direct fabrication of a palatal silicone index as a matrix during the direct buildup.³

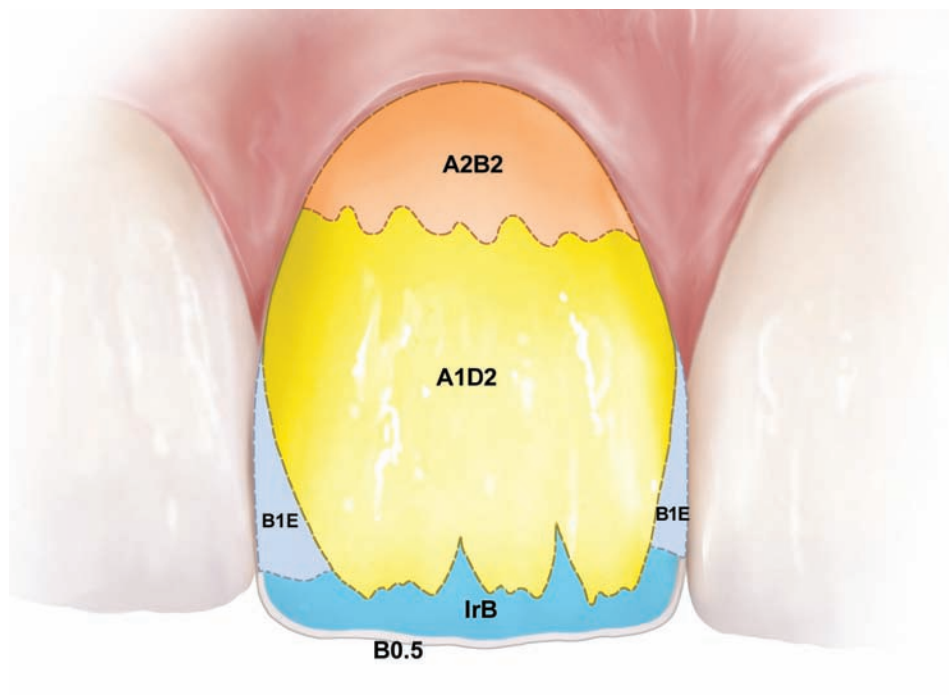


Figure 5: A color map shows the composite layering process for the restoration.

Treatment

Before the restorative phase started, the occlusion was analyzed on an articulator with well-mounted preoperative diagnostic casts. There was no significant discrepancy noted from centric relation (CR) to maximum intercuspation (MI). Protrusive movements revealed adequate disclusion of posterior teeth facilitated by the anterior guidance. Lateral movements revealed a normal canine-guided posterior disclusion. Minor occlusal equilibration was carried out by selective grinding so as to have stable holding contacts in MI. All excursive movements were verified to be free of any posterior interferences.⁴

Tooth Preparations

Teeth #6-11 were anesthetized using local infiltration with 2% lidocaine (Lignospan Special, Septodont; Saint-Maur-des-Fossés, Paris, France). All the old discolored proximal Class III composite restorations in #6-11 were first removed, the cavity preparations refined, the pulp protected with a bonded base technique and, finally, composite restorations were redone. Similarly, all active carious lesions were restored with direct composites (Synergy Duo, Coltene/Whaledent; Cuyahoga Falls, OH)

after adequate pulp protection (Vitre-bond Liner, 3M ESPE; St. Paul, MN).

The preparations were very conservative, with gross axial reduction of 0.5 to 0.75 mm. The gingival margin consisted of a shallow chamfer about 0.3

A color map had been created ahead of time as a blueprint for the incremental layering technique.

mm in depth, placed using a 6844-016 round-end two-grit tapered diamond (Brasseler USA; Savannah, GA). Replacing the old Class III composites allowed for a minimally invasive facial veneer preparation design. The preparations extended sufficiently interproximally to conceal the margins. The incisal preparation was very minimal.

All preparations were finished using flexible pop-on discs (Sof-Lex, 3M ESPE) and polished with a slurry of pumice and chlorhexidine (Consepsis, Ultradent; South Jordan, UT). This preparation design not only conserves natural tooth structure, but also provides maximum enamel substrate for

a stronger bond. Considering the patient's youth, he will one day need treatment again on these teeth. It serves the patient well to preserve the maximum amount of natural tooth structure when restorations need to be repaired or replaced (Fig 4).

Incremental Layering Technique

First the central incisors were built up, then the lateral incisors, and then the canines. Clear mylar strips were used interproximally to protect adjacent teeth from being etched. A total-etch technique was used with a fifth-generation dentin adhesive system (Adper Single Bond, 3M ESPE). The technique of starting first with one central incisor and then subsequently mimicking the second incisor with the completed one was followed.⁵ Tooth #8 was first etched with 32% phosphoric acid (Bisco; Schaumburg, IL) for 15 seconds and thoroughly rinsed. The preparation surface was dried, but not desiccated. Two to three coats of the bonding resin were applied and scrubbed with a micro-brush. The adhesive layer was thinned using an air syringe, then light-cured for 10 seconds.

A color map had been created ahead of time as a blueprint for the incremental layering technique

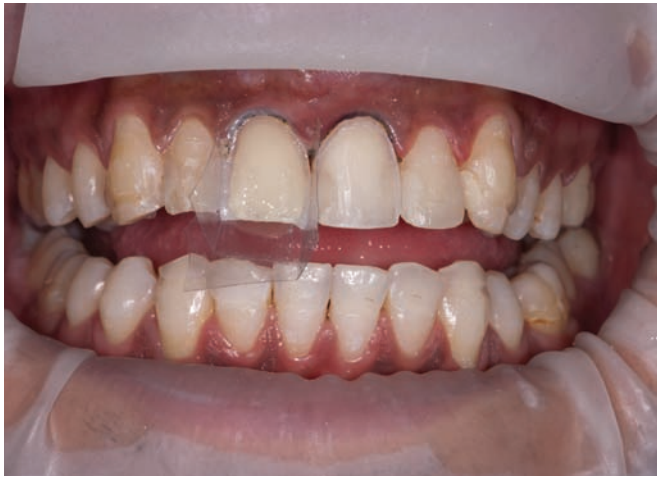

Figure 6: The body of the veneer was formed using a nano-filled composite A1D2 and sculpted to optimum contours.

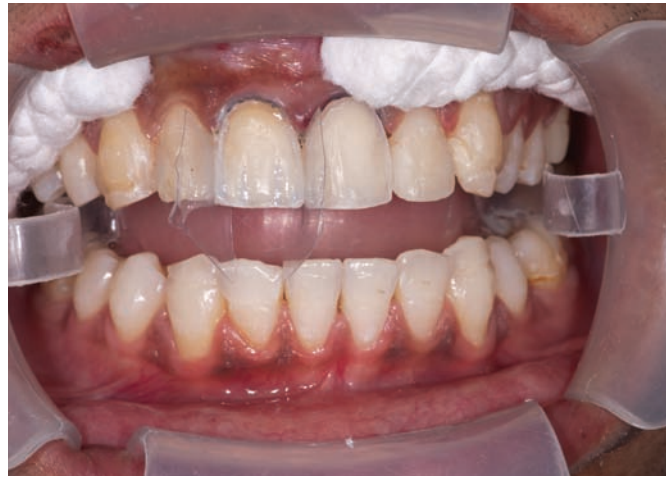

Figure 7: A bluish translucent composite was used between dentin lobes to impart natural incisal translucency.

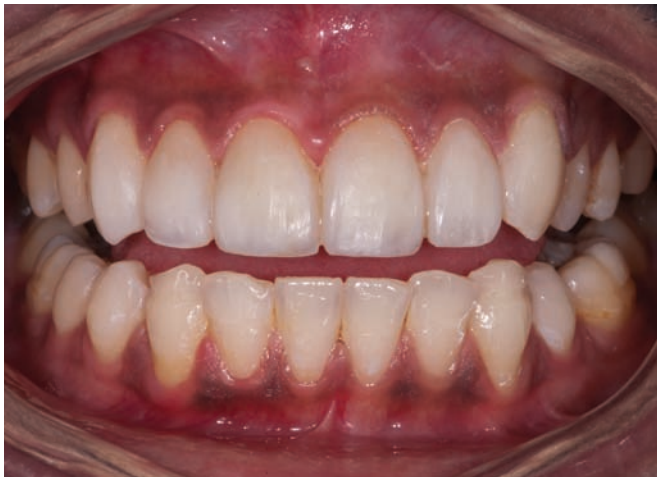

Figure 8: All teeth to be restored were built up prior to development of final labial contours.

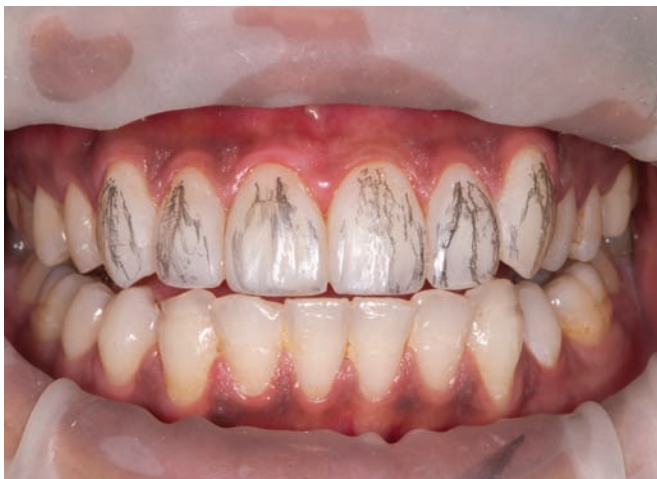

Figure 9: A lead pencil was used to mark the transitional line angles and the mid-labial ridges of all the teeth.

(Fig 5). The first layer of composite was used to create a palatal shelf (CT, Filtek Supreme XT, 3M ESPE). This composite layer served as “scaffolding,” on which further shades and opacities were built. The silicone putty matrix was first lubricated with a composite wetting resin (Ultradent) prior to composite application. The lingual shelf layer was light-cured and the index was removed. The next layer of composite was shade B1E (Filtek Supreme XT), which was used in the proximal areas to create and define the proximal borders. The composite material was sculpted using a Greenstein Color composite instrument (Safident; Gland, Switzerland). The next layer was the cervical higher chroma composite shade A2B2 (Synergy Duo), which was carried to the preparation and sculpted in the cervical area with the Greenstein instrument. A #3 artist brush (Cosmedent; Chicago, IL) was used with a wetting resin (Ultradent) for adaptation of the composite layer without any voids. The composite was pulled incisally with the brush to thin toward the middle third of the tooth. The body of the veneer was formed using dentin material shade A1D2 (Synergy Duo). This layer was sculpted toward the incisal third of the tooth (Fig 6).

Closer to the incisal edge, this material was cut irregularly into lobes to resemble the mammelons of central incisors using a P1 composite instrument (Ivoclar Vivadent; Amherst, NY). A very thin increment of a high-value hybrid composite, shade B0.5 (Filtek Z250) was carefully placed on the incisal-most portion to simulate a “halo” effect in the final restoration using the tip of the Greenstein instrument⁶ (Fig 7).

The area between the lobes was filled with a bluish translucent composite (IrB, Vit-I-escence, Ultradent) to impart the necessary incisal translucency. A final layer of B1E was used on the surface to complete the veneer buildup. A #2 artist’s brush was used to smooth, contour, and sculpt the composite layer prior to curing. De-ox gel (Ultradent) was applied on the entire surface of the ve-

WHAT WOULD YOU DO WITH 20 NEW PATIENTS EVERY MONTH?

(Hint)

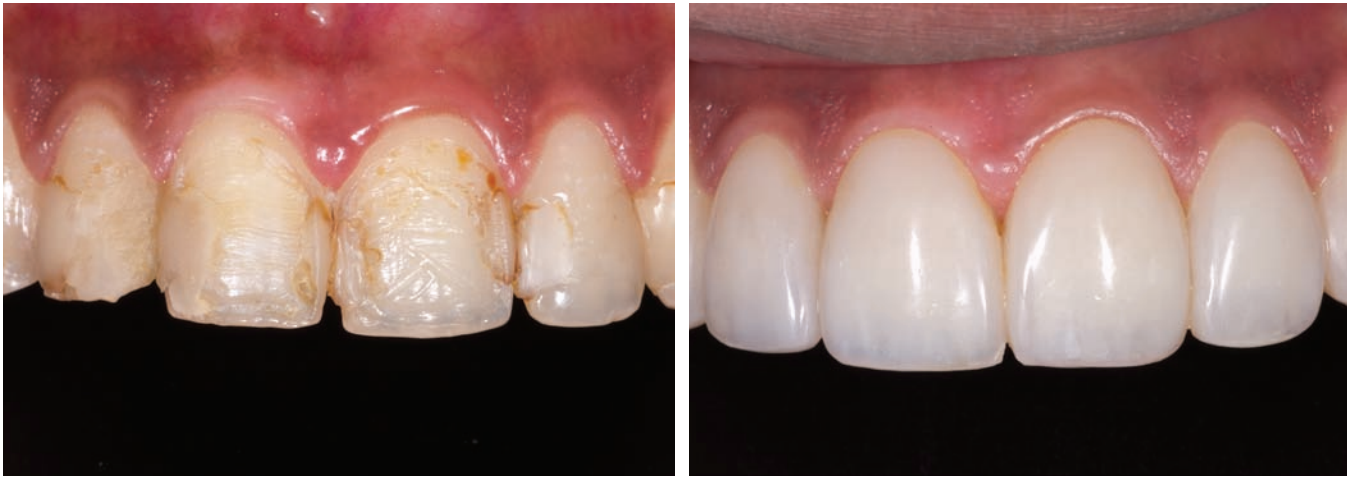Ask how we can provide you with a consistent flow of qualified new patients while bringing rewarding benefits to them and your local community.

Contact Us Today.

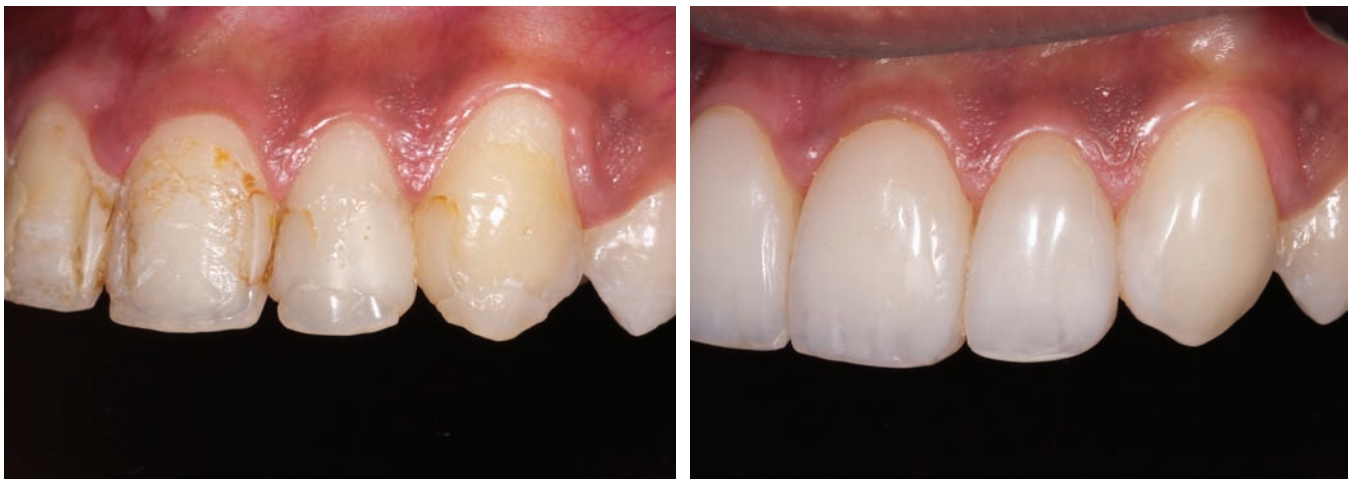Oral Aesthetic Advocacy Group Inc.
Lola Snidman, President, Founder
1.866.670.6579 ext. 2250



WWW.CDGO.ORG



Figures 10a & 10b: Preoperative and postoperative 1:1 retracted view showing creation of seamless natural esthetics with internal effects and translucency.



Figures 11a & 11b: Preoperative and postoperative 1:1 left retracted view showing greatly improved anatomic form of incisors and canines, higher canine chroma, and perfectly formed incisal embrasures.



Figures 12a & 12b: It was very rewarding to have such a happy, satisfied patient.

neer, after which final curing was done for 40 seconds. Gross contouring, refining, and finishing were carried out for tooth #8.

The above-described incremental layering technique was followed exactly for ##9, 7, 10, 6, and 11, in that order. For ##6 and 11, a slightly higher chroma cervical shade of A3B3 as well as a body shade of A2B2 (both Synergy Duo) were used (Fig 8).

Contouring, Refining, and Final Polishing

Some of the excess resin was removed from the surface of the restoration as well as from the margins with a #12 Bard-Parker surgical blade (Becton Dickinson; Franklin Lakes, NJ). The occlusion was checked and adjusted with a football-shaped carbide. The anterior and lateral guidances were also adjusted. The primary anatomic form and contours were achieved with a series of carbide finishing burs (Safe End Series Carbide Finishing Kit, S.S White; Lakewood, NJ). To maintain and refine the primary anatomy, a lead pencil was used to mark the line angles and the central prominence on the labial surfaces of all the veneer surfaces (Fig 9).

Excess removal and contouring was done with a 10-bladed carbide finishing bur (Safe End SE8-10) because it selectively removes the composite while conserving enamel.⁷ The three facial planes of contour were carefully developed without flattening out the line angles. A 20-bladed carbide bur (Safe End SE8-20) was then used to create a smooth surface ready for polishing. The short Safe End burs SE3 and SE4 were used for interproximal spaces and the transitional areas at the gingival margin. Coarse rub-

ber abrasive points and wheels, as well as Sof-Lex pop-on discs were used to refine the contouring, create appropriate embrasures, and develop secondary anatomy. Two grits of plastic abrasive strips were used to finish and polish the interproximal area. The veneers were then polished with a series

Composite resin restorations can replace lost tooth structure very quickly and conservatively with an excellent esthetic outcome.

of fine rubber abrasive points followed by silicone carbide-impregnated nylon bristle brushes. An aluminum oxide-based composite polishing paste (Enamelize, Cosmedent) was applied with a felt cone and used with light pressure to achieve a fine luster. A final step involved buffing the entire surface of the veneers dry with a felt cone at high speed but very low pressure. Postoperative and oral hygiene instructions were given and the patient was scheduled for follow-up and postoperative photographs after two weeks (Figs 10a & 10b, 11a & 11b).

Conclusion

Composite resin restorations can replace lost tooth structure very quickly and conservatively with an excellent esthetic outcome. The wide array of shades, translucencies, and opacities of composite systems available today allow superior control in the hands of an adept clinician to create truly beautiful, lifelike three-dimensional restorations. The use of nano-technology in composite fillers has enabled us to combine high fracture strength and long-term polishability. In this case, the use of direct composite resin veneers proved to be a very conservative cosmetic option that

Dr. Hatkar shares his experiences with Case Type V in a Q&A with Dr. James Peyton.

Q: Can you address how you chose an ideal patient for your direct resin veneer case?

I select composite veneers as my restorative choice for esthetic rehabilitation of a smile in the following situations:

- In young patients where the pulp volume is at a maximum. (More aggressive preparations are required with indirect porcelain veneers, which may compromise pulp vitality.)
- In younger patients' teeth, irrespective of the type of restorations done. They would require replacement in the restorative cycle at some point, so tooth conservation is vital.
- In cases with virtually stable and harmonious occlusal relationships with no or minimal parafunctional activity.
- When minimal changes are required in the form or shape of teeth, except shade improvements and/or coverage of surface defects.
- For patients with time constraints, composite veneers enable the clinician to provide outstanding esthetics quickly.

Q: What were your major concerns and how did you handle them?

Some of the major concerns in my direct resin veneer case were:

- canted midline
- flared incisors
- faulty tooth form, contours, and surface topography
- bilateral asymmetry as well as inappropriate tooth proportions
- improperly developed incisal embrasures.

The direct intraoral composite mock-up was done preoperatively. This helped to confirm choice of restorative materials and shade selection for the composite veneers, and to enable direct fabrication of a palatal silicone index as a matrix during the direct buildup. It also provided an opportunity for esthetic, phonetic, and occlusal evaluation. It confirmed that all major issues of mid-line cant, faulty axial inclinations, and tooth proportions were addressed. The incremental buildup of the veneers was formulated and mapped. The pre-decided shades of composites were used with the previously made silicone index to sequentially build up teeth ##8 and 9, then 7 and 10; and, lastly, 6 and 11. Following proper contouring and polishing steps, I could address most of the initial concerns and achieve an optimal esthetic result.

there's more...

yielded great patient satisfaction. The patient's expectations were more than fulfilled (Figs 12a & 12b), which was immensely satisfying.

References

1. American Academy of Cosmetic Dentistry. Diagnosis and treatment evaluation in cosmetic dentistry: a guide to Accreditation criteria. Madison (WI): The Academy; 2001.
2. Dietschi D. Layering concepts in anterior composite restorations. *J Adhesive Dent.* 2001;3(1):71-80.
3. Peyton J. Mastering anterior direct composite resins to achieve accreditation results. Presented at the 24th Annual AACD Scientific Session; New Orleans, LA, May 8, 2008.
4. Dawson PE. Functional occlusion: from TMJ to smile design. St. Louis: Mosby; 2007.
5. Finlay S. Accreditation clinical case report, Case Type V: six or more direct resin veneers. *J Cosmetic Dent.* 2008;24(3):50-8.
6. LeSage B, Milnar F, Wohlberg J. Achieving the epitome of composite art: creating natural tooth esthetics, texture and anatomy using appropriate preparation and layering techniques. *J Cosmetic Dent.* 2008;24(3):132-41.
7. Glazer HS. Simplifying finishing and polishing techniques for direct composite restorations. *Dent Today.* 2009 Jan;28(1):122,124-5. **JCD**

Q & A continues

Q: What was your greatest influence in learning how to perform direct resin veneers?

My first exposure to Accreditation-level composite artistry was at a hands-on workshop conducted by Dr. Corky Willhite at the 2007 Annual AACD Scientific Session. The step-by-step guidelines that you, Dr. Peyton, gave in your direct resin course handouts at the 2008 Annual Scientific Session were very helpful. Another major influence was a hands-on workshop on direct composite veneers by Dr. Brian LeSage, Dr. Frank Milnar, and Jenifer Wohlberg at the 2009 AACD Session. The 2009 session was a turning point for me; it made me see the innumerable "invisible" criteria that make an Accreditation case successful. I am grateful to the AACD for providing the highest level of continuing education that brings out the best of a clinician's abilities.

Q: How comfortable do you feel in offering direct resin veneers as an alternative treatment option to porcelain veneers?

Over the years I have continually improved my abilities in handling composites. In India, due to lack of excellent laboratory support and economic concerns, our comfort level has always been high with direct resin veneers as a treatment alternative over porcelain veneers. The variety of shades, opacities, and translucencies combined with improved physical properties and longevity of modern composite resins make them a versatile and economically viable option, while being conservative with natural tooth structure.

Q: What challenges have you faced while working toward Accreditation due to your location?

Being in India, I had many challenges to complete each of the five Accreditation cases:

- Currently there are no laboratories in India that are fully acquainted with Accreditation-level quality in their work, or laboratory technicians who are AACD members. Effective communication with technicians about the quality of Accreditation-level work is difficult.
- Outsourcing laboratory work to any major lab in the U.S. is financially taxing for clinicians here, due to considerable differences in practice and fees. Our resources in restorative dental materials and techniques are still very limited, so we need to import from the U.S. For example, two-component silane and the composite sculpting brushes were not available in India when I procured them from the U.S. Also, while I was working on Case Type I, there were only two hard-tissue lasers in India and we had difficulty accessing them. However, I was able to use a hard-tissue laser to perform a closed flap crown-lengthening procedure with osteoplasty on my Case Type V patient.
- With the advent of pressable ceramics, a highly esthetic option like stacked feldspathic veneers has virtually been discontinued in most Indian laboratories due to poor demand and more technique-sensitive fabrication, thus increasing our dependence on outsourcing work abroad.
- Our exposure to world-class educators and courses, although increasing, is still limited compared to the U.S. or Europe.



About the Author: Dr. Hatkar is Professor and Head of the Department of Conservative Dentistry and Endodontics at the School of Dental Sciences, Krishna Institute of Medical Sciences University in Karad, Maharashtra, India. **Author Disclosure:** The author did not report any disclosures.

Examiners' Observations

Mastering the Criteria for Accreditation Case Type V

Scott Finlay DDS, FAGD, AACD Accredited Fellow
Illustrations by Dave Mazierski

Successful management of Case Type V does not occur by accident. Many candidates consider it to be the most taxing of the required case types. Because of the arduous demands placed on the dentist, case selection is crucial. Selecting a case with the appropriate indications, but without complicating multidisciplinary factors, will certainly increase the opportunity for a favorable outcome.¹ No extra points are given for undertaking a complex case. In fact, the opposite is true; points can be deducted for falling short of resolving all the complicating factors. Case selection involves an assessment not only of the clinical aspects of the case, but also of the emotional appraisal of the patient's willingness and availability for extended chair time and the probability of multiple visits. Candidates can avoid frustration and disappointment connected with an inordinate amount of time spent on a case that does not provide the best opportunity to display their talents, skills, and knowledge, by working with and reviewing potential cases with a mentor.

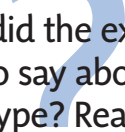
Selecting a case with the appropriate indications, but without complicating multidisciplinary factors, will certainly increase the opportunity for a favorable outcome.

Examiners certainly have a deep appreciation for the toil and commitment involved in Case Type V. Their calibrated focus engages several important criteria with the simple question: Has the candidate achieved excellence? "Excellence" indicates a mastery of skill and knowledge and should not be viewed as an attempt at perfection. In Case Type V, the examiners are looking at the candidate's ability to manage the parameters of smile design and choreograph the application of direct resins to create a natural appearance. Case Type V is also a technique case. The candidate must capture images that illustrate the chronological process used to accomplish the results. In an era of responsible esthetics, in most situations this particular case type lends itself to very conservative tooth preparations. Deliberate, uniform, and aggressive preparations are no longer necessary to create an esthetic and natural result.

Dr. Hatkar should be complimented on his management of this demanding case. He carefully assessed the functional and esthetic requirements through model analysis and mock-ups prior to initiating treatment.² He did his homework. Although this case required absolute recreation of the facial surfaces of the teeth, the multidisciplinary features of the case were minimal. The occlusal scheme required very little augmentive correction and the periodontal architecture did not require significant changes. His technique slides revealed great conservation of existing tooth structure to achieve the desired result. Dr. Hatkar also utilized a stratification layering technique that was effective in creating a polychromatic, natural result.³

The examiners passed Dr. Hatkar's case unanimously. Some criteria, however, are worthy of comment.⁴

- 34. *Is the photography free of excess moisture and debris?* Candidates will present their best opportunity for success by having photography that is free of all debris. Debris was noted between teeth #6 and #7.



What did the examiners have to say about this Case Type? Read on.

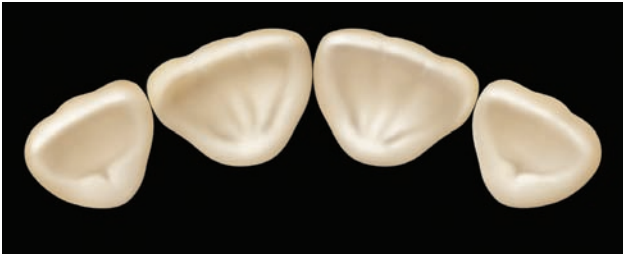

Figure 1: The occlusal view is an excellent perspective from which to evaluate the management of proximal contours, line angles, and facial embrasures.

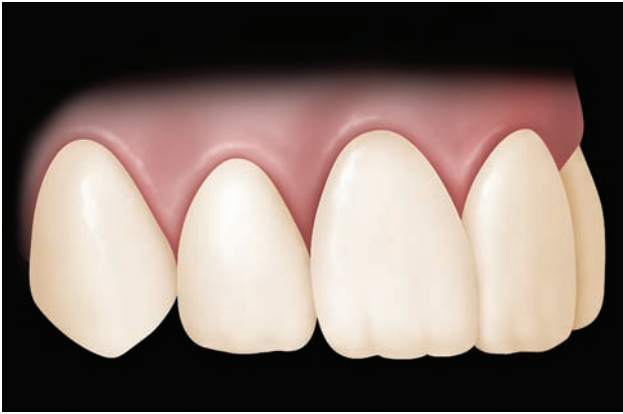

Figure 2: The lateral views should visually define the presence of the multiple planes of facial contour typically observed in nature.

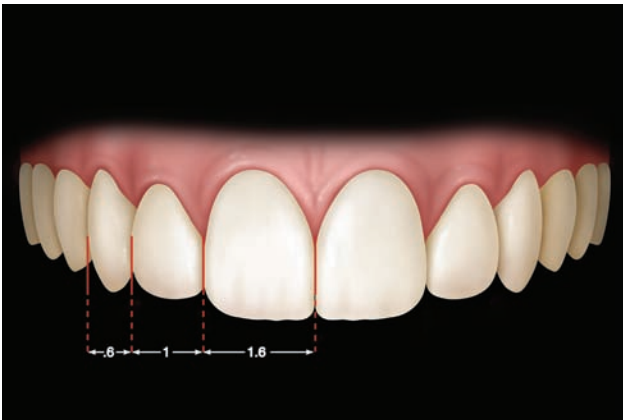

Figure 3: This proposed proportion is based upon the visually apparent width from the frontal view. Contralateral teeth should display balance and harmony. In particular, the central incisors should mirror each other.

- 42/43. Is the labial anatomy (primary, secondary, and tertiary) appropriate? Are there three planes for the labial contour of the central incisor? Have line angles been properly developed? Management of the line angles and facial anatomy often can be best evaluated from the occlusal view. A common fault seen in Case Type V is the elimination or muting of carefully developed facial anatomy and line angles in the process of finishing the case. From the occlusal view, the slightly convex contours of the facial surfaces of ##8-11, and the lack of harmony and definition of the mesial and distal line angles were noted (Figs 1 & 2).⁵
- 61. Is margin placement and design appropriate? Are the margins visible? The restorative material should blend invisibly with the surrounding tooth structure. Upon reasonable examination, it should be difficult to discern restorative material from the tooth.⁶
- 87. Are contralateral teeth in harmony in terms of size, shape, and position? Candidates will find that in Case Type V, a significant amount of effort will be focused on creating symmetrical contralateral teeth, which always begins with the centrals. In this case, the lack of balance between the centrals was noted (Fig 3).⁷

Most criteria noted to be deficient in Dr. Hatkar's case were considered to be minor faults. This case represents a very good example of a dramatic improvement in the patient's appearance, as well as a demonstration of mastery of the criteria required to meet the standard of excellence in Case Type V.

References

1. Dietschi D. Optimising aesthetics and facilitating clinical application of free-hand bonding using the 'natural layering concept.' Br Dent J. 2008 Feb 23;204(4):181-5.
2. Dawson PE. Functional occlusion: from TMJ to smile design. St. Louis: Mosby; 2007. p. 366-77.
3. Finlay S. Conservative esthetics using direct resin. Inside Dent. 2010 May;6(5):96-101.
4. American Academy of Cosmetic Dentistry. Accreditation examination criteria. Madison (WI): The Academy; 2009.
5. Blitz N, Steel C, Willhite C. Diagnosis and treatment evaluation in cosmetic dentistry: a guide to Accreditation criteria. Madison (WI): American Academy of Cosmetic Dentistry; 2001. p. 22-24.
6. *ibid.*, p. 41-42.
7. *ibid.*, p. 16-17. **JCD**



About the Author: Dr. Finlay is an AACD Accredited Fellow and has been an AACD Accreditation Examiner since 2008. A 1986 graduate of the University of Maryland, Baltimore College of Dental Surgery, Dr. Finlay practices in Arnold, Maryland.

ARE YOU *next?*

“INSTEAD OF GIVING MYSELF REASONS WHY I CAN’T,
I GIVE MYSELF REASONS WHY I CAN.” -AUTHOR UNKNOWN



Here are nine reasons why you can be.
Meet the nine newest AACD Accredited
members who have achieved
excellence in cosmetic dentistry.
They decided it was their time.
Are you next?

To start the journey, visit www.AACD.com

AACD American Academy
of Cosmetic Dentistry®

Strengthening Your Bond

Practical Tips for Accreditation Case Type V

James H. Peyton, DDS, AACD Accredited Fellow
Illustrations by Dave Mazierski

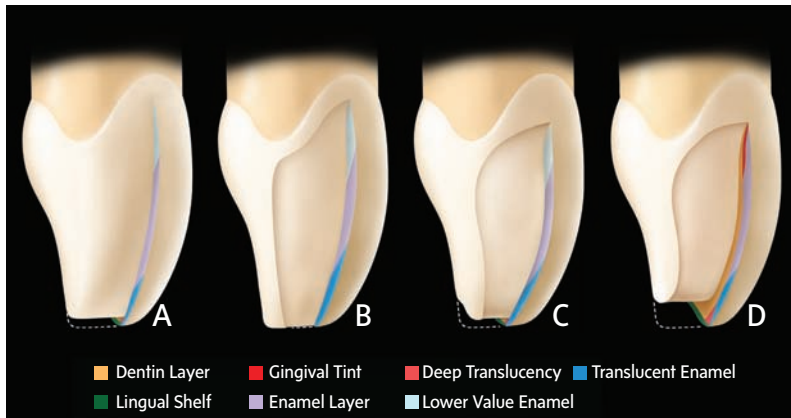


Figure 1: Side view of composite layers: A. Simple layering, no preparation. B. Simple layering, minimal preparation. C. Simple layering, incisal buildup. D. Complex layering for dark teeth.

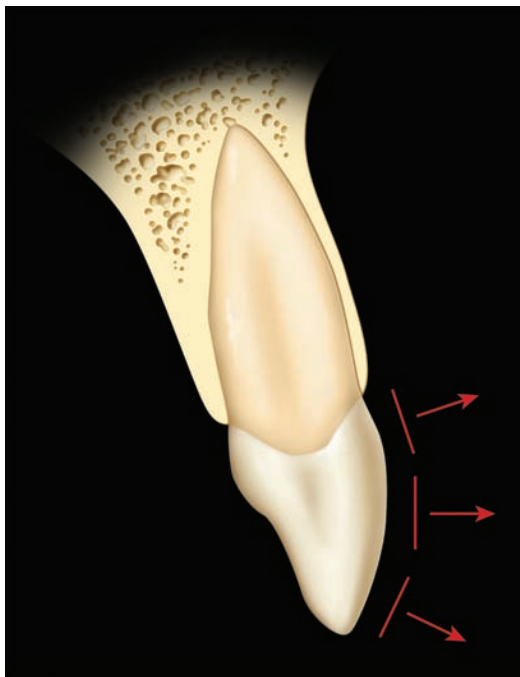


Figure 2: The three planes of facial contour.

- **USE A MENTOR!**
- **CASE TYPE V** is one of the most difficult case types and requires multiple appointments. Select a patient who is a willing participant. If a patient becomes impatient, nervous, and does not keep appointments, achieving an Accreditation-level result will be difficult.
- **SELECT A CASE** that is not too complex. Healthy gingiva and teeth are critical, and gingival position must be ideal. The golden proportion will not be achieved if teeth are severely worn or spaced too far apart. If orthodontics or gingival surgery is needed, do it to create the ideal case. The examiners deduct points if these problems are not corrected. Try to select a case where your only concern is layering the composite on the tooth correctly. Restoring six or more direct resin veneers is very difficult—do not try to make it even more complex.
- **TO OBTAIN AN** Accreditation-level result, the finishing and polishing of the restorations is an important factor. Many unsuccessful cases could have been successful by correcting the anatomy, redefining line angles, and achieving a nice surface polish. Develop your polishing technique prior to completing this case. Over-polishing wipes out much of the anatomy you spent great effort creating.
- **ATTEND SOME DIRECT** composite resin “hands-on” workshops at the Annual AACD Scientific Session. More extensive multiple-day composite resin workshops are available to improve your skills while on your road to Accreditation success.¹
- **PHOTOGRAPH MANY HIGH-QUALITY** images before you start. Ask a mentor to review your case for the correct images, good image quality, and to verify that the case is appropriate for Accreditation.
- **TAKE STUDY MODELS** and do a diagnostic wax-up before you start.

- **USE A PUTTY** matrix when the incisal edge position is being altered. Construct a putty matrix from the diagnostic wax-up or directly from a mock-up in the patient's mouth. Make this in advance to save time.²
 - **MAKE A DETAILED** color map of the composite material layers to be used in the procedure. Do this ahead of time to aid in setting up all the composite material needed for the appointment.
 - **ORGANIZE THE ROOM** in advance. Have all necessary materials laid out and ready for use. If what you need is not at hand, you may tend to stop what you are doing or skip that step. Be prepared.
 - **PRACTICE YOUR DIRECT** resin veneer case on a stone model or typodont ahead of time. Use the same material you plan to use on your patient. Make the same tooth preparation design on the model as you plan to do intraorally. This is your "dress rehearsal" prior to the clinical appointment. You can practice the layering of composite, achieving the primary anatomy, seeing if you have a polychromatic restoration, and seeing how your material can achieve a high polish (Fig 1).
 - **LEARN HOW TO** establish primary anatomy with a direct resin veneer. Review your anatomy text, talk to your laboratory technician, and seek help from a mentor.³ Practice this in wax or with composite material. Be certain you know where the incisal edge position should be, and where the transitional line angles and the three planes of facial contour should be⁴ (Fig 2).
 - **READ AND STUDY** *Diagnosis and Treatment Evaluation in Cosmetic Dentistry: A Guide to Accreditation Criteria*, published by the AACD.
- You will find great pointers on smile design, contours, proportion, materials, photography, and many more factors that are important to Accreditation success.⁵
- **THE FIRST-STEP** in contouring is to create the facial-incisal line angle.⁶
 - **MAKE THE CENTRAL** incisors mirror images of each other in every detail. A caliper is helpful to measure the widths of each tooth.⁷
 - **BE SURE THERE** is no midline cant. After completing the first central, have the patient stand up and check from several directions that the mesial surface is straight up and down. Complete the second central and again look to be sure the midline is correct.
 - **DRAW PENCIL LINES** on the transitional line angles to check for symmetry and position.
 - **OPEN UP THE** facial and incisal embrasures with a disc that is thin, small, and coarse.
 - **THE INCISAL VIEW** (mirror view) is an important view for checking facial contour and facial embrasures.
 - **ALLOW PLENTY OF** time for the procedure. Setting the whole day aside, with no interruptions, would be ideal. Consider working on a non-production day; if you finish early, great. If you need more time, you will not feel rushed. On the first day plan on doing just the primary anatomy and adjusting the occlusion. At a later date have the patient return for final contouring and polishing. Take photos, send them to a mentor and follow up with his/her advice. Take a postoperative impression to evaluate the restoration contour and anatomy. You can then evaluate the case with fresh eyes prior to the

patient's next visit. Create a specific list of things you want to accomplish during the next visit and adhere to it. A tendency to stray from your mission as you intently work through the appointment can result in losing many details you worked hard to develop.

- **BE REALISTIC IN** what you plan to accomplish at each appointment. Initially, most of your time will be spent developing the #8 and #9 contours. Do not rush; the remaining teeth will move along faster. At the initial appointment, you may only accomplish the anterior four teeth.

References

1. Peyton J, Arnold J. Six or more direct resin veneers case for Accreditation: hands-on typodont exercise. *J Cosmetic Dent.* 2008;24(3)38-48.
2. Finlay S. Accreditation clinical case report, Case Type V: six or more direct resin veneers. *J Cosmetic Dent.* 2008;24(3)50-8.
3. Baratieri LN. Esthetics: direct adhesive restoration on fractured anterior teeth. Hanover Park (IL): Quintessence Pub.; 1998. p. 35-46.
4. Peyton J. Finishing and polishing techniques: direct composite resin restorations. *Pract Proced Aesthet Dent.* 2004;16(4)293-8.
5. American Academy of Cosmetic Dentistry. Diagnosis and treatment evaluation in cosmetic dentistry: a guide to Accreditation criteria. Madison (WI): The Academy; 2001.
6. Fahl N Jr. Mastering composite artistry—creating anterior masterpieces. Presented at the 26th Annual AACD Scientific Session; Grapevine, TX, April 30th, 2010.
7. Rufenacht C. Fundamentals of esthetics. Hanover Park (IL): Quintessence Pub.; 1990. p.87-94. **JCD**



About the Author: Dr. Peyton is an AACD Accredited Fellow and has been an AACD Accreditation Examiner for six years. A part-time instructor at the UCLA School of Dentistry, he practices in Bakersfield, CA.

Author Disclosure: The author had no disclosures to report.

A STEP-BY-STEP APPROACH TO A DIASTEMA CLOSURE

A Dual-Purpose Technique that Manages Black Triangles

Marcos Vargas, DDS, MS

Introduction

Freehand direct resin composites provide an esthetic and conservative approach for closing diastemas and should be part of the armamentarium of every cosmetic dentist. By applying a step-by-step approach to diastema closure when using direct resin composites, the practitioner has the opportunity to creatively incorporate shade selection, tooth preparation, material selection, composite layering, material blending, proper gingival contouring, and polishing to close diastemas in a predictable and efficient manner in daily practice.

This article summarizes the technique demonstrated by the author at the 2010 AACD Annual Scientific Session for artistically using direct composite resins to close diastemas. Consideration is given to creating an ideal emergence profile for gingival health, as well as to managing “black triangles.” Few techniques are available to close diastemas. This technique is well suited for non-slumping and non-sticking materials.

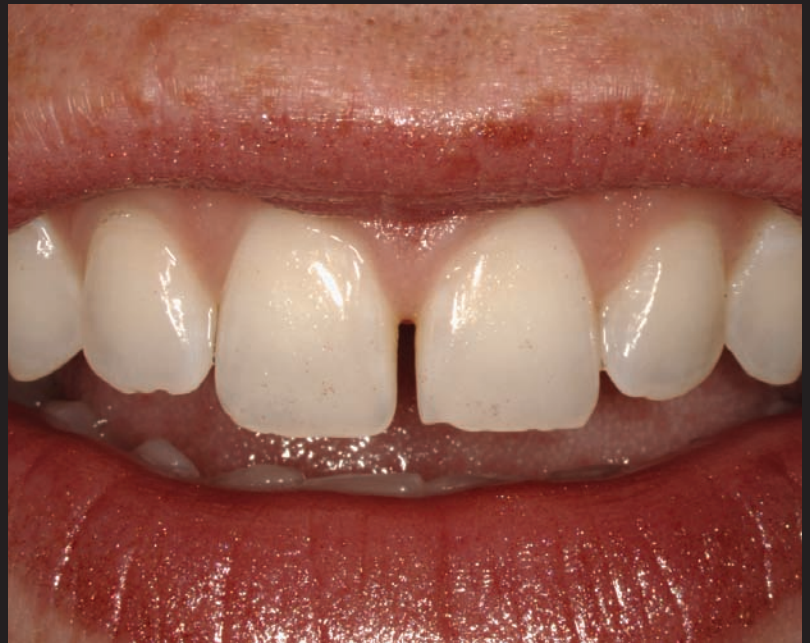

Figure 1: Preoperative view of a patient who presented with a diastema between teeth #8 and #9.

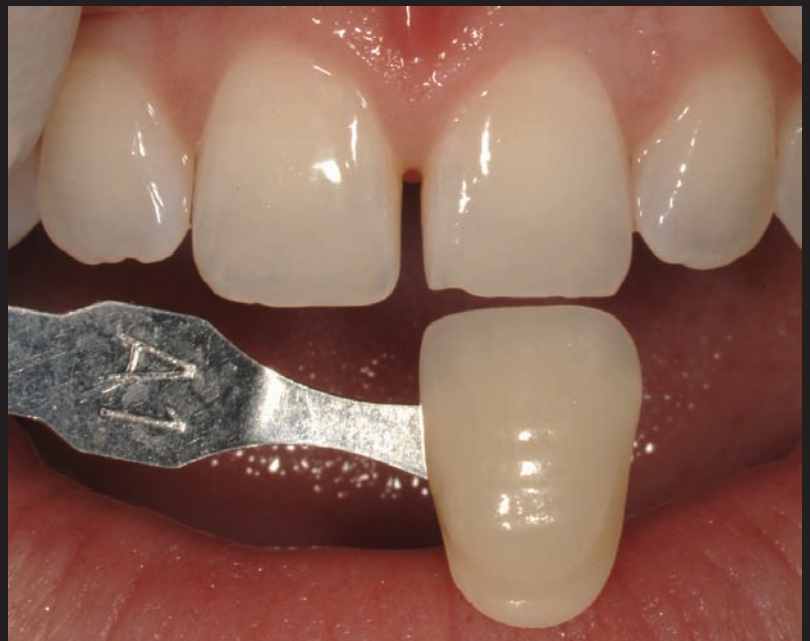

Figure 2: The appropriate shade of direct composite is selected.

This technique is well suited for non-slumping and non-sticking materials.



A1B

What if your composite was more wear-resistant with lasting polish?

It would mean that your patients' restorations can last—and year after year, look as good as the day you placed them.

Especially with restorative work, your reputation is on the line. No other composite is able to match the combined wear resistance and esthetics of Filtek™ Supreme Ultra Universal Restorative. Because of our “TRUE” nanotechnology, it looks and wears like the real thing.*

▶ See why 3M ESPE's “TRUE” nanotechnology is so unique and appealing to dentists, PLUS watch videos, from funny to informative, at www.EveryoneHasAShade.com.

Filtek Supreme Ultra restorative.
One simple shading system ...
endless possibilities.

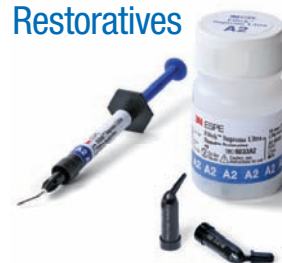▶ Call 800-634-2249 or visit www.3MESPE.com/Filtek



Capsules are now color-coded by opacity.

Filtek™ Supreme Ultra

Universal and Flowable Restoratives



Our new flowable is available in capsules.

3M ESPE

© 3M 2010. All rights reserved. 3M, ESPE and Filtek are trademarks of 3M or 3M ESPE AG. Used under license in Canada.
*In vitro data on file.

Case Presentation

A 27-year-old female concerned with the space between her front teeth presented to our practice (Fig 1). The patient also stated that a friend had their diastema closed, but that a black space was left between the buildups and the gingiva (i.e., black triangles). It was explained that a black triangle results from the architecture of the bone and the distance between the contact points and the crest of the bone.¹ The option of closing the diastema with resin composites was presented to the patient, who agreed to the proposed treatment plan.

Shade and Opacity Selection

Tooth shade should be obtained by comparing the center middle-third of the tooth against the middle of the shade tab (Fig 2). An enamel-like opacity material is usually selected when closing diastemas up to 2 mm. Larger diastemas may require layering of a dentin-like opacity material to prevent show-through, followed by an enamel-like opacity material.

Isolation

Rubber dam isolation with ligatures is recommended. The rubber dam keeps the operatory field dry and free of contaminants. The ligatures help the rubber dam push the gingiva apically, to allow access to the proximal gingival areas for ideal contouring and polishing of the restorations.

Tooth Preparation

Usually, tooth preparation is not required when closing a diastema. In situations where the teeth are slightly misaligned (Fig 3), a slight recontouring may be necessary when the teeth are positioned facially. On the other hand, no preparation is necessary when the teeth are lingually positioned. Roughening of the enamel is recommended only when self-etch adhesives are to be used. Following tooth preparation, the enamel surface of both teeth is etched for at least 30 seconds (Fig 4), after which the adhesive bonding agent is placed and cured (Fig 5).

Material Selection

Composite resin materials for this technique must demonstrate handling characteristics that enable placement without slumping or sticking to placement instruments. Few commercially available resin composites (e.g., Estelite Sigma, Tokuyama [Tokyo, Japan]; Filtek Supreme Ultra, 3M ESPE [St. Paul, MN]; Premise, Kerr [Orange, CA]; Renamel Microfill, Cosmedent [Chicago, IL]) demonstrate the handling characteristics for this particular diastema closure technique.

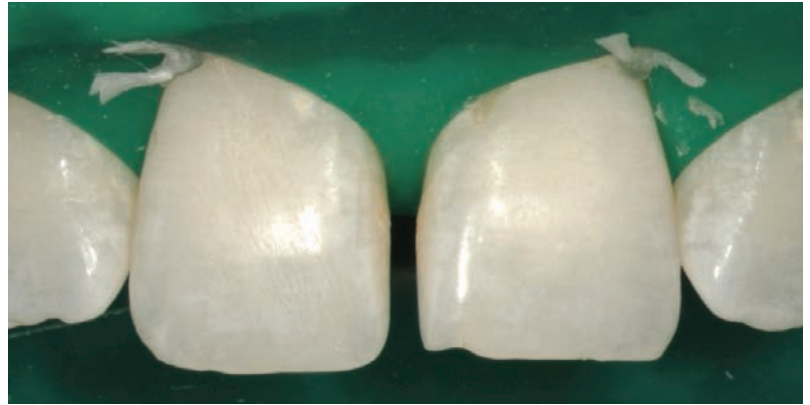


Figure 3: The enamel surface of the teeth is minimally prepared for composite placement.

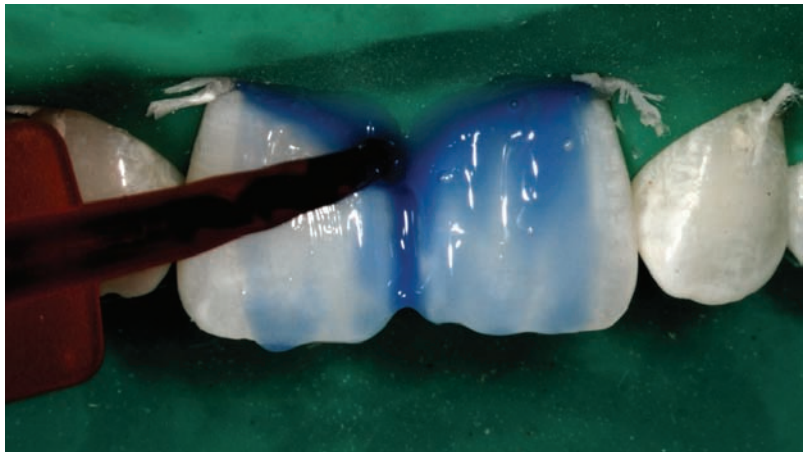


Figure 4: The enamel surface of teeth #8 and #9 is etched.

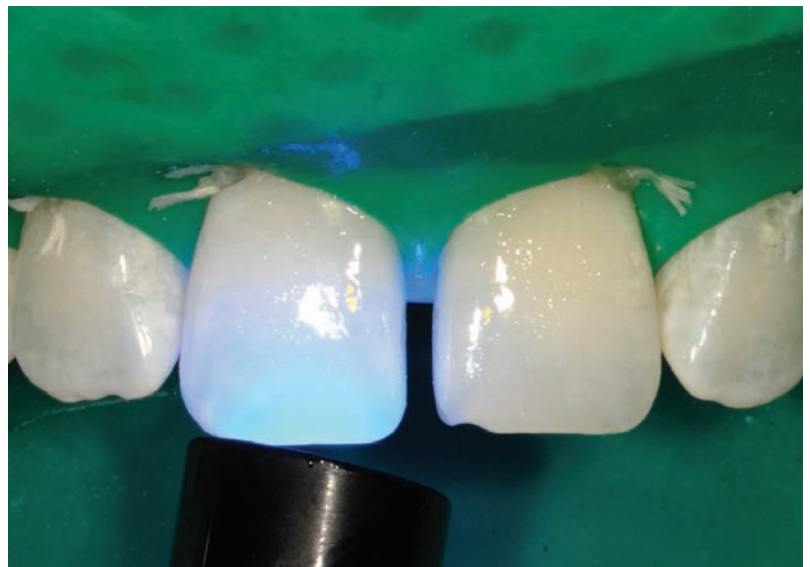

Figure 5: An adhesive bonding agent is applied to the preparations and light-cured.

Using a #12 blade, remove any excess material gingivally to the contact point.

Material Placement

The steps are as follows:

Step 1. A small increment of the appropriately shaded composite resin that corresponds to the facial half of each diastema is placed over the mesiofacial aspect of each tooth. These increments are placed simultaneously and contoured to ensure optimal contour and identical width for both central incisors (**Fig 6**). Attention should be given to blending the increments over the facial surface.

Step 2. Using a thin-bladed interproximal carver (IPC) instrument, contour the increments to match each other's profile and ensure adequate gingival embrasure and emergence profile (**Fig 7**).

Step 3. A metal matrix is sometimes utilized to produce a small separation between the two increments. A small brush is used to smooth the composite resin surface and approximate the increments (**Fig 8**). Light-cure the increments (**Fig 9**).

Step 4. Place a matrix against one of the central incisors and layer the lingual half of the diastema between the tooth and the matrix. Push this increment facially, close the matrix against the tooth, and pull it through toward the facial to ensure proper lingual contour (**Fig 10**). If excess composite remains in the gingival embrasure, remove it prior to light-curing.

Step 5. Light-cure the direct resin buildup and repeat Step 4 for the other central incisor.

Finishing and Polishing

Using a #12 blade, remove any excess material gingivally to the contact point. Sof-Lex disks (3M ESPE) and a coarse polishing cup were used to contour the facial surface of the restorations (**Fig 11**). Create surface characteristics with a diamond bur, without water irrigation (**Fig 12**).

Proximal polishing was achieved by sequentially using polishing strips (Eptax strips, GC America; Al-sip, IL). Polishing cups (HiLuster, Kerr) were used to create the restoration's final luster and surface anatomy (**Fig 13**).

In this case, the patient was scheduled a week later to evaluate her satisfaction, gingival healing, and marginal adaptation.

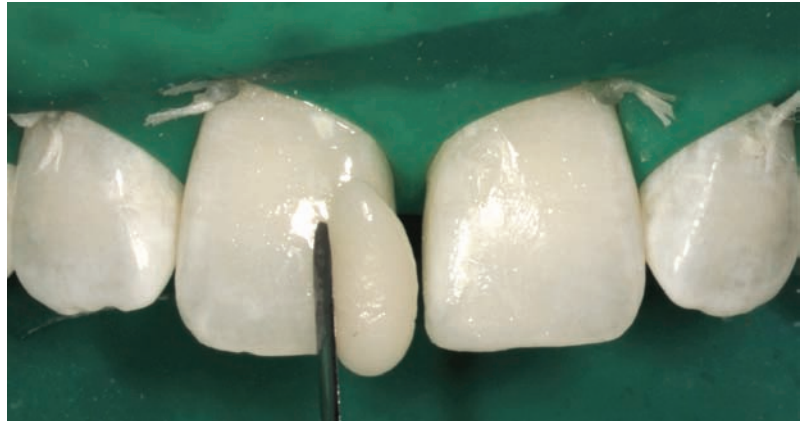

Figure 6: Two increments of nano-composite resin are applied to the diastema simultaneously and contoured to optimal proportion on the mesial aspect.

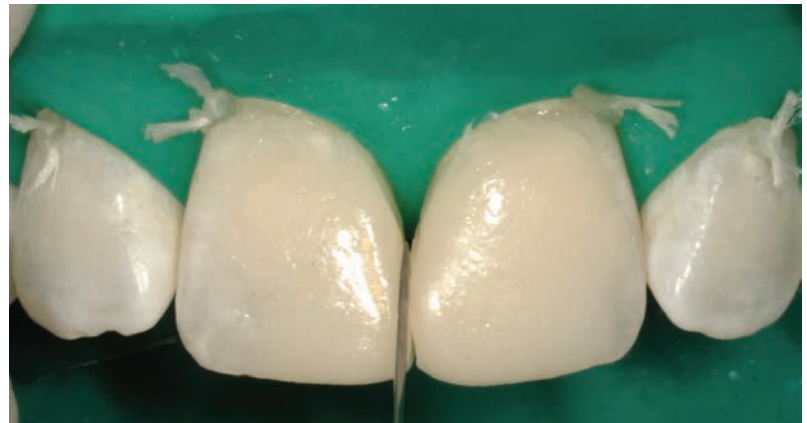


Figure 7: An IPC instrument is used to adapt the resin to the proper contour.

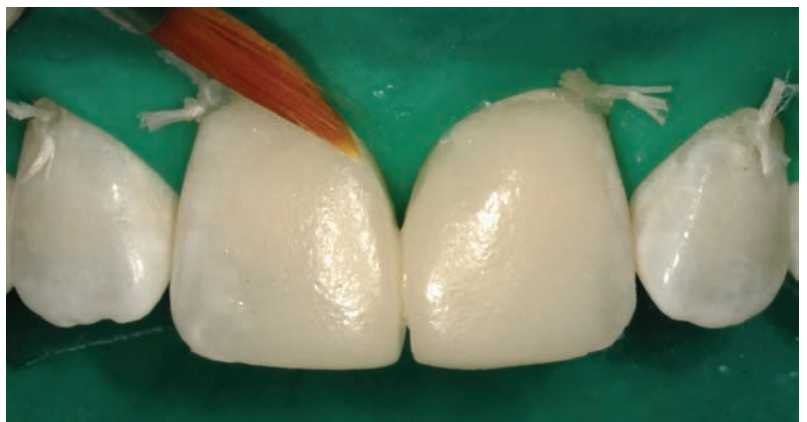

Figure 8: A small brush is used to smooth the composite.

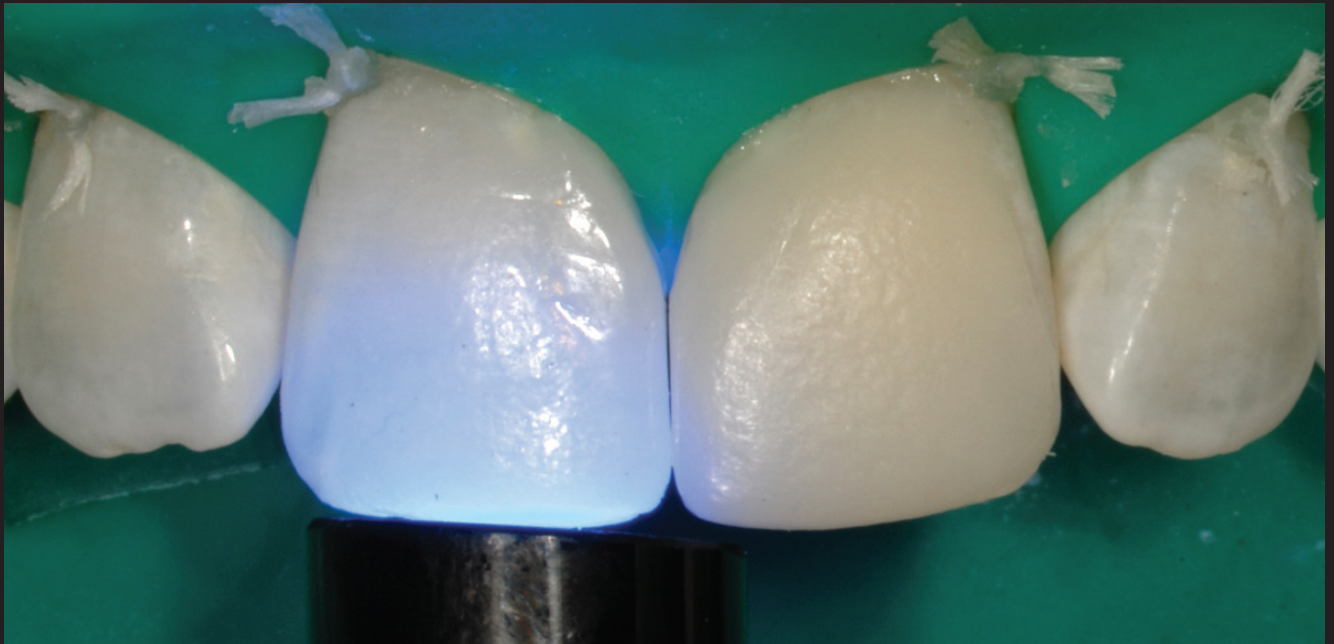


Figure 9: These increments of composite are light-cured.

Although the success of a restorative treatment in anterior teeth depends on the esthetic integration between soft and hard tissues, direct restorative techniques can be applied to treat this condition.

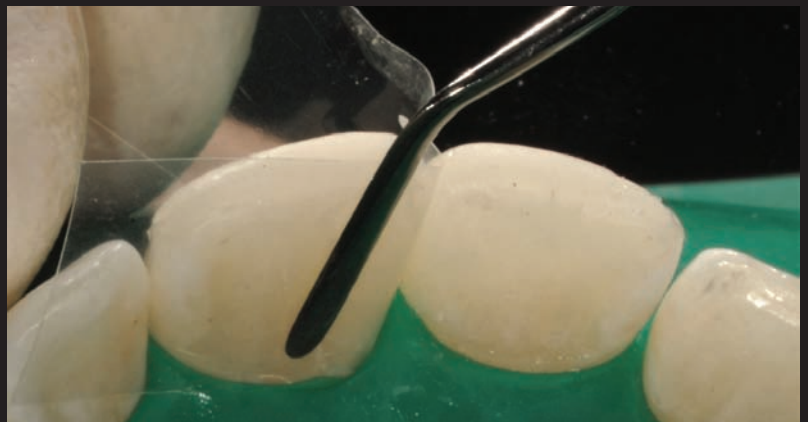


Figure 10: After the matrix is placed, the composite is layered against the matrix lingually and pulled through toward the facial.

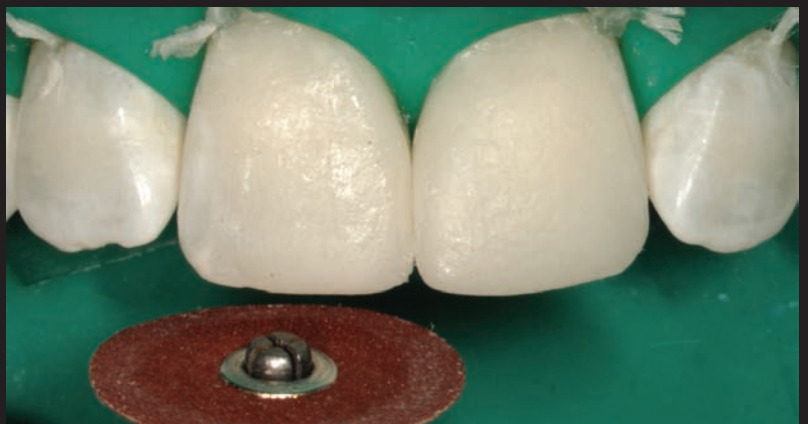

Figure 11: The facial surface is finished using a finishing disk.

Following the step-by-step protocol described here will enable the dentist to successfully close the diastema, while taking into consideration those criteria necessary to create an ideal emergence profile for gingival health and properly managing "black triangles."

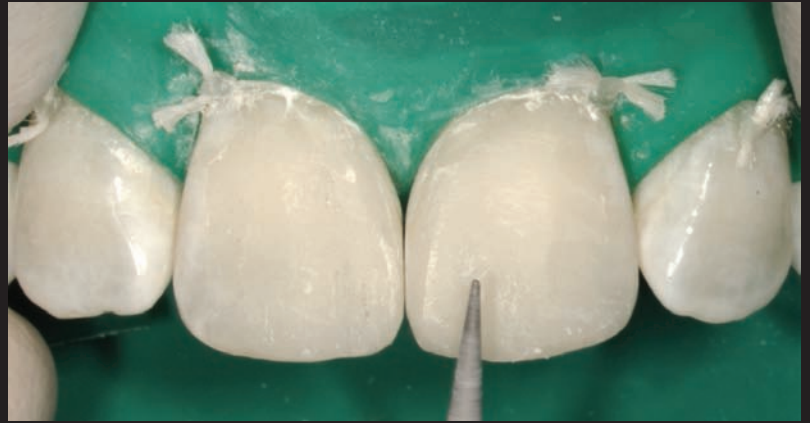

Figure 12: Surface characteristics are created with a diamond bur, without water irrigation.

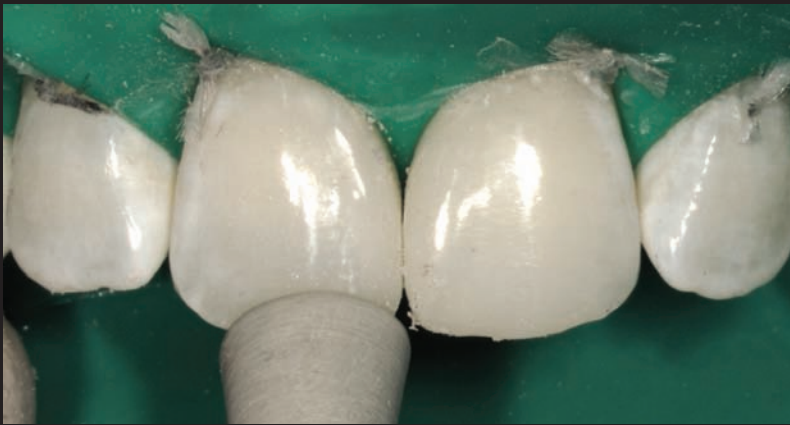

Figure 13: The use of polishing cups contributes to the creation of the restoration's final luster and surface anatomy.

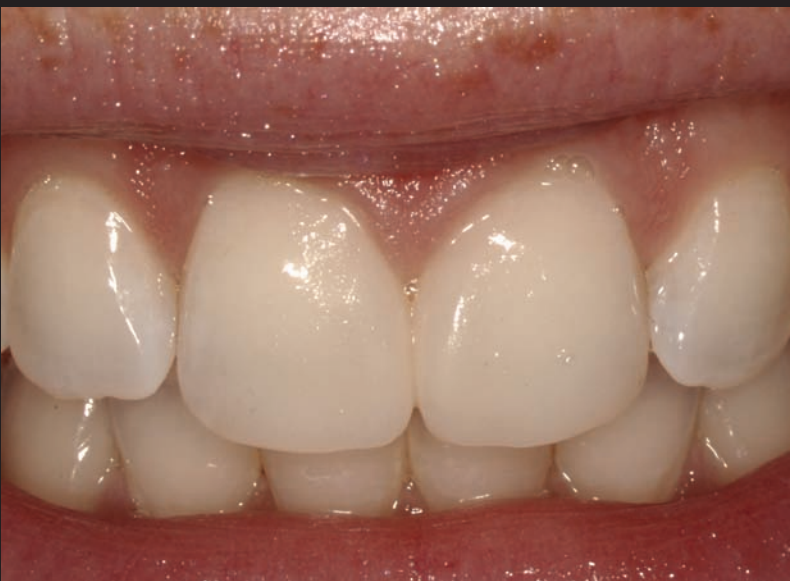

Figure 14: Postoperative view after the diastema between teeth #8 and #9 was closed with direct composite resin.

Conclusion

In esthetic dentistry, one of the biggest challenges practitioners face is closing anterior diastemas without the presence of "black triangles" around the teeth.² Although the success of a restorative treatment in anterior teeth depends on the esthetic integration between soft and hard tissues, direct restorative techniques can be applied to treat this condition (Fig 14).³ Following the step-by-step protocol described here will enable the dentist to successfully close the diastema, while taking into consideration those criteria necessary to create an ideal emergence profile for gingival health and properly managing "black triangles."

References

1. Tarnow DP, Magner AW, Fletcher P. The effect of the distance from the contact point to the crest of bone on the presence or absence of the interproximal dental papilla. *J Periodontol.* 1992 Dec;63(12):995-6.
2. De Araujo EM Jr, Fortkamp S, Baratierri LN. Closure of diastema and gingival recontouring using direct adhesive restorations: a case report. *J Esthet Restor Dent.* 2009;21(4):229-40.
3. Lacy AM. Application of composite resin for single-appointment anterior and posterior diastema closure. *Pract Periodont Aesthet Dent.* 1998;10(3):279-86. **JCD**

About the Author: Dr. Vargas earned his DDS degree in 1985 from the Peruvian University School of Dentistry in Lima, Peru. He is a professor at the University of Iowa College of Dentistry, where he also practices part-time.

Author Disclosure: The workshop upon which this article is based was supported by Kerr.



Reflections of Excellence

"Major League" Smile!

When this cheerleader for a major league team wanted her smile "renewed", she turned to Dr. Matt Bynum and Aurum Ceramic.

Get your patients cheering — with beautiful smiles!

Call our Advanced Esthetic Hotline

1-800-661-1169

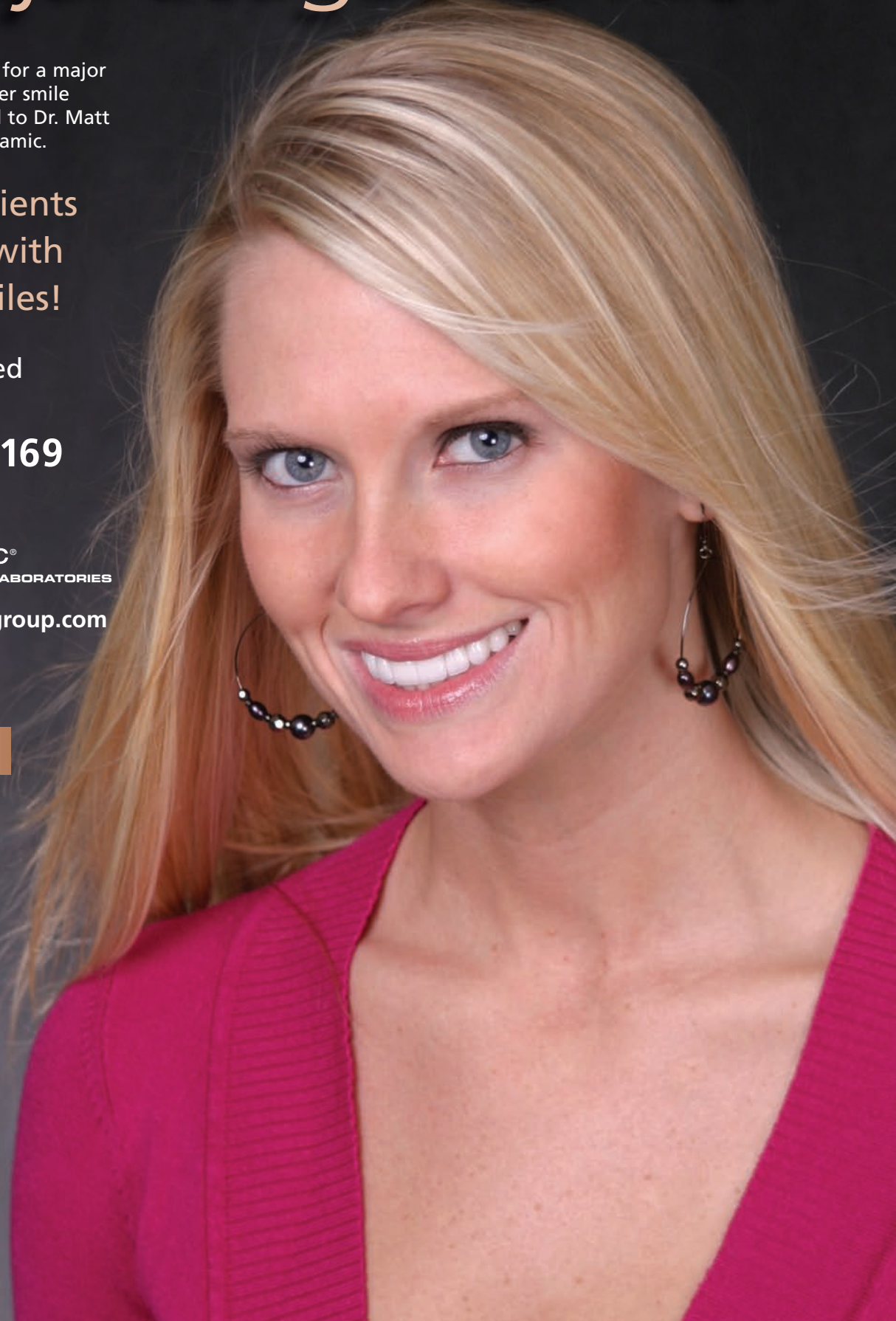

www.aurumgroup.com

Empress®
ESTHETIC

For aesthetically sensitive cases, no material performs like IPS Empress Esthetic. No other laboratory can match Aurum Ceramic in making the most of your IPS Empress Esthetic restorations.

Dentistry courtesy of
Dr. Matt Bynum, Simpsonville, SC.
Restorations fabricated by
Aurum Ceramic.



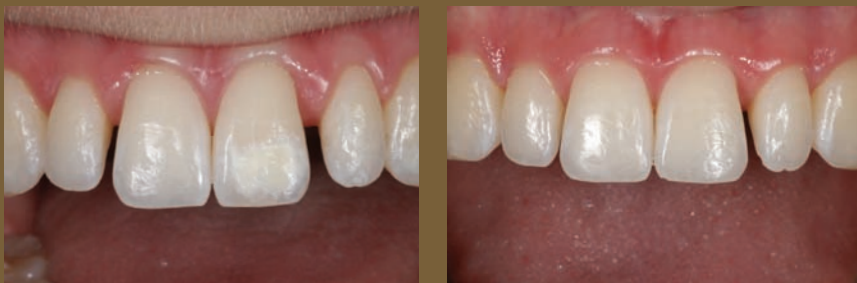Anterior Direct Bonding for Identical Twins

Predictability and Reproducibility in Restoration of Post-Orthodontic Residual Spacing

Kevin M. Brown, DDS

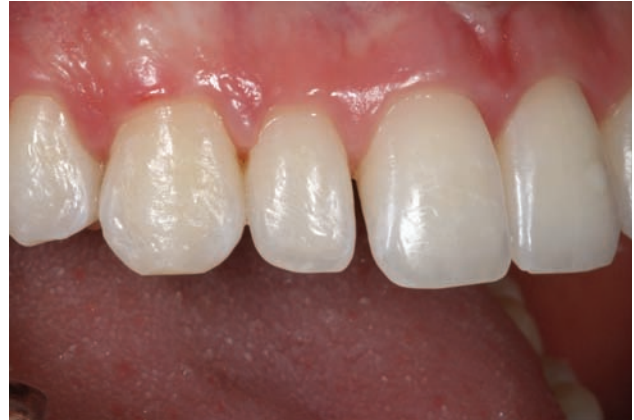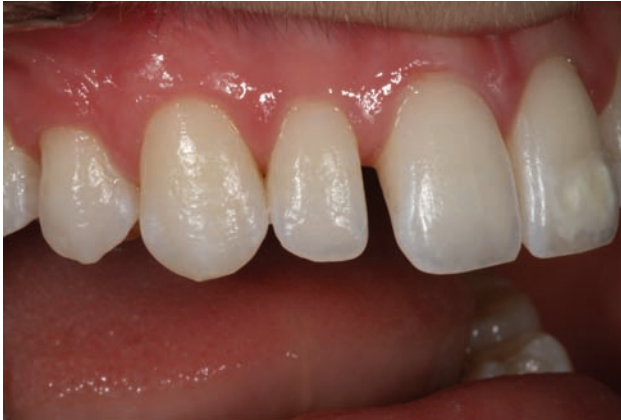Introduction

As patients continue to educate themselves about available dental materials, and as dentists perfect their skills in handling them, direct composite bonding continues to be a popular treatment of choice for conservative enhancements in the smile zone. The AACD 12 standard photographs, along with study models and a diagnostic wax-up, are indispensable tools that aid in finalizing a treatment plan so that all areas of hard and soft tissues are addressed and resolved before the clinical appointment. To minimize the challenges of restoring teeth in the smile zone, close communication with any specialist involved with the patient's treatment is exceedingly important.

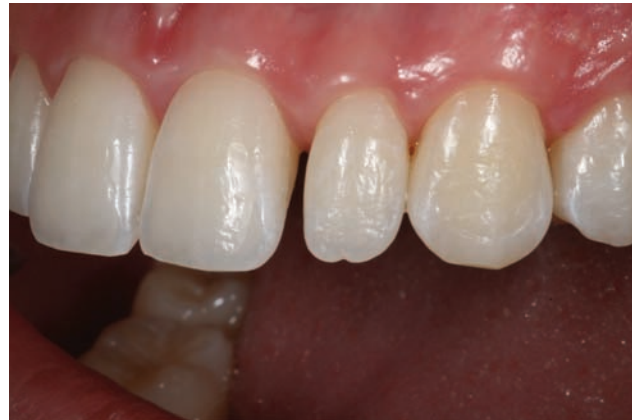
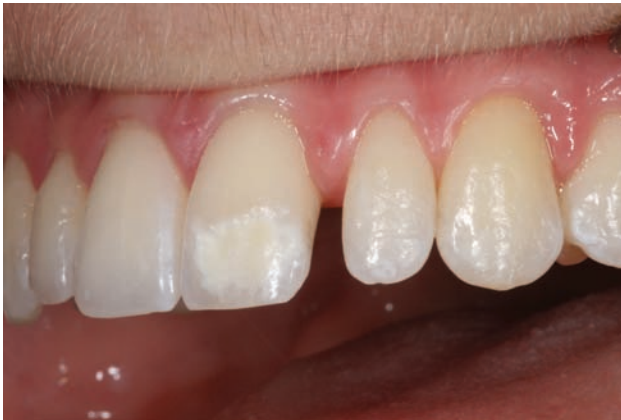
Figures 1a & 1b: Retracted front 1:1 views of Megan (1a) and Morgan (1b) as they presented for the consultation appointment. The large hypo-calcification spot on Megan's tooth #9 was an esthetic concern of hers.

CLINICAL COVER STORY



Figures 2a & 2b: Pre-restorative retracted right lateral 1:1 views (Megan 2a, Morgan 2b). Note the iatrogenic enamel scarring left when the orthodontic brackets were removed.



Figures 3a & 3b: Pre-restorative retracted left lateral 1:1 views. Ideally, the orthodontist should have set the peg laterals with equal space on the mesial and distal. For Megan (3a), the space between teeth #10 and #11 would be difficult to close, regardless of the restorative material.

Case Presentation

Identical twins Megan and Morgan presented for a post-orthodontic consultation to evaluate and discuss the options for restoring the residual spaces left by the maxillary peg lateral incisors (Figs 1a & 1b). As the sisters had been referred to our office by family, we had not been in communication with the orthodontist prior to their completing orthodontic treatment. Comprehensive examinations were completed for the girls, including radiographs, dental and periodontal examinations, occlusal analysis, study models, and the AACD 12 standard photographs. Both girls

showed healthy gums and teeth, with no occlusal discrepancies.

Esthetic Evaluation

Being identical twins, Megan and Morgan displayed nearly identical space discrepancies; however, Megan had larger spaces to close and also had a large hypo-calcification spot on the facial of tooth #9 (Figs 2a & 2b, 3a & 3b). The orthodontist had chosen to distalize the peg maxillary lateral incisors into contact with the canines, which left all residual space between the lateral and central incisors. This would prove very challenging to restore, regardless of the

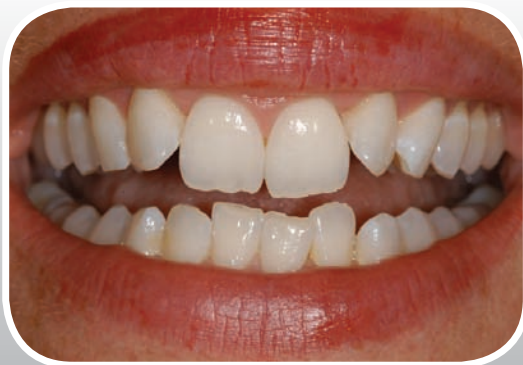material selection, especially in regard to axial inclination and papilla formation. Ideally, the lateral incisors should have been positioned with equal space on the mesial and distal.¹ It was also noted that the enamel on most of their teeth was iatrogenically scarred from cement removal when the brackets were removed. This would also prove a challenge with respect to surface texture in the final restorations, again regardless of material selection. Due to the depth of the enamel scarring, only a minimal effort would be made to polish it out so as not to irreversibly weaken the enamel or potentially change the color of the

*There is a direct correlation between
cosmetic imaging and case acceptance...*

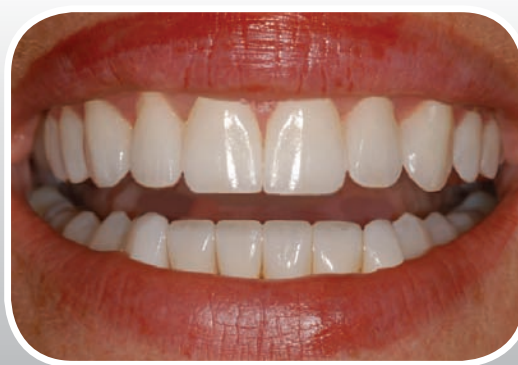

Imaging Service Now Available!

visit www.envisionsmile.com for details!



pre-op



imaging with
Envision a Smile



**Increase Case Acceptance
by purchasing the software OR using our service.**

For a free on-line demonstration from your own photograph, visit us at

www.EnvisionASmile.com
or call 877-841-1122

CLINICAL COVER STORY

teeth by allowing more dentin to show through.

Both girls had beautiful smiles, with the gingival architecture and zeniths appropriately positioned. They simply presented with a classic situation of tooth size discrepancy after orthodontic treatment and requested a conservative approach to completing their smiles.

Treatment Plan

The esthetic dilemma that faced Megan and Morgan was nothing new in the world of cosmetic dentistry. They simply had to help us choose which restorative material(s) would work best in their individual situations. There were only two good options from which to choose: indirect porcelain or direct composite. Each method's risks and benefits were thoroughly explained to the patients and their mother. We then showed them clinical photographs of similar cases illustrating our ability to produce equally esthetic restorations with both materials. The final decision would come down to cost and longevity differences between porcelain and composite, not esthetic advantages.

Showing clinical photographs of our own work can instill confidence in patients about our ability to deliver superior results. The AACD 12 standard photographs should be used on all es-

thetic cases, regardless of Accreditation potential, in order to build a portfolio of "before and after" images for future reference.²

It was mutually decided that direct composite veneers on teeth #7 and #10 would be the treatment of choice for the girls. In addition, Megan would need direct composite to restore the facial hypo-calcification on tooth #9.

Material Selection

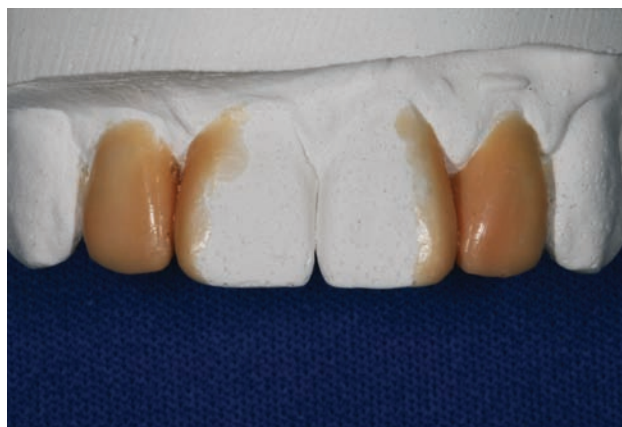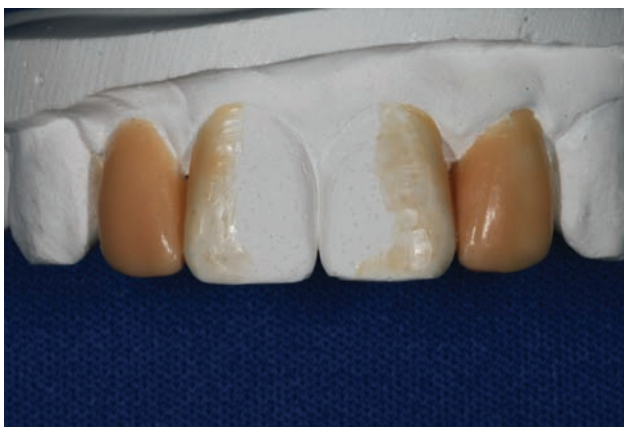When considering direct composite, whether to restore a small fracture or to veneer an entire facial surface, it is necessary to be knowledgeable about the different resin types, strengths, properties, opacities, and translucencies.³ With Megan and Morgan, the composite would easily be placed out of occlusal functioning and have a predictably long service. Nevertheless, a nano-hybrid was selected for the lingual shelf (Grandio Incisal shade, Voco GmbH; Cuxhaven, Germany) and opaque (Amaris shade O2, Voco GmbH) layers for strength.⁴ The top layers must exhibit properties of both color control and polishability.⁵ In the sisters' case, a microfill (Dura-fill VS shades A1/B1, Heraeus Kulzer; South Bend, IN) and nano-fill (Filtek Supreme Plus shade Clear, 3M ESPE; St.

Paul, MN) composite were selected to fulfill these esthetic requirements.

As Dr. Newton Fahl Jr. has explained, it is difficult to find a single brand or system of composite that can fulfill every esthetic need in every situation. Therefore, one can benefit by being familiar with the favorable properties of multiple composite systems, and be comfortable knowing when to use different systems on a single restoration to achieve maximum esthetic results.⁵ This theory was predictably and successfully implemented in the case of Megan and Morgan.

Diagnostic Wax-Up

It is imperative to use a diagnostic wax-up to properly treatment plan a smile design case.⁶ This is especially true with direct composite, as it is the wax-up (indirect) or mock-up (direct) from which a silicone putty index is created. The index serves to predictably transfer the incisal length, shape, embrasure, and interproximal contact from the wax-up to the patient. Given that Megan and Morgan had nearly identical teeth and space discrepancies, this would test just how predictable this method of direct restoration can be. As Megan had a larger space to close, the wax-up was an extremely valuable tool to help us realize that the space could not be



Figures 4a & 4b: The diagnostic wax-ups, 1:1 views. For Megan (4a), it was helpful to practice restoring the teeth in wax on the study model because it made it clear that we also needed to bond to the distal surface of the centrals.

closed by adding only to tooth #7. In order to create proper axial inclination on the laterals for Megan, it became clear that composite also had to be added to the distal of the centrals (Figs 4a & 4b). Accomplishing this in wax on the study model created a wonderful opportunity to do a “practice run” in the laboratory on what would need to be done clinically. When the day of treatment came there were no surprises, because all the problems had been worked out beforehand in wax.

Preparation and Layering

Morgan

Morgan’s case was simpler than her sister’s, so we chose to do her teeth first. No anesthetic was necessary as the only preparation needed was to lightly roughen the surface enamel with a coarse Sof-Lex disk (3M ESPE) and then polish with a pumice water slurry to ensure a clean bonding surface. The silicone index (Panasil fast-set putty, Kettenbach Dental; Huntingdon Beach, CA) was tried in to verify a proper fit prior to the bonding phase. A 40% phosphoric acid etch gel (Ivoclar Vivadent; Amherst, NY) was placed for 15 seconds on tooth #7, thoroughly rinsed, and lightly dried. Before the bonding agent (Excite VivaPen total etch dental adhesive, Ivoclar Vivadent) was cured, a strip of Teflon tape was stretched over tooth #8. A frosty white incisal shade composite (Grandio, shade I) was used to create the lingual shelf. Care was taken with this layer to ensure proper adaptation to the index so that the incisal length, contour, and embrasures were replicated from the wax-up.

Next, an opaque layer (Amaris, shade O2) was layered to replicate the internal dentin. Before curing this layer, a small sable brush was used to help create the

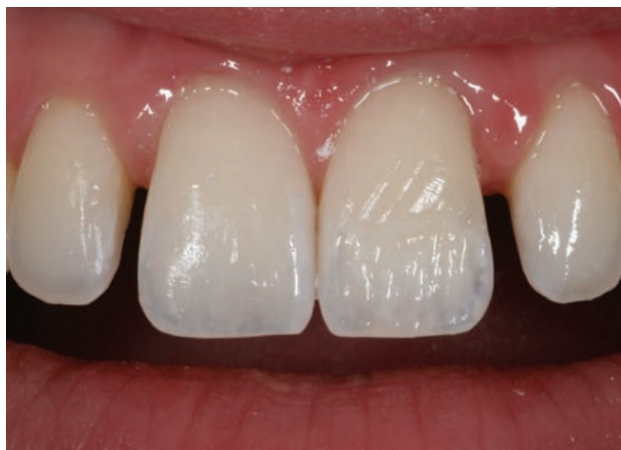

Figure 5: Retracted 1:1 view of Megan’s teeth after preparation with no anesthetic. A round #6 coarse diamond bur was used to remove the hypo-calcification with no discomfort to the patient.

mamelons while leaving a little room for incisal translucency. On the incisal third, a thin layer of clear composite (Filtek Supreme Plus, shade Clear) was placed to allow for some translucency and accentuate the dentin lobes. The gingival and body shades (Durafill VS, shades A1 and B1) were then sculpted into place using a sable brush. Finally, a very thin top layer of Clear shade was sculpted into final contours, making an effort to establish line angles. This top layer of Clear gives the final restoration a natural depth. However, if this layer is too thick the overall value will decrease and make the tooth look grayer. The

It is imperative to use a diagnostic wax-up to properly treatment plan a smile design case.

same steps were repeated for tooth #10.

Finishing and polishing were accomplished with carbide and fine-grit diamond burs (Axis Dental; Coppell, TX), Sof-Lex disks, composite polishing points (3M ESPE), PDQ diamond brush (Axis Dental), and Enamelize

paste with FlexiBuff disks (Cosmedent; Chicago, IL). Before the surface texture was finalized on the restorations, a valiant effort was made to polish the enamel scarring on the natural dentition.

Megan

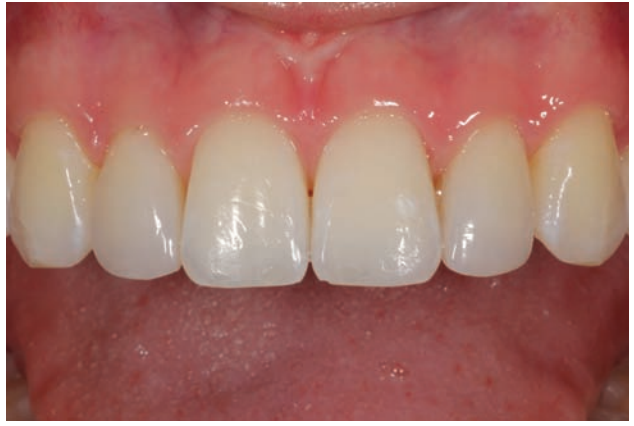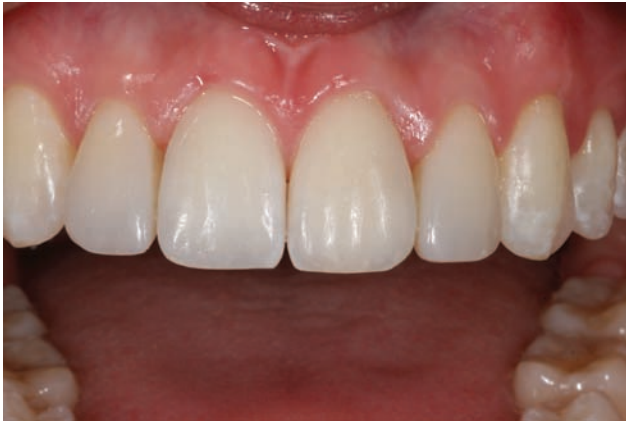Megan had been waiting anxiously for about 90 minutes for her sister’s treatment to be completed. She was a little nervous, but knew that since Morgan had gone first, she would get an indication as to what her own teeth would look like. When she saw Morgan’s new smile, her anxiety disappeared and she was ready to get started.

The same steps were taken for Megan as for her sister; the only difference was that we also bonded to the distal of the central incisors first before restoring the lateral incisors. The large hypo-calcification spot on #9 was removed without anesthetic using a coarse diamond round bur (Fig 5), and was restored in similar fashion to the lateral incisors. Retraction cord (Gingicord, Van R; Oxnard, CA) was placed on the lateral incisors so we could have better access to create an emergence profile on the mesial of teeth #7 and #10.⁷ The space between teeth #10 and #11 was by far the largest, and proved to be the most difficult in achieving an emergence profile and axial inclination. The enamel scarring was smoothed and the finish and polish of the composites were completed exactly as mentioned previously. At this point it was difficult to tell how the papillae between #10 and #11 would turn out after being traumatized by retraction cord and rotary instruments.

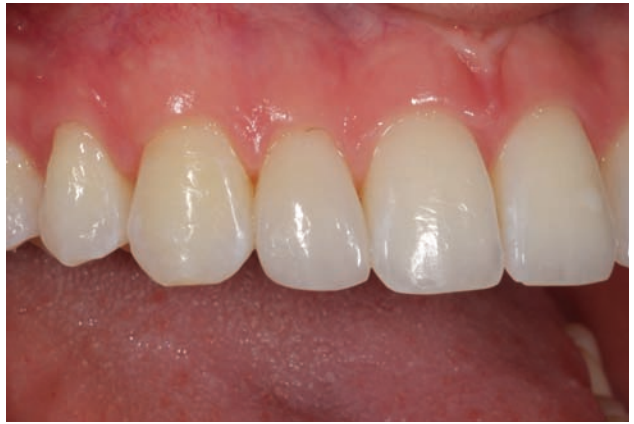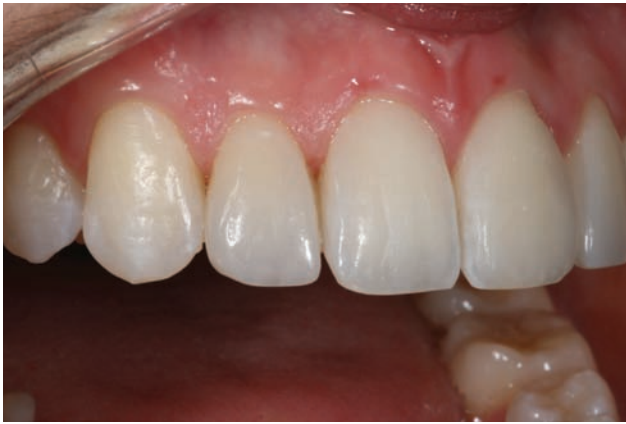Follow-Up

Megan and Morgan returned a week later for a follow-up examination to reevaluate the length, shape, and color of their restorations. They reported that

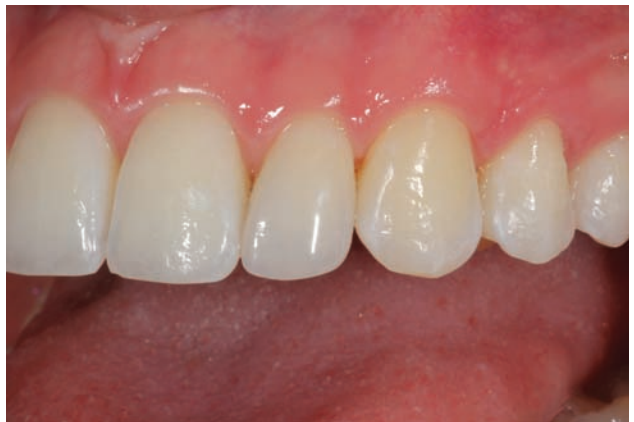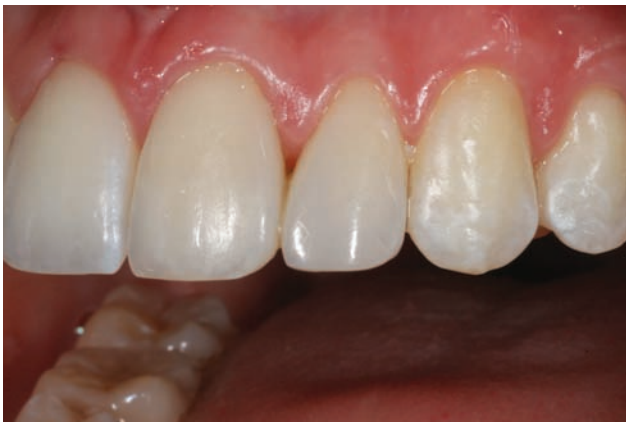CLINICAL COVER STORY



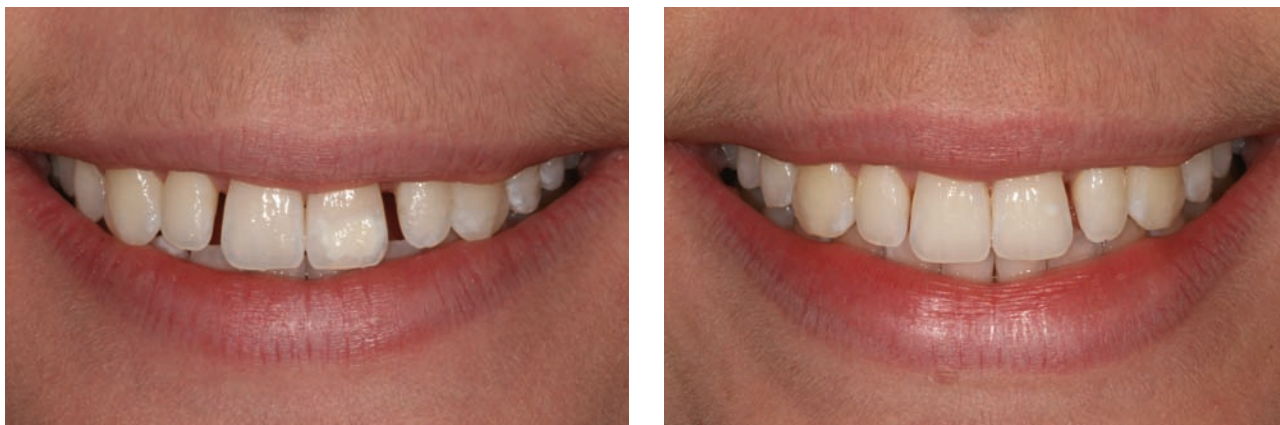Figures 6a & 6b: Retracted 1:1 front views of final restorations (Megan 6a, Morgan 6b).



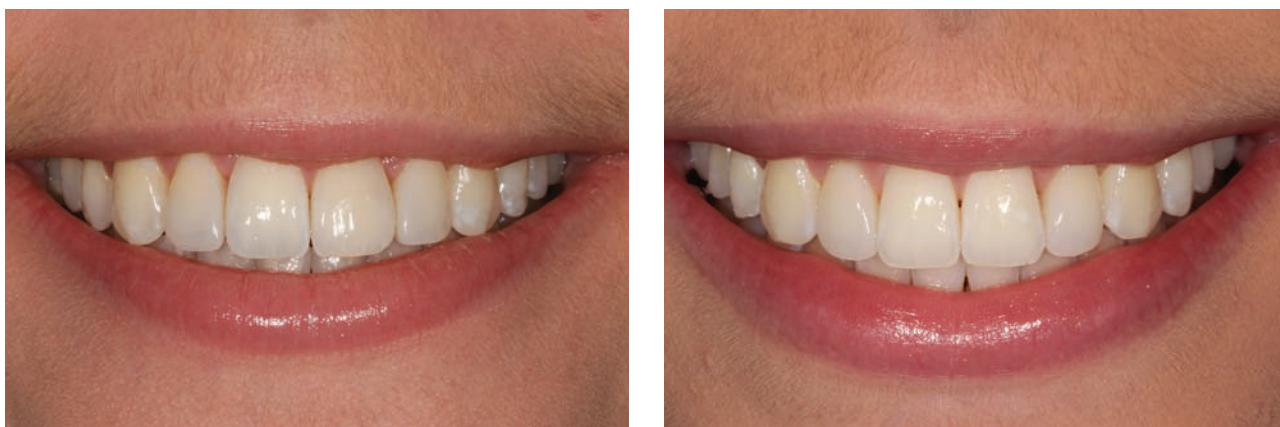Figures 7a & 7b: Retracted 1:1 right lateral views of final restorations (Megan 7a, Morgan 7b).



Figures 8a & 8b: Retracted 1:1 left lateral views of final restorations (Megan 8a, Morgan 8b).



Figures 9a & 9b: Before treatment 1:2 front views of Megan's (9a) and Morgan's (9b) full smile.



Figures 10a & 10b: After treatment 1:2 front views of Megan's (10a) and Morgan's (10b) full smile.

The portraits were then printed and framed and given to the sisters to thank them for trusting us with their smiles.



Figures 11a & 11b: Final portraits of Megan (11a) and Morgan (11b).

CLINICAL COVER STORY

they loved everything about the restorations and requested no changes. Megan's gingival tissues, especially the papillae, appeared to have healed well in the short maturation time. We took final clinical photographs and then portraits in our office studio (Figs 6a-12). The portraits were then printed and framed and given to the sisters to thank them for trusting us with their smiles.⁸

Conclusion

It was an exciting experience to restore Megan and Morgan's identical smiles. The lessons to be learned from this unique experience of restoring the same esthetic dilemma one right after the other are many. The important ones, however, only re-emphasize those truths that have already been taught by those who have gone before; these include using a diagnostic wax-up to visualize the desired outcome, and using clinical photographs to aid in treatment planning for both hard and soft tissues.⁹ Otherwise, the likelihood of achieving excellent results without the aid of a wax-up and silicone index would have been exceedingly slim. The AACD has gone to great lengths to make this kind of information available to all who wish to improve their skills and learn from those who have already paved the way.

References

1. Kokich V. Sr. April 1, 2001. Managing orthodontic-restorative treatment for the adolescent patient. www.kokichorthodontics.com/Articlebc58.pdf. Accessed January 10, 2010.
2. Weston J. Accreditation quality esthetics—combining composite and porcelain for ultimate success! Presented at the American Academy of Cosmetic Dentistry Orange County Affiliate Meeting; San Diego, CA, November 7, 2009.
3. Terry DA. Natural aesthetics with composite resin. Mahwah (NJ): Montage Media; 2004. 23 p.
4. Bergeron C. Aesthetic restoration of maxillary central Incisors. *Dent Today*. 2010 Mar;29(3):122, 124-5.
5. Fahl N Jr. Mastering composites. Presented at the 24th Annual AACD Scientific Session; New Orleans, LA, May 2008.
6. Terry DA. Natural aesthetics with composite resin. Mahwah (NJ): Montage Media; 2004. 43 p.
7. Robins JW. Tissue management in restorative dentistry. *Funct Esthet Rest Dent*. 2007;1(3):40-3.
8. Villadiego BB. World class portrait photography. Presented at the 25th Annual AACD Scientific Session; Honolulu, HI, April 2009.
9. Griffin JD Jr. Use of digital photography to improve composite resin selection and material placement. *Pract Proced Aesthet Dent*. 2008;20(6):359-64. **JCD**



Figure 12: Postoperative portrait of the sisters.



About the Author: Dr. Brown graduated from the University of Washington School of Dentistry in 2006 and practices in Bellevue, Washington. **Author Disclosure:** The author did not report any disclosures.

Timeless Beauty,

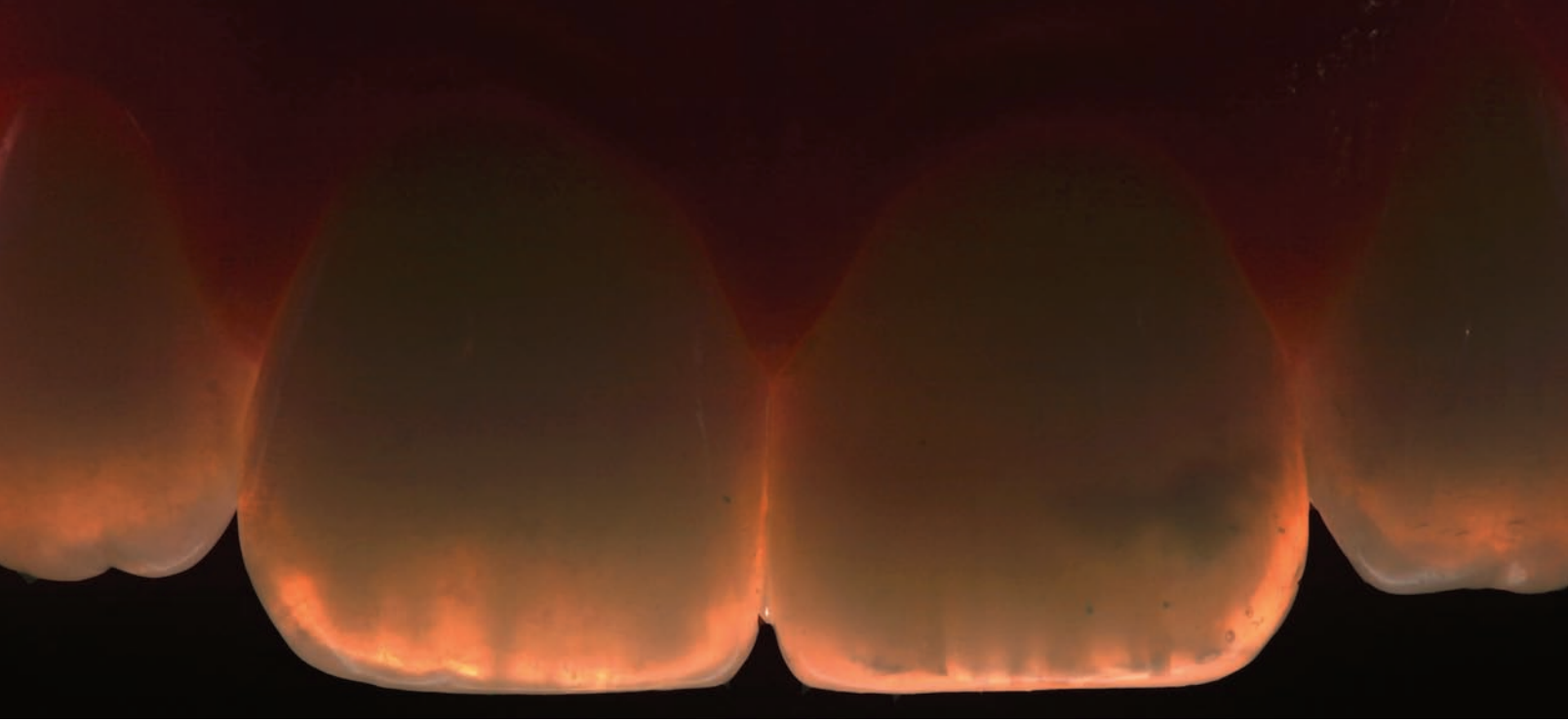
Uncommonly Predictable

Gold Dust
DENTAL LAB

You entrust your dental laboratory to manifest your vision and make it a reality. It requires confidence in the fabrication process, and an understanding about what is important to you and most importantly the talent to deliver. Every case you seat is a reflection of your personal integrity and skills. At Gold Dust, we get it. Which is why our commitment is to delivering uncommon predictability in fit, occlusion, aesthetics, and function for every patient. When your patient is happy, we know you are too.

For more incredibly happy patients,

Call 800.513.6131 today or visit us online www.golddustdental.com



A Solution for Everyday Direct Restorative Challenges

Mastering Composite Artistry to Create Anterior Masterpieces—Part 1

Newton Fahl Jr., DDS

Abstract

This first part of a two-part series introduces a conservative, effective, and artistic philosophy for performing esthetic direct anterior composite restorations based on the principles of emulating the proper form, color, and function of natural teeth. A step-by-step procedural approach to solving day-to-day anterior direct restorative challenges, which include shade selection, color mapping, color mock-up, tooth preparation, composite resin selection, and artistic implementation, is presented. Clinically relevant aspects, such as how to create seamless transitions from tooth structure to the synthetic composite restoratives by correct finishing and polishing techniques, are thoroughly discussed. Necessary armamentarium, from instruments to restorative materials for the predictable, stress-free realization of esthetic anterior direct restorations, are introduced as clinical cases are detailed.

Material, Optical, and Composite Placement Considerations

Essential to the science and artistry of direct free-hand dentistry, creativity enables dentists to devise and execute esthetic restorations using composite resin systems.^{1,2} To understand advanced esthetic treatments, dental professionals must also comprehend the fundamentals of tooth structure, such as color, form, and function.³ With such a thorough understanding, almost any composite system may be used to achieve excellent results.³

In the anterior region, it is important to emulate nature so that both form and color incorporate seamlessly, producing restorations that not only mimic, but are indistinguishable from surrounding natural dentition (Figs 1 & 2).³ Through developments in composites, which are now equal to or better than some porcelain

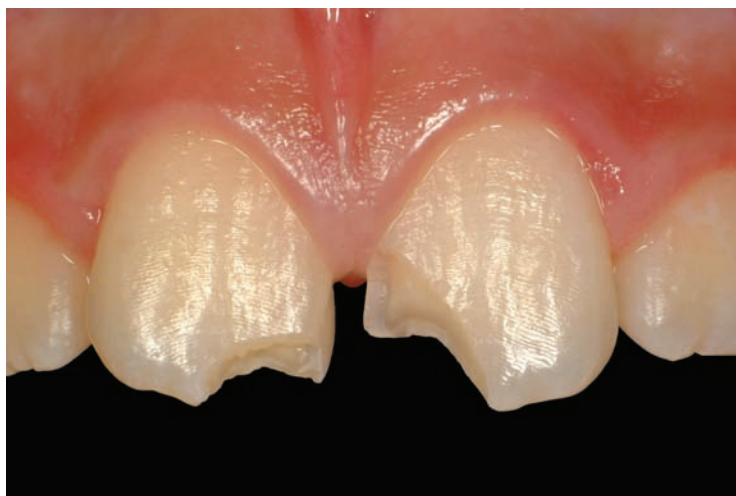

Figure 1: Class III and IV defects involving loss of natural enamel and dentin.

Through developments in composites, which are now equal to or better than some porcelain systems, enhanced optical properties and esthetics can be realized in direct restorations.

systems, enhanced optical properties and esthetics can be realized in direct restorations.^{4,5} It is, however, up to the artist, as an operator and scientist, to understand the principles of working with composite systems and how to correlate them with natural tooth tissues.^{5,6}

Properties of Composite Systems

When choosing a composite system, material characteristics such as handling, sculptability, and viscosities affect the final restorative outcome, dictate specific manipulation techniques required, and influence delivery format.^{5,6} Among others, time from delivery to contouring and brushing, fracture and wear resistance, and polymerization shrinkage rates are important aspects of composite systems to consider before undertaking direct restorative procedures.⁷ With new state-of-the-art composites, however, color stability is less of a concern, since nearly all systems demonstrate predictable and balanced color stability throughout treatment and post-procedure.⁵

In the past five years, dental professionals have witnessed major improvements in composite materials in terms of their particle sizes.^{5,8} Micro- and nano-hybrids produce enhanced luster and polish, while microfills remain unmatched for polishing ease and longevity when exposed to varying degrees of pH levels (i.e., low pH, high acidity, and brushing).⁵ Although polishability is not critical to composite selection, it is important.⁵

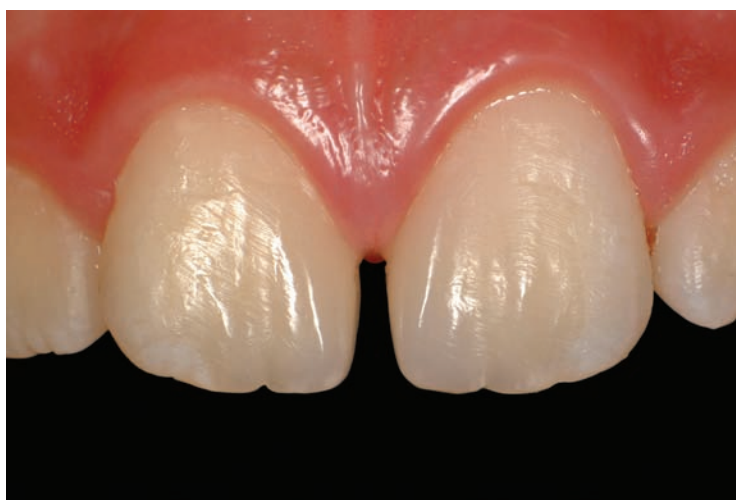
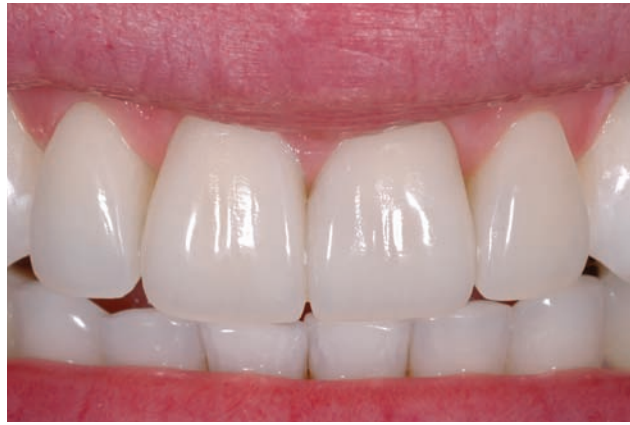
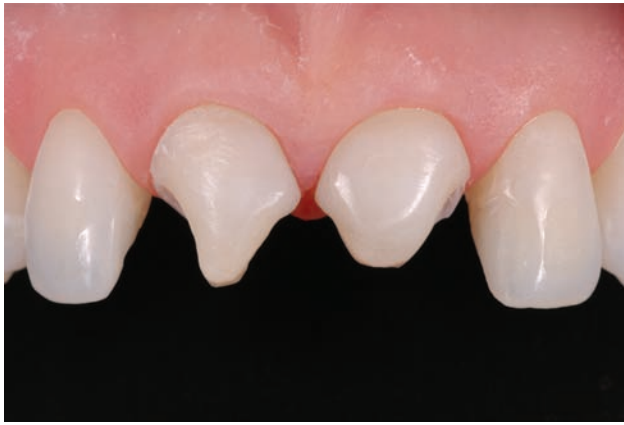Figure 2: Selection of proper composite materials and restorative techniques elicits seamless results.



Figures 3a & 3b: Wear and fracture resistance are necessary characteristics of direct composites in stress-bearing areas.

As operators, dentists and technicians control a limited number of material characteristics and final restorative outcomes.^{5,6} With the ability to control only environmental aspects, finish-

Polishability

Composite resins must also provide high polishability to mimic the gloss of natural enamel.¹⁰ Although composite restorations may exhibit a great final

Microfills

Microfills, conventional or reinforced, provide high sculptability and excellent wear resistance.¹³ With these composites, dentists can expect high polishability and very good color stability that typically lasts more than 20 years.¹³ Fracture toughness, however, is lower than with some other materials, and microfills should not be used over the incisal edge or to build up the incisal edge, as it will eventually break.¹³ Reinforced microfills do provide higher fracture resistance and, depending on the case, may be used in high stress-bearing areas.¹³

Conventional Hybrids

Unlike microfills, a key benefit of hybrid composites is fracture toughness or resistance.¹³ Color stability is considered very good and sculptability is fair, depending on the specific system used.¹³ Wear resistance and polishability of hybrids, however, are not as good as other materials because hybrids present an average of larger particles, which are responsible for pitting of the finished surface, and they tend to be harder to polish than microfill materials.¹³

Micro-Hybrids and Nano-Hybrids

Micro-hybrids are hybrids with a greater content of submicron particles. They demonstrate improved handling and polishability compared to conventional hybrids.⁸ Nano-hybrids are the state-of-the-art in the hybrid category

Although most of today's composites demonstrate excellent color stability, other factors contribute to the lifespan of a direct restoration's color.

ing and polishing, manipulation, and proper polymerization, there is very little dentists can do to ensure the predictability of resins.⁵ Also, today's resins demonstrate a range of 0.9% to 1.5% volumetric shrinkage, which supports esthetically pleasing results without pulling away and disrupting the hydrodynamics of the tubuli.⁷ This low shrinkage rate reduces the likelihood of postoperative sensitivity, marginal leakage, and creates better margins in restorations.⁷

Fracture Resistance

When building the incisal edge, Class IV incisal buildups, and restoring worn dentition, composites that withstand the rigors of occlusion and mastication are required.⁹ The composite material must resist the abrasion that occurs from bruxing tendencies and brushing.⁹ Therefore, wear resistance is a necessary characteristic of direct composites in order for restorations to maintain surface texture and anatomy (Figs 3a & 3b).⁹

polish when the patient leaves the office, they should sustain that gloss over time.¹⁰

Color Stability

Although most of today's composites demonstrate excellent color stability, other factors contribute to the lifespan of a direct restoration's color.¹¹ Polymerization and polishing can affect color stability, as can a patient's dietary and other habits.¹¹ Typically, however, 10 to 20 years of color stability can be expected with current composite systems.¹¹

Composite Types

Available composite materials vary based on filler particle size and shape, and there are many options from which to choose.^{5,6} Although each encompasses different characteristics, material selection will be determined based on the area in which the restoration is planned and the specifics of the case.¹²

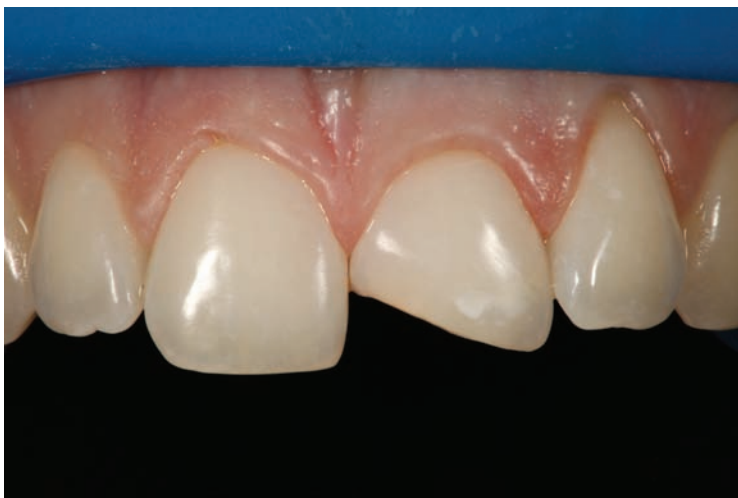

Figure 4: Preoperative view of a fractured central incisor. The intact contralateral incisor depicts marked opalescence at the incisal third.

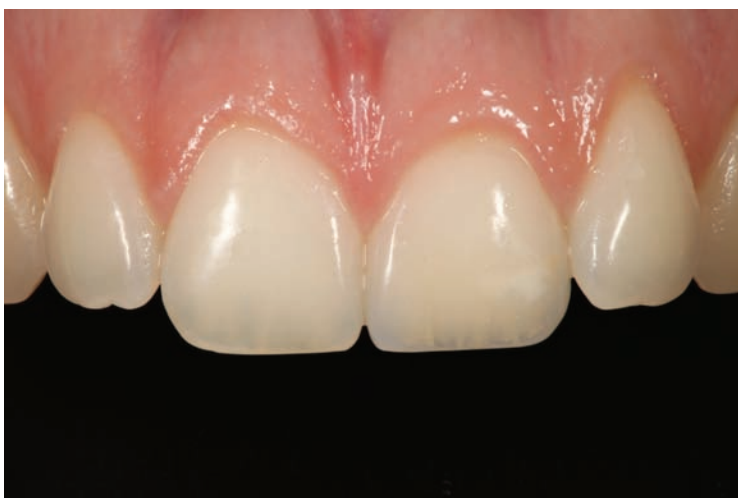

Figure 5: Current esthetic composite systems present effect enamels that mimic true opalescence. A reflected light shot shows a bluish hue along the incisal third.

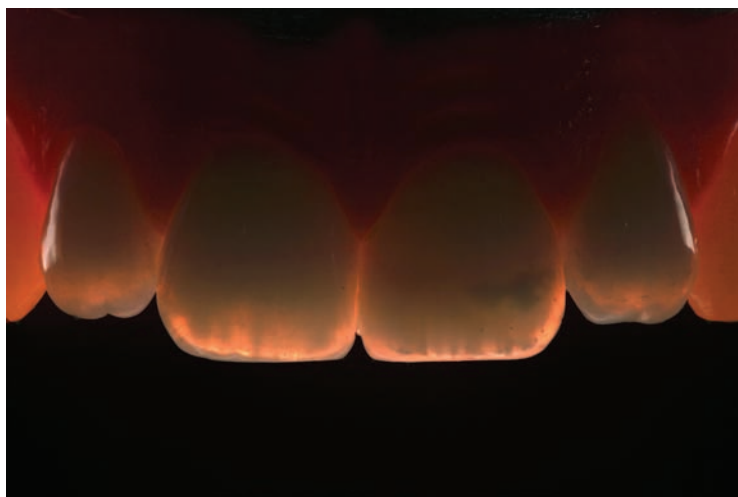


Figure 6: An effect composite enamel that is truly opalescent should allow the perception of amber hues through transmitted light.

and combine fracture toughness, sculptability, improved wear resistance, and color stability. Although the increased content of nano-particles does, in fact, produce a better polish, microfills still remain unchallenged with respect to long-term gloss.

Nano-Fills

Although there are few nano-filled products available, particle size and shape are the most important characteristics of these composites, as a configuration with spherical particles ultimately enables the best polishability.¹³ Due to their smaller particle size, nano-fills exhibit very good fracture and wear resistance, along with good sculptability.¹³ These composites also demonstrate color stability.¹³

It is important to remember that not all systems exhibit the same properties and that there is no truly perfect material.¹² Ultimately, it is up to the dentist to maximize the best properties in each system and manipulate them to create the comprehensive, customized shades that suit the restoration.¹²

Optical Properties

Crucial to restorative success with any composite system is an understanding of the optical properties of natural dentition and the selected composite material.¹⁴ An integral part of esthetics and a result of how light is transmitted, reflected, defracted, refracted, and absorbed through enamel, halos result from a change of the wavelengths of light called *opalescence* that causes a whitish/amberish effect.¹⁴


Opalescence

By definition, opalescence is the result of a change in the wavelength of natural light (5000 K), whereby bluish wavelengths are reflected and amber wavelengths are transmitted—a phenomenon perceived in the opal stone and present in tooth enamel. Providing reflection of white, natural, and bluish hue light, opalescence creates a natural halo.¹⁴ The more translucent a tooth, the more opalescence it will display.¹⁴ On the other hand, the more opaque a tooth, the less opalescence it will display.¹⁴ Some products today exhibit the required opalescence, while some reflect blue and others transmit amber (Figs 4-6).¹⁴ When choosing a material, it is incumbent upon clinicians to evaluate the composite for the specific shade required to provide true opalescence in any restorative case.¹⁴

Opacity

Opalescence is not exclusive from opacity, which has an effect on restoration and natural dentition.¹⁴ A natural tooth exhibits higher chroma and lower value at the cervical third; a lower chroma and higher value at the middle

Bestselling Books in



Aesthetic and Restorative Dentistry: Material Selection and Technique

Edited by Douglas Terry

This dynamic multi-contributor book illustrates important esthetic and restorative dental procedures as they are used in everyday clinical situations. It is designed to explain how a selected material and/or instrument can be used as part of a complete protocol to achieve restorative excellence. Each chapter is divided into two parts. The first part consists of the latest evidence-based clinical concepts and biomaterials information related to the topic. The second section provides step-by-step high-quality illustration of the associated clinical procedures. Clinicians, technicians, and auxiliary staff will discover ways to make improvements in their work, maximize their productivity, and provide improved oral health to their patients.

771 pp; more than 2,000 color illus; ISBN 978-0-9822928-0-8 (BC999); **US \$330**

"A diverse and beautifully illustrated book on the esthetic procedures every dentist has found to be in high patient demand. The book is a virtual encyclopedic treatise of esthetic dentistry... Knowing pictures say far more than words lends credibility to this book, in which the photography is exquisite. Just looking at the photos provides a major education."

Gordon J. Christensen, DDS, MSD, PhD
Director, Practical Clinical Courses

"This book is notable because it combines diagnosis and restorative procedures with leading edge and evidence-based information on the dental materials used in esthetic dentistry."

John M. Powers, PhD
Editor, The Dental Advisor

"Since buying Aesthetic and Restorative Dentistry I have used it on a daily basis as an adjunct in case presentation. I am able to show patients clearly what is entailed in the procedure and what can be achieved... They love it, I love it."

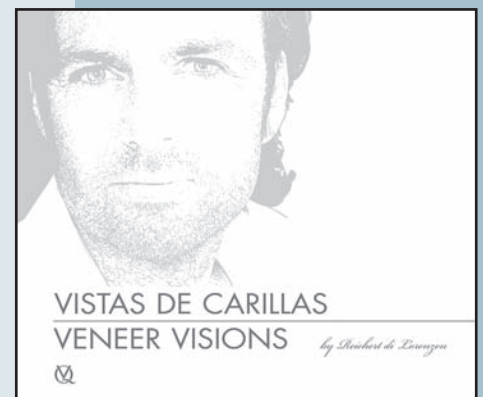Patrick O'Rourke, DDS
Queensland, Australia

Veneer Visions

Oliver Reichert di Lorenzen

Dental esthetics is about much more than simply optimizing the dentition. The state-of-the-art veneer procedures described in this atlas require neither reduction of tooth structure nor administration of anesthetic; the perfect smile can be delivered to patients in one painless appointment. This innovative technique of veneer fabrication challenges conventional methods of restoration and is tailored to meet the demands of cosmetic dentistry patients. Moreover, use of a wax-up/mock-up allows patients to experience the dramatic transformation for themselves by wearing the proposed smile makeover before committing to treatment. Abundant full-color before-and-after cases demonstrate the use of no-prep veneers alone and in combination with other fixed prostheses and present the esthetic possibilities of this revolutionary method. A dual English/Spanish language book.

120 pp; 300 color illus; ISBN 978-1-85097-200-6 (B9061); **US \$138**



Esthetic and Restorative Dentistry

Change Your Smile:

Discover How a New Smile Can Transform Your Life, Fourth Edition

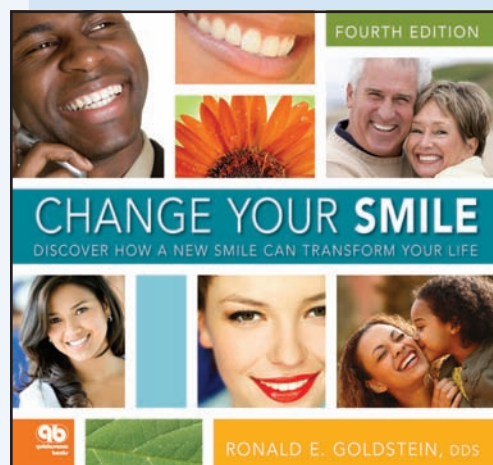Ronald E. Goldstein

Completely updated and revised, this new edition of *Change Your Smile* is even more patient friendly and the most economical resource available for educating and motivating your patients. Take advantage of the multiple purchase price—at less than \$20 per copy, the fourth edition is an inexpensive gift for all your patients. No doubt members of the patient's household, as well as other friends and family, will also look through the book and become motivated to improve their smiles as well. In this way, the book can work to exponentially increase your access to new patients. It is also a great asset in your operatories and waiting room and a perfect gift for your referral sources—specialists, dental labs, plastic surgeons, and cosmetologists.

244 pp (softcover); 484 color illus; ISBN 978-0-86715-466-5 (B4665); **US \$29.50**


"A must-have book for every dental office!"

John C. Kois, DMD, MSD



MULTIPLE PURCHASE RATE

Copies	Price
1-4	\$29.50 each
5-9	\$26.55 each
10-19	\$24.55 each
20-29	\$22.55 each
30+	\$19.55 each



Esthetic Rehabilitation in Fixed Prosthodontics

Volume 1—Esthetic Analysis:

A Systematic Approach to Prosthetic Treatment

Mauro Fradeani

This text provides a systematic approach to facial evaluation during esthetic treatment planning. Each chapter presents a different esthetic parameter involved in facial, dentolabial, phonetic, dental, and gingival analysis. This popular book is an invaluable tool for all clinicians practicing esthetic and restorative dentistry.

352 pp; 1,136 illus (mostly color); ISBN 978-1-85097-108-5 (B9504); **US \$258**

Volume 2—Prosthetic Treatment:

A Systematic Approach to Esthetic, Biologic, and Functional Integration

Mauro Fradeani and Giancarlo Barducci

This extraordinary book presents the procedural phases required to achieve optimal esthetics in fixed prostheses. Communication between the clinician and the technician is highlighted through a presentation of all clinical and laboratory procedures. Detailed clinical photographs and illustrations accompany each treatment phase.

600 pp; 2,500 color illus; ISBN 978-1-85097-171-9 (B9505); **US \$320**



TO ORDER

CALL: (800) 621-0387 (toll free within US & Canada) • (630) 736-3600 (elsewhere)
FAX: (630) 736-3633 **EMAIL:** service@quintpub.com **WEB:** www.quintpub.com
Quintessence Publishing Co Inc, 4350 Chandler Drive, Hanover Park, IL 60133 8/10

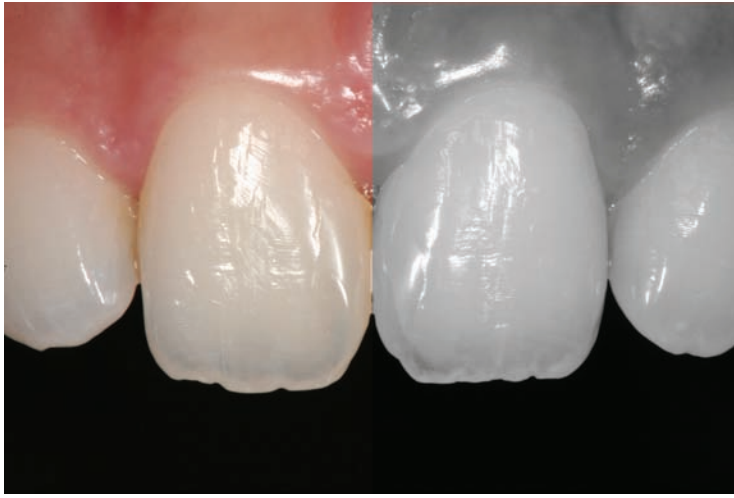

Figure 7: The interplay of varying thicknesses of dentin and enamel from cervical to incisal thirds accounts for the perception of more translucencies, different chromas, and values.

and values, and the proximal lobes.¹⁵⁻¹⁷ Because of how the enamel rods are positioned, light reflectance, opacity, and value areas are directly affected by enamel thickness (Fig 7).¹⁴⁻¹⁷

Dentin

Dentin, both natural and composite, does not exist in amber, gray, or yellow shades.¹⁴⁻¹⁷ Instead, dentin coloring is referred to as yellow/red hue and usually labeled as A1, A2, A3, etc.,¹⁴⁻¹⁷ dependent upon the manufacturer. Many companies also refer to their dentin in terms of saturation (Saturation 0, Saturation 1, etc.).¹⁴⁻¹⁷ The most important thing to remember when working with dentin composites is that all possess a true hue.¹⁵⁻¹⁷ Also, whether they

It is important to remember that not all systems exhibit the same properties and that there is no truly perfect material.

third; and myriad chromas and values at the incisal third. These differences are caused by various thicknesses and opacities of enamel and dentin.¹⁴ To best mimic these characteristics, two different types of translucent composite, one slightly more translucent than the other, can be used.¹⁴

Translucent does not mean transparent, as there is neither transparency in natural enamel nor in the composites used today.¹⁴ *Transparent* would refer to a glass-like material that allows 100% light transmission, whereas translucent materials are more pearl-like and demonstrate more opacity.¹⁴ The thickness of the material is a very important factor in the translucency of a restoration, since an increase in thickness blocks light transmission and dilutes the underlying coloring.¹⁴

Composites that are considered of pearly appearance demonstrate similar properties as translucent materials, such as refractive index and optical density, but shade selection typically varies from tooth to tooth.¹⁴ Dentists often must experiment with the many different products and shades to achieve the

envisioned final result.¹⁴ Contrary to popular belief, one shade of pearl does not necessarily correlate with the age of a tooth, as there are varying optical properties among different patients of different ages.¹⁴

Enamel and Dentin

By looking through the enamel, areas of different color saturation, hue, and value can be seen that are generated by the underlying dentin structure.¹⁴⁻¹⁷ The colors observed in natural dentition directly result from the dentin, since no color is present in the outside enamel.¹⁴ Defects or hypo-plastic spots often can be seen in the enamel matrix, whereas maverick colors of the dento-enamel junction are believed to originate from within the dentin.¹⁴⁻¹⁷

For example, by looking through the center part of a central incisor, varying degrees of opacity and translucency are visible.¹⁴⁻¹⁷ Where the enamel is slightly thinner, light picks up color more readily from the dentin.¹⁴⁻¹⁷ This directly enables those viewing the teeth to see more translucencies, different chromas

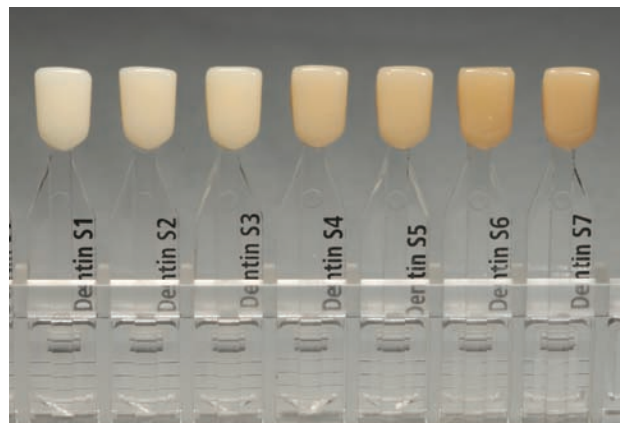
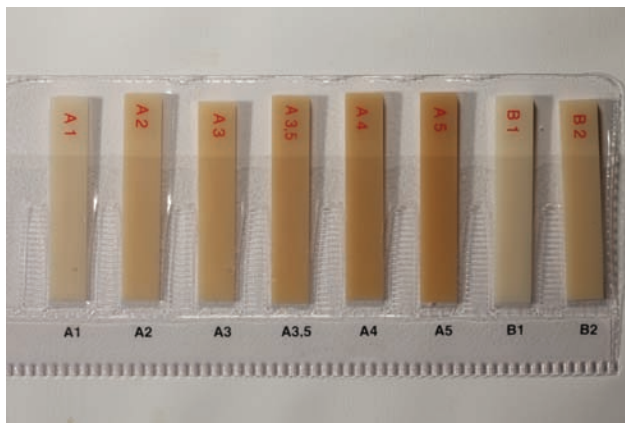
are VITA-based or not, they cannot be achromatic. Dentin composites can only be chromatic, since they bear hue (Figs 8a & 8b).¹⁵⁻¹⁷

Enamel

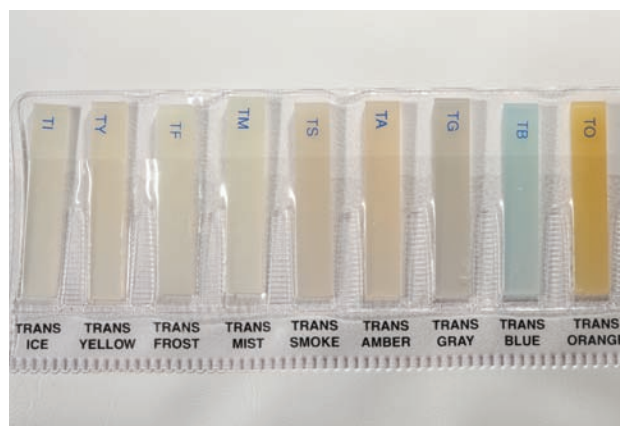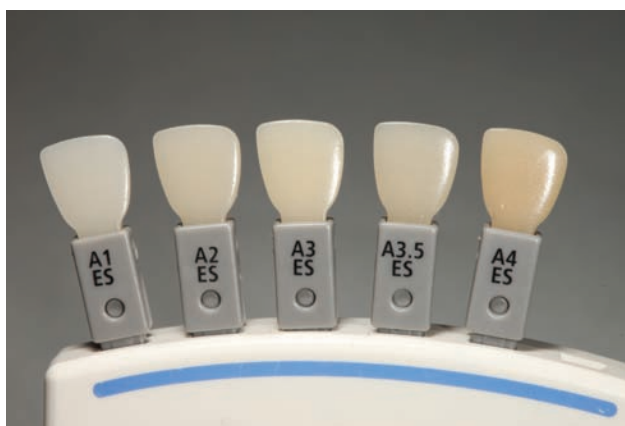
Enamels, however, can be either chromatic (VITA-based) or achromatic (non-VITA based) (Figs 9a & 9b).¹⁵⁻¹⁷ Enamel composites offer dentists many options, since they can be value or effect enamels.¹⁵⁻¹⁷ They can be used to impart translucency or to modify the color value.¹⁵⁻¹⁷ It is important to note that achromatic enamel composites are classified as such because they do not have a built-in VITA hue.¹⁵⁻¹⁷

Color Mapping

By understanding how each of these components of natural dentition influence coloring, dental professionals can create a color map to correlate what is envisioned for the final restoration and the shades of composite necessary to mimic the surrounding dentition.¹⁸ Typically used in the color-mapping stage of the restorative process, the



Figures 8a & 8b: Artificial dentin composites can be VITA-based or non-VITA based but should always generate a yellow-reddish hue of varying chroma.



Figures 9a & 9b: Artificial composite enamels can be chromatic (Vita-based) or achromatic (non-Vita based).

VITA Shade Guide (Vident; Brea, CA) is a tool to help ascertain components of tooth coloring such as hue, chroma, and value.¹⁸ To understand how the guide works, an example would be VITA Classic Shade A2, where A is the color (reddish brown) and 2 is the chroma.¹⁸

enamel approach uses a VITA-based enamel, which gives the restoration a final hue, chroma, and—to some extent—value areas that are missing.¹⁸ The achromatic enamel approach involves the use of a milky-white, semi-translucent layer, which can have vary-

ing degrees of translucency, depending on the brand and manufacturer, to modulate the perception of the underlying chroma and value provided by the dentin.^{5,6,18}

opacity can be seen.^{5,6,8} At the middle third, where color appears to come from the tooth surface, VITA-based chromatic enamels should also be used over the dentin composite.^{5,6,8} When utilizing the chromatic approach, a minimum of approximately four VITA shades of

When interpreting what shade will be needed for a restoration, it is necessary to understand what the hue of the tooth to be restored represents.

However, there is little to no correlation between the tabs and composites with this conventional ceramic shade tab.¹⁸ Dentists must therefore break down the color and its three dimensions and add the fourth dimensions, translucency and opacity, to replicate what A2 actually stands for on the guide.¹⁸

Two different approaches can be used to undertake such a task when using direct composites.¹⁸ The chromatic

ing degrees of translucency, depending on the brand and manufacturer, to modulate the perception of the underlying chroma and value provided by the dentin.^{5,6,18}

Chromatic Approach

Chromatic enamels are best utilized at the thinnest areas of restorations, (e.g., the cervical), where more color and

enamel will be required, including four shades of dentin.^{5,6,8} Non-Vita enamels also can be added for achieving effect, adding up to a total of 13 shades to allow for the best esthetic results.

Examples of chromatic materials include Durafill VS (Heraeus Kulzer; South Bend, IN), shades A1, B1, and C1, based on the VITA Shade Guide.^{5,6,8} Venus Diamond (Heraeus Kulzer) has chromatic enamels in A and B, while

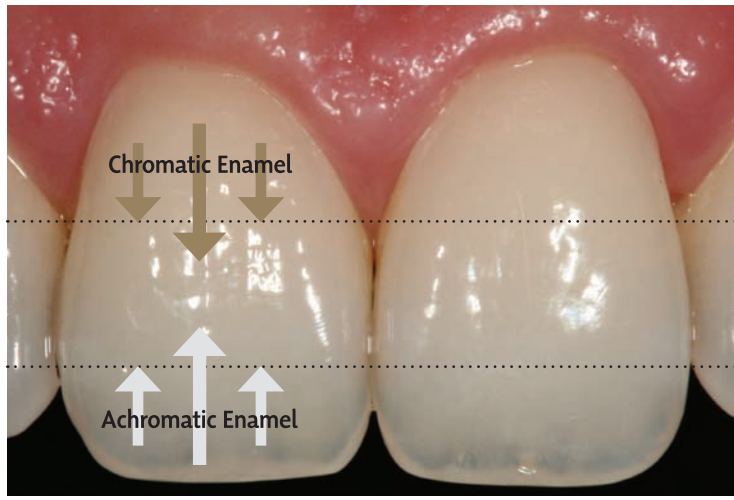


Figure 10: Chromatic and achromatic enamels can be used at specific areas of a tooth to create a gradient of hue, chroma, value, and translucencies.

If the enamel is very translucent and slightly thinner, the underlying dentin will be more prominently displayed.

IPS Empress Direct (Ivoclar Vivadent; Amherst, NY) has chromatic enamel shades A, B, C, and D. Chromatic body enamels generate the hue, chroma, and value (to some extent) of the restoration, while providing color on the outermost surface of the teeth.^{5,6,8}

When interpreting what shade will be needed for a restoration, it is necessary to understand what the hue of the tooth to be restored represents. If the tooth is believed to be an A-based color, then the VITA Shade Guide should be used to understand the color, after which the chromatic enamel would be selected according to the shade. Most times, however, the color from the shade guide may not match the composite material selected. To correct this issue, a different technique is required to obtain the final shade.^{5,6,8}

First, select an artificial dentin with a higher chroma than the final desired color. This is done because, even in nature, dentin is higher in chroma than outer enamel. Therefore, the dentin composite needs to be one shade higher to better mimic the natural dentition. Then, the outer enamel should be left slightly translucent rather than opaque, so that chroma and effects from the underlying dentin can be seen more

clearly. This also allows the enamel to display hue. It is important to note that the opacity and thickness of enamel is crucial in determining how much of the underlying dentin will be seen. Ultimately, the final color of the restoration will be a combination of the underlying dentin composite and the color of the enamel composite.^{5,6,8}

Achromatic Approach

Achromatic enamels should be utilized in areas of high translucency, such as the incisal third, where the mammelons can be seen underneath (Fig 10). When there is a greater display of dentin through the natural enamel, achromatic non-VITA based enamels should also be used. When using the achromatic approach, a minimum of four enamel and four dentin shades are required to enable modulation of enamel value and chroma and achieve the required esthetics.^{5,6,8,17}

To begin the achromatic approach, evaluate the basic hue of the tooth. Then examine the dentin and how the natural chroma is diluted by the thickness and opacity of the natural overlying enamel. For the achromatic approach, as with the chromatic approach, it is

necessary to choose a dentin composite one to two chroma higher than the intended final shade.^{5,6,8,17}

Once the dentin composite shade has been selected, non-VITA based achromatic enamels should be chosen to provide higher value areas for the lobes and lower value areas for the center part of the tooth. When the enamel composites are placed over the dentin, the color should be seen coming from within. If the enamel is very translucent and slightly thinner, the underlying dentin will be more prominently displayed. As a result, many of the effects created when layering the dentin also will be clearly seen. However, if the enamel is thicker and very opaque (higher value), the effects will not be seen as clearly.^{5,6,8,17}

It is important not to make the dentin too thin near the cervical, as this will make the color insufficiently evident. Therefore, the modulation of enamel thickness and opacity is the deciding factor in determining how much color will be seen.^{5,6,8,17}

When selecting a shade of value—and chroma—modifying enamels, only shade guides provided with the composite system that are made of the actual composites should be used, as

What helps patients smile in this economy?

The lowest monthly payment :)

Treatment Fee*	Terms to*	Payment as low as*
\$5,000	60 months	\$107
\$10,000	72 months	\$176
\$20,000	84 months	\$323
\$40,000	84 months	\$646



Visit springstoneplan.com
Call 800-630-1663

* Extended plans from \$2,000-\$40,000 with rates from 5.99% APR. Patients get the rates they've earned and can prepay without penalty. Full range of no-interest plans available, starting at \$499. For no-interest and extended plan details, visit springstoneplan.com.

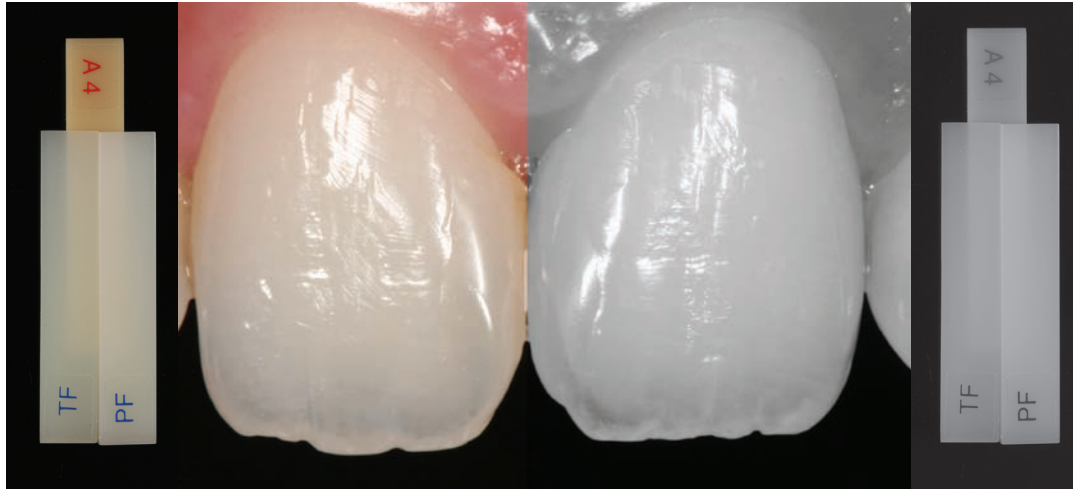
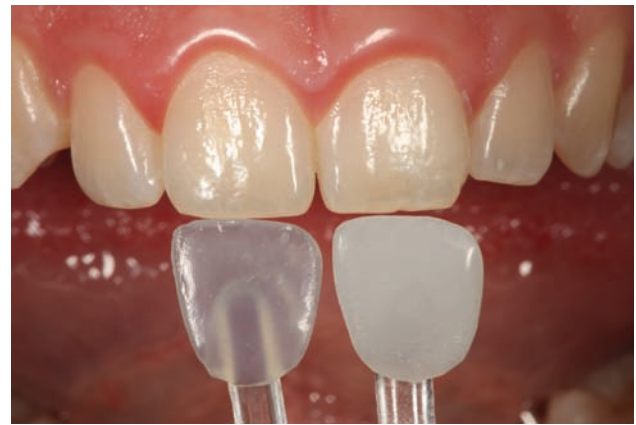
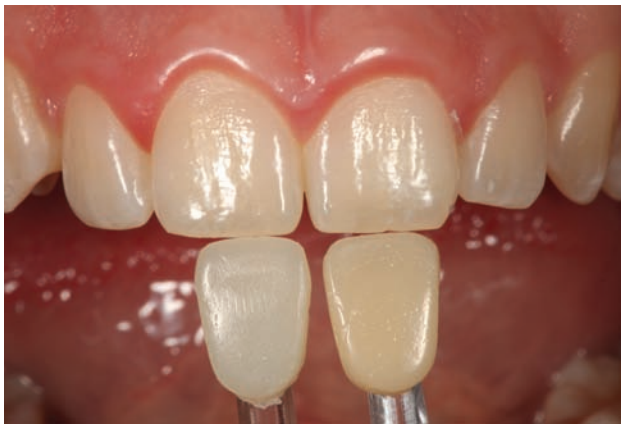
Figure 11: Achromatic enamels are used to modulate the chroma and value of the underlying dentin.



Figures 12a & 12b: Customized composite shade tabs are the most effective and predictable way to select the shade because they are true to the actual restorative material's color.

reports demonstrate no correlation of shade pairing between the composite shade and acrylic shade tabs.¹⁹⁻²¹ For example, when selecting a shade to be used from a suitable composite system (e.g., Vit-I-escence, Ultradent Products; South Jordan, UT), if shade A2 from the shade tabs matches the tooth, then A3 should be used for the dentin (for previously discussed reasons). By using the composite system's shade tabs and not the VITA Shade Guide, the selected enamel will modulate the chroma and value of the underlying dentin as expected, since the guide provides the final shade of the actual composite being used (Fig 11).¹⁹⁻²¹

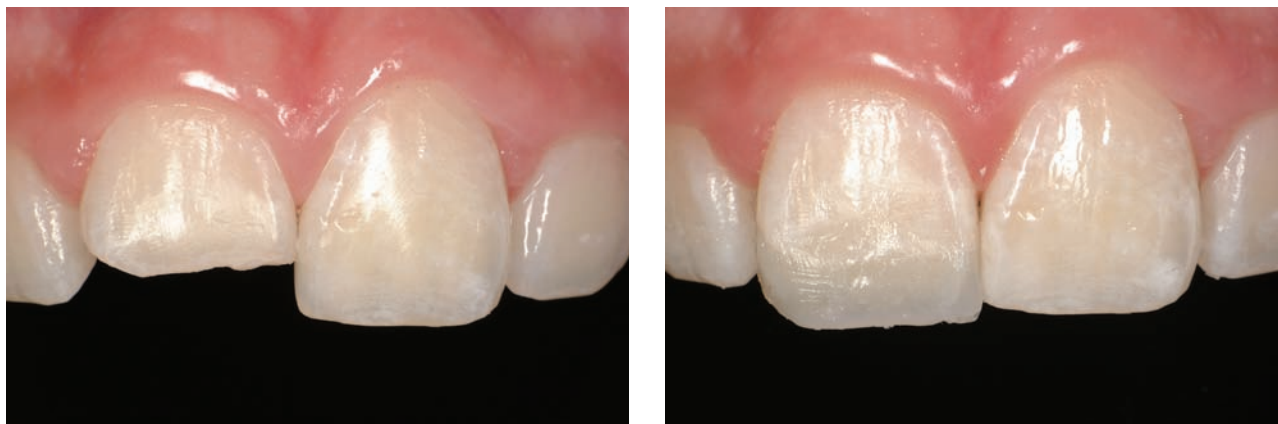
Shade Selection

Given the variety of composite systems available, choosing the correct shade for

a direct restoration can be difficult.^{5,6} Although the VITA Shade Guide is the primary resource for shade selection, research has shown that poor color compatibility of corresponding resin composite shades is notorious.^{5,6} Research also has shown that there is no true correlation between the VITA Guide and actual composites, making the selection of the proper shade an even more daunting task.^{5,6} Many composite systems have tried to correct this problem by including guides specific to their products, but many are made of acrylic and do not represent the actual characteristics of the cured material. The only way to be sure that a composite shade guide displays the correct color and detail of the material is if the guide is composed of the material itself.^{5,6}

For the chromatic and achromatic enamels, dentists must develop their own custom shade guide.^{5,6} A fairly simple project, the time used to create this guide will save precious clinical time and patient frustration, as restorations will be completed correctly the first time.^{5,6}

To begin, use a VITA Shade Guide and your choice of putty impression material to create an imprint, which should be 2.5 mm at the cervical and 0.5 mm at the incisal third. Then, using the selected dentin and enamel composite material, fill the imprint and place a glass slab over the top. Cure the material and remove the glass slab. After curing, use anything suitable to create handles for the newly developed shade tabs and glue them in place with cyanoacrylate. Print the composite shade brand and



Figures 13a & 13b: A color mock-up is an effective tool for ascertaining the impact that each layer will have individually and collectively and allows for correction before the final restoration.

place it on the tab(s) to complete the custom shade guide (Figs 12a & 12b).

Note that these guides only work for the syringes that they were taken from, since studies show that colors vary from batch to batch of resin composites.^{5,6} When a new syringe is ordered, a new guide must be made for the new syringe to ensure perfect shade matching.^{5,6} Although this process can be time-consuming, it is much better than redoing an entire restoration because a patient is dissatisfied.

ered precious clinical time, it will save time during the procedure, which is the ultimate goal of any restorative process (Figs 13a & 13b).

Conclusion

This article, the first of two parts, has introduced an artistic philosophy for performing esthetic direct anterior composite restorations based on principles of emulating the proper form, color, and function of natural dentition. A

- Carlson RS. Dental artistry. *Gen Dent.* 2003;54(4):326-30.
- Bauer J, Chiappelli E, Spackman S, Prolo P, Stevenson R. Evidence-based dentistry: fundamentals for the dentist. *J Calif Dent Assoc.* 2006;34(6):427-32.
- Nathanson D. Current developments in esthetic dentistry. *Curr Opin Dent.* 1991;1(2):206-11.
- Fahl N Jr. A polychromatic composite layering approach for solving a complex Class IV/direct

The only way to be sure that a composite shade guide displays the correct color and detail of the material is if the guide is composed of the material itself.

Color Mock-Up

After selecting the correct shade or shades from the custom shade guide, a color mock-up should be completed.^{5,6,22} Utilizing a silicone stent or matrix based on the original or final wax-up, create a color mock-up to visualize and rehearse the shading of the final restoration. During this process, the lingual shelf, the dentin, any characteristics (e.g., white spots), chromatic and achromatic enamels should be applied to envision highly esthetic final results.^{5,6,22} This tool enables thickness corrections prior to creation of the final restorations and only requires about 15 minutes. Although this may be consid-

step-by-step procedural approach to solving day-to-day anterior direct restorative challenges, which include shade selection, color mapping, and composite resin selection has been outlined.

Part 2 of this article, which will address more step-by-step procedures for anterior direct restorative challenges, will appear in the Winter 2011 issue of the Journal.

References

- Heymann HO. The artistry of conservative esthetic dentistry. *J Am Dent Assoc.* 1987;Dec. (Spec. No.):14E-23E.
- Carlson RS. Dental artistry. *Gen Dent.* 2003;54(4):326-30.
- Bauer J, Chiappelli E, Spackman S, Prolo P, Stevenson R. Evidence-based dentistry: fundamentals for the dentist. *J Calif Dent Assoc.* 2006;34(6):427-32.
- Nathanson D. Current developments in esthetic dentistry. *Curr Opin Dent.* 1991;1(2):206-11.
- Fahl N Jr. A polychromatic composite layering approach for solving a complex Class IV/direct veneer-diastema combination: part I. *Pract Proced Aesthet Dent.* 2006;18(10):641-5.
- Fahl N Jr. A polychromatic composite layering approach for solving a complex Class IV/direct veneer-diastema combination: part II. *Pract Proced Aesthet Dent.* 2007;19(1):17-22.
- Burke FJ, Palin WM, James A, Mackenzie L, Sands P. The current status of materials for posterior composite restorations: the advent of low shrink. *Dent Update.* 2009;36(7):401-2, 404-6, 409.
- Fahl N Jr. Achieving ultimate anterior esthetics with a new microhybrid composite. *Compend Contin Educ Dent (Suppl).* 2000;(26):4-13.

9. Keulemans F, Palav P, Aboushelib MM, van Dalen A, Kleverlaan CJ, Feilzer AJ. Fracture strength and fatigue resistance of dental resin-based composites. *Dent Mater.* 2009;25(11):1433-41.
10. Tjan AH, Chan CA. The polishability of posterior composites. *J Prosthet Dent.* 1989;61(2):138-46.
11. Yazici AR, Celik C, Dayangaç B, Ozgünlaltay G. The effect of curing units and staining solutions on the color stability of resin composites. *Oper Dent.* 2007;32(6):616-22.
12. Sockwell C. Clinical evaluation of anterior restorative materials. *Dent Clin North Am.* 1976;20(2):403-22.
13. Devoto W, Saracinelli M, Manauta J. Composite in everyday practice: how to choose the right material and simplify application techniques in the anterior teeth. *Eur J Esthet Dent.* 2010;5(1):102-24.
14. Friebel M, Povel K, Cappius HJ, Helfmann J, Meinke M. Optical properties of dental restorative materials in the wavelength range 400 to 700 nm for the simulation of color perception. *J Biomed Opt.* 2009;14(5):054029.
15. Fahl N Jr. Ultimate aesthetics with composites: when art and science merge. *Dent Today.* 1999;18(9):56-61.
16. Fahl N Jr., Denehy GE, Jackson RD. Protocol for predictable restoration of anterior teeth with composite resins. *Oral Health.* 1998;88(8):15-22.
17. Fahl N Jr. Optimizing the esthetics of Class IV restorations with composite resins. *J Can Dent Assoc.* 1997;63(2):108-11, 114-5.
18. Priest G, Lindke L. Tooth color selection and characterization accomplished with optical mapping. *Pract Periodontics Aesthet Dent.* 2000;12(5):497-503; quiz 504.
19. Paravina RD, Kimura M, Powers JM. Color compatibility of resin composites of identical shade designation. *Quintessence Int.* 2006;37(9):713-9.
20. Park SK, Lee YK. Shade distribution of commercial resin composites and color difference with shade guide tabs. *Am J Dent.* 2007;20(5):335-9.
21. Browning WD, Contretas-Bulnes R, Brackett MG, Brackett WW. Color differences: polymerized composite and corresponding Vitapan Classical shade tab. *J Dent.* 2009;37(Suppl 1):e34-9.
22. Felipe LA, Monteiro S Jr., De Andrada CA, Ritter AV. Clinical strategies for success in proximal composite restorations. part ii: composite application technique. *J Esthet Restor Dent.* 2005;17(1):11-21. **JCD**

About the Author: Dr Fahl earned his DDS degree in 1987 from Londrina State University in Brazil. Dr. Fahl also has a Certificate in Operative Dentistry and a Master of Science degree from the University of Iowa.
Author Disclosure: Dr. Fahl receives honoraria from Ultradent Products.



Last Quarter Results... C 4 Yourself®

Culturally • Clinically • Managerially • Financially

"We are pumped to be coached at our potential"

- Dr. James Hutson

"She gets me! I know she is set apart as coach, to create momentum, hit our mark daily, consistently & to surpass our expectations"

- Dr. Cristin Wallace

877.528.3962
www.RhondaMullins.com
Rhonda@RhondaMullins.com



Vice President - Georgia Academy of Cosmetic Dentistry



> THE INSIDER'S GUIDE TO A SEXY SMILE | Summer/Fall 2006

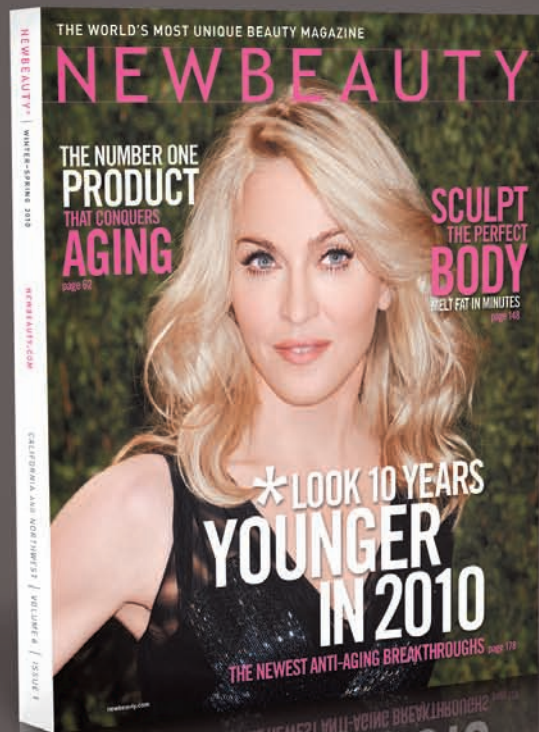

> I WANT TO REMOVE STAINS | Winter/Spring 2008



> ECO-FRIENDLY DENTISTRY | Winter/Spring 2010

— THE ONLY —
**BEAUTY MAGAZINE WITH
 COSMETIC DENTISTRY
 EDITORIAL**
 — IN EVERY ISSUE —



NEWBEAUTY®

& AACD | A BEAUTIFUL PARTNERSHIP

To learn more call **866-NEWBEAUTY** or visit www.newbeauty.com

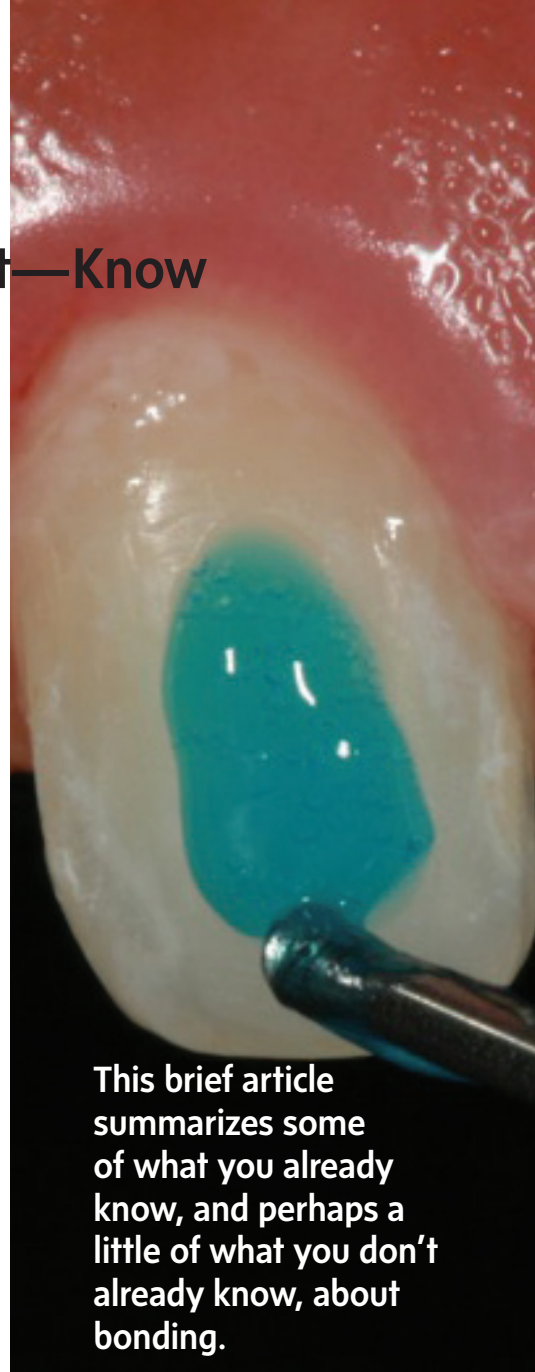20 TIPS ON BONDING

Things You Might—or Might Not—Know

Buonocore introduced the acid-etch technique for bonding resin-based materials to enamel in 1955.¹ It took nearly a quarter-century for this technique to be widely accepted and another 10 years before predictable dentin bonding became a reality.

We have learned much about enamel and dentin bonding over the years, but it is easy to be overwhelmed by the sheer volume of information available on this topic. For example, a recent Medline search revealed that more than 6,500 papers have been published on dentin bonding alone. This brief article summarizes some of what you already know, and perhaps a little of what you don't already know, about bonding.

Edward J. Swift Jr., DMD, MS



This brief article summarizes some of what you already know, and perhaps a little of what you don't already know, about bonding.

1

One of the difficulties with dentin bonding is the inherently complex composition and structure of dentin itself—and adhesion to sclerotic or caries-affected dentin is more difficult than bonding to normal dentin.

2

Adequate light activation is required to optimize bond strengths of any adhesive. **Consider a longer exposure time if the distance between the light guide and the bonded interface is more than 2 to 4 mm** (e.g., in a Class II preparation).

3

Bonds of etch-and-rinse adhesives to dentin are more durable when the resin-dentin interface is surrounded by a rim of etched and bonded enamel.

IPS e.max[®]

“IT IS BOTH **STRONG** AND
BEAUTIFUL. WHAT **MORE**
COULD I ASK FOR?”

Dr. David Hornbrook

IPS e.max lithium disilicate brings a new level of confidence to dentistry. With high esthetics and high strength, we now have the best of both worlds.

theworldspeaksemax.com

all ceramic
all you need



100% CUSTOMER SATISFACTION
GUARANTEED!

ivoclarvivadent.com

Call us toll free at 1-800-533-6825 in the U.S., 1-800-263-8182 in Canada.
©2010 Ivoclar Vivadent, Inc. IPS e.max is a registered trademark of Ivoclar Vivadent.

**ivoclar**
vivadent
passion vision innovation

4

Many etch-and-rinse systems rely on a moist bonding technique for optimal dentin bonding. This is particularly true for systems that have an acetone solvent, less so for those containing ethanol, and even less so for those that contain water.

5

Avoid extended etching times on dentin when using etch-and-rinse adhesives. **Over-etching can demineralize dentin to a greater than desired depth**, making penetration of the resin primer and bonding agent more difficult. Collagen left uncoated by resin provides a potential location for bond degradation

6

Isolation is important; contamination of tooth surfaces with saliva or blood during bonding procedures reduces adhesion of the resin.

7

Chlorhexidine inhibits a class of intrinsic dentinal enzymes that are released by etching and can cause degradation of the hybrid layer, so it can improve the durability of the resin-dentin bond formed by an etch-and-rinse adhesive.

8

The use of a glass ionomer liner, especially in deeper dentin, can reduce postoperative sensitivity with etch-and-rinse adhesives.

9

Re-wetting agents containing glutaraldehyde and hydroxyethylmethacrylate (HEMA) stabilize the hybrid layer formed by etch-and-rinse adhesives and help to reduce postoperative sensitivity.

10

Self-cure and dual-cure composite should not be used with some light-cured adhesives because of chemical incompatibilities related to pH of the adhesive.

11

Despite much anecdotal evidence that self-etch systems have less postoperative sensitivity than etch-and-rinse systems, this has never been verified in clinical trials. **The incidence of postoperative sensitivity is small if either type of system is used properly.**

12

Although the bond of resin to tooth structure is primarily mechanical, one monomer present in some mildly acidic self-etch primer systems provides a chemical bond to hydroxyapatite. This improves the durability of the resin bond.

13

Roughening enamel improves adhesion of self-etch systems.

Additional Reading

- Ernst C-P. Ask the experts: dentin/enamel bonding. *J Esthet Restor Dent.* 2010;22:210-2.
- Perdigão J. Ask the experts: dentin/enamel bonding. *J Esthet Restor Dent.* 2010;22:82-5.
- Sarr M, Kane AW, Vreven J, Mine A, Van Landuyt KL, Peumans M, Lambrechts P, Van Meerbeek B, De Munck J. Microtensile bond strength and interfacial characterization of 11 contemporary adhesives bonded to bur-cut dentin. *Oper Dent.* 2010;35:94-104.

14

Selective etching of enamel margins improves the bond of self-etch systems, but contact of the etchant with dentin should be avoided because it reduces dentin bond strengths for most (not all) self-etch materials.

15

Agitation of most self-etch primers and self-etch adhesives improves their bond strengths.

16

Coating an all-in-one self-etch adhesive with a layer of hydrophobic bonding resin can improve its dentin bond strengths and clinical performance. (Of course, by adding this extra layer, you have converted the self-etch adhesive into a self-etch primer!)

17

A technique called immediate dentin sealing has been introduced for use with bonded indirect restorations. It reduces sensitivity during the provisional phase and has been shown to provide excellent bond strengths.

18

Bond strength tests are a useful tool for evaluating dental adhesives and they provide reasonable information about the likely clinical performance of a material. Materials that achieve high bond strengths in independent testing by multiple investigators are more likely to perform well clinically than materials that achieve low bond strengths under the same conditions. That said, a high average bond strength in the laboratory is not necessarily a guarantee of excellent clinical performance, nor does it make a particular adhesive the best choice for a particular clinical indication.

19

Newer does not necessarily mean better. Based on their clinical performance, the so-called fourth-generation materials (three-step etch-and-rinse) are better than the so-called seventh-generation materials (all-in-one self-etch).

20

Fortunately, the all-in-one self-etch materials are getting better.

Reference

1. Buonocore MG. A simple method of increasing the adhesion of acrylic filling materials to enamel surfaces. *J Dent Res.* 1955;34:849-53. **JCD**




About the Author: Dr. Swift is Professor and Chair of the Department of Operative Dentistry at the University of North Carolina School of Dentistry.

Author Disclosure: The author did not report any disclosures relevant to this article.

- Swift EJ. Ask the experts: dentin/enamel bonding. *J Esthet Restor Dent.* 2010;22:4-6.
- Van Meerbeek B. Ask the experts: dentin/enamel bonding. *J Esthet Restor Dent.* 2010;22:157.
- Van Meerbeek B, Peumans M, Poitevin A, Mine A, Van Ende A, Neves A, De Munck J. Relationship between bond-strength tests and clinical outcomes. *Dent Mater.* 2010;26:e100-e121.

SIMPLE, SUCCESSFUL COMPOSITE REPAIRS

Techniques to Remedy Surface Defects



Corky Willhite, DDS, FAGD, AACD Accredited Fellow
Illustrations by Zach Turner

INTRODUCTION

When patients present with esthetic composite restorations requiring repair, or if defects are detected during the direct restorative process, a simple technique for repairing composite defects is invaluable.¹ This basic technique can be varied slightly to correct composite defects at a couple of different points in the restorative process: initial placement and post-treatment. These procedures can remedy defects involving pits and voids, fractures, white lines, and improper contouring (**Figs 1-2**).

Key to this technique's success is ensuring that the repair is completed prior to any polishing if the procedure is to be accomplished during the initial fabrication of the restoration. If the surface has already been polished, added composite will not bond to the surface. Therefore, it will be necessary to roughen the composite surface in order to repair the composite defect (**Fig 3**).^{2,3}

Additionally, for the post-treatment repair of microhybrid and nanohybrid restorations more than one day old, a micro-etching sandblast should be applied to the defective area prior to etching with 35% phosphoric acid.⁴ For microfill repairs, this author does not recommend sandblasting. Because the microfill composites contain such small and uniform particles, micro-etching decreases the mechanical retention created by the bur marks.

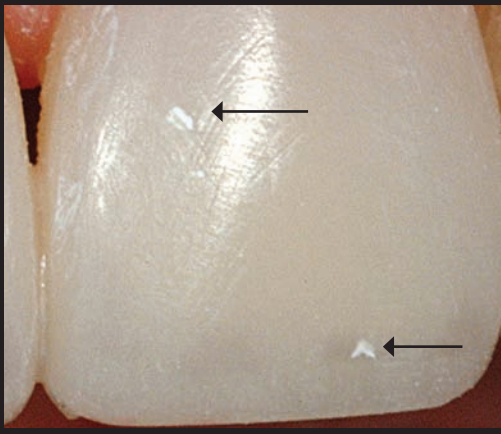


Figure 1: Close-up view showing two defects on tooth #9.

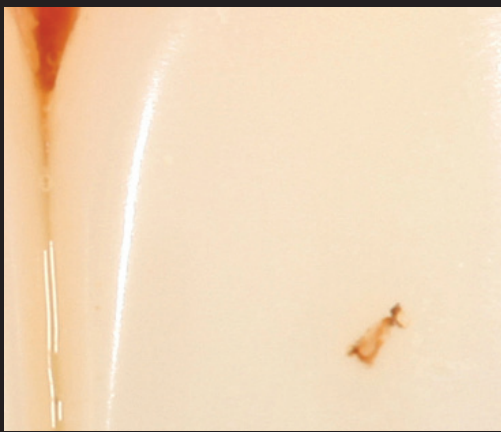

Figure 2: Close-up view of a four-and-a-half year old composite restoration on tooth #9 that presented with a stained void.

Heraeus

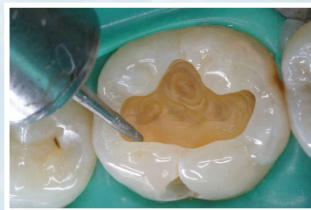
Venus® Bulk Fill

Faster, esthetic posterior restorations. **Simplified.**

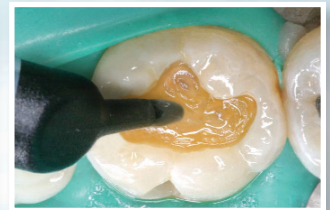Venus® Bulk Fill is a low stress flowable composite that will enable bulk filling of 4mm and provide an efficient and easy solution for esthetic posterior restorations.

Venus Bulk Fill delivers:

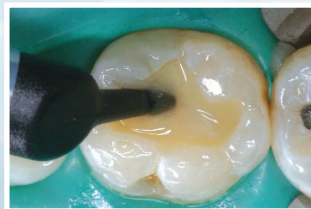
- Self-adaptive handling eliminates steps and provides ideal coverage of cavity floor and walls
- Long working time for when you need it
- Highly radiopaque for more accurate diagnosis



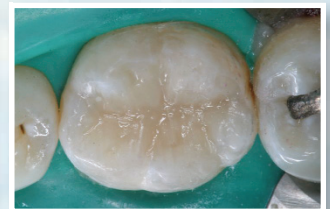1. Prep



2. Fill with Venus Bulk Fill after adhesive placement



3. Final layer with Venus Diamond



4. Final Class I restoration by Dr. Amanda Canto, Houston, TX

To learn more about the clinical advantages of Venus Bulk Fill, call toll-free **877-258-5937** or visit www.heraeusdentalusa.com.

82% of surveyed dentists claim a **SAVINGS UP TO 10 HOURS OF CHAIR TIME** per month when they use a bulk fill material.*

* Integrated Media Survey, May 2010. © 2010 Heraeus Kulzer, LLC
Venus® is a registered trademark of Heraeus Kulzer GmbH.

Venus®
The New Esthetics

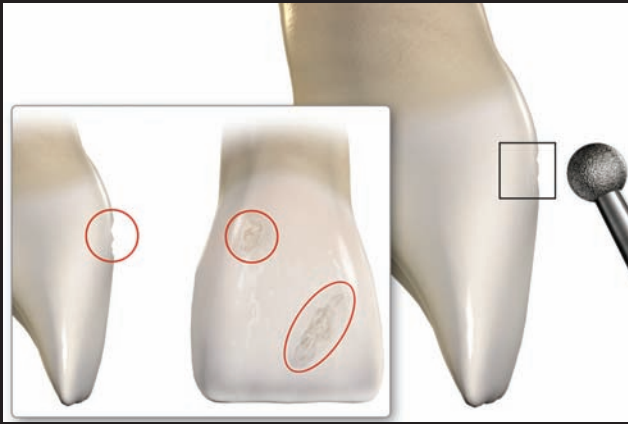


Figure 3: Repairing a composite defect will require roughening the composite surface.

Technique

STEP 1.

If the composite surface has already been polished, lightly roughen the area with a coarse contouring disk or a fine-grit diamond bur. On the unpolished or roughened surface with the defect, place a large, round, fine-grit diamond bur (8801-018, Brasseler USA; Savannah, GA) on the surface of the restoration (Fig 4), engaging it only deep enough to make a shallow saucer-shaped preparation (Fig 5). As a beveled margin is desired (Fig 6), do not allow the bur to sink deeper into the composite surface, which would create a butt joint margin. If the defect extends deeper into the saucer-shaped preparation, to avoid making the repair larger than necessary, use a smaller round bur to deepen only the specific area of the deeper defect (Fig 7).



Figure 4: Use a large, round, fine-grit diamond bur on the surface of the restoration.




Figure 6: A beveled margin is desired.




Figure 5: The bur should only engage deep enough to make a saucer-shaped preparation.



Figure 7: If the defect extends deeper into the saucer-shaped preparation, use a smaller round bur to deepen only that area.

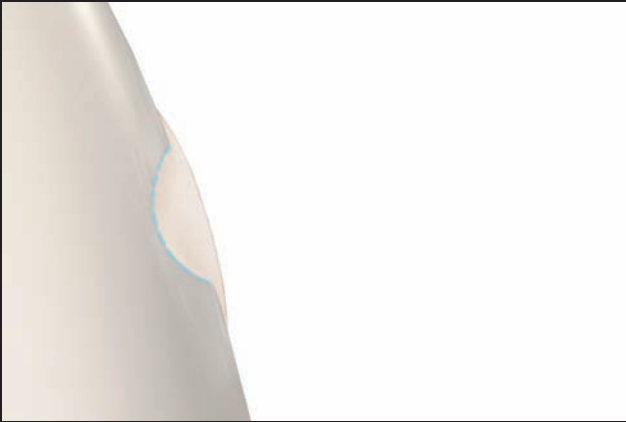


Figure 8: Etch the preparation to clean debris and apply a thin layer of unfilled resin, but do not cure at this time. (Fig 8).

STEP 2.

Acid-etch the prepared area for three to five seconds to remove debris and clean the surface, rinse well, and dry thoroughly. Apply a thin layer of unfilled resin to the preparation. Do not light-cure at this time. (Fig 8).




Figure 9: Place and sculpt the composite, without over-bulking it, then light-cure. (Fig 9).

STEP 3.

Without over-bulking the repair, place and sculpt the composite. Light-cure the composite as directed. (Fig 9).



Figure 10: Contour the repair, then polish the restoration. (Figs 10-12).

STEP 4.

Contour the repair to mimic the natural dentition. After contouring the repair, complete a final polish of the restoration to achieve esthetic and functional success (Figs 10-12).

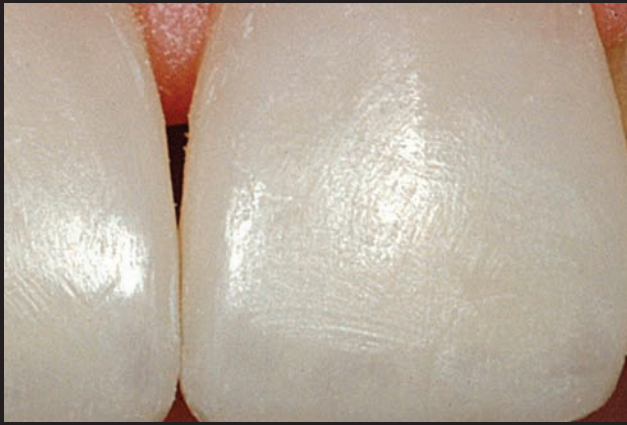

Figure 11: Close-up view of the repair to correct the defects shown in Figure 1.

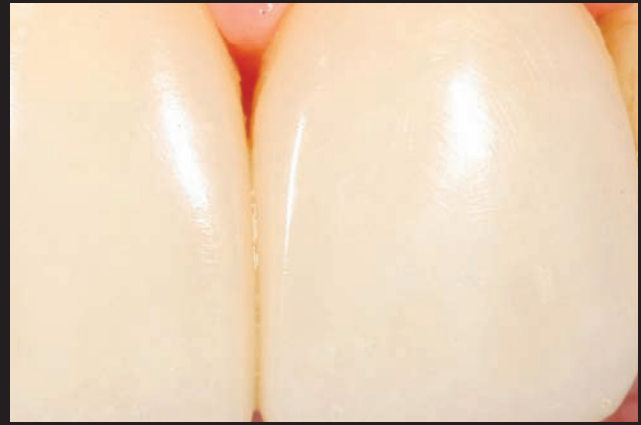

Figure 12: Close-up view of the repair to correct the stained void shown in Figure 2.

References

1. Denehy G, Bouschlicher M, Vargas M. Intraoral repair of cosmetic restorations. *Dent Clin North Am.* 1998;42(4):719-37.
2. Fawzy AS, El-Askary FS, Amer MA. Effect of surface treatments on the tensile bond strength of repaired water-aged anterior restorative micro-fine hybrid resin composite. *J Dent.* 2008 Dec;36(12):969-76. Epub 2008 Oct 7.
3. Nilsson E, Alaeddin S, Karlsson S, Milleding P, Wennerberg A. Factors affecting the shear bond strength of bonded composite inlays. *Int J Prosthodont.* 2000 Jan-Feb;13(1):52-8.
4. Yesilyurt C, Kusgoz A, Bayaram M, Ulker M. Initial repair bond strength of a nano-hybrid resin: effect of surface treatments and bonding agents. *J Esthet Restor Dent.* 2009;21(4):251-60. **JCD**

LARGER REPAIRS:

Repairs of fractures or other large problems can be accomplished using the same steps to prepare the existing surface. Round or smooth any sharp corners or irregular edges, then micro-etch, acid-etch, apply unfilled resin, and add composite.

About the Author: Dr. Willhite graduated from the Louisiana State University (LSU) School of Dentistry in 1979. He is an Adjunct faculty member in the Department of Prosthodontics at LSU. Dr. Willhite's private practice in suburban New Orleans is limited to cosmetic dentistry.

Author Disclosure: The author did not report any disclosures.



HAVE YOU SEEN
THE LIGHT?

"Fantastic"
"Practice Altering"
"Amazing"
"Revolutionary"

SEE THE LIGHT &
JOIN THE BELIEVERS:

VALO
broadband LED curing light

ULTRADENT
improving oral health globally
800.552.5512 • ultradent.com
© 2010 Ultradent Products, Inc. All rights reserved.

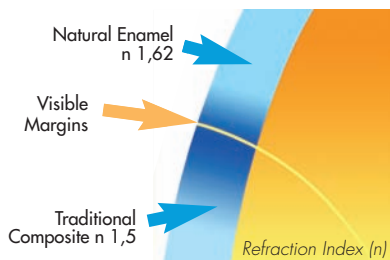
2010
REALITY
Five Star Award
REALITY'S
CHOICES

INTERNATIONAL DESIGN
EXCELLENCE AWARDS '10
DENTAL PRODUCT REPORT
TOP 100

The complete composite system

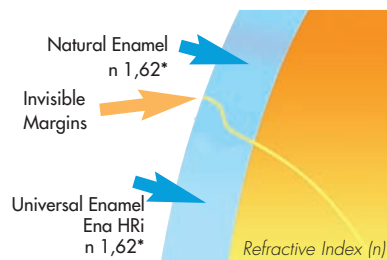
HRi: NATURAL ENAMEL CLONED IN COMPOSITE

TRADITIONAL COMPOSITE



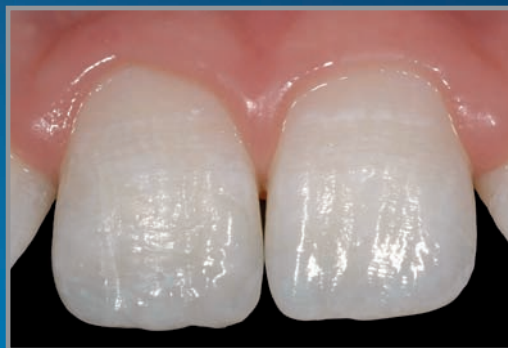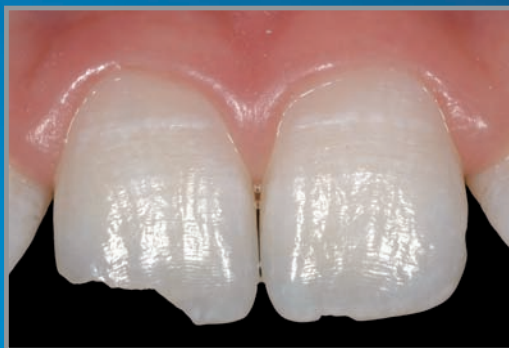The "Glass Effect" lowers the value of the restoration with a grey halo on the margin (dark line)

ENA HRi TECHNIQUE



Invisible margins, reproducing with HRi the same thickness of the natural enamel
 *Measurements refractive indices from the University of Fraunhofer Institute Dresden, on enamel shells natural and universal Ena HRi

RESTORATION MADE BY DR. LORENZO VANINI



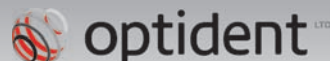ENA HRi UNIVERSAL ENAMEL IS THE FIRST AND ONLY COMPOSITE MATERIAL TO POSSESS THE SAME REFRACTIVE INDEX AS NATURAL ENAMEL.

- Invisible Margins
- Simplified Anatomic Restorations
- Excellent Polish

Available as a complete Kit, Starter Kit & New Bleach Shades



Micerium S.p.A.
 Via G. Marconi, 83 - I 6036 Avegno (Ge) Italy
 Tel. +39 0185 7887 870 • hfo@micerium.it



To order contact our dealer today:
 Optident USA
 Tel 541 741-8808 • hri@optident.com

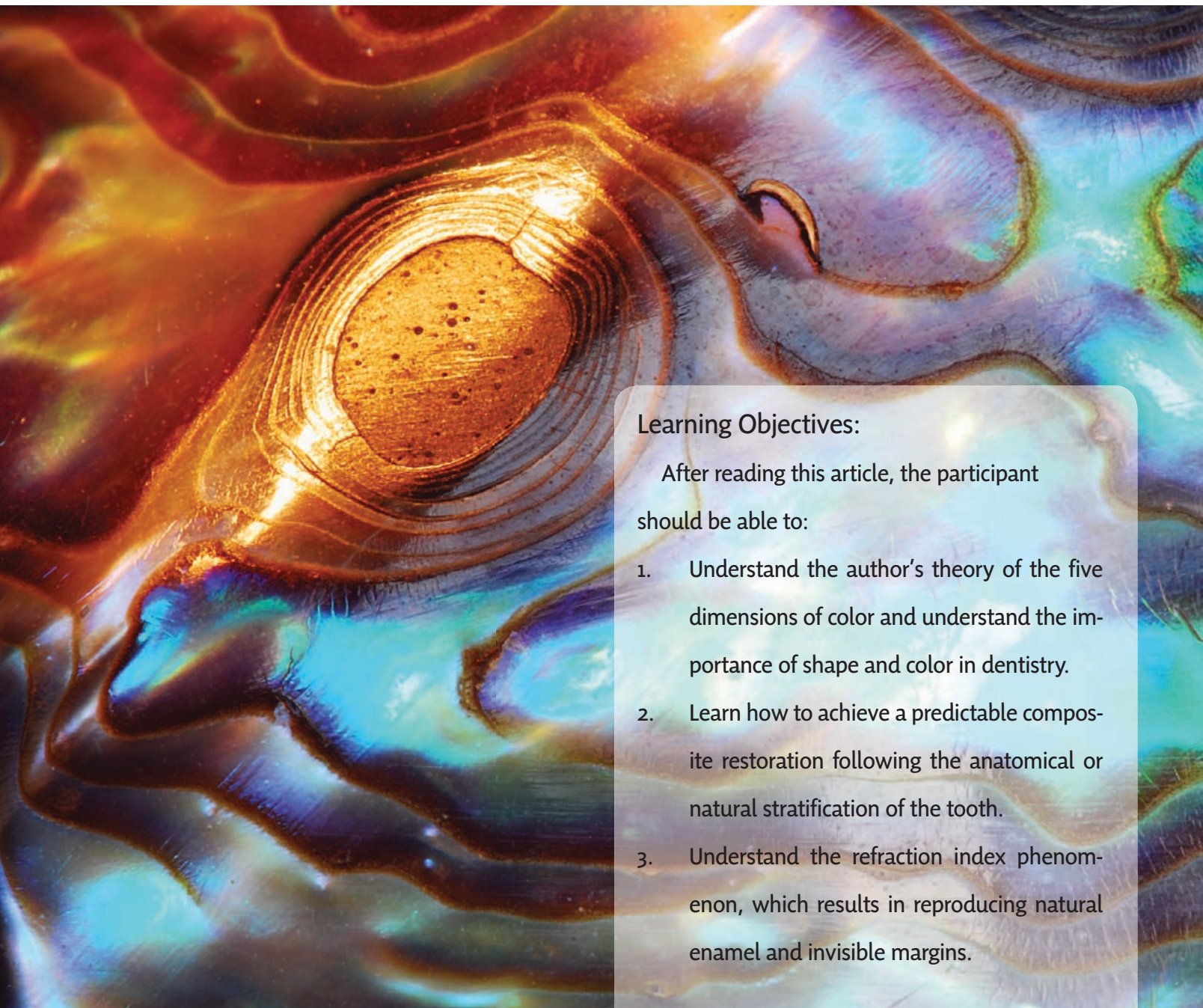


New AACD Member Benefit:
Earn CE—see page 100

Conservative **Composite** Restorations that **Mimic Nature**

A Step-by-Step Anatomical Stratification Technique

Lorenzo Vanini, DDS, MD



Learning Objectives:

After reading this article, the participant should be able to:

1. Understand the author's theory of the five dimensions of color and understand the importance of shape and color in dentistry.
2. Learn how to achieve a predictable composite restoration following the anatomical or natural stratification of the tooth.
3. Understand the refraction index phenomenon, which results in reproducing natural enamel and invisible margins.

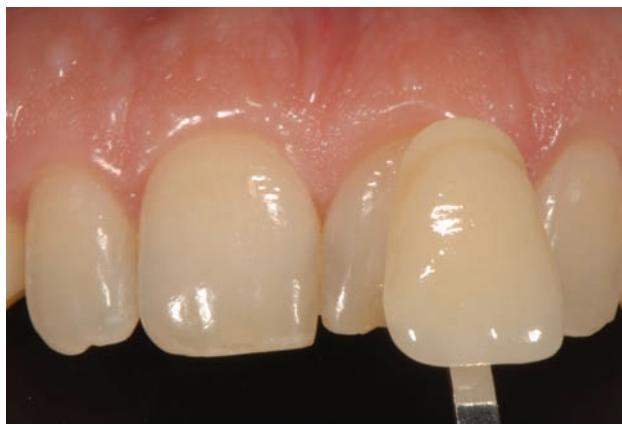

Figure 1: Color determination usually is achieved using shade guides made with different materials and stratification of the shade to be used by the dentist.

Abstract

This article presents the author's theory of the five dimensions of color as a basis for developing esthetic direct composite restorations that mimic natural dentition, and describes his step-by-step anatomical stratification technique for composite placement. By understanding the refractive index of composites and analyzing tooth structures, dentists can achieve predictable composite restorations that replicate the optical properties of natural enamel and dentin structures.

Introduction

Color matching, one of the key factors for determining esthetics, historically has been fraught with confusion. In the past, clinicians have tried to quantify tooth color and shade variables with various explanations and determinations. However, no single model has provided an exact solution to the problem of matching the color of restorative materials to that of natural dentition.¹ As a result, color matching is viewed as one of the most challenging tasks in esthetic dentistry.²

Additionally, during the past 20 years, dentists frequently have changed materials and techniques. Often they developed their own stratification techniques that sometimes were completely unrelated to the optical properties of the restorative material being used.

Compounding the problem has been the absence of precise protocol and planned management of the bodies and thicknesses of materials from manufacturers. The conventional color determination systems and techniques still used today are based on a chromatic scale more than 80 years old.¹ Based on Munsell's three dimensions of color, typical shade guides do not represent the body and thickness of natural tooth anatomy.³

Color matching is viewed as one of the most challenging tasks in esthetic dentistry.


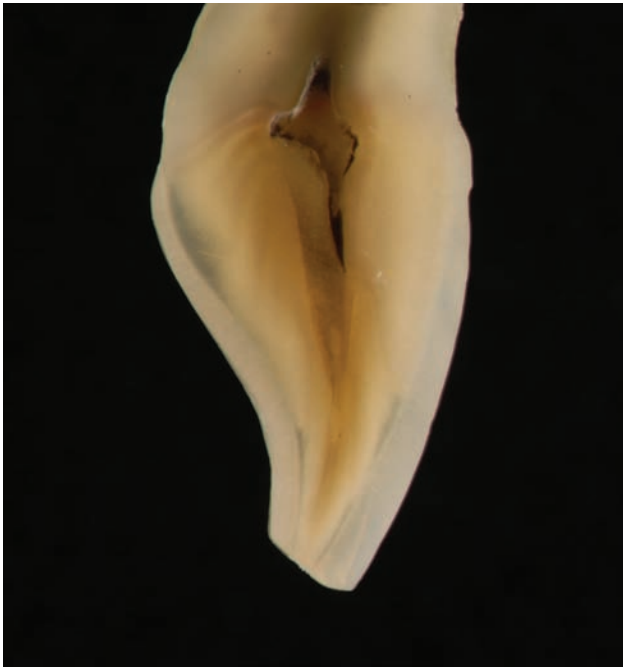
Materials should serve the clinician, not vice versa. Each composite system should be developed based on research and reproducible, universal techniques for determining color.⁴⁻⁶ Therefore, to obtain a predictable esthetic restorative result, precise and repeatable clinical protocol that begin with analysis of tooth shape and five color dimensions are required.^{1,6} Such analysis will enable clinicians to realize a stratification technique that incorporates dentin and enamel materials specifically developed to reproduce the determined tooth anatomy.

The Five Color Dimensions of Teeth

Color in dentistry usually is defined using shade guides based upon the 1898 theory of American painter Albert Henry Munsell, which Clark applied to dentistry in 1930.⁷ According to this theory, color is composed of three dimensions: hue, chroma, and value (Fig 1). Hue is the basic shade of the tooth; chroma is the degree of saturation of the hue; and value represents luminosity. The Classic VITA Shade Guide (Vident; Brea, CA) presents four basic hues (e.g., A, B, C, and D) and four chromas for each hue.

Tooth color, however, is actually a complex culmination of many factors resulting from the interaction of enamel and dentin with light during the refraction and reflection phenomenon of light waves. In the enamel area, shorter waves close to white-blue dominate, while the longer yellow-orange waves are more evident in the dentin.

Tooth enamel (Figs 2a & 2b) displays the unique light characteristics of reflection, absorption, and transmittance. The crystalline structure of the enamel prisms allows light to pass freely, while the inter-prismatic substance is opaque. Enamel acts as a translucent system, combining partial light transmission and internal light diffusion. The degree of enamel translucency depends on its thickness, which affects the value (luminosity) of the tooth, something that changes with age.



Figures 2a & 2b: Enamel absorbs and reflects light, filtering four basic shades: yellow-orange, white, blue, and amber. The hues of these four shades, or "chromatic chords," vary among patients and according to their age.

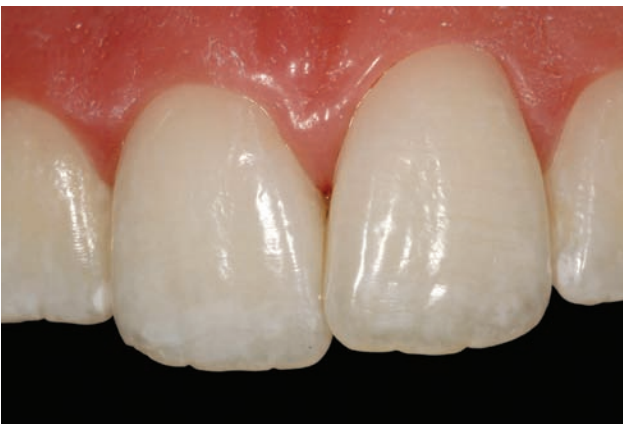

Figure 3: In young teeth, the enamel is thick, dense, with low translucency, high luminosity (value), and high reflectivity.

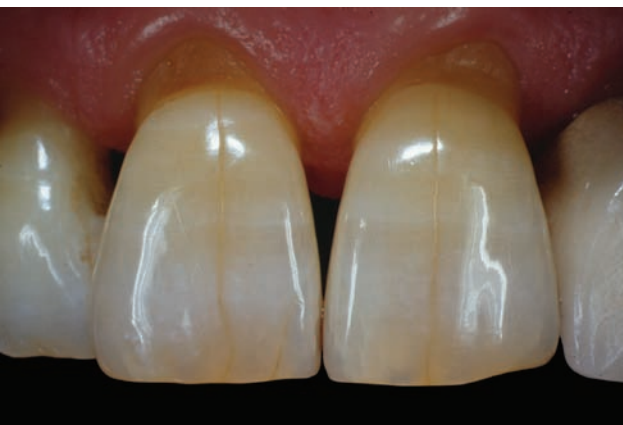

Figure 4: In older teeth, the enamel is thin, has low density, high translucency, low luminosity (value), and low reflectivity.

In young teeth (Fig 3), enamel is thicker and presents a high density, low translucency, high luminosity (value), and high reflectivity. In old teeth (Fig 4), enamel is thinner and presents low density, high translucency, low luminosity (value), and low reflectivity.

In the tooth area where only enamel is present (i.e., incisal edge), the internal light reflection phenomenon creates the opalescence effect, which typically appears as blue and amber hues that create the incisal halo. Frequently, less mineralized areas that appear white (intensives) are present in the enamel.

Dentin is responsible for the hue and chroma of a tooth. In natural teeth, the degree of dentin saturation decreases from the cervical to incisal, and chromaticity increases with aging.³ Dentin also is responsible for tooth fluorescence. It absorbs the ultraviolet energy and diffuses it back as bluish light. Fluorescence reduces metamerism, the phenomenon in which tooth color changes depending on the angle and source of light.

Tooth color, therefore, is the complex result of several factors that must be carefully analyzed in order to understand the unique features that characterize an individual patient's teeth. To analyze tooth color, the author advocates abandoning classical shade guides and, along with them, customary shade-taking habits in favor of performing a higher level of tooth color analysis.^{1,6} Ultimately the tooth color we see is a function of the physical properties of dentin and enamel, and their interaction with light.

The author's theory of tooth color incorporates a detailed analysis of each component responsible for tooth color that can be recorded using a special color chart and subsequently reproduced using specific materials during the stratification phase. Significant to this theory is the concept that tooth color is com-

Never worry about nicking the adjacent tooth again!



Introducing WedgeGuard

the new 2-in-1 interproximal tooth shield from Triodent.

Like other guards, WedgeGuard prevents the bur from nicking the adjacent tooth but uniquely, after cavity preparation the guard is detached while the wedge stays between the teeth, ready for the insertion of a V3 Tab-Matrix beside it. With the wedge staying in place, gingival bleeding is significantly reduced – and you don't have the added cost of a second wedge.

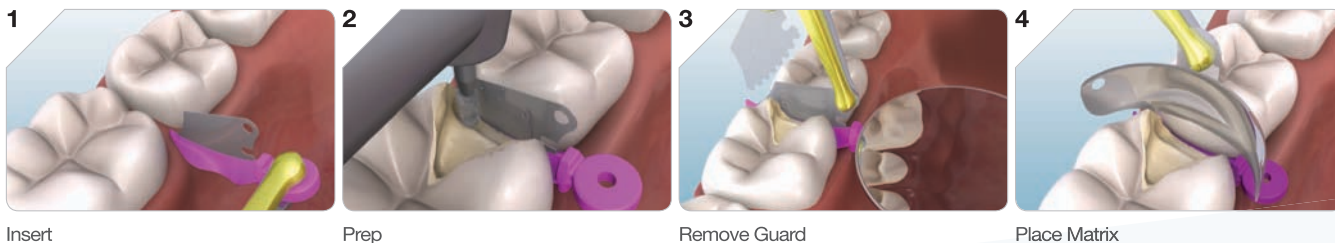
Because WedgeGuard does such a great job of eliminating the risk of hitting the adjacent tooth, not to mention the papilla, you are able to concentrate 100% on the cavity prep in hand, doing a better job in less time.

WedgeGuard is ideal for use on Class II and Class III cavities or with veneers and crowns.

Why use WedgeGuard?

- Prevents bur damage to adjacent tooth
- Saves time, cuts stress
- Retains all the qualities of Wave-Wedge
- Protects gingival papillae, so less bleeding
- Prevents trauma as wedge stays behind when guard is removed


How does it work?



Buy WedgeGuard now and save!

The WedgeGuard Intro Pack contains 25 of each WedgeGuard size (small, medium & large) for only \$89.00. Order now and you can also get 25% off a pair of Triodent Pin-Tweezers.

To order call our friendly customer services team now on: **1-800-811-3949**. Please quote the code: **AA19JA** when you call.



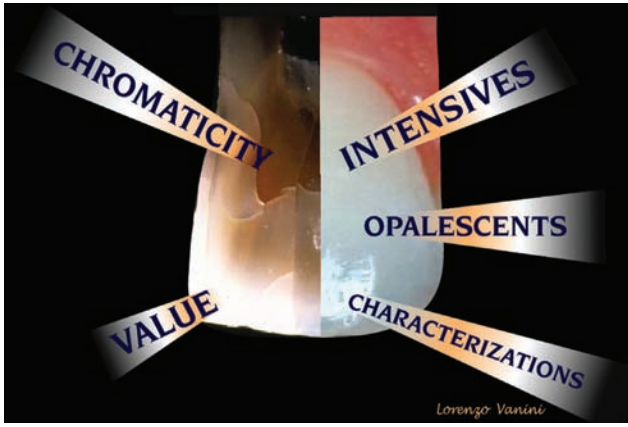


Figure 5: The five color dimensions in dentistry according to the author's technique.

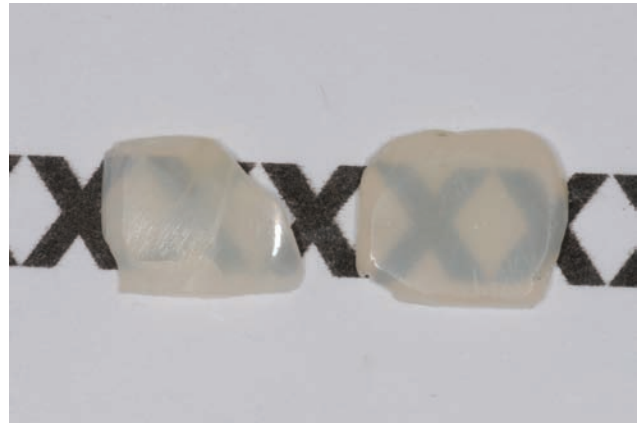

Figure 6: Sample of natural tooth enamel (left) and ENA HRi UE2 composite enamel (right). Each sample is 1 mm thick, showing very similar hue and translucency.

posed of five dimensions. These dimensions are based on the four main hues that present with different tooth shapes and intensities, depending on age: yellow-orange, white, blue, and amber. These four hues, also called “chromatic chords,” are responsible for the five color dimensions, outlined as follows (Fig 5).¹

1. Chromaticity

Chromaticity is the hue and chroma of the dentin body. The composite used in the author's stratification technique requires only one hue, called UD (Universal Dentine), and different chromas (0, 0.5, 1, 2, 3, 4, 5, and 6). In anterior teeth, the chromaticity desaturates from the cervical to the incisal and from the palatal to buccal, and usually is lower in young teeth and higher in old teeth.^{1,3}

2. Value or Luminosity

Value or luminosity is strictly related to enamel. The more mineralized and thin the enamel is, the shinier and lower in value it appears, such as in the old tooth biotype. The thicker, more porous, and more poorly demineralized the enamel is, the less translucent and higher in value it appears, such as in the young tooth biotype.¹

3. Intensives

Intensives occur more frequently in young tooth biotypes and represent hypo-mineralized areas of enamel that

appear white. They are classified by four shape types: spot, small clouds, snowflakes, and horizontal bands.¹

The speed of light through a material depends on the material's density. It is faster through air than water.

4. Opalescents

Opalescents are confined to the incisal third, the interproximal level, and the margin where free enamel is located. These produce the blue and amber hues that create the incisal halo and can exhibit different shapes: mammelon, split mammelon, comb-like, window-like, and stain-like.¹

5. Characterizations

Characterizations affect both dentin and enamel. There are five characterizations: two in the dentin (mammelon and band) and three in the enamel (e.g., margin for young teeth, stain, and cracks for adult and old teeth).¹

Significance of Refractive Index

Color results from the relationship between light and an object (i.e., body/

substance) and, therefore, restorative composite materials should demonstrate optical properties similar to those of dentin and enamel.^{1,4-6} Enamel is the most important structure for this relationship with light, since it covers the dentin structure similar to a fiber-optic system. The translucency and refractive index of composites are very important and also should closely approximate those of the natural enamel.

The speed of light through a material depends on the material's density. It is faster through air than water. The refractive index is the ratio of the speed of light in vacuum compared to a specific medium; the wavelength of light also affects the refractive index. The more optically compact a medium is, the slower the speed of light.

Considerations For Composite Materials

The refractive index (n) of natural enamel is 1.62, while the average refractive index of composite and ceramic restorative materials is 1.50. The refractive index of glass is 1.52, which means that composite and ceramic restorative materials have optical properties that are more similar to glass than to enamel. This presents problems when managing the relationship between translucency and value, because increasing material thickness lowers value (i.e., glass effect), while the behavior of natural enamel is exactly the opposite.⁴



Figure 7: ENA HRi UE2 enamel samples with increasing thickness over a sample of UD₃ dentin. The ENA HRi enamel, with a refractive index of 1.62, demonstrates optical behavior similar to natural enamel. Increasing the thickness also increases the value.

When choosing an enamel composite material, the material should function like natural enamel, presenting a high translucency and demonstrating the same refractive index.⁴ When the proper index is matched, thicker layers of the enamel composite will appear whiter, with high value, high luminosity, and low translucency.⁴ When applied more thinly, the enamel composite should appear more translucent, with a low value, low luminosity, and high translucency.⁴ Unfortunately, as the thickness of standard enamel composite layers increases, the percentage of gray or glass-like effect increases in proportion as well.⁴

Composites With Natural Enamel Properties

However, a composite system developed by the author includes an enamel composite that demonstrates a refractive index of 1.62 and has optical properties very close to those of natural enamel (HRi Universal Enamels, Micerium S.p.A.; Avegno, Italy) (Fig 6). Increasing the material's thickness increases the value (Fig 7). It is possible with this enamel composite to manage the relationship between translucency and value, as well as the esthetic integration of the margin, because light passes through the two structures (i.e., natural

enamel and composite enamel) with the same refractive index. As a result, there is no deviation in optical properties that would otherwise create the

All tooth color information should be recorded in an uncomplicated manner.

clinical challenge of a gray line appearing on the margin.⁴ Furthermore, when placed for incisal edge restorations, the composite is seamlessly integrated, replacing the full enamel thickness, with no need for dentin composites—unlike when using other composite materials (Figs 8a & 8b).⁴

This composite system also includes universal dentin shades (UD) that are available in eight chromatic levels, ranging from Bleach C (UD0) to the darker High C (UD6), many of which correspond with the Vita Shade Guide system.⁶ Although complex restorations may require a basic hue and then the next two darker dentin shades to achieve final shading, most restorations can be completed with only one shade of this dentin composite.⁶

The unique properties of this composite material require placement ac-

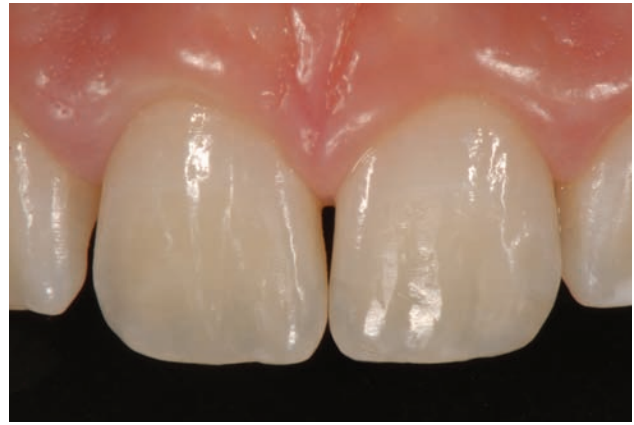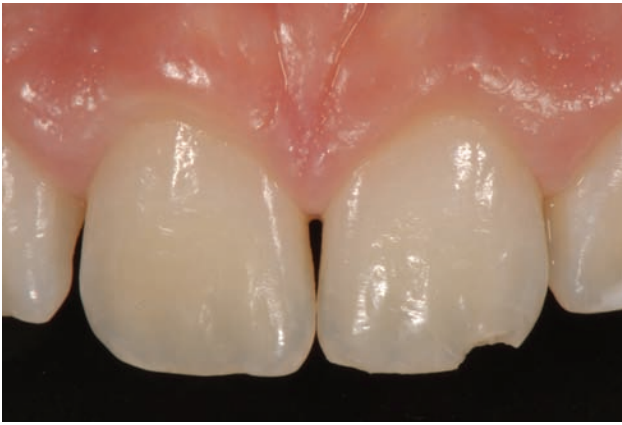ording to a different application protocol than previous composites. A slightly thinner layer of similar thickness as the enamel being replaced on the tooth, with no visible margin, is necessary.⁶

Determining Tooth Color Using the Five Dimensions

To properly determine tooth color, dentists should carefully analyze the tooth structures (e.g., dentin and enamel) and identify the five color dimensions and chromatic chords.^{1,6} To facilitate this process, research has demonstrated that a light with a constant color temperature of 5500K is ideal for shade evaluation (Optilume Trueshade, Optident; Ilkley, UK) (Fig 9).⁸ Additionally, the use of digital photography is fundamental to the analysis of color dimensions because it quickly enables deeper examination of the tooth on a computer. Underexposing the photograph and increasing the contrast allows better visualization of the color dimensions and increases the amber and blue hues of the incisal halo (Figs 10a & 10b).

Recording Tooth Color/Characterization Information

All tooth color information should be recorded in an uncomplicated manner.

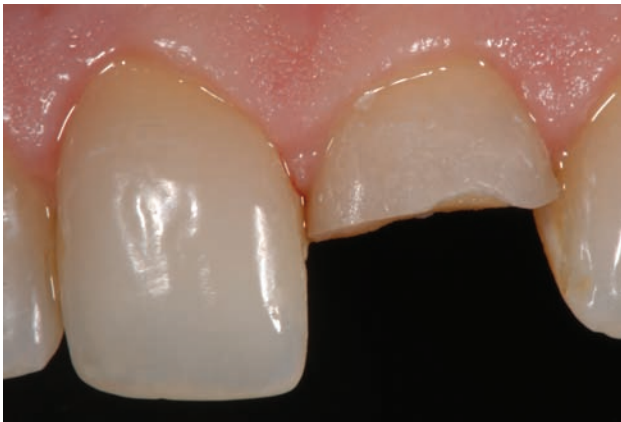


Figures 8a & 8b: Incisal margin fracture. The free enamel is restored using only HRi composite enamel UE2, achieving an excellent esthetic integration.

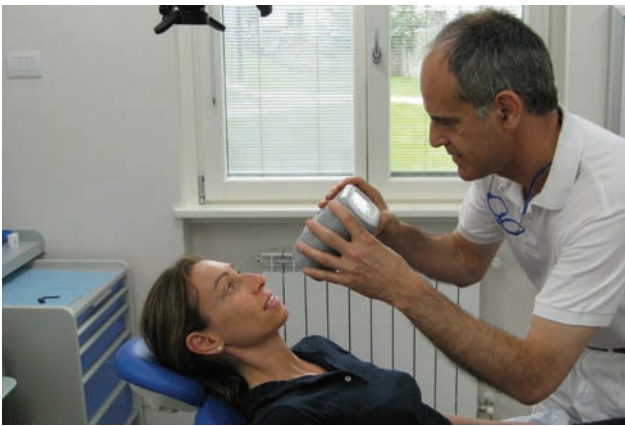
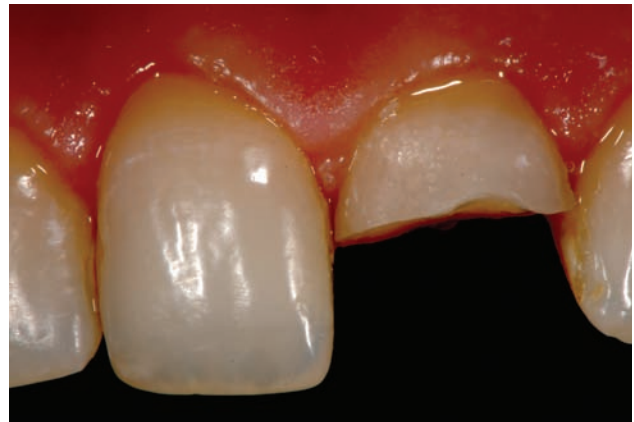
Figure 9: Direct color determination using a special light with a color temperature of 5,500 K.

To properly determine tooth color, dentists should carefully analyze the tooth structures... and identify the five color dimensions and chromatic chords.



Figures 10a & 10b: The color dimension and the amber and blue hues of the incisal halo are better visualized by underexposing the image and increasing the contrast.

GET YOUR INVITATION TO Market Exclusivity

AT ROSEMONT MEDIA,
WE PARTNER WITH LESS
So You Get More

As a boutique firm, we are uniquely positioned to provide market exclusivity and customized internet marketing solutions. How exclusive is your search engine marketing campaign?

Call today (800) 491-8623

The Rosemont Review SEARCH ENGINE MARKETING NEWS FOR THE AESTHETIC PRACTICE **That You Can Trust**

Can your cosmetic dentistry practice afford to wander aimlessly through cyberspace any longer? With countless internet marketing companies, specialists, blogs, and newsletters filled with conflicting advice, how do you know who to trust? The Rosemont Review is a search engine marketing newsletter written by the website designers and proven SEO veterans at Rosemont Media. As a trusted source among many dental professionals, the Rosemont Review features website design tips, social media marketing trends, case studies, and more. Sign up for free today at www.rosemontmedia.com



AACD American Academy
of Cosmetic Dentistry
CORPORATE GOLD MEMBER

AACD | Boston, Mass
May 18-21, 2011
Booths #2230,2228

1010 Turquoise Street, Suite 201, San Diego, CA 92109
Ph. 800.491.8623

www.rosemontmedia.com
info@rosemontmedia.com

 Interact With Us on the Web - www.facebook.com/rosemontmedia

rm
ROSEMONT MEDIA
A MODERN AD AGENCY

Website Design • Search Engine Optimization • Social Media • Internet Video • Consulting

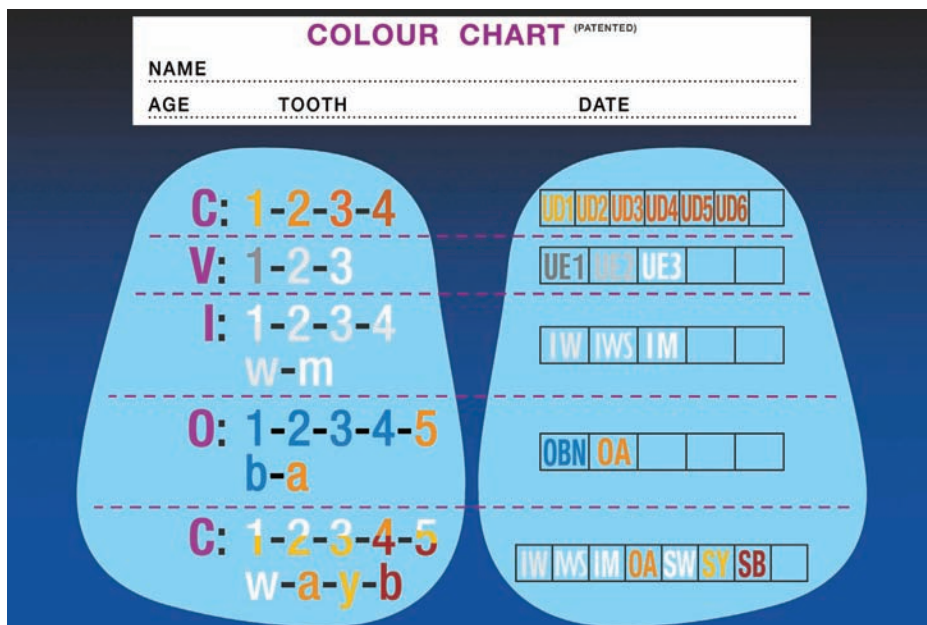


Figure 11: Front of the author's color chart.

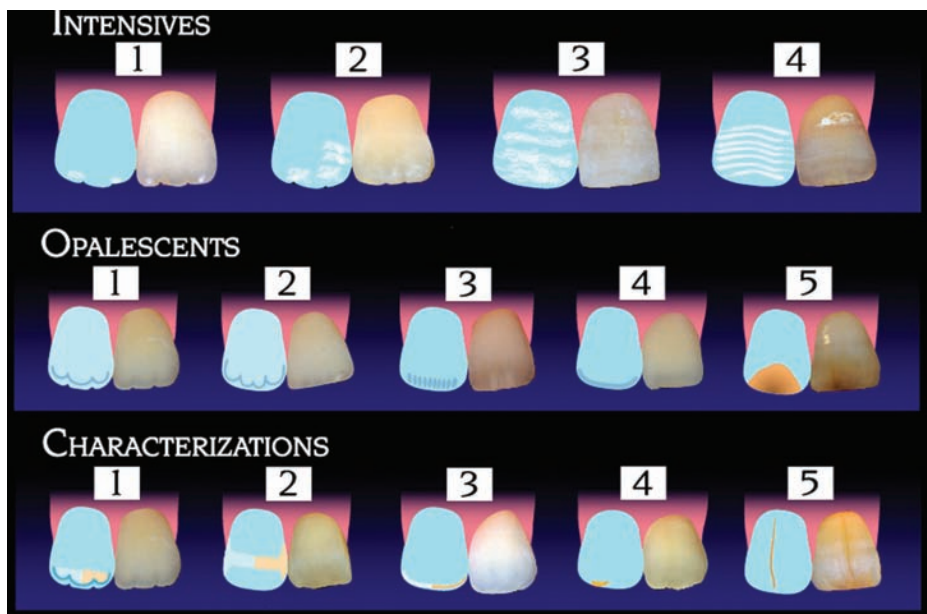


Figure 12: Back of the author's color chart.

For this purpose, the author developed a specific color-mapping chart for researching and identifying the five color dimensions and specific materials to be used to achieve the required effects.¹ The color chart represents the scheme for the restoration, and its proper completion is fundamental for correct restorative results.

The front of the chart (Fig 11) outlines patient details and also includes

two blue tooth-shaped spaces. The five color dimensions are indicated on the left, while the identification initials of the composite system materials (i.e., enamel, dentin) to be used to reproduce the chromatic chords of the color dimensions are indicated on the right.

The back of the chart (Fig 12) lists the classification of intensives, opalescents, and characterizations. Each dimension refers to age biotypes, and each biotype

predicts recurring dimensions for shape and chromatic saturation.

It is important to note that color chart completion should be undertaken prior to restorative procedures and consulted throughout the stratification process.¹ Once a tooth is dehydrated, this natural tooth color information is lost.^{1,9}

Documenting Dimensions of Tooth Color

The first tooth color dimension to be determined is the basic chromaticity (BC) (Fig 13), which is derived from the mean value of the dentin body chromaticities and should be identified on the middle third of the tooth using a shade guide made from the same composite material to be used for the stratification. The basic chromaticity should be recorded on the left side of the chart, while the dentin composites needed should be indicated on the right.

Each biotype predicts three basic chromaticities: two pure and one hybrid. The young biotype displays chromaticity from one to two (1-1,5-2); the adult from two to three (2-2,5-3); and the elderly from three to four (3-3,5-4). The shape of the dentin body and the mammelon contour to be reproduced also must be defined.

The second dimension to be determined is the value or luminosity of the enamel (Fig 14), which will be high in the young biotype (3), medium in the adult (2), and low in the elderly (1). Each of these groups expresses diverse density, translucency, and reflectivity.¹ This evaluation can be performed by taking a black-and-white photograph.

To determine intensives, opalescents, and characterizations, the photograph is compared to the back of the color chart, and it is helpful to analyze the image underexposed with high contrast.

Intensives (Fig 15) are present primarily in the young biotype, where types 1 (spot) and 3 (snowflakes) are usually seen. Adult and elderly biotypes more commonly exhibit intensive types 2 (small clouds) and 4 (horizontal bands).

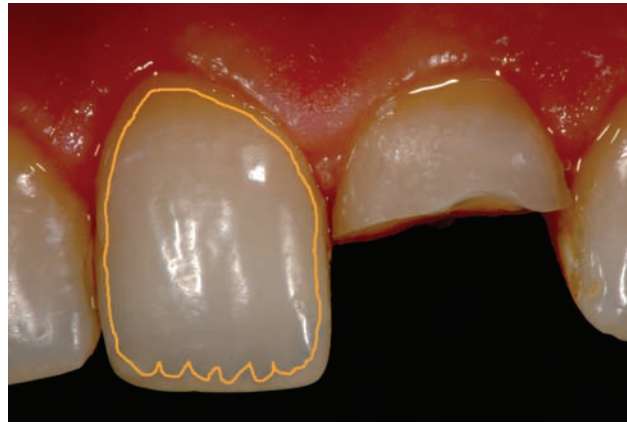


Figure 13: When studying tooth chromaticity, it is important to evaluate the dentin body shape and mamelon contours in order to reproduce them during stratification.

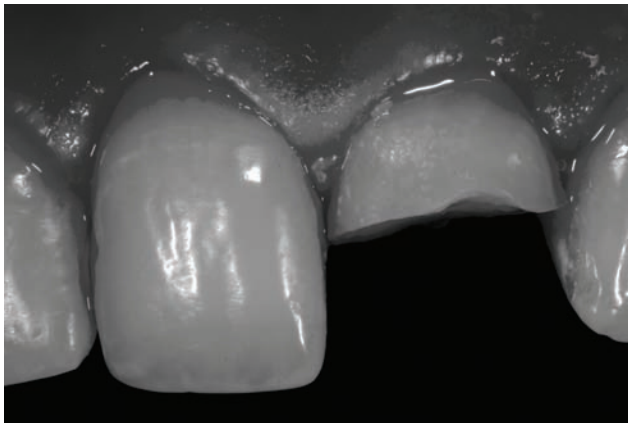


Figure 14: Taking a black-and-white photograph can be helpful when studying the value.

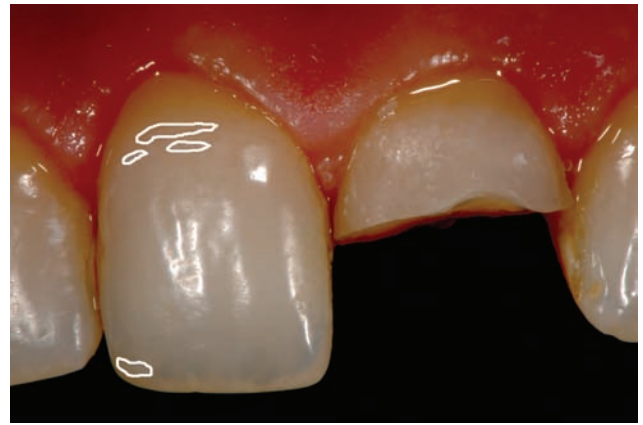


Figure 15: Intensives are represented by opaque white spots, stains, or bands.

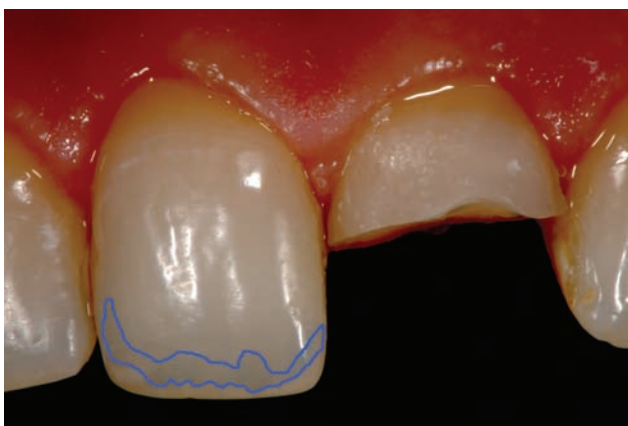

Figure 16: It is very important to evaluate the shape and size of the incisal in order to reproduce the incisal third in a natural way.

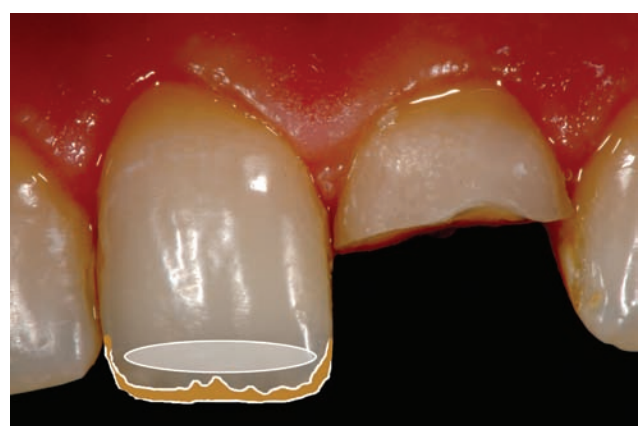


Figure 17: The mamelon and incisal margin characterizations represent the natural frame of the incisal halo.

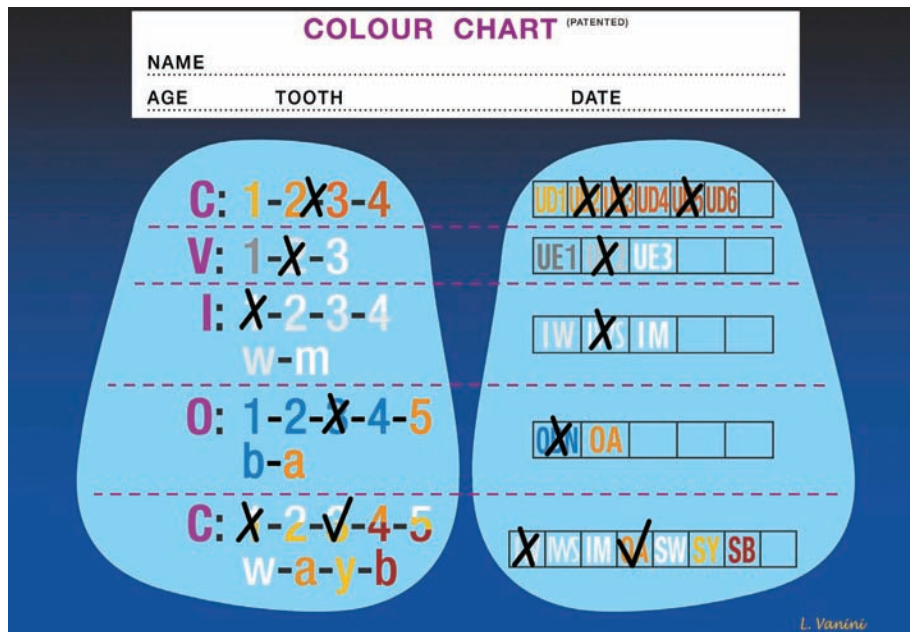


Figure 18: The filled-in color chart guides the project to build up a correct stratification.

Opalescents (Fig 16) in the young biotype appear as gray-blue hues of Types 1 (mammelon) and 2 (split mammelon); in the adult as gray-blue hues of Types 3 (comb-like) and 4 (window-like); and in the elderly as amber hues of Type 5 (stain-like).

The characterizations mostly present (Fig 17) in the young biotype are the mammelons (Type 1), which can appear white or amber, thus creating a clear-cut boundary with the opalescents; and the incisal margin (Type 3), which is emphasized by a white or amber line. In the elderly biotype, the characterizations seen are one or more horizontal bands with a whitish or amber tonality that extend into the interproximal areas (Type 2); amber or brown stain-like characterization (Type 4) at the incisal third; and crack of the enamel (Type 5) produced by brown pigmented fissures or white opaque cracks.

Anatomic Stratification and Composites

Anatomic stratification involves the reproduction of dentin and enamel tissues to the proper thickness and position.^{1,5,6} During this process, it also is necessary to consider the proteinaceous layer between dentin and enamel that is responsible for the internal diffusion of light and luminosity of the restora-

tion.¹ Stratification, or incremental layering, requires a complex understanding of the internal structures of the teeth (i.e., enamel, dentin) and their morphology.^{5,6}

The author's anatomic stratification technique imitates the tooth anatomy, restoring enamel and dentin in their respective locations and thicknesses

Anatomic stratification involves the reproduction of dentin and enamel tissues to the proper thickness and position.

to achieve a light-composite-color relationship similar to natural tooth structure. This is accomplished by precisely planning the documented restoration of the palatal and interproximal enamel, the dentin body, and the buccal enamel.

The composite stratification is guided by the color chart, which must be completed with the characteristics of tooth color dimension prior to initiating restorative procedures (Fig 18). This will ensure that the anatomic stratification demonstrates desaturation of the hue from cervical to incisal, and from

palatal to buccal, in a harmonious and modulated way; exhibits contrast in the incisal area between the dentin body, free enamel, and darkness of the mouth; and diffuses light inside the tooth, imparting a three-dimensional effect to the restoration.

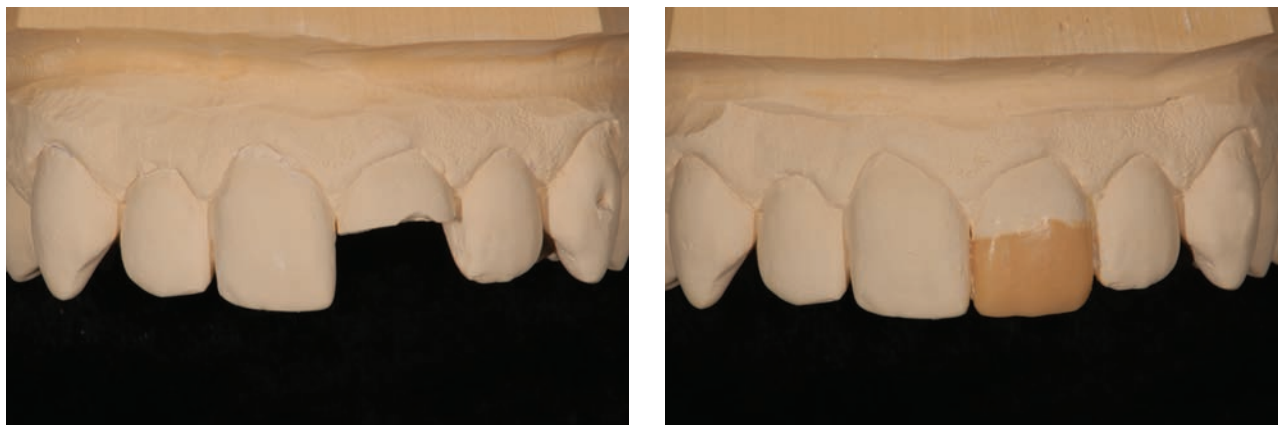
Wax-Up and Matrix Guide

For Class IV restorations, the use of a silicone matrix/stent is advised to ensure the correct anatomic position of the palatal/lingual enamel wall, and to support the enamel body application.¹⁰ The silicone matrix can be provided by a laboratory from the wax-up or created directly in the mouth using a medium-viscosity silicone and temporary restorative, then shaped and adjusted with burs (Figs 19a-20b). Once the silicone has hardened, the stent is removed and adjusted to fit perfectly to the teeth and buccal wall corresponding to the affected tooth, then removed.

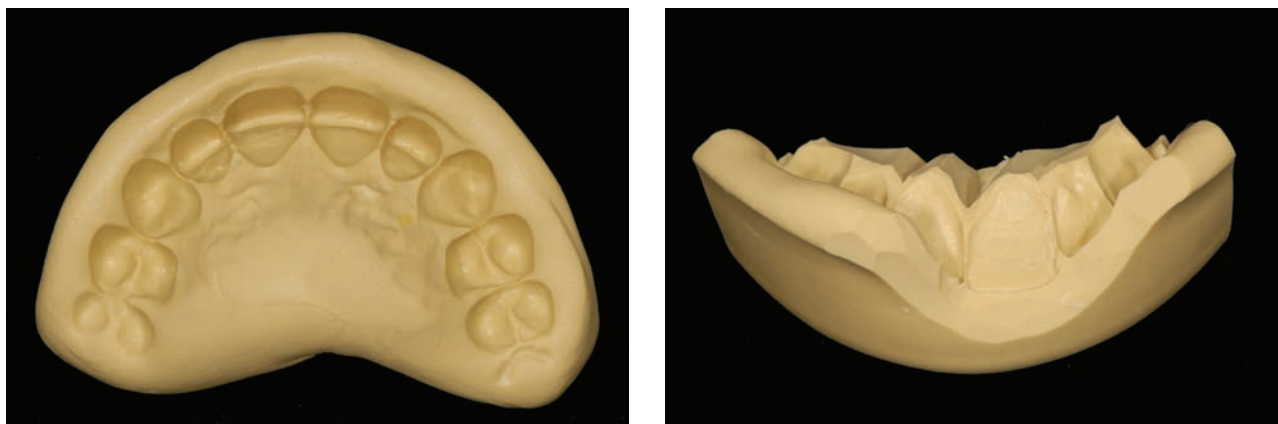
Isolation, Preparation, and Adhesive Protocol

Prior to initiating the stratification technique, the area should be cleaned with a fluoride-free prophylaxis paste and isolation achieved with a rubber dam. For interproximal restorations, a transparent matrix is required.

For Class IV restorations, the ideal margin preparation includes a 90° butt



Figures 19a & 19b: View of the model and wax-up.



Figures 20a & 20b: Impression and silicone stents will be used to build up the palatal wall. The buccal part of the stent is removed to access the cavity and stratify the enamel.

margin on the palatal and interproximal margins, and a short chamfer in the buccal margin. The margin is first prepared using a coarse-grain diamond bur, ball-shaped for the chamfer, and cylindrical for the butt margin. The margin is finished using the same burs with fine grain and, afterwards, polished using a silicone point, since the smooth surface facilitates flow of the adhesive, as well as composite adaptation on the margin (Figs 21a & 21b).

The preparations are etched using a 35% to 38% phosphoric acid (ENA Etch, Micrium S.p.A.) for 15 to 30 seconds for enamel and vital dentin. For sclerotic dentin, 1 minute is necessary, and root non-vital dentin (for post-adhesive cementation) requires 1.5 minutes. The etched surface should be cleaned and dried with oil-free air, leaving a white appearance on the enamel.

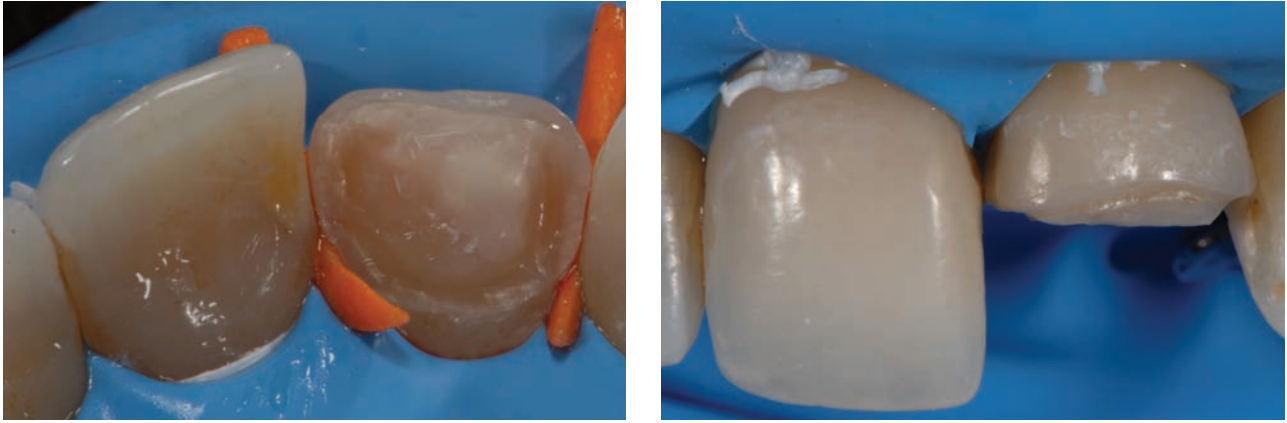
A thin coat of adhesive bonding agent (ENA Bond) is applied to the preparations, down to the margins, and then light-cured for 40 seconds. If using ENA Bond, a second coat of material should be applied and cured.¹¹ Care should be taken to not contaminate the oxygen-inhibiting layer to ensure a strong bond to the composite.¹²

Composite Application

Remove the selected composite from the syringe and warm to 39°C with a heating container.⁵ Place the stent in the mouth, and begin the Class IV stratification by applying the palatal/lingual enamel layer. It should be applied in a thickness that approximates that of the natural enamel being replaced, avoiding the interproximal areas. The stent is used to verify adaptation, then removed for light curing.

Curing should be completed on all sides of the stratification for 40 seconds for each 1 mm to 1.5 mm layer. The light-curing tip should be kept as close to the restoration as possible to ensure a thorough cure. It also is advisable to turn off the overhead light or not have it placed directly overhead to prevent uncontrolled curing.

Using an acetate matrix and a wedge, restore the interproximal walls using the same enamel body composite that was placed for the palatal wall (Fig 22). Once these two steps have been completed, the complex cavity is transformed into a simple shell, the shape and thickness of which should be verified and eventually corrected prior to continuing with the restoration. The volumes to be filled are now evident, making it easier to check the areas that need to be restored.



Figures 21a & 21b: View of the cavity preparation consisting of a buccal mini-chamfer and interproximal and palatal butt margins.

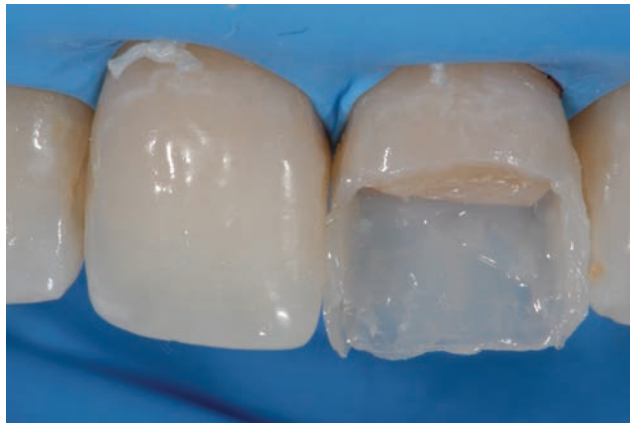


Figure 22: Palatal and interproximal walls create an enamel frame on which the dentin body will be placed.

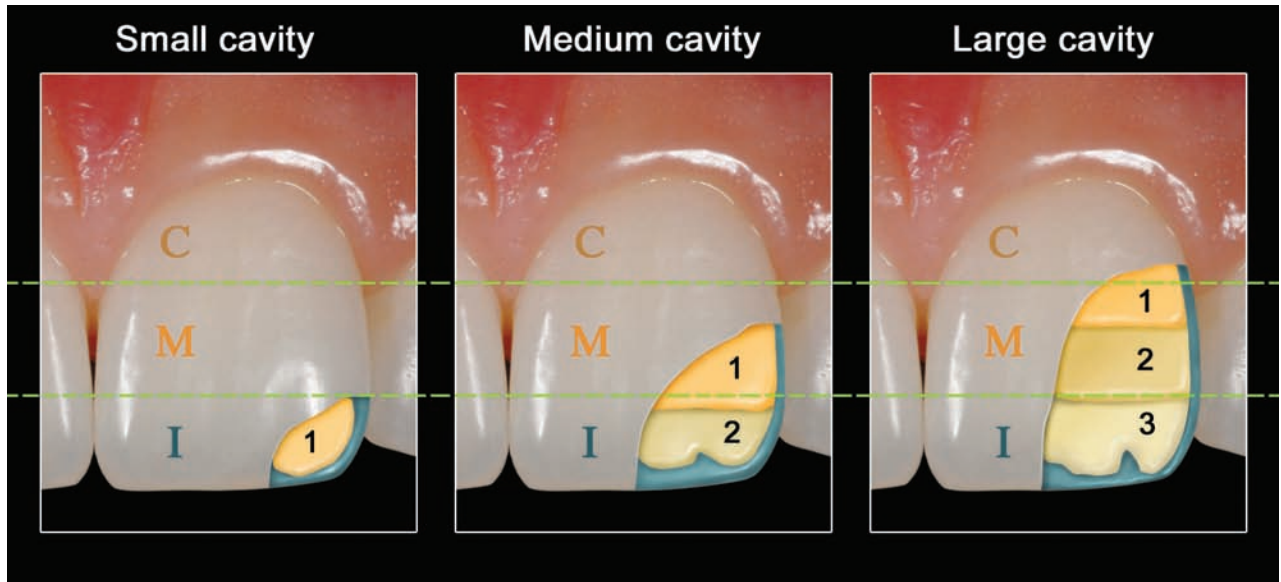


Figure 23: Dentin body and number of composite dentin masses used according to the cavity size.

Helping You Keep Your Promise

You're an AACD dentist.

You're committed to the practice of responsible aesthetics.

*You've been highly educated and trained,
and strive to reach the ultimate Accreditation.*

What are you going to pursue next?

Removable prosthetics is currently the fastest growing segment in dentistry, and every day, more doctors are venturing into aesthetic removables.

Are you ready to take the leap?

Join us in beautiful Sarasota, Florida on December 10, 2010 for a full-day seminar on expanding the aesthetic removable portion of your practice with Dr. Frank Lauciello. Be one of the first 20 to sign up, and we'll help cover your travel costs.

Collaborating with Knight Dental Group and Ivoclar Vivadent can help you reach your next ultimate goal.

Call (800) 359-2043 for course information and to start the next pursuit.



Knight Dental Group
3659 Tampa Road • Oldsmar, FL 34677
800-359-2043
www.knightdentalgroup.com

ivoclar
vivadent®
passion vision innovation

aes-thet-ics: (ěs-thět'iks)

A branch of philosophy dealing with the nature of art, and with the creation and appreciation of beauty.

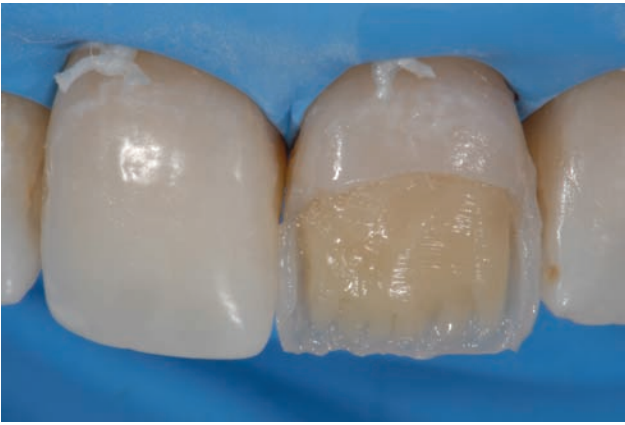


Figure 24: Dentin body stratification is completed with three shades: UD5, UD3, and UD2. Because the basic chromaticity is hybrid (2,5), the first layer used is UD5 instead of UD4 in order to increase the chromaticity a half point.

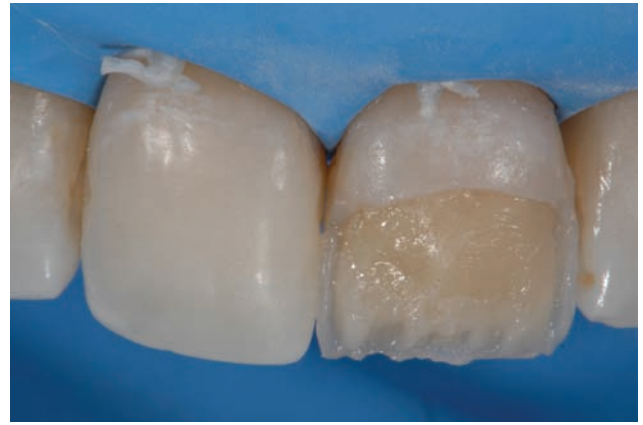


Figure 25: Dentin body mammelons are characterized with a thin layer of IW.

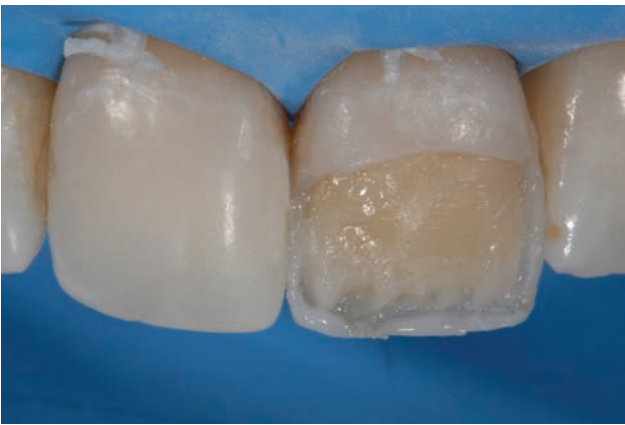


Figure 26: Margin characterization is created with IW and OA.

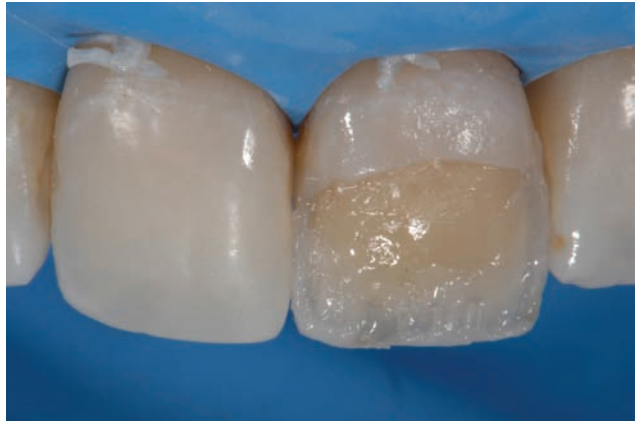


Figure 27: Opalescent natural OBN is placed in the interproximal grooves and between the mammelons.

For the dentin body restoration, the number of dentin shades needed correlates to the size of the preparation: one dentin body for small, two for medium, and three for large (Fig 23). Each tooth exhibits three degrees of chromaticity: high in the cervical third, medium in the middle third, and low at the incisal level.³ Therefore, one or more composites with increasing saturation should be used to reproduce these chromaticities, based on the size of the cavity. For example, if the basic chromaticity is UD2, the required dentin body composite would be UD2 for a small cavity; UD2 and UD3 for a medium cavity; and UD2, UD3, and UD4 for a large cavity.

Such an approach achieves a strong chromatic nucleus that prevents the loss of chromaticity when the buccal enam-

el is applied and creates a desaturation from cervical to incisal, and from palatal to buccal.

Therefore, in a large preparation area, the dentin body stratification begins at the most cervical margin by placing a high saturation dentin composite cervically. Continuing this example, UD4 would be placed and cured, after which UD3 would be applied to completely cover UD4, as well as placed on the buccal chamfer, pushed more incisally, and cured. These two layers then are completely covered with a layer of UD2, which also is placed on the chamfer and extended to the incisal margin, and cured. If mammelons are present, the vertical grooves should be opened first to create the halo shape (Fig 24). This enables creation of a chromatic

composition of the dentin body with different chromas and the balanced desaturation seen in natural teeth.

After building up the dentin body, characterizations, intensives, and opalescents are placed before applying the buccal enamel layer. The most important characterizations are the mammelons and the margin (Figs 25 & 26), which are reproduced using white and amber (IW and OA). Following mammelon and margin characterization, create the opalescents using a specific body composite (OBN) that is placed between the mammelons and the area between the incisal margin and the dentine body (Fig 27) to produce a natural halo. Finally, reproduce the intensives in the shape determined during the col-

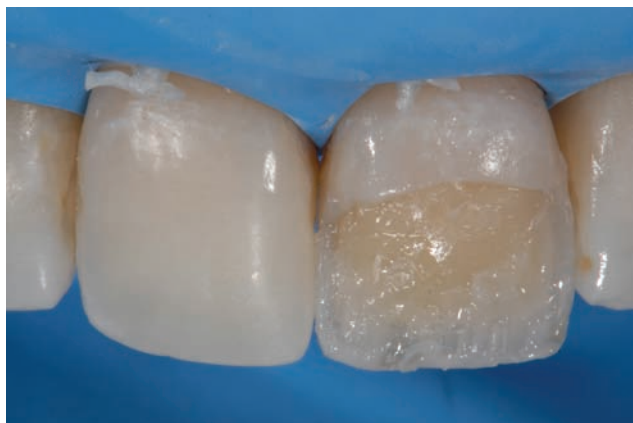

Figure 28: Small increments of IWS, an opaque white body composite, create small intensive spots.

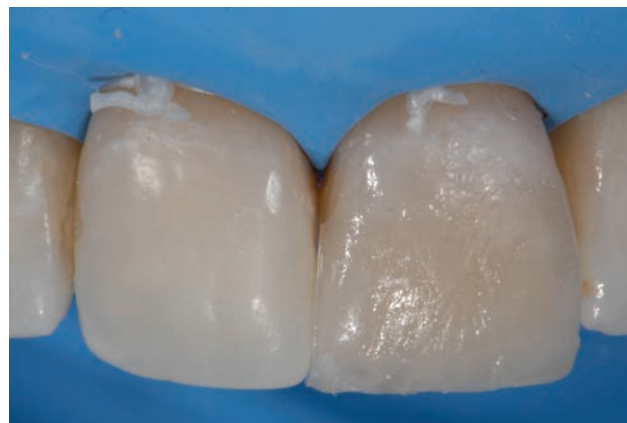


Figure 29: A 0.6-mm increment of UE2 completes the restoration.

or mapping by using the white opaque body composites (IWS, IM) (Fig 28).

It is important to remember that when applying the different composites to build up the dentin body, characterization, opalescents, and intensives, necessary space must be left to apply the buccal enamel layer, which is thinner in the cervical area and thicker at the incisal edge, with a natural vertical contour that creates the natural tooth shape. The stratification technique concludes with the buccal enamel layer, which must be applied to reproduce the transition lines and draft both the macro-texture (i.e., lobes, grooves, and depressions) and micro-texture, using a brush to create the enamel growth lines (Fig 29).

Once the last layer of enamel is cured and prior to initiating finishing and polishing procedures, it is advisable to cover the surface of the restoration with a layer of glycerin gel and perform an additional cycle of light-curing to eliminate the oxygen-inhibited layer and obtain complete composite polymerization.¹¹

Finishing and Polishing

Finishing and polishing complete the restoration and are important steps in the process because they create the ideal relationship between light and the tooth, which is fundamental to achieving the desired esthetic result.¹³ Furthermore, the finished and polished

surface reduces plaque deposits and aging of the restoration. Finishing defines the shape, dimension, and contour of the restoration (Figs 30a & 30b), while polishing shines the surfaces, maintaining the texture details achieved during finishing (Figs 30c-30f).

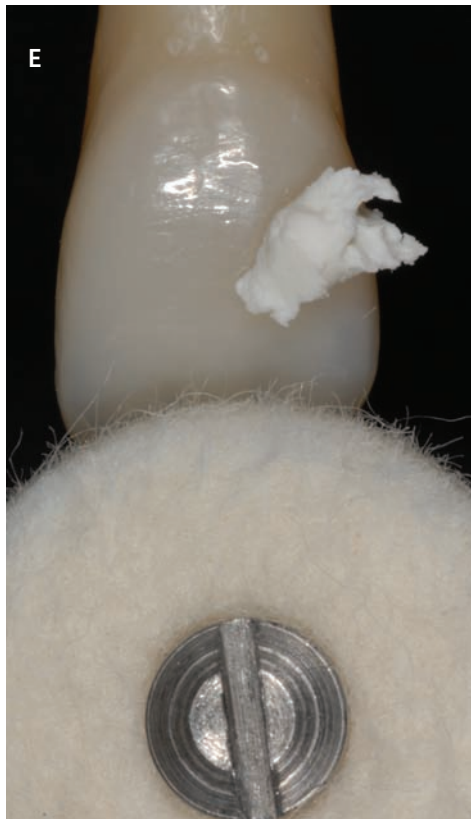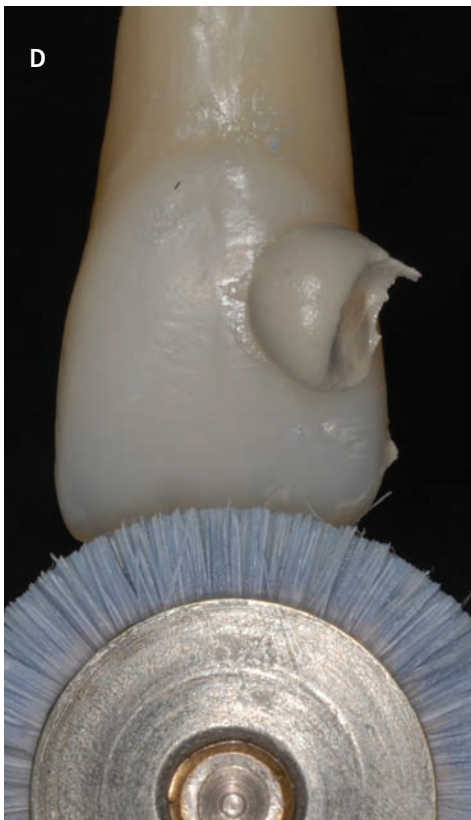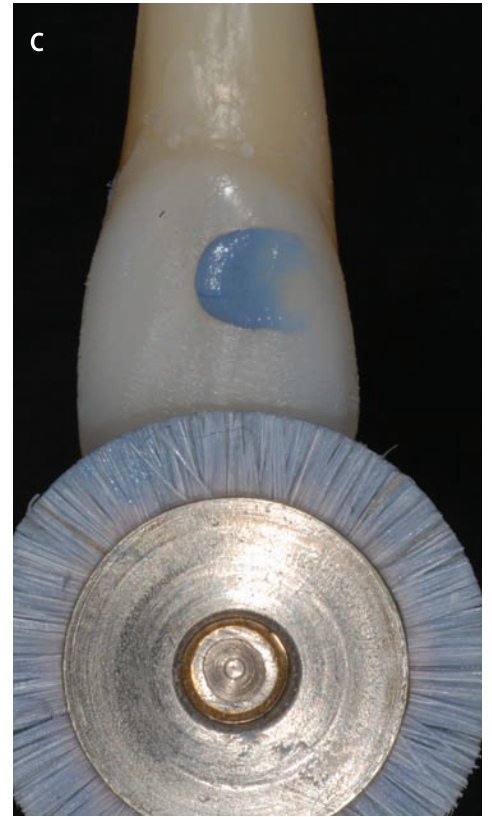Polishing imparts brilliance to the restoration surfaces. The ideal way to polish a restoration is by using diamond pastes and a goat hair brush, which will not destroy the macro- and micro-texture surface details.

Begin finishing by correcting the shape using medium-grain diamond burs (e.g., 30 to 40 μ). Finish the vertical contour by following the tooth anatomy, using the bur along three different inclinations, depending on the area of the tooth (e.g., cervical, incisal, or middle third). Finish the horizontal contour by adjusting the shape and length of the incisal edge and corners; finish the interproximal internal margin using abrasive strips; and finish the interproximal external margin using medium-grain diamond burs. This step is very important because the correct shape

and position of the transition lines (i.e., angles that define the transition from the interproximal margin to the buccal surface) are fundamental to the esthetic integration of the restoration.

After adjusting the shape, finish the surface macro-texture using a medium-grain diamond or multi-bladed bur to create lobes and grooves. The enamel growth lines (micro-texture) are created using the point of a green stone to gently scratch the surface.

Polishing imparts brilliance to the restoration surfaces. The ideal way to polish a restoration is by using diamond pastes and a goat hair brush, which will not destroy the macro- and micro-texture surface details. Begin polishing with a 3- μ diamond paste, then switch to a 1- μ paste with water spray. Polish the interproximal walls using abrasive strips with decreasing grain and diamond pastes. The final glossing can be achieved using an aluminum oxide paste with a felt disc, working at first without water at a very low speed, then increasing the speed but using copious water spray and no pressure on the restoration surface. When the finishing and polishing steps are completed, a conservative composite restoration should be achieved (Fig 31).



Figures 30a-30f: Images demonstrating the main phases of finishing and polishing.

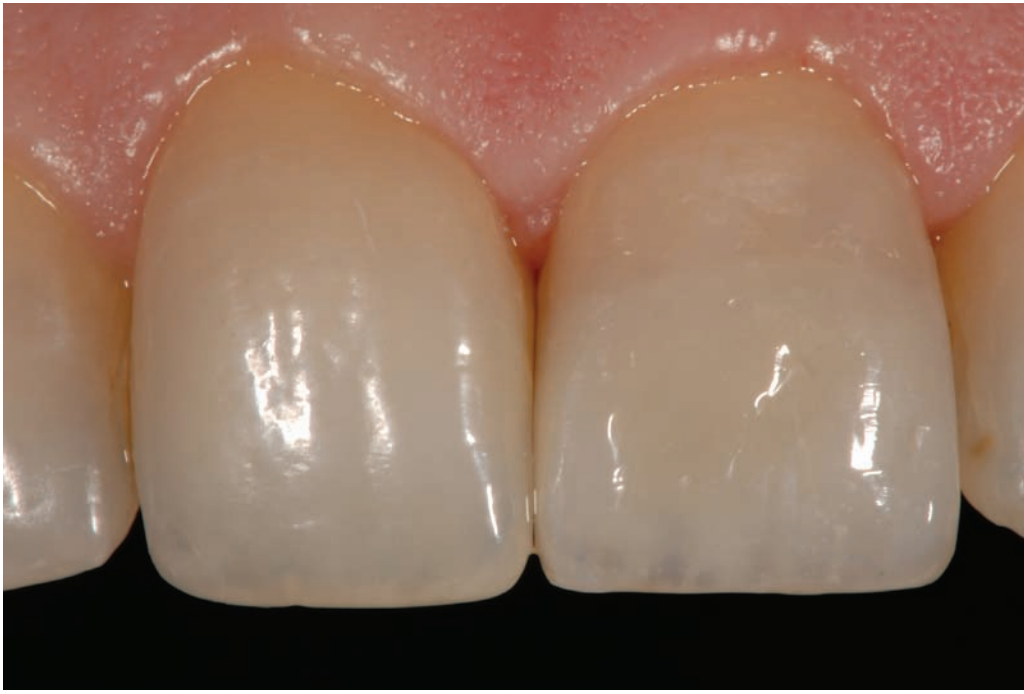
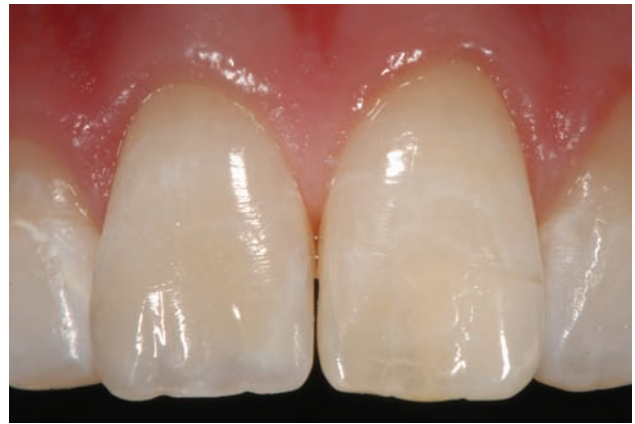
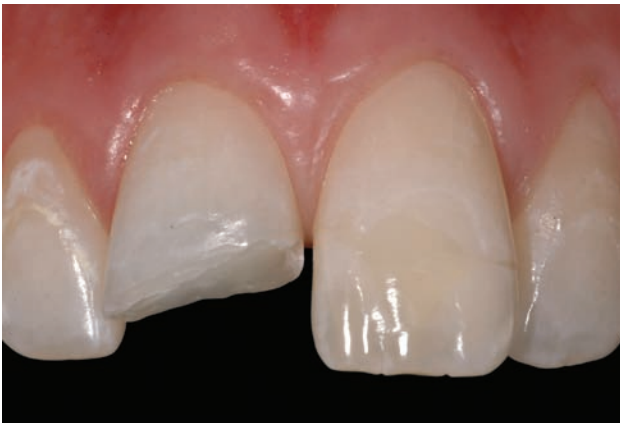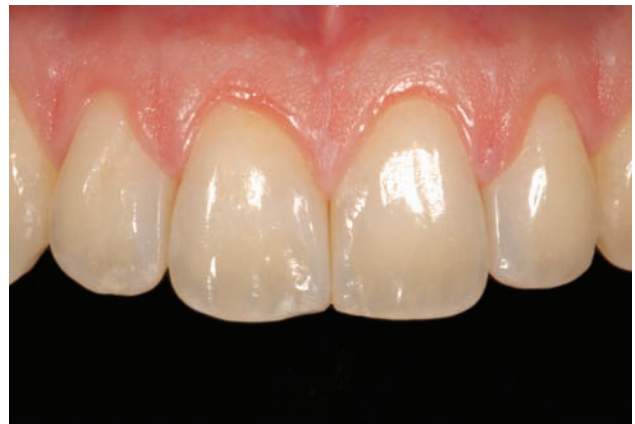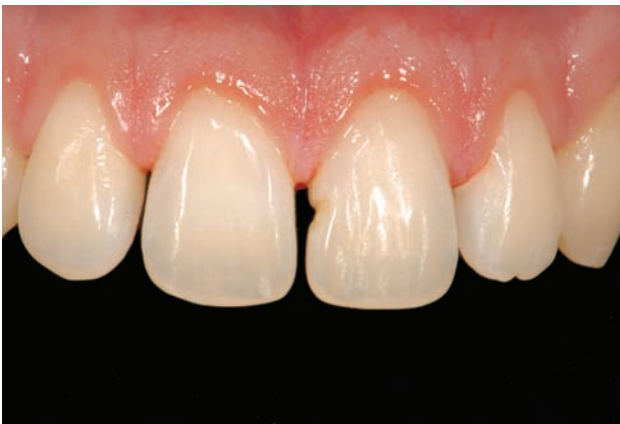Figure 31: View of the restoration after polishing.



Figures 32a & 32b: A well-integrated esthetic restoration should reproduce all five color dimensions in a natural way.



Figures 33a & 33b: Another example of an esthetic restoration using the five dimensions of color.

Examining tooth color beyond the typical three dimensions of color (i.e., hue, chroma, and value) enables dentists to create highly esthetic restorations that are indistinguishable from natural dentition.

Conclusion

Examining tooth color beyond the typical three dimensions of color (i.e., hue, chroma, and value) enables dentists to create highly esthetic restorations that are indistinguishable from natural dentition (Figs 32a & 32b, 33a & 33b).¹ Still one of the most challenging areas in dentistry, color matching direct composite restoratives to natural teeth for the realization of natural-looking treatments can be achieved using new determination techniques and placement protocol. This article has described the theory of the five dimensions of color as a basis for developing esthetic direct composite restorations and presented the details of a predictable direct placement technique.



About the Author: Dr. Vanini is Professor of Restorative Dentistry, University La Sapienza, in Rome, Italy; and Visiting Professor of Restorative Dentistry, University De La Mediterranee, in Marseilles, France. Dr. Vanini can be contacted by e-mail at: dott.vanini@libero.it.
Author Disclosure: Dr. Vanini develops products and lectures for Micerium S.p.A. in Avegno, Italy.

References

1. Vanini L, Mangani FM. Determination and communication of color using the five color dimensions of teeth. *Pract Proced Aesthet Dent.* 2001;13(1):19-26.
2. Ishikawa-Nagai S, Yoshida A, Sakai M, Kristiansen J, Da Silva, JD. Clinical evaluation of perceptibility of color differences between natural teeth and all-ceramic crowns. *J Dent.* 2009;37(Suppl 1):e57-63. Epub 2009 Apr 18.
3. O'Brien WJ, Hemmendinger H, Boenke KM, Linger JB, Groh CL. Color distribution of three regions of extracted human teeth. *Dent Mater.* 1997 May;13(3):179-85.
4. Vanini L. Light and color in anterior composite restorations. *Pract Periodontics Aesthet Dent.* 1996 Sep;8(7):673-82.
5. Vanini L, Mangani F, Klimovskaia O. Conservative restoration of anterior teeth. Viterbo (Italy): Editing ACME; 2005.
6. Vanini L. Anatomic stratification technique. Presented at the 26th Annual AACD Scientific Session; Grapevine, TX, April 27, 2010.
7. Clarke EB. Selection of tooth color for the edentulous patient. *J Am Dent Assoc.* 1947 Dec 1;35(11):787-93.
8. Gokce HS, Piskin B, Ceyhan D, Gokce SM, Arisan V. Shade matching performance of normal and color vision-deficient dental professionals with standard daylight and tungsten illuminants. *J Prosthet Dent.* 2010 Mar;103(3):139-47.
9. Sneed WD, Nuckles DB. Shade determination prior to field isolation. *Dent Surv.* 1978 Apr;54(3):32.
10. Vanini L, Toffenetti F. Nuovi concetti estetici nell'uso dei materiali compositi. *Quaderni di progresso stomatologico a cura degli Amici di Brugg.* Rimini (Italy); 1995.
11. D'Arcangelo C, Vanini L, Prosperi GD, Di Bussolo G, De Angelis F, D'Amario M, Caputi S. The clinical influence of adhesive thickness on the microtensile bond strength of three adhesive systems. *J Adhes Dent.* 2009;10(4):1-7.
12. Ghivari S, Chandak M, Manvar N. Role of oxygen inhibited layer on shear bond strength of composites. *J Conserv Dent.* 2010 Jan;13(1):39-41.
13. Peyton JH. Finishing and polishing techniques: direct composite resin restorations. *Pract Proced Aesthet Dent.* 2004 May;16(4):293-8. **jCD**

Excellence is Never an Accident



Experience Our Signature of Excellence

WESTLUND DENTAL STUDIO

www.westlunddental.com | 800.728.9641

New AACD Member Benefit:
CE, 3 Hours Credit

AACD Self-Instruction Continuing Education Information

General Information

This continuing education (CE) self-instruction program has been developed by the American Academy of Cosmetic Dentistry (AACD) and an advisory committee of the *Journal of Cosmetic Dentistry*.

Eligibility and Cost

The exam is free of charge and is intended for and available to AACD members only. It is the responsibility of each participant to contact his or her state board for its requirements regarding acceptance of CE credits. The AACD designates this activity for 3 continuing education credits.

Testing and CE

The self-instruction exam comprises 10 multiple-choice questions. To receive course credit, AACD members must complete and submit the exam and answer at least 70% of the questions correctly. Participants will receive tests results immediately after taking the examination online and can only take each exam once. The exam is scored automatically by the AACD's online testing component. The deadline for completed exams is one calendar year from the publication date of the issue in which the exam appeared. The exam is available online at www.aacd.com. A current web browser is necessary to complete the exam; no special software is needed.

Note: Although the AACD grants these CE credits, it is up to the receiving governing body to determine the amount of CE credits they will accept and grant to participants.

Verification of Participation (VOP)

VOP will be sent to AACD members via their MyAACD account upon pass completion. Log onto www.aacd.com to sign into your MyAACD account.

For members of the Academy of General Dentistry (AGD): The AACD will send the AGD proof of your credits earned on a monthly basis. To do this, AACD must have your AGD member number on file. Be sure to update your AGD member number in your AACD member profile on MyAACD.com.

All participants are responsible for sending proof of earned CE credits to their state dental board or agency for licensure purposes.

Disclaimer

AACD's self-instruction exams may not provide enough comprehensive information for participants to implement into practice. It is recommended that participants seek additional information as required. The AACD Self-Instruction Program adheres to the guidelines set forth by the American Dental Association Continuing Education Recognition Program (CERP), and the AGD Program Approval for Continuing Education (PACE).

Questions and Feedback

For questions regarding a specific course, information regarding your CE credits, or to give feedback on a CE self-instruction exam, please contact the AACD Executive Office by e-mailing meetings@aacd.com or by calling 800.543.9220 or 608.222.8583.



ADACERP
Continuing Education Recognition Program
American Academy of Cosmetic Dentistry[®]
is an ADA CERP Recognized Provider



ADA CERP is a service of the American Dental Association to assist dental professionals in identifying quality providers of continuing dental education. ADA CERP does not approve or endorse individual courses or instructors, nor does it imply acceptance of credit hours by boards of dentistry. Concerns or complaints about a CE provider may be directed to the provider or to ADA CERP at www.ada.org/goto/cerp.

(CE) Exercise No. JCD01

Anterior Composite Restorations (Operative Dentistry) AGD Subject Code: 254

The 10 multiple-choice questions for this Continuing Education (CE) self-instruction exam are based on the article, "Conservative Composite Restorations that Mimic Nature: A Step-by-Step Anatomical Stratification Technique" by Lorenzo Vanini, DDS, MD. This article appears on pages 80-98.

The examination is free of charge and available to AACD members only. AACD members must log onto www.aacd.com to take the exam. **Note that only Questions 1 through 5 appear here in the printed version of the Journal; they are for readers' information only.** The complete, official self-instruction exam is available online only—completed exams submitted any other way will not be accepted or processed. A current web browser is necessary to complete the exam; no special software is needed. The AACD is a recognized credit provider for the Academy of General Dentistry, American Dental Association, and National Association of Dental Laboratories. For any questions regarding this self-instruction exam, call the AACD at 800.543.9220 or 608.222.9540.

1. Color matching is considered a challenging task in esthetic dentistry due to which of the following?

- a. Typical shade guides represent the body and thickness of natural tooth structures.
- b. Dentists have used stratification techniques that are directly related to the optical properties of the restorative materials.
- c. No single explanation for determining tooth color has provided an exact solution.
- d. The lack of uniformity of the shade guides available with the restorative materials.

2. Value

- a. is strictly related to enamel.
- b. is lower in the younger biotype.
- c. relates to the color intensity of a tooth.
- d. is best evaluated using digital color photography.

3. Which of the following is true?

- a. Tooth color results from the interaction of dentin and light.
- b. Enamel is responsible for the hue and chroma of a tooth.
- c. Fluorescence is created by the tooth's enamel.
- d. Enamel is thicker in mature teeth.

4. Which of the following best describes the esthetic problem that occurs when using standard enamel composite layers?

- a. When the material is applied thinly, the value is lowered and translucency is increased.
- b. Thicker layers of material appear whiter, higher in value, and lower in translucency.
- c. As the thickness of the material increases, the value of the restoration is lowered.
- d. When thicker layers are applied evenly, the value is raised and the translucency decreases.

5. Which of the following is useful when determining tooth color?

- a. A light source color corrected to 4000K.
- b. Digital photography.
- c. Standardized shade guides.
- d. Drying the tooth to show a matte finish.

To see and take the complete exam, log onto www.aacd.com.

Advertiser Index

AACD New Member Benefit (Supplement)	www.aacd.com/learn	outside
AACD Accreditation	www.aacd.com	37
AACD Boston 2011	www.aacd.com	21
3M ESPE	www.3MESPE.com	41
Aurum Ceramic Dental Laboratories	www.aurumgroup.com	46
Cosmedent	www.cosmedent.com	25
daVinci Dental Studios	www.daVincismile.com	13
Discus Dental	www.discusdental.com	IFC
Envision A Smile	www.EnvisionASmile.com	49
Give Back a Smile	www.aacd.com	19
Gold Dust Dental	www.golddustdental.com	55
Heraeus Kulzer	www.heraeusdentalusa.com	75
Ivoclar Vivadent	www.ivoclarvivadent.com	71, IBC
Knight Dental Group	www.knightdentalgroup.com	93
LK Dental Studios	www.lkdentalstudio.com	9
MAC, by Dental Technologies Inc.	www.macveneers.com	BC
Micerium S.p.A.	www.micerium.it	79
New Beauty	www.newbeauty.com	69
Oral Aesthetic Advocacy Group	www.CDGO.org	31
Patient News Publishing	www.patientnews.com	7
Quintessence Publishing Co., Inc.	www.quintbook.com	60
Rhonda Mullins Consulting Inc.	www.rhondamullins.com	68
Rosemont Media	www.rosemontmedia.com	87
Six Month Smiles	www.6monthsmiles.com	24
Springstone Patient Financing	www.springstoneplan.com	65
Triodent	www.triodent.com	83
Ultradent	www.ultradent.com	78
Westlund Dental Studio	www.westlunddental.com	99

jCD ASKED AUTHORS IN THIS ISSUE, "WHAT BOOKS HAVE INSPIRED YOU REGARDING BONDING, COMPOSITES, AND ADHESION?"

Newton Fahl Jr., DDS, MS: *Bonded Porcelain Restorations in the Anterior Dentition: A Biomimetic Approach*, by Pascal Magne and Urs Belser.

Prashant A. Hatkar, MDS: *Fundamentals of Operative Dentistry: A Contemporary Approach* (3rd ed.), by James B. Summitt, J. William Robbins, Thomas J. Hilton, and Richard S. Schwartz.

Jean-François Roulet, DDS, PhD: *Dentist Wealthy—Patients Healthy*, by Mutlu Özcan.

Ed Swift, DMD, MS: *Aesthetic and Restorative Dentistry: Material Selection & Technique*, by Douglas Terry, Karl F. Leinfelder, and Willi Geller.

Note: The AACD does not endorse any of the books listed above; these are the authors' personal selections.

Advertising Deadlines

Issue	Space Reservation
Winter 2011	December 6, 2010
Spring 2011	February 7, 2011

Ad Material
December 20, 2010
February 21, 2011

Security you can rely on.

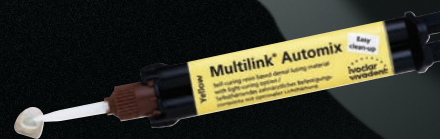Multilink® Automix

Easy Clean-Up Formula!

Developed to maximize the performance of IPS e.max® restorations, Multilink® Automix creates a strong link between lithium-disilicate and dentin and enamel, providing you and your patients with security you can rely on.

- Fast, easy clean-up
- Self-etching primer for reduced sensitivity
- High-immediate bond strengths to all restorative materials

**Multilink®
Automix**
UNIVERSAL ADHESIVE CEMENT



100% CUSTOMER SATISFACTION
GUARANTEED!

ivoclarvivadent.com/multilink

Call us toll free at 1-800-533-6825 in the U.S., 1-800-263-8182 in Canada.
©2010 Ivoclar Vivadent, Inc. Multilink and IPS e.max are registered trademarks of Ivoclar Vivadent, Inc.

**ivoclar
vivadent**
passion vision innovation

—YONES K. 2010 MACVENEERS
MODEL SEARCH WINNER

DENTISTRY BY DR. ALEX M. NAINI
VIENNA, VIRGINIA

Nationally recognized as AACD GALLERY AWARD WINNERS, MACVENEERS provide an exceptional *edge in dentistry*. Our technicians are experienced in all occlusion philosophies and can tailor to each unique smile story. With our industry-leading restorations and dedicated service, we strive to elevate your practice *beyond the ordinary*.

Contact us today to *empower your practice* with MACVENEERS and begin your own remarkable story.

MACVENEERS. A SMILE FOR EVERY STORY™