

# Concepts of Design for Contemporary Anterior All-Ceramic Restorations

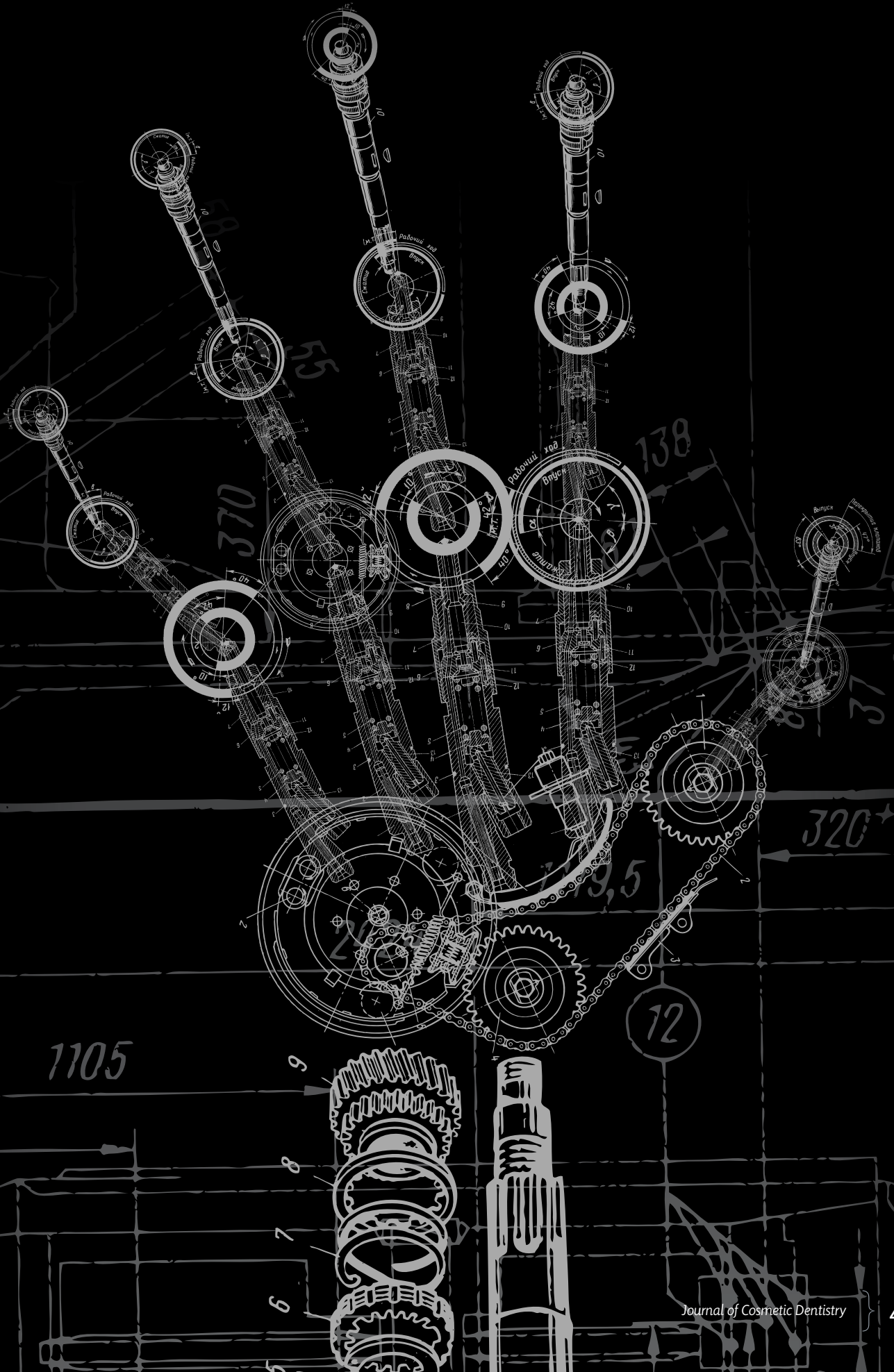
Advantages and Limitations of New Technologies and Materials

Ariel J. Raigrodski, DMD, MS, FACP

## Abstract

Clinicians and dental technicians are constantly challenged with harnessing new technologies and materials with the goal of providing patients with indirect restorations that have superior biomechanical and optical properties. This visual essay focuses on concepts of restoration design for complete-coverage restorations and demonstrates appropriate restorative materials selection from a biomechanical and esthetic perspective while maintaining sound restorative concepts for fostering a successful long-term treatment outcome.

**Key Words:** all-ceramic, bi-layered restorations, monolithic restorations, zirconium dioxide, lithium disilicate



## Introduction

The continuous evolution of all-ceramic systems in the last 20 years has been driven by increasing patient demand for metal-free restorations and the ongoing development of restorative materials, concepts of restoration design, and restoration manufacturing technologies. One of the main advantages of such restorations is their ability to facilitate an esthetic treatment outcome at the soft-tissue restorative interface, especially when patients present with a thin, translucent gingival phenotype.

Numerous considerations, which may require the involvement of multiple dental disciplines, must be weighed during the treatment-planning phase prior to commencing treatment. One such consideration is restoration design and material selection for complete-coverage restorations such as crowns and fixed dental prostheses (FDPs), both tooth- and implant-supported.<sup>1</sup> With the use of either computer-assisted design/computer-aided manufacturing (CAD/CAM) technology or the waxing and heat-pressing technique for their processing, all-ceramic restorations may be designed using two major concepts. To date, heat-pressing technology may provide superior control of restoration contours and occlusal contacts versus CAD/CAM technology, an area in which virtual waxing with three-dimensional imaging and display is still evolving.

## Concepts of Restoration Design

### Bi-layered Approach

All-ceramic restorations may be designed and fabricated as a bi-layered system, much like metal-ceramic restorations. Such systems utilize an infrastructure substitute in the form of high-strength ceramic to support the corresponding veneering porcelain. The veneering porcelain may be applied using one of three techniques: conventional layering with a powder and liquid; waxing and heat pressing to the high-strength ceramic infrastructure; and digital veneering, which fuses a partially sintered milled veneering ceramic with the high-strength ceramic coping.<sup>2-4</sup> In the esthetic zone, the bi-layered approach relies mainly upon the skills of the dental ceramist for a customized ceramic layering and allows the fabrication of highly esthetic restorations.

However, from a biomechanical perspective, the veneering porcelain is relatively weak compared to high-strength ceramics and may be susceptible to cohesive fractures, as well as adhesive failure due to the presence of an interface between the framework and the veneering porcelain. Moreover, adequate framework design to support the veneering porcelain is required.<sup>5,6</sup> In addition, one must consider that the occlusal surfaces and contacts are made of weaker material and, if the infrastructure is conventionally layered, control of occlusal contacts may not always be ideal.

### Monolithic Approach

All-ceramic restorations can also be designed and fabricated as a monolithic system, such as cast gold restorations. With this approach, a high-strength ceramic material is used to provide a complete contour restoration all the way from the intaglio surfaces to the proximal and occlusal surfaces. This approach may facilitate the ability of clinicians to provide a more durable restoration, since the occlusal surfaces and contacts are made of a high-strength ceramic material. In addition, with the technologies currently used for fabricating such restorations, a more accurate reproduction of the occlusal surfaces and occlusal contacts is facilitated (particularly with the waxing and heat-pressing technique). However, such an approach may be accompanied with some esthetic limitations, as characterization of the restoration is mainly limited to external staining.

Hence, these two concepts of restoration design present with their relative advantages and limitations. The bi-layered approach may be more appropriate in the anterior segment, where internal characterization, translucency, and color matching are critical and occlusal forces are relatively low. The monolithic approach may be more appropriate in the posterior segments, where esthetics may be a lesser concern and occlusal forces are relatively high. However, in some clinical scenarios, patients may present with evidence of occlusal parafunction or occlusal dysfunction in the anterior segment. In such situations, prudent management of anterior and canine guidance is critical to the longevity of the restorations. Yet, esthetics is an equally essential element when it comes to achieving adequate color matching, translucency, and characterization.

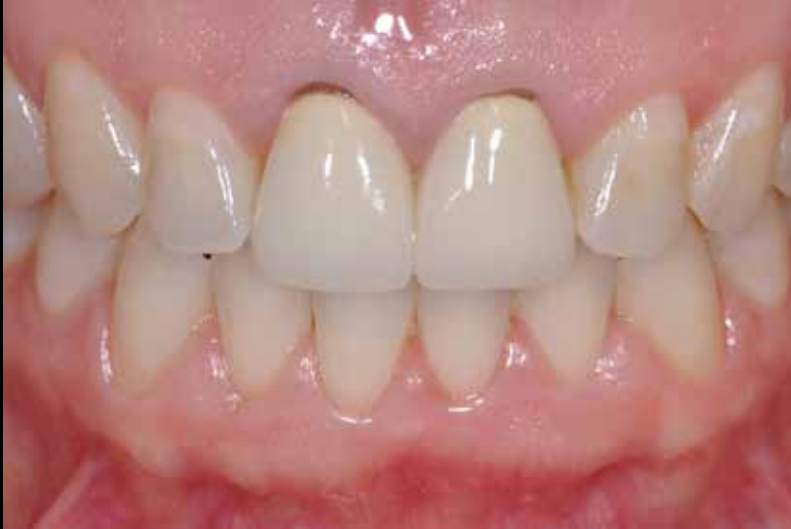### The Hybrid Design

Therefore, in such clinical scenarios, a hybrid restoration design may be preferred. A monolithic, high-strength surface is designed and fabricated at the functional palatal aspects of the restoration to ensure that the palatal anatomy of the restorations coincides with the patient's envelope of parafunction and to ensure optimization of the mechanical properties of the occlusal contacting areas of the restorations. The remaining ceramic infrastructure at the facial and incisal aspects of the restoration may be conventionally layered with the corresponding veneering porcelain to facilitate internal characterization, translucency, and color match with the adjacent and opposing dentition.

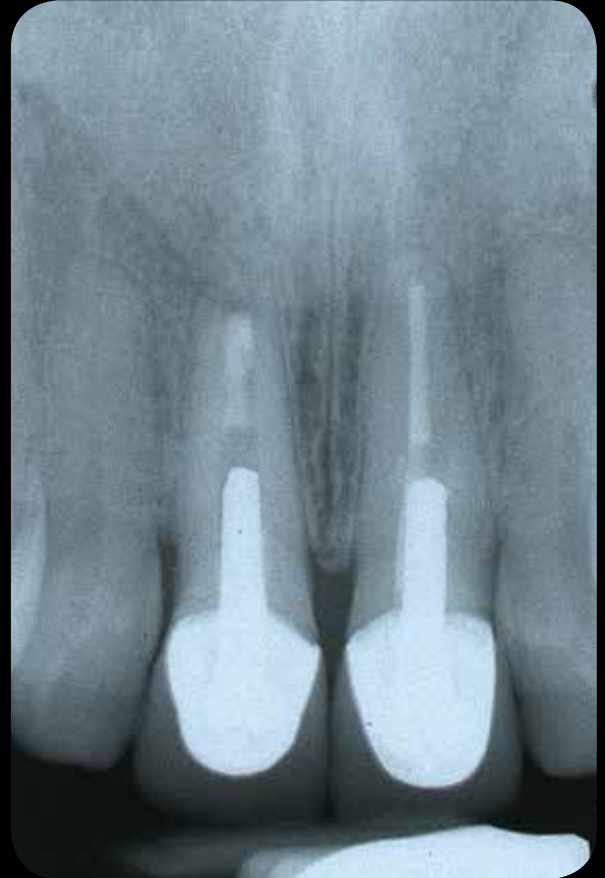## Materials

To date, lithium disilicate and zirconium dioxide-based restorative systems have gained popularity in the dental market as high-strength ceramic materials for crowns and FDPs using both the monolithic and the bi-layered approach for restoration design.<sup>7</sup> Both materials vary in terms of mechanical properties, optical properties, wear properties, and bio-

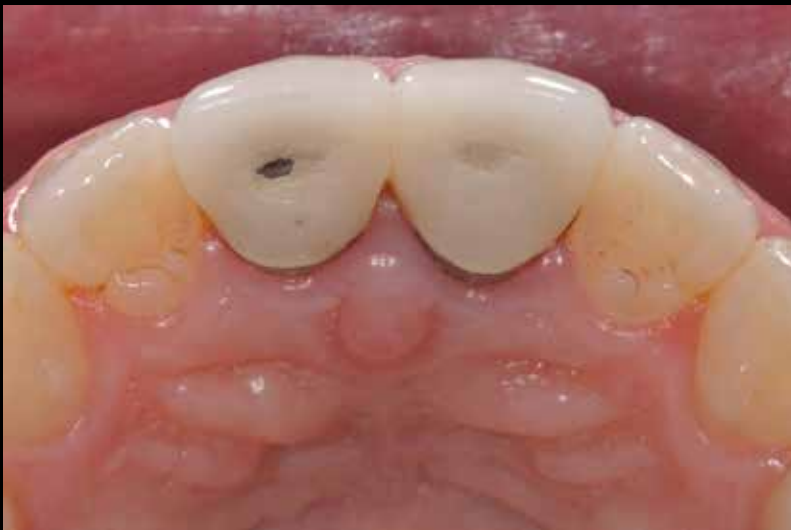“ In the esthetic zone, the bi-layered approach relies mainly upon the skills of the dental ceramist for a customized ceramic layering and allows the fabrication of highly esthetic restorations. ”



**Figure 1a:** Preoperative facial view of two failing metal ceramic crowns on #8 and #9. Note the gingival recessions and inadequate margins as well as the opacity of the restorations.



**Figure 1c:** Although #8 and #9 were asymptomatic, a preoperative radiograph indicates a failing endodontic treatment and less-than-adequate marginal integrity on the crown of #8.



**Figure 1b:** Preoperative occlusal view of the two failing metal ceramic crowns. Note the wear patterns on the palatal aspects of the crowns.

compatibility. These variations affect their indications and limitations, as well as some of the clinical procedures applied while using them, including preparation design and delivery procedures (conventional versus adhesive cementation).<sup>1,7</sup>

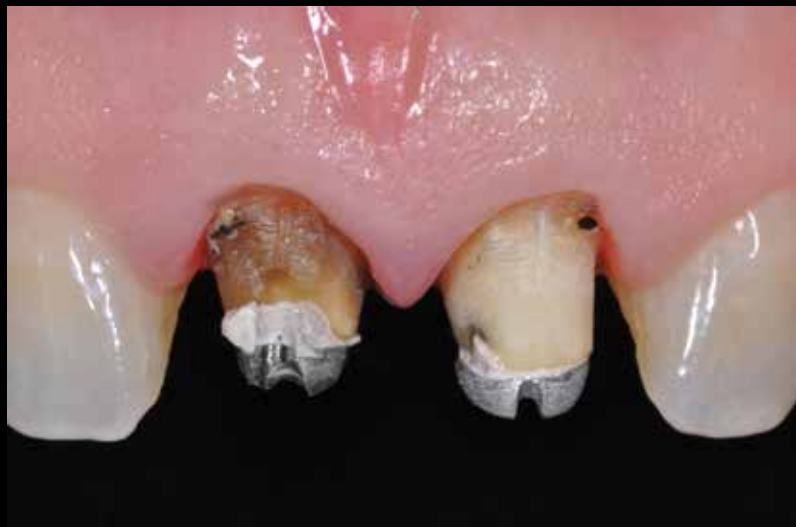**Lithium Disilicate**

Lithium disilicate may be designed and processed with either the lost wax and heat-pressing technique or via CAD/CAM technology. Although inferior to zirconium dioxide in terms of mechanical properties, this material allows for the fabrication of relatively translucent restorations with favorable wear properties as related to the opposing dentition.<sup>7-9</sup> Lithium disilicate restorations may be fabricated using the monolithic, bi-layered, or hybrid design approach. The latter two include the use of nano-fluorapatite porcelain as a veneering material. The intaglio surface of the lithium disilicate monolithic or layered restoration may be etched for 20 seconds with 9.5% hydrofluoric acid and subsequently adhesively cemented to enhance strength and longevity.<sup>1</sup> In the esthetic zone, it is the author's preference to employ this material for single crowns exclusively using the hybrid design approach in the following clinical scenarios:

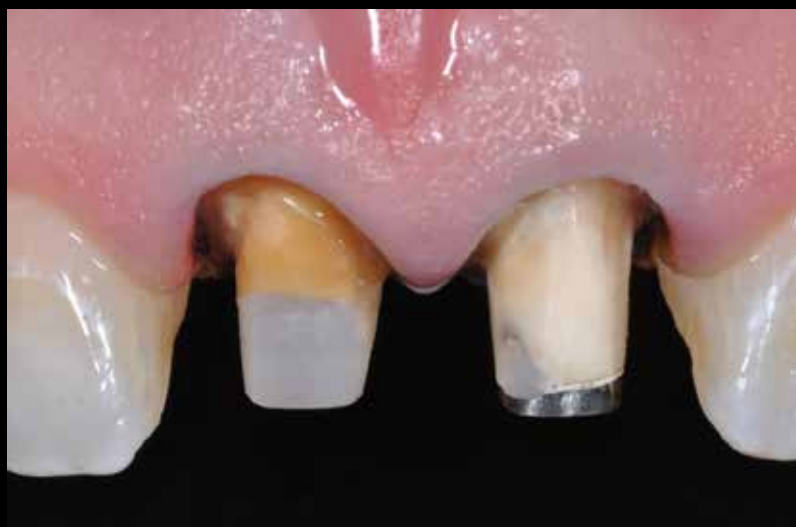- When the abutment tooth is translucent and gingival health is adequate enough to not compromise the bonding procedure, use a more translucent lithium disilicate ingot.
- When the abutment tooth is discolored and gingival health is adequate enough to not compromise the bonding procedure, use a more opaque lithium disilicate ingot.

**Zirconium Dioxide**

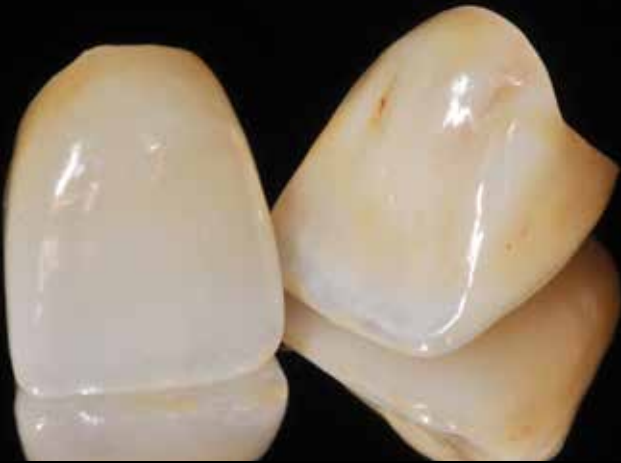With excellent biocompatibility, zirconium dioxide may be designed and processed via CAD/CAM technology.<sup>7</sup> Superior to lithium disilicate in terms of mechanical properties, zirconium dioxide currently allows for the fabrication of less translucent restorations for both crowns and FDPs.<sup>10,11</sup> However, new zirconium dioxide materials are being developed with improved optical and mechanical properties. In addition, the wear properties of zirconium dioxide are improving as related to the opposing dentition.<sup>12,13</sup> With zirconium dioxide, restorations might be fabricated using the monolithic, bi-layered, or hybrid design approach. The latter two include



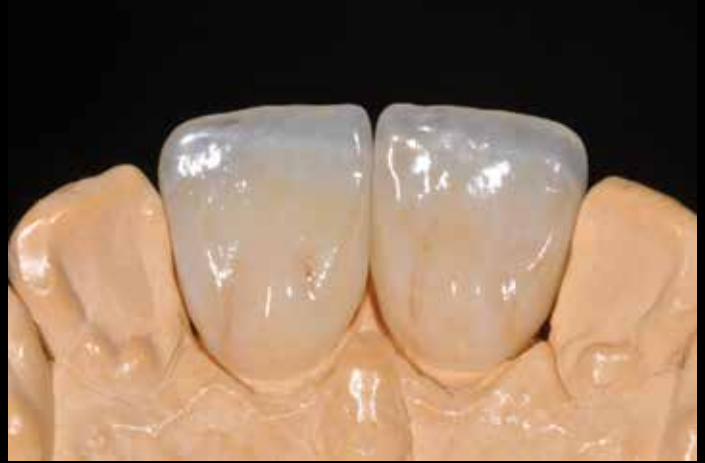**Figure 2a:** The failing restorations were removed, and the severity of the discoloration was noted for #8. The lack of adequate fit of the cast post and core for both teeth was determined as well.



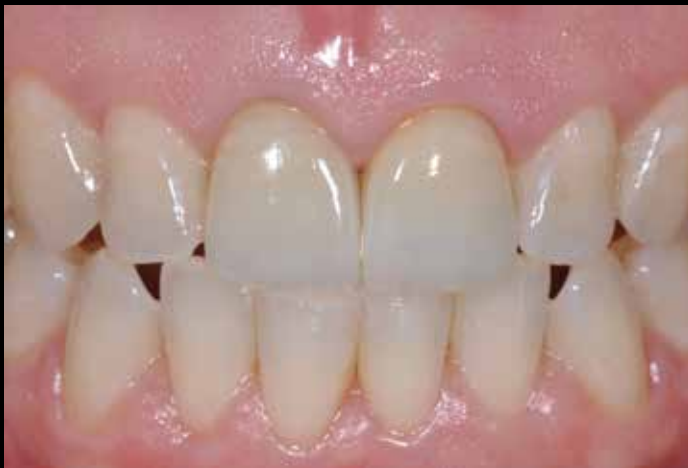**Figure 2b:** The cast post and core has been removed from #8 and the endodontic therapy was remade. Subsequently, internal bleaching procedures were performed, followed by the placement of a fiber post and composite-resin core. Due to the complexity of the post removal and the concern about possible complications, it was decided not to remove the cast post and core from #9. The tooth preparations were refined, and a master impression was made.



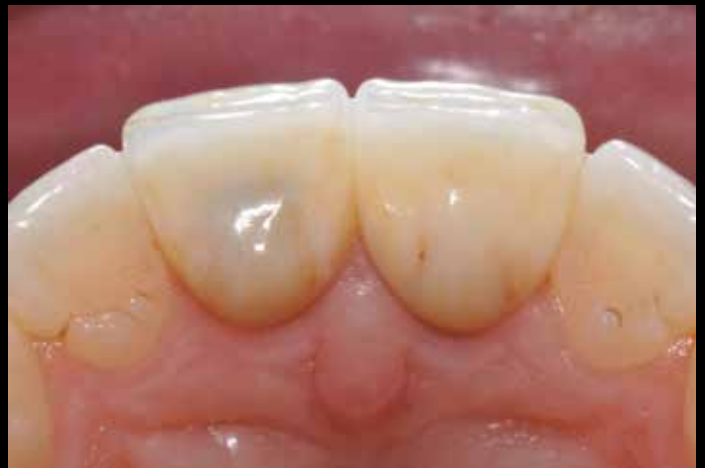**Figure 3a:** Lithium disilicate ceramic material was selected for the fabrication of definitive all-ceramic crowns on #8 and #9. Medium-opacity lithium disilicate ingots (MO1, IPS e.max Press, Ivoclar Vivadent; Amherst, NY) were selected for the fabrication of partial monolithic all-ceramic crowns.



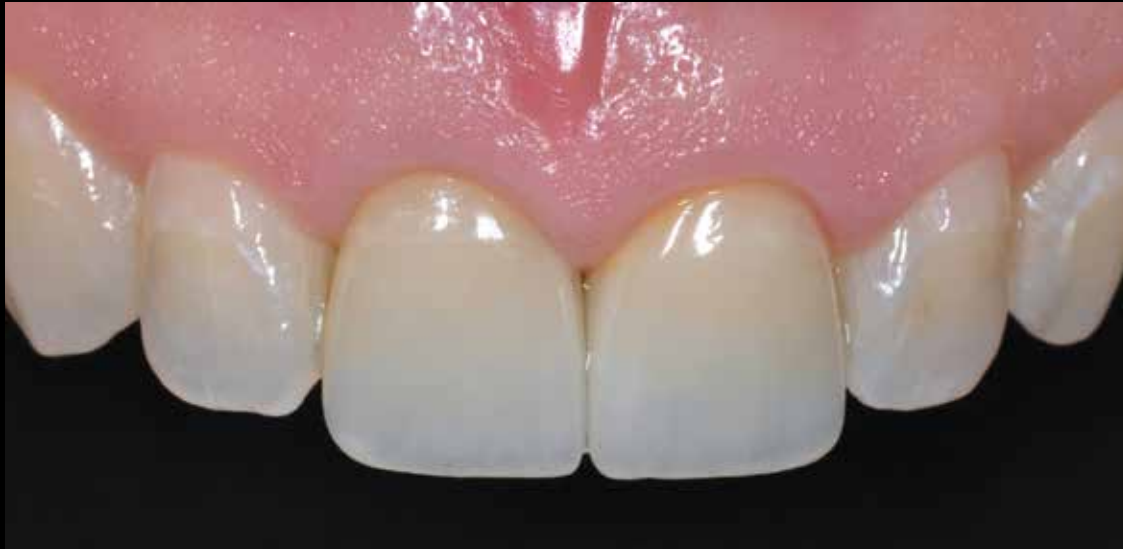**Figure 3b:** A monolithic approach was used for the design and fabrication of the functional palatal aspects of the crowns to ensure that the palatal anatomy of the restorations coincided with the patient's envelope of parafunction. This was reproduced using the provisional restorations and to ensure optimization of the mechanical properties of the occlusal contacting areas of the restorations. The facial and incisal aspects of the crowns were conventionally layered to facilitate internal characterization, translucency, and esthetics using nano-fluorapatite-layering ceramics (IPS e.max Ceram).



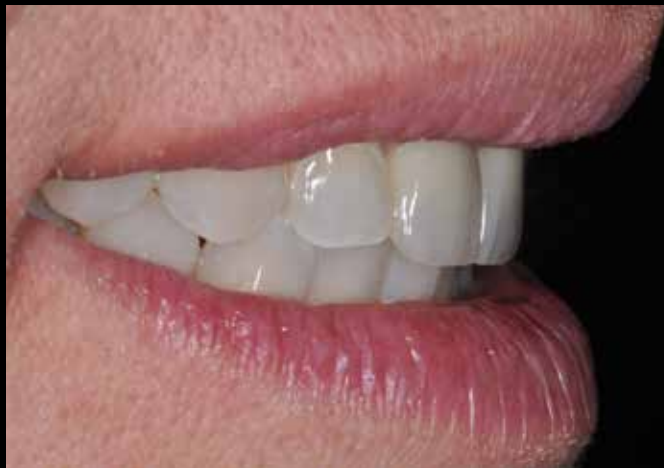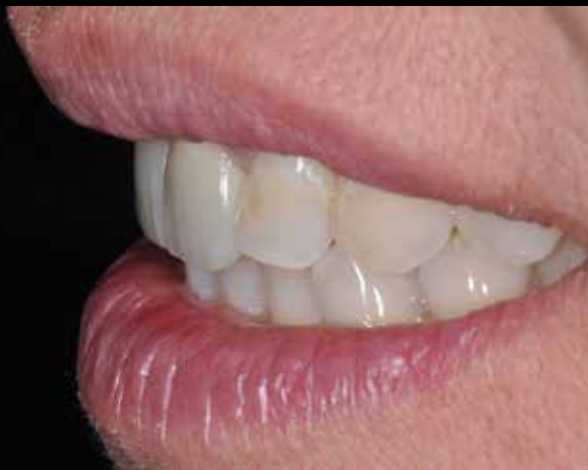**Figure 4a:** The restorations were tried in the patient's mouth to assess color match and esthetics and internal and proximal fit, and to assess occlusal contacts. Functional, esthetic integration with the adjacent and opposing dentition, as well as integration at restorative soft-tissue interface, was noted.



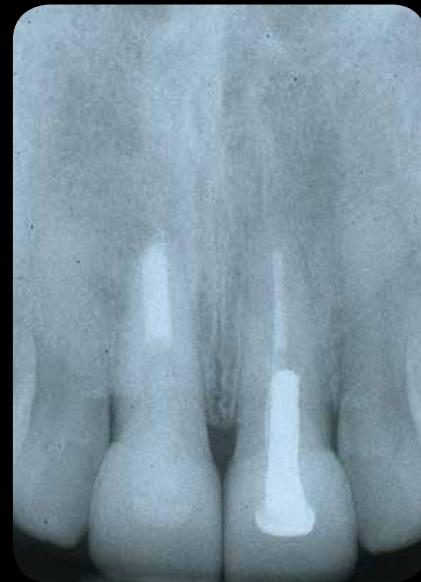**Figure 4b:** Once verified, the restorations were bonded with dual-cured translucent composite-resin cement (RelyX Ultimate, 3M ESPE; St. Paul, MN). However, it was also noted on the palatal aspect of the crown on #8 that the discolored tooth projected a low value through the restoration due to the translucency of the restorative material.



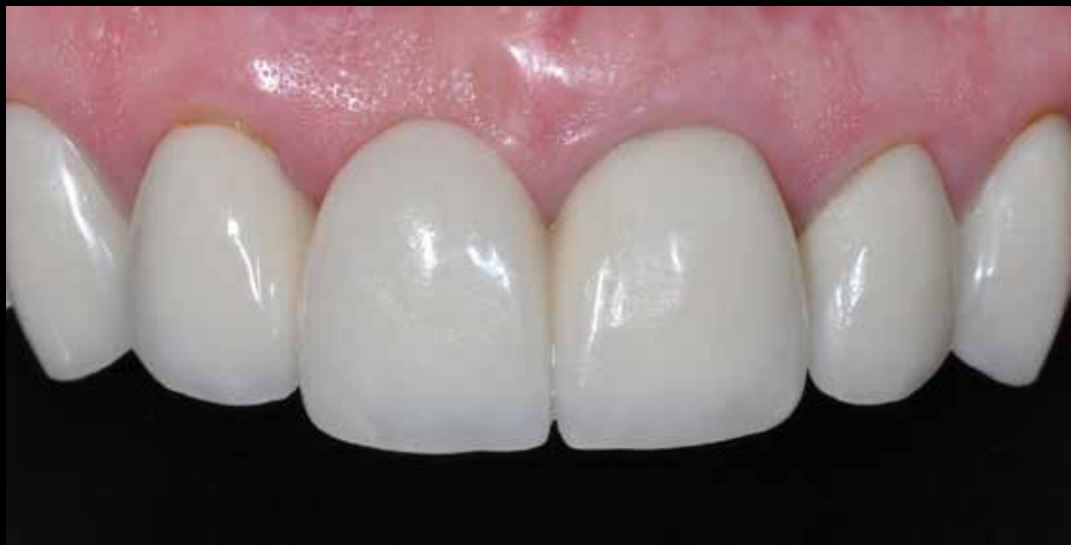**Figure 5a:** A frontal view demonstrates both high translucency at the incisal areas and characterizations at the facial aspect of the restorations; this was the result of the artistic capabilities of the dental ceramist who layered the restorations' facial and incisal aspects.



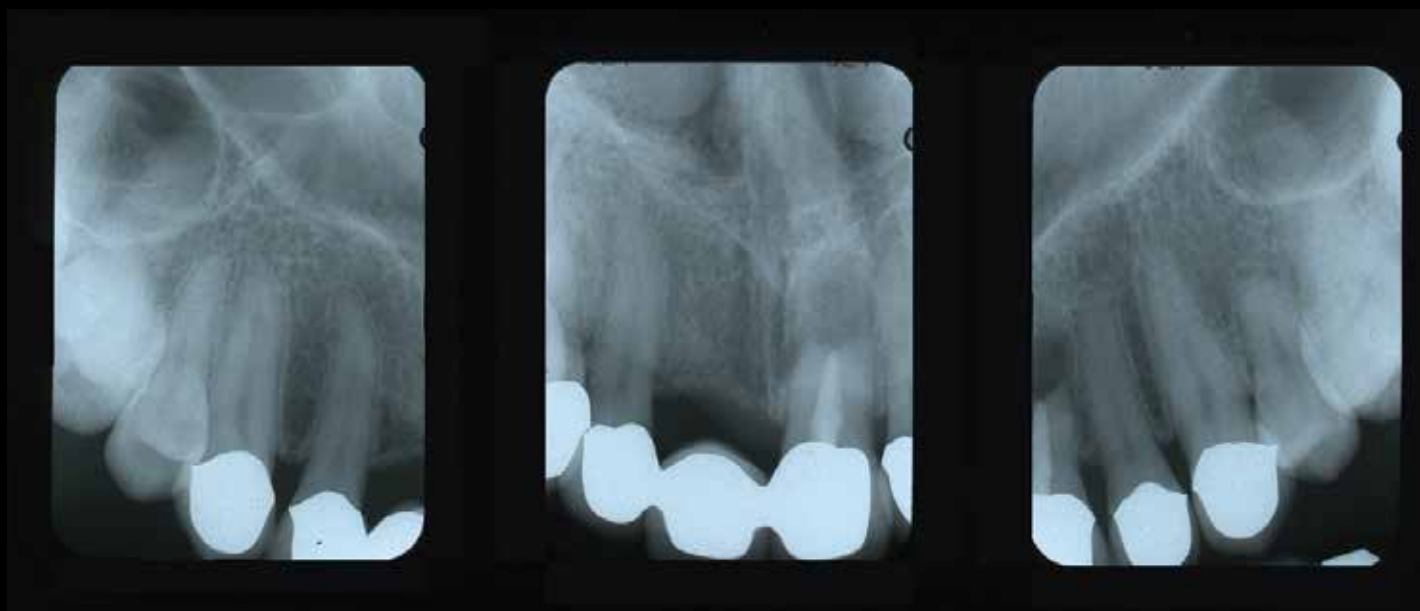
**Figures 5b & 5c:** Right and left lateral views of the patient's partial smile demonstrate the successful integration of the restorations with the upper and lower lips.



**Figure 6:** A postoperative radiograph underscores the success of the endodontic therapy and the new fiber post and core on #8, as well as the excellent marginal integrity and the complete excess cement removal.



**Figure 7:** A preoperative facial view of esthetically failing metal ceramic crowns on #6, #10, and #11; and a failing metal ceramic FDP on #7 (retainer), #8 (pontic), and #9 (retainer). Note the opacity of the restorations, which were made and remade a few times previously.



**Figure 8:** The patient had a history of trauma to the six anterior maxillary teeth. Although they were asymptomatic, a preoperative radiograph demonstrated an endodontic treatment on #9 with a history of periapical surgery.



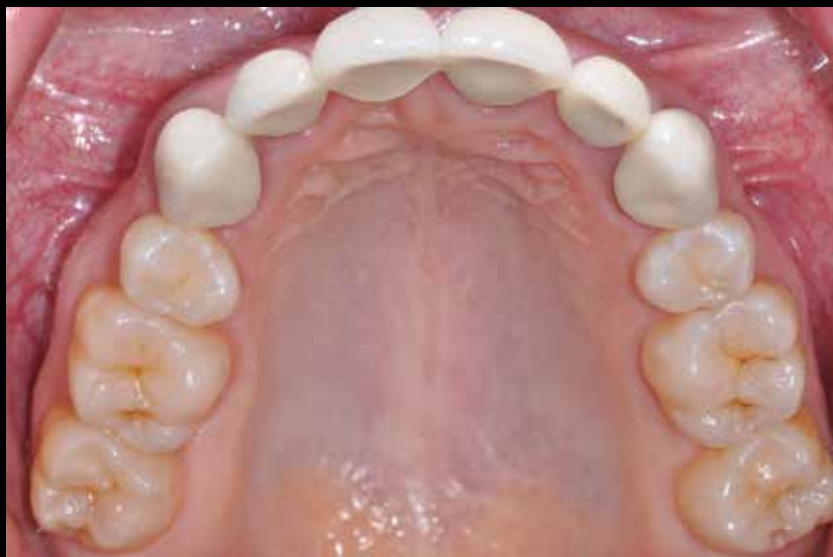the use of feldspathic porcelain as a veneering material, and it has been reported that the use of leucite-containing veneering porcelain may reduce the likelihood of cohesive porcelain fractures.<sup>14</sup> Although zirconium dioxide cannot be etched, it can be treated tribochemically<sup>15,16</sup> or with special methacryloxydecyl phosphate (MDP) monomer adhesives to facilitate bonding.<sup>17,18</sup> In addition, due to the superior mechanical properties of zirconium dioxide, these restorations can be conventionally cemented without compromising their longevity.<sup>10,11,19</sup> In the esthetic zone, it is the author's preference to use this material with the hybrid design approach in the following clinical scenarios:

- If the abutment tooth is discolored and gingival health is adequate enough to not compromise bonding procedures, use a coping thicker than 0.6 mm on the facial aspect.
- If the abutment tooth is discolored and gingival health is inadequate enough to compromise bonding procedures, use a coping thicker than 0.6 mm on the facial aspect.
- If the abutment tooth is translucent and gingival health is inadequate enough to compromise bonding procedures, use a coping thickness of 0.3 mm on the facial aspect.

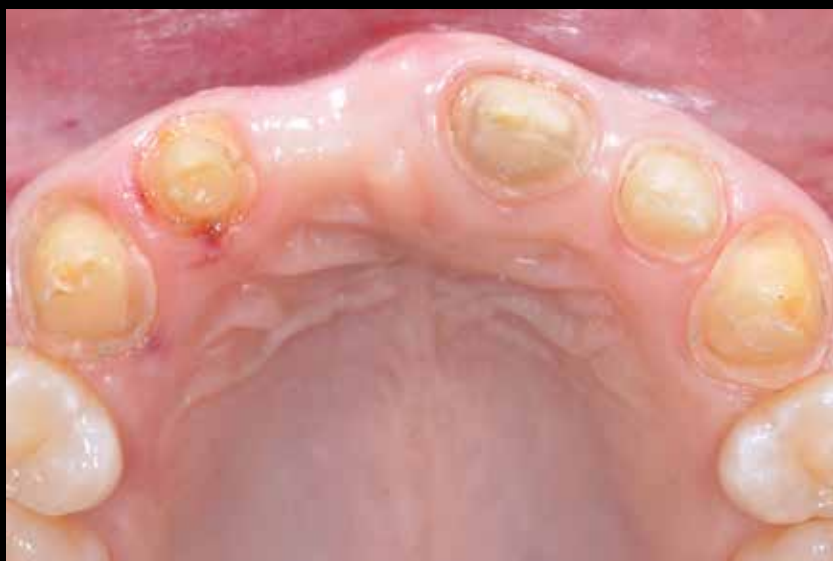These restorations are not limited to single crowns exclusively, as they have been shown to be successful for both anterior and posterior FDPs.<sup>10,11</sup>

## Summary

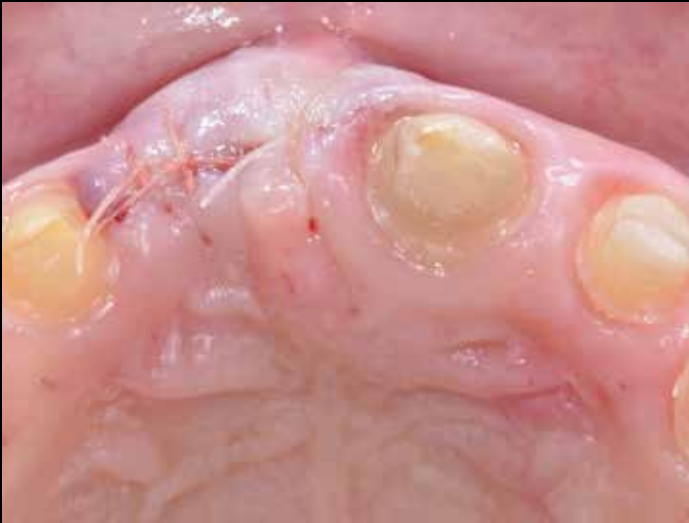Acknowledging the advantages and limitations of the different ceramic core materials and harnessing new technologies and restoration design philosophies are key elements for a successful contemporary practice. This visual essay demonstrates how these concepts can be applied to different clinical scenarios, as suggested herein for multiple crowns and FDPs. By following sound concepts of material selection and restoration design, clinicians and ceramists may customize the design of restorations in the esthetic zone based upon each patient's individual needs and, as a result, promote both restoration longevity and esthetics.



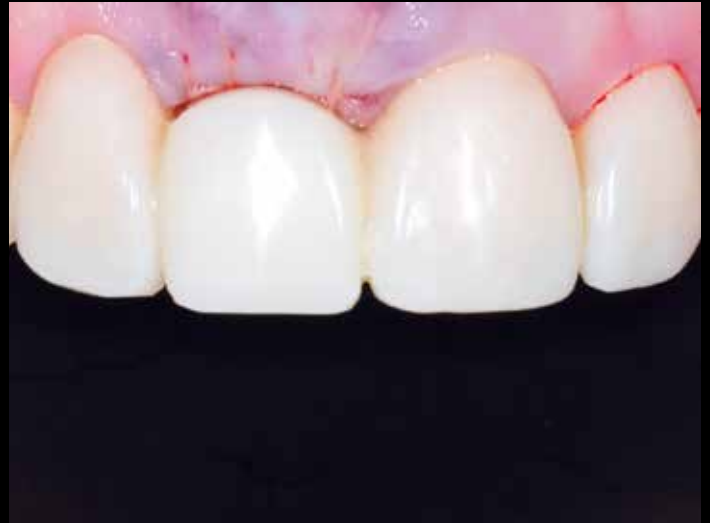**Figure 9:** A preoperative occlusal view of the failing metal ceramic restorations. Note the wear on the crowns' palatal aspects as well as the lack of color match with the adjacent dentition.



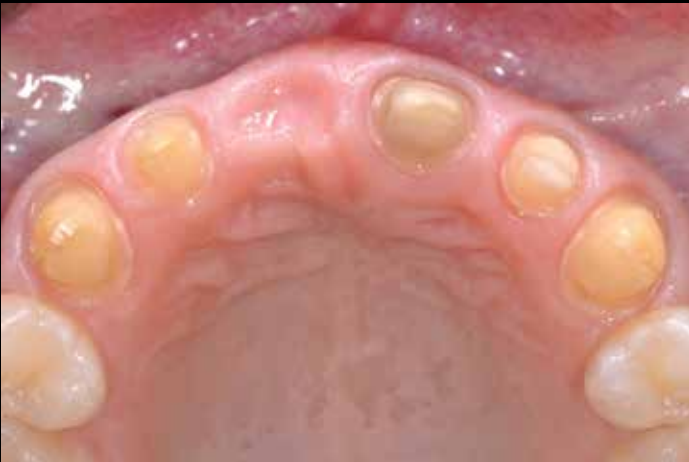**Figure 10:** The failing restorations were removed and the severity of the horizontal residual alveolar ridge deficiency at the site of #8 was noted.



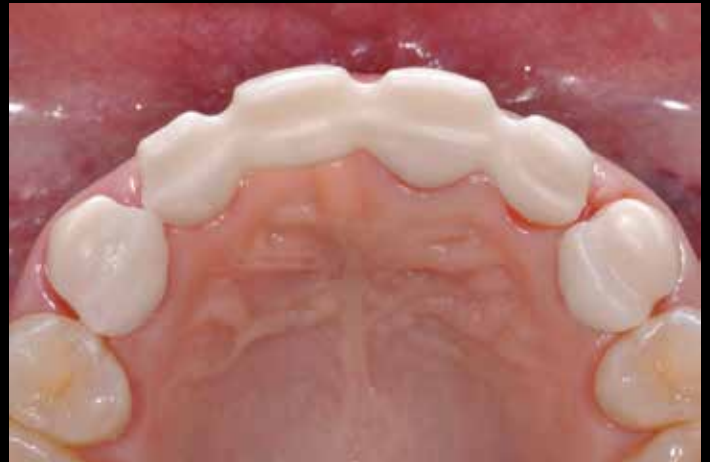**Figure 11a:** Soft tissue augmentation of the residual alveolar ridge was performed using acellular dermal matrix (Alloderm RTM, Lifecell, Biohorizons; Birmingham, AL) to eliminate the horizontal ridge deficiency at the pontic site.



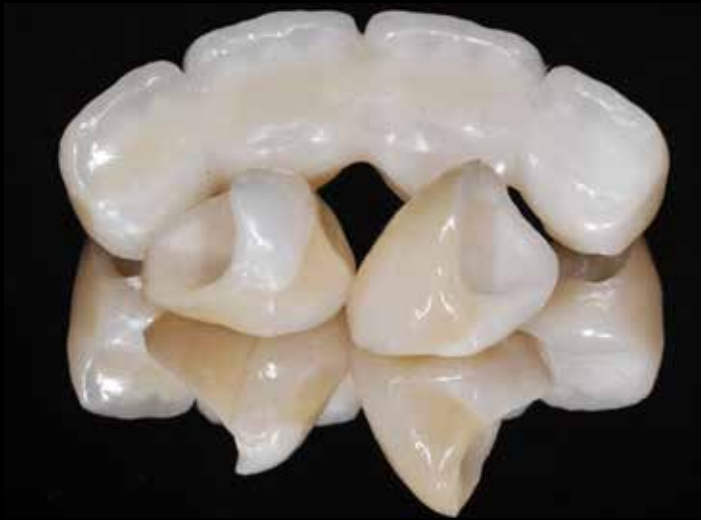**Figure 11b:** A provisional restoration was delivered with the pontic shortened at the cervical aspect to eliminate pressure at the augmented site. After three months, once the tissue healed, the pontic site was trimmed with a KS4 extra-coarse football-shaped diamond bur (Brasseler USA; Savannah, GA) and a direct composite resin was added to the cervical part of the pontic to mold the tissue at the pontic site. The tissue was left to heal for an additional three months.



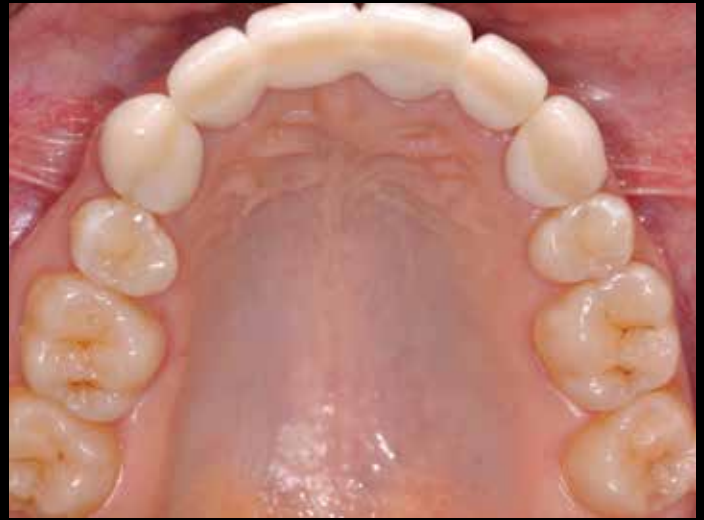**Figure 12:** Once the pontic site was completely healed, the tooth preparations were refined and a master impression was made for a zirconium dioxide-based, four-unit FDP for #7 (retainer), #8 (pontic), and #9 (retainer); and zirconium dioxide-based crowns on #6 and #11.



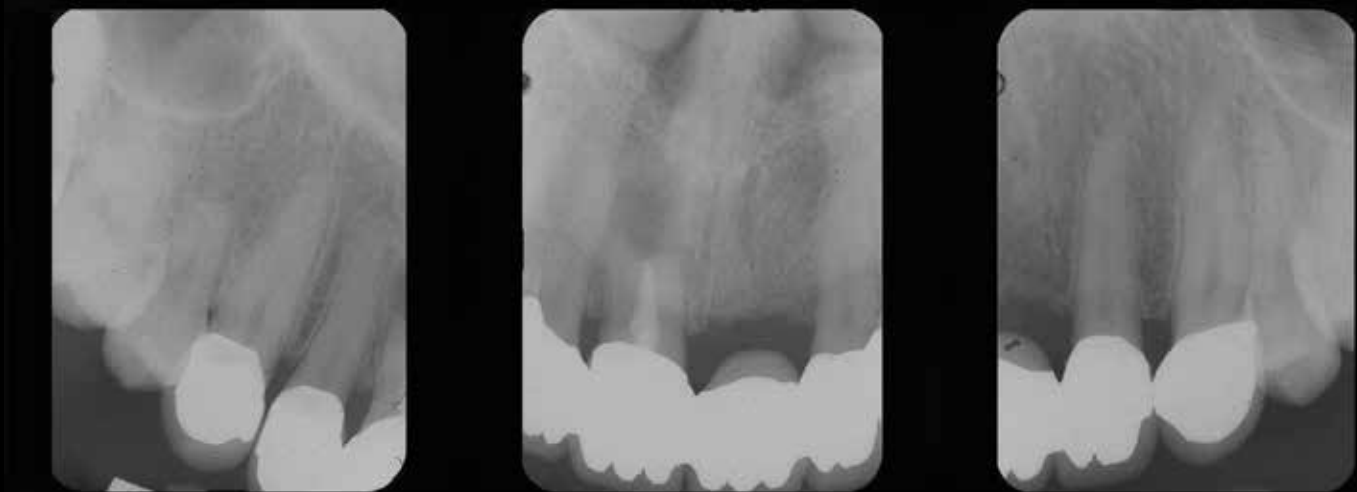**Figure 13:** A zirconium dioxide framework with extensive palatal and interproximal struts was designed and milled with a CAD/CAM system (Lava, 3M ESPE). The framework and copings were tried in the patient's mouth for fit and for soft tissue evaluation at the pontic site. A monolithic approach was used for the design and fabrication of the restorations' palatal aspects.



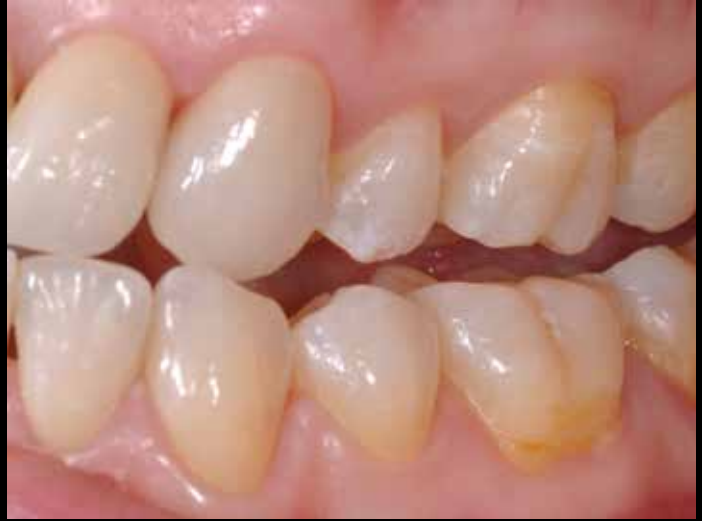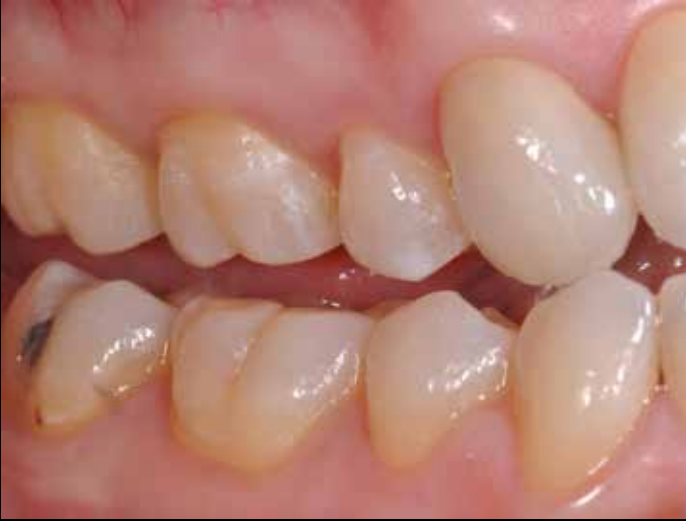**Figure 14:** The zirconium dioxide framework was conventionally layered with a corresponding veneering porcelain (Creation ZI-F, Jensen Dental; North Haven, CT). The zirconium dioxide-based crowns were layered using a digital veneering approach (Lava DVS digital veneering system).



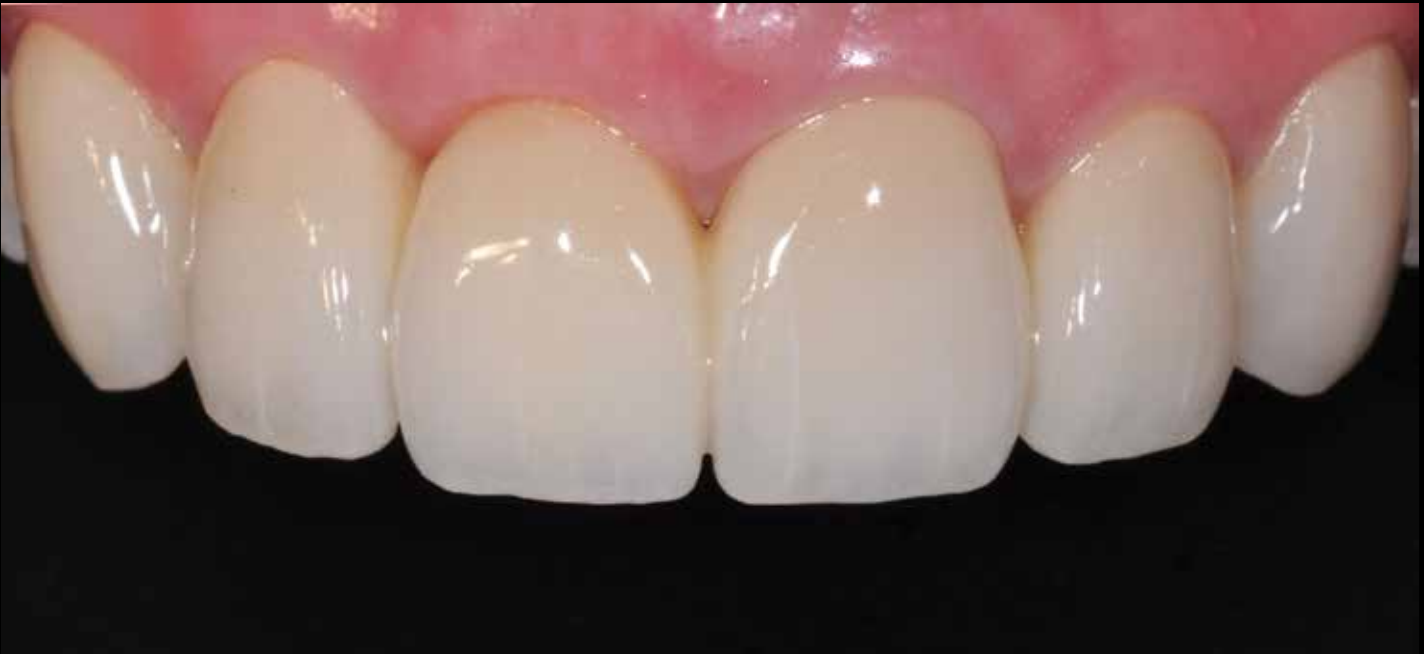**Figure 15:** The restorations were conventionally cemented with self-etching, self-adhesive, dual-cured composite resin cement (RelyX Unicem 2).



**Figure 16:** Excellent marginal integrity and excess cement removal were confirmed.



**Figures 17a & 17b:** The patient was provided with a mutually protected occlusion with canine guidance in lateral excursions and anterior guidance in protrusive movement.



**Figure 18:** The ceramist layered the facial and incisal aspects of the restorations so as to provide characterizations and translucency to the patient's satisfaction.

**Acknowledgments**

*The author expresses his sincere gratitude to Dr. Michael Cohen for the surgical procedures performed in the second case. The author also thanks master ceramists Harald Heindl and Sang Jun for fabricating the restorations presented in the first case and second case, respectively; and Dr. Matthew Mandel for the endodontic therapy of tooth #8 in the first case.*

**References**

1. Raigrodski AJ. Materials selection for complete coverage all-ceramic restorations. In: Cohen M, editor. Interdisciplinary treatment planning principles design implementation. Hanover Park (IL): Quintessence Pub.; 2008. p. 383-406.
2. Ishibe M, Raigrodski AJ, Flinn BD, Chung KH, Spiekerman C, Winter RR. Shear bond strengths of pressed and layered veneering ceramics to high-noble alloy and zirconia cores. *J Prosthet Dent.* 2011;106:29-37.
3. Beuer F, Schweiger J, Eichberger M, Kappert HF, Gernet W, Edelhoff D. High-strength CAD/CAM-fabricated veneering material sintered to zirconia copings: a new fabrication mode for all-ceramic restorations. *Dent Mater.* 2009;25:121-8.
4. Schmitter M, Mueller D, Rues S. Chipping behaviour of all-ceramic crowns with zirconia framework and CAD/CAM manufactured veneer. *J Dent.* 2012;40:154-62.
5. Bonfante EA, da Silva NR, Coelho PG, Bayardo-González DE, Thompson VP, Bonfante G. Effect of framework design on crown failure. *Eur J Oral Sci.* 2009;117:194-9.
6. Rosentritt M, Steiger D, Behr M, Handel G, Kolbeck C. Influence of substructure design and spacer settings on the in vitro performance of molar zirconia crowns. *J Dent.* 2009;37:978-83.
7. Raigrodski AJ. Contemporary materials and technologies for all-ceramic fixed partial dentures: a review of the literature. *J Prosthet Dent.* 2004;92:557-62.
8. Gehrt M, Wolfart S, Rafai N, Reich S, Edelhoff D. Clinical results of lithium disilicate crowns after up to 9 years of service. *Clin Oral Investig.* 2013;17:275-84.
9. Kern M, Sasse M, Wolfart S. Ten-year outcome of three-unit fixed dental prostheses made from monolithic lithium disilicate ceramic. *J Am Dent Assoc.* 2012;143:234-40.

10. Raigrodski AJ, Hillstead MB, Meng GK, Chung KH. Survival and complications of zirconia-based fixed dental prostheses: a systematic review. *J Prosthet Dent.* 2012;107:170-7.
11. Raigrodski AJ, Yu A, Chiche GJ, Hochstedler JL, Mand LA, Mohamed SE. Clinical efficacy of veneered zirconium dioxide-based posterior partial fixed dental prostheses: five-year results. *J Prosthet Dent.* 2012;108:214-22.
12. Beuer F, Stimmelmayr M, Gueth JE, Edelhoff D, Naumann M. In vitro performance of full-contour zirconia single crowns. *Dent Mater.* 2012;28:449-56.
13. Rosentritt M, Preis V, Behr M, Hahnel S, Handel G, Kolbeck C. Two-body wear of dental porcelain and substructure oxide ceramics. *Clin Oral Investig.* 2012;16:935-43.
14. Christensen RP, Ploeger BJ. A clinical comparison of zirconia metal and alumina fixed-prosthesis frameworks veneered with layered pressed ceramic: a three-year report. *J Am Dent Assoc.* 2010;141:1317-29.
15. Kern M, Barloi A, Yang B. Surface conditioning influences zirconia ceramic bonding. *J Dent Res.* 2009;88:817-22.
16. Passos SP, May LG, Barca DC, Ozcan M, Bottino MA, Valandro LF. Adhesive quality of self-adhesive and conventional adhesive resin cement to Y-TZP ceramic before and after aging conditions. *Gen Dent.* 2010;35:689-96.
17. Cristoforides P, Amaral R, May LG, Bottino MA, Valandro LF. Composite resin to yttria-stabilized tetragonal zirconia polycrystal bonding: comparison of repair methods. *Oper Dent.* 2012;37:263-71.
18. Attia A, Kern M. Effect of cleaning methods after reduced-pressure air abrasion on bonding to zirconia ceramic. *J Adhes Dent.* 2011;13:561-7.
19. Rosentritt M, Hmaidouch R, Behr M, Handel G, Schneider-Feyrer S. Fracture resistance of zirconia FPDs with adhesive bonding versus conventional cementation. *Int J Prosthodont.* 2011;24:168-71. **jcd**



Dr. Raigrodski, a diplomate of the American Board of Prosthodontics, is a professor, Department of Restorative Dentistry, University of Washington (UW), in Seattle. He also is an adjunct professor, Department of Materials Sciences and Engineering, UW College of Engineering. He has a private practice in Kenmore, Washington. Dr. Raigrodski can be contacted at [info@draigrodski.com](mailto:info@draigrodski.com)

Disclosure: The author received grants and research support from 3M ESPE, Biomat 3i, Nobel Biocare, and Brasseler USA, and Kuraray Noritake.