

# FOCAL Bleaching Technique

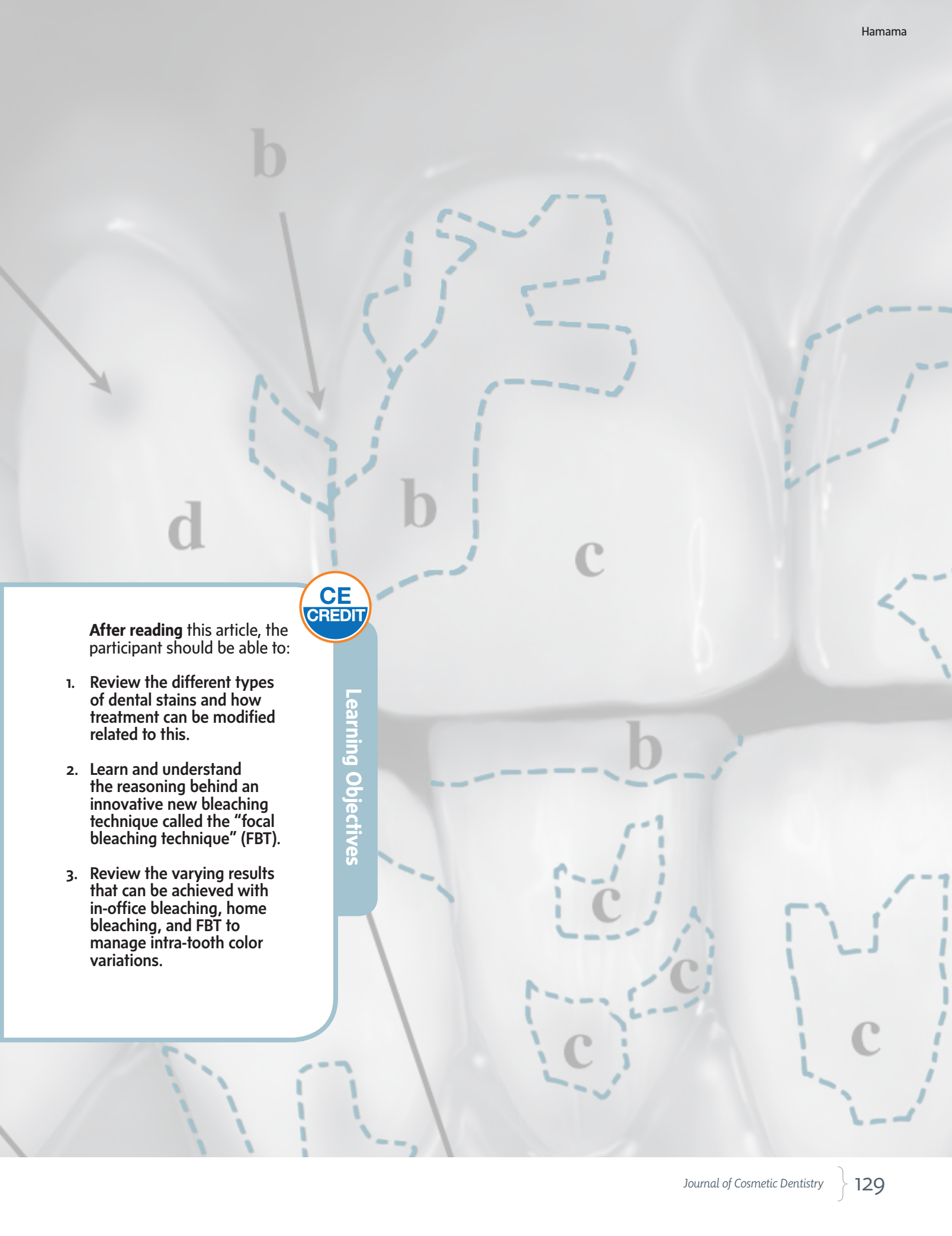
## Determining Stain Distribution by Creating a “Bleaching Map”

Hamdi H. Hamama, BDS, MDS

### Abstract

This study introduces the “focal bleaching technique” (FBT), which is designed to reduce the biological hazards of the application of the bleaching gel on dental tissues. It also can be considered as a direct application of minimal intervention dentistry concepts on bleaching. Drawing a “bleaching map” is a critical step preceding focal bleaching. This map is considered to be an important diagnostic tool that assists the clinician in determining the distribution of stain and developing a comprehensive treatment plan. The current study reports a clinical case of opaque fluorosis combined with brown discoloration treated with FBT. This case demonstrates the step-by-step procedure and limitations of this line of treatment. Using FBT changes the old concept of bleaching from simply that of whitening teeth to a systematic balancing of color between discolored and sound regions of the affected tooth. As with any clinical technique, it has some limitations; for example, the presence of “bleaching-persistent regions” that do not respond to the treatment and require another line of treatment (e.g., direct or indirect veneers). The current study revealed that using FBT guided with bleaching map can achieve better results compared to conventional bleaching methods.

**Key Words:** in-office, bleaching, discoloration, tetracycline, fluorosis



Learning Objectives

**After reading** this article, the participant should be able to:

1. Review the different types of dental stains and how treatment can be modified related to this.
2. Learn and understand the reasoning behind an innovative new bleaching technique called the "focal bleaching technique" (FBT).
3. Review the varying results that can be achieved with in-office bleaching, home bleaching, and FBT to manage intra-tooth color variations.

“ FBT expands the bleaching from a conventional process of shade lightening to a systematic balancing of color between the stained and the normal tooth regions. ”

## Introduction

### Historical Background

*Esthetics* is the field that studies the nature of beauty and seeks to enhance the particular details of static and dynamic objects to make them more visually appealing.<sup>1</sup> The artistic nature of dentistry and the growing esthetic demands of dental patients have led to the speciality of “esthetic dentistry.”

Treatment of tooth discoloration is one of the most important fields of esthetic dentistry. In ancient cultures and their artworks, white teeth symbolized beauty and good health. Past dental surveys revealed that 28 to 34% of surveyed subjects are dissatisfied with the color of their teeth and seek bleaching treatment.<sup>2,3</sup> Dental bleaching has been reported as the most conservative method of treating tooth discoloration.<sup>4</sup> Bleaching techniques have been markedly improved, from using pure chemical peroxides, until reaching the recent light/laser-assisted bleaching systems.<sup>5</sup>

In 1876, the first original work reporting the professional bleaching of stained teeth was written by M'Quillen,<sup>6</sup> who stated, “It is a somewhat remarkable and inexplicable fact that none of the textbooks which have been presented to the profession, so far as my observation goes, pay even the compliment of a passing notice to the means whereby discolored teeth may be improved in appearance.” Furthermore, M'Quillen had reported that the most common cause of tooth discoloration was intrusion of hemoglobin into dentinal tubules, which turns the tooth color to pink “rosy tooth.” M'Quillen used Labarraque's solution (liquor soda chlorinate), chloride of lime (calcium chlorinate powder), and chlorate of potash (potassium chlorate) as bleaching agents to improve the color of stained teeth.<sup>6</sup>

The first attempt to accelerate the bleaching process was introduced in 1918 by Abbot,<sup>7</sup> who used a high-intensity light source to raise the temperature of a peroxide-based bleaching agent. Another accelerating method was introduced in 1937 by Ames and Smithfield,<sup>8</sup> who used an external heat source. They also invented a specially designed hand instrument that was pre-warmed on a Bunsen burner and applied on the bleaching agent (the scientific name of the used bleaching agent was not clearly mentioned in their publication, however; they referred to it only as “liquid” or “solution”) to accelerate the bleaching process.

### Dentist-Supervised Home Bleaching

Bleaching has been a well-known treatment since 1989, after publications from Haywood and Heymann<sup>9-12</sup> about nightguard vital (dentist-supervised home) bleaching. Dentist-supervised home bleaching is a patient-dependent technique that requires a long time before achieving satisfactory results. Moreover, it fails in treating deeply stained teeth.

### “In-Office” Vital Bleaching

Another professional bleaching strategy, “in-office” vital bleaching, was introduced in the last two decades to overcome the drawbacks of the dentist-supervised home bleaching technique. In-office bleaching is performed by chairside application of highly concentrated bleaching agents on discolored teeth with a special regimen. Nowadays, there are many attempts to accelerate the in-office vital bleaching process by using external photo-activation methods (e.g., light-emitting diodes [LEDs], lasers, mercury halide lamps, plasma arc, quartz halogen, and ultraviolet units), also called “power in-office vital bleaching” or “power bleaching.” Incorporation of light-activation technology into dental bleaching techniques decreases the harmful effects of bleaching agents and reduces the treatment time.<sup>13</sup>

### Stain Types

Tooth stains can be classified into two main groups: extrinsic and intrinsic. The extrinsic stain is defined as a temporary stain that can be easily removed with routine prophylactic cleaning and usually results from frequent intake of dark-colored beverages (e.g., coffee, tea, and cola) or smoking. Conversely, the intrinsic stain is defined as an endogenous stain that has been incorporated into the tooth matrix and cannot be removed via routine prophylactic cleaning. Intrinsic stains can be caused by systemic intake of certain drugs (e.g., tetracycline derivatives) during the period of tooth formation. Also, excessive intake of fluoride during childhood can lead to a pathological condition called *dental fluorosis*. Dental bleaching deals with intrinsic stains and tries to remove or dilute their effect on the general shade of the tooth.

Tetracycline stains can be classified, according to their response to bleaching, into four categories: mild, moderate, severe, and intractable.<sup>14,15</sup> “Mild” degree can be observed as a yellow/gray stain uniformly

distributed among the affected teeth, whereas “moderate” degree is noticed as uniformly distributed yellow/brown or dark gray stains. However, severe stains are characterized by blue-gray and/or black stains associated with significant banding across the labial surface of the tooth. Furthermore, Feinman<sup>15</sup> described the remaining heavy tetracycline stains that did not respond to bleaching treatment and require other treatment modalities (e.g., veneers) as intractable stains. Mild and moderate stains can be treated with dentist-supervised home bleaching as well as in-office vital bleaching. However, severe and intractable stains can be treated only with in-office vital bleaching.

Fluorosis is another common intrinsic stain classified by Feinman into three degrees: simple, opaque, and pitting.<sup>15</sup> Feinman reported that simple fluorosis can be observed as brown pigmentation on the smooth surface of enamel and can respond to bleaching. On the other hand, opaque fluorosis can be observed as flat gray or white flakes on the enamel surface. Moreover, opaque fluorosis responds poorly to bleaching, due to the difficulty of obtaining a final uniform tooth shade.<sup>15</sup> Furthermore, it has been reported that pitting fluorosis should be treated with combination of bleaching and veneering techniques.

## Adverse Effects of Vital Bleaching on Tooth Structure

Tooth hypersensitivity is the most commonly reported adverse effect following vital bleaching.<sup>16,17</sup> Previous studies showed that hypersensitivity is a reversible condition that can last from 4 to 60 days after bleaching. The duration of hypersensitivity depends upon the contact time, concentration of the bleaching agent, and condition of the bleached teeth.<sup>17,18</sup> The irritation or accidental bleaching of oral mucosa is another adverse effect that can occur following the application of the bleaching gel. This problem can be reduced by using the appropriate tissue protection measures (e.g., rubber dam and light-cured and composite-based gingival protectors).

Power bleaching can significantly increase the intrapulpal temperature, particularly during the use of plasma arc and quartz halogen light units.<sup>19,20</sup> Although the elevation of intrapulpal temperature associated with laser photo-activation depends upon the

type of laser. The lowest intrapulpal temperature rising was reported with argon and diode lasers (short activation period [60 seconds]), while the highest was recorded with a CO<sub>2</sub> laser.<sup>19,21</sup> The LED activation method also can produce an elevation of the intrapulpal temperature, but this elevation is still within the acceptable range (below 5.5 °C).<sup>20</sup> Increasing the intrapulpal temperature over the critical threshold (5.5 °C) may lead to irreversible pulpitis and permanent damage of pulp tissues. Histological and morphological studies showed that bleaching agents can alter the topography and histological features of the enamel surface.<sup>22-24</sup> Furthermore, mechanical studies have shown that bleaching reduces the hardness of both enamel and dentin.<sup>25,26</sup>

## Bleaching Map Concept

According to the bleaching map concept, every discolored tooth should be diagnosed and treated as a separate case, with careful monitoring of the distribution and degree of saturation of the stain as well as the regions of normal sound tooth structure. A bleaching map should be drawn for each tooth prior to bleaching, demarcating the deeply, moderately, and intermediately stained as well as sound tooth regions.

## Rationale for Using the Focal Bleaching Technique

After reviewing the historical development of bleaching techniques, the author found that in-office vital bleaching technique was introduced to manage the inter-arch color variation of teeth (i.e., the discoloration does not involve all the teeth of the dental arch). However, it is not able to manage the intra-tooth color variation (i.e., the variability of color within the tooth itself). Power in-office vital bleaching provides a great advantage in limiting the application of the bleaching gel to the affected areas only (the FBT). This selective application cannot be achieved with a dentist-supervised home bleaching technique. A home bleaching technique requires applying the bleaching agent on the entire tooth surface, which results in lightening the color of both stained and normal tooth areas at the same level. This unselective whitening decreases the ability of the human eye to recognize the color difference before and after the treatment. Therefore, the FBT expands the bleaching from a conventional process of shade lightening to a systematic balancing of color between the stained and the normal tooth regions.

Feinman’s classification was simple and he assumed distinct borders between the different staining degrees; however, most of the clinical cases showed complex combinations of staining, which consequently increased the complexity of treatment. This led to an increase in the demand for using selective bleaching protocols for treatment of such complicated clinical situations. Moreover, Feinman reported that “bleaching will lighten the teeth, but only relative to the initial color, so that striated discoloration will be less discolored but still striated.”<sup>15</sup> This represents the most difficult challenge during treatment of banding discoloration with conventional bleaching techniques. However, if the selective FBT is

“A bleaching map should be drawn for each tooth prior to bleaching, demarcating all deeply, moderately, and intermediately stained as well as sound tooth regions.”

applied, a marked reduction in demarcation between treated and sound regions will be achieved.

Previous bleaching protocols recommended performing a professional tooth cleaning, using micro brushes and abrasive diamond pastes prior to the bleaching process. This professional cleaning is performed to remove the extrinsic stains and surface fluoride-reach zone of enamel, which may reduce the effect of the bleaching agent on the tooth substrate.<sup>14,27</sup> However, using FBT limits the cleaning process to the stained areas only; this preserves the surface fluoride-reach zone, which plays a great role in caries prevention.

Furthermore, FBT decreases the biological, histological, and mechanical adverse effects of bleaching agents on tooth substrate. It also decreases the quantity of the bleaching agent, which consequently reduces the postoperative hypersensitivity, adverse effects on the pulp, and irritation of the mucosal tissues. Use of FBT also reduces the hazards of enamel cracking and infraction resulting from the non-essential application of the bleaching solution on the sound tooth areas. Studies have demonstrated that bleaching decreases the tensile and shear strength of the enamel surface.<sup>28,29</sup> Therefore, in cases of pitting fluorosis, which require a combination of bleaching and veneering treatments, FBT will help in maintaining good bonding to the bleached surface, due to the presence of remaining unbleached enamel surfaces.

## FBT Protocol

The following section will demonstrate a step-by-step procedure for treating a clinical case of opaque fluorosis (combined with brown discoloration) using the FBT and guided with bleaching map (Figs 1-4). Thirty percent hydrogen peroxide gel (WHITEsmile GmbH; Birkenau, Germany) was used and photo-activated with an LED photo-activation bleaching unit (DY410-B LED whitening light, Denjoy Dental; Changsha, Hunan, China). Region “a” was treated by applying bleaching gel three times successively for 20 minutes per application. Region “b” was treated by applying the gel twice (20 minutes each time). The gel was applied on region “c” just once for 20 minutes. Gel was not applied on the sound tooth surface of region “d.”

## Informed Consent and Professional Cleaning Process

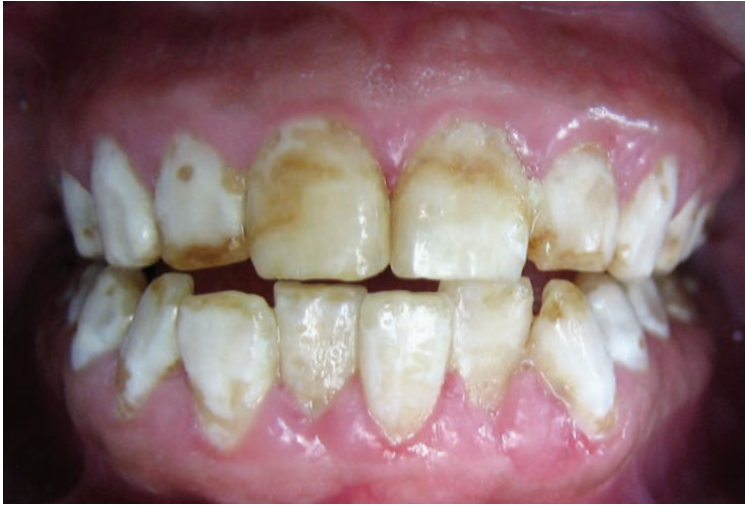In accordance with medical ethics, the entire treatment procedure should be discussed in detail with the patient; then a written informed consent should be signed by the patient before the initiation of treatment. This consent should include a statement that mentions the possibility of transient hypersensitivity of the bleached teeth and mild irritation of gingival tissues after treatment. It also should state that, if the patient’s photographs are to be used in scientific publications or professional advertisements, they will be cropped to feature only the teeth. It also should state that the patient has the right to prohibit publication of these images. The stained areas of the discolored teeth should be selectively cleaned using a fine micro brush and dental prophylaxis cleaning paste without extending into sound tooth areas.

## Treatment Planning

A standardized preoperative photograph should be taken 70 cm away from the patient at the level of the occlusal plane under ordinary white fluorescent light conditions (without using the dental unit light). This photograph will be used as the baseline of the treatment, and a raw photo for drawing the bleaching map (Fig 1). The clinician should, for each tooth, carefully demarcate the normal tooth areas and mark them with the letter “d.” Then, the most deeply stained regions should be marked with the letter “a.” This should be followed by demarcating the moderately and intermediately stained regions with the letters “b” and “c,” respectively (Fig 2). Finally, the clinician should state the treatment plan for each tooth separately, determining the number of gel applications and the bleaching time for each specific discolored area (Fig 2).

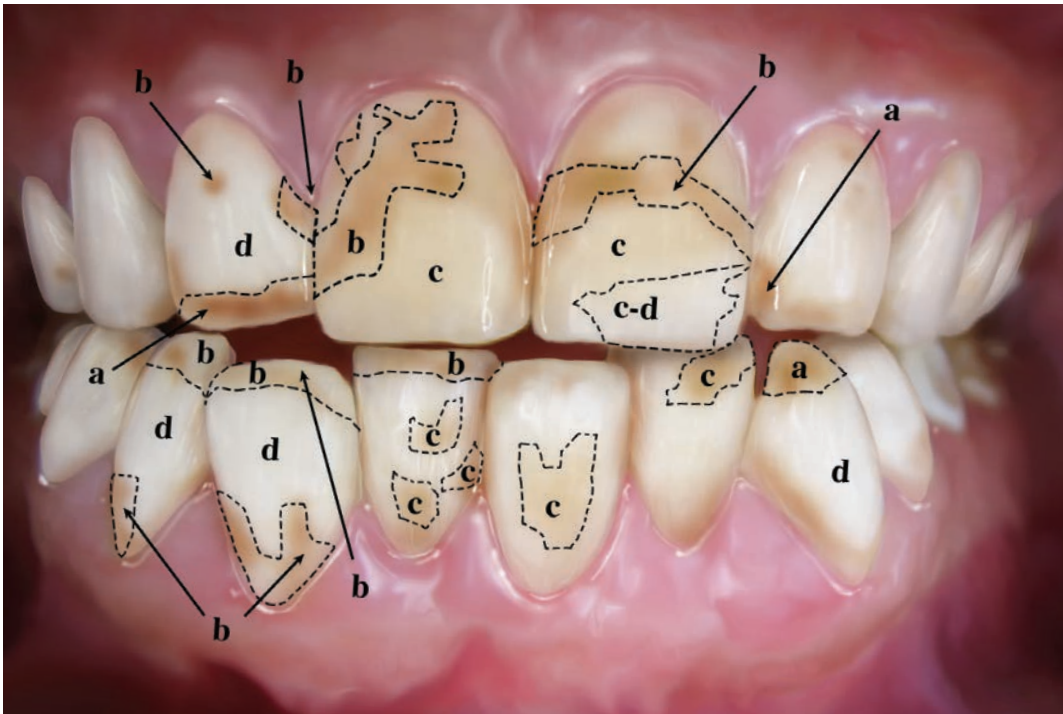
## Definitive Treatment

Tissue-protecting measures should be taken; it is a well-established rule of bleaching and also recommended by the author to use a rubber dam and light-cured, resin-based gingival protectors. The bleaching agent should be applied on the target areas and then photo-accelerated using an appropriate photo-activation method. It is recommended to perform the bleaching in a multi-step process (Fig 3), starting from the most discolored region (a) until reaching the intermediately discolored areas (c). After completing treatment, another postoperative standardized photograph should be taken under the same previously mentioned conditions and compared to the baseline photograph (Fig 4). At this stage, the clinician should be able to determine the areas of persistent stain and decide whether another bleaching session is needed, taking into consideration the patient’s satisfaction level. If the clinician decides to terminate the treatment, an anti-hypersensitivity gel should be applied on the tooth surface to reduce post-bleaching sensitivity. Finally, the patient should be given post-bleaching instructions and scheduled for a recall visit.



**Figure 1:** Preoperative view of a case of opaque fluorosis combined with brown discoloration treated with the “power focal in-office vital bleaching” protocol.

According to the bleaching map concept, every discolored tooth should be diagnosed and treated as a separate case, with careful monitoring of the distribution and degree of saturation of the stain as well as the regions of normal sound tooth structure.



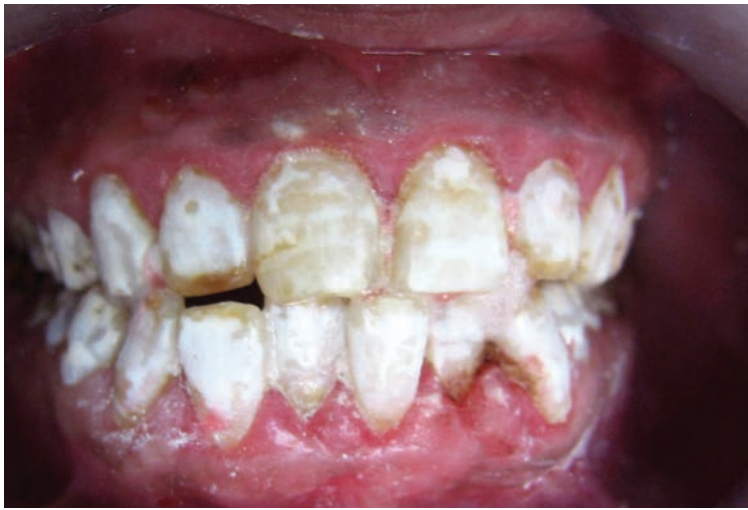**Figure 2:** A “bleaching map” was drawn during the treatment-planning phase. (a) Deeply stained, (b) moderately stained, (c) intermediately stained, and (d) sound tooth regions.

“ FBT decreases the biological, histological, and mechanical adverse effects of bleaching agents on tooth substrate. ”

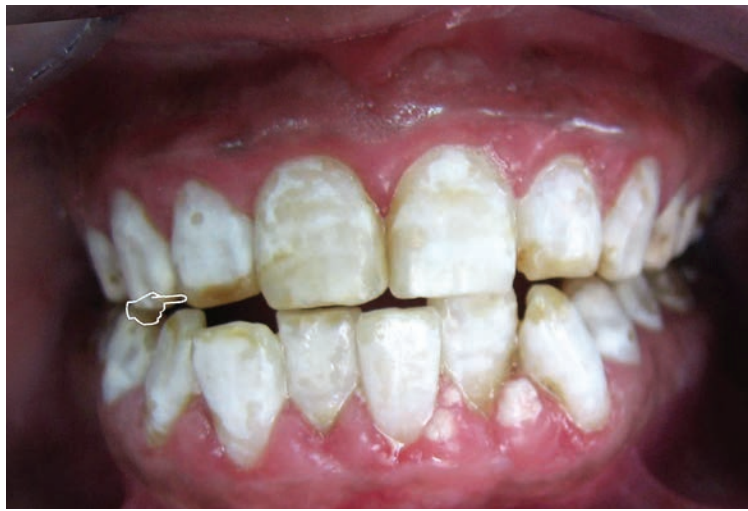### Challenges and Management of Persistent Stain Regions

Patients should be informed that the FBT does not guarantee a 100% success rate for removal of the stain; however, it can provide the maximum benefits with the least hazards. As with any other bleaching technique, the clinician should be able to determine the treatment endpoint, at which time the stain is considered persistent and an alternative form of treatment should be pursued. One of the acceptable alternative treatment modalities for bleaching-persistent areas is enamel microabrasion. This technique is performed by applying acidic water-soluble microabrasive gel (fine abrasive paste with hydrochloric [HCL] acid suspension) on the bleaching-persistent areas using silicone carbide rubber cups (or brushes) mounted to a rotary low-speed handpiece.<sup>30-32</sup> The low HCL concentration, fine abrasive particles, and gel nature of the microabrasion agent control the gel's flow and reduce its scratching effect on the enamel surface.<sup>30</sup>

Although microabrasion is a well-established technique, some authors refused to use enamel microabrasion. This may be due to its adverse effect on the enamel surface<sup>33,34</sup> and the consequences of confining its action to the most superficial enamel layer without penetrating the deep layers.<sup>35</sup> Therefore, the use of FBT preceding microabrasion can also restrict enamel microabrasion to the persistent areas only, which, consequently, reduces the hazards of applying the acidic abrasive gel on the intact sound tooth structure. If the persistent stains are not effectively removed via the aforementioned methods, a direct (or indirect) partial veneering should be the next line of treatment explored; this may achieve more satisfactory results. The selective bleaching protocol may be considered a time-consuming technique, particularly during the preparatory and treatment-planning phases, but this problem can be minimized with more training and practice. The standardization of photographs is another challenge. Therefore, the author recommends that clinicians who are interested in esthetically based treatments should enroll in courses to study the basic principles of dental photography.



**Figure 3:** A marked reduction of the stain can be observed on the deeply and moderately stained regions following the first step of the treatment, in comparison with the baseline stain.



**Figure 4:** Postoperative view of the treated case. The hand pointer shows a bleaching-persistent area; however, the patient's satisfaction rating for this result was 90%, and she preferred to terminate the treatment.

## Summary

The study discussed here revealed that using the focal bleaching technique (FBT), guided with a bleaching map, achieves better results than conventional bleaching methods. Also, the FBT can provide maximum treatment benefits with minimum risks.

## Acknowledgment

*The author is grateful to Professor Richard Simonsen, chairman of the Restorative Sciences Department, Faculty of Dentistry, Kuwait University, Kuwait City, for his advice during the preparation of this article. The author also appreciates the technical support from Mr. Shadow Yeung, The University of Hong Kong, Hong Kong SAR, China.*

## References

1. Wikipedia [Internet]. Aesthetics. Available from: <http://en.wikipedia.org/wiki/Aesthetics>.
2. Qualtrough AJ, Burke FJ. A look at dental esthetics. *Quintessence Int.* 1994 Jan;25(1):7-14.
3. Odioso LL, Gibb RD, Gerlach RW. Impact of demographic, behavioral, and dental care utilization parameters on tooth color and personal satisfaction. *Compend Contin Educ Dent Suppl.* 2000 Jun;(29):S35-41; quiz S43.
4. Buchalla W, Attin T. External bleaching therapy with activation by heat, light, or laser: a systematic review. *Dent Mater.* 2007 May;23(5):586-96.
5. Wetter NU, Barroso MC, Pelino JE. Dental bleaching efficacy with diode laser and LED irradiation: an in vitro study. *Lasers Surg Med.* 2004;35(4):254-8.
6. M'Quillen JH. Bleaching discolored teeth. *Dental Cosmos.* 1866 Apr;8(9):457-9.
7. Abbot CH. Bleaching discolored teeth by means of 30% perhydro and the electric light rays. *J Allied Dent Soc.* 1918;13:259.
8. Ames J, Smithfield V. Removing stains from mottled enamel. *J Am Dent Assoc.* 1937;24:1674-7.
9. Haywood VB, Heymann HO. Nightguard vital bleaching. *Quintessence Int.* 1989 Mar;20(3):173-6.
10. Haywood VB, Leech T, Heymann HO, Crumpler D, Bruggers K. Nightguard vital bleaching: effects on enamel surface texture and diffusion. *Quintessence Int.* 1990 Oct;21(10):801-4.
11. Haywood VB, Heymann HO. Nightguard vital bleaching: how safe is it? *Quintessence Int.* 1991 Jul;22(7):515-23.
12. Haywood VB, Heymann HO. Response of normal and tetracycline-stained teeth with pulp-size variation to nightguard vital bleaching. *J Esthet Dent.* 1994;6(3):109-14.
13. Joiner A. The bleaching of teeth: a review of the literature. *J Dent.* 2006 Aug;34(7):412-9.
14. Greenwall L, Freedman GA. Bleaching techniques in restorative dentistry: an illustrated guide. London: Martin Dunitz; 2001.
15. Feinman RA. Bleaching teeth. Hanover Park (IL): Quintessence Pub.; 1987.
16. Haywood VB, Leonard RH, Nelson CF, Brunson WD. Effectiveness, side effects and long-term status of nightguard vital bleaching. *J Am Dent Assoc.* 1994 Sep;125(9):1219-26.
17. Dahl JE, Pallesen U. Tooth bleaching: a critical review of the biological aspects. *Crit Rev Oral Biol Med.* 2003;14(4):292-304.
18. Fugaro JO, Nordahl I, Fugaro OJ, Matis BA, Mjör IA. Pulp reaction to vital bleaching. *Oper Dent.* 2004 Jul-Aug;29(4):363-8.
19. Baik JW, Rueggeberg FA, Liewehr FR. Effect of light-enhanced bleaching on in vitro surface and intrapulpal temperature rise. *J Esthet Restor Dent.* 2001;13(6):370-8.
20. Coelho RA, Oliveira AG, Souza-Gabriel AE, Silva SR, Silva-Sousa YT, Silva RG. Ex-vivo evaluation of the intrapulpal temperature variation and fracture strength in teeth subjected to different external bleaching protocols. *Braz Dent J.* 2011;22(1):32-6.
21. Convissar RA. Principles and practice of laser dentistry. St. Louis: Mosby Elsevier; 2011.
22. Shannon H, Spencer P, Gross K, Tira D. Characterization of enamel exposed to 10% carbamide peroxide bleaching agents. *Quintessence Int.* 1993 Jan;24(1):39-44.
23. Bitter NC. A scanning electron microscope study of the long-term effect of bleaching agents on the enamel surface in vivo. *Gen Dent.* 1998 Jan-Feb;46(1):84-8.
24. Gjorgievska E, Nicholson JW. Prevention of enamel demineralization after tooth bleaching by bioactive glass incorporated into toothpaste. *Aust Dent J.* 2011 Jun;56(2):193-200.
25. Zimmerman B, Datko L, Cupelli M, Alapati S, Dean D, Kennedy M. Alteration of dentin-enamel mechanical properties due to dental whitening treatments. *J Mech Behav Biomed Mater.* 2010 May;3(4):339-46.



26. Hairul Nizam BR, Lim CT, Chng HK, Yap AU. Nanoindentation study of human premolars subjected to bleaching agent. *J Biomech.* 2005 Nov;38(11):2204-11.
27. Kwon S-R, Ko S-H, Greenwall L. Tooth whitening in esthetic dentistry. Hanover Park (IL): Quintessence Pub.; 2009.
28. Turkun M, Kaya AD. Effect of 10% sodium ascorbate on the shear bond strength of composite resin to bleached bovine enamel. *J Oral Rehabil.* 2004 Dec;31(12):1184-91.
29. Spyrides GM, Perdigao J, Pagani C, Araujo MA, Spyrides SM. Effect of whitening agents on dentin bonding. *J Esthet Dent.* 2000;12(5):264-70.
30. Croll T. Enamel microabrasion. Hanover Park (IL): Quintessence Pub.; 1991.
31. Chhabra N, Singbal KP. Viable approach to manage superficial enamel discoloration. *Contemp Clin Dent.* 2010 Oct;1(4):284-7.
32. Sundfeld RH, Croll TP, Briso AL, de Alexandre RS, Sundfeld Neto D. Considerations about enamel microabrasion after 18 years. *Am J Dent.* 2007 Apr;20(2):67-72.
33. Schmidlin PR, Gohring TN, Schug J, Lutz F. Histological, morphological, profilometric and optical changes of human tooth enamel after microabrasion. *Am J Dent.* 2003 Sep;16 Spec No:4A-8A.
34. Meireles SS, Andre Dde A, Leida FL, Bocangel JS, Demarco FF. Surface roughness and enamel loss with two microabrasion techniques. *J Contemp Dent Pract.* 2009 Jan 1;10(1):58-65.
35. Khatri A, Nandlal B. An indirect veneer technique for simple and esthetic treatment of anterior hypoplastic teeth. *Contemp Clin Dent.* 2010 Oct;1(4):288-90. **JCD**

“ Use of FBT also reduces the hazards of enamel cracking and infraction resulting from the non-essential application of the bleaching solution on the sound tooth areas. ”



Dr. Hamama earned a Master of Dental Science degree in operative dentistry and endodontics from the Faculty of Dentistry, Mansoura University, Dakahliya, Egypt, where he also is an assistant lecturer in the Department of Conservative Dentistry. He can be contacted at [hamdy@connect.hku.hk](mailto:hamdy@connect.hku.hk)

Disclosure: The author did not report any disclosures.

# Analysis

## Discussion Points

### Focal Bleaching Technique: Determining Stain Distribution by Creating a “Bleaching Map”

*This analysis is regarding the article, Focal Bleaching Technique: Determining Stain Distribution by Creating a “Bleaching Map,” by Hamdi H. Hamama, BDS, MDS.*

By Gary M. Radz, DDS, FACE

Today’s in-office whitening treatments provide dental professionals with opportunities to enhance their patients’ smiles in a minimally invasive way. They are fast, effective, and more comfortable for patients than earlier options. The bleaching map concept presented by Dr. Hamama, when used with a focal bleaching technique (FBT), can be an approach for planning the whitening process when regions of staining within a tooth are markedly varied, as well as when the level of discoloration is varied between teeth.

The FBT protocol described in the article for assessing areas of intra-tooth discoloration may benefit from the use of a combination of the subjective and objective tools available to determine tooth color. These tools also can be beneficial for measuring the extent of the whitening achieved from the FBT procedure, without risk of observer bias or fatigue.<sup>1</sup> Subjective tools include shade guides, and objective tools include spectrophotometry, which is a digital method for objectively assessing color change.<sup>2</sup>

Eliminating the influence of observer experience, external light, and the observer’s physiological condition by using a combination of shade-taking methods likely could facilitate the accurate identification and differentiation between those areas of discoloration that Dr. Hamama terms “deeply stained,” “moderately stained,” and “intermediately stained.” This is because spectrophotometry is not influenced by lighting conditions or user characteristics.

Accurately performing the bleaching map treatment planning tooth by tooth, as well as within a given tooth, will help to ensure the proper number of bleaching gel applications and correct light-activation times. Using the tools following the whitening procedure also will eliminate potential observer bias and provide a more accurate post-whitening shade change evaluation.

However, Dr. Hamama admits that FBT may be time consuming, and that, as with other tooth whitening methods, it may not be effective when treating persistent stains. Dentists may therefore wish to understand the optical properties of the stains being treated, as well as the mechanisms of action of the light-accelerated bleaching gel and the lights used to activate it. This will help to ensure that the appropriate gel is applied for an effective length of time, and is activated with a complementary light source for maximum effectiveness and patient safety.<sup>2,3</sup> **JCD**

## References

1. Kalloniatis M, Luu C. The perception of color. In: Kolb H, Fernandez E, Nelson R, editors. *Webvision: The organization of the retina and visual system* [Internet]. Salt Lake City (UT): University of Utah Health Sciences Center; 1995. [updated 2007 Jul 09].
2. Joiner A. Tooth colour: a review of the literature. *J Dent.* 2004;32 Suppl 1:3-12.
3. Kwon SR, Oyoyo U, Li Y. Effect of light activation on tooth whitening efficacy and hydrogen peroxide penetration: an in vitro study. *J Dent.* 2012 Dec 20.



Dr. Radz is a clinical associate professor in the Department of Restorative Dentistry, University of Colorado School of Dentistry. Dr. Radz maintains a practice in Denver, Colorado.

# AACD Self-Instruction Continuing Education Information



## General Information

This continuing education (CE) self-instruction program has been developed by the American Academy of Cosmetic Dentistry (AACD) and an advisory committee of the *Journal of Cosmetic Dentistry*.

## Eligibility and Cost

The exam is free of charge and is intended for and available to AACD members only. It is the responsibility of each participant to contact his or her state board for its requirements regarding acceptance of CE credits. The AACD designates this activity for 3 continuing education credits.

## Testing and CE

The self-instruction exam comprises 10 multiple-choice questions. To receive course credit, AACD members must complete and submit the exam and answer at least 70% of the questions correctly. Participants will receive test results immediately after taking the examination online and can only take each exam once. The exam is scored automatically by the AACD's online testing component. The deadline for completed exams is one calendar year from the publication date of the issue in which the exam appeared. The exam is available online at [www.aacd.com](http://www.aacd.com). A current web browser is necessary to complete the exam; no special software is needed.

Note: Although the AACD grants these CE credits, it is up to the receiving governing body to determine the amount of CE credits they will accept and grant to participants.

## Verification of Participation (VOP)

VOP will be sent to AACD members via their MyAACD account upon pass completion. Log onto [www.aacd.com](http://www.aacd.com) to sign into your MyAACD account.

For members of the Academy of General Dentistry (AGD): The AACD will send the AGD proof of your credits earned on a monthly basis. To do this, AACD must have your AGD member number on file. Be sure to update your AGD member number in your AACD member profile on [MyAACD.com](http://MyAACD.com).


All participants are responsible for sending proof of earned CE credits to their state dental board or agency for licensure purposes.

## Disclaimer

AACD's self-instruction exams may not provide enough comprehensive information for participants to implement into practice. It is recommended that participants seek additional information as required. The AACD Self-Instruction Program adheres to the guidelines set forth by the American Dental Association Continuing Education Recognition Program (CERP), and the AGD Program Approval for Continuing Education (PACE).

## Questions and Feedback

For questions regarding a specific course, information regarding your CE credits, or to give feedback on a CE self-instruction exam, please contact the AACD Executive Office by e-mailing [meetings@aacd.com](mailto:meetings@aacd.com) or by calling 800.543.9220 or 608.222.8583.



ADA CERP is a service of the American Dental Association to assist dental professionals in identifying quality providers of continuing dental education. ADA CERP does not approve or endorse individual courses or instructors, nor does it imply acceptance of credit hours by boards of dentistry. AACD designates this activity for 3 continuing education credits. Concerns or complaints about a CE provider may be directed to the provider or to ADA CERP at [www.ada.org/goto/cerp](http://www.ada.org/goto/cerp).

The 10 multiple-choice questions for this Continuing Education (CE) self-instruction exam are based on the article, "Focal Bleaching Technique: Determining Stain Distribution by Creating a 'Bleaching Map,'" by Dr. Hamdi H. Hamama. This article appears on pages 128-136.

The examination is free of charge and available to AACD members only. AACD members must log onto [www.aacd.com](http://www.aacd.com) to take the exam. **Note: Only Questions 1 through 5 appear in the printed and digital versions of the jCD; they are for readers' information only.** The complete, official self-instruction exam is available online only—completed exams submitted any other way will not be accepted or processed. A current web browser is necessary to complete the exam; no special software is needed. The AACD is a recognized credit provider for the Academy of General Dentistry, American Dental Association, and National Association of Dental Laboratories. For any questions regarding this self-instruction exam, call the AACD at 800.543.9220 or 608.222.8583.

1. The key difference between the focal bleaching technique (FBT) and conventional bleaching is that
  - a. white demineralized areas will bleach faster and become whiter with the FBT.
  - b. conventional bleaching allows all shades of teeth to bleach equally well.
  - c. FBT seeks to balance the color between stained and normal tooth regions.
  - d. conventional bleaching only works on age-related tooth darkening.
2. The "bleaching map" employed with the FBT is used mainly to
  - a. review the treatment with the patient and lab technician.
  - b. show the patient areas that will not respond to treatment.
  - c. review the expected speed and outcome of the treatment.
  - d. guide the systematic balancing of color of the affected teeth.
3. When nightguard vital bleaching was introduced in 1989, the procedure was indicated for
  - a. dentist-supervised home bleaching.
  - b. chairside application of highly concentrated bleaching agents.
  - c. accelerated bleaching with the use of a specialized tray and a photo-initiator.
  - d. accelerated bleaching in-office using external photo-activation.
4. Incorporation of light-activation technology into dental bleaching techniques
  - a. decreases the harmful effects of bleaching agents but increases the treatment time.
  - b. decreases the harmful effects of bleaching agents and reduces the treatment time.
  - c. requires the use of a specialized custom tray and a photo-initiator.
  - d. increases the speed of both at-home and in-office power bleaching.
5. The goal of dental bleaching is to
  - a. remove or dilute the effect of intrinsic stains to the general shade of the tooth.
  - b. remove or dilute the effect of extrinsic stains to the general shade of the tooth.
  - c. reverse staining caused by the systemic intake of dark-colored beverages or smoking.
  - d. eliminate stains that cannot be removed via routine prophylactic cleaning.

**To see and take the complete exam, log onto [www.aacd.com](http://www.aacd.com).**