

Principles of Smile *Demystified*

A 3D rendering of a dental articulator, a mechanical device used to study the movements of the jaw and teeth. The device is shown in a light blue color with various adjustment screws and levers. A hand shadow is visible on the left side, suggesting the device is being held or adjusted. A large, thin black arc is drawn across the bottom of the image, representing a smile arc. The background is white.

Design—

Saiesha Mistry, BDS, MSc
Illustrations by Zach Turner

Abstract

A comprehensive treatment plan is incomplete without an esthetic analysis or smile design defining the end point of the treatment. To obtain consistently high-quality results, it is necessary to methodically analyze the features that the evaluation comprises. Collection of data and precise utilization of various parameters helps to provide a systematic and guaranteed result. This article discusses details of facial analysis and offers a step-by-step sequence for smile design to provide predictable, esthetic results.

Key Words: smile design, facial analysis, esthetic parameters

Introduction

Esthetic dentistry has gone beyond the realm of pure esthetics to become an integral part of the treatment plan. Esthetic analysis or smile design that defines the end point of the treatment is critical. This helps to ensure that the outcome we provide will not only be biologically and functionally successful, but esthetically successful as well.

Today a smile design not only means designing teeth, but also creating a smile that truly complements the patient's face and personality. Following this philosophy, smile design starts with an analysis of the face, then moves to the smile and to the teeth themselves.¹

Keeping this principle in mind, recreating a smile need not be limited to the six anterior teeth, but may extend to include the posterior teeth. The number of teeth involved in the esthetic treatment plan will depend upon the patient's facial and dental esthetic analysis. It is therefore imperative to integrate the esthetic parameters with the functional parameters of the occlusion. The incisal edge and the occlusal plane must be symmetrical and pleasing in appearance, and the form should follow the principles of occlusion to ensure overall health of the dentition. The design of the maxillary and mandibular anterior teeth must attempt to establish an anterior guidance, which will disclude the posterior teeth during protrusive and lateral excursive movements. This is important to ensure longevity and success of the anterior restorations.

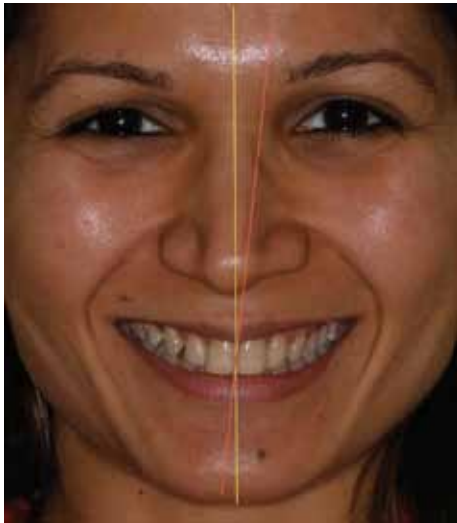


Figure 1: Facial analysis in the frontal plane, relating the facial midline with the midline of the central incisors.

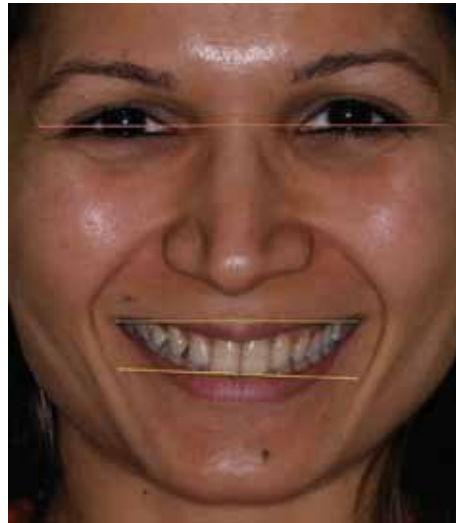


Figure 2: Facial analysis in the frontal plane, showing horizontal parameters relating the inter-pupillary line to the incisal edge position.

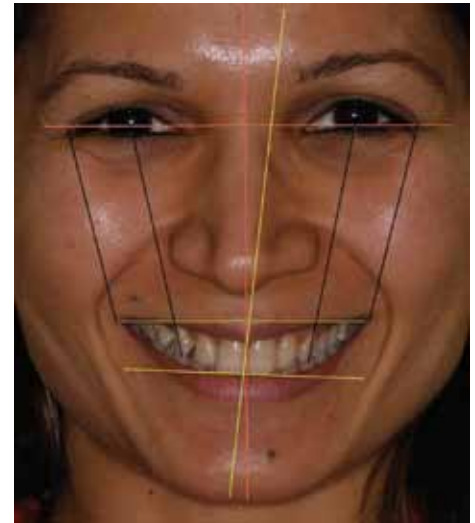


Figure 3: A full-facial analysis using lines to assess parallelism and hence synergy in the various components of the face as related to the smile.

Facial Analysis

The facial analysis involves an assessment of the face as a whole. This analysis is done in two planes: the frontal and the sagittal. In the frontal view the main feature we look at would be the facial midline, which aids in evaluating the symmetry of the face or the lack thereof. There are a number of different opinions on how the midline should be plotted, the most common one being from the glabella to the middle of the philtrum. This is connected to the midline of the smile, creating a relationship between the face and the smile (Figs 1-3). In the sagittal plane we look at the Ricketts esthetic plane (E-plane), formed between the tip of the nose and the tip of the chin (Fig 4). Another parameter is the nasio-labial angle, formed by the base of the nose and the upper lip (Fig 5). These parameters provide information regarding the prominence of the anterior segment and the premaxilla and are instrumental in determining the position of the incisors in the labio-lingual plane while designing the smile. Thus we evaluate the relationship of the features to each other and to the smile.

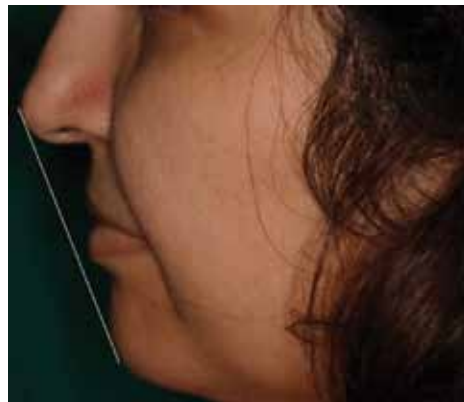

Figure 4: Facial analysis in the sagittal plane: The Ricketts E-plane connects the tip of the nose to the chin prominence. Average distance from the upper lip is 4 mm; and from the lower lip, 2 mm.

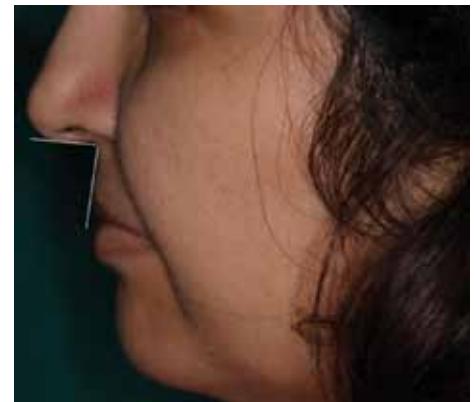

Figure 5: Facial analysis in the sagittal plane: The nasio-labial angle is determined by the base of the nose and the upper lip. The average angle for males is 90 to 95 degrees; for females, 100 to 105 degrees.

Today a smile design not only means designing teeth, but also creating a smile that truly complements the patient's face and personality.

Smile and Dental Analysis

The smile analysis comprises details of the lips and the teeth and gums as a unit. The dental analysis provides insight into characterization and individuality of the teeth.

Details of the factors that come into play in these various analyses have been well documented and can be found in articles and books on esthetic dentistry.²

What often becomes confusing (and therefore, haphazard) is how to use all the data. By following the systematic approach detailed below using the parameters that have been observed during the various analyses, dentists will have a technique to consistently execute a successful smile design.



Figure 6: The full face—the starting point of the smile design.

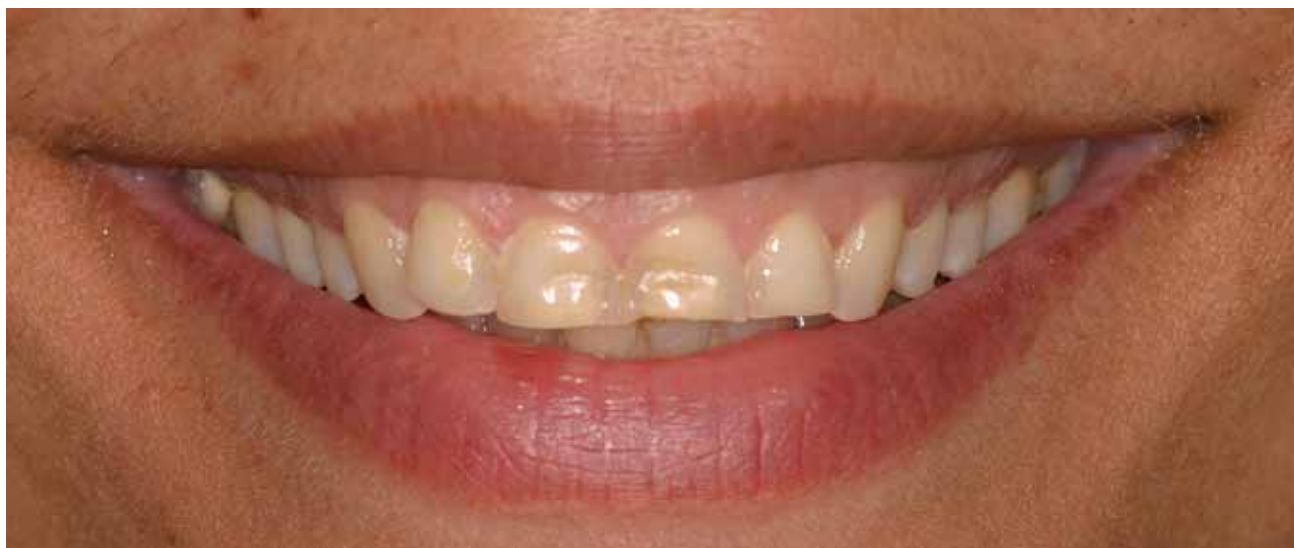

Figure 7: Dentofacial view. The focus is now on the smile itself.

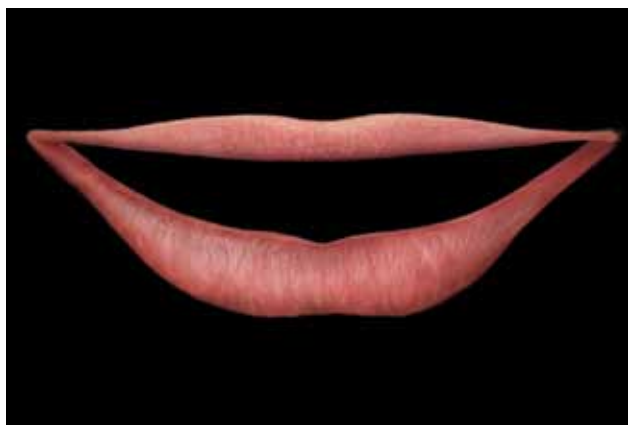

Figure 8a: Define the lips, which form the framework of the smile to be designed. The components are filled in per the smile analysis.

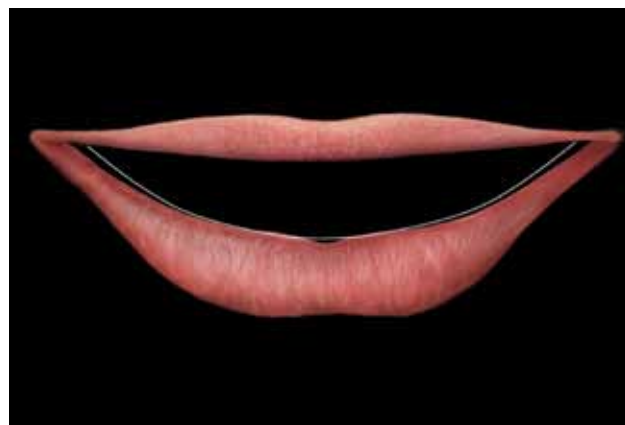

Figure 8b: Establish the Incisal edge position using the interpupillary line, phonetics, and the lip line as guides.

Smile Design Sequence

Start with the full face (Fig 6) and then narrow it down to the smile (Fig 7). Now eliminate all the elements within the smile and use the lips as a frame for a clean slate. Then start designing the smile (Fig 8a).

Step 1: Establish the Incisal Edge Position

The incisal edge position determines the actual shape of the incisal edge and is the best place to start designing the smile. To connect this smile parameter with the face, the incisal edges of the centrals should be made parallel to the inter-pupillary line, so as to relate the smile to the patient's overall facial esthetic. The curve then created by the incisal edges of the lateral incisors and canines should follow the contour of the lower lip. This provides synergy in lines and hence a more attractive picture (Fig 8b).

When considering the incisal edge, we also need to determine the length of the teeth (called tooth reveal). The greater the amount of tooth visible while the lips are at rest, the younger looking the smile will appear.^{3,4} Having the patient repeat the "M" sound will provide an insight into the amount of tooth visible, and the amount that can be increased so as to provide the appearance of youth (Fig 9).

The labio-lingual plane positioning of the labial surface of the anterior teeth provides the lip support. Increase in the cervical third of the labial surface bulks out the maxillary lip and is dependent upon the sagittal analysis done of the face. The incisal edge position is determined using phonetics. The patient's use of the "F" and "V" sounds helps place the incisal edge in the correct relationship to the vermilion border of the lips so

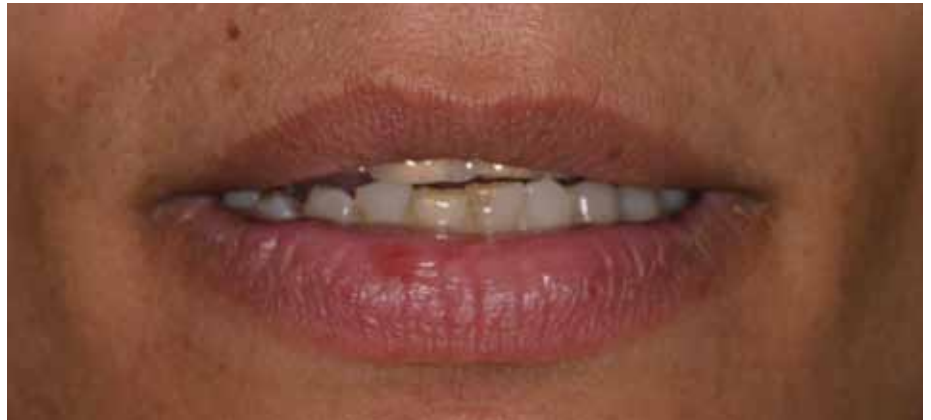

Figure 9: The use of phonetics and the "M" sound help to determine the position of the lips at rest. The amount of tooth visible in this position is important as a baseline for designing the smile. The more tooth visible, the younger the look.

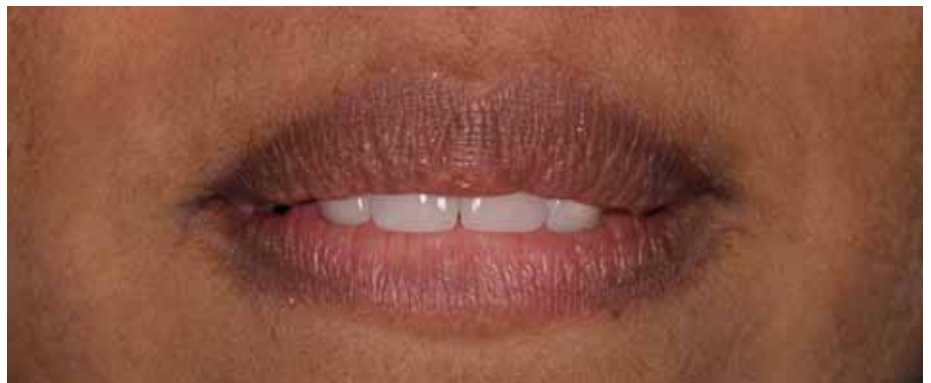

Figure 10a: Use of phonetics to evaluate the location of the incisal edge position. The incisal edges of the maxillary anterior teeth should fall on the vermilion or wet/dry border of the lower lip.

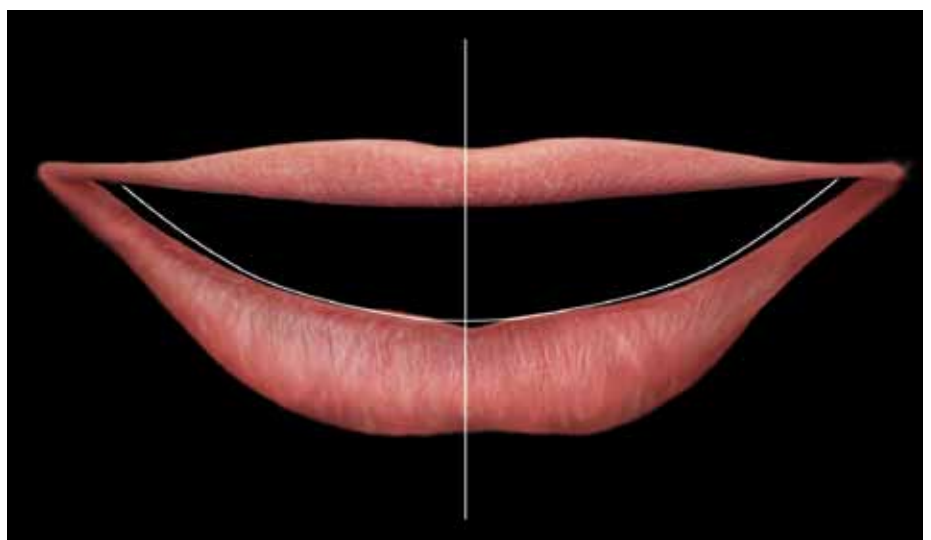

Figure 10b: Develop midline symmetry and align the dental midline to that of the face. This line should be perpendicular to that of the incisal edge position.

as to enhance esthetics without affecting function (Fig 10a).

Step 2: Develop Midline Symmetry

The next parameter to plot is the midline (Fig 10b). This determines where the central incisors should be located. The midline between the centrals is related to the facial midline. An ideal esthetic situation is one where the midline of the face and the teeth are coincident. However, Kokich has shown that as long as the lines are parallel, a displacement of up to 4 mm is not noticeable to the layperson. The least esthetic look is when the dental midline is canted and at an angle to the facial midline.⁵

Step 3: Establish the Gingival Margin

The gingival margin becomes the third parameter in the smile design process. Calculating the tooth dimensions plots the location of the gingival margin. We use individual tooth proportions and the width:length ratio for the teeth (Fig 11). An ideal tooth would have a width that is 78% that of the length. For smile design purposes, teeth with a 75 to 80% ratio fall well within the esthetic category. During the smile analysis, the space calculation is done depending upon whether we need to eliminate crowding or close spaces. Based on the widths determined, we can calculate the most appropriate length. With the incisal edge position already determined, the gingival margin forms the other dimension at the length calculated. Using the concept of the gingival esthetic line, the gingival zenith of the canines and centrals are plotted along the same plane and those of the laterals kept a millimeter shorter for the most esthetic appearance (Fig 12).⁶

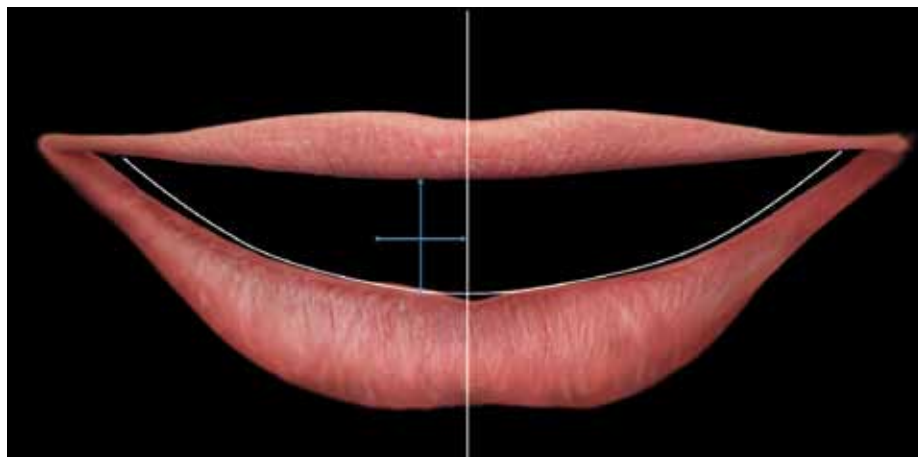


Figure 11: Based on the space available, calculate the length of the teeth using the width:length ratio of 78%.

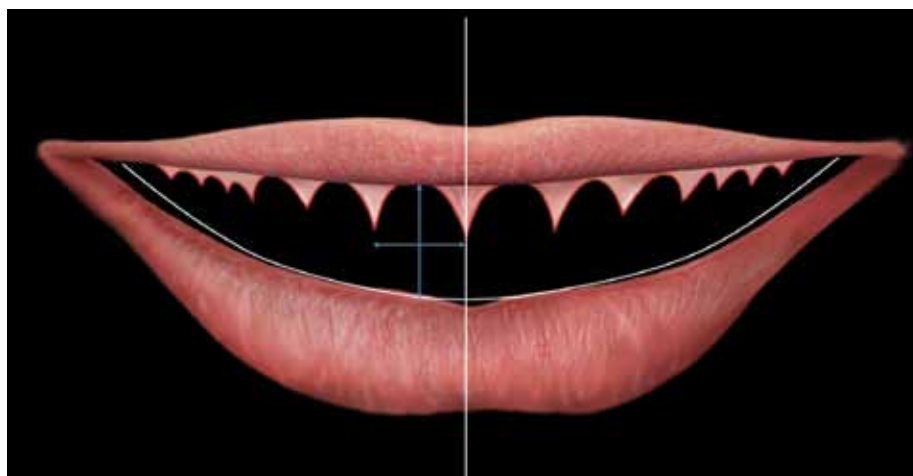


Figure 12: Once the gingival zenith of the central incisors has been plotted, design the gingival esthetic line based upon the esthetic parameters.

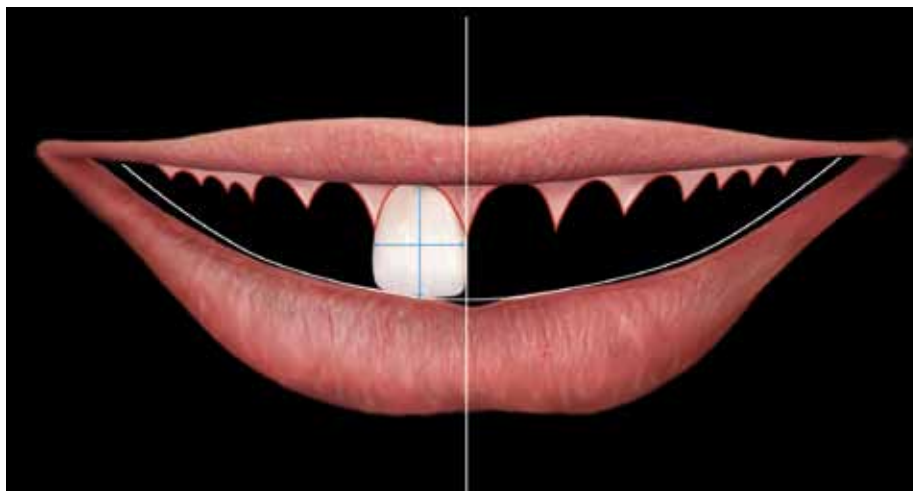


Figure 13: The position of the central incisors is determined using the facial midline as a guide. The size depends on the space analyses and the tooth proportions of 78%.

Step 4: Create Silhouette Form of the Central Incisors

Having established the three parameters for the location and size of the central incisors, we now create the silhouette form of the teeth. The centrals being the most dominant part of the esthetic zone should provide symmetry in the midline (Fig 13). Having calculated the size of one of the centrals, we duplicate that and create a mirror image for the other central, thus creating symmetry in the midline for effective balance of the two sides (Fig 14).

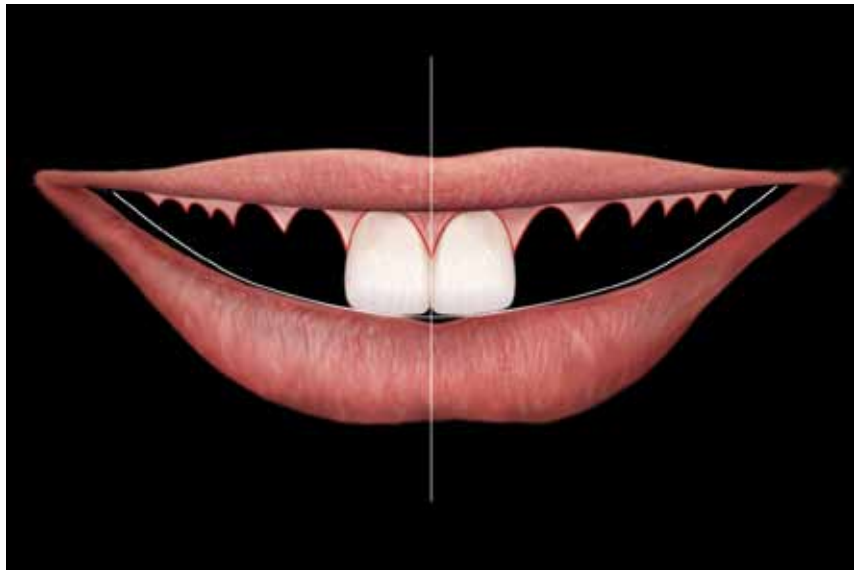
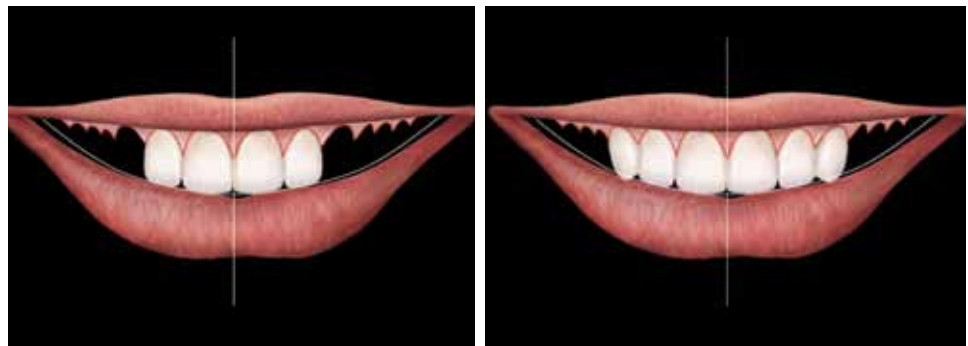


Figure 14: In order to create midline symmetry, the central incisors should be mirror images of each other.

Step 5: Develop Relative Proportions of Lateral Incisors and Canines

This step involves designing the other components of the anterior esthetic zone. Here we use proportion tools, which have been discussed in various journals.^{7,8} The “golden proportion” provides an approximately 62% ratio between the centrals, laterals, and canines (with only the mesial aspect of the canines being taken into consideration). The “recurring esthetic dental proportion” ensures that a consistent proportion exists between all the teeth. The “golden percentage” uses the entire esthetic segment as 100% and places the centrals at 50%, the laterals at 30%, and the canines at 20% of the whole (Figs 15a & 15b). Any number of rules can be followed to ensure that this relevant segment fits in with the golden proportion for the most esthetic relationship between the teeth.



Figures 15a & 15b: The size of the lateral incisors and canines are determined so as to maintain relative proportions to each other and the centrals. We can use principles of tooth proportions, the “golden proportion,” and the various other proportion tools defined for the anterior segment. The aim is to create radiating lateral harmony.

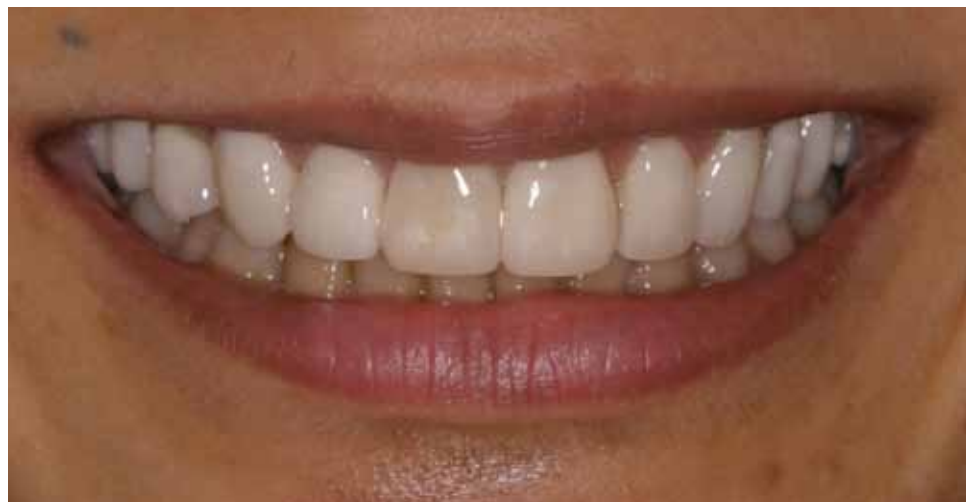

Figure 16: Buccal corridor encroached upon by the teeth, leaving no contrast in color between the teeth, tissues, and space.

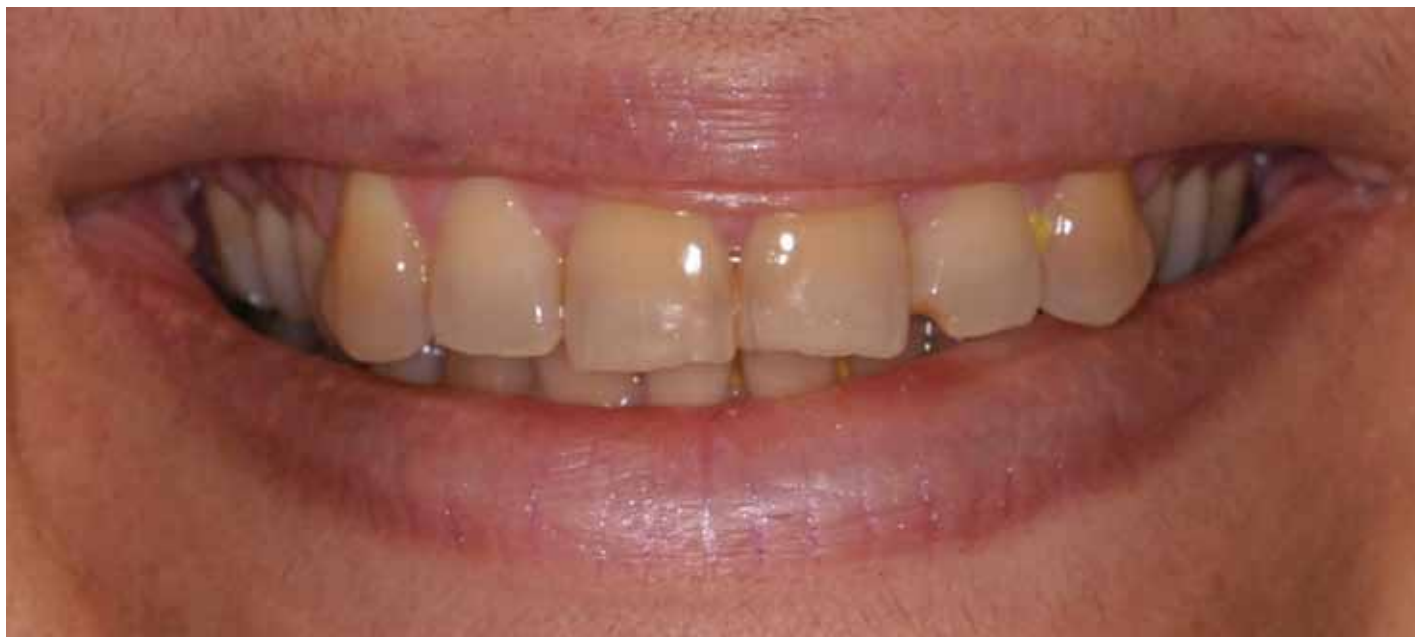

Figure 17: Prominent anterior segment with depressed posteriors gives the impression of an empty, "hollow" smile.

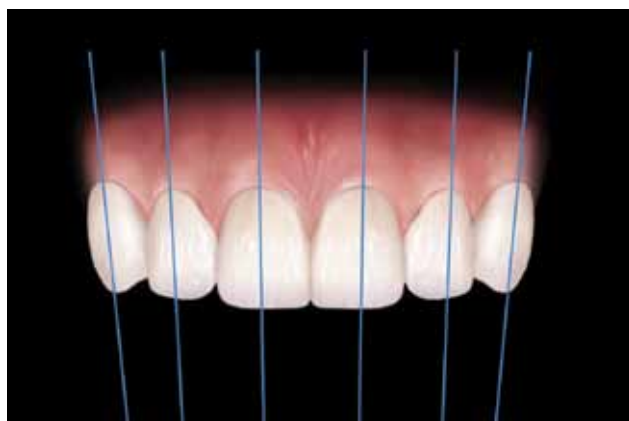


Figure 18: Axial inclinations of the teeth should be medially directed for a more esthetic and pleasing appearance.

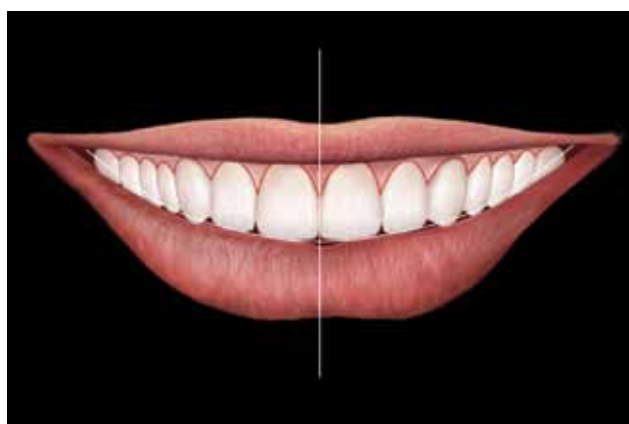

Figure 19: Eliminate the dark corridors of the smile, paying attention to the vertical parallelism and medial axial inclinations.

Step 6: Extend the Smile Into the Corners

Once the esthetic zone has been designed to fit a patient's face, we move posteriorly and fill in the corners of the mouth. The dark buccal corridors are evaluated and filled in so as to create a perfect balance between the white of the teeth, the pink of the tissues, and the black of the space. Over-filling these spaces creates a very toothy appearance (Fig 16) and excess space gives the impression of an empty smile (Fig 17). The teeth are also aligned and their axial inclinations are modified so as to be inclined toward the midline for a more cohesive appearance to the full mouth (Figs 18 & 19).

Step 7: Design the Shape and Texture of Individual Teeth

Once all the teeth have been placed and sized correctly, we can design the finer points of the esthetics as well as the teeth themselves.

Here we establish the contact points or areas and design embrasures to create a smile that suits the individual's age, gender, and personality. Shade and characterization of the teeth are determined to create a result (Fig 20) that can be "Hollywood white" or more natural, depending upon the patient's wants and needs.

Summary

By following the systematic approach described here, designing a smile becomes predictable and easy. The details are in the collection of data and then using the data exactly where required to achieve a beautiful smile (**Fig 21**). Once this has been accomplished, it is a matter of interacting with practitioners from the various disciplines of dentistry to create a plan that will realize the end point we have already designed.

References

1. McLaren AE, Rifkin R. Macroesthetics: facial and dentofacial analysis. *J Calif Dent Assoc.* 2002;30(11):839-46.
2. Rufenacht C. *Fundamentals of esthetics.* Hanover Park (IL): Quintessence Pub.; 1990.
3. Vig RG, Brundo GC. The kinetics of anterior tooth display. *J Prosthet Dent.* 1978;39(5):502-4.
4. Morley J, Eubank J. Macroesthetic elements of smile design. *J Am Dent Assoc.* 2001;132(1):39-45.
5. Kokich VO, Kiyak HA, Shapiro PA. Comparing the perception of dentists and lay people to altered dental esthetics. *J Esthet Dent.* 1999;11:311-24.
6. Ahmad I. Geometric considerations in anterior dental esthetics: restorative principles. *Pract Periodont Aesthet Dent.* 1998;10(7):813-22.
7. Sulikowsky A, Yoshida A. Three-dimensional management of dental proportions: a new esthetic principle: "the frame of reference." *QDT.* 2002;25:8-20.
8. Fayyad MA, Jamani KD, Agrabawi J. Geometric and mathematical proportions and their relations to maxillary anterior teeth. *J Contemp Dent Practice.* 2006;7(5):62-70. **JCD**

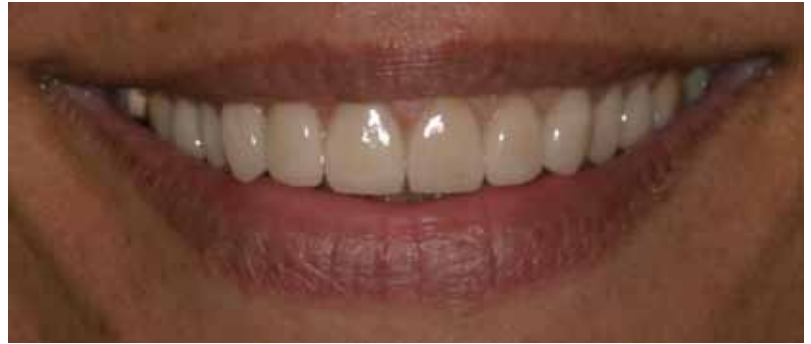

Figure 20: Characterization of the teeth is now developed. Embrasure spaces, contact points and contact areas, color, and translucency are all finalized to complete the smile.



Figure 21: All the features of the smile coming together to complement the patient's face.



Dr. Mistry has a private practice in Mumbai, India.

Disclosure: The author did not report any disclosures.