"CPR" for the Worn Dentition: from Concept to Prototype to Restoration

Dennis Hartlieb, DDS, AAACD

Abstract

Management of the patient with worn dentition is a challenge faced by many restorative dentists. The etiology of wear appears to be multifactorial and the occurrence of wear cases seems to be increasing. The traditional strategy of employing a preoperative wax-up followed directly by preparing the teeth for definitive restorations means the dentist is not able to test the planned occlusal and esthetic changes until after tooth preparation is completed. Unfortunately, in this scenario, patients may be dissatisfied with irreversible changes in tooth length, form, and contour. This article discusses a treatment technique that employs direct resin bonding in a no-preparation, reversible manner. The direct bonded restorations serve as a prototype, permitting the dentist to work out esthetic, occlusal, functional, and phonetic issues with the patient before the teeth are irreversibly prepared, thus allowing far more predictable definitive restorations. The philosophy of concept to prototype to restoration (or "CPR") enables the restorative dentist to treat the wear patient in a safe, reversible manner. The uses for a prototype restoration and how it differs from a temporary or provisional restoration are addressed, a clinical case is described, and an algorithm for treatment options following prototype bonding is shared.

Key Words: prototype, concept, erosion, wear, transitional bonding

CE CREDIT

Disclosure: The author did not report any disclosures.

Learning Objectives

After reading this article, the participant should be able to:

1. Better understand how to use a direct bonded restoration as a prototype for the final restoration.
2. Define and explore how a prototype restoration differs from a temporary or a provisional restoration.
3. Visualize opportunities presented in minimal- to no-preparation designs in the restoration of occlusal wear cases.

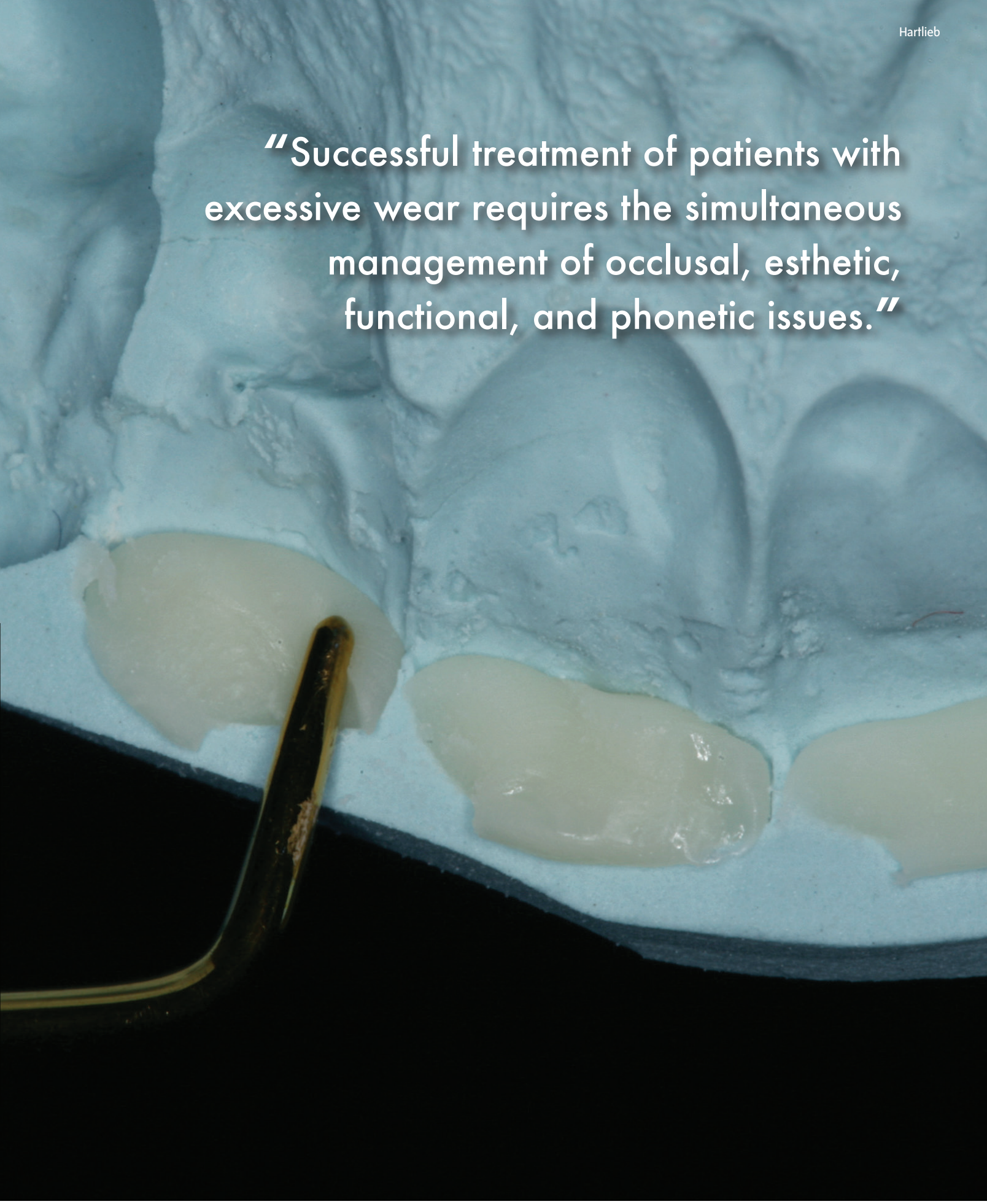

"Successful treatment of patients with excessive wear requires the simultaneous management of occlusal, esthetic, functional, and phonetic issues."

Introduction

Patients often present to dental practices with worn and eroded teeth that require restorative intervention. In fact, the number and severity of these cases seems to be increasing.[1] The etiology of the wear and erosion may be multifactorial, including but not limited to bruxism, highly acidic diets, and gastric acid reflux. Successful treatment of patients with excessive wear requires the simultaneous management of occlusal, esthetic, functional, phonetic, and airway issues. Given the complexity of the treatment to restore such patients, strategies to optimize predictability should be employed.

Traditional Management

Traditional management of the worn dentition case requires a diagnostic wax-up of the appropriate tooth form, maxillary and mandibular incisal edge position, and lingual and occlusal contours. Typically, after the patient and the dentist accept the wax-up, the teeth are prepared for the definitive restorations, impressions of the teeth are made, bite registrations are taken, and provisional restorations are fabricated. It is during the provisional period that the dentist and patient first have an opportunity to evaluate tooth length and form, overjet and overbite, and myriad other issues related to esthetics, function, and phonetics. Some patients may be dissatisfied with the proposed reconstruction but many of their objections also can be modified during the provisional phase. However, once the teeth have been prepared there is no going back; unknowns, such as how the patient will tolerate a change in his or her vertical dimension, cannot be determined until after irreversible preparation has occurred. In an effort to reduce the occurrence of such patient dissatisfaction there has been an emphasis on developing minimally invasive—or even reversible—procedures.

Transitional Bonding

The successful utilization of direct resin as a transitional restorative material has been well documented in recent years.[2-4] This technique, often referred to as *transitional bonding*,[5] can be used to add length to maxillary anterior teeth, open vertical dimension, and make other esthetic and functional changes. With transitional bonding there is an implied sense that there will be a sequence of treatment, from preoperative to transitional to the final definitive dentistry. The challenge the author has seen when treating patients with worn dentition is that the many esthetic, phonetic, occlusal, and functional issues being treated need to be tested during the transitional phase. Therefore, he believes that the term *prototype* is a more accurate descriptor of these "test" restorations.

Prototype Phase

It is critical that prototypes be tested for success and evaluated for possible limitations before the definitive restorations are designed and created. Employing the philosophy of "concept to prototype to restoration" (CPR), the dentist is able to test the provisionals in a safe manner prior to tooth preparation for the definitive restoration.

The information obtained from the development of the prototype is essential for the success of the final product. In dentistry, there is a belief that the laboratory technician's wax-up (concept) will work successfully for the final crowns or veneers (restoration). Without a prototype phase, the testing of the concept occurs during the definitive restorative phase. Failures, whether esthetic, functional, or phonetic, can be modified only minimally once the definitive restorations are placed. The patient should understand that prototype bonding is to test and evaluate the restorative treatment and that the definitive restorations will be based on the prototypes, dependent on the patient's satisfaction and approval.

The author's main objectives during the prototype phase are to:

- involve the patient in treatment decisions
- perform reversible (no or minimal preparation) dentistry
- effect esthetic improvements
- make occlusal changes
- test the planned esthetic and occlusal changes
- modify prototype to achieve patient satisfaction.

Reversibility and Other Advantages

It is the author's experience that some patients will be dissatisfied with or unable to adapt to the changes effected during the prototype phase. Therefore, it is essential that the treatment be reversible. As a reversible procedure, the prototype bonding can be removed with care, essentially returning the patient to his or her original situation. Knowing that the treatment is reversible can help patients feel more comfortable about proceeding.

Beyond the technique's reversibility, there are several other advantages of prototype bonding when treating patients with worn dentition. These advantages include the ability to improve dialogue between the patient, the dentist, and the laboratory technician regarding the patient's esthetic goals. Because the patient is able to fully experience the esthetic and functional changes proposed, he or she is better able to visualize the anticipated definitive restorations. Overjet and overbite, tooth shape and contour, vertical dimension of occlusion (VDO), and the esthetic display of the teeth can be adjusted and modified

"The information obtained from the development of the prototype is essential for the success of the final product."

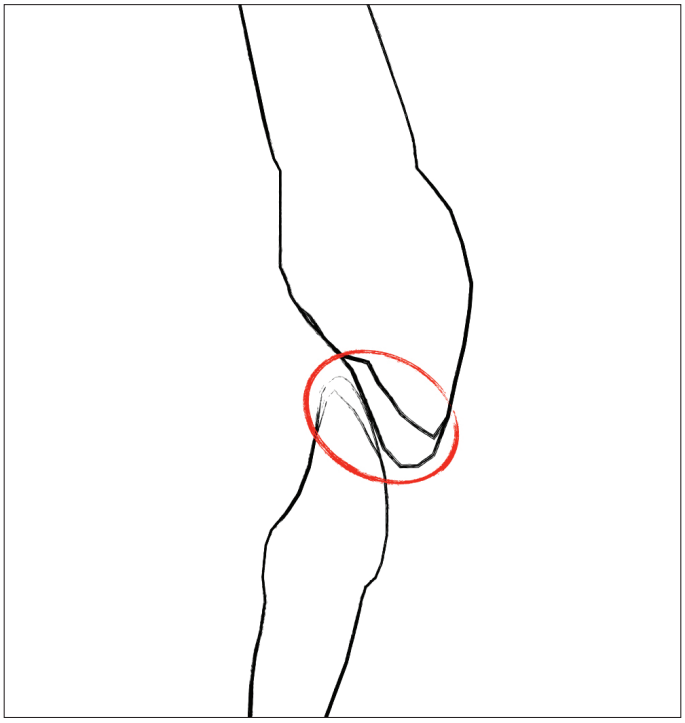

Figure 1: Loss of palatal maxillary anterior tooth structure and facial mandibular anterior tooth structure from wear.

based upon the patient's needs and desires. Limitations of the patient's existing dental situation may help the patient understand the need for additional procedures, such as periodontal crown lengthening, grafting, or orthodontic tooth movement.

Another significant advantage of prototype bonding is its ability to allow for long-term sequencing of the definitive dentistry, given that the prototype bonding has reestablished appropriate occlusal and functional form. Patients with financial constraints can opt for more limited definitive restorative treatment, including single-tooth or quadrant-based dentistry, once the occlusal and esthetic parameters have been created and tested for success. In fact, some patients may determine that the prototype restorations themselves satisfy all of their esthetic and functional needs and decide to maintain these restorations indefinitely.

Finally and critically, prototype bonding allows for decreased treatment time and costs due to predictability in creating the final restorations based on the prototypes. The dental laboratory can utilize an impression (scanned or analog) of the tested and accepted prototype restorations as a guide for the definitive restorations. This replica of the successful prototype restorations reduces the likelihood that remakes will be necessary, thereby also reducing the possibility of patient dissatisfaction.

Limitations

There are several limitations with prototype bonding, as there often are esthetic compromises with no-preparation or minimal preparation bonded restorations. Tooth shine-through is a common esthetic issue when direct resin bonded restorations are placed on teeth that are dark, discolored, or have severe rotations. Prototype bonding also can be monochromatic in nature. Given that the definitive incisal edge position is in question during the initial prototype experience, it is risky to include incisal translucency in the bonding as material may need to be added or length removed for the "ideal" position. Finally, to minimize patients' financial costs, prototype bonding lacks the ultimate surface polish and morphology that is expected with the definitive restorations.

Wear

It is not the intent of this article to delve into the reasons for the significant wear and erosion seen in many patients today. The causes likely are multifactorial; however, there is evidence that suggests the likelihood of a link between airway disturbances and secondary bruxism and gastric reflux.[6,7] Dietary and other individual patient habits also are probable key contributors.

The restorative dentist's challenge when treating the wear patient is to create the space necessary for the teeth to be restored. Due to the compensatory super-eruption of the teeth during the loss of occlusal tooth structure, there typically is a lack of space to create appropriately contoured teeth **(Fig 1)**.[8] Three commonly accepted ways to create the lost restorative space include **(Fig 2)**:

- orthodontic intrusion of the teeth
- seating the condylar joints in centric relation (CR)
- opening the VDO.

Orthodontic Intrusion

Orthodontic intrusion can be used to gain restorative space for both anterior and posterior teeth. For patients with excessive anterior wear and limited posterior wear, intrusion of the maxillary and/or mandibular anterior teeth is an ideal treatment modality **(Fig 3)**.[9,10] Repositioning only the teeth that need restorative treatment can minimize the number of teeth to be restored, thereby reducing the patient's time and monetary costs.

With anterior intrusion, the esthetic parameters are evaluated for gingival margin leveling rather than incisal edge positioning. Intrusion of the maxillary anterior teeth to align the gingival margins will allow for optimally contoured restorations with the appropriate incisal edge positions **(Figs 4 & 5)**. This anterior tooth repositioning maintains the preoperative occlusal situation while allowing for esthetic and functional improvement with the prosthetic enhancement.

Seating Condyles in CR

Seating the condyles in CR often can provide the necessary space for additive dentistry to replace worn tooth structure **(Fig 6)**. If the wear is limited to the anterior dentition, positioning the joints in CR can reduce the number of teeth requiring restorative treatment.[11,12] It is important for the restorative dentist to understand that there are limitations when using CR only as an opportunity to gain restorative space. Seating of the con-

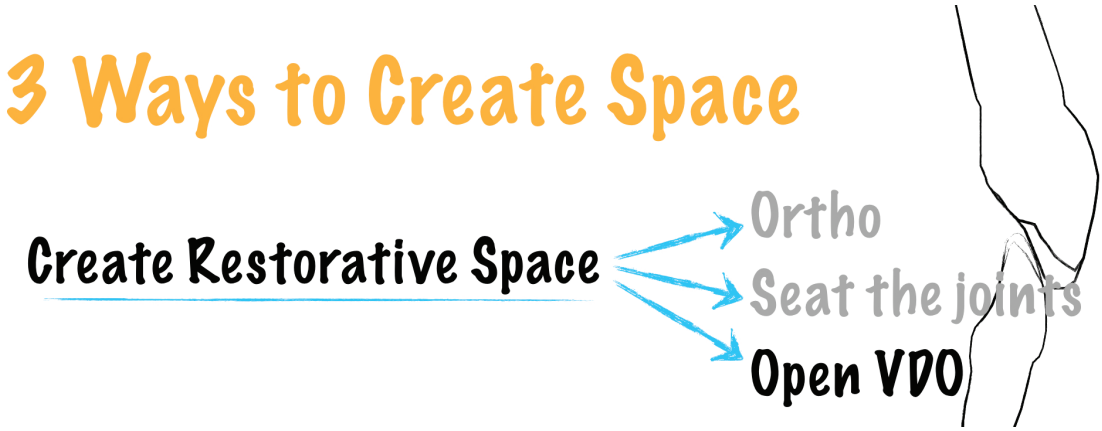

Figure 2: Three treatment options to create restorative space: orthodontics, seating condyles in CR, and opening vertical dimension.

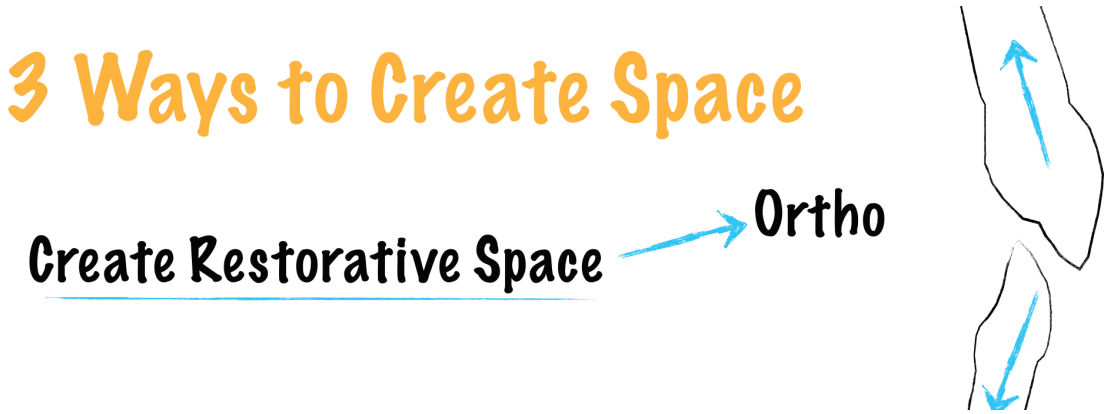

Figure 3: First option for creating restorative space: orthodontic intrusion of anterior teeth.

Figure 4: A patient with intrusion of maxillary anterior teeth (retracted view). Floss positioned to demonstrate optimal cementoenamel junction positioning.

Figure 5: Smile view of the patient utilizing temporary implant anchorage devices and orthodontic elastics.

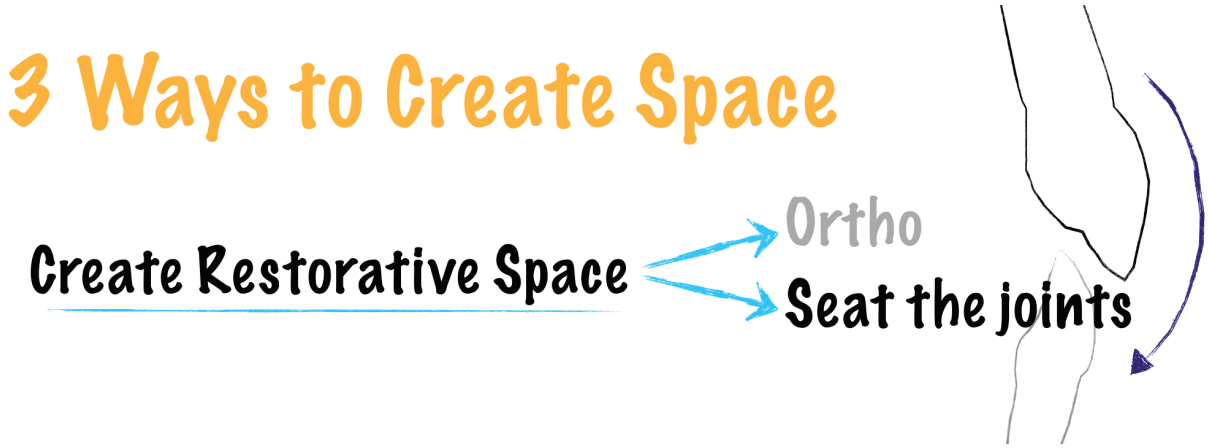

Figure 6: Second option for creating restorative space: seat the condyles in CR.

Figure 7: Retracted image of a patient with teeth in maximum intercuspation (retracted view).

Figure 8: Image of the patient showing the restorative space available with condyles seated in CR utilizing bilateral manipulation technique.

dyles may create anterior space, but if there is posterior wear that needs to be restored seating the condyles in CR often will create initial contacts on the worn posterior teeth. However, if there is an absence of, or minimal posterior wear, utilization of CR may provide sufficient space to restore the worn anterior dentition **(Figs 7 & 8)**. Critically, there exists the possibility that if the reason for the wear and erosion is secondary to airway obstruction issues, seating the joints in CR may cause a decrease in airway patency, potentially creating an increase in airway stress.

Opening VDO

For patients who have both anterior and posterior wear or patients for whom orthodontics may not be an option, it may be necessary to create restorative space by opening the VDO **(Fig 9)**. The principal advantages of increasing the VDO in wear cases are to gain the restorative space necessary to create naturally contoured teeth as well as the ability to manage the occlusal surfaces in one or both arches **(Fig 10)**. Increasing VDO can allow the dentist to better control occlusal forces in functional and parafunctional jaw movements.

Disadvantages: There are several disadvantages to opening the vertical dimension, the most obvious being that it increases the number of teeth to be treated (with subsequent increases in treatment time and costs). In addition, some patients may be sensitive to the changes in their occlusion and find it difficult to adjust to the new vertical dimension. The typical challenge when opening vertical dimension is related to the downward and posterior rotation of the mandible as the vertical dimension is opened. It is important for the restorative dentist to recognize that as the VDO is opened, the mandible does not open only in the vertical axis. The common misconception that there is a straight downward movement of the mandible as VDO is opened is depicted in **Figure 11**. Instead, the condyles are seated superiorly and anteriorly, as there is a rotation of the condyles within the joint space.[12] The

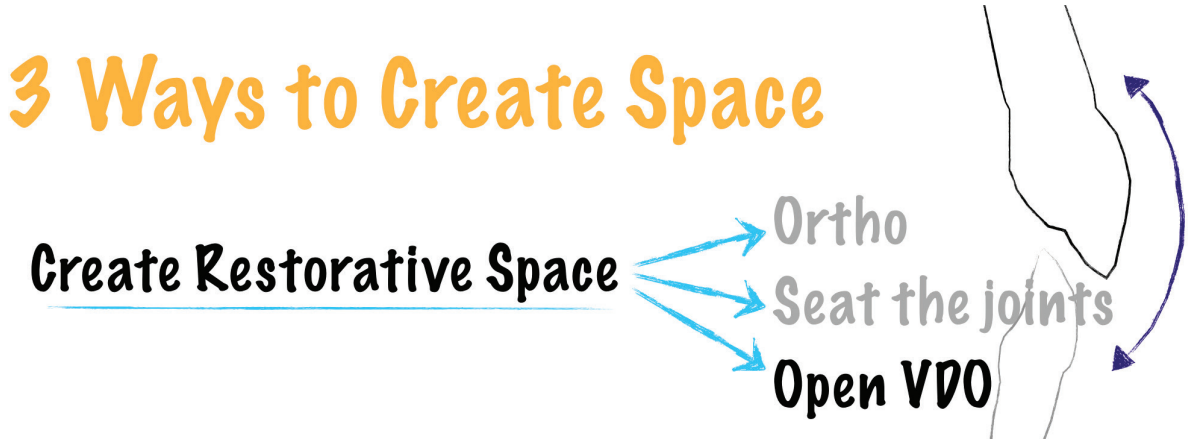

Figure 9: Third option for creating restorative space: increase the VDO.

Figure 10: The patient shown in Figures 7 and 8; restorative buildup of lower anterior teeth with condyles seated in CR.

subsequent rotation of the mandible creates a repositioning of the lower anterior teeth in both the horizontal and vertical axes **(Fig 12)**.

Although opening the vertical dimension can create the necessary space to add to the posterior occlusal surfaces and develop more ideal tooth form for anterior teeth, there might be challenges in gaining anterior guidance, particularly in patients with Class II occlusal skeletal relationships. The lower incisors may need not only to be lengthened, but also broadened buccolingually. Restorative treatment to the palatal of the maxillary anteriors may be necessary to gain occlusal contacts and anterior disclusion. Due to this increase in the anterior teeth overjet, some patients will be unhappy with the new occlusal relationship and real or perceived changes in their facial appearance. Phonetic issues also may occur due to the increased palatal thickness of the maxillary anterior teeth.

With skeletal Class II patients, it may not be possible to gain anterior contacts after opening the vertical dimension. The facial-palatal distance between the maxillary and the mandibular anterior teeth might be too significant to close the space restoratively without creating excessive contour in the restorations **(Figs 13 & 14)**.

Prototype Bonding—Clinical Technique

Patient Complaint and Treatment Options

A 57-year-old male presented at the author's practice for esthetic improvement of his smile. He was displeased with the dark color of his natural teeth and the mismatch of the existing porcelain restorations. Following a clinical examination that included evaluation of the biological and structural health of his teeth, periodontium, and temporormandibular joints, two preliminary treatment options were reviewed with the patient. The first option included orthodontic intrusion of the lower incisors and leveling of the occlusal planes with subsequent restorative treatment (veneering of unesthetic teeth and replacement of existing dentistry). The patient was not willing to consider orthodontic treatment, either through the use of conventional braces or with a removable clear retainer system. The second option, which the patient selected, was to manage the irregular occlusal planes restoratively to create an improved foundation for the proposed esthetic work. The patient was informed that forgoing orthodontics would necessitate compromise in the final treatment and that both dental arches would need treatment with the restorative-based solution, which might not be the case if orthodontics were utilized.

Treatment

Preoperative data: Preoperative study cast impressions and a facebow record were taken for mounting the upper cast to an articulator **(Fig 15)**. Although there is debate over the necessity of employing a facebow for maxillary cast mounting on an articulator, the author favors its use to designate the appropriate facial esthetic plane to set the maxillary cast to the level ho-

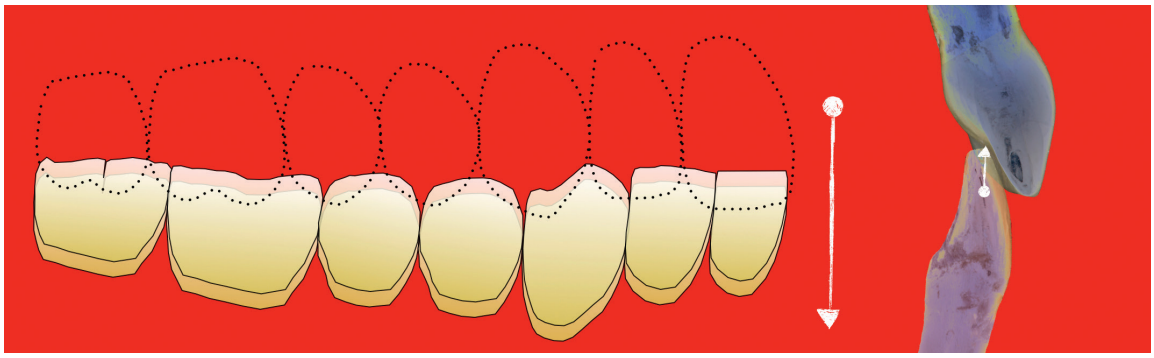

Figure 11: There is a common misconception that there are only vertical changes on anterior bite space with opening of the VDO.

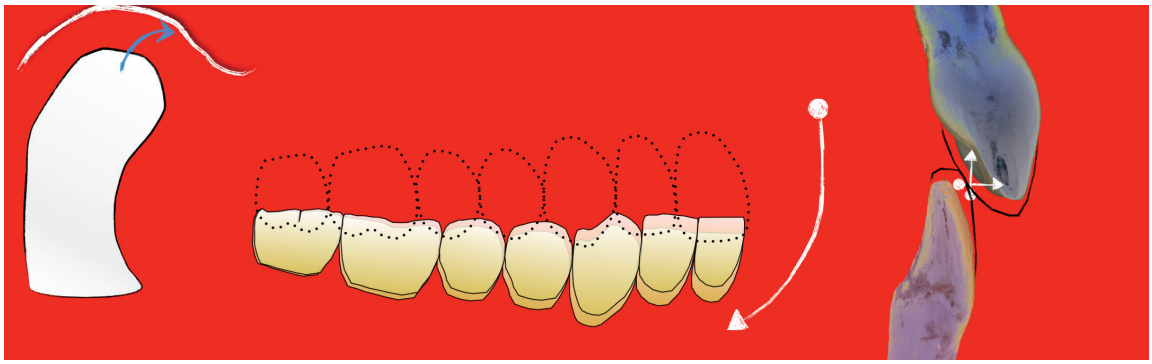

Figure 12: Changes in both horizontal and vertical space witnessed with anterior superior positioning of condyles in increased VDO.

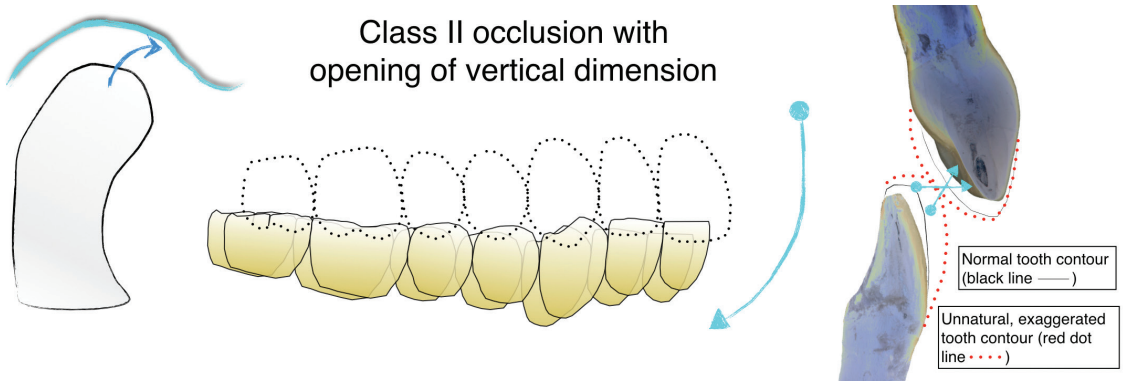

Figure 13: Opening of VDO in skeletal Class II patients.

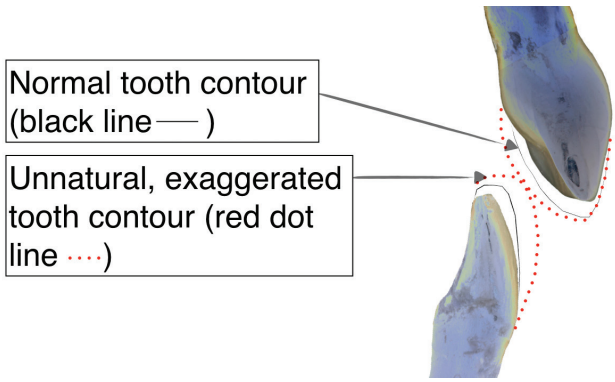

Figure 14: Nonrestorable changes in overjet/overbite jaw relationships in skeletal Class II patients with increased VDO.

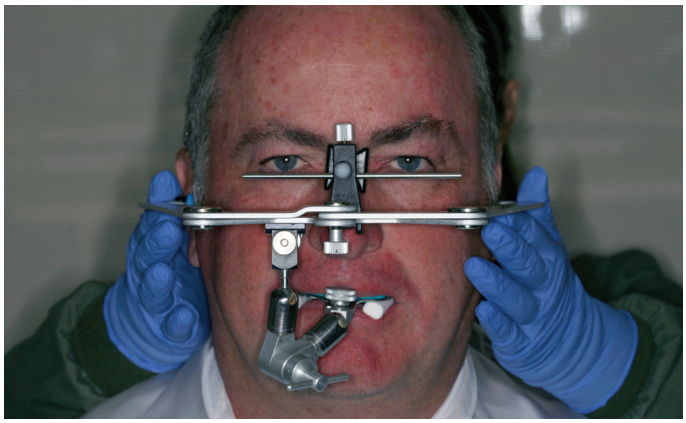

Figure 15: Facebow utilized to register correct maxilla orientation for articulator transfer.

Figure 16: Preoperative image showing canted smile, discolored anterior teeth, inconsistent color development in restorative treatment, and poor occlusal form of lower dentition.

Figure 17: Wax-up of maxillary dentition for patient communication and fabrication of silicone putty matrix guide.

Figure 18: Putty matrix guide in place demonstrating additional length for esthetic development.

rizon.[13,14] Inaccurate recording of the patient's maxilla can lead to canting or midline shifting in the planned restorations. The lower cast was mounted to the upper cast with a CR bite registration. Photographs of the patient with a full smile and with lips in repose were taken for esthetic analysis **(Fig 16)**. A wax-up was created on a duplicate mounted set of casts that properly depicted the desired cosmetic outcome **(Fig 17)**. A polyvinyl siloxane (PVS) guide was fabricated from the model wax-up to use as an intraoral guide when placing the direct resin. Alternatively, a cosmetic "wax-up" can be created digitally and printed; a PVS guide then can be produced from this printed model.

Etching, composite layering, and finishing: The PVS guide was tried in to ensure passive and accurate fit **(Fig 18)**. A line was scribed in the intaglio of the guide detailing the lingual wall of the incisal edges of the teeth to be bonded. The teeth were isolated and micro etched with 50-micron aluminum oxide to remove the pellicle, plaque, and superficial extrinsic staining. In the hope of creating reversible prototype restorations, minimal to no tooth structure was removed. The teeth were etched for 15 seconds with phosphoric acid (if the enamel is unprepared, it should be etched for a full 30 seconds) **(Fig 19)**. A fifth-generation dentinal adhesive was placed per manufacturer's recommendations **(Fig 20)** and polymerized. If the extent of the wear is so excessive that there is minimal enamel remaining, a self-etch or selective etch protocol would be appropriate for the adhesive phase of treatment.

Prior to positioning the PVS guide, a nanohybrid composite was placed into the guide, being sure to bring the material to the scribed line and filling the incisal lingual portion of the guide completely **(Figs 21 & 22)**. The composite was lightly condensed into the matrix to ensure that there were no voids or underfilled areas. It is critical that separation between the teeth be maintained when placing composite in the PVS

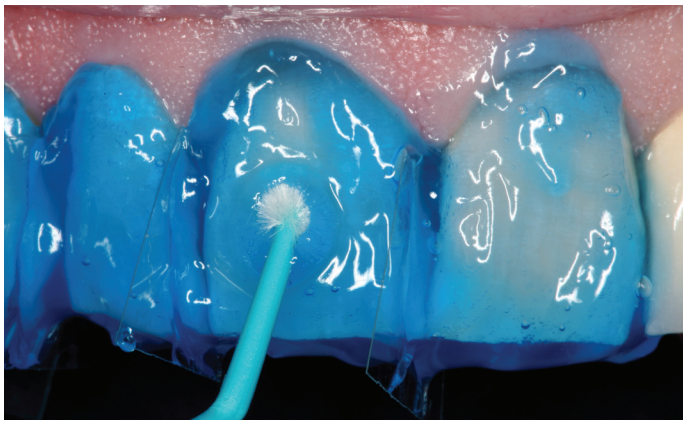

Figure 19: Application of 37% phosphoric acid for 30 seconds to unprepared tooth structure.

Figure 20: Bonding adhesive placed on etched, but unprepared, natural dentition.

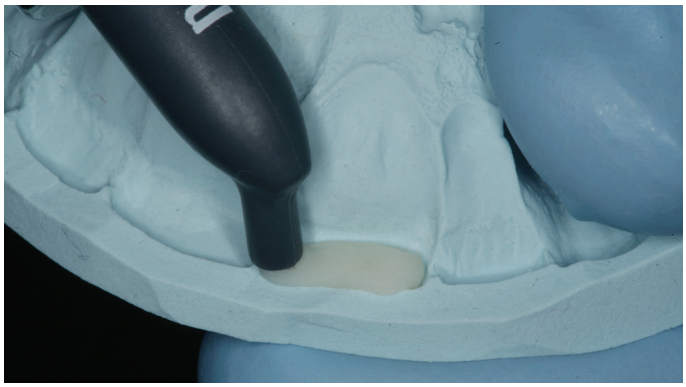

Figure 21: Nanofilled composite placed into putty matrix.

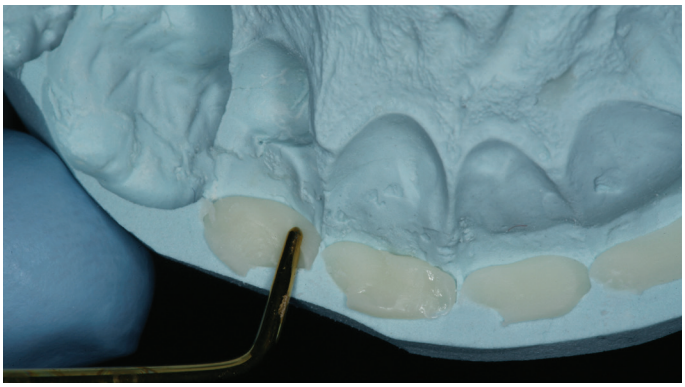

Figure 22: Manipulation of nanofilled composite in putty matrix, creating separation between individual teeth.

guide. The guide was set aside and protected from light while the same shade of composite was placed and blended on the teeth to be restored. The composite was placed on each tooth and left uncured, being sure to maintain separation between each tooth **(Fig 23)**. The PVS guide was placed into position, with great care taken not to apply too much pressure so as not to distort the putty guide or force excess composite into the lingual or palatal potion of the matrix **(Fig 24)**.

A thin composite instrument was used to create separation between the composite on each of the teeth prior to curing. The composite was cured from the facial surface of each tooth for 10 seconds **(Fig 25)**. The putty matrix was gently removed, revealing the lingual wall and the incisal facial line angle created from the matrix **(Fig 26)**. Working one tooth at a time, additional layers of nanohybrid composite were placed to create the optimal facial contours **(Fig 27)**. The composite should be slightly overbuilt to allow for final contouring and polishing. Following the buildup and polymerization of each prototype tooth, the proximal walls were polished to a high finish. Polishing of the proximal composite walls allows for direct composite placement without the fear of bonding each tooth to the adjacent teeth.

Once all the teeth in the arch were bonded, contouring and polishing was completed utilizing carbide composite trimming burs, discs and rubber polishing wheels, cups and points **(Fig 28)**. The occlusion was evaluated and adjusted for appropriate tooth contacts in CR and disclusion in anterior and lateral protrusive jaw movements. The prototype bonding was evaluated for smile esthetics, phonetics and "feel" **(Fig 29)**.

Managing occlusal forces: To manage a patient's occlusal forces in both centric contacts and functional excursions, it also may be necessary to utilize prototype bonding on the opposing arch. To flatten this patient's "stepped" occlusal plane, direct resin was bonded to the facial aspects of the mandibular

Figure 23: Addition of nanofilled composite to incisal edges of teeth to be restored for prototype bonding.

Figure 24: Seating of putty matrix guide, combining the composite from the guide to the composite placed on the incisal edges of the teeth.

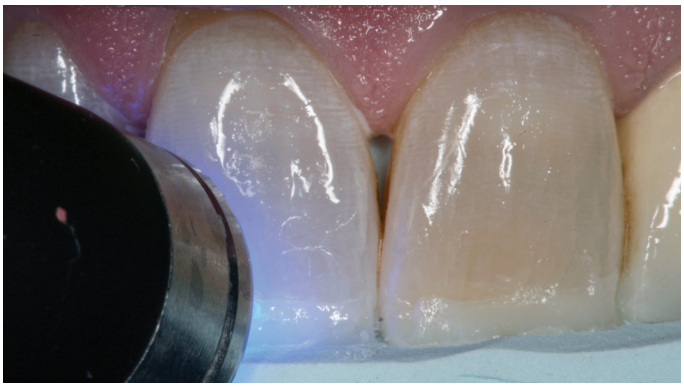

Figure 25: Polymerization of the nanofilled composite with putty matrix in place.

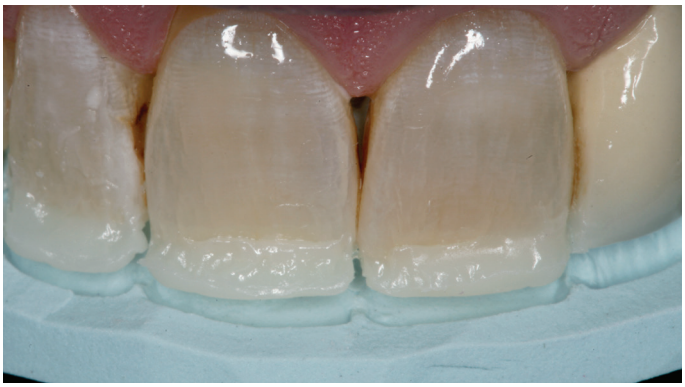

Figure 26: Putty matrix lifted following light-curing of composite, demonstrating additional tooth length.

Figure 27: Nanofilled composite added to facial of individual teeth to block out discoloration of natural teeth and to create proper shape and contour for final esthetics.

Figure 28: Contouring of composite bonding with esthetic trimming bur.

Figure 29: Prototype bonding complete, resurfacing natural tooth structure and existing dentistry to create a pleasing smile and appropriate function and occlusion.

incisors and the buccal cusps of all mandibular posterior teeth. This facial addition of material to the mandibular incisors created additional posterior occlusal space to allow for direct resin additive dentistry to support the increased VDO **(Figs 30-32)**. Occlusal and esthetic adjustments were made as needed and the patient was monitored for several months, evaluating for prototype success.

Adjustments: Mobility of teeth, chipping or failure of the bonded restorations, or heightened tooth sensitivity should alert both patient and dentist to functional disharmonies, parafunctional habits such as bruxism, or destructive patient behaviors. Adjustments and modifications of tooth shape and length, plus occlusal modifications, should be made until occlusal stability is attained and the patient is satisfied with tooth length, shape, and contour.

Options after prototype phase: Following the evaluation period, the patient can choose from three options **(Fig 33)**. First, he or she can choose to maintain the prototype bonding indefinitely. The challenge with maintaining the prototype bonding, as described earlier, is that there are drawbacks to its esthetic qualities, including shine-through of the unprepared tooth structure, lack of natural incisal translucency, monochromacity of the restorative material, and limitation of the final polish of the composite **(Fig 29)**. The advantages of maintaining the prototypes are an obvious decrease in treatment costs and no irreversible tooth structure loss due to preparation.

There are two restorative options following the prototype phase. The first of these is to resurface the prototype bonding with a layered composite veneer approach utilizing opaquers, tints, and microfills for ultimate esthetics and polish. In this option, the facial aspects of the teeth are prepared ideally, leaving the nanofill lingual wall that was created for the prototype phase. The advantage of '"resurfacing" is that the functional contours of the lingual wall and incisal edge position established during the prototype phase are maintained and only the esthetic issues related to color, opacity, and translucency are recreated with more highly esthetic materials.

The second restorative option for the prototype restorations (the option chosen by the patient in this case) is to eventually transition to porcelain, either as veneers, veneer onlays, or full-coverage crowns. It is critical that the functional components (i.e., lingual contours, incisal edge position, and facial contours) be reproduced with the provisionals and, ultimately, the definitive porcelain restorations. Typically, the prototype bonding will serve as a buildup restoration, allowing ideal preparation design for the porcelain restorations. Because the prototype bonding depicts the desired facial contour and incisal edge length, depth cuts can be made through it to help ensure adequate, but not excessive, tooth preparation **(Figs 34-36)**. In the present case, the prototype bonding on the lower arch served to create more ideal occlusal form and the ability to create a bite relationship where centric relation is in harmony with the patient's maximum intercuspation (MIP). This CR/MIP harmony allowed for more predictable bite registrations at the impression appointment, as the author was able to guide the patient into his natural and stable occlusal interdigitation **(Fig 37)**.

The laboratory technician was able to utilize the casts of the prototype bonding as guides for creation of the appropriate length and contour in the desired final restorations. There should be a seamless transition from the proven prototypes to the definitive restorations, provided the dentist supplies the technician with a cast or digitized impression of the prototypes and the technician methodically follows the shape and contour thus dictated **(Figs 38 & 39)**. As occurred in this case, the author has often experienced patients choosing to maintain the prototype bonding on less esthetic areas of the mouth in order to minimize costs **(Figs 40 & 41)**. This patient elected to maintain the prototype bonding on the lower dentition and will transition to definitive porcelain restorations when the prototypes demonstrate signs of breakdown. The prototype bonding has maintained well over the four years since treatment was completed without composite chipping or breakage, with minimal wear observed **(Fig 42)**.

"Knowing that the treatment is reversible can help patients feel more comfortable about proceeding."

Figure 30: Prototype bonding on facial aspect of lower anteriors to open vertical dimension, allowing addition to mandibular posteriors to flatten "stepped" occlusal table.

Figure 31: Prototype bonding on buccal cusps of mandibular posterior dentition to flatten "stepped" occlusal plane.

Figure 32: Prototype bonding complete on lower arch.

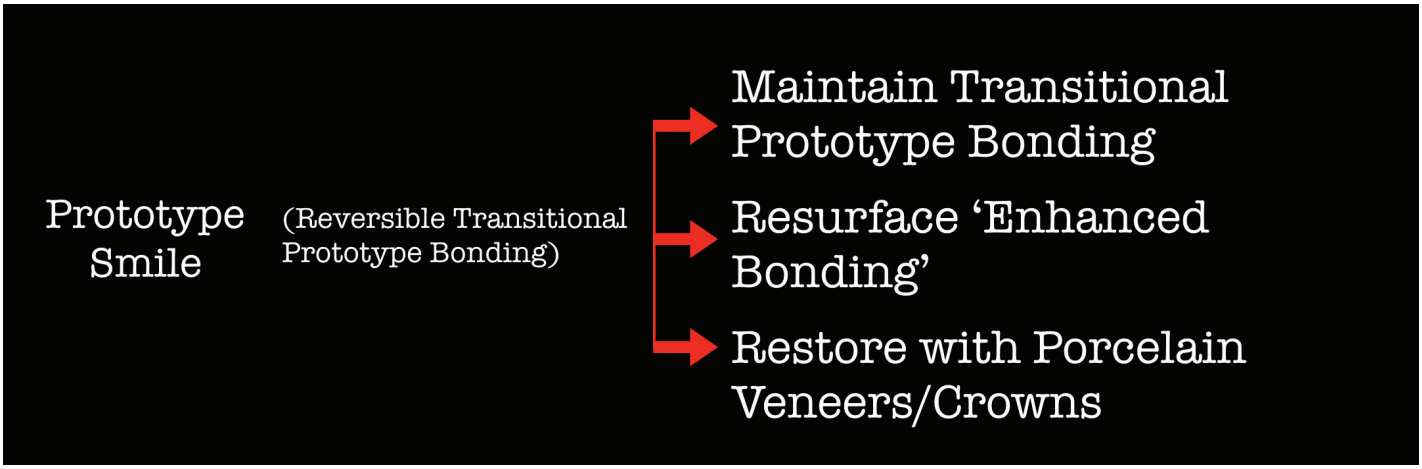

Figure 33: Algorithm to determine treatment options following successful prototype trial period.

Figure 34: Depth cuts in prototype bonding for idealized preparation of porcelain veneers.

Figure 35 Finalized porcelain veneer preparations based on facial and incisal form of the prototype bonding.

Figure 36: Final maxillary preparations based on the prototype bonding.

Figure 37: Bite registration for mounting case for definitive restorations. With the patient's CR bite coincident with MIP, bite registration becomes more predictable.

Figure 38: Final porcelain restorations bonded in place, following shape and form of tested prototype bonding.

Figure 39: Occlusal view of final porcelain restorations bonded in place, following shape and form of tested prototype bonding.

"...some patients may determine that the prototype restorations themselves satisfy all of their esthetic and functional needs and decide to maintain these restorations indefinitely."

Figure 40: Retracted frontal view of final porcelain restorations demonstrating prototype bonding in place on lower arch supporting restored maxillary dentition.

Figure 41: Retracted left lateral view of final porcelain restorations demonstrating prototype bonding in place on lower arch supporting restored maxillary dentition.

Figure 42: Retracted frontal view, four years postoperative.

HELPFUL HINTS

Perfecting Esthetic Prototype Techniques

Significant to a dentist's ability to create esthetic prototypes is refining their skills in first developing tooth shape and contour, then tooth color and intrinsic characteristics to create natural-looking restorations.

Splint Therapy During Prototype Phase

It is important for patients to understand the implications of their clenching/grinding issues. Therefore, unless patients are already committed to wearing an appliance, the author typically does not have patients wear any nighttime protective guard during this treatment phase.

Bonding to Existing Porcelain Restorations

Additional adhesive protocol is required when bonding to existing porcelain restorations. Similar to natural dentition, the restorations in this case were micro-etched, after which a 9.5% hydrofluoric acid was applied for 3 minutes. Silane and bonding adhesive were then applied prior to loading the composite resin.

Recognize the Value of Prototype Bonding

Many patients decide to maintain their prototype bonding and not proceed with more refined dental treatment. To motivate patients to continue with a more esthetic and/or durable restoration, the author applies a portion of the fee paid for the prototype bonding toward the cost of the definitive treatment.

Summary

There are several issues—including esthetic, occlusal, functional, phonetic, and airway—that must be addressed when treating the patient with worn dentition. The traditional strategy of utilizing a preoperative wax-up without testing the planned occlusal and esthetic changes is subject to many challenges, the obvious being that once the teeth have been prepared for a specific type of treatment, the dentist and patient are committed to following through with that particular treatment. Also, because testing is completed during the definitive treatment phase, there is little opportunity for any needed changes to the planned treatment. With the "CPR" method—concept to prototype to restoration—utilizing direct resin as a prototype material in a no-preparation technique, composite can be bonded to the unprepared tooth structure to define the desired incisal edge positions and the occlusal, lingual, and facial contours. The patient therefore is able to function with this prototype bonding for months to be certain they are satisfied with their speech and esthetics; and the dentist can monitor the bonded teeth for composite chipping or tooth mobility that would signify that the functional contours are inappropriate. When both patient and dentist are satisfied with the esthetic, phonetic, and functional characteristics of the prototype bonding it can be maintained indefinitely, resurfaced with a more esthetic composite layering technique, or eventually transitioned to porcelain restorations.

Acknowledgment

The author thanks Bill Marais, RDT (Portland, Oregon) for fabricating the ceramic restorations discussed in this article.

"The restorative dentist's challenge when treating the wear patient is to create the space necessary for the teeth to be restored."

Dr. Hartlieb maintains a full-time practice dedicated to cosmetic, implant, restorative, and sleep dentistry in Glenview, Illinois. He can be contacted at hartliebdds@dothandson.com

Disclosure: The author did not report any disclosures.

References

1. Lussi A, editor. Dental erosion: from diagnosis to therapy. Bern (Switzerland). Karger; 2006.
2. Hulac S. "Training teeth": transitional resin bonding for diagnostic purposes. Compend Contin Educ Dent. 2013 Oct;34(9):686-90.
3. Dietschi D, Argente A. A comprehensive and conservative approach for the restoration of abrasion and erosion. Part I: concepts and clinical rationale for early intervention using adhesive techniques. Eur J Esthet Dent. 2011 Spring;6(1):20-33.
4. Brown K. Transitional bonding for severely eroded dentition. J Cosmetic Dent. 2017 Spring;33(1):28-40.
5. Freedman GA. Contemporary esthetic dentistry. St. Louis: Mosby; 2012. p. 411-22.
6. Gregory-Head B, Curtis DA. Erosion caused by gastroesophageal reflux: diagnostic considerations. J Prosthodont. 1997 Dec:6(4):278-85.
7. Rouse J. The bruxism triad: sleep bruxism, sleep disturbance, and sleep-related GERD. Inside Dent. 2010 May:32-44.
8. Spear F. Managing over-eruption following tooth wear. Spear Digest. 2015 Dec 10. Available from: http://www.speareducation.com/spear-review/2015/12/managing-over-eruption-following-tooth-wear
9. Bellamy LJ, Kokich VG, Weissman JA. Using orthodontic intrusion of abraded incisors to facilitate restoration: the technique's effects on alveolar bone level and root length. J Am Dent Assoc. 2008 Jun;139(6):725-33.
10. Lowe E, Rego J, Rego N. Minimally invasive dentistry combining orthodontic therapy and single-unit restoration. Pract Proced Aesthet Dent. 2008 Jun;20(5):273-8.
11. Dawson PE. Functional occlusion: from TMJ to smile design. St. Louis: Mosby; 2006. p. 114-29.
12. Dawson PE. Centric relation. Its effect on occluso-muscle harmony. Dent Clinic North Am. 1979 Apr;23(2):169-80.
13. Nazir N, Sujesh M, Kumar R. Accuracy of two face-bow/semi-adjustable articulator systems in transferring the maxillary occlusal cant. Indian J Dent Res. 2012. Jul-Aug;23(4):437-42.
14. Farias-Neto A, Dias AH, DeMiranda BF, de Oliveira AR. Face-bow transfer in prosthodontics: a systematic review of the literature. J Oral Rehabil. 2013 Sep;40(9):686-92. **jCD**