



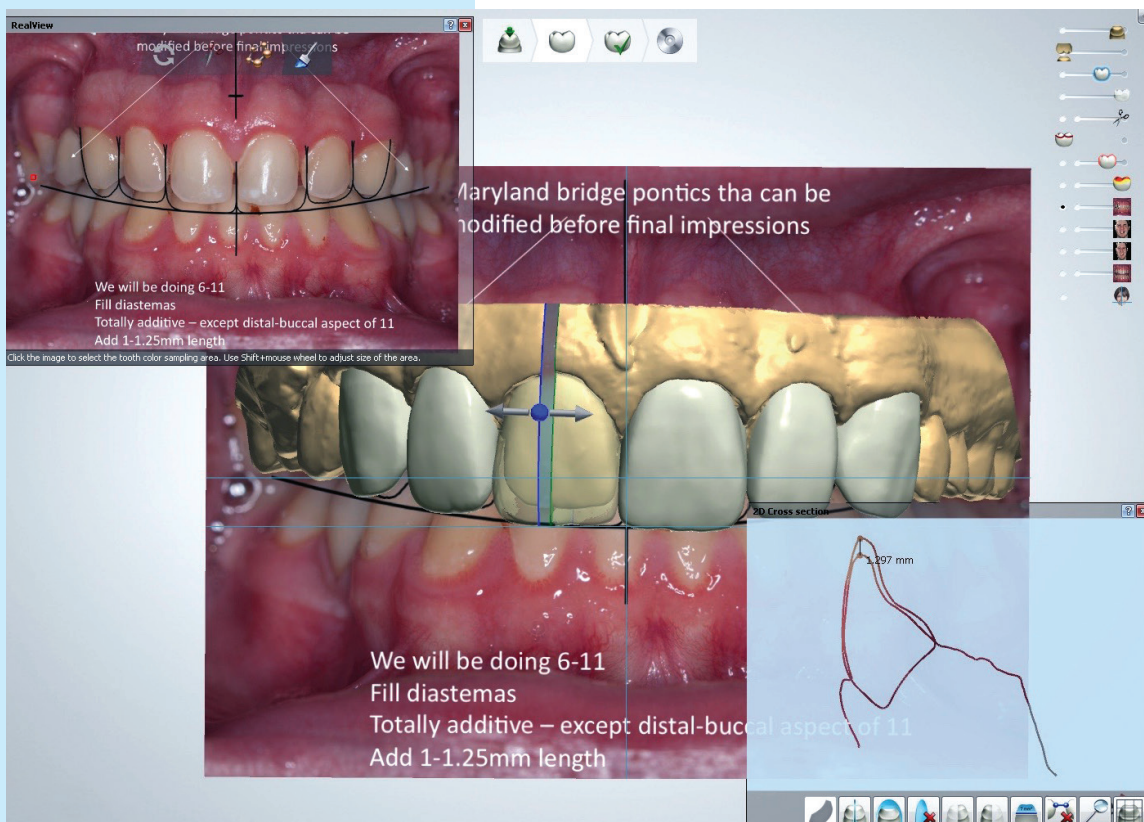
Esthetic Overlays

Matthew R. Roberts, CDT, AAACD
James Fondriest, DDS, FACD, FICD

Abstract

Patient visualization of esthetic procedures is a fundamental step in the treatment communication process. Historically, the use of direct mock-ups has been the best way for patients to visualize outcomes prior to esthetic treatment, but that requires a great deal of chair time and artistic ability. More recently, digital photography and software programs have been employed, as have two-dimensional line drawings placed over photographs. A silicone matrix of a diagnostic wax-up using one of the liquid provisional materials can be tried over existing teeth, but is messy to clean up. Esthetic overlays, composed of milled polymethyl methacrylate and based on a facially generated digital design, fit over existing dentition quickly with no cleanup and are a quick and effective way of showing a patient what is possible with cosmetic treatment. This article discusses the process by which these overlays are fabricated and describes a clinical case in which their use helped a patient overcome his concerns about final treatment results.

Key Words: facial esthetics, esthetic overlays, patient visualization, esthetic preview, motivation, diagnostic



Bonus content! This article has a short supplementary video in the *jCD* digital edition.



Introduction

Three-dimensional (3D) digitally designed and fabricated polymethyl methacrylate (PMMA) overlays, with incisal translucency and very natural surface texture, give the potential veneer patient a preview of esthetic treatment. The process allows patients to visualize, try in, and literally feel what the final result would be like in a matter of minutes, engendering patient appreciation and value for the final restorative process.

The overlay process combines the latest digital design software applications with the benefits of the direct mock-up preview sessions¹ done in top esthetic practices for patient approval prior to bonded ceramic restorative treatment, but it requires much less chair time. Using new technology that allows photographs to be attached to 3D digital designs, it is now possible to virtually try in the design as it is created, enabling the technician to customize it for the individual patient at a level that previously was very difficult to attain with conventional diagnostic waxing and facial photos. These designs are then milled in a very thin, very esthetic, multi-translucency PMMA material that fits over the patient's existing dentition.

Terminology

It will be useful here to define some relevant terms in digital dentistry.

Two-dimensional (2D) digital smile design involves the use of tooth-shaped overlays digitally added to photographs of a patient's teeth to diagnose and communicate their ideal shape and form to the treatment team.² This commonly is done with software such as PowerPoint (Fig 1) Keynote, Smile Designer, and Photoshop.³

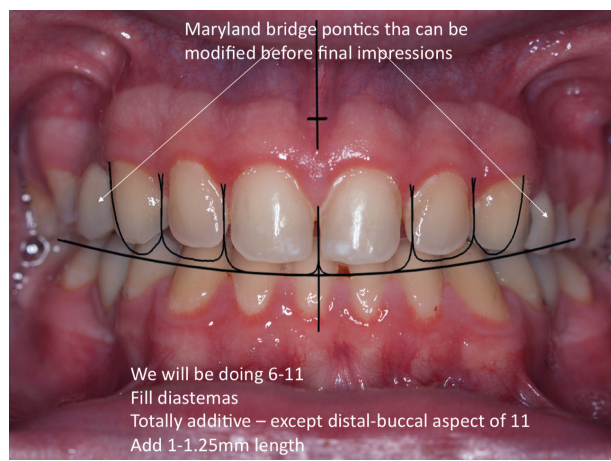


Figure 1: An example of 2D smile design for communication with the lab. In this case, Power Point was used to overlay the photograph with a template showing the laboratory technician what size and length of teeth were desired.

Digital smile design has become extremely topical in cosmetic dentistry, but in most cases this term refers to using design overlays on facial photographs of the patient to diagnose ideal position of the teeth when restored. These digitally created line drawings on the photo are an excellent communication tool for the dentist-laboratory technician-specialist team. The drawings guide the technician during the diagnostic waxing process by enabling him or her to examine the shape and position of the digital tooth outlines relative to previous tooth positions in the photo. The technician then uses this information to guide the shape and proportions while creating the final design in wax or ceramic by hand. This type of communication between dentist and ceramist requires the technician to visually observe the photo with the overlays and translate the information onto the 3D laboratory models where the wax-up or final restorations are being fabricated. Essentially, it is a digital design-analog system for communication and fabrication of esthetic dental restorations.

3D digital smile design and fabrication refers to 3D computer-aided design (CAD) programs that, along with computer-aided manufacturing (CAM), are used to design and mill or print the final restorations.⁴ Using the newest generation of software, the same facial photographs of the patient described above, with or without digitally created outlines of the desired tooth shapes, can be entered into a 3D CAD/CAM software system and synchronized (using multiple points of alignment) to the 3D design to eliminate the analog interpretation part of the equation (Figs 2 & 3). Marking common points on a 3D scan of the patient's teeth and a photograph with his or her teeth prominently displayed in a big smile, the software imports the 2D photograph into the 3D design. All changes to the design's shape or position are represented.

Photographically driven, 3D design gives the technician immediate feedback on the case's esthetics throughout the design process. This eliminates the interpretation and guesswork that occurs when viewing a photograph of the patient while working on a stone model. The treatment team visually evaluates the results, and when all parties are satisfied the technician presses the "Mill" button. There is no "lost in translation" disconnect between the photographic design process and the final physical restoration or wax-up, and the case can be developed to achieve the ideal esthetic and functional outcome. It is critical that the full-face photographs⁵ be taken with the patient directly facing the camera and with a smile big enough so the cusp tips of the first molars are visible. Off-angle photos are misleading as to midline verticality, and images without enough common data points can cause poor alignment between the 3D scan and the photos. These are the only technique-sensitive areas of this process.

3D design and CAM as described above are utilized to create esthetic overlays. This process works especially well when the need for change to the dentition is clearly additive in nature, but it is surprising to see what very thin overlays of even prominent teeth can accomplish.⁶ In the case of rotated teeth, holes

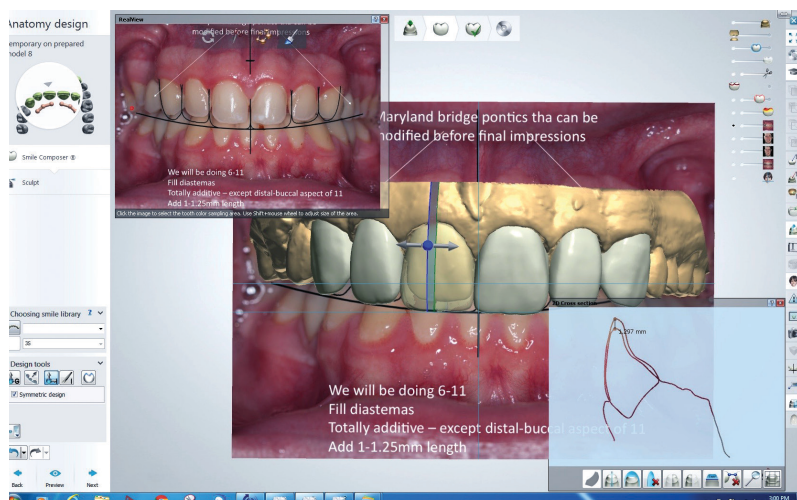


Figure 2: By identifying common landmarks on the photo and the scanned model, the 3D model is synchronized to the 2D digitally overlaid photo using software (3Shape Dental Designer; Copenhagen, Denmark). This allows the laboratory technician to design the outline form created by the dentist as shown in Figure 1. This interconnection of 2D digital design to 3D CAD software improves communication between restorative team members.



Figure 3: Preoperative full-face view.

can be left in the design for the corner of a tooth to protrude if necessary. These PMMA overlays also work well as a communication tool for the periodontist performing a crown-lengthening procedure; the overlay can be extended up over the tissue to the ideal margin position, then used as a surgical guide during full flap surgery. A similar process is used to produce “functional overlays,”⁷ where the same technology creates occlusal overlays to stabilize post splint temporomandibular joint patients with bonded-in PMMA overlays. It also works well to phase treatment of full-mouth reconstruction patients. Its greatest impact, however, is in enabling potential esthetic restorative patients to visualize what is possible with treatment.

Case Presentation

Overlay Fabrication

The patient, a college-age male, had small teeth with a slightly retroclined arrangement and diastemata (Fig 3).⁸ His mother had encouraged him to get veneers but, fearing an undesirable outcome, he had procrastinated. To alleviate his apprehension and to show him what was possible, we discussed doing esthetic overlays using PMMA (Harvest Dental Products; Brea, CA) to help him visualize what veneers could look like. Although this process works well with digital scans, in this case conventional impressions were taken and models were poured, then scanned in the lab and entered into a CAD program (3Shape) to complete the digital design. Facial photographs along with the 2D overlay design were entered into the design software and synchronized with the 3D scan of the patient's models; this enabled visualization of how the overlays would look in the patient's mouth once they were fabricated and tried in (Figs 4 & 5). The

“

...it is now possible to virtually try in the design as it is created, enabling the technician to customize it for the individual patient at a level that previously was very difficult to attain...”

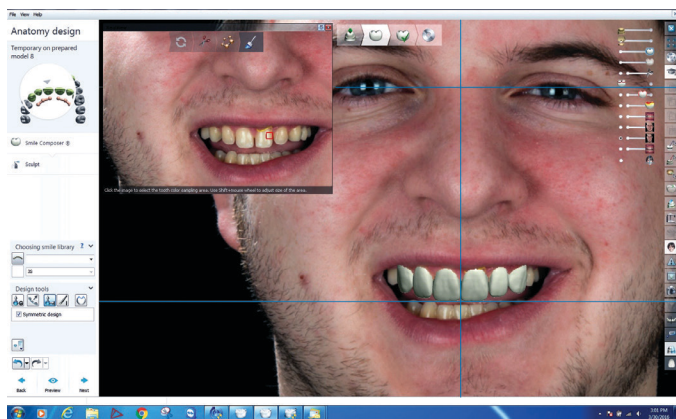


Figure 4: A “virtual patient” was created by synchronizing the 3D design to the full-face photo. All movement of the teeth in the 3D design is visually represented in this view. The thin gray lines identify the vertical and horizontal axes of the face and are used to orient midline and incisal planes for the design, essentially creating a “virtual stick bite.”

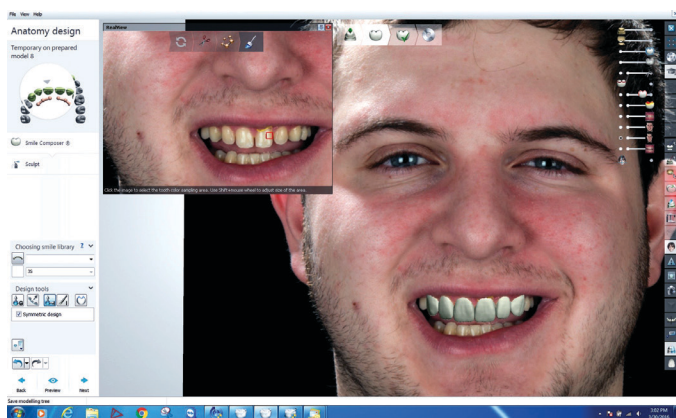


Figure 5: The dentist and patient can view the finalized digital design either as a “screen shot” or via the software’s TeamView option if the clinician wishes to have live 3D evaluation of the design. Here the diastemata have been filled in and an esthetically and functionally appropriate design has been created. This was done over the patient’s unprepared teeth to produce a design for the esthetic overlay, which will be milled from multi-translucency PMMA.

design was completed and milled in PMMA (Fig 6) in a five-axis milling unit (Zenotec Select, Wieland Dental; Pforzheim, Germany). The surface was textured and polished, then sent for delivery.

Try-In Appointment

When the overlay was tried in and the patient was handed a mirror, he and his mother said they would be thrilled if the final product looked like that. The overlay gave them an excellent idea of what could be accomplished (Figs 7-9). The patient scheduled an appointment for treatment as soon as his school schedule allowed.

Final Ceramic Veneers

Part of the beauty of the esthetic overlay workflow is the predictability of the final outcome. Once the patient was happy with the overlays’ shape and form, all we had to do was reproduce them in the final ceramic material. The patient’s preoperative condition had exhibited diastemata between undersized dentition (Fig 10). Due to the minimal nature of the preparation (Figs 11 & 12), no provisionalization was required. The digital design from the PMMA overlay was synchronized with the scan of the prepared model (Fig 13). The new design was adapted to follow the overlays’ contours and position. The final design was also connected to a full-face photograph of the patient to ensure facial harmony with the design (Fig 14).

The design was sent for fabrication. Milling can be done in semi crystallized lithium disilicate if restorations meet minimum thickness requirements; or it can be completed in wax, then invested and pressed with traditional lost wax (a pressed ceramic technique that can accommodate thinner restorations than the milled glass techniques). In this case the latter was chosen due to the very thin nature of the final restorations. Once the restorations were pressed, final contouring was done with a diamond bur to create a harmonious shape and natural-looking surface morphology. The incisal was cut back to allow room for micro layering (e.max Ceram, Ivoclar Vivadent; Amherst, NY) to create subtle incisal translucency effects. Staining, glazing, micro layering, and final contouring and polishing were completed prior to delivery (Fig 15). The final result met the patient’s goals of filling in the gaps in his smile and providing an overall esthetic improvement to his appearance while minimizing the loss of natural tooth structure (Figs 16-19).

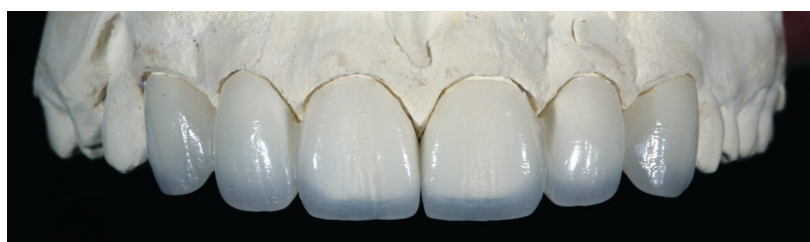

Figure 6: The thin PMMA esthetic overlay. The technician imparted surface texture and final polish prior to try in.

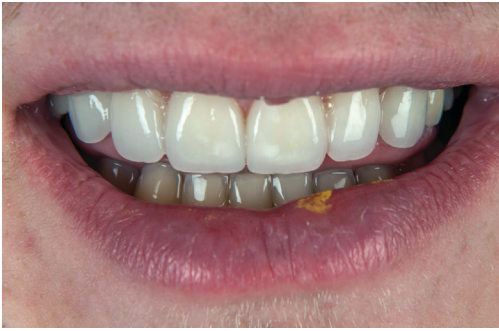

Figure 7: The esthetic overlays were tried in over unprepared teeth. They may be tacked in place with light-cured resin. This shows the patient what is possible if they accept treatment.



Figure 8: The PMMA overlays create a dynamic difference in the patient's appearance.

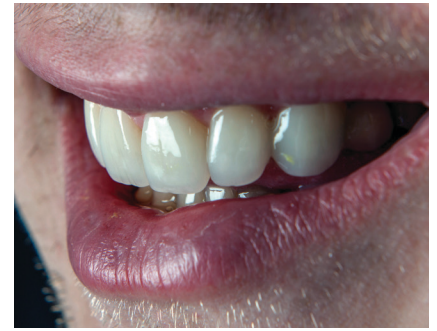

Figure 9: The PMMA has a natural, translucent appearance that helped alleviate the patient's fears of an unnatural-looking result.

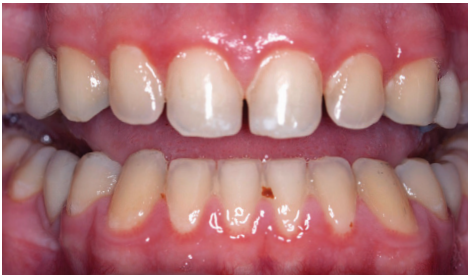
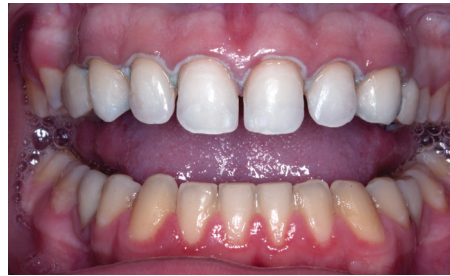
Figure 10: Preoperative retracted view shows the visual difference without the overlays in place.



Figures 11 & 12: Minimal preparation was done to eliminate undercuts and establish a common path of insertion. Most tooth surfaces were untouched. Provisionalization was unnecessary due to the minimal reduction of tooth structure.

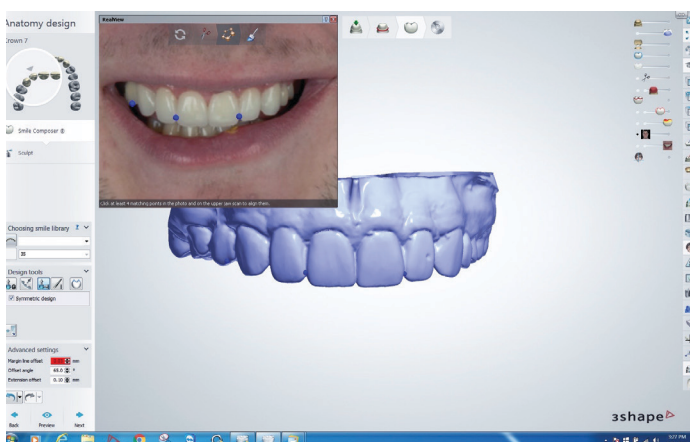
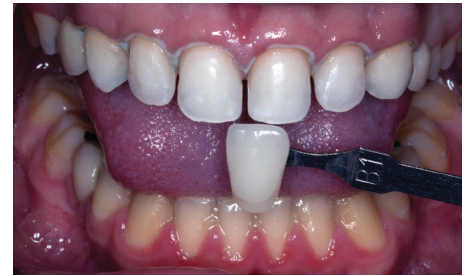

Figure 13: The digital diagnosis design for the esthetic overlays was imported to guide the final ceramic design. The overlay design was superimposed over the preparation scan, allowing the ceramist to design the final restorations to be identical.

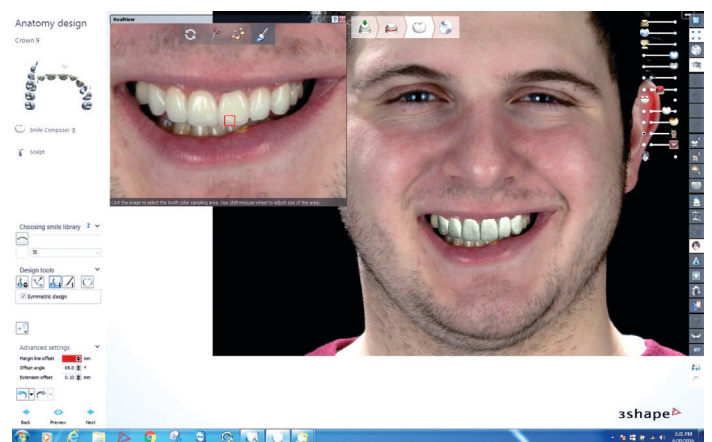
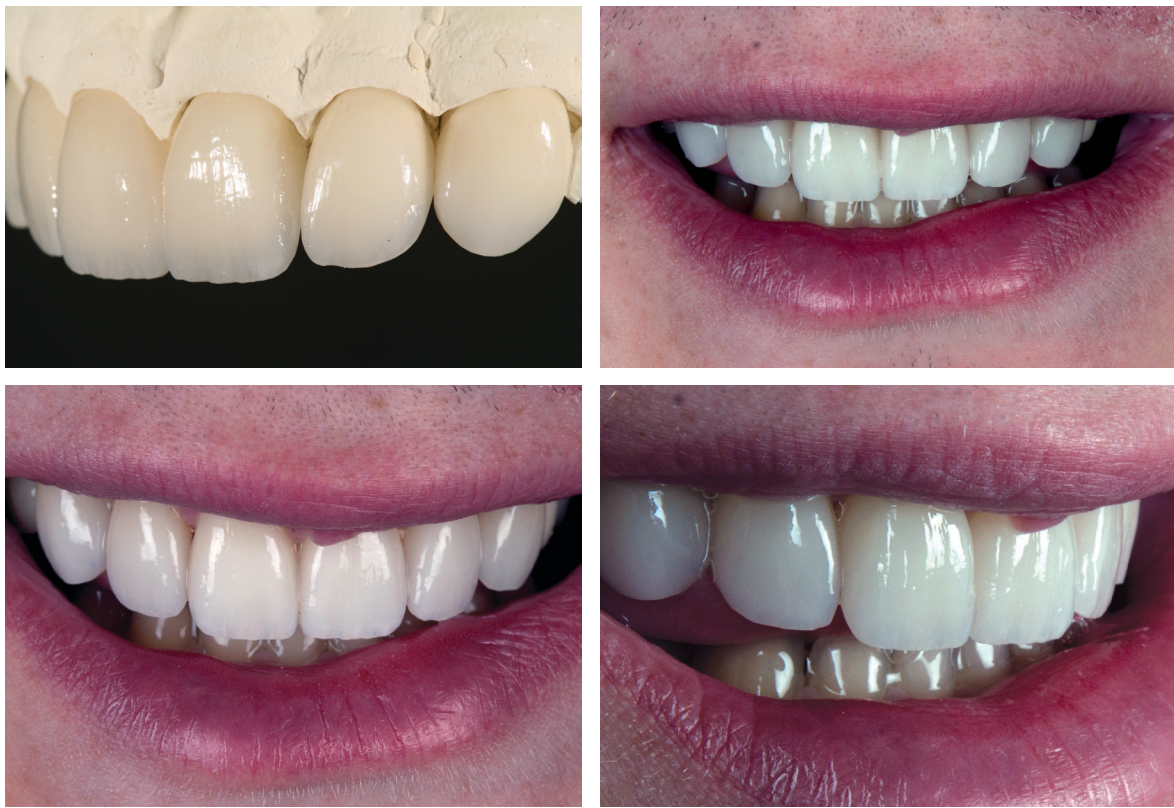

Figure 14: The final digital design was synchronized with the full facial photo for verification.



Figures 15-18: The final minimally prepared veneers. The incisal one third was micro layered to impart minimal incisal translucency. High-translucency ingots were selected to allow the natural color of the patient's teeth to filter through. The final result closely resembled the esthetic overlays.



Figure 19: The patient was very happy with the final result.



“

3D design gives the technician immediate feedback on the case's esthetics throughout the design process.”

Summary

By using the latest technology to combine digital models and photographs, we have the potential to treat patients with a much higher degree of accuracy than ever before. Digital impressions, digital design, and facial scans are now being combined and integrated into a complete interdisciplinary workflow that can be utilized across dentistry; the esthetic overlay case described here presents just one small application. Esthetic overlays enable patients to quickly and easily visualize the potential final results in a very personal, multi-sensory way. It has been the author's experience that this process dramatically increases case acceptance. This technology will continue to impact how we do dentistry in the future and is quickly becoming an accepted standard of care.

References

1. Hollar S. The “trial smile” experience. *J Cosmetic Dent.* 2008 Fall;24(3):106-10.
2. Coachman C, Calamita MA. Virtual esthetic smile design: driving the restorative plan. *J Cosmetic Dent.* 2013 Winter;29(4):102-16.
3. McLaren E. Digital smile design—the smart tool to engage savvy patients. *J Cosmetic Dent.* 2011 Summer;27(2):10.
4. Coachman C, Calamita MA, Sesma N. From 2D to 3D: complete digital workflow in interdisciplinary dentistry. *J Cosmetic Dent.* Spring 2016;32(1):62-74.
5. Touati B, Etienne JM, Van Dooren E. Esthetic integration of digital-ceramic restorations. Mahwah (NJ): Montage Media; 2008.
6. LeSage B, Wells D. Myths vs. realities: two viewpoints on veneers and prep-less veneers. *J Cosmetic Dent.* 2011 Summer;27(2):66-76.
7. DeWood G. Overlays to open VDO and test a muscle mediated position. *Spear Digest.* 2013 Oct 8. Available from: www.speareducation.com/spear-review/2013/10/overlays-to-open-vdo-and-test-a-muscle-mediated-position
8. Magne P, Belser U. Bonded porcelain restorations in the anterior dentition: a biomimetic approach. Hanover Park (IL): Quintessence Pub.; 2002. **JCD**



Mr. Roberts is an AACD Accredited laboratory technician. He is the founder of Team Aesthetic Seminars and of CMR Dental Laboratory in Idaho Falls, Idaho.



Dr. Fondriest has a full-time private practice in Lake Forest, Illinois.

Disclosures: Mr. Roberts presents lectures for 3Shape dental software. Dr. Fondriest did not report any disclosures.