jCD
Journal of Cosmetic Dentistry

Rubber Dam First
Calin Pop, DDS

Analysis with Imaging & Photography

Conservative Composite Bonding

2020 VOLUME 36 ISSUE 3
American Academy of Cosmetic Dentistry®

"We asked, they delivered!"

Based on AACD members' feedback, Ivoclar Vivadent developed a ***NEW Higher Viscocity Veneer Cement.***

Amanda Seay, DDS, FAACD

INTRODUCING

Variolink® Esthetic LC HV

Higher viscosity light curing cement

- Controlled seating
- Precise cleanup
- Ideal for veneers

GET YOUR FREE REFILL AT
blog.ivoclarvivadent.us/free-variolink-sample

ivoclarvivadent.com

For more information, call us at 1-800-533-6825 in the U.S., 1-800-263-8182 in Canada.
© 2020 Ivoclar Vivadent, Inc. Ivoclar Vivadent and Variolink are registered trademarks of Ivoclar Vivadent, Inc.

ivoclar vivadent®
passion vision innovation

jCD
volume 36 issue 3
Journal of Cosmetic Dentistry

A PEER-REVIEWED PUBLICATION OF THE
AMERICAN ACADEMY OF COSMETIC DENTISTRY

EDITORIAL REVIEW BOARD
Pinhas Adar, MDT, CDT, Atlanta, GA
Irfan Ahmad, BDS, Middlesex, United Kingdom
Somkiat Aimplee, DDS, MSc, AAACD, Bangkok, Thailand
Gary Alex, DMD, AAACD, Huntington, NY
Edward P. Allen, DDS, PhD, Dallas, TX
Chad J. Anderson, DMD, MS, Fresno, CA
Elizabeth M. Bakeman, DDS, FAACD, Grand Rapids, MI
Lee Ann Brady, DMD, Glendale, AZ
Kevin M. Brown, DDS, AAACD, Bellevue, WA
Ricardo M. Carvalho, DDS, PhD, Vancouver, BC, Canada
Christian Coachman, DDS, CDT, Sáo Paulo, Brazil
John C. Cranham, DDS, Chesapeake, VA
Michael W. Davis, DDS, Santa Fe, NM
Newton Fahl Jr., DDS, MS, Curitiba-PR, Brazil
Jonathan L. Ferencz, DDS, FACP, New York, NY
Scott W. Finlay, DDS, FAACD, Arnold, MD
Hugh D. Flax, DDS, AAACD, Atlanta, GA
David A. Garber, DMD, Atlanta, GA
Ronald E. Goldstein, DDS, FACD, FICD, Atlanta, GA
Barry D. Hammond, DMD, Augusta, GA
Steve D. Hoofard, CDT, AAACD, Hermiston, OR
Kenneth Hovden, DDS, AAACD, Daly City, CA
Nelson Y. Howard, DDS, AAACD, San Marcos, CA
Sang K. Jun, CDT, Monterey, CA
Michael J. Koczarski, DDS, AAACD, Woodinville, WA
John C. Kois, DMD, MSD, Seattle, WA
Gerard Kugel, DMD, MS, PhD, Boston, MA
Cobi J. Landsberg, DMD, Tel Aviv, Israel
David A. Little, DDS, San Antonio, TX
Robert A. Lowe, DDS, Charlotte, NC
Robert C. Margeas, DDS, Des Moines, IA
Frank J. Milnar, DDS, AAACD, St. Paul, MN
Ricardo Mitrani, DDS, MSD, Mexico City, Mexico
Carlos A. Munoz, DDS, MSD, Buffalo, NY
Thomas W. Nabors lll, DDS, AAACD, Nashville, TN
W. Peter Nordland, DMD, MS, La Jolla, CA
Adamo E. Notarantonio, DDS, FAACD, Huntington, NY
Aikaterini G. Papathanasiou, DDS, Boston, MA
Gary M. Radz, DDS, Denver, CO
Christopher D. Ramsey, DMD, AAACD, Jupiter, FL
Nelson A. Rego, CDT, AAACD, Santa Fe Springs, CA
Dwight G. Rickert, CDT, FAACD, Indianapolis, IN
Robert G. Ritter, DMD, Jupiter, FL
Matthew R. Roberts, CDT, AAACD, Idaho Falls, ID
Henry Salama, DMD, Atlanta, GA
Maurice A. Salama, DMD, Atlanta, GA
Michael R. Sesemann, DDS, FAACD, Omaha, NE
Shashikant Singhal, BDS, MS, Amherst, NY
Michael Sonick, DMD, Fairfield, CT
Rhys D. Spoor, DDS, AAACD, Seattle, WA
Thomas T. Teel, DDS, Fort Wayne, IN
Douglas A. Terry, DDS, AAACD, Houston, TX
Thomas F. Trinkner, DDS, AAACD, Columbia, SC
Eric Van Dooren, DDS, Antwerp, Belgium
Marcos A. Vargas, DDS, Iowa City, IA
Nondas Vlachopoulos, CDT, Athens, Greece
Dennis J. Wells, DDS, AAACD, Brentwood, TN
Barbara Warner Wojdan, CDT, AAACD, Oldsmar, FL
Carlo Zappalà, MD, DDS, Bergamo, Italy

EDITOR-IN-CHIEF — Edward Lowe, DMD, AAACD, Vancouver, BC, Canada, edwardl@aacd.com
EXECUTIVE DIRECTOR — Barbara J. Kachelski, MBA, CAE, barbk@aacd.com
CHIEF MARKETING OFFICER — Mike DiFrisco, CAE, michaeld@aacd.com
DIRECTOR OF PUBLICATIONS — Tracy Skenandore, tracys@aacd.com
EDITORIAL COORDINATOR — Denise Sheriff, denises@aacd.com
GRAPHIC DESIGNER — Erica Neumann, publications@aacd.com
EDITORIAL CONSULTANT — Juliette Kurtz, publications@aacd.com
CONTRIBUTING EDITORS — Brian J. Gilbert, DDS, AAACD, Las Cruces, NM
Julie M. Gillis, DDS, AAACD, Grand Junction, CO
Brenda K. Jennings, DDS, AAACD, Allen, TX
James H. Peyton, DDS, FAACD, Bakersfield, CA
Gregory B. Wright, DDS, FAACD, Southlake, TX

EDITORIAL MISSION

The mission of the *Journal of Cosmetic Dentistry* is to educate AACD members, as well as other professionals in the field, on the art and science of cosmetic dentistry. We will endeavor to do this by publishing well-researched, peer-reviewed articles accompanied by high-quality, comprehensive clinical imagery. The objective is to enhance readers' knowledge and skills while showcasing the latest cosmetic techniques and procedures. The *Journal of Cosmetic Dentistry* will strive to help readers become better clinicians, so they can offer their patients the best—and most responsible—treatment possible.

ADVERTISING POLICY

All advertising appearing in the *Journal of Cosmetic Dentistry* (*jCD*) is approved by the editorial team. Advertisements are not endorsed by the *jCD* or AACD.

AACD OFFICE

402 West Wilson Street, Madison, WI 53703
800.543.9220 • 608.222.8583
fax 608.222.9540 • info@aacd.com • www.aacd.com

Advertising: 800.543.9220 • 608.222.8583 or advertising@aacd.com
Editorial: 800.543.9220 • 608.222.8583 or publications@aacd.com

Reprints

High-quality reprints with possible customization are available for authors and advertisers. Please contact publications@aacd.com and the *jCD* editorial staff will work with you to get the exact reprint you would like for your presentations, lectures, or patient literature.

Journal of Cosmetic Dentistry 2020 • Volume 36 • Issue 3

A peer-reviewed publication and member benefit of the AACD
Peer-reviewed articles are denoted with the following symbol in the Table of Contents: ❖

Features

Column

2020 Statement of Ownership, Management and Circulation

Statement of Ownership, Management and Circulation, required by Title 39, United States Code 3685. Title of publication: *Journal of Cosmetic Dentistry*. Date of filing: September 24, 2020. Publication number: 1532-8910, USPS# 10452. Frequency of issue: quarterly. Annual subscription price: members, included in the membership dues; non-members/subscribers, $200.00 (US and Canada), $240.00 (all other countries) by the American Academy of Cosmetic Dentistry®, 402 West Wilson Street, Madison, WI, 53703. 800.543.9220 OR 608.222.8583. Periodicals postage paid in Madison, WI, and additional offices.

Mailing address of publisher: American Academy of Cosmetic Dentistry, 402 West Wilson Street, Madison, WI 53703. County: Dane. Name and address of the Editor: Edward Lowe, DMD, 402 West Wilson Street, Madison, WI 53703. Name and address of the Director of Publications: Tracy Skenandore, 402 West Wilson Street, Madison, WI 53703. Average number of copies each issue during preceding 12 months: Total number of copies (net press run): 5178; mailed outside-county paid subscriptions stated on PS Form 3541: 4433; paid distribution by other classes of mail through the USPS: 4; total paid distribution: 4437; free or nominal rate copies mailed at other classes through the USPS: 27; free or nominal rate distribution: 0; total free or nominal rate distribution: 27; total distribution: 4464; copies not distributed: 714; percent paid: 99. Number of copies of single issue published nearest to filing date: total number of copies (net press run): 4267; mailed outside-county paid subscriptions stated on PS Form 3541: 3493; paid distribution by other classes of mail through the USPS: 6; total paid distribution: 3499. Free or nominal rate copies mailed at other classes through the USPS: 13; free or nominal rate distribution outside the mail: 0; total free or nominal rate distribution: 13; total distribution: 3512; copies not distributed: 755; percent paid: 99. I certify that all information furnished is correct and complete. Signed Tracy Skenandore, Managing Editor.

Universatility:

The powerful feeling of the entire universe in one single bottle.

LEARN MORE

BUY 2, GET 1 FREE

PROMO CODE: 20AACD EXPIRES: 12/31/20

Discounts cannot be combined with any other offer. U.S. customers only: Limit one.
Rx Only

Let's bond! Give us a call:
1-800-247-3368 • www.bisco.com

BISCO

MC-10163AB

Journal of Cosmetic Dentistry 2020 • Volume 36 • Issue 3

A peer-reviewed publication and member benefit of the AACD
Peer-reviewed articles are denoted with the following symbol in the Table of Contents: ❖

Departments

American Academy of Cosmetic Dentistry®

AACD Mission Statement

The American Academy of Cosmetic Dentistry is dedicated to advancing excellence in the art and science of comprehensive cosmetic dentistry and encouraging the highest standards of ethical conduct and responsible patient care.

Member Publication AADEJ American Association of Dental Editors & Journalists

FSC www.fsc.org MIX Paper from responsible sources FSC® C008955

The *Journal of Cosmetic Dentistry* (ISSN 1532-8910), USPS (10452), published quarterly. $200 per year (U.S. & Canada) or $240 per year (All other countries), single issues available upon request, by the American Academy of Cosmetic Dentistry®, 402 West Wilson Street, Madison, WI 53703. 800.543.9220 OR 608.222.8583. Periodicals postage paid in Madison, WI, and additional offices.

POSTMASTER: send address changes to:
Journal of Cosmetic Dentistry
American Academy of Cosmetic Dentistry
402 West Wilson Street
Madison, WI 53703

Peer-reviewed articles are denoted in the Table of Contents with the following symbol ❖

Statements of fact and opinion are the responsibility of the authors alone and do not imply an opinion on the part of the officers of the AACD. Materials may not be reproduced without written permission. Contents© 2020 American Academy of Cosmetic Dentistry®

The *Journal of Cosmetic Dentistry* maintains signed patient release forms for all articles featuring clinical or other patient photography.

Are you paying too much for payment processing?

Contact us today about exclusive rates just for AACD members.

Hector M. Salas Jr, MBA
888-457-6262
hector.salas@usbank.com

usbank | Payment Solutions
powered by Elavon

Rebounding & Resilience

> "You...have discovered ways to rebound, reinvigorate, and reinvent yourselves to deliver optimal dental care and services to your patients and clients."

It is heartening to know that we are still managing to practice and thrive despite the ongoing impact of Covid-19. Although the pandemic has affected everyone's personal and professional lives, I am inspired by the resilience of my AACD colleagues in dentistry, dental laboratory technology, and dental product companies. You are all survivors and have discovered ways to rebound, reinvigorate, and reinvent yourselves to deliver optimal dental care and services to your patients and clients.

In this vein, be sure to take advantage of the AACD's resources such as its online open forum, MYAACD Network (network.aacd.com/home). It is there to provide you with a community of like-minded professionals, where no question is irrelevant or insignificant and all ideas are welcome. We AACD members hold ourselves to a higher standard and treat each other with mutual respect and admiration. Do not be afraid to ask anything, no matter how trivial you may feel the topic is. We will all learn from it.

In this issue of the *Journal of Cosmetic Dentistry* (*jCD*), I am pleased to introduce Dr. Calin Pop. Not only is he a remarkable dental photographer and clinician, but he also has truly taken the use of the rubber dam in dentistry to another level. His article will motivate you to reexplore the possibilities with this invaluable device. In addition, one of the pioneers of dental photography, Dr. Irfan Ahmad, presents the second part of his article on standardization for clinical and nonclinical dental photos. He is a genuine master of his craft.

It is vital that the *jCD* continue to publish important information from our dental schools. I appreciate the work of A.T. Still University-Missouri School of Dentistry & Oral Health faculty members Dr. Hesham Abdulkarim, Dr. Akshay Vij, and Dr. Dwight McLeod and their article regarding the value of CBCT and intraoral scans.

In closing, I want to thank my AACD colleagues Dr. Eric Hull and Dr. James Peyton, who share their experience and expertise with AACD Accreditation Case Type I; Dr. Kevin Brown and Dr. Ingrida Ivance, who demonstrate their conservative bonding techniques; and Dr. Andi-Jean Miro and Dr. Ilon Choai, who offer their perspectives on clinical photography.

As always, you can email me at edwardl@aacd.com to share your thoughts and ideas. Please stay safe and keep healthy!

Edward Lowe, DMD, AAACD
Editor-in-Chief

Legwork
Happiness delivered.

Are You Sitting on a **Gold Mine?**

Find the nuggets with our *Treatment Opportunities* dashboard.

- Help patients get the smiles they deserve
- Easily discover unscheduled treatment and fill your calendar
- Convert more presented and unscheduled treatment than ever before!

Ready to learn more?
Schedule a demo today!

Call us at: 877-311-4690 or
visit info.legwork.com/gold

Isolation Creation

By Calin Pop, DDS

Photography is an art of observation. And as such, dental photography can be our greatest critic, keeping us grounded by revealing our flaws and imperfections, thereby pushing us to do better.

Seen through the lens of a camera, microscope, or magnifying glasses, restorative dentistry soon becomes a satisfying—and addictive—creative process. Only after I discovered this did I begin to work differently, becoming focused purely on the result and losing track of time. When we add rubber dam isolation to this process, we set the stage for our work, which not only becomes more artistic and gratifying, but we also discover the ergonomics and practicality of these restorative procedures, performed in a safer manner.

Photography can be our best tool for communicating with patients, helping us to better explain their problems and showing how similar cases were successfully treated. Patients who understand the situation and the solution are more likely to feel involved and be motivated to accept treatment, especially important in cases requiring lengthy and complex therapies.

Finally, photography provides clarity in communicating with our laboratory technicians. A single photograph truly can express our intentions more accurately than a thousand words.

Cover image and Behind the Cover photographer: Calin Pop, DDS (Abu Dhabi, United Arab Emirates). Camera: Nikon D750 (Melville, NY) with a NIKKOR 105-mm macro lens and f/2.8, R1C1 dual flash (Nikon), PhotoMed brackets (Van Nuys, CA), and Interfit Modi-Lite Softboxes (Atlanta, GA).

Please turn to page 32 to read Dr. Pop's cover feature article.

"Dental photography can be our greatest critic, keeping us grounded by revealing our flaws and imperfections, thereby pushing us to do better."

LOOKING FOR THE QUINTESSENCE OF

DENTAL PHOTOGRAPHY?

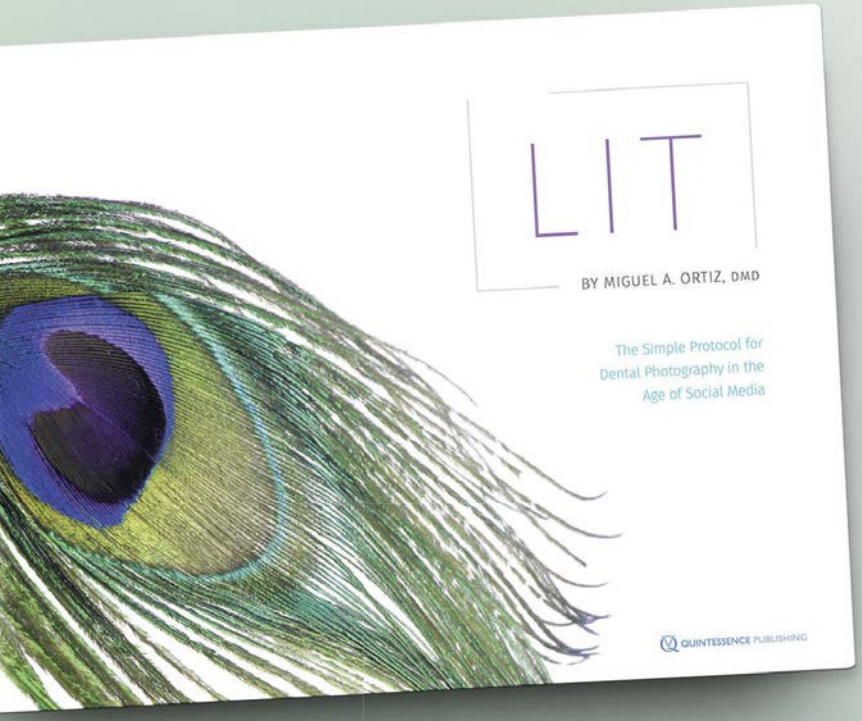

Learn it

Breathtaking artistic volume showcasing photography principles. Who says education can't be beautiful?

Miguel A. Ortiz
248 pp; 357 illus; ©2019;
ISBN: 978-0-86715-802-1;
B8021; **US $148**

Shoot it

Shot-by-shot guide recommending equipment, specs, and tips. A must-have for you and your staff.

Krzysztof Chmielewski
59 pp; (spiral bound with slipcase);
64 illus; ©2016; ISBN: 978-1-85097-297-6;
BG120; **US $98**

QUINTESSENCE PUBLISHING service@quintbook.com www.quintpub.com

LOOK NO FURTHER.



Apply it

Bring your newfound knowledge into your dental office with practical guidelines, no matter your specialty.

Mirela Feraru and Nitzan Bichacho
248 pp; 556 illus; ©2018; ISBN: 978-1-78698-004-5;
BG128; **US $158**

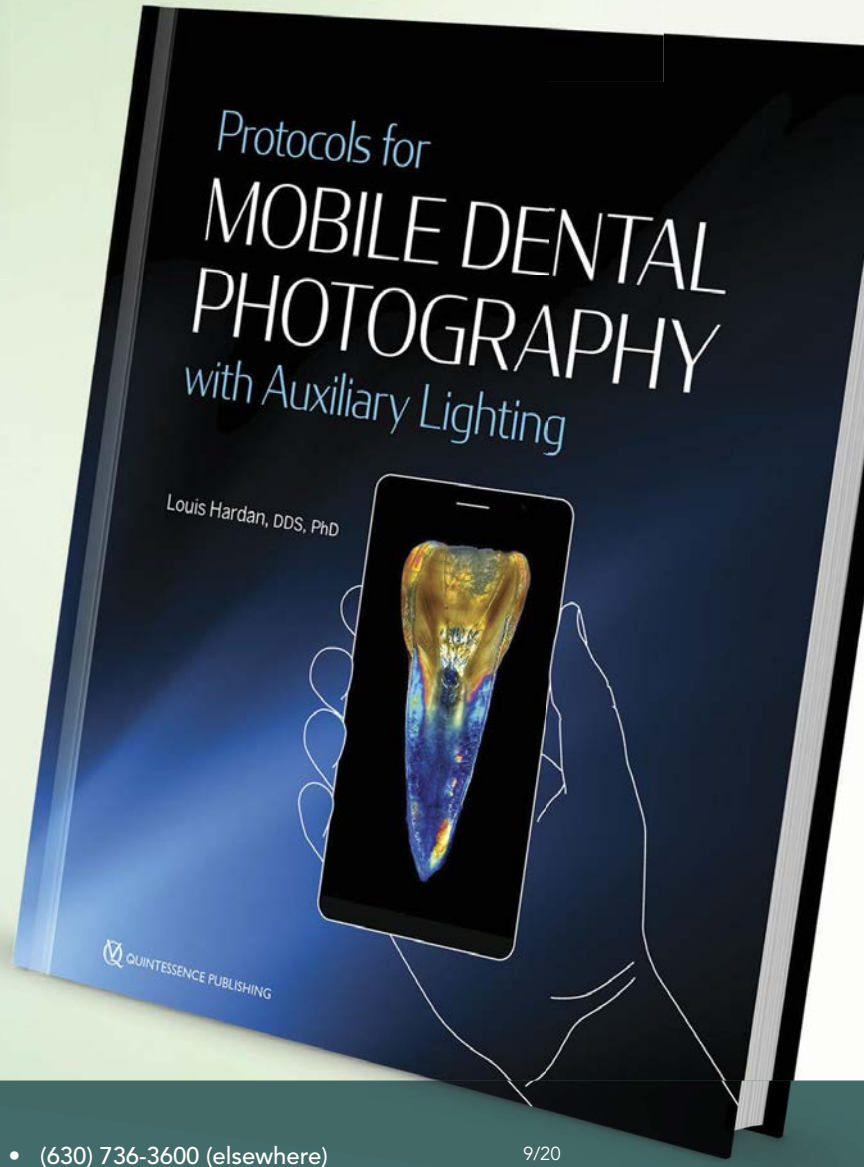

Make it

All of the above—now on your phone.

Louis Hardan
128 pp; 315 illus; ©2020;
ISBN: 978-0-86715-946-2;
B9462; **US $75**

COLLECT THEM ALL!

(800) 621-0387 (toll free within US & Canada) • (630) 736-3600 (elsewhere)

9/20

Utilizing Photography and a Diagnostic Wax-Up as Pillars of Success with Porcelain Veneers

Eric D. Hull, DDS, AAACD

Abstract

Patients today desire a smile in which both the teeth and healthy gums improve the overall facial esthetics. To achieve an optimal esthetic outcome, communication and treatment planning are vital. Digital photography and the diagnostic wax-up are extremely effective tools for achieving a proper level of communication between the clinician and a highly skilled laboratory technician. When using smile design principles to improve esthetics, it is critical to pay close attention to function. It is only when both esthetics and function are properly addressed that an ideal outcome can be achieved.

Key Words: diagnostic wax-up, porcelain veneers, digital photography, smile design, gingival symmetry, Accreditation Case Type I

> With the tooth positions and gingival heights determined, the wax-up was used to focus on proper axial inclination, embrasures, emergence profile, labial contour, and tooth proportions.

Figure 1: The diagnostic wax-up is an excellent way to communicate with the lab technician regarding the restorations' desired contour and anatomy.

Figure 2: Preoperative full-face frontal view (1:10) showing uneven and discolored bonding.

Figure 3: Preoperative frontal smile view (1:2).

Introduction

When multiple indirect restorations are being considered, an ideal end result can be realized only with a proper marriage between esthetics and function.[1] It therefore is important to take into account three different factors: the teeth, the gingival tissue, and overall facial esthetics.[2] A series of digital photographs and a diagnostic wax-up are essential for communication with the laboratory technician **(Fig 1)**. The patient's lip line and facial dynamics will determine a proper position for the teeth. Once this is established, it is important to ensure that proper function is achieved. Finally, the treatment plan should ensure that the gingival contours are idealized.

Case Presentation

Patient Complaint and History

The patient, a 24-year-old female, was unhappy with her smile **(Figs 2 & 3)**. Bonding had been completed approximately eight years prior to close spaces between the teeth due to tooth size discrepancy. The composite bonding had become chipped and stained over the past few years. The patient wanted a smile with no visible stains or chips on any of her teeth. She was not interested in more composite bonding, opting instead for treatment with porcelain veneers for a more permanent and more esthetic solution.

Evaluation, Diagnosis, and Treatment Plan

To properly evaluate and diagnose this case, the AACD series of Accreditation photographs were taken, and diagnostic models were obtained. The first step in treatment planning was to determine the incisal edge position. Based on the relationship of the patient's cuspids to the lip line in repose, the incisal edge position of the cuspids was kept where it was.[3] A proper smile line in the wax-up was created by ensuring the central incisors were not shorter than the canines.

The posterior teeth fit well with the patient's lip line and filled out the buccal corridor nicely, so they did not need to be restored. With the position of the maxillary arch established, the mandible was then evaluated to ensure that there would be no functional concerns with the new restorations.[4] Clinically, the mandibular anterior teeth showed no visible signs of wear, with mamelons present. No joint pain or pathology was noted. The patient's bite felt comfortable, with simultaneous bilateral contacts on the posterior teeth. There were no signs of any functional or parafunctional bite issues, so the current position of the teeth in the mandible was not a concern.[5]

Figure 4: The level of the gingival height can be evaluated in the preoperative retracted view (1:2).

Figure 5: Preparation design, stump shade selection, and cord packed ready for the impression.

Figure 6: The temporary restorations helped give the patient an opportunity to "test drive" her new smile.

Figure 7: Retracted frontal view (1:2) of the temporary restorations, displaying well-fitting margins and symmetrical gingival contours.

The gingival heights of the maxillary anterior teeth (#6-#11) were even and in a straight pattern, with the exception of the left lateral incisor (#10). The tissue height of #10 was too low and lacked symmetry with the tissue height of #7 **(Fig 4)**. Bone sounding was completed, and it was determined that the distance from the gingival height to the bone crest on #10 was approximately 3.5 to 4.0 mm. To obtain symmetry with the gingival heights of #7 and #10, it was determined that minor closed-flap osseous recontouring would be necessary.[6]

The final phase of treatment planning involved using the diagnostic models to wax up the case. With the tooth positions and gingival heights determined, the wax-up was used to focus on proper axial inclination, embrasures, emergence profile, labial contour, and tooth proportions. The wax-up was vital, since it was used to make the provisional restorations and allowed a functional and esthetic assessment of the treatment plan before proceeding to the final restorations.[7]

Treatment

Gingival symmetry: With the diagnostic phase and wax-up complete, treatment began. Gingival symmetry was addressed first. A diode laser (Epic, Biolase; Irvine, CA) was employed to remove 2 mm from the gingival height of #10. Closed-flap osseous recontouring of the bone crest was completed with a chisel (KB-1, Brasseler; Savannah, GA).[6] The bone crest was placed 2.5 mm from the new gingival height of the contour. The diode laser was then used to idealize the shape of #7's gingival crest and to help idealize axial alignment.[8] Teeth #6-#11 were then prepared for indirect veneers (IPS e.max, Ivoclar Vivadent; Amherst, NY).[9] All the chipped and worn composite was removed. A putty guide (Flexitime, Kulzer; South Bend, IN) created from the wax-up was used to analyze the preparation depth **(Fig 5)**.[10] The gingival margins of the preparations were placed directly at the gum line. A #000 cord (Ultrapak, Ultradent Products; South Jordan, UT) was placed, and the margins were reduced an additional 0.5 mm. This ensured that the margins would be placed slightly subgingivally while not violating the biologic width.[11]

Temporaries: A polyvinyl siloxane (PVS) impression was taken (Aquasil Ultra, Dentsply; Charlotte, NC) of teeth #6-#11. The temporary restorations were made from a putty matrix based on the wax-up. The teeth were spot-etched with a 32% phosphoric acid semi-gel etchant with benzalkonium chloride (Uni-Etch, Bisco; Schaumburg, IL) and bonded (Scotchbond Universal, 3M; St. Paul, MN) while light-cured luting cement (Choice 2, Bisco) was used to cement the temporary restorations. Since this element allowed for a trial run of the new smile design, a significant amount of time was spent ensuring

Figure 8: During the initial try-in of the veneers, the contour and anatomy were not ideal, and the case was sent back to the lab.

Figure 9: Postoperative smile view (1:2) showing excellent symmetry and color match.

Figure 10: Postoperative retracted view (1:2) showing nice anatomical form and even gingival contour.

the final polish and form of the provisional restorations. The last restorative procedure was to confirm that the temporary veneers were secure and not causing a functional issue by constricting the bite.[12] While sitting at a 45-degree angle, a blue 200-µ horseshoe-shaped articulating paper (Bausch; Nashua, NH) was used to analyze the bite. There were no blue streaks or excessive forces placed on the lingual edges of the maxillary incisors.

Bleaching and evaluation period: The patient continued to bleach (at-home bleaching with a 16% carbamide peroxide gel [Philips Zoom NiteWhite, Philips Zoom; Stamford, CT] had begun after the initial study models were taken) while still wearing the temporary restorations. A follow-up appointment was scheduled for three weeks later. The patient had stopped bleaching for a two-week period to take final shade photos for the ceramist. During the additional time with the temporary restorations, the patient came in for evaluation of her smile and to take photographs. This evaluation period and the additional photography provided vital pieces of communication. The ceramist was able to use the initial photos, the wax-up, and the photographs of the temporary restorations to fabricate the final restorations **(Figs 6 & 7)**.

Try-in appointments: At the initial try-in appointment, the temporary restorations were removed, and the porcelain veneers were tried in with try-in paste (Choice 2). Photographs were taken to evaluate the restorations. At this initial try-in, there were some minor issues with line angles, tooth anatomy, and tooth contours that had to be addressed.[13] It was decided that the restorations needed to look more lifelike and natural, and that they should harmonize better with the natural posterior teeth **(Fig 8)**.

At the second try-in, it was agreed that the restorations met the esthetic criteria for clinical excellence and patient satisfaction. The margins and contacts were verified, and the restorations were bonded (Clearfil Liner Bond2V Primer, Photo Bond Catalyst, Porcelain Bond Activator, Universal Bonding Agent, Kuraray America; New York, NY) into place **(Figs 9 & 10)**.

Tooth preparation for bonding: The teeth were prepared for bonding as follows:

- temporary veneers were removed
- teeth were microabraded (PrepStart unit, dry, Danville; San Ramon, CA) at 40 psi pressure with 27-µ aluminum oxide particles (Zest Dental Solutions; Carlsbad, CA)[14]
- tissues were retracted with gingival retraction paste (Expasyl, Acteon; Mount Laurel, NJ) and checked to ensure there was no gingival bleeding
- teeth were rinsed with water and air-dried
- plumber's tape was placed on the adjacent teeth to protect them from any etch/bond that was placed
- etchant was placed, rinsed, and air-applied to the teeth
- primer was placed (Liquid A and liquid bottles of Clearfil Liner Bond 2V) and air-dried
- bond was placed, air-dried, and light-cured (Clearfil Photo Bond, Activator and Catalyst mixed with Universal).

Restoration preparation for bonding: The steps taken to prepare the restorations for bonding were as follows:

- cleaning paste (Ivoclean, Ivoclar Vivadent) was used after the try-in
- four coats of silanate (RelyX Ceramic Primer, 3M) were added, with each coat being allowed to dry individually
- bonding agent (Clearfil Photo Bond Catalyst, Porcelain Bond Activator, Universal Bonding) was placed on the restoration
- light-cured luting cement (Choice 2, Milky Bright) was placed.

After cementation, the occlusion was verified. Bausch 200-µ horseshoe articulating paper was used to verify there was no constricted envelope of function.[12]

Figure 11: Postoperative portrait view.

Figure 12: Happy patient with her beautiful new smile.

Summary

A smile design case must be built upon sound treatment planning. Establishing the ideal esthetic position of the maxillary anterior teeth based on the patient's facial esthetics is the proper starting point. From there, the clinician can properly determine the position of the maxillary posterior teeth and the mandibular teeth based on smile design principles and function. Digital photography and a diagnostic wax-up allow the treatment plan to come to life **(Figs 11 & 12)**.

Acknowledgments

The author thanks Sandra Stassen, CDT (Pierson, MI), for her collaboration and ceramic artistry on this case. He also thanks Deb Martin, RDA, for her help with the clinical photographs in this article and assistance with his Accreditation cases. Thanks also go to Dave Burgess of Studio 616 Photography (Grand Rapids, MI) for his beautiful portrait photography.

References

1. Sesemann MR. Enhancing facial appearance with aesthetic dentistry, centric relation, and proper occlusal management. Pract Proced Aesthet Dent. 2005 Oct;17(9):615-20.

2. Arnett GW, Gunson MJ. Facial analysis: the key to successful dental treatment planning. J Cosmetic Dent. 2005 Fall;21(3):20-33.

3. Misch CE. Guidelines for maxillary incisal edge position—a pilot study: the key is the canine. J Prosthodont. 2008 Feb;17(2):130-4.

4. Kois DE, Kois JC. Comprehensive risk-based diagnostically driven treatment planning: developing sequentially generated treatment. Dent Clin North Am. 2015 Jul;59(3):593-608.

5. Kois JC, Hartrick N. Functional occlusion: science-driven management. J Cosmetic Dent. 2007 Fall;23(3):54-7.

6. Bakeman EM, Kois JC. Myths vs. realities: considerations in esthetic crown lengthening. J Cosmetic Dent. 2014 Summer;30(2):54-62.

7. Bakeman EM. Provisional restorations for veneer preparations. Funct Esthetics Restor Dent. 2008 May;2(2):16-22.

8. Chu SJ, Tan JHP, Stappert CFJ, Tarnow DP. Gingival zenith positions and levels of the maxillary anterior dentition. J Esthet Restor Dent. 2009;21(2):113-20.

9. Castelnuovo J, Tjan AH, Phillips K, Nicholls JI, Kois JC. Fracture load and mode of failure of ceramic veneers with different preparations. J Prosthet Dent. 2000 Feb;83(2):171-80.

10. Kois JC. New paradigms for anterior tooth preparation: rationale and technique. Dental Learning Systems Special Edition: Contemporary Esthetic Dent. 1996;2(1):1-8.

11. Kois JC. The restorative-periodontal interface: biological parameters. Periodontol 2000. 1996 Jun;11(1):29-38.

12. Bakeman EM, Kois JC. The myth of anterior guidance. J Cosmetic Dent. 2012 Fall;28(3):56-62.

13. Sesemann MR. Understanding appropriate line angles to optimize smile design restorations. J Cosmetic Dent. 2017 Fall;33(3):66-75.

14. Chaiyabutr Y, Kois JC. The effect of tooth-preparation cleansing protocol on the bond strength of self-adhesive resin cement to dentin contaminated with a hemostatic agent. Oper Dent. 2011 Jan-Feb;36(1):18-26. **jCD**

Dr. Hull practices in Comstock Park, Michigan, and is an Accredited Member of the American Academy of Cosmetic Dentistry.

Disclosure: The author did not report any disclosures.

Raise your hand

if you want to improve your

esthetic dental skills.

The first step to **achieving the AACD Accreditation process is taking** the written exam, **now available** at a testing center near you.

AACD American Academy of Cosmetic Dentistry®

VISIT: AACD.com/firststep

Case Type I: Achieving Excellent Results with Six Indirect Veneers

James H. Peyton, DDS, FAACD

> "The goal is for the patient to feel comfortable and confident when smiling."

AACD Accreditation Case Type I (six or more anterior indirect restorations) is unquestionably a smile design case. The restorations should look natural, and the smile line should evenly follow the border of the lower lip. The goal is for the patient to feel comfortable and confident when smiling.[1]

To achieve an excellent result with Case Type I, there must be effective communication between the restorative dentist and the laboratory technician. This communication should start early in the process so the technician can see the case before any tooth preparation is done. The dentist should take Accreditation photos, create study models, and evaluate the gingival health and position. The laboratory can do a diagnostic wax-up to give the dentist an idea where the teeth should be placed and how they should be anatomically shaped. The wax-up can also be helpful for designing temporary restorations that mimic the shape of the final restorations. This gives the patient a chance to approve the final restorations and get used to their contour, shape, and position. Conversely, if the temporary restorations do not feel or look good to the patient, they can easily be contoured and reshaped until the patient is comfortable. The chances of the patient being satisfied with the final restorations are therefore significantly improved **(Figs 1 & 2)**.[2,3]

Dr. Hull did a commendable job of restoring teeth #6-#11 with porcelain veneers. There was excellent communication with the laboratory technician, and the dentist, the technician, and the patient were all extremely satisfied with the results.

Figure 1: The preoperative frontal smile view (1:2) shows uneven and discolored bonding that did not look natural.

Figure 2: The diagnostic wax-up provides valuable information for the creation of proper tooth shape and form.

As in all Accreditation cases, however, the results were not perfect, and the following flaws were noted by the examiners:

- **Criterion #43:** *Have the line angles been properly developed?* One of the examiners felt that #6 and #11 were slightly bulky.
- **Criterion #67:** *Is the tooth preparation inappropriate or excessive?* One of the examiners believed that the tooth preparations were excessive.
- **Criterion #71:** *Is the periodontal health optimal?* Several of the examiners noted that there was minor tissue inflammation.

Figure 3: The postoperative frontal smile view (1:2) shows a very attractive and natural-looking smile.

Gingival health is one of the most common reasons why points are deducted in Accreditation cases. This reflects the importance of maintaining, or even improving, the health of the gingival tissues. Overall, Dr. Hull did a fine job, and his case was worthy of passing Accreditation **(Fig 3)**.

References

1. American Academy of Cosmetic Dentistry (AACD). A guide to Accreditation criteria. Madison (WI): AACD; 2014.

2. Hastings JH. Laboratory communications: essential keys to exceptional results. J Cosmetic Dent. 1998 Winter;13(4):22-30.

3. Peyton JH. Truly a smile design case. J Cosmetic Dent. 2014 Spring;30(1):30-1. **jCD**

Dr. Peyton is an AACD Accredited Fellow and has been an AACD Accreditation Examiner since 2000. A part-time instructor at the UCLA School of Dentistry, he practices in Bakersfield, California.

Disclosure: The author did not report any disclosures.

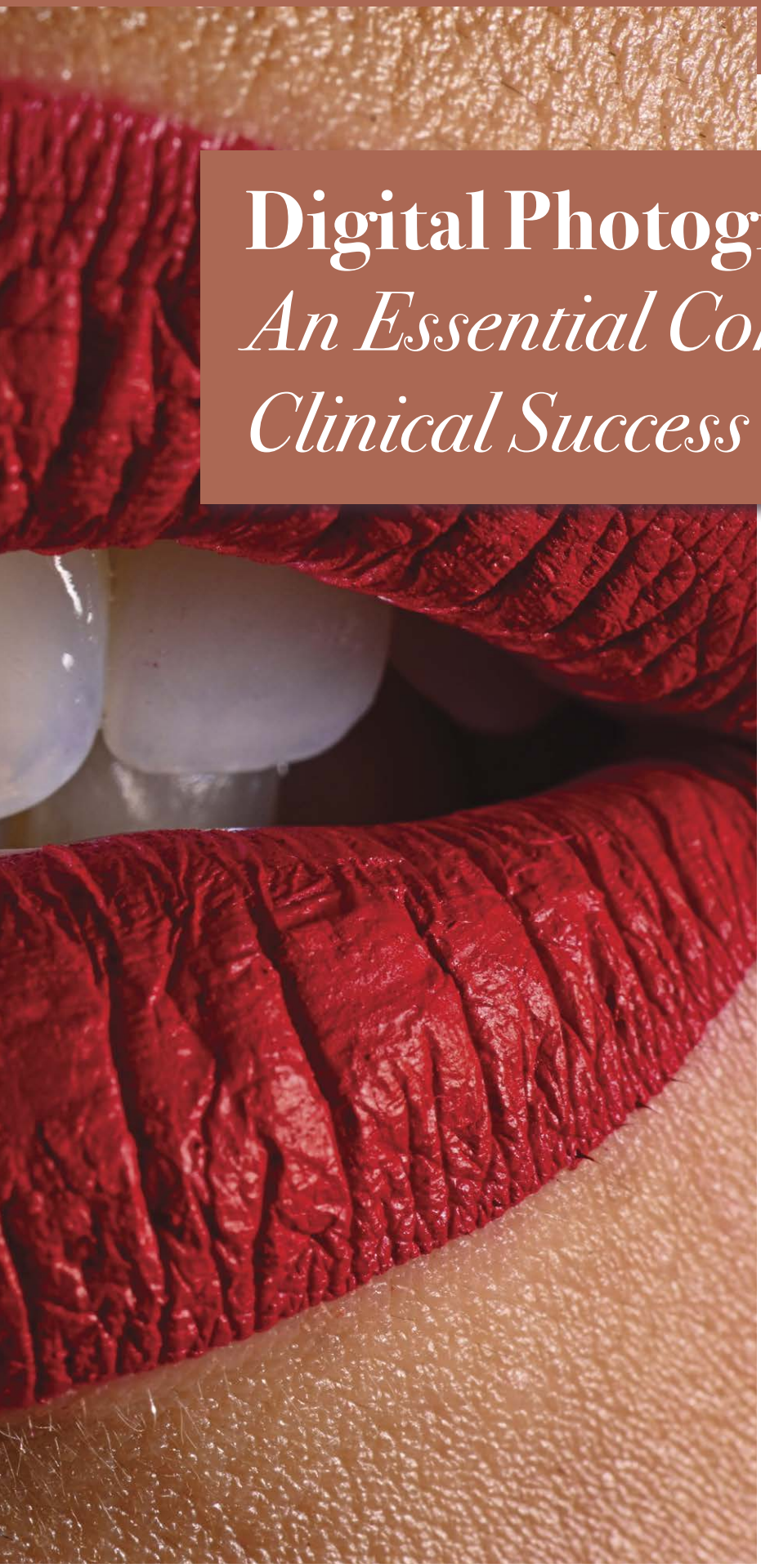

Digital Photography
An Essential Component of Clinical Success

Andi-Jean Miro, DDS
Ilon Choai, DDS

Abstract
There are a variety of cameras on the market today, and new practitioners can be overwhelmed when trying to choose the one that is best suited to their needs. This article describes how to document a case utilizing high-quality dental photographs for optimal treatment planning, documentation, and self-evaluation. It outlines the fundamental principles to understand when using a camera for dental photography and provides information about camera setups and accessory options.

Key Words: Dental photography, camera setup, camera body and lens, camera settings, light source, photo guidelines, shade communication

Bonus content!

This article has a CE course on AACD CEntral. To view, go to AACD.com/central

Introduction

The rise of social media and technological advances have exposed us to a side of dentistry that was never imagined. Our profession has evolved and expanded to a global network of colleagues who share their work with peers and patients alike. Many find themselves on Instagram scrolling through beautiful case photos asking, "How do I even begin taking a picture like that?" In some cases, this exponential increase in exposure to our colleagues' work can push us to improve, but it also can cause us to feel inferior, or even defeated. Dental photography, while not part of the core dental education, is essential not only to creating beautiful smiles but also for self-evaluation, case documentation, patient education, and marketing.[1] Fortunately, learning the skill is within reach provided one has the will to learn.

Lessons

Demystifying the Camera Setup

The setup that most practitioners gravitate toward is a digital single-lens reflex (D-SLR) camera.[2] This type of camera must be viewed as a system rather than a product. Components of the system are purchased individually but work in tandem to create stunning images. The three main components of a DSLR camera are the lens, body, and flash.

Lens: The lens is the camera's "eye," and as it is primarily responsible for the quality of the images, it is the most important investment. Since we are capturing the minute features of the oral cavity, we want a lens that can focus up close while maintaining the highest level of detail. A macro lens has the optics for preserving this detail. Because our photos must be standardized (i.e., we will be documenting in a way that is consistent, the same distance from the subject) we should use a fixed lens. This means that the focal length cannot be adjusted (i.e., the level of "zoom" cannot be changed). To achieve the appropriate "zoom," we must move closer or farther from the subject, rather than adjusting the zoom on the lens.[3,4]

> *"By using a fixed macro lens, we are able to standardize our photography by maintaining a consistent distance from the patient, light source, and position."*

When first diving into dental photography, it is wise to invest in the lens first. Buying a high-quality lens that you can use as you upgrade your camera body is key to investing long term in a dental setup that will grow as your photography skills improve. You eventually may consider upgrading the camera body for one with more features, and as long as you have a high-quality lens you will not sacrifice the image quality.

Light source: A light source often is an overlooked investment. Lighting systems come in all shapes and sizes, but ultimately provide us with the same goal: illuminating the dark and wet oral cavity. The most common options are ring lights and dual flash setups. Depending on the type of dentistry you hope to capture, the type of light source will differ. If your practice is more surgery based, you may want to consider having a ring flash as it will position light posteriorly in the oral cavity. If your practice is more cosmetic based and you do a lot of shade matching, having a dual (twin) flash option is preferable because it allows you to position the light more laterally on the teeth, enabling the camera to capture more information about light scatter, texture, depth of shade, opacity and translucency of the teeth, while avoiding shadows.[3,5,6]

Mirrorless cameras: Many practitioners ask about these cameras, and with good reason. The main difference between a DSLR camera and a mirrorless camera is the way the image is captured and displayed. In a DSLR camera, the image bounces from a mirror to the viewfinder. In a mirrorless camera, the image is displayed directly into the sensor. Why is this important? The lack of a physical mirror reduces the size and weight of the camera body and provides features such as improved video recording and improved autofocus. Currently, dental photography is not significantly impacted by the advances found in mirrorless cameras, but they will certainly become the standard in the next decade. One last thing to consider before buying a mirrorless camera is that they have different lens mounts. This means the lens selection is much more limited compared to DSLR lenses. Adaptors exist to retrofit a traditional lens to a mirrorless camera, so careful consideration is recommended before choosing a mirrorless camera.

Choosing a Camera Body and Lens

Brands: Before delving into the inner workings of a camera, it should be noted that there is a distinction between brands. The two major digital camera manufacturers today are Canon and Nikon. Each has its own proprietary complement of lenses and flash systems that accompany the camera body. Components of Canon and Nikon systems are not interchangeable but there are several other lens and light system brands that can act as alternatives to the name brand lens and lights, including SIGMA, Cameron, and Tokina. Each of these brands makes a lens for both the Nikon and Canon camera system.

The body of the DSLR camera is the camera's "brain." The lens projects the image on the sensor of the camera body, where it is then displayed on the screen and stored on the SD card. You will interact with the body by adjusting the functions of the camera such as the f-stop, the ISO, the white balance, and the



Figure 1: A small aperture (larger number) is beneficial because it gives us a large "depth of field."

shutter speed. Camera bodies range in price from $200 to $6000 U.S. dollars, depending on the internal features and quality of the camera's internal sensor, which is what captures the image projected from the lens. Think of it as a reusable piece of film that captures each image on a digital format.[3,4]

Sensors: Each camera body has a different sensor, some of which are larger than others. The larger the sensor, the better the image quality. Most affordable options have what is called a "crop sensor," seen on spec sheets as APS-C. This simply means that the sensor is smaller. The more expensive options typically have full-frame sensors. The difference between crop and full-frame sensors and how it impacts dental photography is important because for a camera with a crop sensor you would have to move farther away from a patient to capture the same image that a full-frame sensor would capture at a closer distance. Typically, when starting out in dental photography it is ideal to start with a more affordable camera body and spend the bulk of your budget on the lens and light source. Once you are comfortable taking high-quality dental photographs you can update and upgrade your camera body to one with more features as your passion for dental photography grows.

Fixed macro lens: As mentioned previously, it is important to use a macro lens that has a fixed focal distance. The focal length of a lens is defined as the distance in millimeters from the optical center of the lens to the focal point on the sensor. This is important in dental photography because by using a fixed macro lens, we can standardize our photography by maintaining a consistent distance from the patient, light source, and position. The alternative to a fixed lens is a zoom lens. While a zoom lens provides versatility in focal lengths, it is not ideal for the dental office setting. Fixed lenses provide much more accurate photos, whereas zoom lenses' moving components can cause distortion.

Macro lenses are available in different focal lengths. Nikon has both 105-mm and 85-mm macro lenses. Canon has a 100-mm and a 60-mm macro lens. These lenses are all capable of providing high-quality images; however, lenses with smaller focal lengths will require a lesser distance between the lens and the patient. A good rule of thumb sticks close to 100-mm focal length (i.e., 105-mm and 85-mm lenses are similar, but a 60-mm lens will likely prove uncomfortable for intraoral photographs).

Many macro lenses include an adjustable dial for the focus ratio. These ratios relate to a fixed distance from the optical center of the camera to the patient. Setting this ratio will also create images that are cropped similarly from before to after treatment. For example, if you are taking a full-face image, the ratio set on the lens would be 1:10 for a full-frame sensor (or 1:15 for a crop sensor). This equates to shooting the image 7 to 10 feet away from the patient depending on the size of the sensor. Setting the ratio each time before taking a photograph and using your body to move in and out allows the image to come into focus and will allow you to take consistent images each time.

Settings: Aperture, Shutter Speed, ISO

The body of the camera controls three main features that directly impact the images we capture. These three features are the aperture (f-stop), ISO, and shutter speed. Adjusting these settings allows for some flexibility, but in order to adjust them, they must first be understood.[5,7]

Aperture: The lens aperture is the opening where light travels to the camera sensor. The size of this opening can be changed, where it directly affects the image. A large aperture has a smaller number, and vice versa. The larger the aperture, the bigger the opening, the more light that is being let in. A larger aperture is desirable in certain contexts, but our setup has a flash, so we do not need a large aperture to let in light. A small aperture provides a large depth of field (DOF) **(Fig 1)**, the area of the image that is in focus. For intraoral photos, we want all teeth in focus, not just the anterior dentition. Therefore, a small aperture is beneficial.

When taking extraoral full-face photographs we must be approximately 7 to 10 feet from the subject to have the image in focus. The camera and the light source are far from the subject

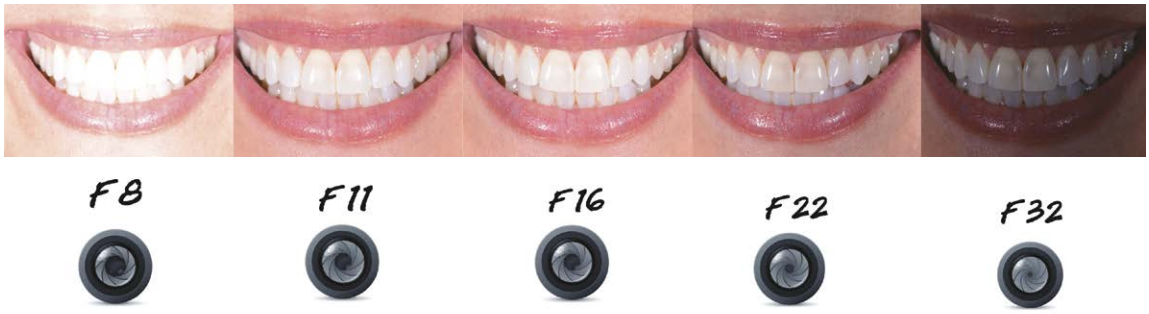

Figure 2: Increasing the number from f/8–f/11 to f/22–f/25 will allow the flash to properly illuminate the subject as well as capture the details with increased depth of field.

Figure 3: A longer shutter speed lets in larger amounts of light for extended periods of time; this is great in low-light situations for nondental photography.

and because of this we want to open up the f-stop (f/8 to f/11), allowing more light to pass into the sensor to capture the image properly illuminated and framed. When moving to extraoral and intraoral close-up photos, the camera body as well as the light source are closer to the subject. It is important to close down the f-stop, increasing the number from f/8–f/11 to f/22–f/25. This will properly illuminate the subject as well as capture the details with increased DOF **(Fig 2)**.

Shutter speed and ISO: While aperture adjusts the amount of light being let through the opening of the lens, shutter speed is the amount of time the camera spends allowing light into the sensor. The shutter speed could be as fast as 1/8000 of a second or as long as 30 seconds. A longer shutter speed would let in larger amounts of light for extended periods of time; this is great in low-light situations for nondental photography **(Fig 3)**. It is important to note that the longer the shutter speed, the higher likelihood a blurry image will be captured. Many times, when fluctuating the shutter speed most photographers set up a tripod to stabilize the camera so that a blurry image is not produced. In dental photography, we want to allow the shutter speed to be fast enough to get a properly exposed image. Changing the shutter speed can have an effect on the exposure as well. However, it is more predictable since we are not using a tripod to capture dental photos that we limit the amount of time the shutter is opened and use the f-stop to change exposure predictably. Typically, we will set the shutter speed to 1/125 of a second for dental photographs.[3,4,8]

It is important to note that ISO technically is not part of the image exposure, but it has a major impact on the result of the image. The higher the ISO, the more sensitive the camera is to light. If you turn the ISO value all the way up, the images will be extremely bright. This is helpful if you are taking pictures in a dark environment. Since our setup has a light source, we do not need to rely on ISO to brighten our images. For this reason, we typically set the ISO for all dental photographs to 125 and instead change the amount of light by adjusting the aperture.[6]

Light Sources

There are two types of flash systems: on-camera and off-camera. The latter includes any lights that wirelessly connect to the camera, similar to what is used at graduation photo studios.

On-camera flashes—ring flash, dual (twin) flash: On-camera flashes are more convenient for dental photography. These flash systems are physically tethered to the camera and provide light in close proximity to the lens. A ring flash falls into this category and is a great option for capturing surgical procedures and posterior areas of the mouth because the light is projected parallel to the lens. The downside to this light system, however, is that it creates a washed-out image that lacks texture and may not capture information that is important when shade-matching teeth. A dual (twin) flash system comprises two lights that are set to either side of the lens. This type of lighting system is excellent for relaying detailed information on color, texture, and translucency. The ability to adjust the

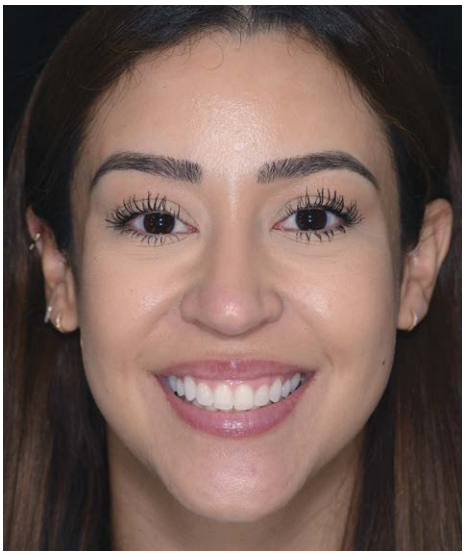

flashes away from the lens allows more flexibility when it comes to the types of images you want to capture. When photographing the anterior region for esthetic dentistry it is crucial to have a twin flash system.

The benefit of twin flashes is even greater when using an adjustable bracket, which enables flexibility of the flash position. Companies such as PhotoMed have bracket systems for both Nikon and Canon cameras that mount the twin flashes to a bracket, away from the lens. This allows you to position the flash for intraoral views or separate them further apart for anterior esthetic views and lab communication.

Recommended Photo Views

The American Academy of Cosmetic Dentistry suggests a specific set of photos that should be taken prior to beginning any dental treatment.[9] Remember, there is only one chance to take a "before" photo. Many practitioners wish they had taken better photos prior to treatment. With that said, it is recommended to take many pretreatment photos prior to starting any treatment on a patient **(Fig 4)**.

Figure 4: The AACD's 12 recommended photos that should be taken prior to any dental treatment.

Table 1. Tips for Capturing Ideal Images

Type of Photo	F - Stop	Lens Ratio Full-frame | Crop	Tips
Natural full face	f/8 to f/11	1:10 | 1:15	The image should be framed including the top of the head and a bit below the chin. The patient should show a full smile utilizing the interpupillary line and vertical midline to orient the face so that it is not tilted left or right, up or down. Position the patient so there are no shadows on the background.
Natural full smile	f/22 to f/28	1:2 | 1:3	The image should show a full natural smile revealing the maximum number of teeth that the patient displays. The incisal plane of the teeth should be reflected in this image. If there is a cant present, be sure to capture this in the close-up photo as it appears in the full face. Focus on the centrals. The lips should not be cropped out of the image.
Right & left lateral smile	f/22 to f/28	1:2 | 1:3	The focus should be the lateral incisor. You want to see a bit of the contralateral lateral and canine.
Retracted teeth slightly parted front, right, & left	f/22 to f/28	1:2 | 1:3	Upper and lower teeth should be slightly parted so the incised edges are visible. Minimize the appearance of lips and retractors and position.
Maxillary anterior sextant front, right & left	f/22 to f/28	1:1 | 1:1.5	No retractors should be visible and only 4 to 6 teeth should be in the frame.
Maxillary & mandibular occlusals	f/22 to f/28	1:2 | 1:3	Draw a line down the incisal edge of the central incisors showing equal parts of the buccal and lingual of the incisors. Take the image 45 degrees to the mirror. Positioning for these images is key. When taking the maxillary occlusal photo, I have my assistant hold the mirror and have the patient lie down completely on their back, tilt their head back and place retractors in their mouth, then shoot down from behind the patient. For the mandibular occlusal shot, I have my patient tip their chin up all the way, have my assistant hold the mirror, stand on the front side of the patient, then shoot upwards to take the photo.

Table 1 gives an overview of each type of photo in detail. The following settings should not change: ISO 125, shutter speed 1/125. F-stop will vary depending on the shot you want to capture.

Common Errors

Incorrect exposure: Some of the most common errors in dental photography can be corrected by recognizing them early and adjusting accordingly. An error many doctors struggle with is capturing an image at the wrong exposure. A dark photo is the "preferred" mistake because the information is still preserved in the digital file. The photo can be edited on the computer to brighten the image while maintaining the integrity of the shot. However, an overexposed photo lacks information. A shot that looks "blown out" that is overly white cannot be salvaged. That brightness should be viewed as lack of information, whereas darkness in an image can be brightened.[4,8]

Improper angle: Another common issue are images taken from an improper angle **(Fig 5)**. Unfortunately, this mistake cannot be corrected after the fact. It is crucial when taking each photo that you position yourself properly to obtain the perfect shot each time. Angulation and positioning are critical elements to achieving a diagnostic photo. When taking extraoral and intraoral photos, be mindful of the spatial relationship between the camera and the patient. Note the height of the patient relative to the camera, as well as the angle at which the camera is facing. It becomes easier with time, but do not be afraid to adjust the patient's position to achieve a quality photograph.[8]

Improperly sized retractors: Retractor size and shape are very important. Using improperly sized retractors can yield photos that have the lips curled over the retractors, making it more diffcult to capture perfect images. Improper sized retractors positioned in the wrong way can lead to shadows in the

Figure 5: Views showing improper angles.

"Dental photography, while not part of the core dental education, is essential not only to creating beautiful smiles but also for self-evaluation, case documentation, patient education, and marketing."

posterior. When taking retracted photos, it is important to position yourself so that as little of the retractor as possible shows in the image, creating a clean esthetic.[10,8]

Depending on what you hope to capture with each photo, it is important to set your camera ratio keeping in mind how far you should be from the subject for each shot. Setting these ratios and moving your body in and out to come into focus will allow you to be the same distance from the subject, creating repeatable and consistent images every time.

Shade Communication

Perhaps one of the most important reasons we take dental photographs is to communicate shade-matching information to our lab technicians. Proper exposure and a variety of photographs are key to shade mapping as well as relaying specific details like color, translucency, and texture.[10]

There are many different tips and tricks to facilitate accurate shade matching. Beyond the 12 recommended photos prior to treatment, I like to take two additional photos for shade matching. One is retracted, slightly opened with three shade tabs in the same plane as the teeth to be matched, about 2 mm from the incisal edge **(Fig 6)**. Selecting the shade you think is the best match along with one slightly brighter and one slightly darker will give the ceramist extra information that will help when trying to consistently achieve a perfect shade match. This photo should be taken with the correct exposure. The second photo should be slightly under exposed so any translucency can be captured in detail as well. The underlying idea is to provide the laboratory with an excess of information, rather than too little.[10]

Tips

Beginner

- It is critical to fully understand how to operate the camera you are thinking of buying/have chosen. Reading the camera's user manual, utilizing YouTube tutorials, and taking CE courses will help you learn how to adjust your camera's settings. Practice as much as possible to become more comfortable with taking a full set of dental photos quickly and effciently.

Intermediate

- Do not get too complacent; there are always "tweaks" that can be made to elevate your photography. Evaluate your photos: Are they at the proper angulation? Is the exposure consistent? Are there shadows? These are issues we all face, but fortunately, they are easily corrected with minor adjustments and practice.

Advanced

- After becoming comfortable operating your camera and maintaining a consistent photography protocol in your office workflow, what is next? Experiment with providing the laboratory with underexposed photos in addition to your standard shade match photos. You also may consider upgrading some components of your camera. (e.g., at this stage, it would be reasonable to upgrade from a crop sensor camera to a full-frame camera body). In addition, it would be wise to invest in some light modifiers and experiment with how a bouncer or an adjustable bracket will allow you to achieve dramatic and altered lighting effects.

Figure 6: This shade-matching image should be captured prior to any treatment being completed. Use a retractor and three shade tabs: one tab slightly darker than the ideal shade, one slightly lighter than the ideal shade, and one of the shade you hope to match. It is important to take this image with the three shade tabs in the same plane as the teeth you hope to match, approximately 1 to 2 mm from the incisal edge.

Summary

To provide the best care for our patients we must practice self-evaluation at the highest level. While social media propels us to put our best out into the world, it is important to realize that we must walk before we can run. Picking up a camera and starting to take photos can be intimidating for many reasons, so recognize and accept that becoming a dental photographer is a lifelong journey. Taking and sharing our high-quality photos with patients can be a critical part of their education, helping them to understand the rationale for different treatment modalities and giving them an idea of what the results will look like over time. Creating a portfolio of cases also can be very helpful to us in determining which types of treatment have been successful long term.

"Perhaps one of the most important reasons we take dental photographs is to communicate shade-matching information to our lab technicians."

References

1. Christensen GJ. Important clinical uses for digital photography. J Am Dent Assoc. 2005 Jan;136(1):77-9.

2. Desai V, Bumb D. Digital dental photography: a contemporary revolution. Int J Clin Pediatr Dent. 2013 Sept-Dec; 6(3):193-6.

3. Casaglia A, De Dominicis P, Arcuri L, Gargari M, Ottria L. Dental photography today. Part 1: basic concepts. Oral Implantol (Rome). 2015 Oct-Dec;8(4):122-9.

4. Lowe E. Digital photography. [Internet]. 2012. Available from: http://www.hdiqdental.com/digital-photography-ed-lowe.html

5. Liu F. Dental digital photography: from dental clinical photography to digital smile design. [Internet]. Singapore: Springer; 2019. Available from: https://link.springer.com/book/10.1007/978-981-13-1622-7#editorsandaffiliations

6. Sincar DC, Decuseara M, Popa GV, Rudnic I, al-Shukeir A, Pepelea G. The role of digital photography in dental medicine. Romanian J Med Dent Educ. 2019;8(9):33-8.

7. Shagam J, Kleiman A. Technological updates in dental photography. Dent Clin North Am. 2011 Jul;55(3):627-33.

8. Bengel W. Mastering digital dental photography. 1st ed. Hanover Park (IL): Quintessence Pub.; 2006.

9. American Academy of Cosmetic Dentistry (AACD). Photographic documentation and evaluation in cosmetic dentistry: a guide to Accreditation photography. Madison (WI):AACD; 2015.

10. Griffin JD Jr. Excellence in photography: heightening dentist-ceramist communication. Dent Today. 2009 Jul;28(7):124-7. **jCD**



Dr. Miro is an assistant clinical professor in the Esthetic Dentistry Department at New York University (NYU) College of Dentistry and an associate at the Apa Rosenthal Group in New York City.



Dr. Choai graduated from NYU College of Dentistry in 2019. He completed his General Practice Residency at Mount Sinai Hospital and currently works in private practice in Vero Beach, Florida.

Disclosures: The authors did not report any disclosures.

Calin Pop, DDS

RUBBER DAM FIRST

> "Once the rubber dam isolation protocol is mastered, it provides a method that can... be replicated in all anterior or posterior restorative scenarios."

Abstract

Restorative dentistry has no better way to reveal its artistry than against the backdrop of the rubber dam. But at a time when enhancing beauty and the dramatic improvements shown in before-and-after images have become paramount to patients, it can be easy to forget the most important role of the rubber dam: It serves as the first line of defense against infection. This article addresses the importance of maximizing the time spent working with rubber dam isolation so that the working time without such isolation is significantly reduced and as efficient as possible.

Key Words: rubber dam, restorative dentistry, infection prevention, dental ergonomics, ethics in dentistry

Introduction

Airborne contamination is minimal and saliva and blood are eliminated from the equation if a procedure is performed under rubber dam isolation.[1] The only possible remaining source for airborne contamination is from any organisms within the tooth that is undergoing treatment.[2]

Likewise, high-volume evacuators (HVEs) have been shown to significantly reduce contamination arising from the operative site.[3] However, from a practical point of view, the suction is more efficient if it is applied in a controlled, well-delimited area focused only on a few teeth that are exposed to receive the treatment.

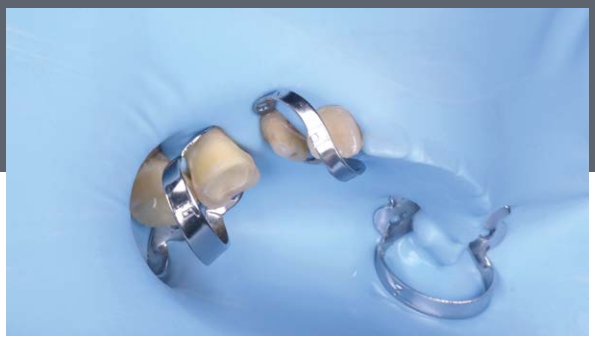

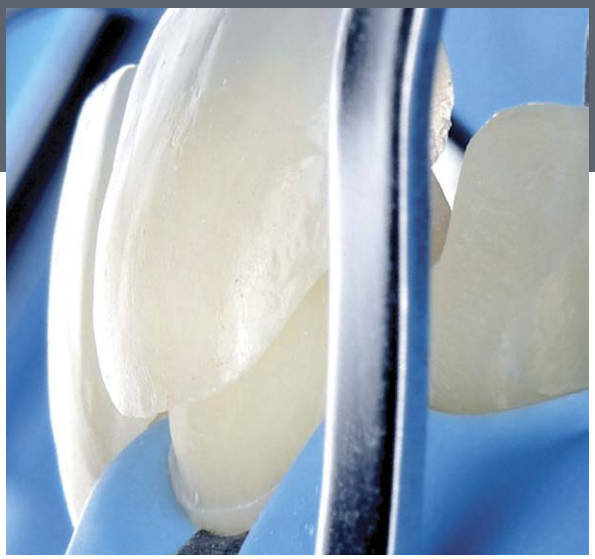

Figures 1–7: Manipulation of the rubber dam to create more space around the working area.

Figure 8: Keeping the patient shielded from materials.

Rubber Dam Isolation Protocol

A rubber dam can be manipulated to provide space around the teeth, enabling the dentist to prepare the tooth surfaces, clean excess cement, and polish, with the cheeks, tongue, lips, and gingiva retracted and protected **(Figs 1-8)**. Additionally, the patient is shielded from the accidental inhalation of resultant material when removing old fillings and drilling caries.

As the margins of preparations often are placed subgingivally **(Figs 9-11)**, there are two options to see these margins and evaluate the fit of the restorations or to properly layer and adapt composites: a rubber dam or a retraction cord **(Fig 12)**. If properly selected and positioned, clamps can cause less tissue trauma than retraction cords **(Fig 13)**. Retraction cords also can be more time consuming to place and can cause more bleeding, which may be hard to control, than the rubber dam **(Fig 14)**.

Figures 9-12: Margins placed subgingivally can be exposed only with the use of rubber dam or retraction cords.

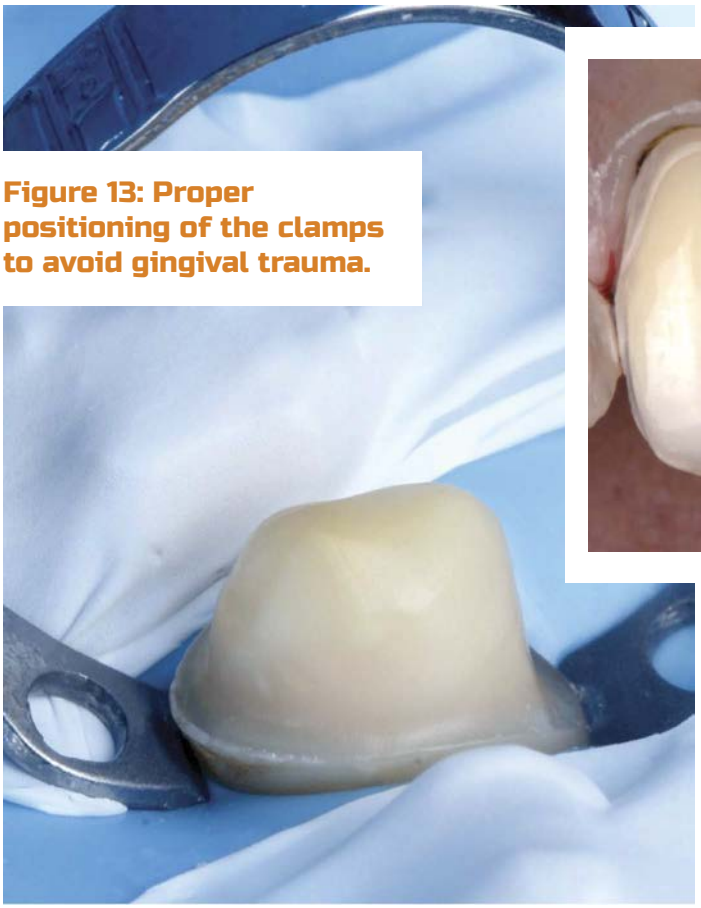

Figure 13: Proper positioning of the clamps to avoid gingival trauma.

Figure 14: Gingival bleeding caused by retraction cords.

Rubber dam or retraction cords?

The rubber dam should be placed before doing anything else **(Figs 15 & 16)**. Only after the dam is placed should we proceed to removing the old restorations **(Fig 17)**. Although the handpiece is the main source of aerosol formation,[4] with rubber dam isolation, aerosol formation from saliva and blood does not occur **(Fig 18)**.

HVEs will function at maximum capacity in a well-delimited area focusing on a reduced number of teeth and without tongue, cheeks, and cotton rolls blocking the tube's absorbent surface. The ground amalgam goes on the rubber dam, not in the patient's mouth or throat. The clinician thus has direct access to areas that might be difficult to visualize without rubber dam isolation.

The gingival tissue is retracted, and deep margins are available for cleaning and proper preparation. In most cases, and especially when removing old overhanging Class II restorations, bleeding from the gums is hard to control.[5] One of the greatest advantages of working with a dental dam is that not only is the gingival bleeding isolated from the treatment area by the dam, but we also are able to proceed with immediate dentin sealing (IDS)[6] under more optimal conditions **(Fig 18)**.

Once the rubber dam isolation protocol is mastered, it provides a method that can be employed in any procedure. The rubber dam is placed in the same way for the delivery appointment, and everything is bonded under proper isolation **(Figs 19-21)**. The protocol is predictable and can be replicated in all anterior or posterior restorative scenarios.

Figures 15–21: Every step under rubber dam isolation, from preparation to delivery.

Case Examples

Anterior

Some clinicians might approach the case shown in **Figures 22 through 39** in a more exploratory fashion, starting with crown preparation of the four anteriors and seeing what remains after preparation. However, when we rely on prior experience, we can easily anticipate that we will need to replace the old restorations and potentially even place posts and buildups.

In the author's opinion, rather than rushing to prepare whatever we find and take the impression, it is more ethical to instead take sufficient time with details such as replacing the old composite restorations. When we take the time to do these things, we may find overhanging fillings with recurrent decay that are improperly bonded and unreliable as support for new crowns. While some dentists may say that it is not important because bonding to dentin is unreliable anyway, a properly bonded new composite is certainly better than an old restoration that has microleakage or caries, and these faulty restorations will usually detach just from the vibration of the bur.[7]

There are some situations in which the rubber dam cannot be placed first, such as when bridges must be removed. When we cannot start with absolute isolation, a convenient solution is open rubber dam **(Fig 23)**, at least for the initial phase of the preparation. However, the advantage of placing the rubber dam properly before the preparation is that the convexity of the nonprepared teeth will aid us in inserting, gliding, inverting, and stabilizing the dam in the sulci with the help of floss ligature **(Fig 24)**. It is very difficult to do this once teeth are prepared unless we use clamps.

Once isolation and protection from blood and saliva are achieved, we have the ideal conditions for adhesion in any restorative scenario and can start the preparation **(Fig 25)**. In order to properly evaluate the remaining tooth structure, it is necessary to perform the initial preparation and remove the old restorations **(Fig 26)**. We can then observe the remaining tooth structure **(Fig 26)** and determine whether post-and-core reinforcement is needed **(Figs 27 & 28)**.[8] With the rubber dam on, we can continue the initial preparation **(Fig 29)**. The time spent working without rubber dam isolation is decreased as much as possible and limited to refining the margins, providing occlusal clearance, and taking impressions **(Fig 30)**. Afterward, rubber dam isolation is again achieved to properly reveal the prepared margins for a textbook delivery/adhesive protocol **(Figs 31-39)**.

Figure 22: It was decided to replace the old composites and reinforce with posts and buildups as a reliable support for the new crowns.

Figure 23: Open dam is an option when absolute isolation is not possible.

Start the preparation or place the rubber dam first?

Figures 24-28: Buildups and posts under isolation.

Figure 29: Crown preparation with rubber dam.

Figure 30: Impression and occlusal clearance without rubber dam.

Figures 31–39: Absolute isolation, properly revealing the prepared margins for a perfect delivery/adhesive protocol.

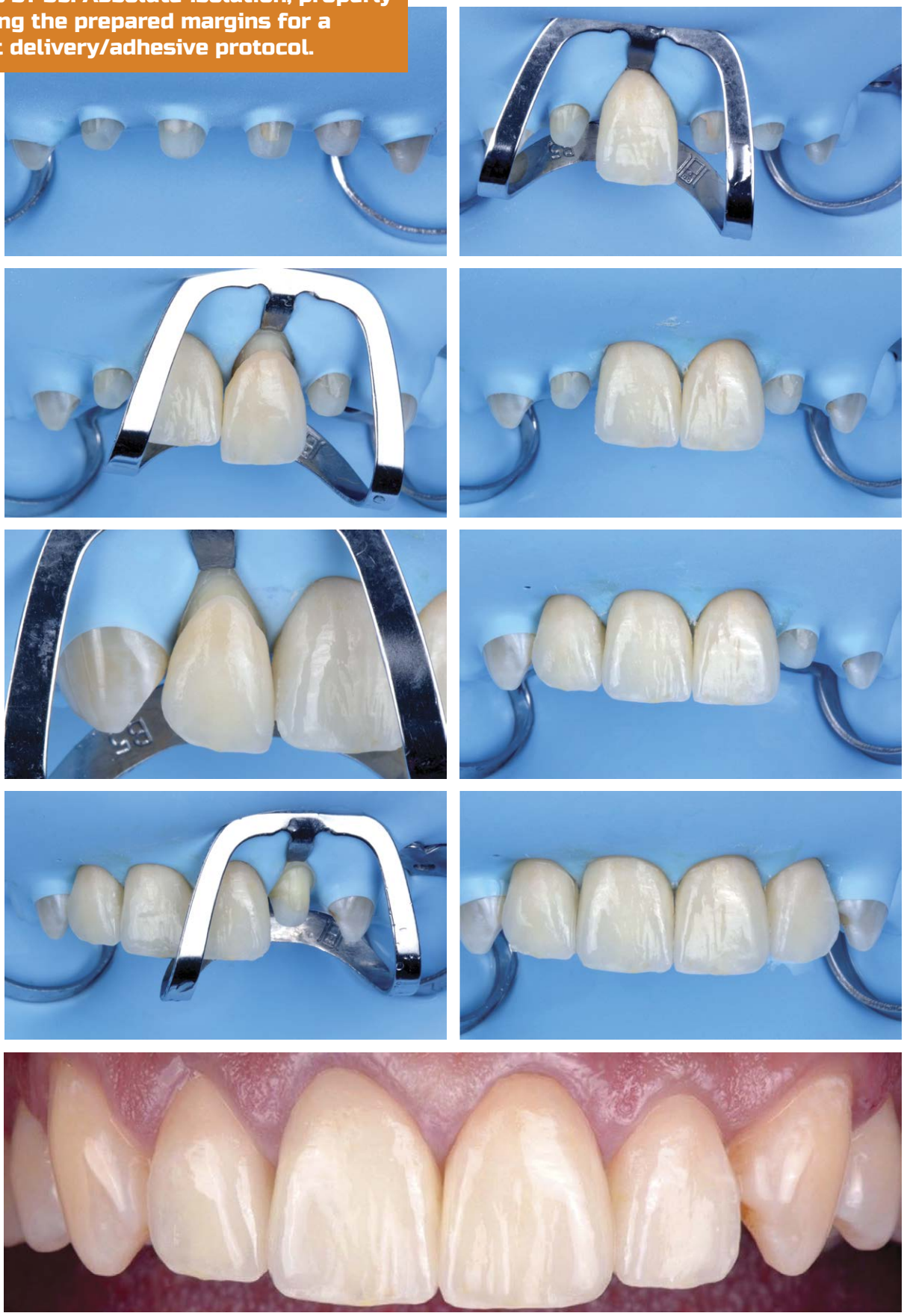

Posterior

The rubber dam must be placed before any treatment is initiated. If we remove the fillings before, the gums will bleed, and it will be difficult to pass the rubber dam over the margins, especially if the margins are deep. In quadrant dentistry, all direct restorations within a quadrant are done in the first session, as are the preparation and IDS for the indirect restorations **(Figs 40-45)**. To maximize our time spent with the protection provided by the rubber dam, we also can use 3D scanners without removing the rubber dam to determine the clearance necessary for the thickness of the future ceramic restorations using the scanner software's preparation analysis feature.

The same isolation method is followed during the delivery appointment for a flawless adhesive protocol. Removing excess cement and polishing are done with the rubber dam on, again to maximize the time spent protected from saliva and blood **(Figs 46-55)**. It is at this point—when we hold in our hands a piece of porcelain that we then can bond onto the prepared tooth **(Fig 56)**—that we can see and begin to feel rewarded by the beautiful creation of our responsible dentistry.

Figures 40-45: This posterior case demonstrates the ergonomic benefits of quadrant dentistry.

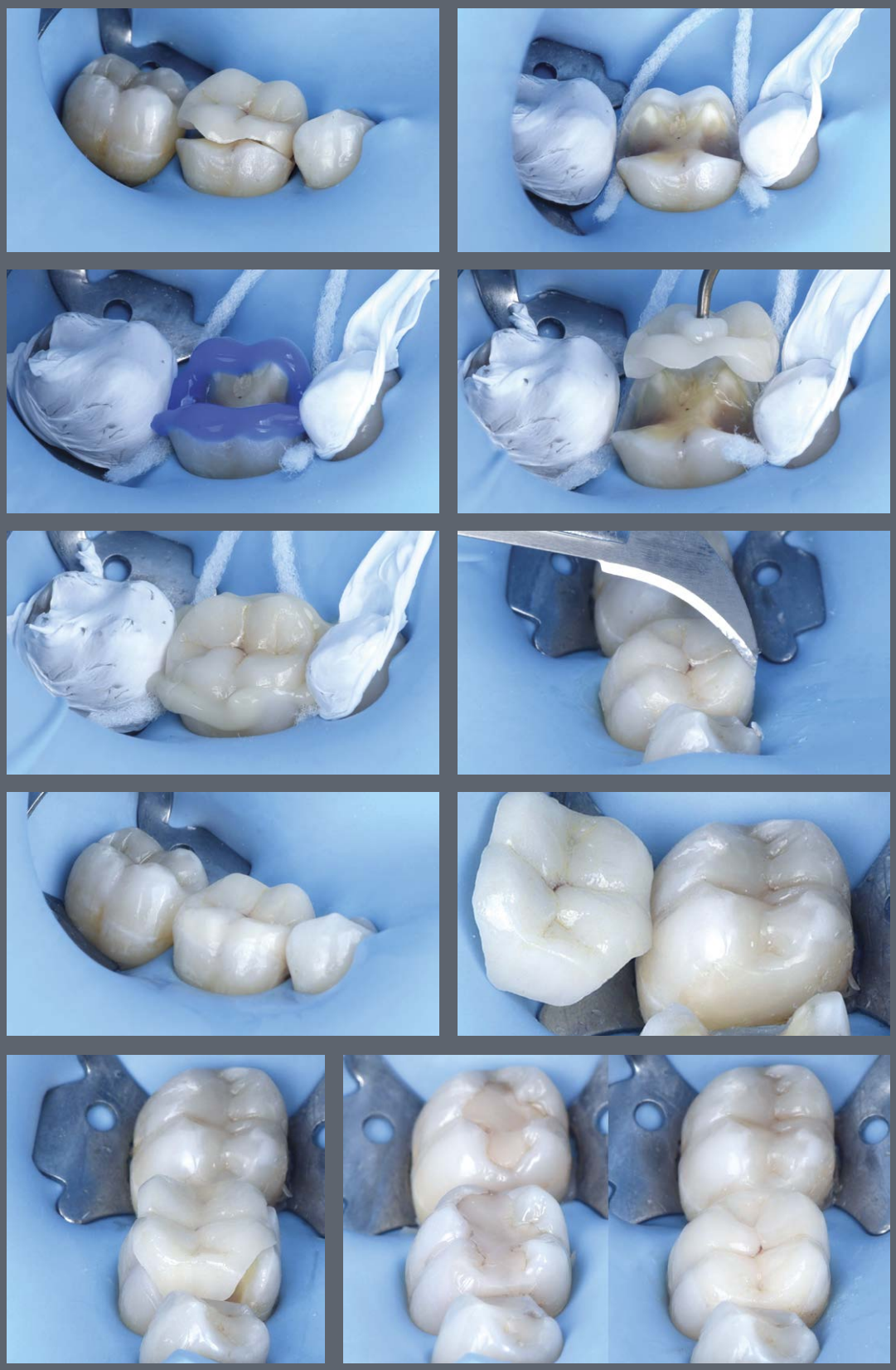

Figures 46-55: Direct and indirect restorations within a quadrant are all performed in the same isolation setup from start to finish.

Figure 56: Preparation awaiting the clinician's final artistry.

Summary

The use of rubber dam isolation and HVEs is a precaution that should always be followed during dental procedures, even when we are not in the midst of a global pandemic. Certain protocols can be followed to make the most of the time spent with rubber dam isolation for the greatest protection.[9] In addition, from a business perspective, patients will have more confidence and trust in a dentist who employs all available protocols to maximize infection prevention. World events today should serve as a wake-up call for us to practice more responsible dentistry.

"The use of rubber dam isolation and HVEs is a precaution that should always be followed during dental procedures, even when we are not in the midst of a global pandemic."

References

1. Harrel SK, Molinari J. Aerosols and splatter in dentistry: a brief review of the literature and infection control implications. J Am Dent Assoc. 2004 Apr;135(4):429-37. doi: 10.14219/jada.archive.2004.0207.

2. Cochran MA, Miller CH, Sheldrake MA. The efficacy of the rubber dam as a barrier to the spread of microorganisms during dental treatment. J Am Dent Assoc. 1989 Jul;119(1):141-4. doi: 10.14219/jada.archive.1989.0131.

3. Jacks ME. A laboratory comparison of evacuation devices on aerosol reduction. J Dent Hyg. 2002 Summer;76(3):202-6.

4. Belting CM, Haberfelde GC, Juhl LK. Spread of organisms from dental air rotor. J Am Dent Assoc. 1964 May;68(5):648-51. doi: 10.14219/jada.archive.1964.0145.

5. Pack AR, Coxhead LJ, McDonald BW. The prevalence of overhanging margins in posterior amalgam restorations and periodontal consequences. J Clin Periodontol. 1990 Mar;17(3):145-52.

6. Magne P. Immediate dentin sealing: a fundamental procedure for indirect bonded restorations. J Esthet Restor Dent. 2005;17(3):144-54.

7. Román-Rodríguez JL, Agustín-Panadero R, Alonso-Pérez-Barquero J, Fons-Font A, Solá-Ruíz MF. Shear bond strength of partial coverage restorations to dentin. J Clin Exp Dent. 2015 Jul 1;7(3):e396-9. doi: 10.4317/jced.52471. eCollection 2015 Jul.

8. Xie W, Yang S, Hai Q, Wang J. Effect of ferrule thickness on fracture resistance of endodontically treated incisors restored with fiber post and metal crown. Int J Prosthodont. 2020 May/Jun;33(3):321-7. doi: 10.11607/ijp.6423.

9. Al-Amad SH, Awad MA, Edher FM, Shahramian K, Omran TA. The effect of rubber dam on atmospheric bacterial aerosols during restorative dentistry. J Infect Public Health. 2017 Mar/Apr;10(2):195-200. **jCD**

Dr. Pop is in private practice in Abu Dhabi, United Arab Emirates.

Disclosure: The author did not report any disclosures.

PART 2

Standardization for Dental Photography

Irfan Ahmad, BDS



Abstract

Defining and implementing standards for dental photography is important for comparing, monitoring, and evaluating treatment outcomes. This article presents detailed guidelines for achieving standardized intraoral and extraoral images in clinical practice as well as two portfolios, the essential dental and the essential portrait portfolios. It is important to note that additional optional views may be required for specific modalities, or for a particular course of treatment.

Key Words: extra- and intraoral clinical images, clinical photography positioning, essential dental and portrait portfolios, portrait photography, dental camera setups and settings

> “Unlike conventional photography, dental photography has additional factors to consider, such as cross-infection control, health and safety, and confidentiality.”

Introduction

Part 1 of this article discussed the rationale for standardization in dental photography and its benefits. In this second part, the focus is on how to realize these objectives in a clinical environment. Two portfolios—the essential dental portfolio (EDP) and the essential portrait portfolio (EPP)—covering both intraoral and extraoral (portraiture) images, respectively, are detailed. The comprehensive, step-by-step guidelines presented below can be readily mastered and routinely incorporated into daily practice.

Extraoral and Intraoral Images

This discussion covers the most frequently documented images in dentistry: extraoral and intraoral compositions.[1] The former is also referred to as the *dentofacial composition* since it includes the lips, extraoral soft tissues, and their relationship to the intraoral dentogingival elements.

Positions of Patient, Photographer, Assistant, and Equipment

Unlike conventional photography, dental photography has additional factors to consider, such as cross-infection control, health and safety, and confidentiality. Besides these fundamental requirements, positioning the patient, photographer, assistant, photographic equipment, and dental adjuncts are crucial for extra- and intraoral pictures. The position of the patient is key, and determines the positions of the photographer, assistant, and equipment.[2] The type of image dictates the position of the patient, who can be seated upright, partially reclined, or supine. For the majority of standardized extraoral and intraoral images, the ideal patient position is seated upright. This position is repeatable, whereas the degree of recline varies, and compromises standardization. However, for promotional and marketing images, positioning can be somewhat more casual, since a rigid posture is perceived as tense and possibly antagonistic.

For the majority of extra- and intraoral clinical images, the patient's head and the camera axis are perpendicular to the facial midline and parallel to the horizon **(Figs 1-3)**. The lens axis is centered exactly at the mesial contact point areas of the maxillary centrals. Using facial landmarks such as the interpupillary or intercommissure lines for orientation helps to prevent incorrect alignment of the incisal plane and/or dental midlines **(Fig 4)**. In the sagittal plane, the head should neither be pointing up, nor down (i.e., parallel to the ala-tragus [Camper's line] or Frankfort plane and perpendicular to the lens axis) **(Fig 2)**. Maintaining a perpendicular lens axis ensures correct perspective; if the lens axis is superior or inferior, the teeth appear elongated or shortened, especially the maxillary and mandibular anteriors. In addition, if a ring flash is mounted on the front of the lens, a superior or inferior lens axis will unduly illuminate the "red" oral mucosa and the light reflected onto the palatal aspects of the teeth will make them appear more reddish, conveying an incorrect color rendition that may affect precise tooth shade evaluations. Also, it is important to avoid using the occlusal or incisal planes for orientation as the latter may be misaligned. Instead, use the horizon for alignment for recording true inclination, which is essential for diagnosing cants of the maxilla or altered eruption patterns.

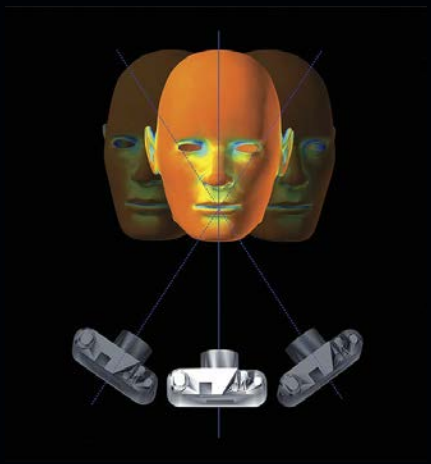

Figure 1: Incorrect angulation of the camera or the patient's head in the vertical plane causes distorted perspective or unwanted shadows.

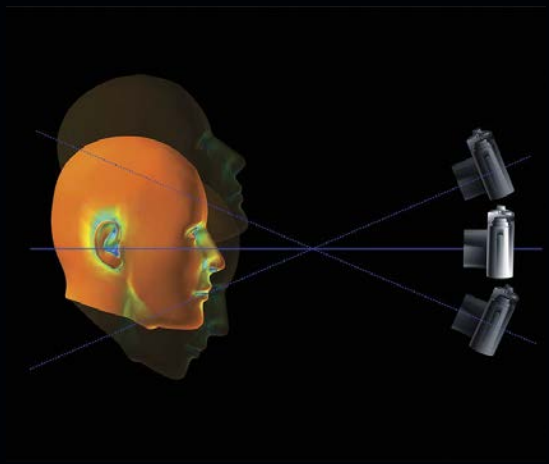

Figure 2: Incorrect angulation of the camera or the patient's head in the sagittal plane causes distorted perspective, unwanted shadows and/or imparts a reddish color to the teeth, which are unintentionally illuminated by the reflected "red" shadows of the oral cavity.

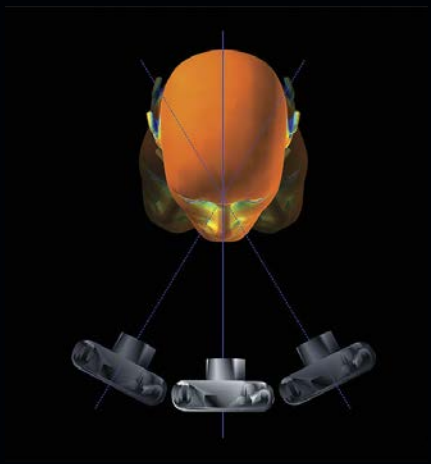

Figure 3: Incorrect angulation of the camera or the patient's head in the horizontal plane causes distorted perspective or unwanted shadows.

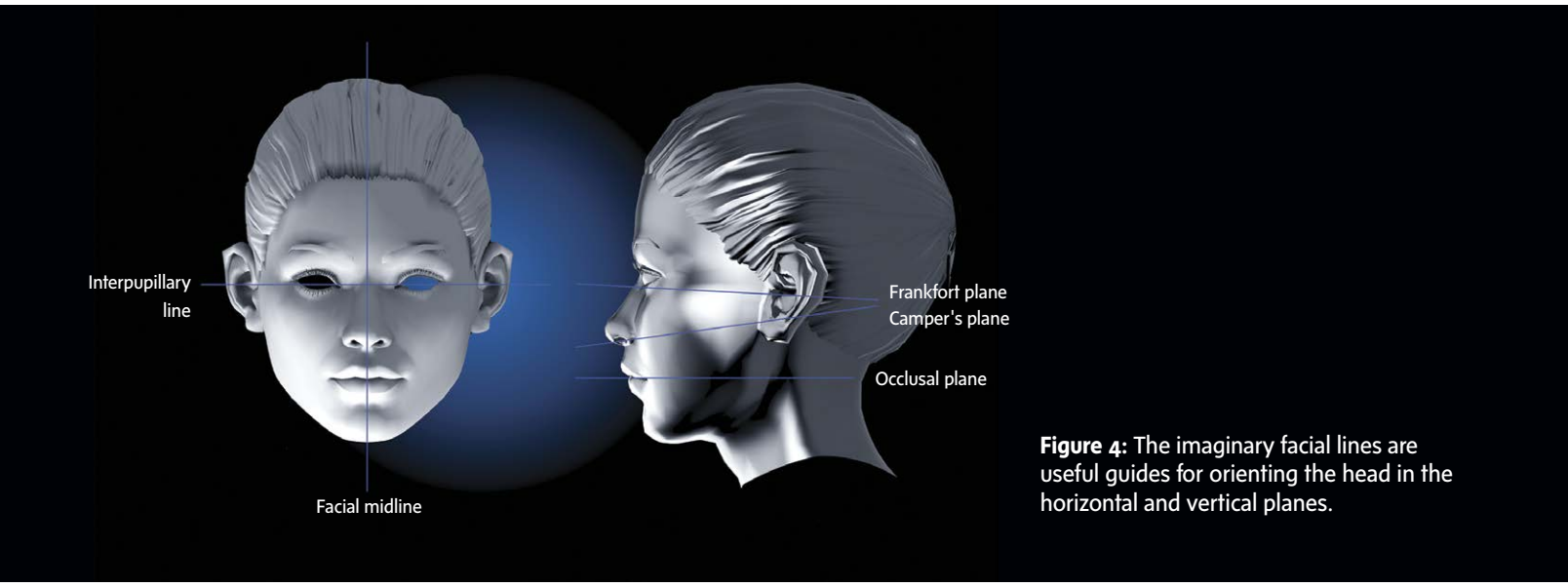

Figure 4: The imaginary facial lines are useful guides for orienting the head in the horizontal and vertical planes.

After positioning the patient, the photographer positions himself/herself accordingly with the photographic equipment, depending on the angle of view to be recorded. The assistant stands to the patient's right or left, ensuring easy access to an aspirator, three-in-one dental syringe, and other dental armamentarium. Alternatively, the assistant may stand behind the patient to hold two unilateral cheek retractors for displacing the lips and cheeks. However, the latter ties up the assistants' hands, and therefore may require another assistant for aspiration, etc. Since there are several different types of images with different angles of views, the section below graphically depicts the setups required for each type of photograph as well as the necessary equipment settings and technical notes for expediting the photo session.

The Essential Dental Portfolio (EDP)

Depending on the discipline in question, different dental organizations and clinicians advocate varying number of images for a dental portfolio.[3-8] In addition, extra images are required according to individual patient needs, clinical findings, and the proposed treatment. However, the EDP is suitable for most dental applications, regardless of the discipline. Since the intended use of an EDP is clinical photo documentation, standardization is mandatory, and the guidelines below are intended to ensure that intra- and interpatient comparisons are possible. Furthermore, an EDP should form part of the patient's dental records, no different than charting or radiographic documentation. This portfolio serves as a record, even if no treatment is contemplated, and is an invaluable reference for restoring dentition if the patient suffers acute trauma, especially involving the anterior teeth. Furthermore, an EDP can be vital for forensic identification should the patient become the victim of a fatal accident or fire.

> "The EDP consists of nine basic dental views: three extraoral (dentofacial) and six intraoral compositions."

The EDP consists of nine basic dental views **(Fig 5)**: three extraoral (dentofacial) and six intraoral compositions, as follows:

- EDP image #1: extraoral frontal view in habitual or "resting" lip position
- EDP image #2: extraoral frontal view, relaxed smile
- EDP image #3: extraoral frontal view, laughter
- EDP image #4: intraoral frontal view in maximum intercuspation (MI)
- EDP image #5: intraoral frontal view with separated teeth
- EDP image #6: intraoral right lateral view in MI
- EDP image #7: intraoral left lateral view in MI
- EDP image #8: intraoral occlusal full-arch maxillary view
- EDP image #9: intraoral occlusal full-arch mandibular view.

The full-face, or clinical, portrait is excluded from the EDP since some patients may withhold consent to photograph their faces. However, if this is not a concern, the 7 full-face images of the essential portrait portfolio (EPP) can be added to the EDP, bringing the total number to 16 images.

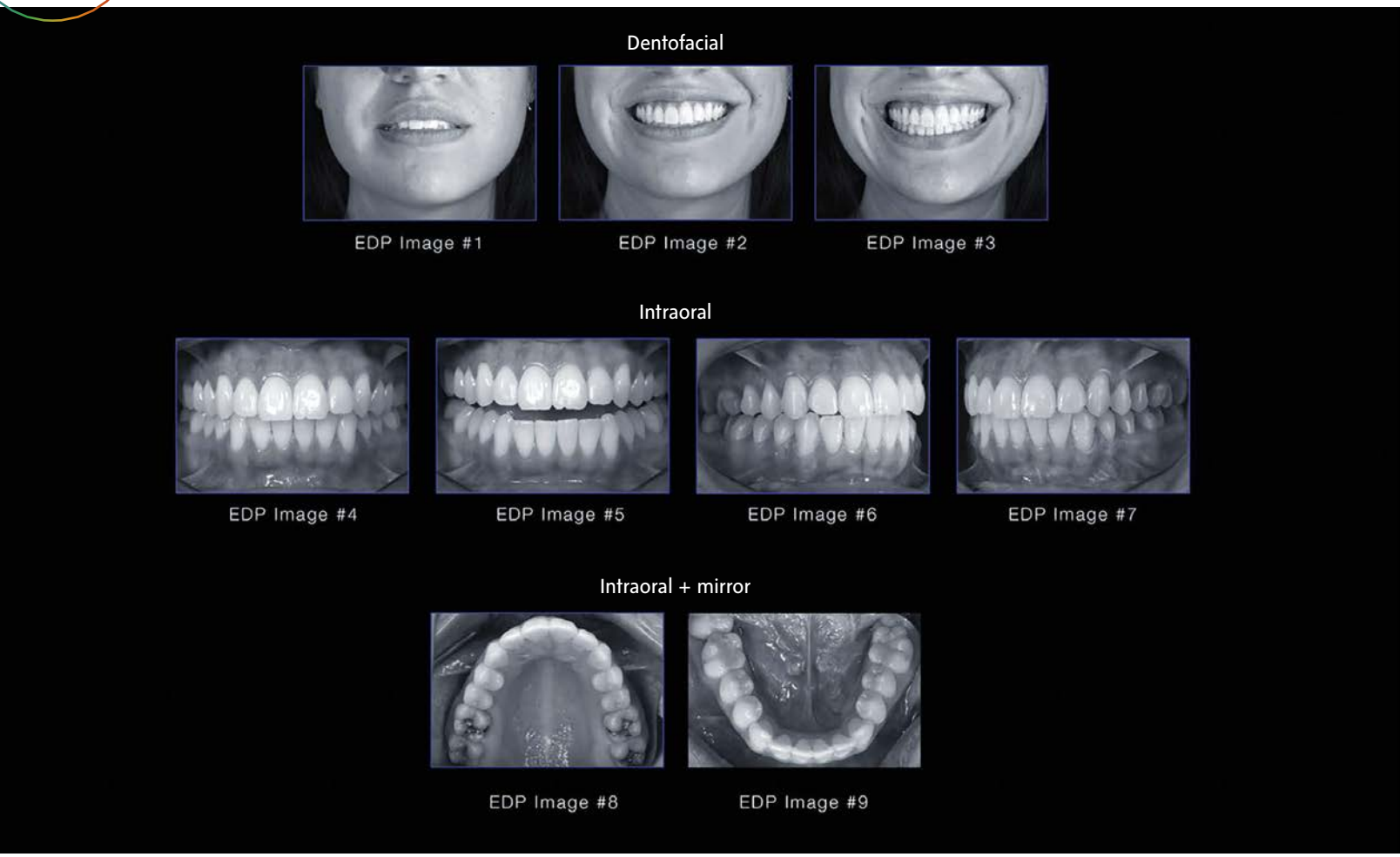

Figure 5: Thumbnails of the EDP.

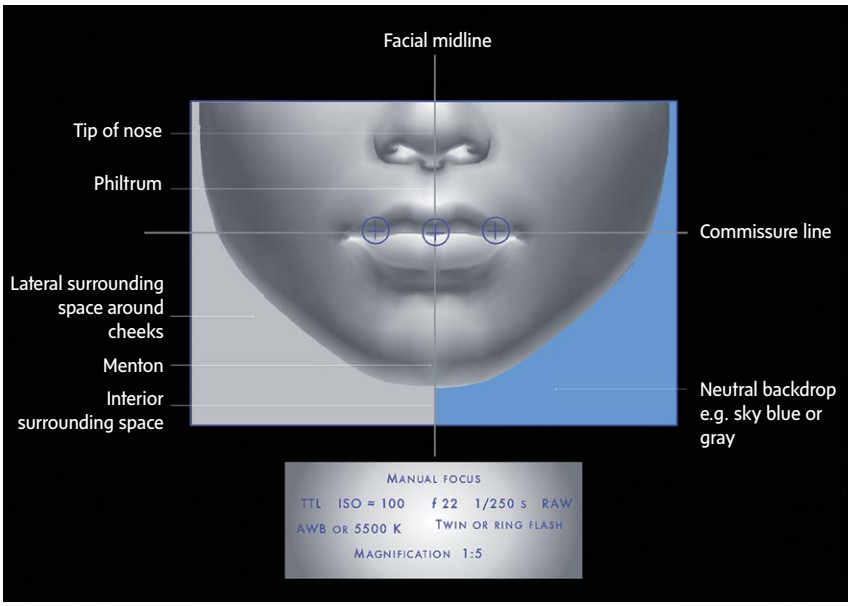

Figure 6: Photographic settings and field of view (FOV) for dentofacial compositions, EDP images #1, #2, and #3. Point of focus (POF) = blue crossline reticle (a reticle is a guide found in the viewfinders of most cameras to denote the center point of the image to be photographed). For a relaxed smile, the POF is the central incisors; for laughter, the POF is the canine tips.

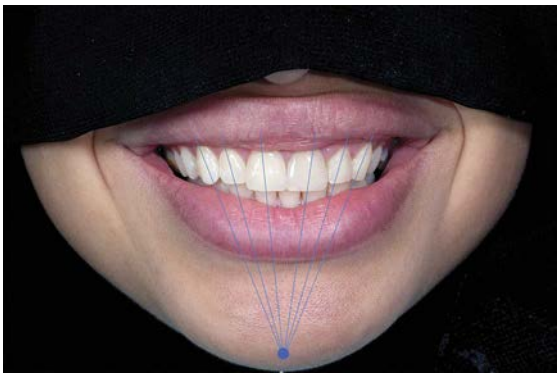

Figure 7: Imaginary lines representing the mesial axial inclination of the maxillary anterior teeth converging at the menton.

Figure 8: EDP images #1, #2, and #3 setup. The patient is seated upright facing the camera, which is tripod-mounted with bilateral flashes. The assistant is out of frame but standing to the side ready to assist and ensure patient comfort (sagittal view).

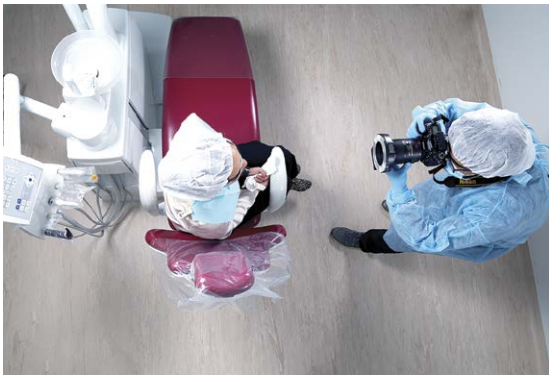

Figure 9: EDP images #1, #2, and #3 setup. The patient is seated upright facing the camera, which is hand-held with a ring flash (bird's-eye view).

Figure 10: EDP images #1, #2, and #3 setup, photographer's POV.

Extraoral (Dentofacial) Compositions

EDP image #1—extraoral frontal habitual or "resting" lip position: An extraoral or dentofacial composition centers on a commissure-to-commissure view of the lips in static and kinetic states. Although the static state is often referred to as the *resting position* this is erroneous, since the orofacial muscles are contracting and not truly at rest. The true resting position is while sleeping, when all the orofacial muscles are completely relaxed and the mandible drops down, causing the mouth to open. A more accurate term for this is the *habitual lip position* (e.g., while walking or concentrating on a task). This view is usually the starting point for most dental portfolios, and its setup is similar to that for subsequent intraoral views. Dentofacial images, together with portraits, are the most appealing and relevant to patients' esthetic sense. Furthermore, most laypeople assess the outcome of esthetic dental treatment by these compositions, rather than clinical intraoral images. The best method for attaining the habitual lip position is asking the patient to iterate the letter 'm' or "Emma" and then relaxing to achieve an interlabial gap or habitual lip separation. The composition is framed to include the tip of the nose above, and the menton below **(Fig 6)**. This allows assessment of the dental midline in relation to the facial midline (philtrum), and the axial inclination of the maxillary anterior teeth during a relaxed smile. The mesial axial inclinations of the teeth in maxillary anterior sextant ideally should converge at the menton **(Fig 7)**.

The patient is seated upright in the dental chair and asked to turn around 90 degrees toward the camera. The positioning of the photographer and assistant are shown in **Figure 8** (sagittal view), **Figure 9** (bird's-eye view), and **Figure 10** (photographer's point of view [POV]). It is advisable to take the extraoral pictures before moving onto the intraoral images to avoid transient creasing or redness of the lips caused by the cheek retractors, which may be visible in the photographs. Also, the flashes (either twin bilateral or ring) should be able to alter the light intensity output to enable the flash ratio to be adjusted to 1:2 (fill flash:key flash) for producing three-dimensional images with highlights and subtle shadows. The technical settings and guidelines for extraoral images #1, #2, and #3 are summarized in **Table 1,** and EDP image #1 is shown in **Figure 11**.

EDP images #2 and #3—extraoral frontal relaxed smile and laughter: The next two extraoral images are a relaxed and exaggerated smile (laughter). The degree of lip contraction influences elevation of the commissure line, smile line parallelism, oral mucosa visibility (bilateral negative spaces), and tooth display and amount of gingival exposure, which is particularly relevant for disciplines such as orthodontics, cranio-maxillofacial surgery, periodontics, and dental esthetics. However, the smile can be highly problematic as many patients "train" themselves to smile in a particular way. This may involve concealing dental anomalies such as excessive gingival display (gummy smile), diastemata, imbrications, discolorations, decay, fractured teeth, or the results of poor-quality dentistry (e.g., unsightly fillings, crowns, veneers). Therefore, capturing a relaxed smile is challenging, and may require several attempts until the patient feels comfortable. Nevertheless, it is important to capture smiles that have diagnostic value, including a relaxed smile as well as laughter, so that all relevant factors are visible for assessment and treatment planning. These include incisal embrasures while the teeth are separated, as well as the incisal plane inclination relative to the curvature of the mandibular lip (essential for revealing maxillary or incisal plane cants), and dental midline shifts in relation to the facial midline. This is another reason that the tips of the nose and chin should be included in the dentofacial composition for assessing the relationship of the facial midline to the dental midlines (maxillary and mandibular). The setup and settings are identical to photographing the habitual lip position shown in **Table 2**, and EDP images #2 and #3 are shown in **Figures 12 and 13**.

Table 1. Settings & Guidelines for Extraoral EDP Images ##1-3

ITEM	SETTING/DESCRIPTION	NOTES
Focus	Manual	
Exposure metering	TTL or manual	Manual: take a few test shots to ascertain correct exposure, or use histogram
ISO	50-200	
Aperture	f/22	
Shutter speed	1/125s or 1/250s	Flash synchronization speed depends on the camera brand
Image data format (file format)	RAW or DNG (digital negative graphic)	
White balance	AWB (automatic white balance), 5500 K, or manual	Manual: numerical value input, or take a reference image with an 18% neutral-density gray card
Flash	Twin bilateral with diffusers angled 45°, or ring flashes	Adjust fill light:key light ratio to 1:2. If images are too bright or too dark, adjust intensity of flashes, or move flashes closer or further away until correct exposure is achieved (only applicable for bilateral flashes as ring flashes are usually fixed on the front of the lens)
Magnification factor	1:5	Only relevant for full-frame sensors, or set predefined focusing distance on lens, or use anatomical landmarks (see field of view [FOV] below)
Point of focus (POF) represents the ideal hyperfocal distance for maximum depth of field (DOF)	Habitual lip position: central incisors Relaxed smile and laughter: canine tips (The POF will depend on the shape of the face; if parts of the image are out of focus, change the POF either anterior or posterior to the suggested areas)	Hand-held cameras: for predefined magnification or focusing distance, move camera backward and forward until focus is obtained, or use anatomical landmarks for composing (see FOV below) Tripod-mounted camera: for predefined magnification or focusing distance use macro stage for focusing, or use anatomical landmarks for composing (see FOV below)
FOV	Anatomical landmarks	Right/left: lateral aspects of cheeks (with surrounding lateral space) Superior/inferior: tip of nose to menton (if possible, with surrounding inferior space) Anterior/posterior: tip of nose to lateral aspects of cheeks
Background	Variable	Standardized clinical images: neutral sky blue or gray Promotional images: vivid colors - carte blanche

Figure 11: EDP image #1.

Figure 12: EDP image #2.

Figure 13: EDP image #3.

Table 2. Settings & Guidelines for Intraoral EDP Images #4 & #5

ITEM	SETTING/DESCRIPTION	NOTES
Focus	Manual	
Exposure metering	TTL or manual	Manual: take a few test shots to ascertain correct exposure, or use histogram
ISO	50-200	
Aperture	f/22	
Shutter speed	1/125s or 1/250s	Flash synchronization speed depends on the camera brand
Image data format (file format)	RAW or DNG (digital negative graphic)	
White balance	AWB (automatic white balance), 5500 K (photographic daylight), or manual	Manual: numerical value input for 5500 K, or take a reference image with an 18% neutral-density gray card
Flash	Twin bilateral with diffusers angled 45°, or ring flashes	Adjust fill light:key light ratio to 1:2. If images are too bright or too dark, adjust intensity of flashes, or move flashes closer or further away until correct exposure is achieved (only applicable for bilateral flashes as ring flashes are usually fixed on the front of the lens)
Magnification factor	1:2	Only relevant for full-frame sensors, or set predefined focusing distance on lens, or use anatomical landmarks (see FOV below)
POF	Maxillary canine tips (The POF will depend on the shape of the arches; if all teeth are not in focus, change the POF either anterior or posterior to the canines)	Hand-held cameras: for predefined magnification or focusing distance, move camera backward and forward until focus is obtained, or use anatomical landmarks for composing (see FOV below) Tripod-mounted camera: for predefined magnification or focusing distance use macro stage for focusing, or use anatomical landmarks for composing (see FOV below)
FOV or composition	Anatomical landmarks	Right/left: buccal corridors (negative bilateral spaces) Superior/inferior: apical to maxillary and mandibular mucogingival junctions and showing labial frenum attachments Anterior/posterior: as many teeth as possible from central incisors to second or third molars
Background	n/a	

Intraoral Compositions

EDP image #4—intraoral frontal view in MI, and EDP image #5—intraoral frontal view with separated teeth: The first two intraoral images are frontal views showing the teeth in MI[9,10] and separated approximately 5 mm to show the incisal edges, occlusal plane inclination, curves of Spee and Wilson, sphere of Monson, and incisal embrasures angles, which are particularly relevant if tooth wear or tooth surface loss is suspected due to attrition or other etiology. Both these views require cheek retractors to displace the lips and cheeks for a clear view of the oral cavity, and the assistant ready with aspiration and a three-in-one dental syringe. The setup and settings are similar to those for extraoral images, with a few exceptions such as magnification factor, field of view (FOV) and background, summarized in **Table 2** and **Figures 14 and 15**. The setups from various perspectives are shown in **Figures 16-18**, and EDP images #4 and #5 in **Figures 19 and 20**.

EDP image #6—intraoral right lateral view in MI, and EDP image #7—intraoral left lateral view in MI: The next two intraoral images are repetitions of EDP image #4, the only difference being that they are photographed from the right and left sides to show the lateral (or buccal) aspects of the teeth. Hence, the FOV is different, and ideal for showing Angle's molar, canine and incisal relationships, curve of Spee, overerupted teeth, and available interocclusal space for replacing missing teeth. There are two methods for capturing lateral views: direct and indirect. The direct method is simply to ask the patient to turn their head to the opposite side from the side being photographed and rotating the cheek retractor on the side being photographed to reveal the buccal aspects of as many posterior teeth as possible. The lens axis is positioned at a 45-degree angle to the dental midline **(Figs 21 & 22)**. The indirect method is using a narrow or lateral intraoral mirror to reflect the buccal surfaces of the teeth. This involves placing a uni-

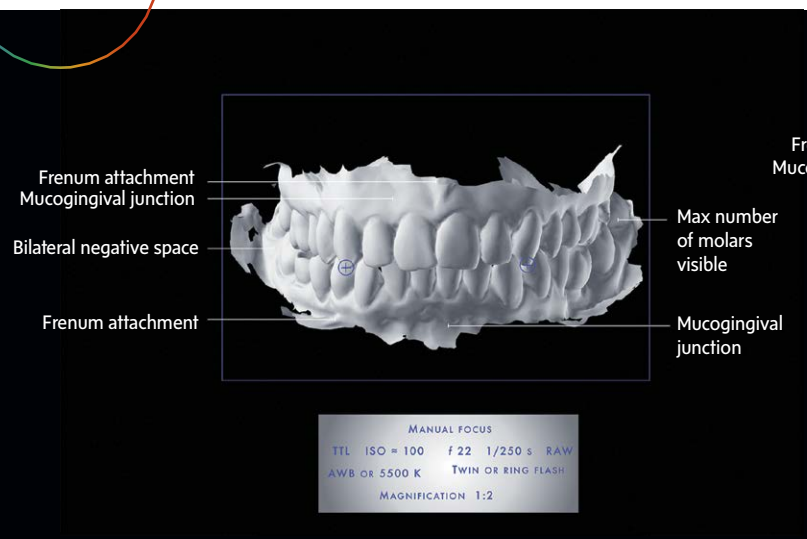

Figure 14: Settings and FOV for intraoral compositions, EDP image #4 (POF = blue crossline reticle).

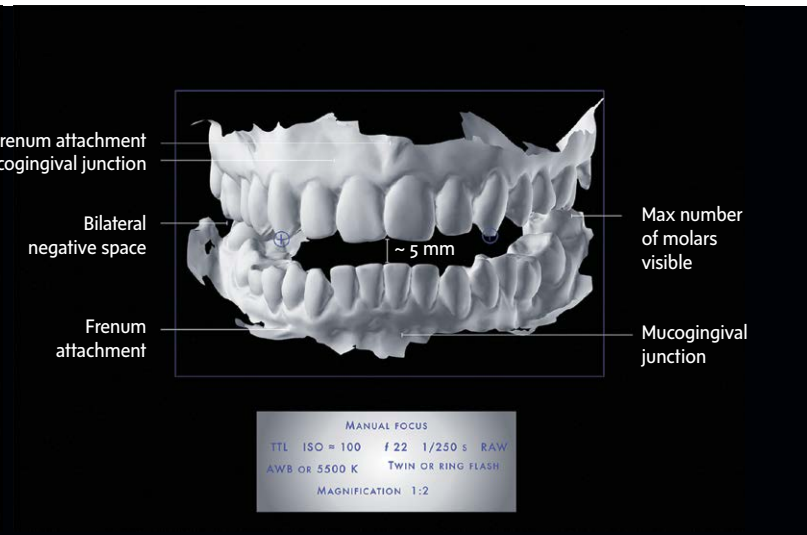

Figure 15: Settings and FOV for intraoral compositions, EDP image #5 (POF = blue crossline reticle).

Figure 16: EDP images #4 and #5 setup. The patient is seated upright facing the camera and holding the bilateral plastic cheek retractors, the camera is tripod-mounted with bilateral flashes. The assistant holds the saliva ejector and three-in-one dental syringe (sagittal view).

Figure 17: EDP images #4 and #5 setup. Positions of the patient, assistant, and photographer with hand-held camera and ring flash (bird's-eye view).

Figure 18: EDP images #4 and #5 setup, photographer's POV.

Figure 19: EDP image #4.

Figure 20: EDP image #5.

Figure 21: EDP images #6 and #7 setup (direct method). The patient is asked to rotate the cheek retractors laterally to the side being photographed. The photographer moves 45 degrees to the side, while the assistant holds the saliva ejector and three-in-one dental syringe (sagittal view).

Figure 22: EDP images #6 and #7 setup (direct method), photographer's POV.

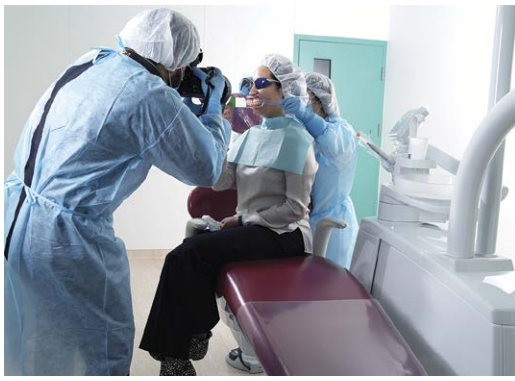

Figure 23: EDP images #6 and #7 setup (indirect method). A narrow intraoral lateral mirror is placed on the side to be photographed and is held by the patient. The assistant holds a unilateral cheek retractor on the opposite side and prevents condensation on the mirror by blowing air from a three-in-one dental syringe. The photographer moves 45 degrees to the side, aiming the lens axis to the center of the lateral mirror (sagittal view).

Figure 24: EDP images #6 and #7 setup (indirect method). Alternatively, the patient can hold both the mirror and cheek retractor, while the assistant holds a saliva ejector and three-in-one dental syringe (bird's-eye view).

Figure 25: EDP images #6 and #7 setup, photographer's POV.

lateral buccal cheek retractor on the contralateral side to be photographed, and then sliding a mirror into the buccal corridor on the side to be photographed to displace the cheek for capturing the reflection of the lateral surfaces of the teeth. The lens axis is positioned and aimed at the center of the intraoral mirror **(Figs 23-25)**. **Table 3** and **Figure 26** detail the salient differences with previous EDP images, and EDP images #6 and #7 are shown in **Figures 27 and 28**. The reflected images also need to be laterally inverted (flipped) in imaging software to ensure the correct perspective.

EDP image #8—intraoral occlusal full-arch maxillary view, and EDP image #9—intraoral occlusal full-arch mandibular view: The last two EDP images are full-arch occlusal views of the maxillary and mandibular arches; these are the most challenging pictures for the clinician, and the most uncomfortable for the patient. For both arches, the mirror is positioned so that the incisal edges or cusp tips are clearly visible. Also, the sulci are sufficiently deflected so that the lips are off the buccal surfaces of the teeth, with a clear view of the buccal gingiva. Furthermore, whenever possible, the cheek retractors and intraoral mirrors should not be visible in the picture. For maxillary occlusal views, the nostrils should be obscured by using a contraster **(Fig 29)**. The reflected EDP images #8 and #9 also need to be laterally inverted (flipped) and rotated in imaging software to ensure the correct perspective.

For the maxillary arch (EDP image #8), the patient is asked to open as wide as possible and point their chin downwards. The reverse surface of the mirror touches the mandibular anterior teeth and the lens axis is positioned at a 45-degree angle to the center of the mirror to capture an image that appears to be taken perpendicular to the occlusal plane of the maxillary arch. If mouth opening is limited, the resulting shallow or reduced

Table 3. Salient Differences for Lateral View EDP Images #6 & #7

ITEM	SETTING/DESCRIPTION	NOTES
Aperture	f/22 (direct method) f/16 (indirect method)	Reduce aperture by 1 f-stop to compensate for using intraoral mirror with the indirect method
POF	Maxillary first premolar cusp tip (The POF will depend on the shape of the arches; if all teeth are not in focus, change the POF either anterior or posterior to the first premolars)	Hand-held cameras: for predefined magnification or focusing distance, move camera backward and forward until focus is obtained, or use anatomical landmarks for composing (see FOV below) Tripod-mounted camera: for predefined magnification or focusing distance use macro stage for focusing, or use anatomical landmarks for composing (see FOV below)
FOV or composition	Anatomical landmarks	Right/left: Extending from second or third molars to the canine on the opposite side) Superior/inferior: apical to maxillary and mandibular mucogingival junctions and showing labial frenal attachments Anterior/posterior: contralateral buccal mucosa background to buccal surfaces of the molars on the side being photographed

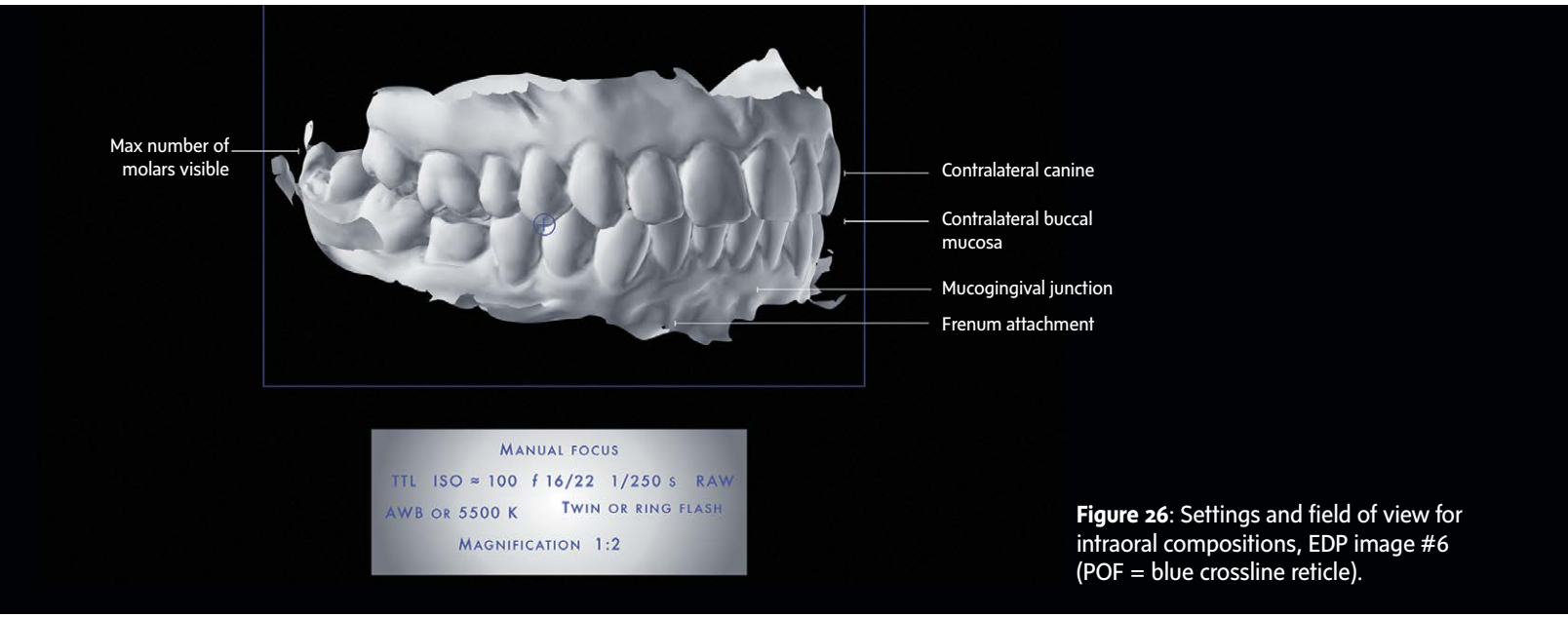

Figure 26: Settings and field of view for intraoral compositions, EDP image #6 (POF = blue crossline reticle).

Figure 27: EDP image #6.

Figure 28: EDP image #7.

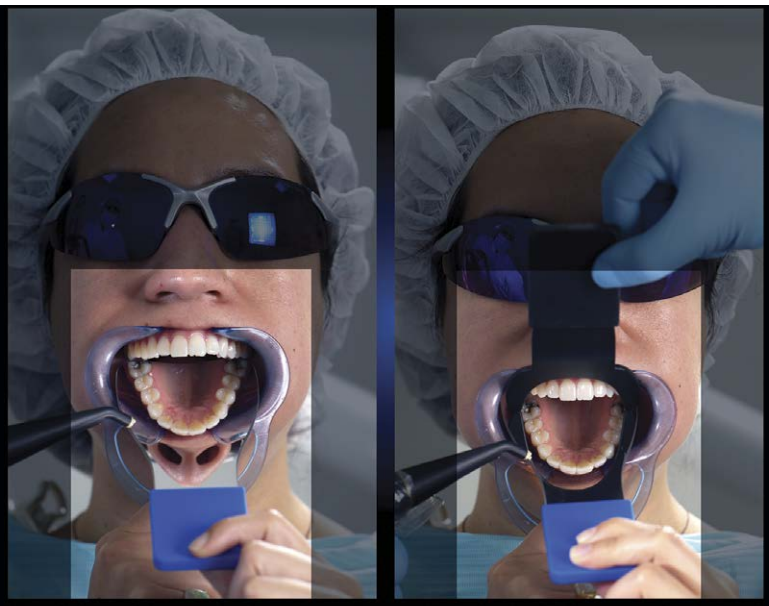

Figure 29: Contrasters are used to exclude unwanted anatomy (e.g., nostrils when using intraoral mirrors).

Figure 30: EDP image #8 setup. The patient's head is titled downward and the patient holds the intraoral occlusal mirror, while the assistant holds the contraster and three-in-one dental syringe to blow air onto the mirror. The photographer aims the lens axis 45 degrees to the mirror (sagittal view).

Figure 31: EDP image #8 setup. Positions of the patient, assistant, and photographer with hand-held camera and ring flash (bird's-eye view).

Figure 32: EDP image #8 setup, photographer's POV.

intraoral mirror angle will alter perspective and prevent visualization of the teeth's buccal and lingual surfaces **(Figs 30-32)**. **Table 4** details the salient differences between EDP images #8 and #9 and other EDP images. The settings and FOV for EDP image #8 are shown in **Figure 33** and EDP image #8 is shown in **Figure 34**.

For the mandibular arch (EDP image #9), the patient is asked to point the chin upward, allowing the reverse surface of the mirror to touch the maxillary anterior teeth, with the lens axis at 45 degrees to the center of the mirror. The tongue is gently elevated and pushed back with the mirror to exclude it as much as possible from the frame so that the lingual surfaces of the teeth are visible **(Figs 35 & 36)**. The settings and FOV for EDP #9 are shown in **Figure 37**, and EDP image #9 is shown in **Figure 38**.

> "Dentofacial images, together with portraits, are the most appealing and relevant to patients' esthetic sense."

Table 4. Salient Differences for Occlusal View EDP Images #8 & #9

ITEM	SETTING/DESCRIPTION	NOTES
Aperture	f/16	Reduce aperture by 1 f-stop to compensate for using intraoral mirror
Magnification factor	1:2 or 1:3 (depending on size of the arches)	Only relevant for full-frame sensors, or set predefined focusing distance on lens, or use anatomical landmarks (see FOV below)
POF	Maxillary and mandibular occlusal surfaces of second premolars (The POF will depend on the shape of the arches; if all teeth are not in focus, change the POF either anterior or posterior to the second premolars)	Hand-held cameras: for predefined magnification or focusing distance, move camera backward and forward until focus is obtained, or use anatomical landmarks for composing (see FOV below) Tripod-mounted camera: for predefined magnification or focusing distance use macro stage for focusing, or use anatomical landmarks for composing (see FOV below)
FOV or composition	Anatomical landmarks	Right/left: buccal sulci Superior/inferior: bordered by labial sulcus to soft palate or deflected inferior surface of tongue Anterior/posterior: incisal edges or cusp tips to buccal attached gingiva

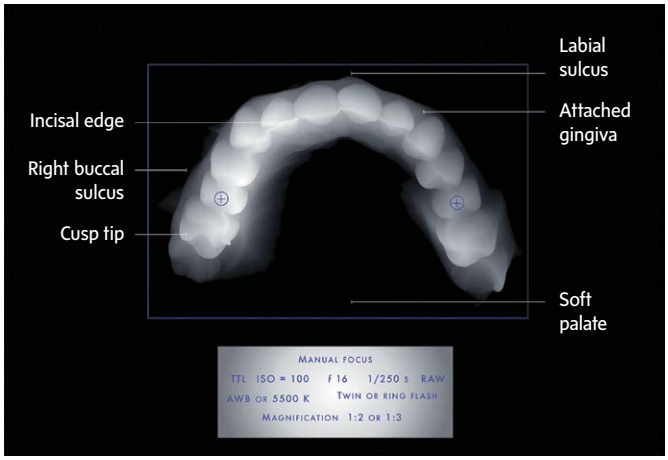

Figure 33: Settings and FOV for EDP image #8 (POF = blue crossline reticle).

Figure 34: EDP image #8.

Figure 35: EDP images #9 setup. The patient's head is tilted upwards. The assistant holds the intraoral occlusal mirror and three-in-one dental syringe to blow air onto the mirror. The photographer aims the lens axis at a 45-degree angle to the mirror (sagittal view).

Figure 36: EDP images #9 setup, photographer's POV.

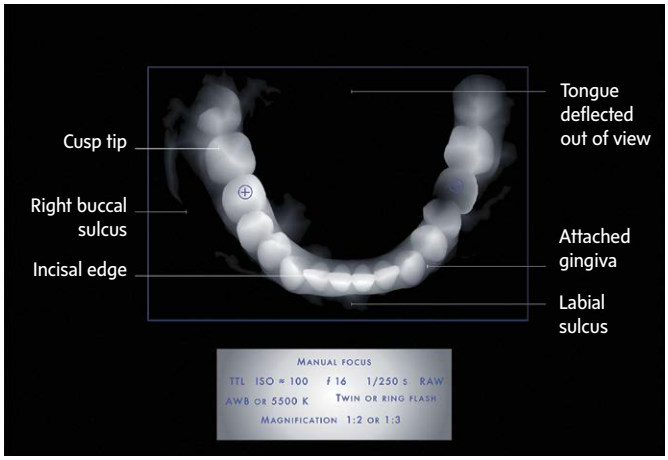

Figure 37: Settings and FOV for EDP image #9 (POF = blue crossline reticle).

Figure 38: EDP image #9.

Portraiture

The pertinent question regarding portraiture is, should it depict harsh reality, or enhance attractiveness? The answer is both. There are two types of portraits, clinical and nonclinical, and each type serves a different purpose. The former yields unadulterated information that is essential for analysis and diagnosis; whereas the latter, influenced by the subject's wishes and the photographer's vision, is evocative and meant to please. Since clinical portraiture shows harsh reality, standardization is essential for comparison and interdisciplinary communication, as well as gauging treatment progress and monitoring treatment outcomes. Nonclinical portraiture, on the other hand, enhances attractiveness, and may veer into glamor, fantasy, artistic, and surreal territory **(Figs 39 & 40)**. Therefore, for clinical portraiture, adhering to strict guidelines is mandatory, while for the nonclinical variety, the rule book is discarded. The photographer has carte blanche, and depending on his or her artistic slant, is free to experiment and "paint" a unique picture of the patient's persona.[11,12]

Clinical Portraiture Setup

Signed consent from the patient is necessary before embarking on portrait photography. If consent is obtained, the ensuing pictures should be treated with the utmost confidentiality and archived safely and securely. However, if consent is withheld, the photography session should be abandoned.

Location and atmosphere: The ideal location for taking portraits is a dedicated room, or an allocated space within a dental practice, preferably apart from the clinical environment. This allows a more peaceful atmosphere to put the patient at ease. Music can be extremely helpful in relaxing patients; this is particularly important for taking nonclinical portraits when the patient needs to feel comfortable to express his or her true inner self.

Positions of patient, photographer, and equipment: For clinical portraits, the patient is seated upright in a swivel chair, hair back to exposure the auricles, ostentatious jewelry removed, and makeup muted or washed off to capture natural skin tones and texture. There are several reference lines that are useful for orienting the head in the vertical and horizontal planes, including the interpupillary and facial midlines, ala-tragus line (Camper's plane), or Frankfort plane **(Fig 4)**. However, it is important not to rely on the incisal or occlusal plane as a reference, as this may result in misalignment.

The photographer is situated behind camera, which can be tripod-mounted (ideal for standardization) or hand-held about 1 to 2 meters from the patient. The camera is adjusted so that the lens axis is at the same level as the middle of the face **(Figs 1-3)**. The dental assistant is at hand to help set up the photographic equipment and ensure patient comfort.

Flashes: The photographic apparatus for clinical portraits consists of three studio flashes with light-modifying soft boxes or umbrellas, trigger mechanism for simultaneously firing the flashes, and a cloth or paper backdrop. The preferred backgrounds are neutral sky blue or gray, which complement most patients' complexions. White or black backgrounds should be avoided since the former creates shadows, while the latter is not conducive for patients with darker skin tones.[4] The patient is positioned sufficiently in front of the background to prevent distracting projection shadows and to throw the background out of focus for greater visual separation between the subject and background.

Portraiture requires slave flash photography. The electronic flashes output photographic daylight at a color temperature of around 5500 K. They are either triggered wirelessly by radio controllers and apps, or cables connected from the flashes to the sync cord pin on the camera. The exposure is usually calculated manually using an incident light meter, or taking test shots at a given aperture and shutter speed, and adjusting the distance or power of the flashes until the correct exposure is attained. Some studio flashes offer TTL (through-the-lens) metering using an

Key Takeaways

- A good starting point for photo documentation is to compile two portfolios, the essential dental portfolio (EDP) and the essential portrait portfolio (EPP).
- The positioning of the photographer, patient, and equipment are crucial for achieving consistent and predictable results.
- The settings on the camera and electronic flashes can be stored as "User Presets" and recalled when taking either intraoral or extraoral images.

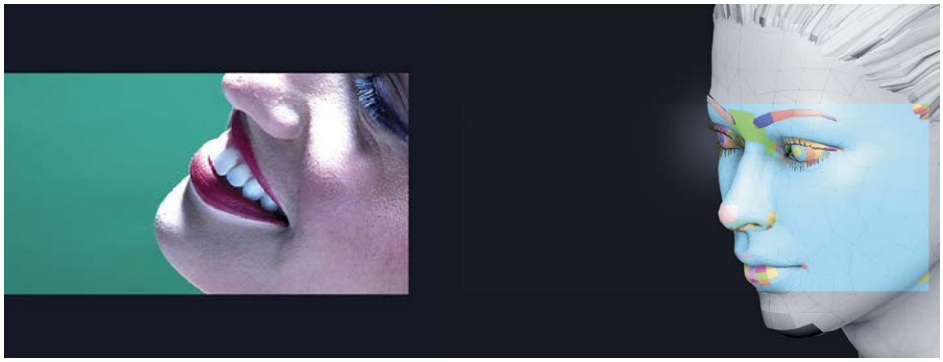

Figures 39 & 40: Nonclinical or marketing images do not always convey clinical reality, since their purpose is to entice and allure and often are stylized to attract attention.

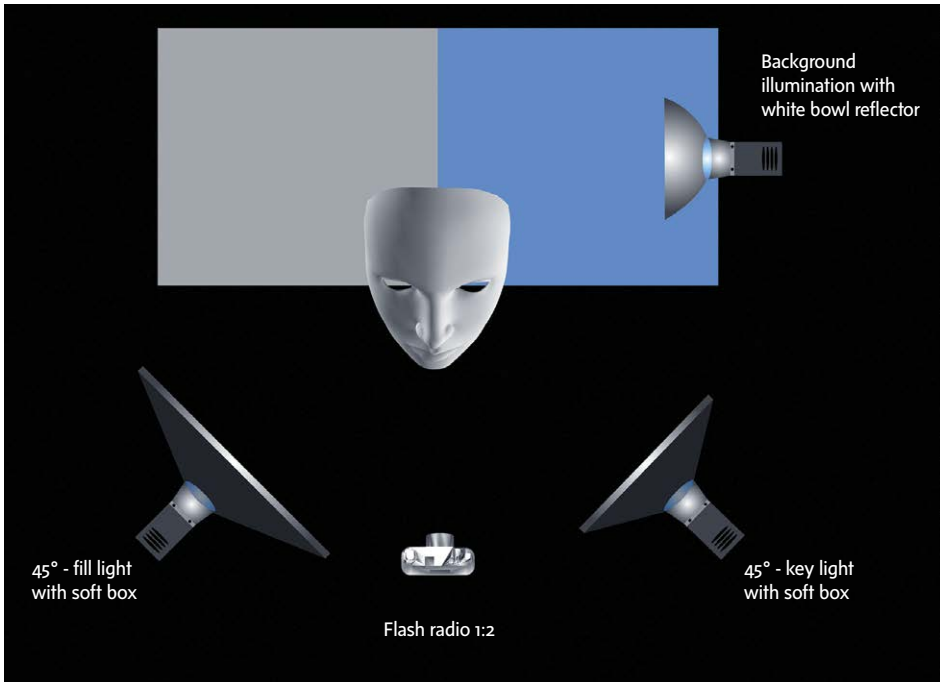

Figure 41: A standardized clinical portrait setup consists of two flashes positioned at a 45-degree angle in front of the patient with a flash ratio of 1:2, and a third flash to illuminate the background, which is usually a neutral sky blue or gray.

adapter mounted onto the hot-shoe of the camera that controls the flash bursts for ensuring correct exposure. This is similar to camera-mounted compact flashes controlled by TTL metering.

Location of studio lights: The location of the studio lights is determined by available space and funds. There are two options: The first is mounting the flash heads onto tripods placed on the floor; the second, more elaborate and expensive, is suspending the flashes from ceiling-mounted tracks. The retractable ceiling mounts are beneficial as they eliminate cables trailing on the floor but need a room with sufficient ceiling height. Tripod-mounted units have the advantage of greater mobility, especially if mounted on a dolly, but require substantial floor space. In both circumstances, a minimum of three flashes are required, two angled 45 degrees toward the patient with a fill light:key light ratio of 1:2, and the third directed to the backdrop. The key and fill light output are muted to soft light by attaching soft boxes or umbrellas onto the flash heads, while the third flash has a white bowl reflector for uniformly illuminating the background. This setup is very "clinical," devoid of distinct shadows or highlights, producing a relatively flat image. However, as the purpose of clinical portraiture is to convey reality, without either glamorizing or denigrating the subject, this lighting setup is appropriate for the intended purpose. The predefined positions of the patient's swivel chair, camera, flashes, and backdrops should be marked on the floor (or ceiling) with markers or adhesive masking tape so that their location is repeatable. The studio setup for clinical portraiture is shown in **Figure 41**.

The Essential Portrait Portfolio (EPP)

While the essential dental portfolio (EDP) concentrates primarily on the teeth, the essential portrait portfolio (EPP) consists of basic full-face images and the relationship of the teeth to the face. The EPP is suitable for a variety of dental disciplines, including orthodontics, prosthodontics, periodontics, restorative dentistry, implantology, pedodontics, smile analysis, smile design, facial enhancement, and cranio-maxillofacial procedures. The clinical portraits were previously excluded from the EDP since some patients are reluctant to give consent to photograph their face. However, if appropriate consent is obtained, the EPP can be added to the EDP to compile a total of 16 standardized images. The EPP consists of 7 views **(Fig 42)**, as follows:

- EPP image #1: frontal view with interlabial separation
- EPP image #2: frontal view with relaxed smile
- EPP image #3: frontal view, biting wooden spatula
- EPP image #4: profile right side with interlabial separation
- EPP image #5: profile left side with interlabial separation
- EPP image #6: oblique right side with interlabial separation
- EPP image #7: oblique left side with interlabial separation

The photographic equipment settings for standardized clinical portraits are as follows. The magnification factor ranges from 1:8 to 1:15, depending on the size of the patient's physical build and whether the camera has a full-frame sensor. An alternative approach is setting a predefined focusing distance on the lens barrel or framing the picture according to the FOV. An aperture of f/11 is recommended for adequate depth of field with a 1/125- or 1/250-seconds shutter speed to eliminate the influence of ambient light. The relevant camera/flash settings and guidelines for these views are outlined in **Table 5**.

Essential Portrait Portfolio (EPP)

Figure 42: Thumbnails of the EPP.

Table 5. Settings & Guidelines for Standardized Clinical Portraits

ITEM	SETTING/DESCRIPTION	NOTES
Focus	Manual or auto-focus	
Exposure metering	Manual or TTL	Manual: use light meter, histogram, or take test shots to ascertain correct exposure
ISO	50-200	
Aperture	f/11	
Shutter speed	1/125s or 1/250s	Flash synchronization speed depends on the camera brand
Image data format (file format)	RAW or DNG	
White balance	Automatic or manual	Manual options: numerical value input (5500 K), or take a reference image with an 18% neutral-density gray card
Flash	Two studio flashes with soft boxes or umbrellas, angled 45° toward patient, third flash to illuminate background	Set the two flashes aimed at patient to a fill light:key light ratio of 1:2, alter intensity or distance of flashes to achieve correct exposure
Magnification factor	1:8 to 1:15	Only relevant for full-frame sensors, or set predefined focusing distance on lens, or see below for FOV
POF	The POF will depend on the angle of view, (e.g., rhinion or bridge of the nose for frontal views)	Hand-held cameras: for predefined magnification or focusing distance, move camera backward and forward until focus is obtained, or use anatomical landmarks for composing (see FOV below) Tripod-mounted camera: for predefined magnification factor or focusing distance use macro stage for focusing, or use anatomical landmarks for composing (see FOV below) If using autofocus, ensure that the lens axis is centered on the tip of the nose for frontal views
FOV (composition)	For frontal full-face images	Right/left: bounded by background space Superior: bounded by background space Inferior: sternoclavicular joint Anterior/posterior: tip of nose to auricless
Background	Variable	Clinical images: neutral sky blue or gray

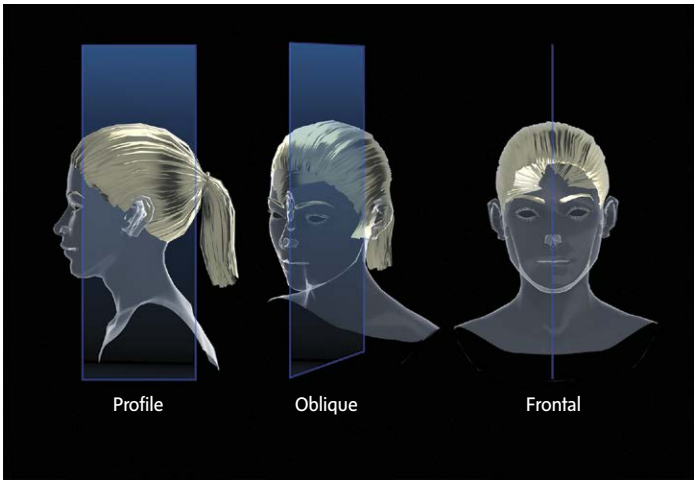

Figure 43: Positioning the patient's head.



Figure 44: Landscape versus portrait aspect ratios.

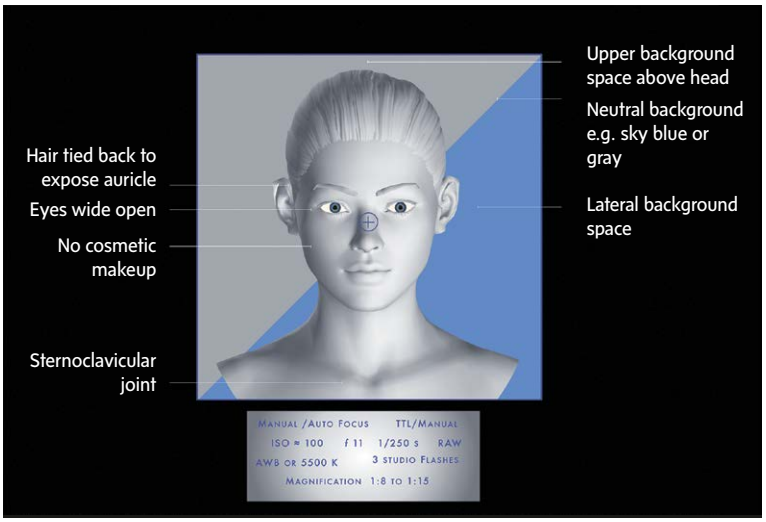

Figure 45: Standardized clinical portraiture settings, FOV, and POF (blue crossline reticle) for EPP images #1, #2, and #3.

> "To obtain perfectly standardized images requires a model patient, assistant, photographer, equipment, and environment. However, in reality, achieving all of these is a challenge, and compromises may be necessary."

Figure 46: EPP image #1

Figure 47: EPP image #2.



Figure 48: EPP image #3.

EPP images ##1-3—frontal views: The frontal views, EPP images #1, #2, and #3, are taken with the patient looking straight at the camera, whereas for profile and oblique views the patient is asked to turn on the swivel chair until the desired angle of view is obtained **(Fig 43)**. Similar to the dentofacial compositions discussed above, interlabial separation is achieved by asking the patient to iterate the letter "m" or "Emma." For EPP image #2, a relaxed smile is captured (usually accompanied by narrowing of the inter-eyelid spaces). EPP image #3 is biting into a wooden spatula with the head positioned to the horizontal. The angulation of the spatula is ideal for assessing incisal/occlusal plane alignment to the interpupillary line.

The field of view, or composition, depends on the aspect ratio setting on the camera, or the aspect ratio used in imaging software to crop the image. For portraiture, the selected aspect ratio determines the amount of background space at the upper, right, and left borders of a composition (the lower border is bounded by the sternoclavicular joint). There are two options: The first is to be consistent with the EDP and use a landscape aspect ratio, which ensures standardization for both the EDP and EPP. However, landscape orientation for portraits results in larger empty spaces to the right and left sides of the face compared to the upper border. The second option is to frame/crop the images with reduced amounts of background on the right and left sides, using the so-called "portrait" aspect ratio, but the framing is obviously incongruent with the EDP **(Fig 44)**.

EPP images #4 and #5—profile views, and EPP images #6 and #7—oblique views: The point of focus (POF) also differs according to the angle of view. For frontal views, the POF is usually the rhinion or bridge of the nose **(Figs 45-48)**. For profile views, EPP images #4 and #5, the contralateral side should be totally invisible and the POF is on the ala-tragus line, at the midpoint between the tragus and lateral canthus of the eye **(Figs 49-51)**. Finally, for oblique views, EPP images #6 and #7, the contralateral eye and its upper and lower eyelashes are visible, and the POF is on the ala-tragus line at the intersection of the lateral canthus **(Figs 52-54)**.

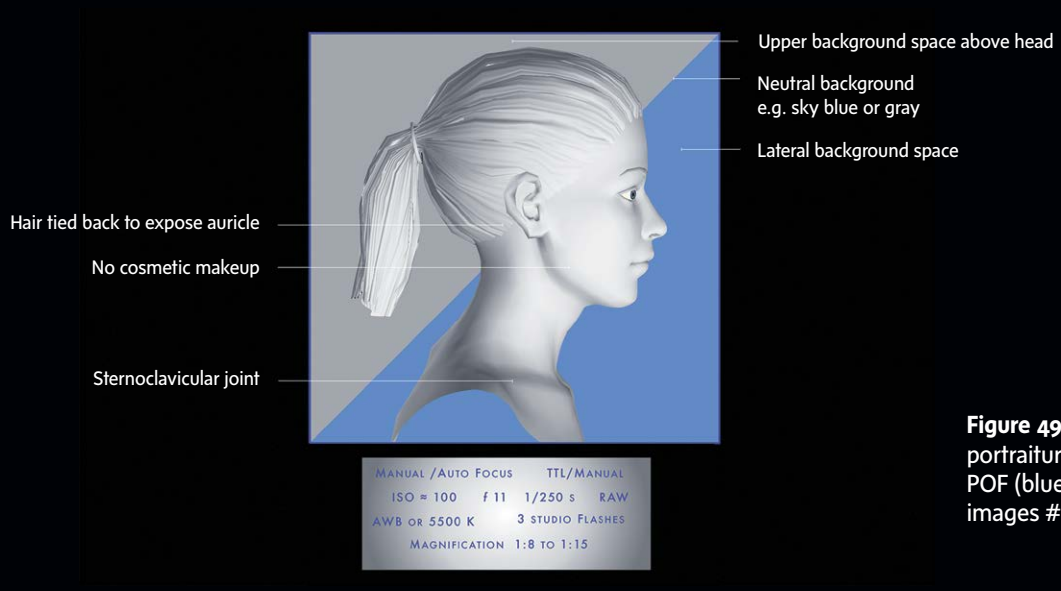

Figure 49: Standardized clinical portraiture settings, FOV, and POF (blue crossline reticle) for EPP images #4 and #5.

Figure 50: EPP image #4.

Figure 51: EPP image #5.

Summary

The first part of this two-part article presented the rationale for standardization in dental photography. This second part proposes two portfolios—the essential dental portfolio and the essential portrait portfolio—for photo documentation. These portfolios serve most dental disciplines, but additional optional views may be required for specific modalities, or for a particular course of treatment.

It is worth remembering that to obtain perfectly standardized images requires a model patient, assistant, photographer, equipment, and environment. However, in reality, achieving all of these is a challenge, and compromises may be necessary. These may include accepting less than ideal fields of view, visible edges of cheek retractors or mirrors, poor angulations, copious saliva, or fogging of mirrors, to name but a few. While poor photographic technique is indefensible, even an experienced operator may be confronted with insurmountable hurdles such as uncooperative patients, limited mouth opening, and technical issues with equipment. Although certain mistakes such as poor exposure or visible extraneous objects can be corrected at the editing stage, other errors such as poor framing, skewed perspectives, gross blemishes due to saliva or blood droplets, or excessive condensation on intraoral mirrors are impossible to rectify. Hence, a degree of pragmatism is necessary, and although the aim is to produce flawless images, achieving this ideal may sometimes prove elusive.

Editor's Note: This article is adapted from the author's book *Essentials of Dental Photography* (Wiley; Oxford, UK, 2019).

References

1. Ahmad I. Digital dental photography. Part 8: intra-oral set-ups. Br Dent J. 2009 Aug;207(4):151-7.

2. Devigus A. A picture is worth... J Cosmetic Dent. 2012 Spring;28(1):82-8.

3. Bengel W. Mastering digital dental photography. London: Quintessence Pub.; 2006.

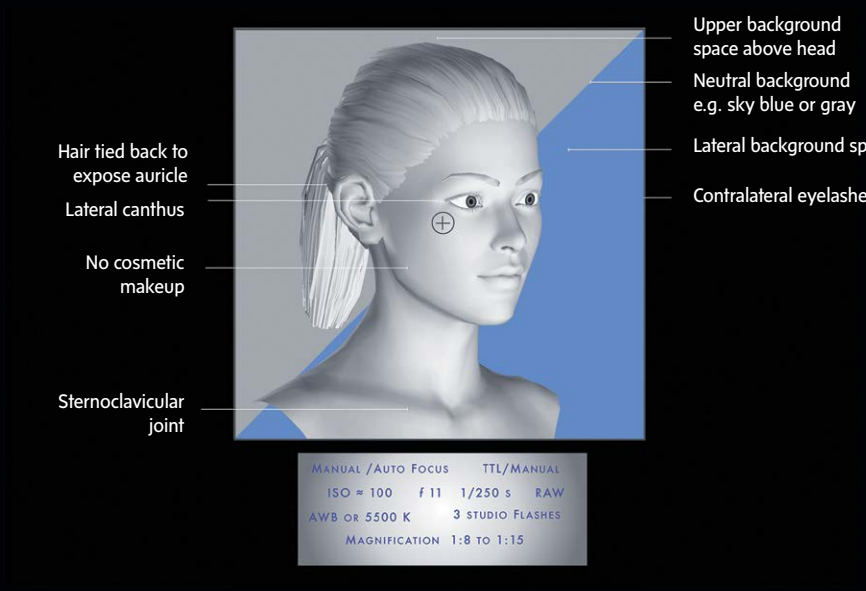

Figure 52: Standardized clinical portraiture settings, FOV, and POF (blue crossline reticle) for EPP images #6 and #7.

Figure 53: EPP image #6.

Figure 54: EPP image #7.

4. Ettorre G, Weber M, Schaaf H, Lowry JC, Mommaerts MY, Howaldt HP. Standards for digital photography in cranio-maxillo-facial surgery—part I: basic views and guidelines. J Craniomaxillofac Surg. 2006 Mar;34(2):65-73.

5. Evans S, England P, Jones M, Bowen R. Institute of Medical Illustrators: national guidelines for orthodontic photography. 2008 Feb;1-27. Available from: https://www.imi.org.uk/resources/professional-resources/national-guidelines/

6. Haddock FJ, Hammond BD, Romero MF. Guide to dental photography. J Multidiscip Care Decisions in Dentistry. 2018 Dec;4(12):1-4.

7. Pani S. A review on clinical digital photography. Int J Appl Res. 2017;3(7):10-17.

8. American Academy of Cosmetic Dentistry (AACD). Photographic documentation and evaluation in cosmetic dentistry: a guide to Accreditation photography. Madison (WI): AACD; 2015

9. Kandasamy S, Greene CS, Obrez A. An evidence-based evaluation of the concept of centric relation in the 21st century. Quintessence Int. 2018;49(9):755-60.

10. Keys LG, Agar JA. Documentation of maxillomandibular relationships during dental photography. J Prosthet Dent. 2002 Apr;87(4):466.

11. Jung CG. Collected works of C.G. Jung, volume 9 (part 1): archetypes and the collective unconscious. Princeton (NJ): Princeton University Press; 1969 [1933].

12. Ahmad I. Digital dental photography. Part 7: extra-oral set-ups. Br Dent J. 2009 Aug;207(3):103-10. **jCD**



Dr. Ahmad is in private practice in Harrow, United Kingdom.

Disclosure: The author did not report any disclosures.

Combination Scan Technique: An Innovative Approach to Diagnosing Altered Passive Eruption

Hesham H. Abdulkarim, BDS, MSD
Akshay Vij, BDS, ACT, FAGD
Dwight E. McLeod, DDS, MS

Abstract

This case report describes the diagnosis and treatment of a patient with altered passive eruption using an innovative combination scan technique to determine the exact location of the alveolar bone crest in relation to the position of the cementoenamel junction and to confirm the diagnosis. Crown lengthening was performed on the upper maxillary anterior sextant to achieve ideal tooth contours and reduce labial bone thickness. On average, 2 mm of crown exposure was obtained, and gingival display when smiling was reduced. The patient was extremely satisfied and reported no complications. This technique can also be used to measure hard and soft tissue thicknesses and postoperative tissue stability.

Key Words: bone sounding, CBCT, crown lengthening, biologic width, gummy smile



> “Distortion, calibration issues, and technical complexities…make 2D radiographs an impractical option for evaluating multiple teeth and not a reliable tool for determining the subtype of the APE pattern.”

Introduction

Gummy smile, or excessive gingival exposure while smiling,[1] has been described as more than 2 mm of maxillary gingival display below the lower border of the upper lip during a full smile.[2] There are different etiological factors for a gummy smile, including altered passive eruption (APE), which has a prevalence of 12% to 35%.[3,4] To confirm the diagnosis and the subtype of APE,[5] clinicians traditionally use crestal bone sounding with a periodontal probe to determine the positional relationships between the gingival margin (GM), cementoenamel junction (CEJ), and alveolar bone crest and to determine the bone thickness. Once a diagnosis of APE is confirmed, surgical correction of the gingival and osseous architecture generally is required.[6] Since bone sounding cannot be performed on patients without anesthetizing the gingival tissue, many clinicians postpone it until the day of the surgery. However, postponement of this procedure may limit the amount of information about the etiology, proper surgical planning, and the expected outcomes for the clinician and the patient.

Studies have investigated the use of two-dimensional (2D) radiographs to diagnose patients with APE.[7,8] Distortion, calibration issues, and technical complexities, however, make 2D radiographs an impractical option for evaluating multiple teeth and not a reliable tool for determining the subtype of the APE pattern. Another limitation of 2D radiographs is that bone thickness cannot be evaluated.[9]

To address these issues with 2D radiographs and to obtain more information about bone thickness, Januário and colleagues[10] developed a soft tissue cone beam computed tomography (CBCT) technique, wherein two separate CBCT scans were obtained for the same patient so the clinician could measure hard and soft tissue components. Batista and colleagues[11] suggested the use of a single CBCT scan to identify anatomical features of APE.

In the current case report, an innovative combination scan technique (CST) was employed, in which a single preoperative CBCT scan and a digital intraoral scan were obtained at baseline and combined to evaluate the underlying bone. More specifically, the intraoral scans were superimposed and merged with the CBCT scan. This merged combination scan enabled the visualization, evaluation, and measurement of hard and soft tissue topographies of the treatment site **(Fig 1)**. After treatment, postoperative scans can be superimposed onto the previously made baseline combination scan to evaluate tissue stability.

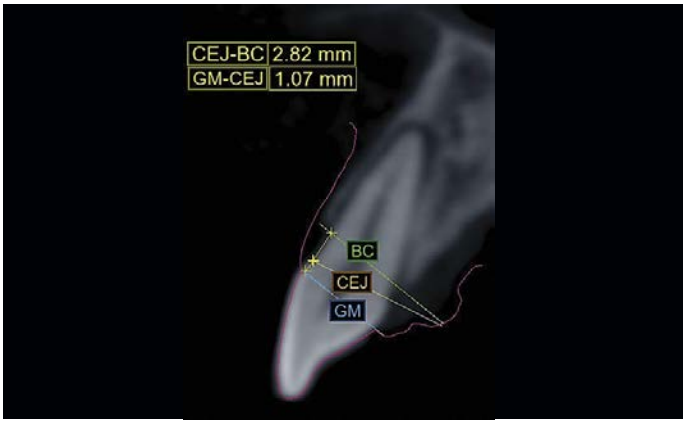

Figure 1: Example image of the CST and the possible measurements that can be made, showing the labial bone crest, cementoenamel junction, and gingival margin.

Case Report

Chief Complaint and Evaluation

A healthy 25-year-old female presented to a dental school clinic with a chief concern of excessive gingival display during smiling. Extraoral and intraoral clinical examinations revealed the following:

- a thick gingival phenotype
- 4 mm of labial gingival display below the lower border of the upper lip at the position of the upper central incisors during full smile
- normal lip length and mobility
- 8 to 12 mm of labial keratinized tissue
- a small diastema between teeth #8 and #9
- a mesioincisal chip in the enamel on #8 **(Fig 2)**.

Her medical and medication history were noncontributory.

Diagnosis

To predict the maximum coronal tooth exposure that could be obtained with esthetic crown-lengthening surgery without root exposure, use of the CST was recommended. A low-dose, limited field-of-view sectional CBCT scan was obtained preoperatively via a digital panoramic system (CS 8100, Carestream Dental; Atlanta, GA), and the resultant image was exported into the Digital Imaging and Communications in Medicine (DICOM) format. A maxillary intraoral scan that included the teeth and gingival tissues was completed with a scanner (CEREC Omnicam, Dentsply Sirona, York, PA) and was exported into standard tessellation language (STL) format. The resultant STL model was superimposed onto the CBCT (DICOM) file using a best-fit algorithm with treatment-planning software (Blue Sky Plan, Blue Sky Bio; Libertyville, IL) **(Fig 3a)**.

The following measurements were performed on the merged file: GM to the CEJ, CEJ to the alveolar bone crest, and bone thickness **(Fig 3b)**. Measurements were made at multiple points on the tooth for all teeth from the upper second bicuspid to the contra-

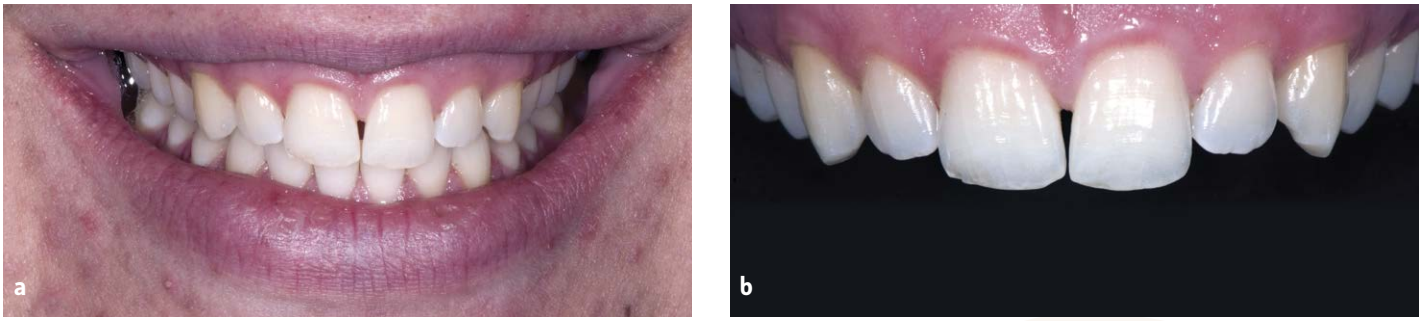

Figure 2: Initial presentation. (a) Frontal smile showing excessive gingival display. (b) Frontal intraoral view. Note the keratinized tissue, midline diastema, and minor mesioincisal chip on #8.

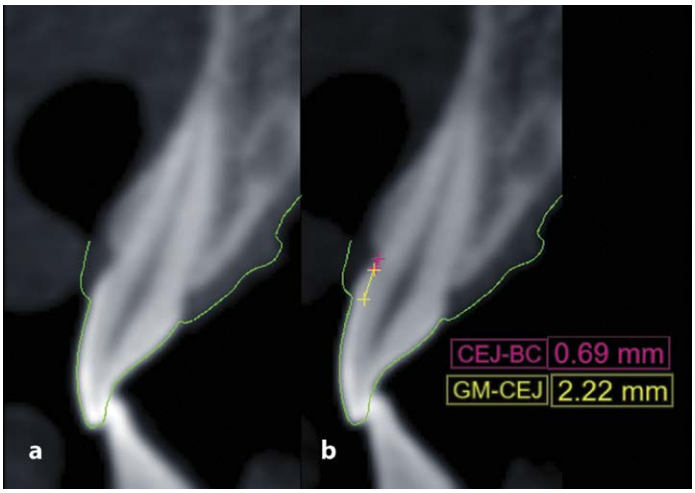

Figures 3a & 3b: Preoperative CST. (a) Tooth #9. (b) Tooth #9 with measurements.

> "This merged combination scan enabled the visualization, evaluation, and measurement of hard and soft tissue topographies of the treatment site."

lateral second bicuspid. After reviewing information obtained from clinical examination and the combination scans, the patient was diagnosed with APE, Type I, subgroup B.[5]

A treatment plan of esthetic crown-lengthening surgery for teeth #4-#13 was formulated. The combination scans were used to discuss the diagnosis and the recommended treatment with the patient. The risks, benefits, alternatives, and long-term stability of treatment were also discussed with the patient, who consented to the proposed plan.

Treatment

From the combination scans, the measurements between the GM and CEJ were transferred to the labial gingiva using a periodontal probe **(Fig 4a)**. The initial submarginal scalloped gingivectomy incision was scored on the buccal gingiva at the level of the CEJ **(Fig 4b)**. Sulcular incisions were placed from the mesial to the distal line angles for each tooth. Split-thickness incisions were placed at the middle third of the papillae area with the papillae tips left intact. A buccal mucoperiosteal flap was raised over the buccal bone, and a split-thickness flap was created in the area of the papillae **(Fig 4c)**.

An osteoplasty was performed to reduce buccal alveolar bone thickness and to produce concave surfaces at interradicular areas **(Figs 4d & 4e)**. An ostectomy was performed to establish the desired 2-mm distance between the CEJ and the bone crest.[12] Sutures (4-0 Vicryl, Ethicon; Bridgewater, NJ) and oral tissue adhesive (PeriAcryl, GluStitch Inc.; Delta, BC, Canada) were used to secure the flap at the CEJ level **(Fig 4f)**.

Follow-up

At the six-month postoperative appointment, the patient's gingival tissue appeared to have healed and matured and reached the final position.[13,14] A direct composite resin restoration was used to close the diastema between #8 and #9 **(Fig 5)**. A final intraoral digital impression was made with the intraoral scanner and overlaid on the preoperative CBCT scan to evaluate the amount of clinical crown exposure gained **(Fig 6)**. Approximately 2 mm of tooth exposure was gained from the esthetic crown-lengthening procedure. The patient was satisfied with the esthetic results and reported no postoperative complications.

Figures 4a-4f: Esthetic crown lengthening for teeth #4-#13. (a) Gingival markings. (b) Scalloping incisions on buccal aspect. (c) Full-thickness flap reflected; note alveolar crest level in relation to the CEJ.
(d) After osteotomy and ostectomy. (e) Preoperative and postoperative bone thickness. (f) Flap sutured.

Figure 5: Six-month postoperative views. (a) Frontal smile. (b) Frontal intraoral view

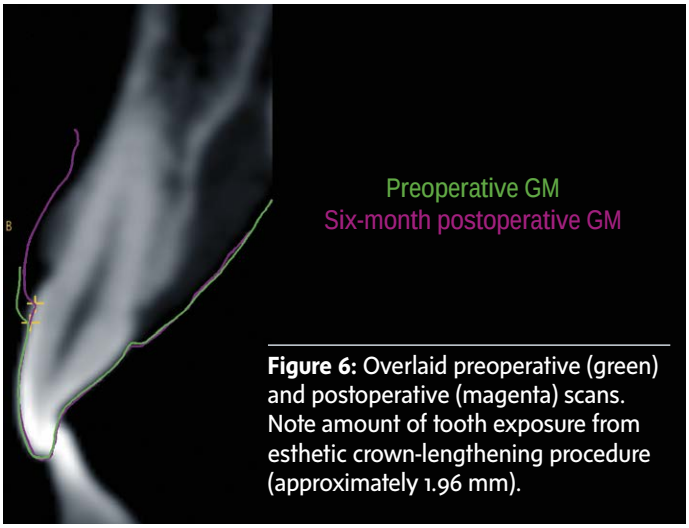

Figure 6: Overlaid preoperative (green) and postoperative (magenta) scans. Note amount of tooth exposure from esthetic crown-lengthening procedure (approximately 1.96 mm).

Discussion

This case report describes the diagnosis and treatment of a patient with altered passive eruption utilizing a combination scan technique. In general, it is difficult to noninvasively establish the relationship between the cementoenamel junction and the alveolar bone in cases of APE because of a tightly attached long junctional epithelium and the CEJ being at the level of, or apical to, the alveolar bone crest.[9] Although previous studies employed radiographic tools to determine the dimensions of dentogingival components,[7,8] 2D radiographs do not allow for three-dimensional (3D) evaluation of the GM, CEJ, alveolar bone crest, and bone thickness.[9]

Several studies have investigated the use of CBCT for 3D evaluation of the dentition.[8,9] Januário and colleagues[10] used two CBCT scans to measure hard and soft tissue components, and Batista and colleagues[11] employed a single CBCT scan to identify anatomical features. The current study utilized a CST, wherein intraoral scans were overlaid on a single CBCT scan with the teeth as common hard tissue landmarks. Including intraoral scans as part of the CST reduces the radiation dose compared to Januário and colleagues' technique, since only a single CBCT scan is needed and it also provides a more distinct and accurate soft tissue surface. This technique is a better alternative than simply altering the contrast/threshold values of a CBCT scan, as an STL file allows for better and more accurate visualization and measurement of hard and soft tissue surfaces. The superimposition and merging of the intraoral STL model on the CBCT scan is accurate and repeatable because common hard tissue landmarks are used for reference. The information obtained from the CST allows for more customized, patient-centered diagnosis and treatment and results in a more predictable outcome that can be evaluated over time for long-term soft tissue stability, and the tissue can be rebound around the surgically exposed crowns because of the crown-lengthening procedure.[13,14] This technique also provides easy visualization of a cross-sectional model that clinicians can show patients to discuss treatment options in an informative and engaging way that reduces patient anxiety and enhances treatment acceptance.

Tips for Combination Scan Technique

Beginner

- Pursue continuing education to master the evaluation of patients using principles of facial esthetics, dental esthetics, dentogingival esthetics, and gingival phenotypes.
- Perform a comprehensive intraoral and extraoral examination that includes obtaining the appropriate photographs, lip and teeth measurements, intraoral digital impression, and complete periodontal evaluation.

Intermediate

- Obtaining an accurate overlay or merge of the intraoral scan and CBCT is paramount to making accurate measurements.
- Highly radiopaque materials such as restorations containing metal, gutta-percha as well as dental implants can cause artifacts and scatter in the CBCT that will make it difficult to obtain an accurate stitch.

Advanced

- Take into consideration the multitude of etiologies that can cause excessive gingival display, including hypermobile lip, vertical maxillary excess, short upper lip, deep bite or dental alveolar extrusion, or altered passive eruption.
- In cases with altered passive eruption, in addition to the vertical positional dentogingival relationship, consider the horizontal soft tissue and alveolar bone thicknesses as confounding factors.
- Accurate transfer of the preoperative measurements and precise surgical execution of the predetermined plan are paramount.

Despite reported positive esthetic and psychological effects of surgical correction of gummy smiles,[15] and compared to studies of functional crown lengthening, there remains a lack of studies investigating treatment planning, surgical outcomes, and prognosis of esthetic crown-lengthening procedures. Perhaps the variability in the distance between the CEJ and the alveolar bone crest limits investigation in this area because it complicates the diagnostic process and the preoperative determination of the amount of ostectomy required to address the APE with current techniques.[16] Use of the CST can address these limitations.

Even though the CST can be beneficial, clinicians should use caution when employing this technique since, unlike traditional bone sounding, it involves exposing patients to additional radiation. The added cost of equipment for the CBCT and intraoral scans may also be a limiting factor for use of this combined technique. Further, if the scans are improperly aligned, there is the potential for measurement errors and subsequent misdiagnosis. When considering the CST for treatment planning, clinicians should discuss the risks, benefits, and alternatives with the patient, and the patient's preferences should be incorporated into the treatment plan.

Summary

The case discussed in this article employed a novel combination scan technique to evaluate and diagnose a patient with altered passive eruption and a chief complaint of a gummy smile. Successful management of the case involved proper identification of the etiologic factors contributing to the APE and the combined use of CBCT and intraoral scans to determine the best treatment plan and application of indicated surgical techniques.

References

1. Allen EP. Surgical crown lengthening for function and esthetics. Dent Clin North Am. 1993 Apr;37(2):163-79.
2. Peck S, Peck L, Kataja M. The gingival smile line. Angle Orthod. 1992 Summer;62(2):91-100.
3. Volchansky A, Cleaton-Jones PE. Delayed passive eruption: a predisposing factor to Vincent's infection? J Dent Assoc S Afr. 1974 May;29(5):291-4.
4. Nart J, Carrió N, Valles C, Solís-Moreno C, Nart M, Reñé R, Esquinas C, Puigdollers A. Prevalence of altered passive eruption in orthodontically treated and untreated patients. J Periodontol. 2014 Nov;85(11):e348-53.
5. Coslet JG, Vanarsdall R, Weisgold A. Diagnosis and classification of delayed passive eruption of the dentogingival junction in the adult. Alpha Omegan. 1977 Dec;70(3):24-8.
6. Garber DA, Salama MA. The aesthetic smile: diagnosis and treatment. Periodontol 2000. 1996 Jun;11(1):18-28.
7. Levine RA, McGuire M. The diagnosis and treatment of the gummy smile. Compend Contin Educ Dent. 1997 Aug;18(8):757-62.
8. Alpiste-Illueca F. Dimensions of the dentogingival unit in maxillary anterior teeth: a new exploration technique (parallel profile radiograph). Int J Periodontics Restorative Dent. 2004 Aug;24(4):386-96.
9. Zucchelli G. Altered passive eruption. In: Zucchelli G, editor. Mucogingival esthetic surgery. Berlin: Quintessence Pub.; 2013. p. 749-93.
10. Januário AL, Barriviera M, Duarte WR. Soft tissue cone-beam computed tomography: a novel method for the measurement of gingival tissue and the dimensions of the dentogingival unit. J Esthet Restor Dent. 2008;20(6):366-73.
11. Batista EL Jr, Moreira CC, Batista FC, de Oliveira RR, Pereira KK. Altered passive eruption diagnosis and treatment: a cone beam computed tomography-based reappraisal of the condition. J Clin Periodontol. 2012 Nov;39(11):1089-96.
12. Camargo PM, Melnick PR, Camargo LM. Clinical crown lengthening in the esthetic zone. J Calif Dent Assoc. 2007 Jul;35(7):487-98.
13. Deas DE, Moritz AJ, McDonnell HT, Powell CA, Mealey BL. Osseous surgery for crown lengthening: a 6-month clinical study. J Periodontol. 2004 Sep;75(9):1288-94.
14. Arora R, Narula SC, Sharma RK, Tewari S. Evaluation of suprascrestal gingival tissue after surgical crown lengthening: a 6-month clinical study. J Periodontol. 2013 Jul;84(7):934-40.
15. Ribeiro FV, Hirata DY, Reis AF, Santos VR, Miranda TS, Faveri M, Duarte PM. Open-flap versus flapless esthetic crown lengthening: 12-month clinical outcomes of a randomized controlled clinical trial. J Periodontol. 2014 Apr;85(4):536-44.
16. Mele M, Felice P, Sharma P, Mazzotti C, Bellone P, Zucchelli G. Esthetic treatment of altered passive eruption. Periodontol 2000. 2018 Jun;77(1):65-83.

jCD

Dr. Abdulkarim is an assistant professor of dental implants and periodontics at A.T. Still University-Missouri School of Dentistry & Oral Health (ATSU-MOSDOH), in St. Louis, Missouri.

Dr. Vij is the specialty care unit director of esthetic and digital dentistry at ATSU-MOSDOH, in St. Louis, Missouri.

Dr. McLeod is the dean of ATSU-MOSDOH, in St. Louis, Missouri.

Disclosures: The authors did not report any disclosures.



jCD
Journal of Cosmetic Dentistry

Submit your case or most intriguing photo concept for the front cover of the *jCD!*

Send inquiries to publications@aacd.com

Properly Contoured and Tight Contacts in the Maxillary Anterior Dentition

Ingrida Ivance, DDS, AAACD

Abstract

The clinical case documented in this article demonstrates an approach to direct composite veneers with the buildup of proximal contact areas achieved using the individualized matrix technique. Working in a clinical setting, this matrix technique facilitates the accurate buildup of physiological proximal contact areas without overhangs of composite resin in the cervical region and with a close fit at the margins. This technique gives a high degree of reliability and produces controlled, predictable results.

Key Words: Direct composite restoration, tight proximal contacts, conservative, anterior esthetics



Bonus content!

See the digital edition of the *jCD* for a technique video that demonstrates key concepts in this article.

Introduction

Providing successful direct composite restorations, especially in the esthetic zone, requires several things from the clinician, including a thorough understanding of the dental anatomy as well as the colors and materials involved. One of the main challenges is achieving properly contoured and tight proximal contacts.

Different methods can help the clinician to restore a tight, well-contoured proximal contact surface correctly. Various matrices and techniques such as freehand modeling, use of a silicone index alone or combined with Teflon tape, Mylar pull through, anterior transparent matrix, anterior/posterior metallic matrices, have been described to aid practitioners in obtaining predictable results.[1-8] More recently, true anatomical matrix systems (e.g., Bioclear, Bioclear Matrix Systems; Tacoma, WA and Uveneer, Ultradent; South Jordan, UT) as well as the injectable molding technique and others, bring esthetic restorations within everyone's capability because of their simplicity and versatility, allowing the dentist to capture the final contour and volume of the material used.[9-11]

The restoration of a functionally and morphologically correct tooth shape and proximal contact areas allows the formation of harmonious interdental papillae, keeping food from packing between the teeth, and helps stabilize the dental arches through the combined anchorage of all the teeth in positive contact with each other.[12] In the literature, the terms *contact point* and *contact area* have been used interchangeably. Research suggests that between maxillary anterior teeth, proximal contact areas (PCAs) are observed, not contact points.[13] Contact points appear when contacting surfaces exhibit perfect curvatures and are commonly observed in young patients with newly erupted teeth.[12] The dimensions of anterior PCAs should be taken into consideration when restoring teeth in a clinical setting **(Figs 1a & 1b)**.[13]

The shape of each contact area of maxillary anterior teeth depends on the anatomical shape of the teeth (rectangular, triangular, oval), the type (canines, laterals, central incisors), the surface location (lateral, mesial), and the distance between the teeth (diastemas, crowding, loss of interproximal space due to poor restorations). Due to the number of initial conditions that must be present, it is essential to have a large variety of anatomically preformed matrices at one's disposal. The author uses the technique described below, wherein the matrices can easily be made chairside.[6]

Custom Proximal Contact Area Matrices

The individual shaping and subsequent fitting of the transparent matrix allows for the accurate construction of the specific outline of the proximal contact area.[14] First, the dentin core and the palatal and vestibular surfaces are constructed. This is followed by the construction of the interproximal contacts. If multiple anterior teeth are restored, then the order of restoration of contact areas should be from the canines to the center.

Fabricating a Preformed Contour Matrix

A long, contoured stainless steel strip was used to fabricate a contour matrix. Called the "wave" because of its shape, this device can be made by a dental technician and installed on an accessible corner of dental furniture **(Fig 2a)**. To fabricate a preformed matrix, a transparent strip (Hawe Striproll, Kerr; Orange, CA) with a 10-mm width and 0.05-mm thickness should be pressed on a working surface of the "wave." This is done by first applying pressure to define the contact contour and then by gradually reducing the pressure, completing the formation of the required proximal curvature **(Figs 2b & 2c)**.

The matrix should be less convex for anterior teeth with a rectangular or triangular shape, incisors, mesial surfaces, cases of crowded teeth, or cases with a loss of distance between the teeth due to failing restorations. The matrix should be more

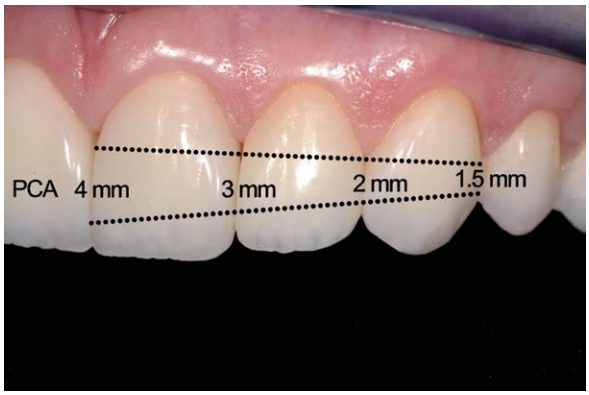

Figure 1a: The 4-3-2-1.5 rule of the PCA. The apicoincisal extent of PCA between the eight maxillary anterior teeth.

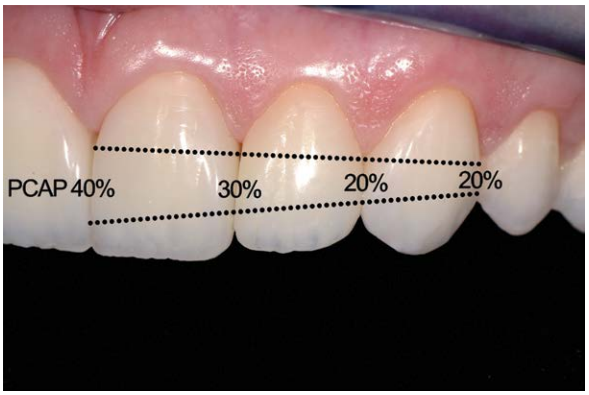

Figure 1b: The proximal contact area proportion (PCAP) refers to the percentage ratio of mesial PCA to individual crown length.

Figure 2a: A wave-shaped chairside device for the fabrication of a preformed contour matrix.

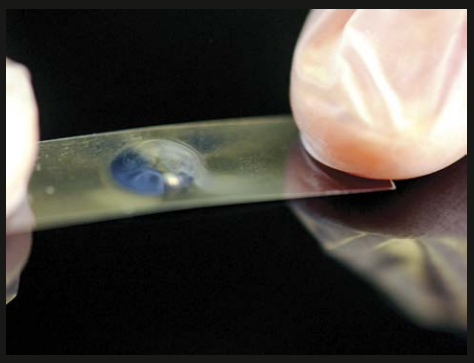

Figures 2b & 2c: The individual shaping and subsequent fitting of the transparent strip allows the accurate construction of the specific outline of the proximal contact area.

Figure 3: Preoperative full-smile view.

convex for oval teeth, canines, distal surfaces, or when closing diastemas. If teeth are longer (e.g., with periodontal pathology), it is advisable to use two overlapping matrices.

The use of thicker matrices is not recommended due to a significant wedging of teeth to obtain tight contacts. The more wedging is done, the more painful the procedure becomes. The use of transparent wedges (Luciwedges Soft, small, or medium, KerrHawe; Bioggio, Switzerland) facilitates visibility in the operation field and allows composite polymerization in approximal surfaces.

Clinical Case Report

History, Evaluation, and Treatment Plan

A healthy 34-year-old female presented to the author's practice at the end of her orthodontic treatment expressing esthetic concerns about her teeth. She wanted a warm, brighter, natural-looking smile to enhance her appearance **(Fig 3)**. She did not want any invasive treatment. In addition to the orthodontic treatment, her dental history included routine fillings and endodontic treatment on tooth #9.

The initial clinical examination included intraoral analysis of preexisting restorations, occlusion, periodontal health, and digital radiography and photography **(Figs 4a-4d)**. Root canal treatment and a core buildup with a fiber post and composite resin for #9, implantation of #3, and laser gingival recontouring for #4, #5, #12, and #13 were planned. Taking into consideration the patient's age, sound tooth structure, and the patient's preference for additive, minimally invasive procedures, direct resin veneers were chosen as the treatment modality for teeth #6-#11. During the final month of orthodontic treatment, the patient was seen several times to emphasize teeth position, especially maxillary, to the orthodontist.

Treatment

Composite: A nanohybrid composite based on a natural layering concept[15] with only two layers (dentin and enamel) to mimic the tooth structure and appearance[16] was chosen to enhance the patient's smile (inspiro direct, Edelweiss DR; Zug, Switzerland) **(Fig 5)**.

Under local anesthesia, the old composite was removed from #9 and the mesial aspect of #8. No preparation was done for teeth #6, #7, #10, and #11. When giving the preparation its final inspection, any unstable or overhanging enamel structures were removed using an extra-fine diamond bur (7803, Shofu Dental; San Marcos, CA), as these overhangs have a negative effect on the adhesive bond of the restoration **(Fig 6a)**. Weak enamel structures left untrimmed at the margins lead to the so-called "prism effect" once composite is applied.[17]

Acid-etching and adhesion: The rubber dam was applied from teeth #4 to #13 for better working field isolation[18] and for a full-smile view. A clamp (#212, Hu-Friedy; Chicago, IL) was placed to facilitate access to tooth #9. The prepared #9 was sandblasted with 27-µ aluminum oxide (PrepStart, Danville Materials; San Ramon, CA) to clean the preparation and enhance adhesion.[19]

Clear Mylar strips were used in the interproximal areas to confine acid-etching only to the tooth currently being treated.

Figure 4a: Preoperative 1:2 smile view: note an excessive gingival display at teeth #4, #5, #12, and #13.

Figures 4b-4d: Preoperative 1:1 close-up images revealing insufficient facial enamel volume, composite restorations interproximally and at the incisal edges, and a medium-sized Class IV defect on #9.

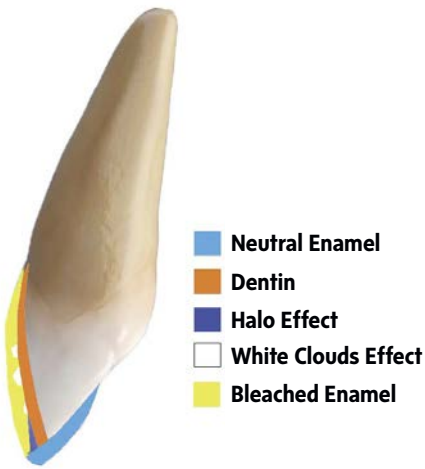

Figure 5: Side view of composite veneer showing color and thickness map.

Acid-etching with 38% phosphoric acid (Etch-Rite, Pulpdent; Watertown, MA) was performed over the enamel for 30 seconds and the dentin for 15 seconds. This was done to remove the smear layer that forms after dentin preparation and to open collagen fibers. Subsequently, adhesive (Adhese Universal, Ivoclar Vivadent; Amherst, NY) was rubbed[20] into the enamel and dentin for 20 seconds, air-thinned, and light-cured for 10 seconds.

Composite placement: The lingual shelf enamel wall was modeled freehand using a neutral enamel shade (Skin Neutral, inspiro). This layer replicates the lingual layer of enamel and serves as a foundation upon which subsequent layers are formed **(Fig 6b)**. The dentin shade (Body i1, inspiro) was applied in the cervical middle half of the tooth and extended into the incisal third to start the development of the dentinal lobes. The string-like projections of the mamelons were brought toward the halo area to complete mamelon creation.[2] The layer was light-cured for 20 seconds **(Fig 6c)**.

An artist's brush (#1, Cosmedent; Chicago, IL) was used to apply a little halo effect tint (Effect Shade Azur, inspiro) in be-

Figure 6a: Prepared surfaces of #9. Any unstable or overhanging enamel structures were removed.

Figure 6b: The palatal thin enamel wall was modeled freehand using a semitranslucent enamel shade.

Figure 6c: View showing the extent of the completed dentin core and the effect tints. Space has been left for the facial enamel mass.

Figure 6d: View of the completed essential stages of restoration. Space has been left for the contact enamel mass.

Figure 7: The two contact surfaces were separated using a wedge and transparent matrix.

Figure 8: The semitranslucent enamel mass applied against the shaped matrix in a layer 0.5 mm thick.

tween the mamelons to achieve an opalescent incisal effect. A white tint (Effect Shade Ice, inspiro) spread into "clouds"[1] over the labial surface of the dentin created diffused white areas and elevated the value of the tooth **(Figs 5, 6c)**.

A final enamel layer of bleached enamel shade (Skin Bleach, inspiro) was applied to cover the facial aspect of the tooth. The final layer should be about 10% over contoured. During finishing, this layer is removed to reach ideal volume and contour.[2] All layers were light-cured for 20 seconds **(Fig 6d)**.

The completion of the essential stages of restoration was followed by the construction of mesial and distal contacts.

Matrix placement and composite application: The preformed individual matrix was placed in the subgingival area between the rubber dam and the surface of the tooth. The teeth were separated by positioning the interdental wedge so that the cervical part of the strip did not move during the formation of the contact area. It is critical to carefully adapt the matrix in the cervical region, especially from the palatal side. This ensures the close fit of the composite resin at the margins without overhangs and decreases finishing procedures **(Fig 7)**.

One of the benefits of the transparent strip is the absence of an oxygen inhibition layer at the interface with the gingival tissue. The composite cured against a Mylar strip leaves a highly polished surface,[21] eliminating the need to use rotary instruments below the free gingival margin for finishing.

Acid-etching was performed, and the surface was rinsed and air-dried. The adhesive was applied and air-thinned. The surface was light-cured for 20 seconds. Self-etch adhesives also can be employed in this step. Transparent, neutral, or another shade of composite corresponding to the opacity of the enamel surface can be used. Stiff composites are contraindicated due to the resistance they may impart in this technique. To reduce viscosity, increase flowability, and improve physical and mechanical properties, composite preheating using composite warmers has been suggested.[22] In this case, neutral enamel shade (inspiro Skin Neutral) was used.

The composite was distributed along the contact surface with a thin spatula (IPCT, Cosmedent). An artist's brush (#3, Cosmedent) helped to adapt and smooth the composite **(Fig 8)**. Modeling liquid (Composite Wetting Resin, Ultradent; South

> *It is critical to carefully adapt the matrix in the cervical region, especially from the palatal side. This ensures the close fit of the composite resin at the margins without overhangs and decreases finishing procedures.*

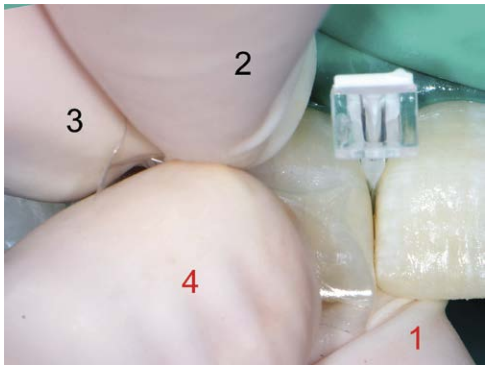

Figure 9a: The sequence and combination of fingers during the contact modelling of the mesial contact of #8: 1, right index; 2, left index; 3, left thumb; 4, right thumb.

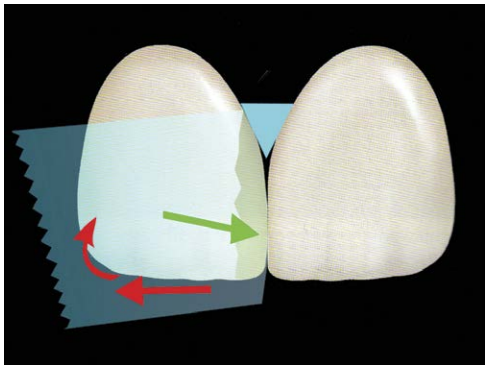

Figure 9b: Tightly holding the matrix in the cervical area (fingers 1-3), stretch it downward and mesially until the matrix contact with the neighboring surface reaches the required height of the contact area (green arrow). Form a fold using finger 4 (red arrows). The part of the matrix located below the fold forms the corner of the incisal edge.

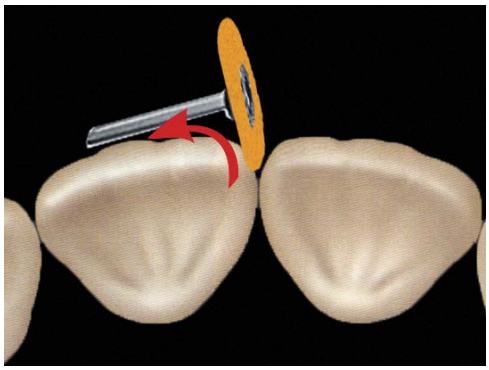

Figure 10a: Work on each transition line.

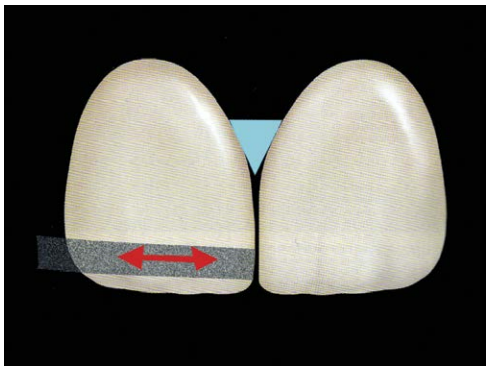

Figure 10b: The glossy layer is removed from the contact surface with diamond strips of different abrasive grades.

Jordan, UT) was used carefully to give the brush an optimal moisture and consistency that prevents composite from sticking to it and maintains the bristles' uniformity.[1] These instruments enable modeling in narrow spaces and even penetrating them from side to side.

The composite was pushed under the matrix from the vestibular side until it appeared on the palatal surface. It is necessary to keep condensing until there is excess material showing on the palatal side. If needed, an additional increment of composite can be placed from the palatal side. The composite was then rubbed to the surface along the cervix, toward the contact surface, and along the corner of the incisal edge.

Contact surface modeling: The palatal part of the matrix was pulled down slightly and fixed, and the vestibular part of the matrix was stretched downward and mesially until the matrix contact with the neighboring surface reached the required height of the contact area. Once the matrix was stretched, the composite shifted from the interdental wedge toward the incisal edge. A fold was formed along the vestibular surface at the same time a contact area was being established. Due to fold formation, the part of the matrix located below the fold formed the corner of the incisal edge. In this process, the excess composite shifts below the incisal edge **(Figs 9a & 9b)**.

The achieved result of the contact surface formation is fixed by polymerization for 10 seconds per vestibular and palatal sides.

Tip: When performing contact surface modeling, the clinician is best positioned by pulling the matrix toward himself or herself. The sequence and combination of fingers during the contact modelling of the mesial contact of #9 would be:

1, left index; 2, right index; 3, right thumb; 4, left thumb. The clinician would be on the patient's left side.

Removing the excess and modeling a corner: An extra-coarse disc (Sof-Lex, 3M; St. Paul, MN [or finishing bur 806 314 250 016, Acurata; Thurmansbang, Germany]) was used to remove the composite excess at the transition of the contact surface into the palatal and vestibular surfaces. It also was used at the fold along the vestibular surface and at the corner of the incisal edge **(Fig 10a)**.

The composite excess at the incisal corner was removed with the above-mentioned disc/finishing bur. The interdental wedge must be inserted beforehand to protect the neighboring surface. Then, the glossy layer was also removed from the contact surface with fine and super-fine diamond strips (Brasseler; Savannah, GA) **(Fig 10b)**. The smoothness of the contact surfaces was checked with dental floss.

Tip: After one interproximal wall and incisal angle is done, the protocol is repeated for the neighboring tooth. When working on the middle line between #8 and #9, it is recommended to begin restoring contact from the tooth that appears narrower.

Contouring, finishing, and polishing: After an initial evaluation of the primary anatomy, a Sof-Lex extra-coarse composite polishing disc and red-striped, flame-shaped fine and yellow-striped, flame-shaped extra-fine diamonds (8859-010 and 859EF-010, Brasseler) were used to remove excess material, recontour, and establish outline forms and the facial planes. Facial surfaces of the restoration were obtained respecting the transitions and inclinations between the cervical, middle, and incisal thirds, along with the transitional line angles. Contouring of the mesial proximal transitional surfaces should be completed meticulously prior to adjusting the distal surface.[23]

The flame-shaped burs in a red slow-speed contra-angle handpiece were worked along the axis of the teeth from mesial to distal to create the macro texture details and form perikymata on the surfaces **(Figs 11a & 11b)**. Excess material on the palatal sides was removed using a football-shaped fine diamond (806 314 277 023, Acurata).

The central incisors were checked with a digital caliper (Dentagauge, Erskine Oral Care; Macksville, NSW, Australia) to verify symmetrical mesiodistal widths. The proximal surfaces were polished with finishing strips of different abrasive grades (Edenta AG; St. Gallen, Switzerland; and Sof-Lex Finishing Strips Coarse Medium).

The interproximal zone was inspected using unwaxed dental floss to verify adequate contact and the absence of resin composite tags or gingival overhangs.[11] The proximal contact area should not be left rough or it will cause plaque accumulation.[24] The contact between #8 and #9 was measured through the sounding of the most coronal interproximal bone level, which was at 4 mm, to ensure

Tips

Beginner

- Undetectable integration of composite resin with natural tooth structure requires the use of correct composite materials, as well as the application of a consistent protocol.
- Take a comprehensive hands-on workshop course to gain more in-depth knowledge of the composite restorations.

Intermediate

- Perfect your technique on the model first.
- The best position for the clinician is when the matrix is pulled toward them.
- Stiff composites are contraindicated due to the resistance they may impart in this technique.
- When working on the middle line between #8 and #9, begin restoring contact from the tooth that appears narrower.
- The technique is executed with the help of a dental assistant. After the doctor finishes modeling, the assistant cures the composite.
- Use the red slow-speed contra-angle hand piece for finishing and macro texture of the surface.

Advanced

- Paying careful attention to every detail makes up the essential beauty of the work.

Figures 11a & 11b: The flame-shaped burs were worked along the axis of the teeth to create the macro texture details and produce perikymata on the surfaces.

Figure 11c: Polishing with yellow and gray polishing points.

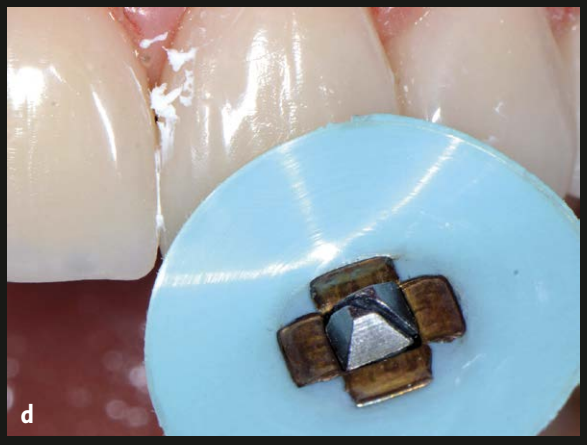

Figure 11d: The final gloss was accomplished by applying polishing paste with a felt wheel.

that the open gingival embrasure would close over time.[25] Facial and palatal surfaces were modeled with ultra-fine diamonds (T&F Hybrid Points LT2, 7406, Shofu Dental; San Marcos, CA).

Proper lingual contours were designed by simulating functional postures and movements. Evaluating dynamic relationships in the clinical setting requires an approach that more closely mimics the outside/in functional pathways.[26] Using this method, static and dynamic occlusions were checked with 200-, 20-, and 8-µ articulating papers (Bausch; Nashua, NH). In the upright position, the incisors should allow 8-µ shimstock to slide through when the teeth are in maximum intercuspation.[26]

If the lingual contours are not appropriately developed, unfavorable consequences can occur, including chipped restorations, sore muscles and joints, tooth mobility, cement fatigue, and attrition.[27] All surfaces were polished using yellow and gray polishing points (Identoflex Composite Polishers, Kerr) and Flexidiscs (Cosmedent) **(Fig 11c)**. Labial surface texture is determined by how long the yellow point is applied and by the amount of pressure used.

Before the final polishing, the restorations were covered with a water-soluble glycerin gel to prevent the oxygen-inhibited layer (Liquid Strip, Ivoclar Vivadent). Final polymerization was then carried out with 20-second cycles on the palatal and facial

Figures 12a-12c: Postoperative anterior images. The precise contact areas of required height and tightness allow the formation of interdental papillae, keeping food from packing between the teeth.

Figure 12d: Postoperative retracted close-up view. The width of the central incisors appears symmetrical.

Figure 12e: Postoperative full-smile portrait view of the very satisfied patient.

sides to obtain the maximum monomer conversion in the uppermost layer of composite material, normally inhibited by oxygen.[28] Prior to polishing, the glycerin was rinsed off; the result was a harder composite surface that was easier to finish.[29] The final gloss was obtained by polishing surfaces with a Flexibuff disc and Enamelize paste (Cosmedent) **(Fig 11d)**.

The patient was given home care instructions and scheduled to return three days later for a final check of function and esthetics, and to complete photographic documentation **(Figs 12a-12e)**. During this appointment, the patient was encouraged to return for maintenance procedures, such as refinishing and/or repolishing surface roughness, slight marginal defects, and slight marginal discoloration, as these will lengthen the lifespan of the restorations.[31,32]

Summary

Achieving physiologically tight contacts is a significant challenge when restoring anterior teeth. The individualized matrix technique offers a method to accurately produce controlled functional, esthetic, and long-lasting outcomes.

Acknowledgments

The author is grateful to Dr. Serhiy Radlinsky (Poltava, Ukraine), Dr. Didier Dietchi (Geneva, Switzerland), and Dr. Newton Fahl (Curitiba, Brazil) for their inspiration and mentorship in direct composite restorations.

References

1. Manauta J, Salat A. Layers: an atlas of composite resin stratification. Milan: Quintessence Pub.; 2017. p. 114-6.

2. Fahl N. Step-by-step approaches for anterior direct restorative challenges: mastering composite artistry to create anterior masterpieces—part 2. J Cosmetic Dent. 2011 Winter;26(4):42-55.

3. LeSage B, Milnar F, Wohlberg J. Achieving the epitome of composite art: creating natural tooth esthetics, texture, and anatomy using appropriate preparation and layering techniques. J Cosmetic Dent. 2008 Fall;24(3):132-41.

4. Denehy G. Simplifying the Class IV lingual matrix. J Esthet Dent. 2005 Sep;17(5):312-9.

5. Meiser HP. Case report: the margin perfect matrix – a predictable technique for the fabrication of direct composite veneers. Oral Health. Available from: https://www.oralhealthgroup.com/features/case-report-margin-perfect-matrix-predictable-technique-fabrication-direct-composite-veneers/

6. Radlinsky S. Restoration of proximal contact areas in the maxillary anterior dentition. 2008. Russian. Available from: DentArt. http://dentart.org/?p=558.

7. Lazar D. Class IV restoration with Unica anterior. Available from: https://www.styleitaliano.org/class-iv-restoration-with-unica-anterior/

8. Manauta J. Synchro matrix. Available from: https://www.styleitaliano.org/synchro-matrix/

9. Clark D. Advanced techniques for diastema closure: a microscopic perspective. Contemp Esthet. 2007 Sep;36-41. Available from: https://www.endoexperience.com/documents/ContempEsthetBioclearDiast.pdf

10. Lowe RA. Uveneer: simplifying artistic direct composite veneering. Dent Today. May 2015:1-5. Available from: https://www.dentistrytoday.com/k2/item/803-uveneer-simplifying-artistic-direct-composite-veneering

11. Terry DA. Restoring with flowables. Hanover Park (IL): Quintessence Pub.; 2017. p. 65-67.

12. Nelson SJ. Wheeler's dental anatomy, physiology, and occlusion. 10th ed. New York: Elsevier; 2014. p. 102-27.

13. Stappert CF, Tarnow DP, Tan JH, Chu SJ. Proximal contact areas of the maxillary anterior dentition. Int J Periodontics Restorative Dent. 2010 Oct;30(5):471-7.

14. Ness JC. Anterior anatomy and the science of a natural smile. Morgan Hill (CA): Productivity Training Corp; 2011-2015. p. 96-101.

15. Dietschi D. Optimising aesthetics and facilitating clinical application of free-hand bonding using the 'natural layering concept.' Br Dent J. 2008 Feb 23;204(4):181-5.

16. Inspiro product brochure. Available from: https://edelweissdr.com

17. Hugo B. Esthetics with resin composite: basics and techniques. Berlin: Quintessence Pub.; 2008. p. 19-20.

18. Heintze SD, Rousson V, Hickel R. Clinical effectiveness of direct anterior restorations––a meta-analysis. Dent Mater. 2015 May;31(5):481-95.

19. Mujdeci A, Gokay O. The effect of airborne-particle abrasion on the shear bond strength of four restorative materials to enamel and dentin. J Prosthet Dent. 2004 Sep;92(3):245-9.

20. Zander-Grande C, Ferreira SQ, da Costa TR, Loguercio AD, Reis A. Application of etch-and-rinse adhesives on dry and rewet dentin under rubbing action: a 24-month clinical evaluation. J Am Dent Assoc. 2011 Jul;142(7):828-35.

21. Yazici AR, Tuncer D, Antonson S, Onen A, Kilinc E. Effects of delayed finishing/polishing on surface roughness, hardness and gloss of tooth-coloured restorative materials. Eur J Dent. 2010 Jan;4(1):50-6.

22. Lucey S, Lynch CD, Ray NJ, Burke FM, Hannigan A. Effect of pre-heating on the viscosity and microhardness of a resin composite. J Oral Rehabil. 2010 Apr;37(4):278-82.

23. Kataoka S, Nishimura Y, Sadan A. Nature's morphology: an atlas of tooth shape and form. Hanover Park (IL): Quintessence Pub.; 2002. p. 59-65.

24. Ichimaru T, Saito S, Matsuzaki A, Ando Y, Furukawa K. [Plaque accumulation (S. mutans) in various dental restorative materials and fluoro-resins (in vitro)]. Shika Zairyo Kikai. 1989 May;8(3):337-48.

25. Tarnow DP, Magner AW, Fletcher P. The effect of the distance from the contact point to the crest of bone on the presence or absence of the interproximal dental papilla. J Periodontol. 1992 Dec;63(12):995-6.

26. M. Bakeman EM, Kois J. The myth of anterior guidance. 10 steps in designing proper clearance for functional pathways. J Cosmetic Dent. 2012 Fall;28(3):56-62.

27. Dawson PE. Evaluation, diagnosis, and treatment of occlusal problems. 2nd ed. St Louis: Mosby; 1989. p. 2-32.

28. Gauthier MA, Stangel I, Ellis TH, Zhu XX. Oxygen inhibition in dental resins. J Dent Res. 2005 Aug;84(8):725-9.

29. Park HH, Lee IB. Effect of glycerin on the surface hardness of composites after curing. J Korean Acad Conserv Dent. 2011 Nov;36(6):483-9.

30. Fernández E, Martín J, Vildósola P, Oliveira Junior OB, Gordan V, Mjor I, Bersezio C, Estay J, de Andrade MF, Moncada G. Can repair increase the longevity of composite resins? Results of a 10-year clinical trial. J Dent. 2015 Feb;43(2):279-86.

31. Hickel R, Brüshaver K, Ilie N. Repair of restorations—criteria for decision making and clinical recommendations. Dent Mater. 2013 Jan;29(1):28-50.

32. Peumans M. Clinical performance of direct and indirect adhesive restorations: longitudinal medium- to long-term results. J Cosmetic Dent. 2015 Spring;31(1):110-27. **jCD**



Dr. Ivance is an AACD Accredited member. She practices in Vilnius, Lithuania.

Disclosure: The author did not report any disclosures.

"Evaluating dynamic relationships in the clinical setting requires an approach that more closely mimics the outside/in functional pathways."



POST-ORTHODONTIC RESTORATIVE SOLUTION:

Conservative Techniques with Direct Composite Bonding

Kevin M. Brown, DDS, AAACD

Abstract

With the popularity and success of clear aligner therapy, more adults are electing to improve their smiles with orthodontic treatments. Yet even after their teeth are straight, many of these patients remain unsatisfied with their smiles, which still exhibit worn or chipped incisal edges or residual spacing. Influenced by social media "success stories" and orthodontist recommendations, many adult patients are consulting with restorative dentists on conservative and affordable treatment options for their post-orthodontic smile enhancement needs and wishes. As a result, restorative dentists are seeing direct composite bonding in the anterior segment as an increasingly popular treatment choice to improve the smiles of their patients, especially adults completing orthodontic treatment. Although it might be more challenging technically, the direct deposit bonding procedure—when performed utilizing sound principles and the proper esthetic materials—allows for predictable results in a noninvasive, conservative, and economical manner that often does not require anesthesia. Equally important, it produces happy, satisfied, and grateful patients with beautiful smiles.

Key Words: composite bonding, composite layering, diagnostic wax-up, Class IV fracture, post-orthodontic, anterior teeth

Learning Objectives

After reading this article, the participant should be able to:

1. Understand how different direct composite materials are used to create polychromatic layered restorations and the value these materials bring in producing beautiful end results.
2. Efficiently perform each step in the sequence of polychromatic layering to deliver predictable and reliable results.
3. Recognize how being able to give the patient options for post-orthodontic cosmetic enhancements that are less invasive and sometimes more cost-effective will gain patient confidence and potentially bring more patients to your practice.

Disclosure: The author did not report any disclosures.

Introduction

With the advent of clear aligner orthodontic therapy, a growing number of people, especially adults, are choosing to straighten their teeth.[1] Yet even after their teeth are straight, many of these adult patients remain unsatisfied with their smiles, which still exhibit residual spacing or uneven, worn, or chipped incisal edges resulting from years of wear due to previous malocclusion, destructive habits, or sleep bruxism (a possible side effect of obstructive sleep apnea).[2]

Consequently, many dental practices are seeing these patients for post-orthodontic consultations to discuss options to correct worn incisal edges, residual spaces, diastemas, or undersized teeth. Increasingly aware of current dental materials and techniques as a result of education from their orthodontists and social media posts from others sharing their own smile-enhancing treatments, these adult patients come prepared with a list of demands and expectations.

In such instances, restorative treatment options consist of direct, indirect, or a combination of the two methods. Some patients choose treatment with indirect porcelain restorations, but not all. Many other patients—seeking a conservative, non-invasive alternative that is also economical, especially after just having paid for costly orthodontics—are opting for direct composite bonding.

Advantages and Disadvantages of Direct Composite Bonding Versus Indirect Porcelain Restorations

From a patient's perspective, the two biggest advantages of direct composite are affordability and tooth structure preservation. Modern composite bonding can serve as a more economical alternative for patients unable to afford costly indirect restoration treatment for multiple teeth.[3] And even when a patient's ability to afford porcelain veneers is not a consideration, the ultra-conservative nature of direct composite bonding—whether it involves one tooth or several—appeals to many since it does not involve drilling.

The main disadvantage of direct composite bonding is expected longevity. Considering the many individual variables that may affect longevity, restorative dentists should present patients with a broad range of predictability; any direct anterior restoration can last between five to approximately 15 years.[4] However, this concern is somewhat offset by patients' realization that with composite bonding they have the option of eventually transitioning into the more durable porcelain in the future, if needed or desired.

From a dentist's perspective, it often is a matter of familiarity and skill level. Some restorative dentists may lean toward the indirect method simply because they do not feel as confident doing a direct resin restoration. While this hesitance is understandable and justifiable, it is the author's opinion that the polychromatic layering of dental composites can be mastered by anyone who devotes the time and effort to practice the technique.

> *"Lighting is a key factor when creating reflective and deflective zones and making the surface texture visible on the natural tooth that is to be replicated."*

Clinical Recommendations for Restorative Success with Direct Composite Bonding

Whether it involves one tooth or several, the likelihood of success using the direct composite bonding technique in the anterior region increases when dentists follow some general principles and practices. These include the following:

1. Always preplan treatment. Study models made for diagnostic wax-ups are key in tooth preparation to ensure for optimal bond strength, color blending, and marginal masking. It also helps if immediate postoperative photographs are taken at the initial texturizing and polishing appointment so the dentist can later review and evaluate the initial polish in order to have a clear understanding of what details will require fine-tuning at the final polish appointment.
2. When it comes to finishing and polishing—no matter the composite discs, burs, and polishers used—the first step should always be to establish the overall primary outline form, which includes the facial line angles, incisal and facial embrasures, and three facial planes. Once this framework is established, secondary and tertiary facial anatomy and textures can be created. There is no one single bur or polisher that is perfect for every situation; the choice of instruments is up to clinician preference.
3. Lighting is a key factor when creating reflective and deflective zones and making the surface texture visible on the natural tooth that is to be replicated. Available in either silver or gold, a reflective powder, such as Hi-Light (American Dental Supply; Allentown, PA), serves as a useful tool in revealing a tooth's tiniest details. Coating the powder on the natural tooth/teeth that are to be matched will greatly enhance visualization. Clinicians should also reapply it to the tooth/teeth they are working on as they progress through the polishing sequence to ensure they are proceeding well. If they notice any imperfections at this time, they can backtrack a step or two to correct them before progressing to the next stage.
4. Texturing should always be completed with a slow-speed, high-torque handpiece. Electric handpieces work well

Figures 1 & 2: Preoperative views showing uneven incisal edges after orthodontic treatment. Knowing the incisal edges would be restored, the orthodontist did an excellent job of balancing the gingival zeniths.

Figure 3: Lateral view showing the 1.5- to 2-mm incisofacial bevel to help with color blending.

since their settings can be adjusted to the desired revolutions per minute (rpm) and torque. If you do not have an electric handpiece, an air-driven, slow-speed friction grip handpiece, such as Star Dental Titan 3 (Dental EZ; Lancaster, PA) works equally well. (This handpiece was used to complete all three cases discussed in this article.)

5. Particularly when many anterior teeth are to be restored, the appointments should be broken up. Final texturizing and polishing on this many teeth can take about an hour; the lengthy and tiring aspects can take its toll on both patient and dentist. To alleviate the impact, at the first appointment the composites should just be given a quick general shaping, polish, and occlusal verification before the patient is sent home. By giving the patient time to "test-drive" the new smile and the dentist a break, both parties can regroup at a subsequent visit with collaborative feedback to finalize the detail work from a fresh perspective.

Case Presentations

The three cases described in this article illustrate common complaints of patients presenting for post-orthodontic smile enhancements (e.g., uneven incisal edges, old or inferior composite work on anterior teeth, and moderate to severe wear on the maxillary/mandibular anterior teeth). They demonstrate, step by step, how to correct these issues using layered direct composite bonding in an efficient manner that delivers predictable and reliable results. In each of the three case examples, the composite and shades used were Estelite Omega (Tokuyama Dental America; Encinitas, CA). However, it should be noted that there are many composite brands that can provide excellent results; the choice is up to clinicians' individual preferences.

Case 1: Uneven Incisal Edges

Referred by his orthodontist after finishing clear aligner treatment (Invisalign, Align Technology; San Jose, CA), a patient presented to discuss restorative options for the four upper incisors **(Figs 1 & 2)**. These teeth exhibited a common occurrence for adults who undergo orthodontic treatment. For decades these patients functioned with crowding and malocclusion, which created wear patterns on the incisal edges. Once they are in proper alignment, those worn edges do not line up, the smile is not attractive, and the patient is left wanting those imperfections corrected.

The patient was presented with various restorative options and materials, with the choice essentially coming down to porcelain versus composite. Despite the ultraconservative porcelain veneer preparation techniques used with modern ceramics, the patient did not like the prospect of having his teeth drilled for such small adjustments. Instead, he opted for bonding. Although the primary concern when choosing a composite restoration is potential longevity issues due to functional stresses, he reasoned that if he were to have any chipping issues over time, he could eventually transition into porcelain. He also knew he would be wearing retainers (Invisalign Vivera) at night for life, and that these would help protect the restorations.

Therefore, with the treatment choice decided, tooth whitening was performed, and study models made for a diagnostic wax-up. For small incisal additions, tooth preparation is important to help ensure optimal bond strength, color blending, and marginal masking. First, a pumice slurry and a prophy cup were used to preclean the surface of any plaque. Second, a conservative incisal edge bevel was placed with a medium-grit diamond bur (#6844, Komet USA; Rock Hill, SC) **(Fig 3)**.[5-7] While

Figure 4: Silicone putty index from diagnostic wax-up used to establish the lingual shelf with an achromatic milky-white (MW) composite.

Figure 5: Dentin shade DA1 composite was used to create the dentin layer. This was feathered about halfway onto the incisofacial bevel. Creating vertical striations helps scatter the light and block the hard incisal edge.

Figure 6: View of internal calcification effects placed with the BL1 composite.

Figure 7: View of the final thin layer of MW composite over the incisal one-third.

Figure 8: Postoperative view of the final restorations.

Figure 9: Lateral view of final restorations with angled lighting showing seamless marginal blending on the facial surface.

this step is not always necessary, it is extremely helpful when trying to hide a hard incisal edge on such a small addition. Finally, an air abrasion unit (MicroEtcher II, Zest Dental Solutions; Carlsbad, CA) was used to micro etch the facial and incisal surfaces to help increase micromechanical bond strength.[8]

Using the diagnostic wax-up to fabricate a silicone putty index, the lingual shelf was first established on teeth #7-#10 with an achromatic milky-white composite (MW) **(Fig 4)**. It is extremely important to keep this layer thin and not let any of the MW shade feather onto the facial surface. If it does, then the hard incisal edge will be visible in the final restoration. Next, a dentin shade (DA1) was sculpted along the incisal third, just onto the facial bevel **(Fig 5)**. As this patient's other teeth did not have much incisal translucency, the incisal mamelons were kept subtle. Creating vertical lines within this layer helps scatter the light, which aids in hiding the hard incisal edge while also replicating the natural dentinal surface.[9] Taking care to avoid over application, a small amount of incisal (TRANS) was placed. The body enamel (EB1) was then placed just short of the final facial contour, leaving room to add subtle internal white calcification effects **(Fig 6)**.

Figure 10: Full-smile preoperative view showing old composite restoration on #8.

Figure 11: A 1:1 view showing color difference and poor marginal blending of existing composite on #8.

There are several techniques to create internal calcification effects. In this case an opaque bleach white composite (BL1) was used rather than a liquid resin.[10] A final thin layer of MW was then placed to just beyond the final facial contour to leave room for finishing and polishing **(Fig 7)**. A layer of glycerin gel (K-Y, Reckitt Benckiser; Parsippany, NJ) was used during the final photopolymerization to ensure a full cure of the oxygen inhibition layer.[11]

Finishing and polishing were completed with a series of discs (Sof-Lex, 3M; St. Paul, MN), carbide and diamond burs (#6844 and #H379, Komet), composite polishers (PDQ, KavoKerr; Brea, CA), and diamond polishing paste (Porcelize, Cosmedent; Chicago, IL).[12-14] The patient was quite pleased with the final results **(Figs 8 & 9)** and grateful for the conservative, noninvasive, and cost-effective treatment, as well as the fact that no anesthesia was necessary.

Case 2: Old Bonding Replacement

A female patient presented with an old, extremely unsightly composite on a maxillary central incisor (#8) **(Figs 10 & 11)**. Fortunately, anticipating the placement of new composite after clear aligner treatment (Invisalign), her orthodontist had skillfully positioned the affected tooth by leveling the gingival zenith with #9 instead of leveling the incisal edges, which would have left the gingival zeniths uneven. Treatment options offered at other dental offices included a single porcelain crown/veneer or porcelain crowns/veneers on #8 and #9 and even #7-#10 to facilitate color matching. The patient, averse to the idea of more tooth grinding, preferred the most conservative option of a direct composite veneer, which in her case required no drilling on natural tooth structure.

Alginate impressions were taken to fabricate bleaching trays and a diagnostic wax-up. The patient's anterior teeth did not have much incisal translucency, but there were some areas of chromaticity that needed to be replicated. A palate of six shades of composite (MW, DA2, EA1/EB1, BL1, TRANS) and two shades of colored resins (Blue and High Chroma Opaque) were used **(Fig 12)**. Often a single shade of A1 or B1 is not quite right for the dentin or enamel, but if the two are mixed in the proper proportions, it is possible to create a more desirable shade. The same formula was followed for establishing a lingual shelf and incrementally layering from back to front **(Figs 13 & 14)**. To help with the incisal chromatic effects, a combination of liquid resins was applied after the body enamel, and then a final thin layer of MW allowed those effects to show in the final restoration **(Figs 15 & 16)**.

For the finishing and polishing stages, the first step was to establish the overall primary outline form, which includes the facial line angles, incisal and facial embrasures, and three facial planes **(Fig 17)**. Once this framework was established, secondary and tertiary facial anatomy and textures were created. There is no one single bur or polisher that is indicated; it is the clinician's choice.

This case was selected for illustrative purposes because the natural surface texture of #9 was quite visible and more challenging to match compared to a smooth glossy finish. Accordingly, a silver reflective powder (Hi-Light) was used to greatly enhance visualization of the minutest details of the surface anatomy and texture of #9's natural enamel **(Fig 18)**. The powder was reapplied during the polishing sequence to ensure that work was progressing on the right track; when minor imperfections were spotted, the dentist backtracked to correct these before proceeding to the texturing stage. Texturing was completed with an air-driven, slow-speed friction handpiece (Star Dental Titan 3) **(Figs 19-23)**. The patient and her orthodontist were pleased with the result **(Figs 24 & 25)**.

> *"From a patient's perspective, the two biggest advantages of direct composite are affordability and tooth structure preservation."*

Figure 12: View of the composite shades (MW, DA2, EA1/EB1, BL1, TRANS) and liquid resin colors (Blue and High Chroma Opaque) used for this restoration.

Figure 13: With the aid of the silicone putty index, the lingual shelf was established with MW composite.

Figure 14: Dentin shade DA2 was used to create the dentin layer.

Figure 15: Using a gloved finger, equal amounts of EA1 and EB1 were mixed together on the composite pad to get a better color match, and then layered into place. Next, High Chroma Opaque and Blue liquid resins, along with BL1 composite, were used to better replicate and complement the chromatic and calcification effects seen on #9.

Figure 16: A final thin layer of MW was placed on the incisal one-third to allow the effects to show through.

Figure 17: A disc was used to establish initial facial outline form.

Figure 18: A silver reflective powder was used to enhance visualization of the surface anatomy and texture of #9's natural enamel.

Figure 19: A medium- or fine-grit diamond bur was used in a slow-speed, high-torque handpiece to define three facial planes and initiate facial grooves/lobes and tertiary anatomy.

Figure 20: A football/egg-shaped carbide bur was used to refine what was just developed by the diamond bur and to mimic the surface texture of #9 with subtle stippling.

Figure 21: A medium-grit diamond bur was used to create a fine perikymata effect.

Figure 22: A rubber polishing disc was used to erase and blend the texture to the desired results.

Figure 23: A silicone polishing brush was used to shine and polish without removing surface texture.

Figure 24: A 1:1 view of final restoration on #8 showing how the surface texture and characterization closely matches those of #9.

Figure 25: Full-smile postoperative view of the final direct composite veneer restoration on #8.

Case 3: Worn Maxillary/Mandibular Anterior Teeth

A male patient presented with moderate to severe wear on the maxillary and mandibular anterior teeth **(Figs 26-29)**. His posterior teeth were in good shape with almost no wear.[15] Having just finished orthodontic treatment, his occlusion was in a new, more ideal position so it was not known whether his protrusive parafunction would continue. The stressful nature of his work had also changed for the better. These factors were considered when the patient was presented with the restorative treatment and material options, as well as the risks of potential material failure over time.

In this particular case, the advantages of current affordability and tooth structure preservation outweighed the less-immediate disadvantage of durability issues. The patient chose to start with composite, knowing he could transition into the costlier, longer-lasting porcelain if he needed or wanted to in the future.

Once orthodontic treatment was completed, alginate impressions were taken to fabricate bleach trays and a diagnostic wax-up. The wax-up was evaluated on an articulator for excursive pathway movements to reproduce the best possible palatal contours of the upper incisors and incisofacial contours of the lower interiors.

Tooth preparation was completed with a prophy cup and pumice/water slurry to remove any plaque. A slight 1.5- to 2-mm incisofacial bevel was made at 45 degrees with a medium-grit diamond bur (#6844) to help with color blending. Finally, air abrasion (PrepStart, Zest Dental) was used to micro etch the surfaces. A total-etch technique was used and a bonding agent (OptiBond Solo Plus, Kerr Dental; Orange, CA) was applied and light-cured.

Using the silicone putty index, MW composite was used to establish the lingual shelf for teeth #6-#11 **(Fig 30)**. A serrated nonabrasive metal strip (Smart Strips, KaVo Kerr) was used to open the interproximal contacts from the bonding agent. In some cases, it is better to restore one or two teeth at a time; in other cases, such as the one described here, it is helpful to restore them all at once as it is easier to visualize the overall smile line, incisal edge positions, height-to-width ratios, and emergence profiles. It also speeds the process, thus reducing the time patients have to stay openmouthed. Since most of these procedures are done with no anesthetic and employ a lip retractor (e.g., OptraGate, Ivoclar Vivadent; Amherst, NY), wearing such a device for an extended period of time can be quite uncomfortable for some patients.

A sectional matrix (Composi-Tight 3D, Garrison Dental; Spring Lake, MI) normally used for posterior restorations was employed to further establish the incisal embrasures **(Figs 31 & 32)**. With this framework established, it was much easier to visualize where and how thin/thick the subsequent layers needed to be. An equal-parts mix of DA1 and DA2 was used to replicate the dentin morphology **(Fig 33)**. Before light-curing, a photograph was taken with cross-polarized filters (polar_eyes, PhotoMed; Van Nuys, CA) to ensure correct shade matching. (Cross-polarized photography removes all reflective light interference, making it easier to evaluate the actual color of the teeth and composite before and during the procedure.[16]) The next layer used was a translucent composite (TRANS) along the incisal edge to provide subtle light transmission to replicate natural opalescence and translucency. A body enamel of shade B1 was then sculpted to full contour in the middle one-third and feathered incisally to leave room for a final thin layer of MW along the incisal one-third. The same procedure was completed for the six lower anteriors **(Fig 34)**.

In consideration of the appointment's lengthy and tiring aspects for both patient and dentist, the composites were just given a quick general shaping, polish, and occlusal verification. At this time immediate postoperative photographs were also taken so the dentist could evaluate the initial polish and have a clear understanding of what details would require fine-tuning at the final polish appointment **(Fig 35)**. The patient was sent home to try out his new smile. At the final polish appointment, the dentist—having reviewed postoperative photographs and in collaboration with patient feedback—finalized the detail work to achieve seamless integration between the restorations and natural teeth.

Figures 26-29: Preoperative views of maxillary and mandibular anterior teeth showing post-orthodontic tooth positioning and worn incisal edges.

Figure 30: View of lingual shelf established with MW composite using the silicone putty index.

Figure 31: A metal sectional matrix was used to further develop the incisal embrasures with MW composite.

Figure 32: Lateral view of lingual shelf showing how this layer was kept thin, allowing room for the dentin shade that follows to be thick enough to block out the hard incisal edge.

Figure 33: A mixture of DA1/DA2 composite was sculpted to replicate the dentin morphology.

Figure 34: View of lower anteriors with lingual shelf established with MW composite using the silicone putty index as a guide.

Figure 35: Basic shaping and polishing was done at the end of the first appointment.

TIPS

Using Composite Resin to Restore Four or More Anterior Teeth

BEGINNER

- In preparation for working on composite, first learn anterior tooth morphology and how to wax anterior teeth.
- Work on one tooth at a time. This will take longer, but will minimize the chance of bonding interproximal contacts together.
- When working on a single tooth, isolate the adjacent teeth with polytetrafluoroethylene (PTFE) tape. Some prefer to first isolate with Mylar strips to do the etch and bond, and then place the tape so that it is free of any bonding resin.

INTERMEDIATE

- For greater time efficiency, layer the central incisors and canines concurrently. However, create each lingual shelf one at a time to prevent the adjacent lingual shelves from connecting and bonding together.
- Isolate the lateral incisors with PTFE tape and layer the central incisors and canines at the same time. For the central incisors, after curing the bonding resin, use a nonabrasive serrated interproximal reduction (IPR) strip to maintain the interproximal contact and repeat after each subsequent layer, as needed.
- Create each lingual shelf one at a time. After all the lingual shelves are established, use a medium- or fine-grit disc to refine the incisal edge and embrasure form. This should prevent creating any dust that interferes with subsequent layers. If dust is noticed, however, remove it using a small amount of wetting resin on a sable brush before continuing to layer. When placing the final layer, use the "Mylar pull" technique (i.e., using a Mylar strip as an instrument, rather than a matrix) one at a time to get a smooth transition of composite from facial to lingual.

ADVANCED

- Layer all teeth at the same time. Doing so provides an overall view of incisal length, smile line flow, and symmetry of tooth size and ratios, allowing clinicians to notice and resolve any minor adjustments as they are encountered during the actual layering process.
- The lingual shelf can be created singly or all at once. If doing all at once, position the silicone putty index orally and bring the composite to the putty rather than placing the composite in the putty and then adapting into position. The former technique allows for more sculpting control, thereby minimizing overflow; with the latter technique there is a higher risk of composite overflow from the lingual side going unnoticed into the interproximal contact area.
- If excess composite from the lingual shelves happens to connect the embrasure and contact area, use a thin IPR diamond disc to carefully shape and reopen the contact and then refine with medium- and fine-grit discs. Being able to layer all teeth at once is also helpful because you can see in real time how each layer matches in hue, chroma, value, translucency, and characterization. A Mylar strip can then be used to shape the final layer interproximally one tooth at a time beginning on one end.
- Another technique for managing interproximal contacts is to use a posterior sectional matrix to help shape the composite interproximally. Once the lingual shelf is established, use a serrated IPR strip to open the contact area from any bonding resin. Place the sectional matrix longitudinally and use a small amount of MW composite to create a thin layer that connects the lingual self to the facial interproximal line angle. Instead of feathering the MW composite onto the facial surface, adapt it up against the matrix and remove excess until the desired shape is created. Once this is done on adjacent teeth, the interproximal contact is established and facial layering is all that is needed for finalization.

Figures 36-44: Postoperative views of maxillary and mandibular anterior direct composite restorations showing seamless integration and harmony with the natural teeth.

The new smile "reveal" at the completion of treatment is always a rewarding moment, and this case was no exception. Even at the basic polish stage at the end of the long appointment, the patient was extremely grateful for his enhanced smile. The following week when he returned to complete the detailed texturizing and polishing, he marveled at how well the composite material blended into his existing teeth to produce such natural-looking results **(Figs 36-44)**. He was also very thankful for the treatment's conservative nature.

Additional Recommendations

As in each of the three examples described in this article, clinicians treating cases involving a direct composite bonding post-orthodontic restorative solution should do the following:

1. Instruct patients who have just finished with clear aligner orthodontic treatment to wear a provisional retainer until the new restorative work is completed.
2. Advise patients that when they schedule their restorative appointment, they also should schedule their final orthodontic retainer impression appointment for the next day in order to minimize any tooth shifting.
3. Whenever possible, schedule these longer, more challenging restorative appointments for the typically less busy end of the day; this allows clinicians greater focus to do their best work without feeling rushed or distracted.

Figures 45 & 46: Case 1, two-year postoperative view.

Figures 47 & 48: Case 2, two-year postoperative view.

Figures 49 & 50: Case 3, two-year postoperative view.

Summary

Patient awareness and understanding of modern dental materials and procedures is greater than ever as a result of social media and people sharing their own smile-enhancing dental treatment experiences. Many of these treatments are being done with indirect porcelain restorations, but not all. More people are seeing beautiful examples of direct composite bonding to repair chipped or worn incisal edges, or excess spacing, and are seeking practitioners who are proficient at this type of dentistry. Orthodontists are also educating their patients about this minimally invasive option. Although the polychromatic layering technique is the ultimate in direct composite artistry, newer single-shade composite systems are making it easier to obtain acceptable results with one shade.[17] Even with a single-shade system, the layering principles are applicable with the use of a silicone putty index, lingual shelf for establishing the backdrop, and facial contour shaping.

As dental materials continue to evolve and allow for more conservative procedures, restorative dentists would do well to consider and become proficient at direct anterior composite bonding as a more economical and noninvasive alternative to costly porcelain veneers for their adult patients requiring post-orthodontic smile enhancements.

It is the author's opinion that the polychromatic layering of dental composites can be mastered by anyone who devotes the time and effort to practice the technique. The benefits are well worth it: Patients appreciate the minimally invasive approach, and dentists can not only derive the satisfaction of creating conservative and esthetic restorations, but also can attract and serve a new adult patient segment, affording them the opportunity to grow their practices and areas of expertise. The restorations are still doing well after two and a half years **(Figs 45-50)**.

Acknowledgments

The author thanks Dr. Paula Leone and Dr. Greg Vaughn (Leone & Vaughn Orthodontics; Seattle and Bellevue, WA) and Dr. Steven Lemery (Overlake Orthodontics; Bellevue, WA) for their outstanding orthodontic care of the patients whose cases are featured in this article.

References

1. Kim TW, Echarri P. Clear aligner: an efficient, esthetic, and comfortable option for an adult patient. World J Orthod. 2007;8(1):13-8.
2. Rouse JS. Autonomic nervous system trial: control and resolve for sleep-breathing disorders. Compend Contin Educ Dent. 2016 May;37(5):316-21.
3. Brown K. Transitional bonding for severely eroded dentition. J Cosmetic Dent. 2017 Spring;33(1):28-40.
4. Collares K., Opdam NJM, Laske M, Bronkhorst EM, Demarco FF, Correa MB, Huysmans MCDNJM. Longevity of anterior composite restorations in a general dental practice-based network. J Dent Res. 2017 Sep;96(10):1092-9.
5. LeSage B, Milnar F, Wohlberg J. Achieving the epitome of composite art: creating natural tooth esthetics, texture, and anatomy using appropriate preparation and layering techniques. J Cosmetic Dent. 2008 Fall;24(3):132-41.
6. Douglas TA, Leinfelder KF. Composite resin restorations: a simplified approach. Inside Dent [Internet]. 2008 Jun;4(6). Available from: https://www.aegisdentalnetwork.com/id/2008/06/esthetics-composite-resin-restorations-a-simplified-approach
7. Peyton J. Finishing and polishing techniques: direct composite resin restorations. Pract Proced Aesthet Dent. 2004 May;16(4)293-8.
8. Chaiyabutr Y, Kois JC. The effects of tooth preparation cleansing protocols on the bond strength of self-adhesive luting cement to contaminated dentin. Oper Dent. 2008 Sep-Oct;33(5):556-63.
9. Guadix JT. The biomimetic equation: bio-emulation and biomechanics for direct and indirect restorations. Bio-emulation symposium. 2015; Oslo, Norway.
10. Brown K. How to create natural looking tooth calcification effects within indirect composite resins. AACD blog post. [2019 Sept 30]. Available from: https://aacd.com/express/newsviewpost&id=12796
11. Park HH, Lee IB. Effect of glycerin on the surface hardness of composites after curing. J Kor Acad Cons Dent. 2011 Nov;36(6):483-9.
12. Fahl N Jr. A polychromatic composite layering approach for solving a complex Class IV/direct veneer-diastema combination: part I. Pract Proced Aesthet Dent. 2006 Nov-Dec;18(10):641-5.
13. Fahl N Jr. A polychromatic composite layering approach for solving a complex Class IV/direct veneer/diastema combination: part II. Pract Proced Aesthet Dent. 2007 Jan-Feb;19(1):17-22.
14. Strain RL. Class IV composite repair: a heavily textured central incisor. J Cosmetic Dent. 2014 Spring;30(1):14-9.
15. Meyers IA. Diagnosis and management of the worn dentition: conservative restorative options. Ann R Australas Coll Dent Surg. 2008 Jun;19:31-4.
16. Villavicencio-Espinosa CA, Narimatsu MH, Furuse AY. Using cross-polarized photography as a guide for selecting resin composite shade. Oper Dent. 2018 Mar/Apr;43(2):113-20.
17. Brown K, Gillespie G. Advancements in composite resin materials enable streamlined direct restoration process. Comp Contin Educ Dent. 2019 Nov/Dec;40(suppl 2):2-6. **jCD**

Dr. Brown has a practice in Bellevue, Washington, where he specializes in minimally invasive dental esthetics. He can be reached at kbrown@jensenbrowndds.com

jCD Self-Instruction

Operative (Restorative) Dentistry (CE) Exercise No. jCD43 AGD Subject Code: 250

3 Hours Credit

This Continuing Education (CE) self-instruction examination is based on the article *Post-Orthodontic Restorative Solution: Conservative Techniques with Direct Composite Bonding* by Kevin M. Brown, DDS, AAACD. This article appears on pages 84-97.

The exam is free of charge and available to AACD members only. AACD members must log onto www.aacd.com/jcdce to take the exam. Note that only Questions 1 through 5 appear in the printed and digital versions of the *jCD*; they are for readers' information only. This exercise was developed by members of the AACD's Written Examination Committee and *jCD*'s Contributing Editors.

1. What is an advantage of direct composite restorations compared to indirect porcelain restorations?

a. Less clinician skill is required.
b. Composite material stains less.
c. It is more affordable.
d. There is usually more tooth preparation involved.

2. What is the main disadvantage of direct composite bonding over bonded porcelain restorations?

a. staining
b. longevity
c. polish
d. shading

3. What is the benefit of using an air abrasion unit on the tooth preparation?

a. It helps with color blending.
b. It increases micromechanical bond strength.
c. It helps in concealing a hard incisal edge.
d. It helps with the final contouring.

4. What is the key factor in creating reflective and deflective zones in direct composite restorations?

a. shade of the composite
b. lighting
c. postoperative photographs
d. addition of tints and stains

5. What is required for successful restorations with direct composite?

a. The use of a single bur and polisher for proper anatomic detail.
b. All imperfections can be corrected at the end of final polishing.
c. Using a high-speed handpiece to produce a better texture and polish.
d. Study models for a diagnostic wax-up to ensure optimal bond strength of the composite.

To take the complete exam, log onto www.aacd.com/jcdce

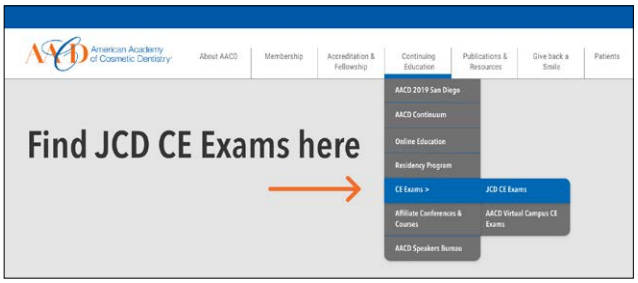

AACD Self-Instruction Continuing Education Information

Exams will be available for 3 years from publication date for dentists, and 1 year from publication date for laboratory technicians.

Original release date: November 30, 2020. Expiration for dentists: November 30, 2023. Expiration for laboratory technicians: November 30, 2021.

To receive course credit, AACD members must answer at least 70% of the questions correctly.

Participants will receive test results immediately and can only take each exam once. A current web browser is necessary to complete the exam.

Verification of participation will be sent to AACD members via their MyAACD account. All participants are responsible for sending proof of earned CE credits to their state dental board or agency for licensure purposes.

For more information log onto www.aacd.com/jcdce.

Contact the AACD at email: info@aacd.com or phone: 800.543.9220 or 608.222.8583.

ADA CERP® | Continuing Education Recognition Program

ADA CERP is a service of the American Dental Association to assist dental professionals in identifying quality providers of continuing dental education. ADA CERP does not approve or endorse individual courses or instructors, nor does it imply acceptance of credit hours by boards of dentistry. AACD designates these activities for 1-3 credit hours to continuing education credits. Concerns or complaints about a CE provider may be directed to the provider or to ADA CERP.

CDT CONTINUING APPROVED EDUCATION

NBC Approved Qualified Continuing Education Provider.

PACE ACADEMY of GENERAL DENTISTRY PROGRAM APPROVAL FOR CONTINUING EDUCATION

American Academy of Cosmetic Dentistry® Nationally Approved PACE Program Provider for FAGD/MAGD credit. Approval does not imply acceptance by any regulatory authority or AGD endorsement. 1/1/2019 to 12/31/2022.
Provider ID# 216647

iTero®

5D

"Hi, I'm
iTero Element® 5D.
And I expand your
spectrum of visualization."

Let patients see what you see with state-of-the-art visualization that helps take your practice to new levels of innovation. See beyond the current spectrum of what's possible for aid in diagnostics, patient engagement, and digital workflow with the iTero Element 5D imaging system.

Learn more about the first 3D intraoral scanner with NIRI technology at iTero.com.

Customer Advocacy: 800-577-8767

AGD MEMBER'S CHOICE AWARD

3D digital impressions

Simulation capability

Intraoral camera

Real-time TimeLapse

Proximal caries detection aid

No harmful radiation

align

©2020 Align Technology, Inc. All rights reserved. Invisalign, iTero, iTero Element, the iTero logo, among others, are trademarks and/or service marks of Align Technology, Inc. or one of its subsidiaries or affiliated companies and may be registered in the U.S. and/or other countries. MKT-0004067

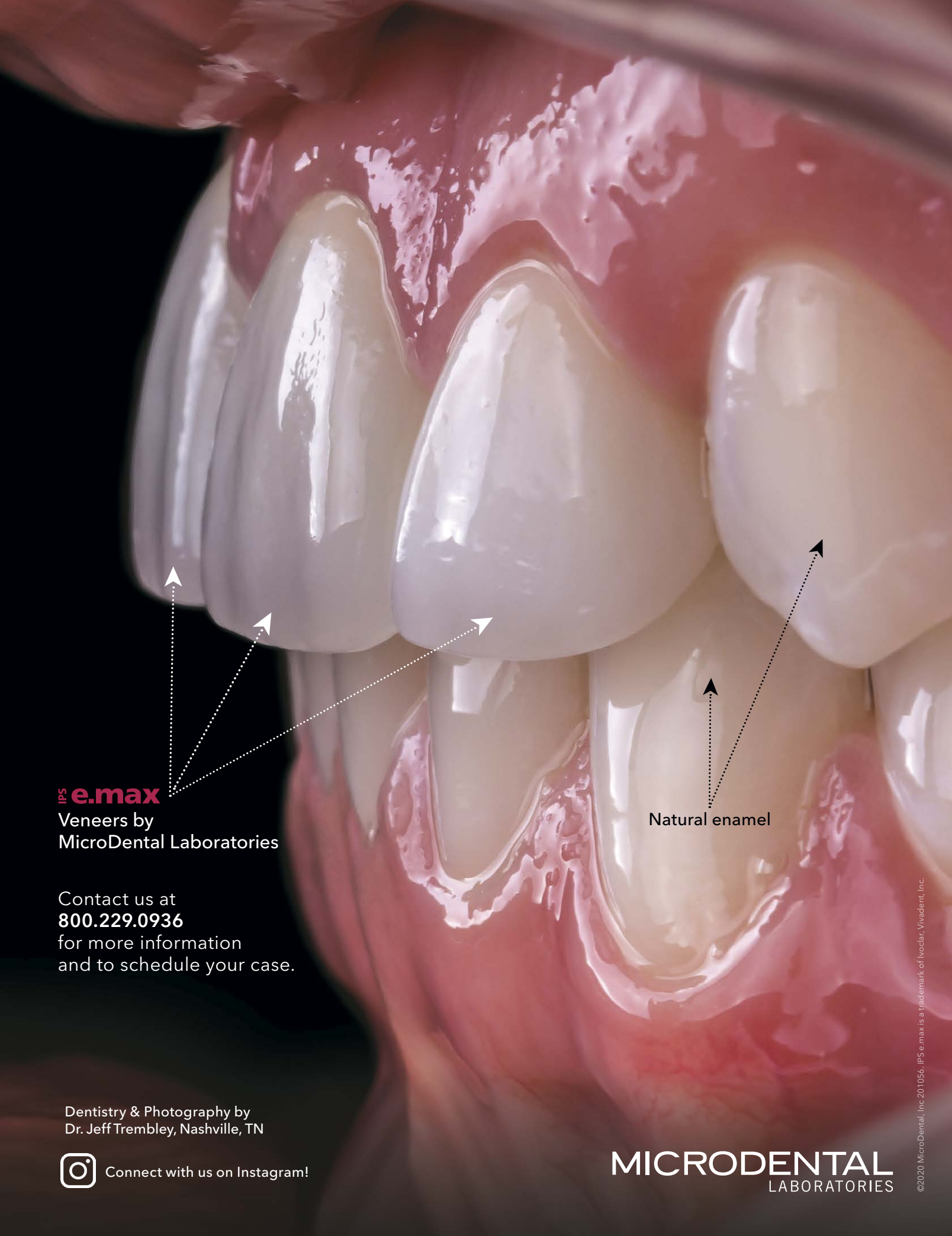
IPS e.max
Veneers by
MicroDental Laboratories
Natural enamel
Contact us at
800.229.0936
for more information
and to schedule your case.
Dentistry & Photography by
Dr. Jeff Trembley, Nashville, TN
Connect with us on Instagram!
MICRODENTAL
LABORATORIES
©2020 MicroDental, Inc 201056. IPS e.max is a trademark of Ivoclar, Vivadent, Inc.